

Sudden loss of vision

N Du Toit MBChB, DipOphth(SA), FRCS(Ed), FCOphth(SA), MMed

To cite this article: N Du Toit MBChB, DipOphth(SA), FRCS(Ed), FCOphth(SA), MMed (2013) Sudden loss of vision, South African Family Practice, 55:3, 235-240, DOI: 10.1080/20786204.2013.10874342

To link to this article: <http://dx.doi.org/10.1080/20786204.2013.10874342>



© 2013 SAAFP. Published by Medpharm.



Published online: 15 Aug 2014.



Submit your article to this journal [↗](#)



Article views: 161



View related articles [↗](#)

Sudden loss of vision

Du Toit N, MBChB, DipOphth(SA), FRCS(Ed), FCOphth(SA), MMed, Senior Lecturer
University of Cape Town; Groote Schuur Hospital, Cape Town

Correspondence to: Nagib du Toit, e-mail: nagib.dutoit@uct.ac.za

Keywords: sudden loss of vision, transient visual loss, retinal vascular occlusion, vitreous haemorrhage, retinal detachment

Abstract

Sudden loss of vision, which causes consternation for both the patient and clinician, is a clinical problem that is encountered fairly regularly in most primary healthcare settings. Sudden visual loss or obscuration which is transient may simply be a symptom of a dry eye or a migraine, but it may also be the onset of irreversible visual loss or a stroke. Most cases of sudden loss of vision are serious, require referral and have an associated underlying systemic disease. Visual loss is usually unilateral, but may be bilateral. This clinical problem may present a diagnostic challenge. No cause may be found in some instances. However, it is important to remember that the more sinister causes of sudden visual loss, such as temporal arteritis, carotid or cardiac emboli that cause retinal vascular occlusion, retinal detachment, vitreous haemorrhage and orbital masses, need to be identified early. Using the duration of the visual loss as the primary differentiating factor, with associated symptoms and signs as supplementary factors, the causes can be narrowed down. A thorough history, goal-directed examination, proper investigation and appropriate referral should enable early diagnosis and adequate management. This will prevent further ocular morbidity, and even patient mortality.

© Peer reviewed. (Submitted: 2012-10-31 Accepted: 2012-12-15.) © Medpharm

S Afr Fam Pract 2013;55(3):235-240

Introduction

A sudden loss of vision causes consternation for both the patient and clinician. Sudden visual loss or obscuration which is transient may simply be a symptom of a dry eye, or it may be the onset of irreversible visual loss or a stroke.¹ Most cases of sudden loss of vision are serious, require referral and have an associated underlying systemic disease. Associated symptoms provide important clues to the cause. The need for an update in the field of primary healthcare eye care knowledge became apparent in a recent study that was carried out among general practitioners.² This article is the second in a series which attempts to address this issue.

Approach to the patient

A goal-directed assessment of a patient who presents with sudden loss of vision is required. A history of the duration of visual loss is critical. As pointed out by Goold et al,¹ it is important to distinguish between true sudden visual loss and the sudden realisation that vision has been lost. Spontaneous loss of vision when both eyes are open is probably acute, while gradual monocular loss of vision may appear to be acute when the normal eye is temporarily obscured or closed, thus revealing poor vision in the other eye. Sudden visual loss is usually unilateral, but may

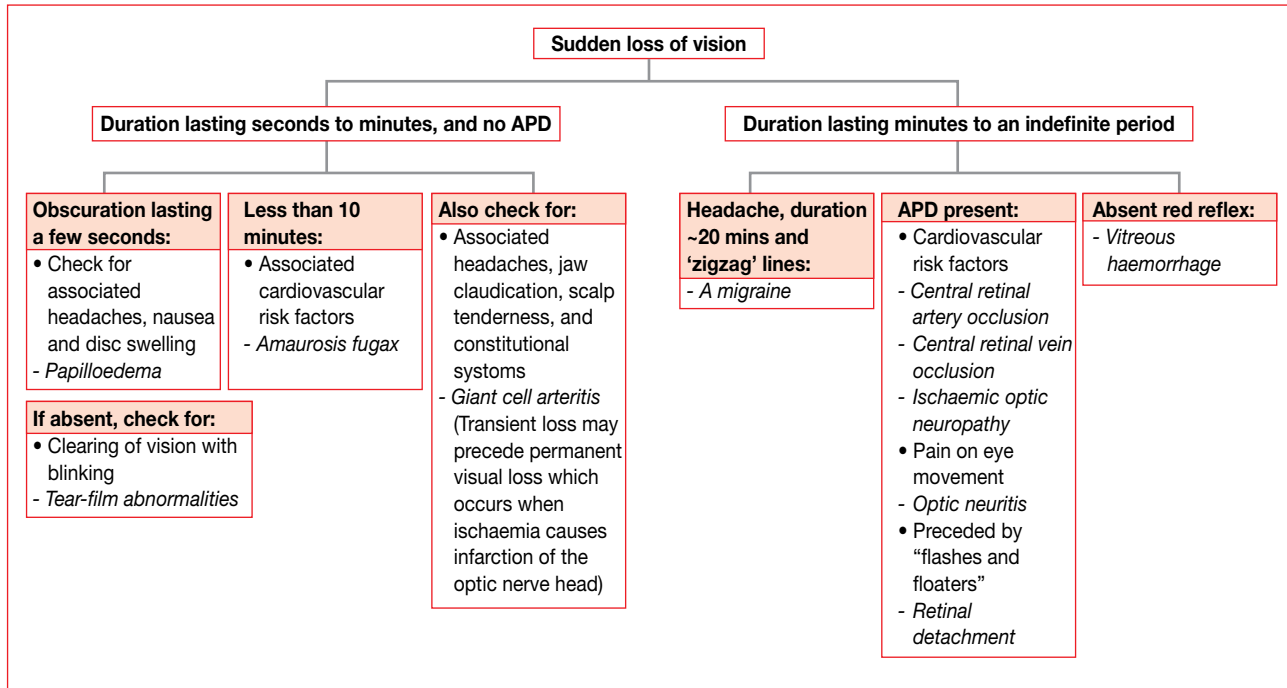
occasionally be bilateral. An examination should focus on visual acuity (VA), confrontation visual field testing, pupil testing for the presence of an afferent pupil defect (APD), assessment of the red reflex and fundoscopy. Many of the conditions discussed below will initially cause temporary visual loss, but several may become permanent if not promptly managed.³

The more common conditions that cause sudden loss of vision can be divided into two groups, based on the duration of the visual loss. The conditions in these two categories are listed in Table I. Some of these will be discussed later. Trauma as a cause of visual loss is not discussed here.

Table I: The more common clinical conditions that cause sudden loss of vision

Transient visual loss	Visual loss of longer or permanent duration
Amaurosis fugax	Central retinal artery occlusion
Migraines	Central retinal vein occlusion
Papilloedema	Vitreous haemorrhage
Tear film disturbance	Ischaemic optic neuropathy
Functional visual loss	Optic neuritis
	Retinal detachment

It is important to establish whether the visual loss is unilateral or bilateral, as a bilateral visual disturbance rarely indicates



APD: afferent pupillary defect

Figure 1: Flow chart for the primary care assessment of patients with a sudden loss of vision

bilateral ocular or optic nerve disease, but more commonly is a sign of disease posterior to the optic chiasm, including the optic tract and cerebral cortex. It may indicate impaired posterior cerebral circulation or even a migraine.¹ Transient loss of vision, particularly in patients with significant cardiovascular risk factors, may be owing to amaurosis fugax, resulting from atherosclerosis. These patients require further investigation. A floating, mobile scotoma is consistent with vitreous pathology, as the vitreous undulates relative to the retina when the globe moves.¹ Testing visual fields to confrontation is of importance in cases where history points to a retinal or neurological cause of the loss of vision.

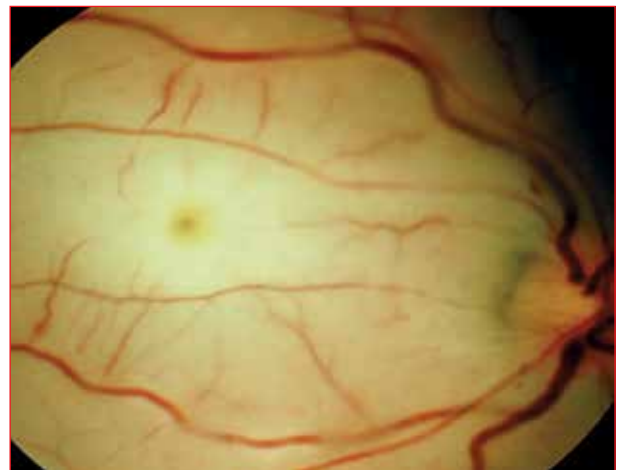Keeping in mind that normal pupil reactions require normal oculomotor and optic nerve functioning, it is important to assess the direct, as well as consensual, pupillary responses in each eye. Subtle differences between the two optic nerves may be detected by carrying out the swinging flashlight test for a relative APD. It is important to assess the red reflex in each eye. This may be obscured by media opacities, such as vitreous haemorrhage, as well as intraocular pathology, for example, retinal detachment.⁴ Fundoscopy should be performed after pupil dilation if acute angle closure glaucoma is not suspected. An examination of the cranial nerves may also help to diagnose orbital disease. In any setting, papilloedema requires prompt imaging.¹ Loss of vision may be associated with migraine. Usually, the visual aura of a migraine presents as zigzag lights or shimmering colours and precedes the headache. Atypical cases should be referred to a neurologist.

Using the duration of the visual loss as the primary differentiating factor, with associated symptoms and signs as secondary factors, the causes can be narrowed down, as indicated in Figure 1.

Clinical conditions

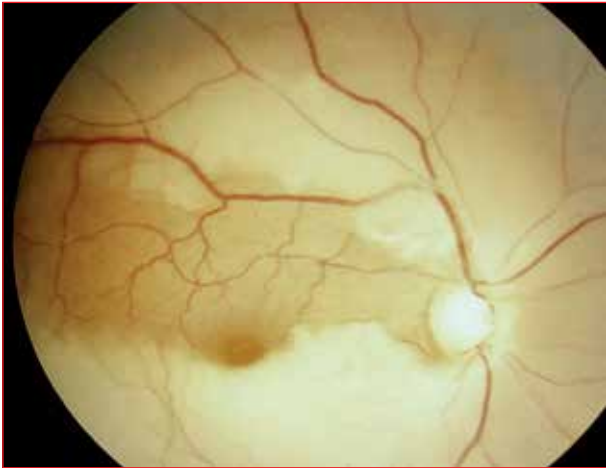
Central retinal artery occlusion

Blood cannot get into the eye, usually as a result of embolic (e.g. patients with endocarditis) or thrombotic (e.g. patients with atherosclerosis), occlusion of the retinal artery. Arteritic occlusion, as a result of giant cell arteritis (GCA), is less common. Usually, patients present with the VA of “finger-counting” or worse. An APD is present and the retina



Source: Division of Ophthalmology, University of Cape Town

Figure 2: Non-perfused, thread-like arteries that are partly obscured by the retinal oedema are apparent



Source: Division of Ophthalmology, University of Cape Town

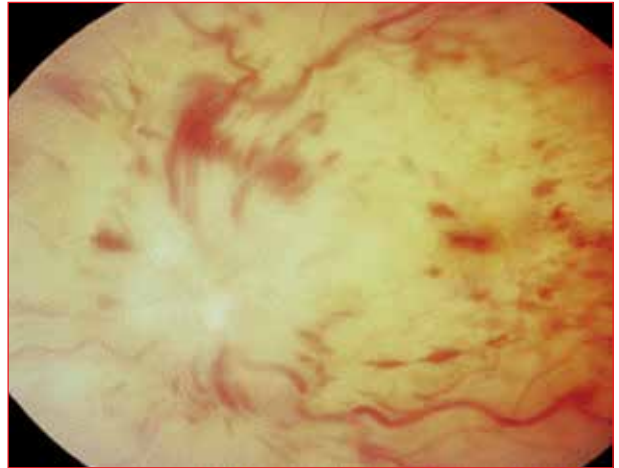
Figure 3: Central retinal artery occlusion with cilioretinal sparing

appears pale (infarcted). Non-perfused, thread-like arteries that are partly obscured by the retinal oedema are apparent (Figure 2). A “cherry-red spot” at the macula, because of the visibility of the underlying intact choroidal circulation, is a classic sign. [Note: The macula is supplied by an artery from the ciliary circulation in approximately 20% of people. In these cases, central retinal artery occlusion (CRAO) (Figure 3) results in a perfused macula in “a sea of infarcted retina”.] Hemiretinal artery occlusions, where only half of the retina is affected, may also occur.⁴ Branch retinal artery occlusions create a more limited scotoma, while cilioretinal artery occlusions may only reduce the central vision.³

If embolus or thrombosis is suspected, patients need an age-appropriate stroke workup and appropriate management. The following measures to prevent permanent retinal damage and possible dislodgement of the embolus⁵ can be taken in these patients, if they are seen within four hours of the event: digital massage of the globe and oral acetazolamide to reduce intraocular pressure. Breathing into a paper bag (the patient) which causes an increase in partial pressure of carbon dioxide and vasodilatation. If symptoms suggest GCA, an elevated erythrocyte sedimentation rate (ESR) and platelet count will confirm the diagnosis. High-dose oral steroids should be started before referral to an ophthalmologist.

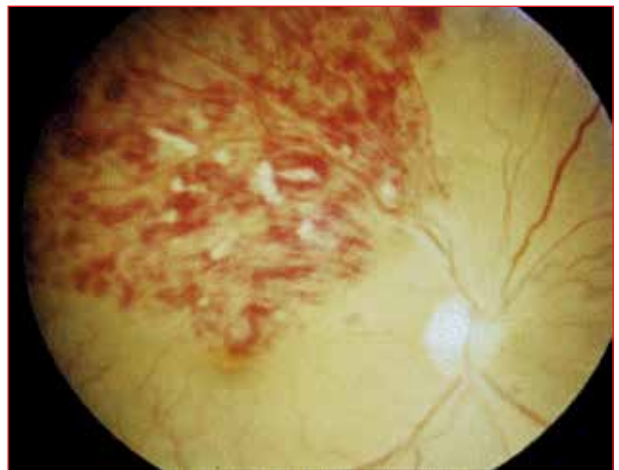Central retinal vein occlusion

Blood cannot get out of the eye, usually secondary to poorly controlled hypertension or diabetes. Central retinal vein occlusion (CRVO) can also be caused by raised intraocular pressure, as well as hypercoagulable states, including systemic malignancy.⁴ Hypertension-related CRVO and branch vein occlusions are usually caused by sclerotic changes in the artery which contribute to compression of the vein. At presentation, VA is decreased to somewhere between 6/18 and “finger-counting”. Dilated, tortuous veins are visible on fundoscopy. Cottonwool spots,



Source: Division of Ophthalmology, University of Cape Town

Figure 4: Cottonwool spots and retinal haemorrhages occur in all four quadrants in central retinal vein occlusion



Source: Division of Ophthalmology, University of Cape Town

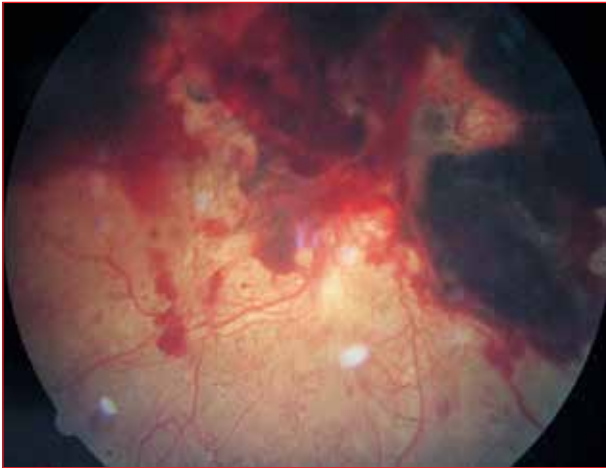
Figure 5: Cottonwool spots and retinal haemorrhages occur only in affected quadrants in branch vein occlusions

retinal haemorrhages [which occur in all four quadrants in CRVO (Figure 4), and only in affected quadrants in branch vein occlusions (Figure 5)], as well as disc swelling, are pathognomonic. If there is very severe ischaemia, a “blood and thunder” retinal appearance is evident with VA of “finger-counting”, or worse. Vein and artery occlusions both cause sudden loss of vision and the resultant chronic ischaemia can also lead to neovascularisation of the disc, retina and iris; vitreous haemorrhage; and neovascular glaucoma.

Patients should have their blood pressure and blood glucose checked to exclude hypertension and diabetes before referral to an ophthalmologist.⁴

Vitreous haemorrhage

Painless sudden loss of vision in a patient with diabetes or hypertension may suggest vitreous haemorrhage, which is often described as being heralded by “a shower of black dots”. Subhyaloid (Figure 6), retinal or subretinal haemorrhages are more discrete, less mobile, and may



Source: Division of Ophthalmology, University of Cape Town

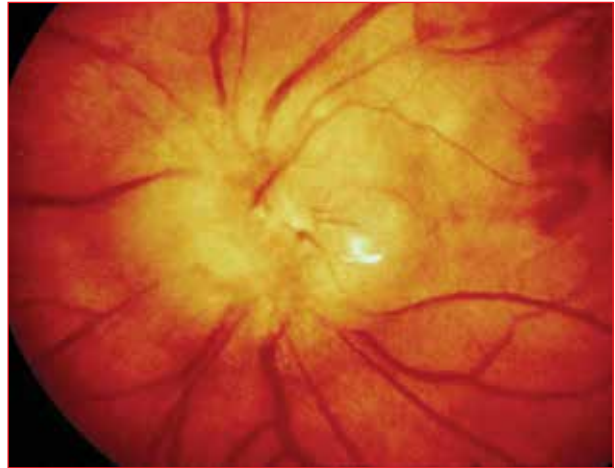Figure 6: Subhyaloid retinal or subretinal haemorrhages are more discrete, less mobile, and may initially appear as a red, brown or black scotomata

initially appear as a red, brown or black scotomata.¹ Bleeding into the vitreous cavity results from any disease that causes retinal ischaemia (e.g. diabetes, CRAO and CRAO). These can stimulate the production of angiogenic factors with resultant new vessel formation. Haemorrhage occurs from these friable vessels into the vitreous gel. Nonischaemic causes of vitreous haemorrhage include trauma, bleeding disorders, tumours and retinal tears (with or without detachment). Patients experience “floaters” in the affected eye, followed by loss of vision. After major haemorrhage, the red reflex is lost.⁴ Vitreous haemorrhage of any cause must be referred to an ophthalmologist for assessment.

Ischaemic optic neuropathy

Ischaemia, due to occlusion of the short posterior ciliary arteries, results in infarction of the optic nerve head and leads to ischaemic optic neuropathy.⁴ Causes may be arteritic (GCA) or nonarteritic (arteriosclerotic). The physician should always consider GCA if the patient is older than 60 years of age. Patients with GCA often have malaise, myalgia, jaw claudication, weight loss and scalp tenderness. Neuropathy causes severe loss of vision and often affects the superior half of the optic disc, with a resultant inferior altitudinal field defect, which can be picked up on confrontation visual field testing. The affected part of the disc is pale and swollen on fundoscopy (Figure 7).

Elevated ESR and C-reactive protein (CRP) should be assessed if GCA is suspected. The ESR may be normal in 17% of patients with GCA. The sensitivity of ESR alone for the diagnosis of GCA is 84.9%, the sensitivity of CRP alone is 97.5%, while the sensitivity of raised ESR and CRP is 99.2%.⁶ The platelet count is also important as GCA is six times more probable in a patient with thrombocytosis, than in a patient with a normal platelet count.⁶ If GCA is



Source: Division of Ophthalmology, University of Cape Town

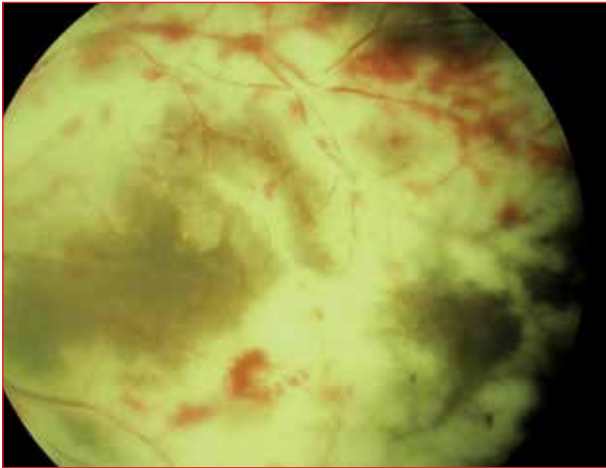
Figure 7: The affected part of the disc is pale and swollen on fundoscopy in ischaemic optic neuropathy

diagnosed, oral prednisone of at least 1 mg/kg is needed and immediate referral required, as the other eye may also become affected if treatment is not started urgently.⁴ The patient needs a temporal artery biopsy to confirm the diagnosis and will have to go on long-term steroid therapy, the aim of which is to further limit vision loss, as well as to protect the fellow eye. There is no immediate treatment for the nonarteritic type of ischaemic optic neuropathy.¹ All patients should be referred for further management.

Retinal detachment

The retina stays attached to the wall of the eye by fastening to the retinal pigment epithelium (RPE), which, in turn, is connected to the uveal tract and the sclera. There is an embryological potential space, analogous to the ventricles of the brain, between the neurosensory retina and the RPE, which stays closed by a pump mechanism in the RPE. If a hole develops in the retina, fluid leaks into this potential space and the retina detaches. In other words, the neurosensory retina separates from the RPE. Detachment may be rhegmatogenous (secondary to a retinal tear), tractional (involving scar tissue, e.g. with trauma, and in proliferative diabetic retinopathy) or exudative (e.g. with uveitis, tumours and severe hypertension).

Signs and symptoms of the rhegmatogenous type include flashing lights (photopsia) and floaters (“dancing flies”) because of the development of posterior vitreous detachment. These are followed by showers of dots or “tadpoles” as vitreous haemorrhage ensues. A “grey curtain” or shadow that comes over the field of vision from the periphery indicates detachment of the retina. The differential diagnosis of these symptoms includes scintillating scotomata/fortification spectrum of a migraine for the “flashes”, and amaurosis fugax for the “curtain”. Both of these cause intermittent loss of vision and require



Source: Division of Ophthalmology, University of Cape Town

Figure 8: Cytomegalovirus retinitis

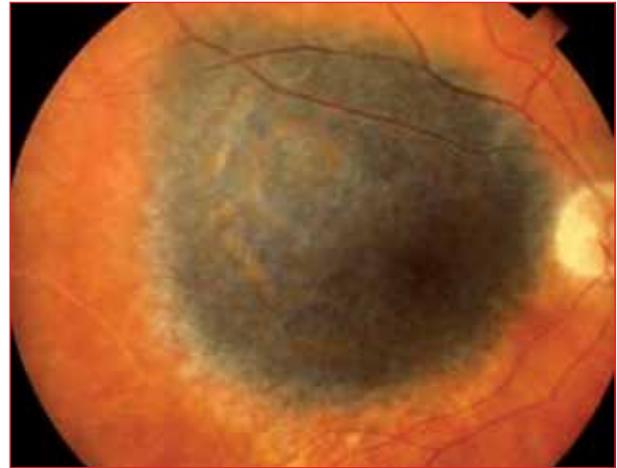primary care management. Loss of vision or part of the visual field only, if the macula is still attached, follows. The clinician should be particularly aware of detachment in patients with a history of cataract surgery, high myopia, recent eye trauma and a personal or family history of retinal detachment.¹ Loss of the red reflex, the presence of APD and an elevated, detached retina on fundoscopy, complete the spectrum of signs. Referral for urgent surgery is necessary if the vision is still good and if the detachment is of recent onset (within the last few days).

Optic neuritis

Optic neuritis refers to inflammation of the optic nerve owing to demyelination or infective, immune and infiltrative causes.¹ Compressive lesions in the orbit need to be eliminated as they may have a similar appearance, but also have associated proptosis and cranial nerve palsies.³ The common causes are multiple sclerosis, syphilis, human immunodeficiency virus, sarcoidosis and idiopathy. Optic neuritis occurs in 70% of patients with known multiple sclerosis and may be the first sign of demyelinating disease.¹ Loss of vision varies from mild to profound. A central scotoma, APD and loss of colour vision, are usually present. Patients may have pain on eye movement in typical cases. The optic disc may be swollen or normal, if the inflammation is retrobulbar. Repeated attacks are not uncommon and the other eye may become affected as well, especially with demyelination. Usually, visual recovery is good after a single attack. Pallor of the temporal part of the disc may develop following repeated attacks. Referral for treatment is essential.

Retinitis and choroiditis

Inflammation of the retina and/or choroid, which may be infective, immune-mediated or idiopathic, may result in sudden loss of vision. More common causes include tuberculosis, syphilis, cytomegalovirus retinitis (Figure 8)



Source: Division of Ophthalmology, University of Cape Town

Figure 9: Melanoma appears as a solid elevated lesion in tumours

and toxoplasma chorioretinitis.⁴ In toxoplasmosis, old pigmented scar tissue is seen, surrounded by sheathed vessels and vitreous haze. In viral, bacterial or protozoal retinitis, vision may be minimally affected until the fovea or optic nerve is affected.⁷ There may be a poor red reflex. Sudden loss of vision means that referral should be urgent in order to save the other eye.

Tumours

Certain ocular tumours can cause sudden loss of vision. Choroidal metastases, usually from the breast or lung, choroidal malignant melanoma, as well as cancer and melanoma-associated retinopathy may be causative.⁴ Melanoma of the choroid is the most common primary intraocular malignancy in adults. On fundoscopy, the majority of observed pigmented choroidal lesions are benign naevi. Choroidal malignant melanoma can present with flashing lights or visual loss, which may occur when fluid exudation or a solid tumour detach the fovea. Melanoma appears as a solid elevated lesion (Figure 9), often with greyish pigmentation. With metastases, vision is usually normal or distorted until a secondary exudative retinal detachment suddenly detaches the macula. Cancer and melanoma-associated retinopathy can cause sudden, bilateral blindness with no retinal findings. The blindness is permanent, on an autoimmune basis. Referral for investigation and treatment is needed in these cases.

Homonymous hemianopia

This refers to loss of the same half of the visual field of each eye and may appear as loss of vision in one eye only to the patient. A stroke is by far the most common cause.⁴ Lesions that affect the visual pathway unilaterally, and anywhere from the optic tract to the occipital lobe, will result in a homonymous hemianopia, with varying degrees of congruency. Occipital lobe infarction is most likely if there are no other prominent neurological symptoms.

When taking a history, it should always be established whether or not the patient means “one eye” or “one side of the world”. The VA and pupil reactions are usually normal. Visual field testing by confrontation will reveal the hemianopia. Management includes immediate referral to a physician, neurologist or stroke unit if the lesion is less than 3-6 hours old. Otherwise, it should be discussed with a physician and referred as recommended.

Functional visual loss

Loss of vision, in the absence of organic disease, is referred to as functional. The diagnosis and management of this condition may present considerable problems.⁴ Hysteria may be a cause or sometimes the patient may be malingering.⁸ Detailed assessment by an ophthalmologist is required.

Conclusion

Patients with transient or sudden changes in vision may present a diagnostic challenge. In some cases, no cause may be found. Occasionally, tear film abnormalities, and less commonly, migraines, may be causative.¹ However, it is important to remember that more sinister causes of loss of vision exist. These include GCA, carotid or cardiac emboli, retinal detachment, vitreous haemorrhage, orbital tumours and other vascular events. A thorough history, goal-directed examination, proper investigation and appropriate referral

will enable early diagnosis and adequate management, thus preventing further ocular morbidity, and even patient mortality. In many cases, follow-up monitoring by the ophthalmologist should be coupled with management of the patient's underlying systemic disease by the primary care physician.⁹

Acknowledgements

We acknowledge the Division of Ophthalmology, University of Cape Town, for permission to use the clinical photographs.

Conflicts of interest

The authors have no conflict of interest to declare.

References

1. Goold L, Durkin S, Crompton J. Sudden loss of vision: history and examination. *Aust Fam Phys.* 2009;38(10):764-747.
2. Van Zyl LM, Fernandes N, Rogers G, et al. Primary health eye knowledge among general practitioners in the Cape Town metropole. *S Afr Fam Pract.* 2011;53(1):52-55.
3. Goold L, Durkin S, Crompton J. Sudden loss of vision: investigation and management. *Aust Fam Phys.* 2009;38(10):770-772.
4. Du Toit N, Cook C. Sudden loss of vision. Cape Town: Juta, 2009; p. 26-32.
5. Khan J, Chong V. Sudden visual loss. *Lancet.* 2007;370(9587):590.
6. Danesh-Meyer HV, Savino PJ. Giant cell arteritis. *Curr Opin Ophthalmol.* 2007;18(6):443-449.
7. Vortmann M, Schneider JI. Acute monocular visual loss. *Emerg Med Clin North Am.* 2008;26(1):73-96.
8. Beran DI, Murphy-Lavoie H. Acute, painless vision loss. *J La State Med Soc.* 2009;161(4):214-226.
9. Paulman A, Paulman P. Sudden loss of vision. *J Fam Pract.* 2004;53(4):269-273.