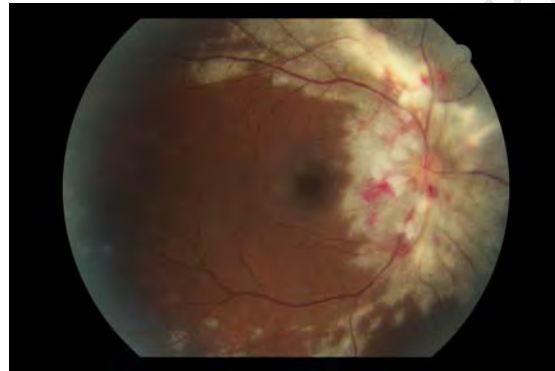


# **CYTOMEGALOVIRUS RETINITIS AT GROOTE SCHUUR HOSPITAL: CLINICAL MANAGEMENT AND OUTCOMES**

By

**Dr Steven Lapere**

Student number LPRSTE001



SUBMITTED TO THE UNIVERSITY OF CAPE TOWN

In fulfilment of the requirements for the degree

**MMed (Ophthalmology)**

Faculty of Health Sciences

University of Cape Town

**26 June 2015**

Supervisor: Dr James Rice, Division of Ophthalmology  
University of Cape Town  
james.rice@uct.ac.za

The copyright of this thesis vests in the author. No quotation from it or information derived from it is to be published without full acknowledgement of the source. The thesis is to be used for private study or non-commercial research purposes only.

Published by the University of Cape Town (UCT) in terms of the non-exclusive license granted to UCT by the author.

## **Declaration**

### **CYTOMEGALOVIRUS RETINITIS AT GROOTE SCHUUR HOSPITAL: CLINICAL MANAGEMENT AND OUTCOMES**

I, Steven Lapere (student number LPRSTE001) hereby declare that the work on which this dissertation is based is my original work (and where the work of others has been used, whether quoted verbatim, paraphrased or referred to, it has been attributed and acknowledged) and that neither the whole work or part of it has been or is to be submitted for another degree in this or any other university.

This work has not been reported or published prior to registration for the abovementioned degree.

Signed by candidate

Signed: SRJ Lapere

Date: 26 June 2015

## Table of contents

<b><u>PART A: ABSTRACT</u></b> .....	<b>5</b>
Objectives .....	5
Design & method.....	5
Results .....	6
Conclusion .....	7
<b><u>PART B: PROTOCOL</u></b> .....	<b>8</b>
Purpose.....	8
Background.....	8
Methodology .....	11
Risks and benefits .....	12
Informed consent .....	12
Privacy and confidentiality.....	12
Reporting of findings .....	13
References.....	13
<b><u>PART C: LITERATURE REVIEW</u></b> .....	<b>14</b>
1. Introduction.....	14
2. Cytomegalovirus.....	14
3. HIV/AIDS and CMV retinitis.....	16
4. HAART and CMV retinitis.....	16
5. Treatment of CMV retinitis .....	18
6. Discontinuing anti-CMV treatment .....	19
7. Complications.....	21
8. Conclusion.....	21
References.....	22

<b><u>PART D: MANUSCRIPT</u></b> .....	<b>25</b>
<b>1. ABSTRACT</b> .....	<b>26</b>
<b>Objectives</b> .....	<b>26</b>
<b>Design &amp; method</b> .....	<b>26</b>
<b>Results</b> .....	<b>26</b>
<b>Conclusion</b> .....	<b>27</b>
<b>2. INTRODUCTION</b> .....	<b>28</b>
<b>3. METHODS</b> .....	<b>30</b>
<b>4. RESULTS</b> .....	<b>31</b>
<b>5. DISCUSSION</b> .....	<b>35</b>
<b>References</b> .....	<b>38</b>
<b>Appendix A: Data capture form with coding</b> .....	<b>40</b>
<b>Appendix B: Questionnaire: CMV retinitis treatment protocol</b> .....	<b>41</b>
<b>Appendix C: Department of Surgery Research Committee approval</b> .....	<b>44</b>
<b>Appendix D: Human Research Ethics Committee approval</b> .....	<b>45</b>
<b>Turnitin originality report</b> .....	<b>46</b>

## **Part A: ABSTRACT**

# **CYTOMEGALOVIRUS RETINITIS AT GROOTE SCHUUR HOSPITAL: CLINICAL MANAGEMENT AND OUTCOMES**

**Lapere SRJ, Rice J**

**University of Cape Town**

### **Objectives**

1. To review the clinical presentation, management and outcomes of patients who were diagnosed and treated for cytomegalovirus (CMV) retinitis at Groote Schuur Hospital over a 10 year period
2. To review and compare the treatment protocols of thirteen public hospital centres in South Africa that treat patients for CMV retinitis

### **Design & method**

This is a retrospective cohort study. A record review of 141 eyes in 91 patients diagnosed with and treated for CMV retinitis between 2003 and 2013 was performed. Additionally, a standard questionnaire was sent to thirteen public hospitals in South Africa that treat patients for CMV retinitis to determine current treatment protocols.

At Groote Schuur Hospital, all cases of suspected CMV retinitis undergo a vitreous biopsy for polymerase chain reaction (PCR) confirmation. Treatment consists of weekly intravitreal ganciclovir injections until clinical resolution has taken place. Patients not on highly active anti-retroviral treatment (HAART) are referred for initiation of treatment. Ganciclovir treatment is continued until immune reconstitution has taken place.

## Results

All patients were PCR positive for CMV. The median age was 33.6 years (range 14-58 years) and patients were followed up for a mean of 8.1 months (range 0-56 months). Sixty percent of patients were female. Ninety-nine percent of patients were HIV positive and 73% were on HAART at presentation. Presenting CD4 counts ranged from 1 to 478 cells/mm<sup>3</sup>, with a mean of 58 cells/mm<sup>3</sup>. Presenting visual acuity ranged from Snellen acuity of 6/6 to no light perception.

Fifty percent of patients had macular involvement on presentation and 48% had the margin of the optic disc involved. The number of injections ranged from 0 to 29 per eye, with an average of 4.9 injections per eye. Nineteen percent of patients had a final visual acuity of light perception or no light perception. Those that achieved a final visual acuity of hand movements or better had a mean final visual acuity of LogMAR 1.05 (Snellen acuity 6/60).

There was a significant association between the number of retinal quadrants involved and final visual outcome ( $p=0.009$ ). Patients who were on HAART at the time of presentation had a better mean final visual acuity than those not on HAART ( $p=0.001$ ). Macular involvement had a significant effect on visual outcome compared to those with uninvolved maculas ( $p<0.005$ ). Presenting visual acuity strongly predicts final visual acuity - patients who presented with a visual acuity of 6/18 or better had a 4.6 times higher chance of obtaining a final visual acuity of 6/18 or better ( $p<0.005$ ) at the end of follow up. Neither the presenting CD4 count nor the number of injections affected the final visual outcome.

Twenty-two percent of patients developed retinal detachments. The number of retinal quadrants involved, CD4 count and presenting visual acuity had no statistically significant effect on retinal detachment rate. Forty-two percent of patients defaulted treatment or died during treatment.

All centres in South Africa that responded to the survey treat CMV retinitis with intravitreal ganciclovir as the primary treatment. The differences in protocol are found in: diagnosing clinically or using PCR, intravitreal injection time interval and whether fundus photos or serial diagrams are used to assess treatment response.

## **Conclusion**

Independent risk factors that predict final visual outcome include presenting visual acuity, number of retinal quadrants involved, macular involvement and HAART treatment at presentation. Most centres in South Africa follow similar protocols for diagnosing and treating CMV retinitis.



## **Part B: PROTOCOL**

### **CYTOMEGALOVIRUS RETINITIS AT GROOTE SCHUUR HOSPITAL: CLINICAL MANAGEMENT AND OUTCOMES**

S Lapere      *Registrar: Department of Ophthalmology*

Supervisor    *Dr J Rice: Consultant, Department of Ophthalmology  
Groote Schuur Hospital*

#### **Purpose**

The purpose of this study is to review the clinical presentation, management and outcomes of patients diagnosed and treated for cytomegalovirus retinitis at Groote Schuur Hospital.

#### **Background**

Cytomegalovirus (CMV) is a ubiquitous, large DNA member of the family Herpesviridae. It persists in the body like other Herpes viruses resulting in latency. It is the most common ocular opportunistic infection among patients with AIDS. It occurs with increasing frequency as the CD4 count drops below 100 cells/, with most patients having CD4 counts of less than 50 cells/mm<sup>3</sup>. Twenty to forty percent of patients with CD4 counts of <50 develop CMV retinitis.

The hallmark of CMV retinitis is a necrotising, full thickness retinitis. It is characterised by a dense, white, well-demarcated, geographical area of confluent opacification often associated with retinal haemorrhages. There is a slow but relentless “bushfire-like” extension along the course of retinal vascular arcades that may involve the optic nerve head. Without treatment the entire retina may become involved.

The two main principles of treatment of CMV retinitis are to improve the patient’s immune function and to use specific anti-CMV agents. Previous studies have investigated the effect of highly active antiretroviral therapy (HAART) on CMV retinitis.<sup>1,2</sup> The incidence and recurrence rates have been shown to decrease as a result

of the restored immunity that HAART treatment provides. With the advent of HAART there has been a 75% reduction in the number of new cases of CMV retinitis.<sup>1</sup> Maintenance treatment with anti-CMV agents is continued until immune reconstitution is achieved. Thereafter, CMV treatment can be stopped and HAART is continued lifelong.

It has been shown that HAART alone can cause regression of small areas of CMV retinitis. However, because of the delay in recovery of immune function, HAART should not be used alone in the management of these patients. It typically takes 3 months with a CD4 count of above 100 cells/mm<sup>3</sup> to heal CMV retinitis.

Current treatment regimes for the management of CMV retinitis include intravenous therapy (ganciclovir, foscarnet or cidofovir), oral therapy (ganciclovir or valganciclovir) and intravitreal therapy (ganciclovir injection, ganciclovir implant or foscarnet injection). Intravenous therapy requires lengthy inpatient admissions and can cause haematological abnormalities. Oral ganciclovir has very poor bioavailability (6%), while valganciclovir has better bioavailability (60%) but is an expensive drug. Intravitreal ganciclovir is the most effective drug for treating CMV retinitis, but does not protect against CMV in the fellow eye.

There is no standardised protocol for the treatment of CMV retinitis in South Africa. A study done in Durban in 2003, in which patients received bi-weekly intravitreal injections of ganciclovir, showed promising results, with 51% of patients showing an improvement in vision, 15% unchanged and 34% deteriorating. However, in this study, only 16.6% of patients were on HAART.<sup>3</sup>

In the above study, ganciclovir injections were administered twice weekly. A study done in 1996 found that the intravitreal concentration of ganciclovir after a single injection was above the ID50 for CMV (0.25-1.22 mg/l) after 7 days. This supports the use of a weekly injection for induction and maintenance therapy,<sup>4</sup> which is currently practiced at Groote Schuur Hospital.

At Groote Schuur Hospital, our current protocol is as follows:

1. The diagnosis of CMV retinitis is made clinically.

2. Fundus photographs are taken for referencing purposes.
3. The diagnosis is confirmed by obtaining a vitreous sample for polymerase chain reaction (PCR) testing at the time of the first intravitreal ganciclovir injection.
4. Patients are offered HIV testing if their status is not known.
5. Intravitreal ganciclovir injections are administered weekly until resolution occurs.
6. Thereafter, patients are reviewed 2-weekly and discharged from the clinic when the ophthalmologist is satisfied that clinical resolution is maintained and the patient's immune system has improved to a CD4 count of >100cells/microliter for 3 months. Patients who are not on HAART are referred to their ARV clinics so that HAART can be started as soon as possible.

We plan to contact the ophthalmology consultants at the thirteen state hospital centres in South Africa that have the facilities to treat CMV retinitis to enquire on their eye unit's protocols for the treatment of CMV retinitis. When we publish our findings, this will add a good discussion point as to whether treatment for CMV retinitis is standardised across all eye units in South Africa. We plan to contact the following centres:

- Tygerberg Hospital
- George Hospital
- Port Elizabeth Hospital Complex
- East London Hospital Complex
- Umtata Hospital
- Durban Hospital Complex
- Pietermaritzburg Hospital
- Bethlehem Hospital
- Bloemfontein Hospital Complex
- Johannesburg Hospital Complex
- Pretoria Academic Hospital
- Kimberley Hospital
- Mankweng Hospital

## Methodology

### *Study design*

Retrospective cohort study.

### *Study population*

All patients treated for cytomegalovirus retinitis at Groote Schuur Hospital from 1 June 2003 to 1 June 2013 will be included in the study. Follow-up will be documented up to 3 months after the date of diagnosis.

### *Recruitment*

The uveitis database (HREC reference R047/2014) will be used to identify the patients.

### *Data collection*

The patients' hospital folders will be accessed to collect relevant data. No contact will be made with the patient.

The following data will be collected from the database and folders:

- Hospital number
- Age
- Gender
- Date of diagnosis
- Presenting visual acuity
- Ocular signs
  - Vasculitis
  - Number of retinal quadrants involved
  - Macula involved
  - Vitritis
- HIV status
- CD4 count at diagnosis
- Vitreous PCR results
- Number of injections
- Final visual acuity

- Co-infections (if any)
- Complications
  - Retinal detachment
  - Infection (endophthalmitis)
- Treatment given
  - Intravitreal ganciclovir only
  - Intravenous ganciclovir for those patients with systemic CMV

### *Data analysis*

Microsoft Excel tables will be used to for data capturing. Statistical significance related to continuous variables will be analysed using t-tests or Wilcoxon-Mann Whitney rank sum depending on the normality of the distribution of the data. Categorical variables will be analysed using the Chi-square test. Logistic regression models will be used to assess risk factors for outcomes in the multivariate analysis.

### **Risks and benefits**

There will be no risk to the participants as this is a retrospective review of treatment which has already been administered.

Benefits would include measuring the outcome of the treatment and comparing this to national and international literature. We would also be able to contribute to the current body of literature on the subject. The study was approved by the Human Research Ethics Committee of the University of Cape Town (HREC reference 384/2014).

### **Informed consent**

No consent will be obtained, as this is a retrospective folder review without any patient contact.

### **Privacy and confidentiality**

Privacy and confidentiality of all data and results will be ensured. All data will be stored on a password protected computer. Hospital numbers will be used a patient

identification and no names will be stored in the database. Reporting will not include any form of patient identification.

### **Reporting of findings**

Our aim would be to publish our results in an ophthalmology journal for peer review.

We also aim to present our results at the annual Ophthalmological Society of South Africa congress.

### **References**

1. Jabs DA, Van Natta ML, Thorne JE, Weinberg D V, Meredith TA, Kuppermann BD, et al. Course of Cytomegalovirus Retinitis in the Era of Highly Active Antiretroviral Therapy. *Ophthalmology*. 2004;111(12):2224–31.
2. Zambarakji HJ, Newson RB, Mitchell SM. CMVR diagnoses and progression of CD4 cell counts and HIV viral load measurements in HIV patients on HAART. *Br J Ophthalmol*. 2001;85(7):837–41.
3. Visser L. Managing CMV retinitis in the developing world. *Community Eye Heal*. 2003;16(47):38–9.
4. Morlet N, Young S, Naidoo D, Graham G, Coroneo MT. High dose intravitreal ganciclovir injection provides a prolonged therapeutic intraocular concentration. *Br J Ophthalmol*. 1996;80(3):214–6.

## **Part C: LITERATURE REVIEW**

### **1. INTRODUCTION**

South Africa has HIV epidemic in the world. In 2012, an estimated 6.1 million people were living with HIV, with 240,000 South Africans dying from AIDS-related illnesses.<sup>1</sup> According to the Lancet 'Health in South Africa Series', South Africa has the largest antiretroviral treatment rollout programme in the world, with about 1.8 million people estimated to be taken antiretrovirals by April 2011. This has assisted in raising the life expectancy to 60 years.<sup>2</sup> The Lancet World Report states that South Africa now invests more than 1 billion annually to run its HIV and AIDS programs.<sup>3</sup>

### **2. CYTOMEGALOVIRUS**

Cytomegalovirus (CMV) is ubiquitous, large DNA member of the family Herpesviridae. It receives its name from the typical enlargement of infected cells. Transmission can occur from exposure to infected saliva or urine, sexual contact, via an infected maternal carrier or from donor organs at the time of organ transplantation.

CMV persists in the body like other Herpes viruses, resulting in latency. It is continually suppressed by cell-mediated immunity. In immunocompetent hosts, infection is usually asymptomatic, although some people may develop an influenza-like syndrome characterized by malaise, myalgia, arthralgia, fever and chills. It is rare for people with normal immune systems to develop long-term sequelae. CMV is an opportunistic infection and remains latent until the patient suffers from a significant local or systemic immunodeficiency. Immunocompromised patients suffer from decreased cell mediated immunity and may develop colitis, pneumonitis, hepatitis and CMV retinitis. In the past, immunosuppression associated with organ transplantation and chemotherapy was the most common cause of CMV retinitis. In the current era, the increasing number of occurrences of patients with AIDS has led to a marked increase in the number of occurrences of CMV retinitis.

CMV retinitis is thought to reach the eye via the blood stream, although the possibility of reactivation of latent virus has not been ruled out. Evidence of haematogenous spread includes the fact that one eye frequently develops retinitis several months before the other, and that new foci of retinitis can appear in an already infected eye.<sup>4</sup>

CMV retinitis begins as small, white retinal infiltrates which, if seen early, may resemble a large cottonwool spot. Two types of clinical appearance may be seen: The first is a perivascular fluffy white lesion with many scattered retinal haemorrhages.<sup>4</sup> There is a slow but relentless “bushfire-like” extension along the course of retinal vascular arcades that may involve the optic nerve head. Without treatment the entire retina becomes involved within a few months.<sup>(5)</sup> (Figure 1)

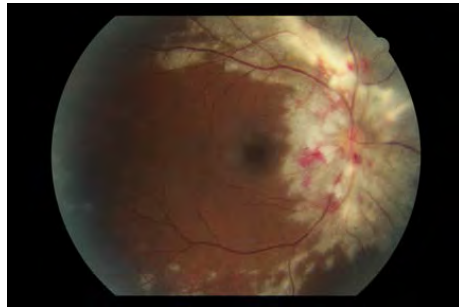


Figure 1: Extension and retinal necrosis along the arcades

Another manifestation is a more granular appearing lesion that has few associated haemorrhages and often has a central area of clearing, with atrophic retina and stippled retinal pigment epithelium. (Figure 2)

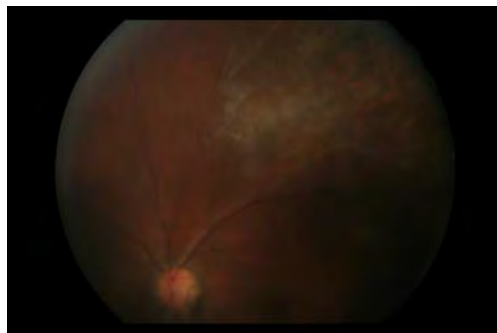


Figure 2: Granular indolent appearance



CMV is diagnosed clinically in most patients as it has a characteristic fundoscopic appearance.<sup>5</sup> In cases where there may be co-existing infection with other organisms, or where the clinical diagnosis is not clear, polymerase chain reaction (PCR) has a sensitivity of 95% and a specificity of 99%. PCR based analysis of vitreous samples in the diagnosis of infectious retinitis is well supported.<sup>6</sup>

### **3. HIV/AIDS and CMV RETINITIS**

CMV retinitis is the most common cause of vision loss in patients with AIDS.<sup>7</sup> In a British based post-mortem series of HIV patients in the pre-HAART era, 72% of patients had chronic uveal inflammation, with 38% being caused by CMV.<sup>8</sup> CMV retinitis is an opportunistic and late manifestation of the HIV disease, usually associated with T-lymphocyte CD4 counts of  $<50$  cells/mm<sup>3</sup>.<sup>9</sup> Kestly documented the epidemiology of CMV retinitis in Africa and found the prevalence to vary 0 to 8.5% in patients with acquired immunodeficiency syndrome.<sup>10</sup>

A study by Hodge et al. assessed clinical risk factors for CMV retinitis in AIDS patients. In patients who are not on HAART it is estimated that the time from development of AIDS to manifestation of CMV retinitis is 9 to 18 months. Among the clinical risk factors studied, cotton wool spots and floaters or flashing lights were found to be important predictors of CMV retinitis. Cotton wool spots represent an area of damaged retinal microcirculation and hence an avenue whereby CMV can gain access to the retina. They also found nonocular CMV infection to be a very strong predictor of CMV retinitis.<sup>11</sup>

### **4. HAART and CMV RETINITIS**

Before HAART, treatment of CMV retinitis consisted of lifelong treatment. Mortality rates due to HIV were high. In a study done in 1992 which studied the difference in mortality of patients treated with ganciclovir and those treated with foscarnet, the median survival was 8.5 months in the ganciclovir group and 12.6 months in foscarnet group. Relapses were common within weeks of discontinuing maintenance therapy.<sup>12</sup> HAART was introduced in 1996. It was originally defined as two nucleoside reverse transcriptase inhibitors (NRTI's) combined with a protease inhibitor (PI). In 2004, the

definition was expanded by the Kaiser panel to include a PI, a non-nucleoside reverse transcriptase inhibitor and one of the NRTI's. In a study of 1632 AIDS patients with a history of severe immune deficiency, it was found that HAART led to a substantial decrease in the incidence of CMV retinitis when compared to other studies (5.60/100 person-years).<sup>13</sup> This Longitudinal Study of the Ocular Complications of AIDS had an oversampling of CMV retinitis due to the groups interest in ocular complications, and this data is best interpreted as the upper limit on the incidence of CMV retinitis in patients who are on HAART. The actual incidence may be even lower.<sup>13</sup> A separate study showed that there has been a 75% reduction in the number of new cases of CMV retinitis since the advent of HAART.<sup>14</sup>

Further benefits of HAART include a reduction in the number of hospital admission and improvement in quality and length of life. A study by Douglas et al showed that patients with immune reconstitution could safely have their anti-CMV maintenance therapy discontinued. In this study, there were no relapses.<sup>15</sup> The United States Department of Health and Human Services guidelines for the management of opportunistic infections in patients with AIDS recommend discontinuing anti-CMV therapy if the CD4+ T cells have increased to a level of >100 cells/for 3 to 6 months. A follow up study done supported these guidelines, and showed that discontinuing CMV therapy after immune recovery did not increase the risk of poor outcomes. Poor outcomes were defined as shortened survival or worsened course of retinitis.<sup>16</sup>

Patients not on antiretroviral medication require workup and commencement of this . For HAART-failure patients, changing medication should be considered. Some infectious disease specialists may consider delaying the commencement of HAART in patients with opportunistic infections to minimize the risk of immune recovery uveitis.

## 5. TREATMENT OF CMV RETINITIS

The principles of treatment of CMV retinitis are to improve the patient's immune function and treat the infection with anti-CMV compounds. include intravitreal injections of ganciclovir or foscarnet, intravitreal ganciclovir implants, intravenous medications (ganciclovir, foscarnet or cidofovir) or oral valganciclovir.

### Intravenous therapy

Intravenous drugs require admission with venous access and daily therapy, which significantly impacts on quality of life, as immune reconstitution may take several months. Patients require a peripherally-inserted central catheter (PIC) line to allow atraumatic, intravenous access. Catheter-related sepsis remains an important complication and can occur in up to 12% of patients.<sup>17</sup> Ganciclovir causes haematologic abnormalities (anaemia, neutropenia and thrombocytopenia) and may produce long term reproductive complications.<sup>18</sup> Foscarnet is highly nephrotoxic and must be administered carefully to patients with renal disease. Patients require adequate hydration and frequent monitoring of creatinine levels. Cidofovir is rarely used as long-term therapy as it causes severe renal toxicity.

### Oral therapy

Oral ganciclovir was introduced in 1994 in an attempt to reduce costs, eliminate the inconvenience of admitting patients for intravenous infusions and to reduce the rate of catheter-related sepsis. The bioavailability was only 6% to 9%, so patients could not achieve plasma concentrations sufficient for induction therapy.<sup>17</sup> Valganciclovir is the prodrug of ganciclovir. Its bioavailability is 60% and it can be used for both induction and maintenance therapy.<sup>19</sup> It is well tolerated, with the most common side effects being neutropenia, anaemia, diarrhoea, nausea and vomiting.

### Intravitreal therapy

Intravitreal ganciclovir was first investigated in animal models in 1985. It was initially used in patients who had severe adverse reactions to systemic ganciclovir. The pharmacodynamics were studied by Henry et al. in 1986(20) Lopez-Cortex et al. compared intravitreal ganciclovir with intravitreal foscarnet and found the that

intravitreal ganciclovir had a better pharmacokinetic profile. They supported the administration of the injection twice per week.<sup>21</sup>

Initial suggested doses of intravitreal ganciclovir were 200mcg in 0.1ml.<sup>20</sup> Morlet et al used 2mg in 0.1ml and found that the concentration of ganciclovir was 143.8mg/l at 24 hours and 23.4mg/l at 72 hours. The mean half life was 18.8 hours. The calculated mean at seven days was 0.6mg/l. The intravitreal concentration achieved with this high dose therapy remained above the ID50 for CMV (0.25-1.22mg/l) for up to 7 days and they found that the drug was not likely to accumulate.<sup>22</sup> This supports our protocol, which is the use of a weekly injection as induction and maintenance.

The sustained-release intravitreal ganciclovir implant releases 1 microgram of ganciclovir per hour for 8 months. It is inserted through the pars plana and has shown to be highly efficacious against CMV retinitis, but is also very costly.

Young et al. compared intravitreal ganciclovir alone with systemic ganciclovir. The results of this study strongly support the use of intravitreal ganciclovir alone, which is the current management strategy at Groote Shuur Hospital. They found a lower relapse rate in the intravitreal group (7% vs 56%) as well as more patients maintaining vision of 20/40 or better in the intravitreal group (85% vs 59%).

## **6. DISCONTINUING ANTI-CMV TREATMENT**

In the absence of immune reconstitution, discontinuing anti-CMV treatment is not an option. Douglas et al. looked at retinitis progression in patient with CMV retinitis in the era of HAART. They found that the CD4+ T-cell count at enrollment was directly associated with the rate of retinitis progression (0.27/person year for patients with CD4+ T-cell of <50 vs 0.02/person year for patients with a CD=T-cell of >200, p<0.01). The decision to stop anti-CMV therapy depends upon many factors, including rising CD4+ T-lymphocyte counts, decreasing systemic HIV viral load, duration of HAART and inactivity of CMV lesions. Among patients with immune reconstitution to levels considered safe to discontinue anti-CMV therapy (>100 cells/microliter), this study found that the rate of retinitis progression in patients with CD4+ T-cell counts of 100 to 199 cells/microliter was 0.06/person year and in

patients with CD4+ T-cell counts of >200 cells/microliter, the rate was 0.02/person year. They concluded that the rate of retinitis progression in the HAART era is greatly reduced from that of the pre-HAART era, but the rate of progression was not zero.<sup>14</sup>

Zambarakji et al. looked at the relationship between CD4 cell counts and CMV retinitis progression in 1292 patients who were started on HAART. Sixty-six percent of patients developed CMV retinitis. They found that the proportion of patients with CD4 cell counts of <50 cells /decreased in response to HAART and the rate of change was greatest between 1 and 3 months after commencing treatment. HAART considerably reduced the rate of CMV retinitis adverse events, from 0.35 per 100 patient days at risk, to 0.14. From a clinical standpoint, there were only 5 patients who developed adverse events during the second year of follow up and none during the third year, indicating significant immunorestitution beyond 12-18 months for all patients.<sup>23</sup>

From the literature review of stopping anti-CMV treatment, there appears to be no absolute CD4 T-cell count value at which immune reconstitution occurs. It has been clearly shown that HAART significantly reduces the rate of CMV retinitis progression, but both clinical and CD4 T-cell count monitoring are required as some patients get recurrences despite high CD4 T-cell counts. There are no strict guidelines for discharging patients and discontinuing monitoring altogether – this monitoring appears to be at the discretion of the treating physician, centre and resources available.

The United States Public Health Service provided guidelines in 1999 to suggest discontinuing anti-CMV therapy after patients with quiescent retinitis achieve sustained immune recovery. Immune recovery was defined as having CD4+ T-cell counts of 100 cells/or more for at least 2 or more consecutive visits at least 6 months apart.<sup>24</sup>

## **7. COMPLICATIONS**

Jennifer et al. studied 494 eyes of 379 patients with CMV retinitis on HAART to determine the common causes of visual acuity loss in these patients. Involvement of the posterior pole accounted for visual acuity loss of 20/50 or worse in half of the patients. Cataract accounted for 14.5% of visual loss and retinitis related retinal detachment accounted for 16.7% of visual loss. They concluded that zone 1 involvement and retinal detachment remain the most common causes of visual acuity loss in patients with CMV retinitis.<sup>25</sup> Yen et al. looked at risk factors for developing retinal detachments in patients with CMV retinitis and found bilateral disease and lesion size to be the strongest predictors.<sup>26</sup>

## **8. CONCLUSION**

CMV retinitis in HIV positive patients is a sight-threatening opportunistic infection which requires aggressive and continuous treatment to preserve visual function. Intravitreal ganciclovir remains the most cost effective, available method of controlling CMV retinitis. Anti-CMV therapy needs to be continued until immune reconstitution has taken place.

## References

1. Sidibé M. Global Report. 2013.  
<http://www.unaids.org/en/media/unaids/contentasset>.
2. Mayosi BM, Lawn JE, Van Niekerk A, Bradshaw D, Abdool Karim SS, Coovadia HM. Health in South Africa: Changes and challenges since 2009. *Lancet*. 2012;380(9858):2029–43.
3. Maurice J. South Africa's battle against HIV/AIDS gains momentum. *Lancet*. 2014;383(9928):1535–6.
4. Nussenblatt RB WS. Uveitis: Fundamentals and Clinical Practice. Uveitis. 2004.
5. Kanski J, Bowling B. *Clinical Ophthalmology* 7<sup>th</sup> Ed. Elsevier Limited. 2011. 442 - 444.
6. Knox MC, Chandler D, Short GA, Margolis TP. Polymerase chain reaction-based assays of vitreous samples for the diagnosis of viral retinitis: Use in diagnostic dilemmas. *Ophthalmology*. 1998;105(1):37–45.
7. Kestelyn PG, Cunningham ET. HIV / AIDS and blindness. *WHO bulletin*. 2001;79(3):208–13.
8. Pecorella I, Ciardi A, Garner A, McCartney AC, Lucas S. Postmortem histological survey of the ocular lesions in a British population of AIDS patients. *Br J Ophthalmol*. 2000;84(11):1275–81.
9. Kuppermann BD, Petty JG, Richman DD, Mathews WC, Fullerton SC, Rickman LS, et al. Correlation between CD4+ counts and prevalence of cytomegalovirus retinitis and human immunodeficiency virus-related noninfectious retinal vasculopathy in patients with acquired immunodeficiency syndrome. *Am J Ophthalmol*. 1993;115:575–82.
10. Kestly P. The epidemiology of CMV retinitis in Africa. *Ocul Immunol*. 1999;7(304):173–7.
11. Hodge WG, Boivin J-F, Shapiro SH, Lalonde RG, Shah KC, Murphy BD, et al. Clinical risk factors for cytomegalovirus retinitis in patients with AIDS. *Ophthalmology*. 2004;111(7):1326–33.
12. Studies of the Ocular Complications of AIDS Research Group. Mortality in patients with the acquired immunodeficiency syndrome treated with either foscarnet or ganciclovir for cytomegalovirus. *N Engl J Med*. 1992;326(4):213–20.
13. Jabs DA, Van Natta ML, Holbrook JT, Kempen JH, Meinert CL, Davis MD. Longitudinal Study of the Ocular Complications of AIDS. 1. Ocular Diagnoses at Enrollment. *Ophthalmology*. 2007;114(4):780–6.

14. Jabs DA, Van Natta ML, Thorne JE, Weinberg DV, Meredith TA, Kuppermann BD, et al. Course of Cytomegalovirus Retinitis in the Era of Highly Active Antiretroviral Therapy. *Ophthalmology*. 2004;111(12):2224–31.
15. Jabs DA, Bolton SG, Dunn JP, Palestine AG. Discontinuing anticytomegalovirus therapy in patients with immune reconstitution after combination antiretroviral therapy. *Am J Ophthalmol*. 1998;126(6):817–22.
16. Holbrook JT, Colvin R, Van Natta ML, Thorne JE, Bardsley M, Jabs DA. Evaluation of the United States public health service guidelines for discontinuation of anticytomegalovirus therapy after immune recovery in patients with cytomegalovirus retinitis. *Am J Ophthalmol*. 2011;152(4):628–37.
17. Lalezari JP, Friedberg DN, Bissett J, Giordano MF, Hardy WD, Drew WL, et al. High dose oral ganciclovir treatment for cytomegalovirus retinitis. *J Clin Virol*. 2002;24(1-2):67–77.
18. Stewart MW. Optimal management of cytomegalovirus retinitis in patients with AIDS. *Clin Ophthalmol*. 2010;4:285–99.
19. Jung D, Dorr A. Single-dose pharmacokinetics of valganciclovir in HIV- and CMV-seropositive subjects. *J Clin Pharmacol*. 1999;39(8):800–4.
20. Henry K. Use of intravitreal ganciclovir for cytomegalovirus retinitis in patients with AIDS. *Am J Ophthalmol*. 1987;1:17–23.
21. López-Cortés LF, Pastor-Ramos MT, Ruiz-Valderas R, Cordero E, Uceda-Montañés A, Claro-Cala CM, et al. Intravitreal pharmacokinetics and retinal concentrations of ganciclovir and foscarnet after intravitreal administration in rabbits. *Investig Ophthalmol Vis Sci*. 2001;42(5):1024–8.
22. Morlet N, Young S, Naidoo D, Graham G, Coroneo MT. High dose intravitreal ganciclovir injection provides a prolonged therapeutic intraocular concentration. *Br J Ophthalmol*. 1996;80(3):214–6.
23. Zambarakji HJ, Newson RB, Mitchell SM. CMVR diagnosis and progression of CD4 cell counts and HIV viral load measurements in HIV patients on HAART. *Br J Ophthalmol*. 2001;85:837–41.
24. CDC. USPHS/IDSA guidelines for prevention of opportunistic infections in persons infected with HIV. 1999.
25. Thorne JE, Jabs DA, Kempen JH, Holbrook JT, Nichols C, Meinert CL. Causes of Visual Acuity Loss among Patients with AIDS and Cytomegalovirus Retinitis in the Era of Highly Active Antiretroviral Therapy. *Ophthalmology*. 2006;113(8):1441–5.



26. Yen M, Chen J, Ausayakhun S, Kunavisarut P, Vichitvejpaisal P, Ausayakhun S, et al. Retinal Detachment Associated With AIDS-Related Cytomegalovirus Retinitis: Risk Factors in a Resource-Limited Setting. *Am J Ophthalmol*; 2015;159(1):185–92.

## **Part D: MANUSCRIPT**

# **Cytomegalovirus retinitis at Groote Schuur Hospital: Clinical Management and Outcomes (For submission)**

### **Authors:**

Steven Lapere FCOphth (SA)\*  
James C. Rice FCOphth(SA)\*

\*Department of Ophthalmology, Groote Schuur Hospital, Observatory, Cape Town, South Africa

The authors have no proprietary interest in any aspect of this study.

Correspondence to: Dr Steven Lapere  
Department of Ophthalmology, Groote Schuur Hospital, Observatory, Cape Town 7925, South Africa;  
steven.lapere@gmail.com

## **1. ABSTRACT**

### **Objectives**

1. To review the clinical presentation, management and outcomes of patients who were diagnosed and treated for cytomegalovirus (CMV) retinitis at Groote Schuur Hospital over a 10 year period
2. To review and compare the treatment protocols of thirteen public hospital centres in South Africa that treat patients for CMV retinitis

### **Design & method**

This is a retrospective cohort study. A record review of 141 eyes in 91 patients diagnosed with and treated for CMV retinitis between 2003 and 2013 was performed. Additionally, a standard questionnaire was sent to thirteen public hospitals in South Africa that treat patients for CMV retinitis to determine current treatment protocols.

At Groote Schuur Hospital, all cases of suspected CMV retinitis undergo a vitreous biopsy for polymerase chain reaction (PCR) confirmation. Treatment consists of weekly intravitreal ganciclovir injections until clinical resolution has taken place. Patients not on highly active anti-retroviral treatment (HAART) are referred for initiation of treatment. Ganciclovir treatment is continued until immune reconstitution has taken place.

### **Results**

All patients were PCR positive for CMV. The median age was 33.6 years (range 14-58 years) and patients were followed up for a mean of 8.1 months (range 0-56 months). Sixty percent of patients were female. Ninety-nine percent of patients were HIV positive and 73% were on HAART at presentation. Presenting CD4 counts ranged from 1 to 478 cells/mm<sup>3</sup>, with a mean of 58 cells/mm<sup>3</sup>. Presenting visual acuity ranged from Snellen acuity of 6/6 to no light perception.

Fifty percent of patients had macular involvement on presentation and 48% had the margin of the optic disc involved. The number of injections ranged from 0 to 29 per eye, with an average of 4.9 injections per eye. Nineteen percent of patients had a final

visual acuity of light perception or no light perception. Those that achieved a final visual acuity of hand movements or better had a mean final visual acuity of LogMAR 1.05 (Snellen acuity 6/60).

There was a significant association between the number of retinal quadrants involved and final visual outcome ( $p=0.009$ ). Patients who were on HAART at the time of presentation had a better mean final visual acuity than those not on HAART ( $p=0.001$ ). Macular involvement had a significant effect on visual outcome compared to those with uninvolved maculas ( $p<0.005$ ). Presenting visual acuity strongly predicts final visual acuity - patients who presented with a visual acuity of 6/18 or better had a 4.6 times higher chance of obtaining a final visual acuity of 6/18 or better ( $p<0.005$ ) at the end of follow up. Neither the presenting CD4 count nor the number of injections affected the final visual outcome.

Twenty-two percent of patients developed retinal detachments. The number of retinal quadrants involved, CD4 count and presenting visual acuity had no statistically significant effect on retinal detachment rate. Forty-two percent of patients defaulted treatment or died during treatment.

All centres in South Africa that responded to the survey treat CMV retinitis with intravitreal ganciclovir as the primary treatment. The differences in protocol are found in: diagnosing clinically or using PCR, intravitreal injection time interval and whether fundus photos or serial diagrams are used to assess treatment response.

## **Conclusion**

Independent risk factors that predict final visual outcome include presenting visual acuity, number of retinal quadrants involved, macular involvement and HAART treatment at presentation. Most centres in South Africa follow similar protocols for diagnosing and treating CMV retinitis.

## 2. INTRODUCTION

Cytomegalovirus (CMV) is a ubiquitous, large DNA member of the family Herpesviridae. It persists in the body like other Herpes viruses resulting in latency. It is the most common ocular opportunistic infection among patients with AIDS.<sup>1</sup> It occurs with increasing frequency as the CD4 count drops below 100 cells/mm<sup>3</sup>, with most patients having CD4 counts of less than 50 cells/mm<sup>3</sup>.<sup>2</sup> Twenty to forty percent of patients with CD4 counts of <50 cells/mm<sup>3</sup> develop CMV retinitis.

The hallmark of CMV retinitis is a necrotising, full thickness retinitis. It is characterised by a dense, white, well-demarcated, geographical area of confluent opacification often associated with retinal haemorrhages. There are two types of clinical appearance. The first is a slow but relentless “bushfire-like” extension along the course of retinal vascular arcades that may involve the optic nerve head. Without treatment the entire retina becomes involved within a few months. The second is a more granular appearing lesion that has few associated haemorrhages and often has a central area of clearing, with atrophic retina and stippled retinal pigment epithelium.

The principles of treatment of CMV retinitis are to improve the patient’s immune function and to use specific anti-CMV agents. Many studies have investigated the effect of highly active antiretroviral therapy (HAART) on CMV retinitis.<sup>3</sup> The incidence and recurrence rates have been shown to decrease as a result of the restored immunity that HAART treatment provides. With the advent of HAART there has been a 75% reduction in the number of new cases of CMV retinitis.<sup>4</sup>

It has been shown that HAART alone can cause regression of small areas of CMV retinitis. It typically takes 3 months with a CD4 count of above 100 cells/mm<sup>3</sup> to heal CMV retinitis. Because of the delay in the recovery of the immune function, HAART should not be used alone in the management of these patients.

Alternate treatments regimes for the management of CMV retinitis exist, and these include more expensive agents such as valganciclovir (oral), foscarnate (intravenous or intravitreal) and cidofovir (intravenous or intravitreal).

There is no standardised protocol for the treatment of CMV retinitis in South Africa. A study done in Durban in 2003, in which patients received bi-weekly intravitreal injections of ganciclovir, showed promising results, with 51% of patients showing an improvement in vision, 15% unchanged and 34% deteriorating. However, in this study, only 16.6% of patients were on HAART.<sup>5</sup> In this study, ganciclovir injections were administered twice weekly. A previous study in 1996 found that the intravitreal concentration of ganciclovir was above the ID50 for CMV (0.25-1.22 mg/l) after 7 days and the drug is not likely to accumulate. This supports the use of a weekly injection as induction and maintenance<sup>6</sup>, which is what is currently practiced at Groote Schuur Hospital.

At Groote Schuur Hospital, our current protocol is as follows:

1. The diagnosis of CMV retinitis is made clinically.
2. Fundus photographs are taken for referencing purposes.
3. The diagnosis is confirmed by obtaining a vitreous sample for polymerase chain reaction (PCR) testing at the time of the first intravitreal ganciclovir injection.
4. Patients are offered HIV testing if their status is not known.
5. Intravitreal ganciclovir injections are administered weekly until resolution occurs.
6. Thereafter, patients are reviewed 2-weekly and discharged from the clinic when the ophthalmologist is satisfied that clinical resolution is maintained and the patient's immune system has improved to a CD4 count of >100 cells/mm<sup>3</sup> for 3 months. Patients who are not on HAART are referred to their ARV clinics so that HAART can be started as soon as possible.

In this study, we examined risk factors which could possibly predict a poorer or more favourable outcome in patients with CMV retinitis. We also assessed whether centres in South Africa have a standardised approach to induction, maintenance and discontinuation of treatment of patients with CMV retinitis. Current treatment strategies across these centres were compared.

### 3. METHODS

This is a retrospective cohort study. A record review of 141 eyes in 91 patients diagnosed with and treated for CMV retinitis between 2003 and 2013 was performed. Patients were identified from the uveitis database (HREC reference R047/2014). Only patients with PCR proven CMV retinitis were included. Patients with CMV retinitis who had co-infection with another organism (E.g. syphilis, herpes simplex) were excluded. Patients who had poor or no follow-up and patients in which poor fundal view precluded accurate assessment were excluded.

Data was captured on a single data capture sheet for each patient, and transferred to an excel spread sheet where it was analysed using Stata 10.0.<sup>7</sup> Statistical significance related to continuous variables will be analysed using t-tests or Wilcoxon-Mann Whitney rank sum depending on the normality of the distribution of the data. Categorical variables will be analysed using the Chi-square test. Logistic regression models will be used to assess risk factors for outcomes in the multivariate analysis.

Visual acuity was captured as Snellen visual acuity, and converted to LogMAR.<sup>8</sup> For our statistical analysis, vision of 'light perception' and 'no light perception' were not used in the calculation of mean acuity but were included in categorical analyses.

A good visual outcome was defined as final visual acuity of 6/12 (LogMAR 0.3) or better (Category 1). A moderate visual outcome was defined as 6/18 to 6/36 (LogMAR 0.5 to 0.8) (Category 2), with a poor visual outcome being 6/60 (LogMAR 1.00) or worse (Category 3).

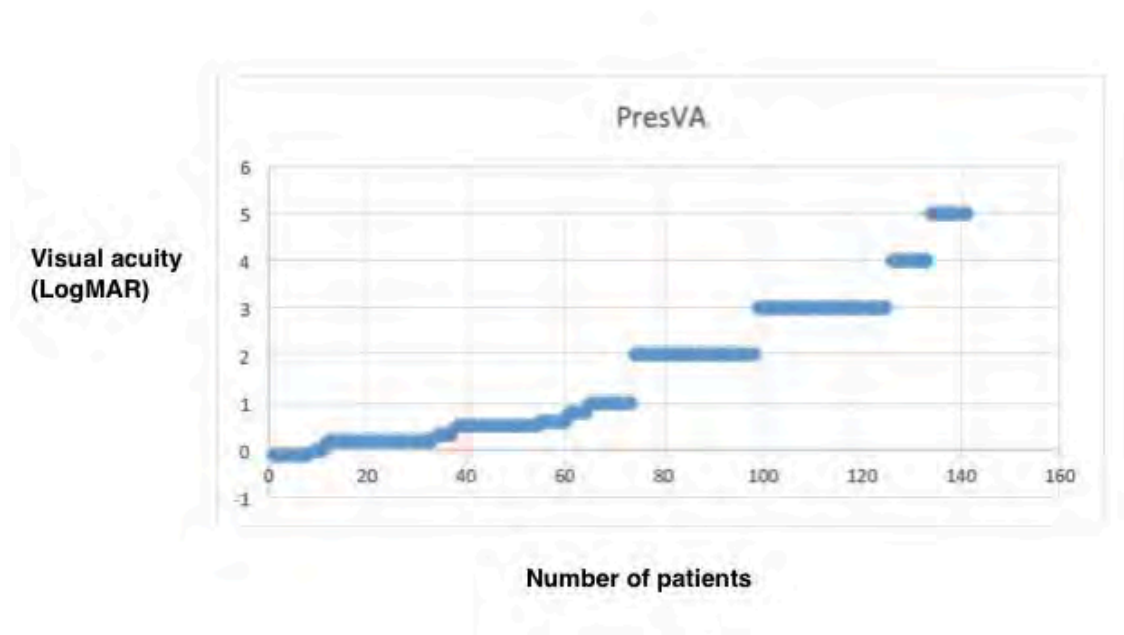
A standard questionnaire was sent to thirteen public hospital centres in South Africa that treat patients for CMV retinitis (Appendix B).

The study was approved by the Human Research Ethics Committee of the University of Cape Town (HREC reference 384/2014).

## 4. RESULTS

One hundred and forty one eyes of 91 patients were included in the study. Twenty seven patients were excluded from the study (10 did not have PCR proven CMV retinitis, 6 had files that were not traceable, 6 had co-infection in the eye with other organisms and 5 did not return after an initial visit). Fifty patients had bilateral disease and 41 patients had unilateral disease. The median age was 33.6 years (range 14-58 years) and patients were followed up for a mean of 8.1 months (range 0-56 months). Sixty percent of patients were female. Ninety-nine percent of patients were HIV positive and 73% were on HAART at the time of presentation. Forty-two percent of patients defaulted treatment or died during treatment.

Presenting visual acuity ranged from 6/6 (LogMAR 0.0) to no light perception. Fifty five percent of eyes had a presenting Snellen visual acuity of 6/60 (LogMAR 1.00) or worse. The presenting acuities are summarised in Table 1.



[Table 1:](#) Presenting visual acuity

Presenting CD4 counts ranged from 1 cell/mm<sup>3</sup> to 478 cells/mm<sup>3</sup>, with a mean of 58 cells/mm<sup>3</sup>. We found presenting CD4 count to have no effect on final visual acuity. Using the Wilcoxon-Mann-Whitney test, there was no statistically significant difference in the median final visual acuity when comparing patients who presented



with a CD4 of less than 50 cells/mm<sup>3</sup> to those with a CD4 of more than 50 cells/mm<sup>3</sup> (p=0.89).

The number of injections ranged from 0 to 29 per patients, with an average of 4.9 injections per patient. There was no association between the number of injections administered and the final visual outcome. (p=0.17, Fishers exact)

Fifty percent of patients had macular involvement on presentation and 48% had the margin of the optic disc involved. Patients with macular involvement on presentation had poorer visual outcomes (p<0.05) compared with those in whom the macula was spared.

Sixty percent of patients presented with retinal vasculitis, and 71% had vitritis of varying degrees on presentation. There was a significant association between the number of retinal quadrants involved and final visual outcome. (p=0.009, Pearson Chai Square) (Table 2)

Quadrants vs Final VA

	Final VA category 1	Final VA category 2	Final VA category 3	Total
1	17	3	9	29
%	58.62	10.34	31.03	100
2	11	14	16	41
%	26.83	34.15	39.02	100
3	4	325	5	12
%	33.33		41.67	100
4	11	13	32	56
%	19.64	23.21	57.14	100
Total	43	33	62	138
%	31.16	23.91	44.93	100

**Table 2:** Pearson Chi Square analysis showing the correlation between retinal quadrants involved and final visual outcome

Seventy three percent of patients were on HAART at presentation. Patients who were on HAART at the time of presentation had a better final visual acuity than those not on HAART. Two-sample Wilcoxon rank-sum test showed a p-value of 0.001.

However, there was no statistically significant difference when comparing the number of injections needed to achieve disease resolution in patients on HAART and patients who were not on HAART (p=1.88).

Twenty-two percent of patients developed retinal detachments. Chi Square analysis revealed no statistically significant relationship between presenting CD4 count and the development of a retinal detachment (p=0.499). Unlike final visual acuity, the number of retinal quadrants involved did not affect the development of a retinal detachment (p=0.40, Chi Square). Presenting visual acuity could also not predict the rate of retinal detachment (p=0.58).

Presenting visual acuity was a strong predictor of final visual acuity (Chi Square p<0.01). (Table 3)

Presenting VA category	Final VA category			Total
	1	2	3	
1	26 (17%)	5 (4%)	6 (5%)	37
2	10 (7%)	10 (7%)	7 (5%)	27
3	7 (5%)	18 (13%)	52 (37%)	77
	43	33	65	141

**Table 3:** Relationship between presenting and final visual acuity

Linear regression model analysis showed that patients who presented with a visual acuity of 6/18 or better had a 4.6 times higher chance of obtaining a final visual acuity of 6/18 or better (p<0.01).

Questionnaires were sent to thirteen public health centres in South Africa that treat CMV retinitis. Responses were received from nine centres. All centres that participated use intravitreal ganciclovir as the primary treatment of CMV retinitis. Five centres diagnose CMV retinitis by clinical appearance alone, two centres used PCR only in cases with an atypical presentation, and two centres perform PCR vitreous taps routinely on all suspected cases.

There was considerable variability with intravitreal ganciclovir injection intervals between centres. Two centres inject patients weekly, three centres inject patients twice per week until injections are stopped (they do not decrease the intervals to weekly), three centres start injections at intervals of twice per week, and decrease the intervals to weekly either according to set protocols or titrated to CD4 count. One centre injects all patients on an 'as needed' basis only.

Four centres have 'set regimes' for the minimum number of injections and intervals, which they will administer to all patients before titrating the number and interval of injections to the clinical response. Five centres do not have these 'set regimes' and will re-evaluate patients at each visit.

Five centres rely on fundus drawings for comparison when deciding whether a repeat injection is necessary, while four centres compare fundus photographs on each visit.

Seven centres do not perform prophylactic argon demarcation laser on any patients, while two centres perform laser on selected patients only.

Six centres have fixed criteria for stopping anti-CMV treatment. They all vary slightly and none of them strictly adhere to the United States Public Health Service guidelines of 1999 for discontinuing anti-CMV therapy. Three centres do not have fixed criteria, with decisions being made on a patient-by-patient basis.

Seven centres monitor patients' CD4 counts as part of their treatment, while two centres do not. All centres refer patients who are not on HAART to their local clinics for workup and commencement of HAART.

## 5. DISCUSSION

This retrospective cohort study describes the spectrum of presenting features, clinical course and prognostic factors of patients presenting with CMV retinitis at Groote Schuur Hospital.

Independent risk factors associated with better final visual outcome include good presenting visual acuity, fewer retinal quadrants involved, absence of macular involvement and HAART treatment at presentation. Presenting CD4 count and the number of injections received were not predictive of final visual outcome.

Our study found that patients who were on HAART at the time of presentation had a better mean final visual acuity than those not on HAART ( $p < 0.01$ ). Several other studies have shown that the introduction of HAART has led to a substantial decrease in the incidence and course of CMV retinitis<sup>9,4</sup>, which would explain why patients on HAART had better final visual acuities. A separate study showed that HAART considerably reduced the rate of CMV retinitis adverse events, from 0.35 per 100 patient days at risk, to 0.14.<sup>10</sup>

In a study of 494 eyes of 379 CMV retinitis patients, 16.7% of patients were found to have a retinitis-related retinal detachment.<sup>11</sup> Twenty-two percent of patients in our study developed retinal detachments. Forty percent of patients in this study<sup>11</sup> had macular involvement at baseline, compared to the 50% in our study. Yen et al. looked at risk factors for developing retinal detachments in patients with CMV retinitis and found bilateral disease and lesion size to be the strongest predictors.<sup>12</sup> Macular involvement understandably has a significant effect on visual outcome when compared to uninvolved maculas ( $p < 0.05$ ). Prophylactic argon retinal photocoagulation has been successful in anecdotal reports and small case series<sup>13</sup> but there is not uniformity among the centres in South Africa about treating patients prophylactically with laser.

The decision to stop anti-CMV therapy depends upon many factors, including rising CD4+ T-lymphocyte counts, decreasing systemic HIV viral load, duration of HAART and inactivity of CMV lesions. There is a discrepancy amongst the centres in South

Africa regarding the decision to stop therapy.

Forty two percent of patients defaulted treatment or died during treatment. Patients with CMV retinitis usually have severe immunosuppression and are susceptible to a wide variety of other opportunistic infections. In our patient population, transport difficulties and social stigma are further barriers that may prevent optimal follow up. This has affected our results, as only 58% of patients had adequate follow-up until the treating ophthalmologist had discharged them. Another limitation is the retrospective nature of our study. Injection dates were often missed. Different clinicians were examining patients at each visit, but this was overcome by using photos rather than drawings for comparison.

There is no 'national protocol' for initiation, continuation and discontinuation of treatment for CMV retinitis. The only similarities between centres are the use of intravitreal ganciclovir as the mainstay of treatment, as well as vague similarities when discontinuing treatment. The most striking differences are diagnostic methods (clinical vs PCR), intravitreal injection time interval, monitoring of CD4 counts and criteria for repeat injections.

A protocol for all centres would certainly be useful, as our countries healthcare system is resource-limited.

Our suggested protocol for treating CMV retinitis is as follows:

1. The diagnosis of CMV retinitis can be made clinically. If there is any doubt, PCR confirmation should be used.
2. Fundus photographs should be taken for referencing and comparison purposes. If a centre does not have fundus photos available, the same clinician should preferably examine the patient on subsequent visits.
3. Patients should be offered HIV testing if their status is not known.
4. Intravitreal ganciclovir injections should be administered weekly until clinical resolution occurs.
5. Once clinical resolution has occurred, patients can be reviewed with increasing frequency between visits.

6. Patients can be discharged from the clinic when the ophthalmologist is satisfied that clinical resolution is maintained and the patient's immune system has improved to a CD4 count of  $>100$  cells/mm<sup>3</sup> for 3 months.

Our study found that patients who are more likely to have favourable visual outcomes are those who present with better visual acuities, have less retinal quadrants involved, do not have macular involvement and are on HAART at presentation. The converse is true for poor visual outcomes. Most centres in South Africa follow similar protocols for diagnosing and treating CMV retinitis, but a standardised protocol is yet to be adopted by all centres.

## References

1. Kestelyn PG, Cunningham ET. HIV / AIDS and blindness. WHO bulletin. 2001;79(3):208–13.
2. Kuppermann BD, Petty JG, Richman DD, Mathews WC, Fullerton SC, Rickman LS, et al. Correlation between CD4+ counts and prevalence of cytomegalovirus retinitis and human immunodeficiency virus-related noninfectious retinal vasculopathy in patients with acquired immunodeficiency syndrome. *Am J Ophthalmol.* 1993;115(5):575–82.
3. Campbell RJ, Chow B, Victor G, Kravcik S, Hodge WG. Treatment of CMV retinitis with intravitreal ganciclovir in the HAART era. *Can J Infect Dis.* 2001;12(5):300–4.
4. Jabs DA, Van Natta ML, Thorne JE, Weinberg D V, Meredith TA, Kuppermann BD, et al. Course of Cytomegalovirus Retinitis in the Era of Highly Active Antiretroviral Therapy. *Ophthalmology.* 2004;111(12):2224–31.
5. Visser L. Managing CMV retinitis in the developing world. *Community Eye Heal.* 2003;16(47):38–9.
6. López-Cortés LF, Pastor-Ramos MT, Ruiz-Valderas R, Cordero E, Uceda-Montañés A, Claro-Cala CM, et al. Intravitreal pharmacokinetics and retinal concentrations of ganciclovir and foscarnet after intravitreal administration in rabbits. *Investig Ophthalmol Vis Sci.* 2001;42(5):1024–8.
7. StataCorp. 2013. *Stata Statistical Software: Release 13.* College Station, TX: StataCorp LP.
8. Holladay J. Proper Method for Calculating Average Visual Acuity. *J Refract Surg.* 1997;13:388–91.
9. Jabs DA, Van Natta ML, Holbrook JT, Kempen JH, Meinert CL, Davis MD. Longitudinal Study of the Ocular Complications of AIDS. 1. Ocular Diagnoses at Enrollment. *Ophthalmology.* 2007;114(4):780–6.
10. Zambarakji HJ, Newson RB, Mitchell SM. CMVR diagnoses and progression of CD4 cell counts and HIV viral load measurements in HIV patients on HAART. *Br J Ophthalmol.* 2001;85(7):837–41.
11. Thorne JE, Jabs DA, Kempen JH, Holbrook JT, Nichols C, Meinert CL. Causes of Visual Acuity Loss among Patients with AIDS and Cytomegalovirus Retinitis in the Era of Highly Active Antiretroviral Therapy. *Ophthalmology.* 2006;113(8):1441–5.
12. Yen M, Chen J, Ausayakhun S, Kunavisarut P, Vichitvejpaisal P, Ausayakhun S, et al. Retinal Detachment Associated With AIDS-Related Cytomegalovirus Retinitis: Risk Factors in a Resource-Limited Setting. *Am J Ophthalmol.* 2015;159(1):185–92.

13. McCluskey P, Grigg J, Playfair TJ. Retinal detachments in patients with AIDS and CMV retinopathy: a role for laser photocoagulation. *Br J Ophthalmol.* 1995;79(2):153–6.



## Part E: APPENDICES

### Appendix A: Data capture form with coding

		Coding
Folder No.		
Age		
Gender		0=female 1=male
Eye		0=right 1=left
HIV status		.=unknown 0=negative 1=positive
Date of diagnosis		
Presenting visual acuity		Convert to LogMAR
CD4 count on presentation		
Macula involved		0=no 1=yes
Optic disc involved		0=no 1=yes
Number of quadrants involved		1, 2, 3, 4
Vasculitis		0=no 1=yes
Vitritis		0=no 1=yes
On HAART at presentation		0=no 1=yes
CMV PCR result		.=unkown/not done 0=negative 1=positive
Dates of injections		
Number of top-up injections after initial phase		
Was prophylactic laser performed		
CD4 count on discharge		
Did fellow eye become involved		0=no 1=yes
Final visual acuity		Convert to LogMAR
Treatment for systemic ganciclovir		0=no 1=yes
Complications		.=retinal detachment 0=infection 1=other (specify)

## Appendix B: Questionnaire: CMV retinitis treatment protocol

Dear Doctor,

I am doing my MMed dissertation on the clinical management and outcomes of CMV retinitis at Groote Schuur Hospital.

There is currently no standardised protocol that is being used nationwide. I would like to gather the management protocols of all the units in South Africa that treat CMV retinitis, and compare these. As part of the discussion for my dissertation, I would like to propose a standardised treatment regime that can be used by all units.

I would appreciate it if you would take a few minutes of your time to complete the questionnaire below.

Thank you

Dr Steven Lapere

1. How do you diagnose CMV retinitis at your unit?
  - a. Clinically only
  - b. PCR
  - c. Both clinically and PCR
  - d. Clinically, but we use PCR in cases with an atypical presentation
  - e. Other (specify)

Answer\_\_\_\_\_

2. How do you treat CMV retinitis at your unit?
  - a. Intravitreal ganciclovir injections
  - b. Intravenous ganciclovir
  - c. Intravenous acyclovir
  - d. Other (specify)

Answer\_\_\_\_\_

3. If you use intravitreal ganciclovir, how often are the injections given?
- a. Twice a week
  - b. Weekly
  - c. Every 2<sup>nd</sup> week
  - d. As needed
  - e. Other (specify)

Answer\_\_\_\_\_

4. Do you have a set regime for a minimum number of injections, or are patients re-evaluated at each visit?
- a. Set regime (specify how many and interval)
  - b. Re-evaluated at each visit

Answer\_\_\_\_\_

5. How often are patients asked to return for follow-up visits?
- a. Twice a week
  - b. Weekly
  - c. Every second week
  - d. Monthly
  - e. As needed
  - f. Other (specify)

Answer\_\_\_\_\_

6. What criteria do you use to decide if a repeat injection is necessary?
- a. Clinically – compared to previous drawing
  - b. Clinically – compared to previous fundus photograph

Answer\_\_\_\_\_

7. Do you perform prophylactic demarcation laser?

- a. Yes – all patients
- b. Yes – selected patients only
- c. No

Answer\_\_\_\_\_

8. Do you have fixed criteria for stopping treatment? What are these?

Answer\_\_\_\_\_

9. Are patients' CD4 counts monitored as part of the treatment?

Answer\_\_\_\_\_

10. How is it used if it is monitored?

Answer\_\_\_\_\_

11. When patients are not on ARV's, are they referred for commencement of ARV's?

Answer\_\_\_\_\_

## Appendix C: Department of Surgery Research Committee approval



UNIVERSITY OF CAPE TOWN

---

### Department of Surgery

#### Departmental Research Committee

**Professor Anwar Suleman Mall**

J-45 Room Old Main Building, Groote Schuur Hospital,  
Observatory 7925, South Africa

Tel (021) 406 6168/6232/6227 Fax (021) 448 6461

Email: [Anwar.Mall@uct.ac.za](mailto:Anwar.Mall@uct.ac.za)

25<sup>th</sup> February 2014

Dr S Lapere  
Department of Surgery  
Division of Ophthalmology  
Groote Schuur Hospital  
University of Cape Town

Dear Dr Lapere,

**RE: PROJECT 2014/019**

**PROJECT TITLE:** Cytomegalovirus retinitis at Groote Schuur Hospital: Clinical management and outcomes

The above proposal was reviewed by the Department of Surgery Research Committee and I am pleased to inform you that the committee approved the study.

Please use the above project number in all future correspondence.

Yours sincerely

**PROFESSOR ANWAR S MALL  
CHAIRMAN: RESEARCH COMMITTEE**

## Appendix D: Human Research Ethics Committee approval



UNIVERSITY OF CAPE TOWN  
Faculty of Health Sciences  
Human Research Ethics Committee



Room E52-24 Old Main Building  
Groote Schuur Hospital  
Observatory 7925  
Telephone [021] 406 6492 • Facsimile [021] 406 6411  
Email: [Sumayah.ariefeldien@uct.ac.za](mailto:Sumayah.ariefeldien@uct.ac.za)  
Website: [www.health.uct.ac.za/research/humanethics/forms](http://www.health.uct.ac.za/research/humanethics/forms)

29 May 2014

HREC/REF: 348/2014

Dr J Rice  
Department Ophthalmology  
H53.26  
OMB

Dear Dr Rice

**Project Title:** CYTOMEGALOVIRUS RETINITIS AT GROOTE SCHUUR HOSPITAL: CLINICAL MANAGEMENT AND OUTCOMES-MMeD-5 Lapere

Thank you for submitting your study to the Faculty of Health Sciences Human Research Ethics Committee for review.

It is a pleasure to inform you that the HREC has **formally approved** the above mentioned study.

**Approval is granted for one year until the 30 May 2015.**

Please submit a progress form, using the standardised Annual Report Form, if the study continues beyond the approval period. Please submit a Standard Closure form if the study is completed within the approval period.

***We acknowledge that the following student/s:- Steven Lapere is also involved in this project.***

Please note that the on-going ethical conduct of the study remains the responsibility of the principal investigator.

**Please quote the HREC REF in all your correspondence.**

Yours sincerely

**PROFESSOR M BLOCKMAN  
CHAIRPERSON, HSF HUMAN ETHICS**

Federal Wide Assurance Number: FWA00001637.

Hrec/ref:348/2014

## Acknowledgements

Dr James Rice: Mmed supervisor  
Dr Hamzah Mustak: Data analysis

## Turnitin originality report

Turnitin Originality Report

2015-06-24 11:16 nm.



### Turnitin Originality Report

lprste001:MMed\_final.doc by Steven Lapere

From For TurnItIn Submission - 2014 - 2015 (4f4f916e-b6ff-441b-bc4c-d486cb3882ed)

Similarity Index	Similarity by Source
26%	Internet Sources: 17% Publications: 22% Student Papers: 5%

Processed on 16-Jun-2015 22:27 SAST

ID: 550933633

Word Count: 8197

#### sources:

1 2% match (publications)

[Michael Stewart, "Optimal management of cytomegalovirus retinitis in patients with AIDS", Clinical Ophthalmology, 04/2010](#)

2 1% match (publications)

[the Studies of Ocular Complications of AIDS Research Group, "Course of cytomegalovirus retinitis in the era of highly active antiretroviral therapy", Ophthalmology, 200412](#)

3 1% match (publications)

[Studies of Ocular Complications of AIDS Research Group, "Course of cytomegalovirus retinitis in the era of highly active antiretroviral therapy", Ophthalmology, 200412](#)

4 1% match (publications)

[Studies of Ocular Complications of AIDS \(SOCA\) Research Group, "Evaluation of the United States Public Health Service Guidelines for Discontinuation of Anticytomegalovirus Therapy After Immune Recovery in Patients With Cytomegalovirus Retinitis", American Journal of Ophthalmology, 201110](#)

5 1% match (publications)

[Hodge, W.G., "Clinical risk factors for cytomegalovirus retinitis in patients with AIDS", Ophthalmology, 200407](#)

6 1% match (publications)

[Miller, J.J., "Endophthalmitis caused by streptococcus pneumoniae", American Journal of Ophthalmology, 200408](#)

7 1% match (Internet from 07-Aug-2013)

<http://www.sajhivmed.org.za/index.php/sajhivmed/article/view/804/685>

8 1% match (publications)

[J. Fernando Arevalo, "Angiography of Inflammatory Diseases in Immunocompetent and](#)