

The incidence of recurrence after Delorme's
procedure for full thickness rectal prolapse - a
retrospective private-public cohort study

by

Dr Jeremy John Plaskett

MBChB (UCT) . FCS (SA)

Student Number: PLSJER001

Submitted in fulfilment of the requirements for the degree:

Master of Medicine (Surgery)

by minor-dissertation

DIVISION OF COLORECTAL SURGERY
DEPARTMENT OF SURGERY
GROOTE SCHUUR HOSPITAL
UNIVERSITY OF CAPE TOWN
2016



Supervisors:

Professor R.J. Baigrie

Professor P. Goldberg

Professor D. Kahn

The copyright of this thesis vests in the author. No quotation from it or information derived from it is to be published without full acknowledgement of the source. The thesis is to be used for private study or non-commercial research purposes only.

Published by the University of Cape Town (UCT) in terms of the non-exclusive license granted to UCT by the author.

DECLARATION

I, Dr Jeremy John Plaskett, hereby declare that the work on which this dissertation is based is my original work and that neither the whole work or any part of it has been, is being, or is to be submitted for another degree in this or any other university.

Signature: Signed by candidate
Signature removed

Date: 24 November 2016

ABSTRACT

Background: Delorme's perineal repair has remained a procedure reserved for full-thickness rectal prolapse in elderly or co-morbid patients due to its low morbidity and complications. Reported recurrence rates are higher than in abdominal approaches.

Aim: The study assesses long-term outcomes after Delorme's procedure (DP), specifically recurrence and postoperative bowel function, in both a multi-surgeon public hospital and a single surgeon cohort in the private sector (Groote Schuur Hospital and Kingsbury Hospital).

Patients and Methods: This retrospective cohort study includes all patients who underwent DP between February 2001 and March 2014 at both study sites. The primary outcome was absence of recurrence. Secondary outcomes were bowel function (incontinence and constipation), postoperative mortality and morbidity and length of hospital stay. Patient data was collected from electronic records (Kingsbury Hospital) and paper folders/op notes (Groote Schuur Hospital) and current status was acquired by telephonic interview with either the patient, a family member or caregiver, as appropriate.

Results: Seventy patients underwent DP: 37 private and 33 public, mean age 71yrs. There were 16 (23%) recurrences (7 private, 9 public), of which 8 (11%) underwent reoperation. Mean time to recurrence was 30 months (48 private; 15 public). There were 2 postoperative deaths (pneumonia, myocardial infarction), 6 major complications (rectal bleeding requiring transfusion or reoperation, bowel obstruction, pneumonia, myocardial infarction), and 6 minor complications (rectal pain, rectal bleeding not requiring reoperation or transfusion, urinary retention, confusion, hyponatraemia). The mean postoperative hospital stay was 4 days.

Conclusion: Long-term outcome from this large series compares favorably with most other published series, specifically a low recurrence rate. Proposed reasons for this will be presented, within the context of the published literature.

TABLE OF CONTENTS

CHAPTER 1

Literature review

1. Background	Pg. 7
1.1 Introduction & history	Pg. 7
1.2 Epidemiology	Pg. 8
2. Spectrum of pelvic floor dysfunction	Pg. 9
2.1 Dyssynergic defaecation	Pg. 11
2.2 Descending perineum syndrome	Pg. 14
2.3 Rectal intussusception	Pg. 15
2.4 Rectocele	Pg. 16
2.5 Solitary rectal ulcer syndrome	Pg. 17
2.6 Enterocoele	Pg. 18
3. Pathophysiology of rectal prolapse	Pg. 19
3.1 Normal anatomy	Pg. 19
3.2 Aetiology	Pg. 19
4. Diagnosis	Pg. 22
4.1 Presentation	Pg. 22
4.2 Patient workup	Pg. 22
4.3 Defaecography	Pg. 23
4.4 Ultrasound	Pg. 24
4.5 Classification	Pg. 26
5. Management	Pg. 28
5.1 Abdominal approach	Pg. 28
5.1.1 Open rectopexy	Pg. 28
5.1.2 Laparoscopic rectopexy	Pg. 29

The incidence of recurrence after Delorme's procedure for full thickness rectal prolapse - a retrospective private-public cohort study.

5.1.3	Anterior resection	Pg. 32
5.1.4	Resection rectopexy	Pg. 32
5.2	Perineal approach	Pg. 33
5.2.1	Altemeier's procedure	Pg. 34
5.2.2	Delorme's procedure	Pg. 36
6.	Summary	Pg. 39
7.	Conclusion	Pg. 40
8.	Research proposal	Pg. 41
9.	References	Pg. 44

CHAPTER 2

Publication-ready manuscript

1. Introduction	Pg. 57
2. Patients & methods	Pg. 57
2.1 Surgical technique	Pg. 58
2.2 Follow-up	Pg. 59
2.3 Statistical analysis	Pg. 59
3. Results	Pg. 59
3.1 Preoperative characteristics	Pg. 59
3.2 Surgical complications	Pg. 62
3.3 Outcome following Delorme's procedure	Pg. 62
3.4 Changes in bowel function following Delorme's procedure	Pg. 63
4. Discussion	Pg. 65
5. Conclusion	Pg. 67
6. References	Pg. 68
7. Appendix	Pg. 71

The incidence of recurrence after Delorme's procedure for full thickness rectal prolapse - a retrospective private-public cohort study.

The incidence of recurrence after Delorme's procedure for full thickness rectal prolapse - a retrospective private-public cohort study.

Principle Investigator:

J.J. Plaskett, Registrar, General Surgery, Groote Schuur Hospital, University of Cape Town

Research Supervisors:

R.J. Baigrie, Professor, Colorectal Surgery, Kingsbury & Groote Schuur Hospital

P. Goldberg, Professor, Colorectal Surgery, Groote Schuur Hospital

D. Khan, Professor, Head of Department, General Surgery, Groote Schuur Hospital, University of Cape Town

CHAPTER 1: Literature Review

1. Background

1.1 Introduction & History

Three different clinical entities are often combined under the umbrella term rectal prolapse, comprising a spectrum of anatomical abnormalities involving descent (of variable length) of full- or partial-thickness rectal wall associated with pelvic floor dysfunction – according to the criteria stated at the Tripartite Consensus Conference on Definitions for Anorectal Physiology and Rectal Cancer:

- Full-thickness rectal prolapse or complete rectal prolapse (procidentia), defined as protrusion of all layers of the rectal wall through the anus
- Mucosal prolapse or incomplete prolapse, defined as protrusion of only the rectal mucosa through the anus
- Internal/occult prolapse or intussusception, where the prolapsed tissue (either full-thickness or partial wall) does not pass beyond the anal canal (Felt-Bersma, Tiersma & Cuesta, 2008).

The incidence of recurrence after Delorme's procedure for full thickness rectal prolapse - a retrospective private-public cohort study.

This condition was reported as early as 400-500 BC by Egyptian and Greek civilizations, and first documented in the Ebers Papyrus of 1500 BC. Hippocrates proposed the first treatment for rectal prolapse by hanging the patient upside down and vigorously shaking him. An abundance of aetiological theories and surgical treatments have been documented since then. In recent years, the restoration of normal function has gained greater emphasis over the restoration of normal anatomy in the surgical management of proctodistal treatments. As a result, the different approaches and techniques described in the literature are no longer judged solely by their reported recurrence rate, but rather considered along with their patient- and symptom-specific functional results too. Division of the pelvic floor into anterior, middle and posterior compartments has replaced the traditional organ-specific approach in order to reduce the problem of fragmentation amongst the various disciplines: the anterior compartment containing the urethra and bladder has become the realm of the urologist and urogynaecologist, the middle compartment containing the uterus and reproductive organs has been the domain of the gynaecologist, and the posterior compartment containing the small and large intestine and anorectum belongs to the colorectal surgeon. Recognition of rectal prolapse as a key component of the syndrome of pelvic floor dysfunction has led to a multidisciplinary approach to managing this challenging problem – dysfunction in one compartment may influence the structure and function of another. Improvements in safety with laparoscopic rectopexy coupled with the functional advantages of a ventral, nerve-sparing approach have further paved the way towards an optimal abdominal prolapse repair. The abdominal vs perineal dilemma, however, still remains unanswered, although there is growing consensus.

1.2 Epidemiology

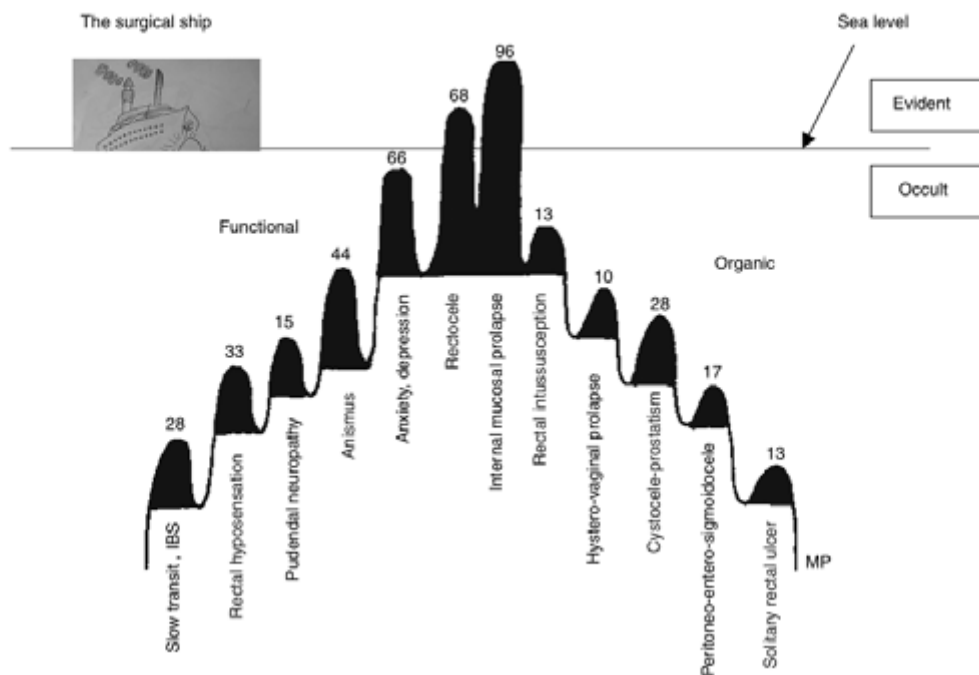
Women above the age of 50yrs are at least six times more likely than men to develop rectal prolapse, with the condition occurring mainly in elderly and multiparous women (90%) (Jacobs, Lin & Orkin, 1997). But underreporting by patients means the true incidence is unknown. Despite the common assumption that rectal prolapse is a consequence of multiparity, 35% of female patients are nulliparous (Wassef, Rothenberger & Goldberg, 1986). Peak occurrence is in the 4th and 7th decades in men and women respectively. Young male patients with rectal prolapse have been found to have a tendency to have psychiatric / neurologic comorbidities as well as significant symptoms related to bowel function (Marceau et al., 2005), but the condition is well described in well adjusted young males and females, with no comorbidities or history of sexual abuse or anal penetration.

2. Spectrum of Pelvic Floor Dysfunction

Pelvic floor dysfunction may result from both functional (dyssynergic defaecation) and structural (rectal prolapse, rectal intussusception, solitary rectal ulcer syndrome (SRUS), rectocele, enterocele, descending perineum syndrome) abnormalities, with a wide spectrum of disease and disability. Damage to this intricate support structure ultimately results in abnormal descent of the urinary bladder, the uterovaginal vault, and the rectum, leading to symptoms of urinary incontinence, faecal incontinence and complete external pelvic organ prolapse. The aetiology is invariably multi-factorial. Risk factors include pregnancy, multiparity, obesity, connective tissue disorders, smoking, chronic obstructive pulmonary disease, and factors that result in a chronic rise in intra-abdominal pressure. Symptoms of pelvic floor dysfunction are wide and varied depending on severity and which compartment is affected. Posterior compartment dysfunction results in abnormalities to rectal anatomy and defaecatory function. These include: constipation, obstructed defaecation, and a sensation of incomplete evacuation. Small volumes of residual stool left in the rectum between defaecation episodes may unwittingly escape, leading to reports of faecal incontinence.

An important aspect of managing this difficult group of patients was highlighted by Pescatori et al in a prospective evaluation of occult disorders in obstructed defaecation. His novel 'iceberg diagram' recognizes these disorders as an 'iceberg syndrome' characterized by 'underwater rocks' or occult diseases which may affect the outcome of surgical management. Adequate evaluation of these occult diseases, such as psychological disorders (anxiety and depression), functional disorders (dyssynergic defaecation, rectal hyposensation, pudendal neuropathy), and organic disorders (urogynaecological diseases), results in better tailored treatment for patients. As a result, conservative management (psychological counseling, behavioural modification, and biofeedback) should precede any decisions regarding surgery (Pescatori, Spyrou & Pulvirenti d'Urso, 2007).

The incidence of recurrence after Delorme's procedure for full thickness rectal prolapse - a retrospective private-public cohort study.



Source: A prospective evaluation of occult disorders in obstructed defecation using the 'iceberg diagram'. M. Pescatori (2006)

The pelvic floor consists of superficial and deep muscle layers that interlace and envelop the rectum, bladder and uterus. Superficial muscle layers such as the internal and external anal sphincters, the perineal body and the transverse perinei muscles are relevant to anal function (Raizada & Mittal, 2008). The deep pelvic muscles (levator ani) consist of pubococcygeus, ileococcygeus and puborectalis. It is the traction of the puborectalis muscle that maintains the anorectal angulation and creates a mechanical barrier for stool flow from the rectum (Azpiroz et al., 2005). Neurological innervations, primarily from the pudendal nerve, as well as from sympathetic and parasympathetic nerves facilitate the normal function of the pelvic floor.

The neuromuscular components of the pelvic floor play a central role in the primary functions of defaecation, micturition, and sexual function. Defaecation requires coordinated relaxation of the anal sphincters and puborectalis muscle (allowing the anorectal angle to widen and the perineum to descend) along with voluntary contraction (straining) of the abdominal muscles. This simultaneous effort of bearing down increases intra-abdominal pressure, together with contraction of the rectum and relaxation of the puborectalis muscle. The complex mixed voluntary and involuntary movements facilitate the development of a stripping wave which moves the stool from the rectum and relaxes the pelvic floor muscles and the anus, resulting in stool evacuation (Quigley, 2013).

2.1 Dyssynergic defaecation

This condition is characterized by failure of recto-anal coordination manifesting as either impaired rectal contraction, paradoxical anal contraction, or inadequate anal relaxation (Rao, Welcher & Leistikow, 1998). Many other terms have been used in the literature to describe this condition: anismus, pelvic floor dyssynergia, obstructed defaecation syndrome, paradoxical puborectalis contraction, pelvic outlet obstruction, and spastic pelvic floor syndrome. It is commonly found in patients suffering from chronic constipation, with an incidence of 40-50% in one study (Rao et al., 2004). It is characterized by excessive straining at defaecation, a dependency on laxatives and enemas, a sense of incomplete evacuation or fragmented defaecation, abdominal bloating and rectal discomfort, the passage of hard pellet-like stools, and less than 3 satisfactory bowel movements per week (Rao et al., 2004). The most frequent associated anatomic findings are rectocele and rectal intussusception sometimes resulting in solitary rectal ulcer syndrome (Jayne, Schwandner & Stuto, 2009). Diagnosis is suspected on history and digital rectal examination – the patient will usually demonstrate paradoxical contraction of their external anal sphincter and puborectalis muscle when asked to bear down. Investigations include anorectal manometry (measuring anal and rectal pressures at rest and during simulated defaecation, rectal compliance, rectal sensation, and recto-anal reflex), a colonic transit study, and a balloon expulsion test with the patient in the sitting position to further investigate chronic constipation thought to be due to dyssynergic defaecation.

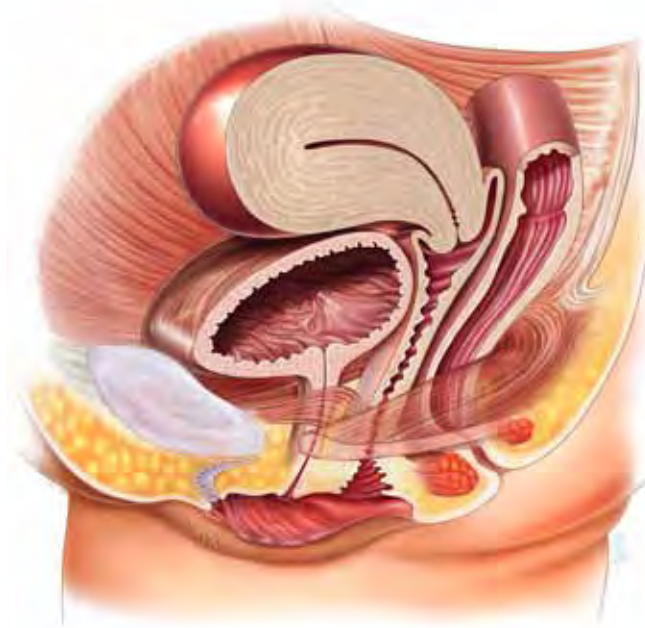
However, all these investigations may remain inconclusive and can be omitted if defaecography is available. This involves syringe insertion of barium paste into the patient's rectum and using video fluoroscopy to record anatomical and functional changes as the patient bears down to evacuate the barium. The morphology of the rectum and anal canal in correlation with bony pelvic components are evaluated both statically and dynamically. Incomplete evacuation during defaecography and prolonged evacuation time provide quantifiable measures of abnormal defaecation when investigating this group of patients (Rao, Welcher & Leistikow, 1998). But the primary characteristic is a lack of pelvic floor descent during straining and evacuation with paradoxical contraction of the levator ani muscle (Faccioli et al., 2010).

Management of this condition is non-surgical and includes: avoiding any constipating medications, increasing dietary fibre intake, increasing fluid intake, physical exercise, timed toilet training, and laxatives (stool softeners, stimulant and osmotic). Biofeedback achieves successful results (normalizing rectal and anal manometry pressures) in up to 75% of patients, and 4 randomized

The incidence of recurrence after Delorme's procedure for full thickness rectal prolapse - a retrospective private-public cohort study.

controlled trials have shown that biofeedback is superior to laxatives, sham feedback, standard therapy, placebo, and diazepam (Rao et al., 2007)(Chiarioni, Salandini & Whitehead, 2005)(Chiarioni et al., 2006)(Heymen et al., 2007). Biofeedback restores the normal pattern of defaecation using an instrument-based learning process based on 'operant-conditioning' techniques by correcting the underlying dyssynergia involving the abdominal, rectal and anal muscles, and improves rectal sensory perception in those with impaired rectal sensation (Rao, 1998).

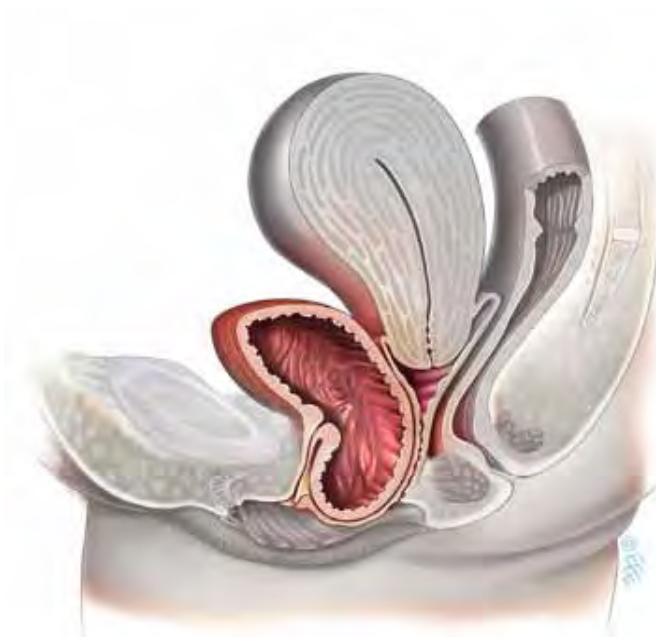The pelvic floor is divided into three compartments. The anterior compartment contains the urinary bladder and the urethra; the middle compartment contains the uterus, cervix, and vagina; and the posterior compartment contains the rectum. The support for these structures arises from the attachment of the muscles, fascia, and ligaments to the bony pelvis. It is the weakness of these supporting muscles, fascia, and ligaments that result in pelvic floor relaxation, dysfunction and ultimately pelvic organ prolapse.



Source: IUGA. Pelvic Organ Prolapse: A Guide For Women (2011)
https://c.ymcdn.com/sites/www.iuga.org/resource/resmgr/brochures/eng_pop.pdf

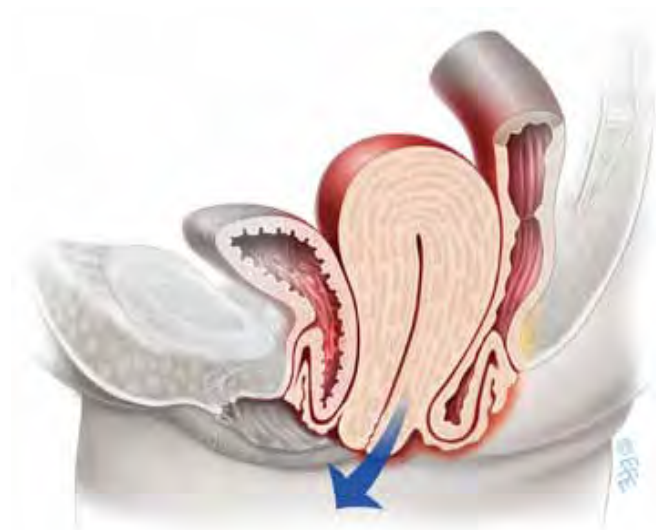
The incidence of recurrence after Delorme's procedure for full thickness rectal prolapse - a retrospective private-public cohort study.

In anterior compartment prolapse, loss of support to the urinary bladder and the urethra results in prolapse of the urinary bladder and protrusion of the anterior vaginal wall, forming a cystocele, which may result in urinary incontinence.



Source: IUGA. Pelvic Organ Prolapse: A Guide For Women (2011)
https://c.ymcdn.com/sites/www.iuga.org/resource/resmgr/brochures/eng_pop.pdf

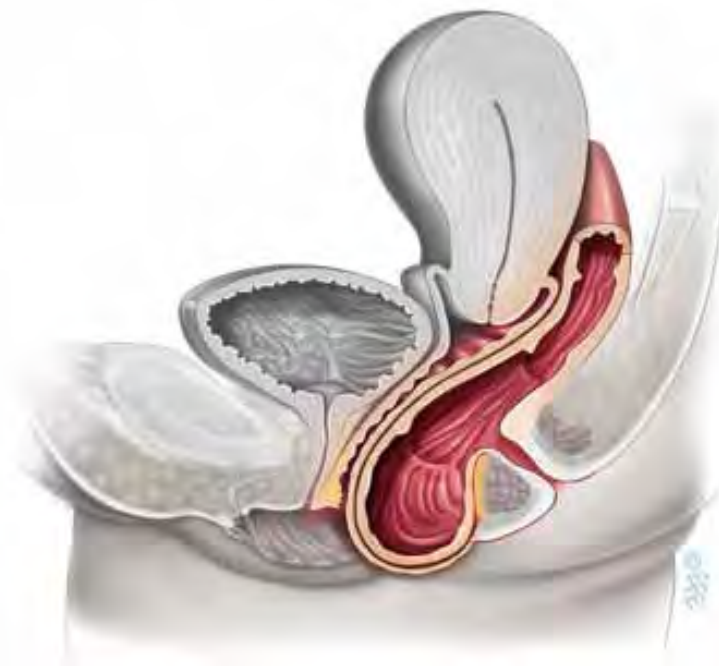
Weakness of the parametrium and paracolpium causes prolapse of the cervix and uterus in middle compartment prolapse. In patient who have undergone a hysterectomy, prolapse of the vaginal apex can arise because of weakness of the paracolpium, resulting in apical or vault prolapse.



Source: IUGA. Pelvic Organ Prolapse: A Guide For Women (2011)
https://c.ymcdn.com/sites/www.iuga.org/resource/resmgr/brochures/eng_pop.pdf

The incidence of recurrence after Delorme's procedure for full thickness rectal prolapse - a retrospective private-public cohort study.

In posterior compartment prolapse, weakness of the rectovaginal fascia results in prolapse of the rectum and protrusion of the posterior vaginal wall forming a rectocele, and may result in faecal incontinence on the basis of incomplete evacuation at defaecation. Prolapse of the small bowel through the rectovaginal fascia, to occlude the rectum and obstruct defaecation, results in an enterocele. This can also occur when the small bowel prolapses through the vaginal vault after hysterectomy.



Source: IUGA. Pelvic Organ Prolapse: A Guide For Women (2011)
https://c.ymcdn.com/sites/www.iuga.org/resource/resmgr/brochures/eng_pop.pdf

2.2 Descending perineum syndrome

Excessive perineal descent is characterized by ballooning of the perineum several centimetres below the bony pelvic outlet during straining (Pucciani et al., 2005). Descending perineum syndrome, a term first coined by Parks et al (Parks, Porter & Hardcastle, 1966), indicates an element of pelvic floor weakness and is usually associated with other anorectal disorders such as rectal prolapse, rectocele, SRUS, and enterocele (Harewood et al., 1999). Diagnosis is based on Parks' and colleagues criteria on physical examination whereby the anal canal is examined in the left lateral position for rapid descent of > 3 cm during straining (Pucciani et al., 2005).

Defaecographic criteria for diagnosis is more than 3.5 cm of caudal descent of the anorectal

The incidence of recurrence after Delorme's procedure for full thickness rectal prolapse - a retrospective private-public cohort study.

junction from rest to maximum straining. The anorectal angle is usually greater than 130 degrees at rest (Faccioli et al., 2010). The Oxford Pelvic Floor Centre regards internal rectal prolapse as the central component of a commonly coexisting triad along with a rectocele (with or without an enterocele) and a descending pelvic floor – with 80% of patients having a coexisting rectocele and internal rectal prolapse, and the remainder having either an isolated rectocele (10%) or internal rectal prolapse (10%) (Lindsey, Nugent & Dixon, 2011). A previous hysterectomy is often found to be a predisposing condition to the development of these disorders (Pucciani et al., 2005). Symptoms include: painful defaecation, impaired defaecation, excessive straining during defaecation, sense of incomplete evacuation, and faecal incontinence. Excessive repeated straining causes the anterior rectal wall to protrude into the anal canal, creating a sensation of incomplete evacuation, causing more straining and establishing a vicious cycle. Entrapment and stretch injury to the pudendal nerves result in denervation of the anal sphincter muscles and faecal incontinence (Henry, Parks & Swash, 1982)(Ho & Goh, 1995). Biofeedback is recommended to correct the excessive straining and the components may be surgically repaired on their merits (as the components are individually better understood and managed differently as described below).

2.3 Rectal intussusception

Also known as occult or internal rectal prolapse, rectal intussusception is often associated with other structural abnormalities of the posterior pelvic floor (rectocele, SRUS, pudendal neuropathy, and previous sphincter damage). It is often a consequence of untreated dyssynergic defaecation (Felt-Bersma, Tiersma & Cuesta, 2008). It is not always a pathological finding, and 50-60% of healthy individuals may demonstrate some degree of rectal intussusception on defaecography (Shorvon et al., 1989). The mucosal protrusion usually originates 6-8cm above the anal canal at the level of the main rectal fold, and is almost exclusively found on the anterior rectal wall with a thickness less than 1cm (Karasick, Karasick & Karasick, 1993). Patients will most often report a feeling of incomplete evacuation, although it may only be detected on clinical examination in a third of patients. For this reason, defaecography is the most useful investigation in establishing a diagnosis of rectal intussusception. The role of surgery in managing this condition is controversial and non-operative management should always be the first line of treatment. This includes stool softeners, patient education, and biofeedback to address any underlying dyssynergia. Surgery should be reserved for patients with large intussusceptions with refractory symptoms and in whom all conservative and behavioural approaches have failed over several years. The poor surgical

The incidence of recurrence after Delorme's procedure for full thickness rectal prolapse - a retrospective private-public cohort study.

results of posterior rectopexy led to the abandonment of surgical treatment of this condition for 15 years (Orrom et al., 1991), however, excellent functional results of the nerve-sparing anterior rectopexy have been reported in recent years, reviving this treatment modality (Slawik et al., 2008)(Collinson et al., 2010). Stapled transanal rectal resection (STARR) was a novel approach to restore normal anatomy in patients with large symptomatic rectal intussusception and rectocele by strengthening the rectovaginal septum and resecting redundant tissue from the anterior and posterior rectal walls (Corman et al., 2006). Derived from stapled haemorrhoidopexy introduced by Antonio Longo in 1998 (Longo, 2002), initial series by enthusiasts of the STARR procedure reported promising results for the treatment of rectal intussusception (Boccasanta et al., 2004)(Schwandner & Fürst, 2007). A large number of case reports and case series, however, have highlighted serious major complications following STARR (Pescatori & Gagliardi, 2008)(Pescatori & Gagliardi, 2008)(Gagliardi et al., 2008) and skepticism regarding the safety and effectiveness of this procedure has limited its adoption outside of a few centers. A high incidence of recurrent symptoms has emerged with longer follow-up (Schwandner et al., 2008). The STARR pioneers were established in 2006 to address this lack of evidence-based data (Schwandner et al., 2008), and the European STARR Registry was established in the same year in order to accrue a sufficient amount of data (on the basis of a lack of a suitable surgical comparator for a randomized trial) (Jayne, Schwandner & Stuto, 2009). The one-year results of the European STARR Registry concluded that further investigation is required to optimize patient selection and to reduce the potential complications of postoperative defaecatory urgency, incontinence and pain following this procedure (Jayne, Schwandner & Stuto, 2009). This has remained lacking as enthusiasm for the procedure has declined.

2.4 Rectocele

This is a protrusion of the rectal wall, usually anterior and towards the vagina caused by weakness of the pelvic floor and rectovaginal septum. Outpouchings smaller than 2cm are frequently found in asymptomatic females without clinical significance and are not considered pathological (Shorvon et al., 1989). Despite this, they are often incorrectly blamed for defaecatory problems and repaired unnecessarily. Obstetric injury from multiple vaginal deliveries is a commonly described risk factor and it is often seen in postmenopausal women (Felt-Bersma, Tiersma & Cuesta, 2008). Associated structural abnormalities include previous hysterectomy and rectal intussusception, but it is also associated with dyssynergic defaecation, whether the latter two are cause or effect. Symptoms are

The incidence of recurrence after Delorme's procedure for full thickness rectal prolapse - a retrospective private-public cohort study.

sometimes non-specific and include: pelvic pain, feeling of heaviness or something coming down, backache, constipation, faecal soiling, urologic problems, and dyspareunia (Felt-Bersma, Tiersma & Cuesta, 2008). These symptom collections are a reflection of the association of rectocele with other pelvic floor disorders. In addition to these symptoms, diagnosis is based on inspection and digital rectal and vaginal examination, revealing an anterior bulging of the rectal wall (more evident on straining). The Pelvic Organ Prolapse Quantification (POP-Q) is used to grade pelvic organ prolapse – using 6 different measurements of the female genital area to grade genital prolapse into 4 stages (Bump et al., 1996). Based on defaecography, it consists of an anterior bulge of the rectal wall wider than 2cm in the anteroposterior diameter (Mezwa, Feczko & Bosanko, 1993). Three degrees of rectocele can be classified by defaecography: first degree (< 2cm); second degree (2-4cm); and third degree (> 4cm) (Faccioli et al., 2010). Because surgical management of symptomatic rectoceles leads to frequent recurrences, first line treatment is non-surgical, consisting of stool softeners and patient education. Surgery is only considered appropriate in larger rectoceles (> 4 cm) or after conservative medical therapy has failed, performed either through a vaginal or transanal approach (Felt-Bersma, Tiersma & Cuesta, 2008). The STARR procedure remains controversial in treating patients with a rectocele, because of its high failure rate and risk of serious complications (Corman et al., 2006).

2.5 Solitary rectal ulcer syndrome (SRUS)

Repeated forceful straining against an unyielding, immobile pelvic floor eventually results in mucosal ulceration as a result of ischaemic necrosis of the prolapsing rectal mucosa. This condition is often associated with rectal intussusception on defaecography (40-80% of patients), but primarily with dyssynergic defaecation (82% In a prospective study following 11 patients with refractory SRUS) (Felt-Bersma, Tiersma & Cuesta, 2008)(Rao et al., 2006). Spontaneous resolution of SRUS during pregnancy suggests that hormones may play a role in its pathogenesis (Sood, Garner & Amin, 2008), although the alterations in pelvic floor behaviour during pregnancy are also a likely contributor. Symptoms include rectal bleeding, rectal pain, mucus discharge, straining and tenesmus, and a sense of incomplete evacuation. About 55% of patients will present with constipation, 20-40% with diarrhoea, and 25% are asymptomatic (Felt-Bersma, Tiersma & Cuesta, 2008). Up to a quarter of patients are misdiagnosed as having inflammatory bowel disease (Felt-Bersma, Tiersma & Cuesta, 2008). Diagnosis is made on sigmoidoscopy – a small, shallow ulcer with white slough or a hyperemic mucosa is seen on the anterior wall of the rectum. Occasionally

The incidence of recurrence after Delorme's procedure for full thickness rectal prolapse - a retrospective private-public cohort study.

these can be large with very thickened adjacent muscle and mucosa and hence mistaken for rectal cancer. Biopsy will differentiate SRUS from other causes of rectal ulceration, particularly IBD and malignancy, the pathognomonic finding being muscularisation of the lamina propria. Ulceration, invariably very superficial, need not be present and exuberant granulation tissue (a cap polyp, or even a cluster of small polyps) may be found. Biofeedback, behavioural and dietary advice make up the most important forms of treatment. Patients are advised not to strain during defaecation and to avoid all digital rectal maneuvers. Biofeedback is the most effective treatment modality, with 75% of patients experiencing symptomatic improvement and 31% showing resolution of the lesion on sigmoidoscopy (Jarrett et al., 2004). Surgery is reserved for highly selected cases. Constipation was a common complication after traditional open rectopexy (Felt-Bersma, Tiersma & Cuesta, 2008) and, as a result, the laparoscopic procedure is preferable with a minimal denervation technique. Anterior excision of the rectum has not been associated with encouraging results and in some cases has worsened symptoms. Even rectal excision with coloanal anastomosis is associated with recurrence (Vaizey, Roy & Kamm, 1997)

2.6 Enterocoele

This is a peritoneum-lined sac, usually containing small bowel, which herniates into the space between the vagina and rectum (Pouch of Douglas), producing symptoms of obstructive defaecation. Although epidemiology is not completely understood, there is a higher incidence amongst women who have undergone a hysterectomy. Additional anorectal abnormalities such as rectocoele, descending perineum syndrome, and rectal intussusception often coexist. Symptoms of enterocoele include pelvic pain or heaviness (usually worst on standing and disappearing on lying down), straining and incomplete evacuation. Diagnosis relies on demonstrating the structural deformity on defaecography – opacified ileal loops seen in a widened retovaginal space (with or without air) on straining or evacuation (Faccioli et al., 2010). Biofeedback is the therapy of choice. Although functional outcomes from surgery are historically poor, some patients might benefit from surgical intervention, and it should be reserved for those with persistent and debilitating pelvic pain and uncontrollable symptoms (Takahashi et al., 2006). The goal of surgery is to obliterate the pouch of douglas and can be performed through an abdominal (open or laparoscopic) or transvaginal approach (Felt-Bersma, Tiersma & Cuesta, 2008). Despite surgical correction of the structural defect, symptoms of obstructive defaecation persisted in 75% of patients after long term follow-up in one study (Oom et al., 2007).

3. Pathophysiology of Rectal Prolapse

3.1 Normal Anatomy

The rectum constitutes the distal 12-15cm of the large intestine and primarily serves as a reservoir for faecal material. It follows the curvature of the sacrum and coccyx, ending at the tip of the coccyx by piercing the pelvic diaphragm. The rectum can be divided into 3 parts: the upper third is covered by peritoneum on its anterior and lateral surfaces, mid third is covered by peritoneum only on its anterior surface, and the distal third devoid of peritoneum. Columnar epithelium forms the inner mucosal lining of the rectum (endoderm), and is separated from the squamous epithelium of the distal anal canal (ectoderm) by an anal transitional zone (ATZ) above the dentate line. The internal anal sphincter is the most distal extension of the inner circular smooth muscle layer of the colon and rectum and is not under voluntary control. The external anal sphincter is striated muscle forming a circular tube around the anal canal. Proximally, it merges with the puborectalis muscle and levator ani to form a single muscular complex under voluntary control.

3.2 Aetiology

Two competing theories evolved in the twentieth century to explain the aetiology of rectal prolapse:

- Alexis Moschcowitz postulated in 1912 that rectal prolapse is caused by a defect in the pelvic floor fascia resulting in a sliding hernia of the pouch of Douglas with increasing intra-abdominal pressure (Moschcowitz, 1912)
- With the advent of defaecography in 1968, Broden and Snellman showed that procidentia is a full-thickness rectal intussusception starting approximately three inches above the dentate line and extending through the anus (Brodén & Snellman, 1968)

Although a unifying pathophysiology of the condition remains unknown, it is often associated with long-standing constipation and numerous theories for its pathophysiology exist. Abnormal motor activity of the pelvic floor muscles seems to be important. In some cases, functional disturbances result from intense, repeated straining against a pelvic floor which does not relax concomitantly. This may eventually cause rectal wall intussusception and a sensation of incomplete evacuation and obstructed defaecation, resulting in a vicious cycle of further straining. In this way, rectal prolapse

The incidence of recurrence after Delorme's procedure for full thickness rectal prolapse - a retrospective private-public cohort study.

most likely begins as a mid-rectal anterior intussusception in keeping with Broden & Snellman's original defecographic findings (Devadhar, 1965). In response to this chronic and prolonged straining when passing stool, the pelvic floor muscles become stretched, the perineum descends, and the pudendal nerve becomes stretched. This traction injury results in a pudendal neuropathy with denervation of the anal sphincters and puborectalis muscle. Over time, with continued straining, the initial intussusception of rectum begins to protrude beyond the anus. Similarities in manometric findings among patients with rectal prolapse and rectal intussusception support the hypothesis of this common pathophysiology (Sun et al., 1989).

Other causes of a chronically increased abdominal pressure, such as COPD and Cystic Fibrosis, have been implicated in the same way. A number of anatomical and physiological abnormalities have been described in association with the development of rectal prolapse – whether these are primary and causative or secondary to the prolapse. These include:

- Diastasis of the levator ani with lax/atonic muscles of the pelvic floor and anal canal
- An abnormally deep pouch of Douglas
- A redundant sigmoid colon
- A patulous anal sphincter
- Lack of the normal rectosacral attachments with a mobile mesorectum
- Proximal bilateral pudendal neuropathy resulting in denervation atrophy of the external sphincter - this can be due to either direct trauma (obstetric injury), chronic disease (diabetes), neoplastic processes involving the sacral nerve roots or from back injury or surgery (Kuijpers, 1992)(Brodén & Snellman, 1968).

In addition to the above risk factors, connective tissue and neurological disorders, as well as high parity and previous pelvic floor surgery, are thought to be predisposing factors.

A recent reappraisal of the pathophysiology of internal rectal prolapse has shown the natural history of this condition to be one of general progression through various grades until the appearance of external rectal prolapse (Wijffels et al., 2010). There is ongoing debate about its clinical significance. Some suggest that it represents the first stage of a progressive abnormality eventually leading to full-thickness external rectal prolapse (Devadhar, 1965)(Brodén & Snellman, 1968)(Ihre & Seligson). Other studies, however, have shown that progression of rectal intussusception to full-thickness external rectal prolapse is rarely observed at long-term follow-up (Mellgren et al., 1997)(Choi et al., 2001). Furthermore, rectal intussusception is a common defecographic finding

The incidence of recurrence after Delorme's procedure for full thickness rectal prolapse - a retrospective private-public cohort study.

(50-60%) in asymptomatic individuals (Shorvon et al., 1989). These studies may have been limited by including individuals with clinically insignificant mucosal and low-grade recto-rectal intussusceptions overstating the frequency of true asymptomatic recto-anal intussusceptions. Prior to this study, Pomerri et al (Pomerri et al., 2001) and Dvorkin et al (Dvorkin et al., 2005) both showed that internal rectal prolapse is significantly different in morphology in symptomatic compared with asymptomatic patients and identified an association between severity, degree of rectal prolapse and symptoms. Pomerri et al reported a greater intussusception thickness, and a greater ratio between intussusciens diameter and intussusceptum lumen in symptomatic patients. Dvorkin et al, on the other hand, found that patients with symptoms of obstructed defaecation had a significantly thicker intussusceptum as well as a higher incidence of an occluding intussusception. Symptomatic patients had predominantly full-thickness intussusception, whereas asymptomatic patients had mucosal intussusception.

4. Diagnosis of rectal prolapse

4.1 Presentation

Patients with full-thickness rectal prolapse will most often describe a sensation of something coming down and protruding through the anal canal with defaecation or straining. Minimal external or spontaneously reducible prolapses may progress with time, requiring manual reduction and later, prolapsing simply on standing or walking until it becomes increasingly difficult to keep reduced. This is associated with chronic mucous drainage, intermittent bleeding, soiling, and incontinence. Chronically prolapsed rectal mucosa may become thickened or ulcerated and cause significant bleeding. Rarely, the prolapsed rectum can become irreducible and, if not resolved with gentle pressure or topical sugar, may require emergency surgery.

Women may complain of concomitant anterior pelvic organ prolapse and associated genitourinary symptoms. From a functional standpoint, 50-75% of patients with rectal prolapse exhibit faecal incontinence (Madoff & Mellgren, 1999)(Madiba TE, Baig MK, 2005). This is thought to be either due to the traumatic stretch injury to the sphincter complex (Siproudhis et al., 1998)(Aitola, Hiltunen & Matikainen, 1999) (supported by endosonography findings) (Woods et al., 2003)(Dvorkin et al., 2004a), or continuous stimulation of the rectoanal inhibitory reflex leading to chronic low internal anal sphincter pressures (supported by manometry findings) (Farouk et al., 1994)(Hiltunen et al., 1986). Many will confuse a dirty mucous discharge from the prolapsed mucosa as incontinence. Larger case series have found chronic constipation (infrequent stools or severe straining due to evacuation difficulty) to be present in over 30-72% of patients (Marchal et al., 2005)(Lechaux, Lechaux & Perez, 1995)(Kairaluoma & Kellokumpu, 2005).

4.2 Patient workup

Careful history and physical examination will elucidate the diagnosis of rectal prolapse in most cases. Associated pelvic floor disorders and urogenital symptoms (urinary incontinence, vaginal vault prolapse) will require multidisciplinary evaluation and intervention, with the involvement of gynaecological and urological specialties. Perineal and digital rectal examination will often reveal a

The incidence of recurrence after Delorme's procedure for full thickness rectal prolapse - a retrospective private-public cohort study.

patulous anus with soiling and poor or absent anal sphincter tone. Examination of the perineum in the sitting or squatting position can be most helpful to visualize the prolapsed segment of rectum. If not detectable on physical examination, however, confirmation can be obtained by asking the patient to strain or bear down while sitting on the toilet in order to reproduce the prolapse. Rectal prolapse can be differentiated from prolapsing internal haemorrhoids by the concentric pattern of the mucosal folds (projecting radially in prolapsed internal haemorrhoids). Particular attention should be given to enquiring about the presence of constipation or faecal incontinence, along with detailed grading if either is present – this information is vital when considering the different surgical options suitable for the patient as well as counseling them regarding their postoperative improvement in bowel function.

Proctoscopy may reveal a solitary rectal ulcer on the anterior surface of the rectum in up to 10-15% of patients. In less obvious presentations, defaecography may be required to demonstrate the prolapse and may also reveal associated defects such as cystocoele, vaginal vault prolapse and enterocoele. Colonoscopy should precede an operation in all cases as a significant finding may change the operative approach, bearing in mind that this age group has the highest incidence of colorectal neoplasia. A neoplasm forming the lead point for a rectal intussusception has been described. Anal manometry and pudendal nerve terminal motor latency studies, the latter of which is not widely available, may be used preoperatively to further evaluate anal physiology, and may be helpful in providing prognostic information and allowing accurate selection of the most appropriate technique for repair (Madbouly et al., 2003). In cases of longstanding severe constipation, a transit study will evaluate colonic inertia, which might be important given the propensity for postoperative constipation with the old style wide rectal mobilization for posterior mesh placement.

4.3 Defaecography

First described by Wallden more than 50 years ago (Walldén, 1953), defaecography is a cost-effective diagnostic tool in the evaluation of evacuation disorders and can be performed in any hospital with fluoroscopic screen facilities with a short radiological learning curve. By being able to identify the associated morphological and functional abnormalities of the rectum and anal canal in real time, it provides diagnostic information that is unlikely to be identified by static imaging techniques. More recently, MR defaecography has gained increasing interest due to its high-contrast

The incidence of recurrence after Delorme's procedure for full thickness rectal prolapse - a retrospective private-public cohort study.

resolution and lack of ionizing radiation exposure to the patient, but it has important limitations. The patient has to lie still and flat in the scanner, creating a wholly unrealistic scenario for evaluating the pelvic floor.

The patient is fasted from the evening before the investigation and the rectum cleansed by means of an enema. An oral contrast solution is given to opacify the pelvic loops of small bowel. In the left lateral position, about 300ml of thick barium paste is injected into the rectum with complete filling being indicated by the patient experiencing the urge to defaecate. In female patients, the vagina is opacified with barium paste or an impregnated tampon. At this point, the fluoroscopic table is tilted vertically and the patient is asked to sit on a special commode with screening from the right lateral position. Complete evacuation, without interruption, is filmed with short radiosopic sequences and radiographs in order to capture all salient phases of defaecation step by step: (i) during rest with contrast-filled rectum; (ii) during maximum contraction of anal sphincters and pelvic floor muscles; (iii) during straining without evacuation; (iv) during evacuation; and (v) during rest when evacuation is completed. Measured parameters include: the anorectal angle (ARA), an indirect indicator of puborectal muscle activity (average value at rest = 95-96 degrees, becoming more acute during straining and more obtuse during relaxation; and craniocaudal movement of the anorectal junction (ARJ) during straining, representing elevation and descent of the pelvic floor (normally less than 3.5cm relative to the resting position) (Faccioli et al., 2010).

A relaxed and cooperative patient is paramount to the success of this investigation and an empathetic explanation of the procedure is therefore crucial to reduce anxiety and embarrassment in this regard.

4.4 Ultrasound

The advantages of ultrasonography include: absence of ionizing radiation, relative ease of use, minimal discomfort, cost effectiveness, relatively short time required, and wide availability. Unfortunately, skillful pelvic floor ultrasonography is not widespread and there remains a great deal of operator dependence. Multicompartment ultrasound scanning of the pelvic floor (using EAUS, TPUS, TVUS) provides an accurate anatomical assessment of patients with faecal incontinence and define the presence and grade of pelvic organ prolapse (Santoro et al., 2011).

The incidence of recurrence after Delorme's procedure for full thickness rectal prolapse - a retrospective private-public cohort study.

Endoanal ultrasound (EAUS)

The application of endoanal ultrasound in the diagnosis and workup of rectal prolapse has become more established in the last 20 years – due to improvements in technology of ultrasound transducers with the advent of 10MHz rotating probes with 360 degrees of scanning. With EAUS, the balloon system used for rectal scanning is replaced with a hard cone. There is no need for sedation or bowel preparation. The procedure can be performed in the left lateral decubitus or supine lithotomy position, is well tolerated, easily available and cheap (compared to endoanal MR imaging). In addition to its already established role patients with anorectal neoplasms and fistulas, EAUS is now increasingly used in the workup of faecal incontinence and defaecation disorders (Saranovic et al., 2007). The adoption of EAUS has revealed that anal sphincter tears (esp. external sphincter), sphincter laceration and sphincter division are far more common than was originally assumed (Law, Kamm & Bartram, 1991). It's accuracy for diagnosis of sphincter disruption approaches 95%, and has been validated both histologically and intraoperatively (M.H. & A.G., 2003)(A.A. et al., 1996)(Deen et al., 1993). Rectal prolapse with faecal incontinence is associated with deformed anal morphology, typically affecting the anterior and posterior aspects, with relative sparing of the lateral aspects (Dvorkin et al., 2005). In a study of anal sphincter morphology using EAUS in patients with rectal prolapse, internal anal sphincter and submucosal area and thickness were studied in each scan. Eighteen patients with clinical or radiologically overt rectal prolapse were compared to a control group of 23 asymptomatic healthy volunteers. Gross elliptical distortion of the anus was reported in the rectal prolapse group, with an increase in the submucosal thickness and area (most pronounced in the upper anal canal) (Dvorkin et al., 2004b). Poen et al also described submucosal and internal anal sphincter thickening in 12 patients with rectal prolapse (Poen et al., 1996).

Transperineal ultrasound (TPUS)

This is performed with the patient in the dorsal lithotomy position with hips flexed and abducted. A convex transducer is positioned on the perineum between the mons pubis and the anal margin. Imaging is performed with the patient at rest, during maximal valsalva maneuver, and pelvic floor muscle contraction. All 3 compartments and all anatomical structures (bladder, urethra, vaginal walls, anal canal, rectum) can be visualized and any prolapse demonstrated (Santoro et al., 2011). Dynamic TPUS has been shown to demonstrate rectocele, enterocele, and rectal intussusception with images comparable to defaecography (Dietz & Steensma, 2005)(Beer-Gabel et al., 2002).

The incidence of recurrence after Delorme's procedure for full thickness rectal prolapse - a retrospective private-public cohort study.

Transvaginal ultrasound (TVUS)

Performed with the patient in the same position as TPUS, TVUS provides sagittal and axial sectional imaging of the anterior and posterior compartments. Imaging is once again performed with the patient at rest, during maximal valsalva maneuver, and during pelvic floor muscle contraction. This may provide complimentary information when combined with other compartmental scans.

4.5 Classification of internal & external rectal prolapse

Physical examination tends to underestimate prolapse and may be able to diagnose only 30-40% of rectal prolapse (Lieberman, Hughes & Dippolito, 2000). For this reason, defaecating proctography has become increasingly helpful in establishing a precise preoperative diagnosis and selecting a rational treatment program by assigning the patient to a treatment-defined group and providing objective evidence for the corrective surgery (Pomerri & Muzio, 2008). One of the difficulties in evaluating the natural history and progression of rectal prolapse is the lack of a widely accepted grading system (Wijffels et al., 2010).

Full-thickness rectal prolapse, therefore, can be regarded as a continuum comprising increasing degrees of prolapse from occult internal to complete external and this can be graded as follows:

According to Pescatori's endoscopic grading of rectal internal mucosal prolapse (Pescatori & Quondamcarlo, 1999)

- 1st degree: rectal mucosa prolapsing into the anal canal below the anorectal ring
- 2nd degree: rectal mucosa descending at the level of the dentate line
- 3rd degree: rectal mucosa reaching the anal verge
- 4th degree: rectal mucosa extending beyond the anal verge

According to Fleshman's defecographic grading of anorectal intussusception and prolapse (Fleshman, Kodner & Fry, 1989)

- Grade 1: nonrelaxation of the sphincter mechanism
- Grade 2: mild intussusception or mobility from the sacrum
- Grade 3: moderate intussusception

The incidence of recurrence after Delorme's procedure for full thickness rectal prolapse - a retrospective private-public cohort study.

- Grade 4: severe intussusception
- Grade 5: rectal prolapse

The Oxford rectal prolapse grade (ORPG) is a radiological grading system based on the lowest point reached by the intussusceptum in relation to the rectum on a defecating proctogram. It describes rectal prolapse as a gradually evolving process that passes through radiologically identifiable stages, high and low recto-rectal intussusception (grades 1 & 2), high and low recto-anal intussusception (grades 3 & 4), and finally external rectal prolapse (Wijffels et al., 2010).

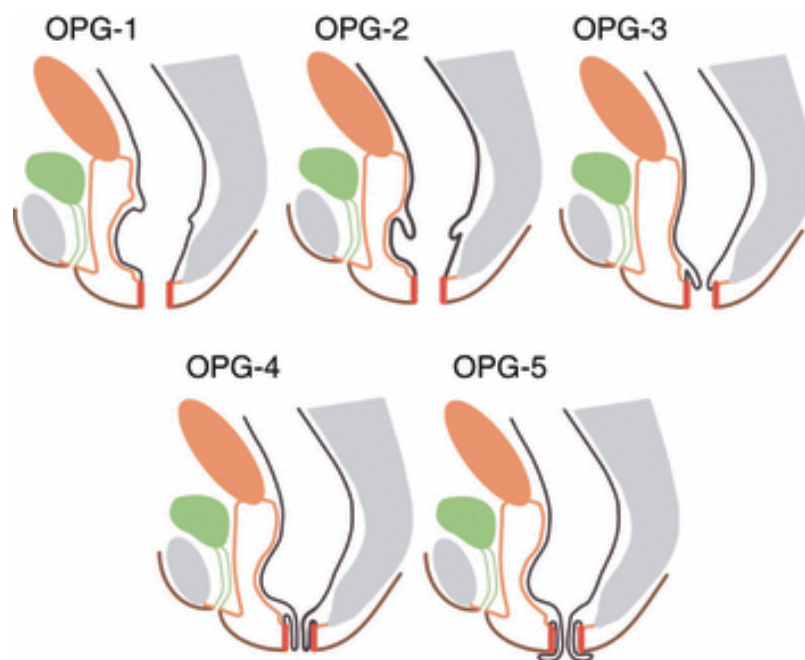


Table 1. Oxford rectal prolapse grade, a radiological grading system.

	Grade of rectal prolapse	Radiological characteristics of rectal prolapse
Internal (RI)		
Recto-rectal Intussusception (RRI)	i (high/rectal)	Descends no lower than proximal limit of the rectocele
	ii (low/rectal)	Descends into the level of the rectocele, but not onto sphincter/anal canal
Recto-anal Intussusception (RAI)	iii (high/anal)	Descends onto sphincter/anal canal
	iv (low/anal)	Descends into sphincter/anal canal
External (ERP)		
External rectal prolapse (ERP)	v (overt rectal prolapse)	Protrudes from anus

Source: Oxford Rectal Prolapse Grade (2010)

https://www.researchgate.net/profile/Chris_Harmston/publication/51078488/figure/fig1/AS:277497020207106@1443171853306/Fig-1-

[The-Oxford-Prolapse-Grade-for-proctographic-grading-of-internal-and-external.png](#)

5. Management of rectal prolapse

Curative management of complete/full-thickness rectal prolapse is exclusively surgical. More than 100 surgical techniques have been described during last century with no accepted standard procedure - testament to the inability of any one technique to provide an adequate solution to rectal prolapse. But this is gradually changing as the subspeciality develops, so that only a few are now routinely advocated, and the rest are of historical interest only.

Surgical procedures can be divided into two broad categories – those performed using a perineal approach and those using an abdominal approach. The aim of all these procedures is to correct the prolapse, restore normal bowel function, and avoid recurrence. The decision as to which to adopt is dictated by the age and comorbidities of the patient, extent of prolapse and symptomatology (chronic constipation and/or faecal incontinence). The perineal approach results in less perioperative morbidity and pain, and a reduced length of hospital stay. These advantages may be offset by a higher recurrence rate. Recent data is unclear on this point, however, and a properly executed perineal operation may yield the same good long-term results as abdominal procedures (Senapati et al., 2013). In general, the traditional algorithm has been abdominal rectopexy if young and fit, and perineal surgery if not (Lindsey, 2010).

5.1 Abdominal surgical approach & techniques

The abdominal approach involves mobilization of the rectum out of the true pelvis and fixation of the rectum to the sacrum (rectopexy) using sutures or mesh, with or without resection of colon. Abdominal procedures that are currently common in practice and routinely reported on in the literature over the past ten years are of 3 main types:

5.1.1 Abdominal Rectopexy

The rationale for rectopexy is to keep the rectum attached in the desired elevated position until it becomes fixed by scar tissue. After mobilization of the rectum out of the true pelvis it is fixed to the sacrum by means of sutures or a prosthetic mesh. Suture rectopexy was first described by Cutait in 1959 (Cutait, 1959). A review article by Madiba et al looked at 10 prospective and retrospective studies (all containing more than 10 patients) published between 1983 and 2001, and found no

The incidence of recurrence after Delorme's procedure for full thickness rectal prolapse - a retrospective private-public cohort study.

reported mortality with recurrence rates ranging from 0% to 27% (with the exception of one series with a recurrence rate of 27%, the majority of reports claimed rates ranging from 0% to 3% (Madiba TE, Baig MK, 2005).

Prosthetic or mesh rectopexy, on the other hand, is based on the assumption that the insertion of foreign material will evoke more fibrous tissue formation than ordinary suture rectopexy. A wide variety of materials have been used through the years to achieve this end, including: fascia lata, non-absorbable synthetic meshes (nylon, polypropylene, Marlex, polyvinyl alcohol, polytef), and absorbable meshes (polyglactin, polyglycolic acid). Two small studies by Winde and colleagues (Winde et al., 1993) in 1993 (comparing polyglycolic acid mesh with polyglactin mesh) and Galili and colleagues (Galili & Rabau, 1997) in 1997 (comparing polyglycolic acid mesh with polypropylene mesh) found no statistically significant difference for residual mucosal prolapse between groups, with only a single recurrent rectal prolapse recorded in the polyglycolic acid mesh group in the Galili study. A Cochrane Collaboration review in 2015 concluded again that there is no difference in primary outcomes between different materials used to fix the mobilized rectum (Tou, Brown & Nelson, 2015)

The two most widely adopted mesh rectopexies described were: anterior sling rectopexy (Ripstein procedure) and posterior mesh rectopexy. The Ripstein repair, first described in 1952 (Ripstein, 1952), involves placement of the mesh around the anterior aspect of the mobilized rectum with attachment of the mesh to the presacral fascia below the sacral promontory by means of sutures. In a review article of 8 retrospective and prospective studies published between 1982 and 2000, mortality rates for the Ripstein procedure ranged between 0% and 2.8%, and recurrence rates between 0% and 13% (Madiba TE, Baig MK, 2005). The Wells procedure evolved from Ripstein's original repair by affixing the mesh to the posterior aspect of the mesorectum and then to the presacral fascia, thereby reducing the possibility of rectal obstruction seen as a complication of Ripstein's anterior mesh placement (Launer et al., 1982)(Madoff & Mellgren, 1999). Both these procedures have largely disappeared from practice because of long term poor outcomes of constipation, mesh obstruction and recurrence.

5.1.2 Laparoscopic rectopexy

Similarly to minimally-invasive approaches in other colorectal diseases, laparoscopic rectopexy (using sutures or mesh with or without resection) has been found to have essentially equivalent results to open rectopexy (Heah et al., 2000)(Ashari et al., 2005)(Kairaluoma, Viljakka &

The incidence of recurrence after Delorme's procedure for full thickness rectal prolapse - a retrospective private-public cohort study.

Kellokumpu, 2003). Despite being associated with a longer operative time and greater cost, laparoscopic surgery has the advantages of less pain, lower wound infection rates, shorter hospital stay, early recovery and earlier return to work as compared with laparotomy. Boccasanta et al compared functional and clinical results of laparoscopic with open rectopexy in 2 similar groups of patients with complete rectal prolapse and showed that the shorter postoperative hospital stay determined an overall reduction in the total cost of laparoscopic rectopexy, despite the prolonged operative time and higher cost of surgical materials (Boccasanta et al., 1998). Another prospective randomized controlled study by Solomon and colleagues in 2002 concluded that laparoscopic rectopexy had short-term benefits in terms of return to normal diet and mobility, earlier discharge from the hospital, and less morbidity (Solomon et al., 2002). In addition to this, a reduced neuroendocrine and immunological stress response was reported. There was only a single recurrence in the open group between both studies. Since these publications, laparoscopic skills and equipment have improved considerably in the last 15-20 years and a more recent meta-analysis of available data within the published literature comparing laparoscopic rectopexy with open repair found laparoscopic rectopexy to be a safe and effective modality comparable to open repairs. Twelve comparative studies on 688 patients showed a statistically significant difference in length of operation and length of postoperative hospital stay. There was no statistically significant difference in morbidity, incontinence, constipation, or mortality between the two groups (Sajid, Siddiqui & Baig, 2010)(Tou, Brown & Nelson, 2015). In more recent years, ventral mesh rectopexy (most often performed laparoscopically) has gained popularity as a novel nerve-sparing approach to the surgical treatment of rectal prolapse, due to its perceived functional advantages by avoiding complete mobilization and subsequent autonomic denervation of the rectum. In laparoscopic ventral mesh rectopexy (LVMR), the anterior wall of rectum is mobilized off the vagina as low as the puborectalis, and mesh is secured anteriorly to the rectum with sutures. The proximal end of the mesh is fixed to the sacrum (D'Hoore & Penninckx, 2006). Although initial descriptions by Loygue and colleagues included both anterior and posterior mobilization, an alternate approach is to perform rectopexy with posterior mobilization along the sacrum only to fix the mesh posteriorly (Melton & Kwaan, 2013). This is believed to address the common problem of postoperative constipation seen with most mesh suspension techniques. Unfortunately, there are limitations in the published literature regarding LVMR, and to date, there is not a single prospective study directly comparing posterior to ventral mesh rectopexy. In a systematic review to assess the effectiveness of LVMR for rectal prolapse (and rectal intussusception) in adults, Samaranayake et al reported on 12 non-randomized case series studies with a total of 728 patients. Seven studies used the Orr-Loygue procedure, with posterior rectal mobilization to the pelvic floor, and five studies used ventral

The incidence of recurrence after Delorme's procedure for full thickness rectal prolapse - a retrospective private-public cohort study.

rectopexy without posterior mobilization. They concluded that ventral rectopexy has a low recurrence rate (weighted mean = 3.4%) and improved faecal incontinence postoperatively (overall weighted mean percentage decrease in faecal incontinence rate was 45%). They also found a greater reduction in postoperative constipation if ventral rectopexy is used without posterior rectal mobilization, with a weighted mean percentage decrease in constipation rate of 2.4%

(Samaranayake et al., 2010). A prospective study by D'Hoore and colleagues looked at the long-term outcome of laparoscopic ventral rectopexy performed at a single center in Belgium on 42 patients after a median follow-up of 61 months. No major postoperative complications were reported, and late recurrence occurred in 2 patients (5%). Once again, symptoms of obstructed defaecation resolved in 16 of 19 patients and they concluded that this was most likely explained by the ventral position of the mesh placement. There was a significant improvement in continence in 28 of 31 patients experiencing incontinence preoperatively (D'Hoore, Cadoni & Penninckx, 2004).

Traditional rectopexy and LVMR primarily differ in the extent of rectal mobilization and management of the lateral sacral ligaments. Ripstein advocated preservation of these lateral rectal attachments (originally describing division of only the upper portion while future iterations have left them wholly intact). Wells, on the other hand, described transection of the lateral ligaments. Preservation of the lateral ligaments with posterior rectopexy is thought to benefit patients by sparing the autonomic innervation to the rectum and thereby preventing postoperative constipation. Mollen and colleagues confirmed this theory by reporting lower rates of constipation (43% vs 67%) with preservation of the lateral ligaments (reported as colonic transit times rather than number for those people considered to be constipated) (Mollen, Kuijpers & van Hoek, 2000), while Speakman et al showed a 50% greater incidence of postoperative constipation with divided lateral stalks.

(Speakman et al., 1991). This may be at the expense of a higher recurrence rate, presumably due to a tendency towards incomplete mobilisation of the rectum – rectal prolapse recurred in 19% of patients following preservation of the lateral ligaments (Mollen, Kuijpers & van Hoek, 2000) and there were 2 cases (17%) of mucosal prolapse following rectopexy with preserved stalks in the Speakman study (Speakman et al., 1991). Complications of prosthetic mesh repairs include large bowel obstruction, erosion of the mesh through the bowel, ureteric injury or fibrosis, sacral vein haemorrhage, small bowel obstruction, rectovaginal fistula and faecal impaction.

Gouvas et al carried out a systematic review of 1460 patients undergoing LVMR for both rectal prolapse (675 patients) and obstructed defaecation syndrome. They reported a recurrence rate of 0-15% (mean 2.4%), a conversion rate of 0-14.3% (mean 1.9%), and a complication rate of 8.9%.

The incidence of recurrence after Delorme's procedure for full thickness rectal prolapse - a retrospective private-public cohort study.

There were no postoperative deaths. The mean intraoperative time was 56-221 min (significantly longer with robotic surgery), and the intraoperative morbidity was 8.57% (3 cases of intra-abdominal bleeding and 1 perforation of the posterior vaginal wall). Preoperative constipation improved from 21.4-93.3% to 6.7-22% postoperatively, and preoperative incontinence improved from 23.3-92.9% to 0-28.6% postoperatively. Both were statistically significant. From their study they concluded that LVMR is a safe procedure with low morbidity and mortality. Complications associated with the prosthesis are rare, despite the theoretical increased risk of synthetic mesh erosion. There is a significant reduction in constipation and incontinence and the recurrence rate is low. To establish LVMR as the gold standard for rectal prolapse, however, will require higher quality studies with longer follow-up and comparison to standard rectopexy techniques (Gouvas et al., 2015).

5.1.3 Anterior resection

Rectosigmoid resection was first described as an alternative strategy to repair rectal prolapse in 1955 based on the observation that after low anterior resection, a dense area of fibrosis forms between the anastomotic suture line and the sacrum, securing the rectum to the sacrum (Kuijpers, 1992). This procedure was particularly well suited to patients with a long redundant sigmoid colon and a long history of constipation. Several retrospective reviews have shown higher recurrence rates and a lack of functional improvements (Cirocco & Brown, 1993). This, coupled with the morbidity associated with a low pelvic anastomosis, has limited the widespread use of this procedure and its use is confined to studies before 1980.

5.1.4 Resection rectopexy

First described by Frykman and Goldberg in 1966, this technique involves complete mobilization of the sigmoid colon and rectum to the level of the levator muscles with sigmoid resection and suture fixation to the presacral fascia, combining the advantages of mobilization and fixation with sigmoid resection. Classically described with division of the lateral ligaments, a revised version preserves the lateral attachments with unilateral fixation of the rectal mesentery to the sacrum at the level of the sacral promontory. Although originally done to reduce recurrence, sigmoid resection was found to significantly reduce constipation in those patients suffering from this symptom preoperatively (Luukkonen, Mikkonen & Jarvinen, 1992)(Tou, Brown & Nelson, 2015). Recurrence rates are low, ranging from 0-5% (Madiba TE, Baig MK, 2005) and complication rates range from 0-20% related either to obstruction or anastomotic leakage. Two small prospective randomized controlled trials have compared the outcomes of rectopexy with and without bowel resection. In 1992, Luukkonen et

The incidence of recurrence after Delorme's procedure for full thickness rectal prolapse - a retrospective private-public cohort study.

al combined resection with suture rectopexy and compared with mesh rectopexy alone. In the other study in the same year, McKee et al performed suture rectopexy in both groups of patients, with resection in one group. No recurrent rectal prolapse was reported by either trial. There was a statistically significant difference between groups with regard to residual faecal incontinence, with 33% found to have postoperative incontinence in the resection group versus 21% in the rectopexy group. But the biggest advantage of resection was the significant reduction in postoperative constipation in the resection groups (8% vs 50%). In a multicenter review of 643 patients from 15 centres between 1979 and 2001, Raftopoulos et al reported 38 (5.9%) recurrences at a median follow-up of 43 months. The pooled one-, five-, and 10-year recurrence rates were 1.06, 6.61, and 28.9% respectively. Although the vast majority of patients in the study underwent mobilization and pexy only without resection (n=467), they concluded that age, gender, surgical technique, means of access, and rectopexy method had no impact on recurrence rates. Unfortunately, despite the large number of patients, the study was likely underpowered due to the heterogeneity of patients and procedures and it is difficult to make strong conclusions from it.

5.2 Perineal surgical approach & techniques

Perineal surgery avoids the increased morbidity and mortality associated with a laparotomy and abdominal rectopexy/resection, particularly in the elderly and high-risk patient population. Perineal repairs can be divided between Altemeier's procedure (more popular in North America) and Delorme's procedure (more popular in Europe), with both procedures generally reserved for patients with the highest operative risk due to age and comorbidity. Assessment of preoperative continence, other defecatory dysfunction, as well the size of the prolapse should be considered with the choice of procedure as the two techniques have different merits in this regard. An additional place for these 'less-invasive' techniques is in young men suffering from rectal prolapse, in whom there is an increased risk of autonomic pelvic nerve injury with consequent impotence and sexual dysfunction. Renewed interest in these techniques has seen recent studies showing a reduced recurrence rate to what was previously accepted in the published literature. However, due to the significant degree of patient selection bias when comparing abdominal to perineal approaches, coupled with the inherent difficulties of follow-up in an elderly population postoperatively, it has remained difficult to draw any meaningful conclusions from the literature thus far.

The incidence of recurrence after Delorme's procedure for full thickness rectal prolapse - a retrospective private-public cohort study.

In the largest series of rectal prolapse repair reported, Fleming et al compared 30-day outcomes following perineal and abdominal approaches to identify patient and operative factors associated with perioperative complications. As most of the data on short-term morbidity following rectal prolapse repair arise from older case series, this study aimed to address the paucity of recent data examining outcome, including complications. Abdominal cases were further subdivided by procedure, comparing resection with rectopexy alone. A total of 1275 patients from the United States multi-institutional NSQIP database were compared, with 706 (55%) perineal procedures. Mortality rates were 0.4% in the abdominal group and 1.4% in the perineal group. A perineal approach was associated with a reduced risk of both major and minor complications compared with an abdominal approach. An abdominal resection rectopexy was associated with a doubling of the major complication rate compared with abdominal rectopexy alone. There was no significant difference in major complications between the perineal and abdominal rectopexy groups (Fleming et al., 2012). Fleming and colleagues also demonstrated a marked difference in the profile of patients undergoing an abdominal and perineal repair – patients in the perineal group were older, had a higher incidence of comorbid conditions, an increased rate of dependent functional status and higher ASA class. This is in accordance with most other reports from previous retrospective studies. An additional limitation of the NSQIP dataset is the lack of information regarding the level of experience or subspecialty interest of the surgeon involved. Despite this, this study was once again able to demonstrate the clinical trade-off in the management of rectal prolapse with these two approaches - that the long-term reduction in recurrence offered by the abdominal approach comes at the cost of a significantly increased risk of both major and minor complications compared to the perineal approach.

5.2.1 Altemeier's procedure

Perineal sigmoidectomy was first described by Mikulicz in 1899 and remained the favoured treatment for prolapse in Europe for many years. Altemeier from the University of Cincinnati promoted this procedure in the United States where it has remained the preferred perineal technique. It has been argued that a perineal proctosigmoidectomy may be more appropriate in the setting of large prolapse or significant constipation (Ramanujam & Venkatesh, 1988; Zbar et al., 2002; Glasgow et al., 2006; Melton & Kwaan, 2013). Glasgow et al reported a significant decrease in incontinence (77.8% preop vs 35.6% postop) and constipation (33.3% preop vs 6.7% postop) in a retrospective study of 45 patients who underwent perineal proctectomy (Glasgow et al., 2006). More specifically, the most improved functional outcome in terms of faecal incontinence was seen

The incidence of recurrence after Delorme's procedure for full thickness rectal prolapse - a retrospective private-public cohort study.

in patients with maximal squeeze pressure > 60mmHg preoperatively. Recurrence rates have been reported to be as high as 16% (Madiba TE, Baig MK, 2005), although recent series have demonstrated these to be significantly lower in the region of 5-10% (Lee et al., 2011)(Glasgow et al., 2006)(Agachan et al., 1997). Complications can include bleeding from the suture/staple line, pelvic abscess, anastomotic stricture and, rarely, anastomotic leakage. In a very small randomized trial by Deen et al published in *The British Journal of Surgery* in 1994, abdominal resection rectopexy and pelvic floor repair (n=10) was compared with perineal rectosigmoidectomy and pelvic floor repair (n=10) in elderly female patients with full-thickness rectal prolapse and faecal incontinence. They reported a single recurrence following perineal rectosigmoidectomy, and none following resection rectopexy. In addition, they showed improved functional and physiological results after abdominal resection rectopexy when compared to perineal rectosigmoidectomy – continence to liquid and solid stool was achieved in 9 patients (with faecal soiling reported in only 2 patients) following resection rectopexy, and in 8 patients (with faecal soiling in 6 patients) following recosigmoidectomy. Mean resting pressure and compliance were also found to be greater postoperatively in the resection rectopexy group (Deen et al., 1994). Elsewhere the procedure was found to worsen preoperative incontinence by 20%, attributed to resection of the rectal reservoir, and led to additions to the standard procedure in the form of a pouch or levatorplasty to address this shortcoming (Yoshioka, Ogunbiyi & Keighley, 1998)(Ramanujam & Venkatesh, 1988). Agachan and colleagues at the Cleveland Clinic, Florida concluded that perineal rectosigmoidectomy with levatorplasty resulted in significantly better short-term functional outcomes than either perineal rectosigmoidectomy alone or Delorme's operation, achieving not only a more significant improvement in continence but also a lower short-term recurrence rate (5% vs 13% vs 38%) (Agachan et al., 1997). Kimmins et al followed a series of 68 patients between 1993 and 1999 over a median of 20.8 months. Seventy percent of the surgeries were performed under regional or local anaesthetic and 80% discharged within 24 hours. They reported a complication rate of 10% with no mortality. All patients had complete objective resolution, with a subjective improvement in 80% (Kimmins et al., 2001). Zbar et al reported on 15 years experience with the Altemeir procedure performed (with the addition of a levatorplasty) on 80 patients in a single unit with a median follow up of 22 months. There were only 3 recurrences in this series, with a 1.9% complication rate (a single perianastomotic abscess) (Zbar et al., 2002). In a more recent series of 103 patients collected between 2000 and 2009 with a mean follow up of 43 months, Cirocco et al reported no recurrences after the Altemeir procedure. 96% of these operations were performed under general anaesthetic, and 10% under spinal anaesthesia. The mean postoperative hospital stay was 4.2 days. Preoperative

The incidence of recurrence after Delorme's procedure for full thickness rectal prolapse - a retrospective private-public cohort study.

constipation improved in 94% and incontinence in 85% (Cirocco, 2010). In the largest Altemeir series to date, Kim et al reported a recurrence rate of 16% amongst 183 patients (Kim et al., 1999).

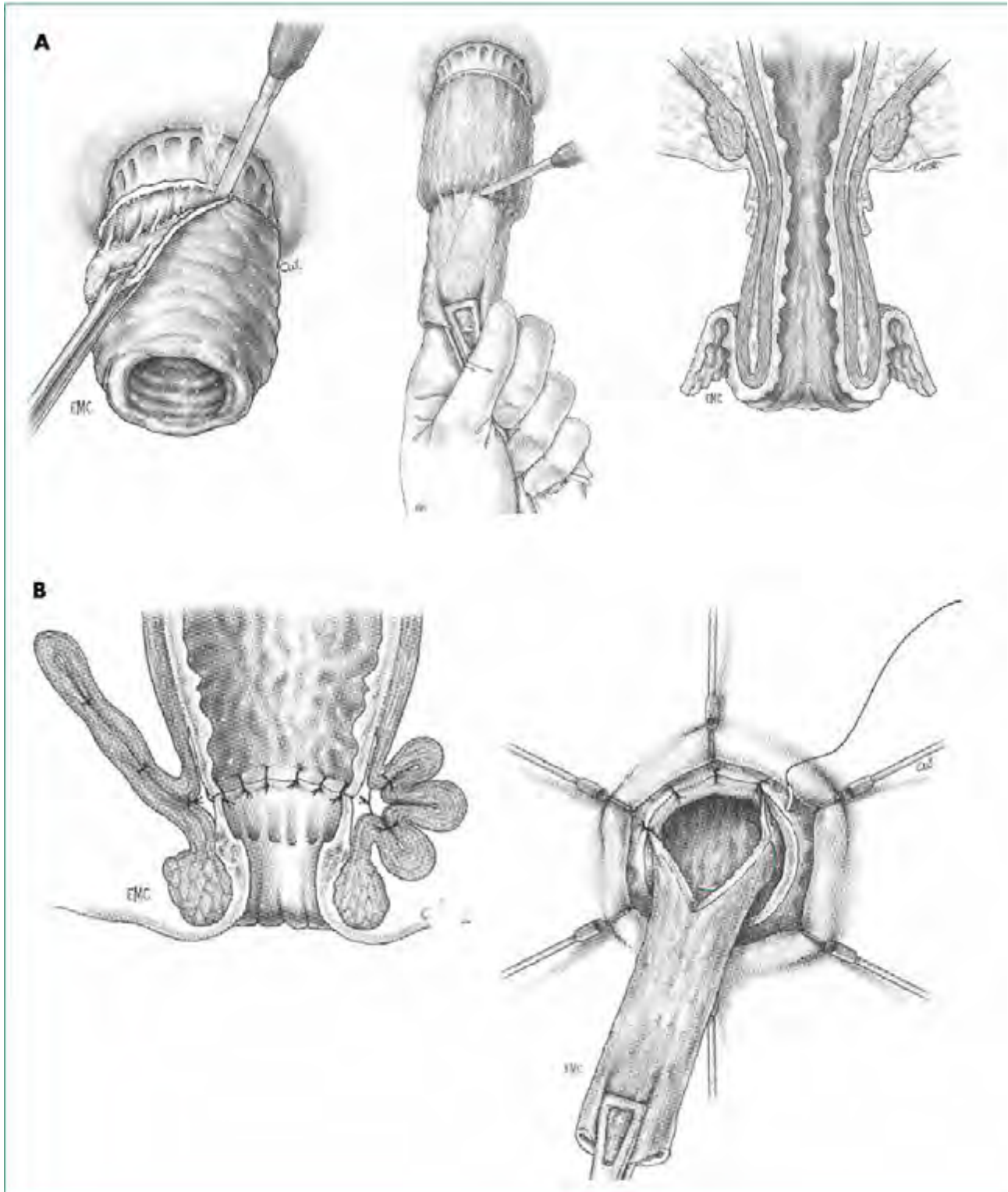
5.2.2 Delorme's procedure

Delorme's procedure is a perineal technique for the repair of full-thickness rectal prolapse, first described by the French military surgeon Edmond Delorme in 1900. Initially regarded as a technically simple and safe operation, the technique fell into disfavor after anecdotal reports of high recurrence rates and high postoperative morbidity and mortality rates. Due to improved techniques, it's popularity has re-emerged - ideal for those not fit enough to withstand an abdominal operation (Watts & Thompson, 2000). It can be performed under local/regional (spinal/epidural) anaesthesia, and has the additional benefits of having a shorter intervention time, no risk of an intra-abdominal anastomosis and postoperative peritoneal adhesions, a lower risk of injury to pelvic nerves (erection problems) or hypo gastric nerves (ejaculation problems), reduced postoperative pain, and a shorter hospital stay. A mucosal sleeve resection (involving circumferential removal of redundant anal canal and distal rectal mucosa) is performed transanally with plication of the muscularis layer by means of circumferential vertical sutures. Delorme's procedure has long been believed to have a higher recurrence rate than abdominal procedures in the range of 10-30% (Madiba TE, Baig MK, 2005)(Rothenhoefer et al., 2012). Similarly to Altemeir's procedure therefore, it has been advocated for those patients considered 'high risk' due to comorbidities or risk of nerve injury. Faecal incontinence is improved after Delorme's procedure (Madiba TE, Baig MK, 2005)(Rothenhoefer et al., 2012). Constipation and difficulty passing stool are not generally seen postoperatively and rarely reported in the literature. Plusa et al studied the physiological changes after Delorme's procedure for full-thickness rectal prolapse, and reported an improvement in rectal sensation, but also found lowered compliance in 19 female patients of mean age 77 years (Plusa et al., 1995). Two additional studies have reported similar manometric findings (Penninckx et al., 1997)(Chow & Ho, 1996). By combining the Delorme's procedure with a sphincteroplasty in 33 patients, Pescatori et al achieved good results in 79% of patients – continence improved in 70% and 44% of patients were cured of their constipation postoperatively (Pescatori et al., 1998). The recurrence rate was 21%. They concluded that the addition of a sphincteroplasty to the basic Delorme's procedure seemed most indicated in the setting of clinical and physiological findings of concomitant severe pelvic floor dysfunction. An alternative modification of Delorme's operation was shown by Lechaux et al to have a slightly reduced recurrence rate when compared to the original procedure (Lechaux, Lechaux & Perez, 1995). A total of 85 patients, ranging in age from

The incidence of recurrence after Delorme's procedure for full thickness rectal prolapse - a retrospective private-public cohort study.

21 to 97 years were operated on using either a standard Delorme's procedure or an innovative extended transrectal repair aimed at performing a total pelvic floor repair. The modified technique was shown to have a statistically significant reduction in recurrence rate (5% of 41 patients) over the original procedure (21% of 44 patients). An equally significant result of the study was the difference in reported recurrence rates between the 44 elderly and poor operative risk patients not suitable for abdominal surgery (22.5%) and the 41 younger patients without concurrent medical conditions electively submitted to the perineal repair group (5%) (Lechaux, Lechaux & Perez, 1995). A more recent study reported a single recurrence in 41 patients (2.43%) undergoing a modified procedure with the addition of a post anal repair and levatorplasty, compared to a recurrence rate of 14.28% in the 41 patients undergoing a classic Delorme's procedure (Youssef et al., 2012). To assess the efficacy in younger adults, Fazeli and colleagues reported on 52 patients who underwent a Delorme's repair for full-thickness rectal prolapse at Imam Khomeine Medical Centre, Iran between 2009 and 2012. Forty one of the patients were aged less than 50 years and they were followed up for at least 30 months. Recurrence rate was 9.75% in the younger group, compared to 18.18% in the older group. Incontinence resolved in 92% of the younger age group patients, and improved in 60% of the older patients (Fazeli et al., 2013). A study by Sielezneff and colleagues looking at selection criteria for Delorme's procedure reported a number of factors associated with potential failure of this technique, including: proximal procidentia with retrosacral separation on defaecography, faecal incontinence, chronic diarrhea, and perineal descent of > 9cm (Sielezneff et al., 1999).

The incidence of recurrence after Delorme's procedure for full thickness rectal prolapse - a retrospective private-public cohort study.



Source: Surgical Treatment of Complete Rectal Prolapse. J-L. Faucheron (2008)
http://www.jle.com/e-docs/00/04/42/3E/texte_alt_jlehp00412_gr4.jpg

6. Summary

The traditional algorithm for the management of full-thickness rectal prolapse has been abdominal surgery if young and fit, perineal surgery if old and frail (Lindsey, 2010). An exception to this rule being the adoption by some of a perineal technique in younger patients to avoid the consequences of autonomic denervation often seen with the traditional posterior rectopexy. Despite the large number of surgical options available, no single operation has consistently achieved optimal results for all patients. Furthermore, the ever-increasing population of elderly females means that this difficult pathology is being increasingly encountered.

A better understanding of prolapse has followed advancements in diagnostic workup (defaecography & endoanal ultrasound) and functional assessment resulting in a more rational approach to both non-operative and operative management of rectal prolapse. Pescatori's original 'iceberg theory' with its principles of multidisciplinary, non-operative management of defecatory dysfunction, along with its abundance of associated occult psychological and functional disturbances, has changed the entire philosophy of surgical management. Furthermore, the recognition of rectal prolapse as part of a spectrum of posterior organ prolapse in the larger picture of pelvic floor dysfunction has led to the development of a multidisciplinary approach to this challenging pathology. Consequently, the restoration of normal anatomy is no longer regarded as the only goal in rectal prolapse surgery – the restoration of normal bowel function is now considered to be of equal importance.

At the turn of the twentieth century, the perineal surgical technique dominated the operative management of rectal prolapse, with Thiersch's anal encirclement operation (1891) preceding Miculicz's perineal sigmoidectomy (1899), and Delorme's mucosal sleeve resection (1900). The first half of this century saw the proliferation of a number of novel abdominal approaches based on Ripstein's original principle of mobilization and rectopexy, then Wells' popular variation, followed by resection rectopexy. The latter, first described by Frykman and Goldberg in 1969, was a post hoc modification to try and solve the persistent problem of constipation that was prevalent in all reported abdominal rectopexy series (Madoff & Mellgren, 1999). The addition of resection to the surgical approach was shown to modify postoperative bowel function, especially with respect to the avoidance of constipation.

The incidence of recurrence after Delorme's procedure for full thickness rectal prolapse - a retrospective private-public cohort study.

In more recent years, laparoscopic techniques for repair of full-thickness rectal prolapse have shown promise due to improvements in safety and reduction in postoperative morbidity as well as a recurrence rate of less than 10% (Madiba TE, Baig MK, 2005). It is claimed that laparoscopic ventral mesh rectopexy combines the efficacy of an abdominal procedure with the safety of a perineal one, without major functional disturbance (Lindsey & Cunningham, 2004). As a result of these improvements in safety and morbidity, coupled with the postoperative functional improvements with ventral nerve-sparing rectopexy, the role of Delorme's operation has been questioned of late due to its higher frequency of recurrence quoted by the literature in the last 20 years (Wijffels et al., 2011)(Young et al., 2015).

7. Conclusion

Although the respective roles of abdominal and perineal approaches to the surgical management of full-thickness rectal prolapse is most often governed by patient factors such as comorbid disease and physiological baseline, the comparative recurrence rates are still based solely on a small number of retrospective studies with a variety of shortcomings. The PROSPER study highlighted this in its recently published results, once again fueling the abdominal vs. perineal debate and strengthening the potential role of perineal techniques in the hands of experienced colorectal surgeons (Senapati et al., 2013). What has become increasingly clear is that additional, larger prospective randomized studies are needed to delineate further the role of perineal, abdominal, and laparoscopic operations in the management of patients with rectal prolapse. The DeloRes trial is currently recruiting patients in an attempt to meet this requirement and eliminate some of the shortcomings which have plagued previous studies (Rothenhoefer et al., 2012).

8. Research Proposal

Objectives

Aims

- To assess long-term clinical outcomes of Delorme's procedure in the management of full-thickness rectal prolapse with absence of recurrence as the primary outcome measure, and constipation and incontinence as secondary outcomes.
- To identify statistically significant predictors of complication, recurrence and constipation/faecal incontinence.
- To compare outcomes in a multi-surgeon public hospital and a single surgeon series in the private sector.

Ultimately, this study will contribute to the greater body of scientific research regarding the place of Delorme's procedure in the management of full-thickness rectal prolapse, and perhaps challenge the prevailing restriction on its use in different patient groups due to its supposed greater recurrence rate. Due to the significant variability in published recurrence rates of previous studies, Delorme's operation has long been reserved for the elderly and comorbid patient population. We are hopeful that this study will, one way or another, address this current perspective. In addition, the results obtained in both the public and private sector will serve as a valuable comparison between colorectal surgeons with different degrees of surgical experience in and preference for Delorme's operation.

Primary Outcome

Absence of recurrence of full-thickness rectal prolapse after Delorme's procedure (examined by telephonic history and interview).

Secondary Outcomes

The incidence of recurrence after Delorme's procedure for full thickness rectal prolapse - a retrospective private-public cohort study.

Complication rates (30-day) - minor, major, surgery site-specific (from clinical records)

Functional results after Delorme's procedure - constipation, faecal incontinence (examined by telephonic interview and grading where appropriate)

Hypothesis

Recurrence of prolapse after Delorme's procedure may be lower than many published series, in the hands of a colorectal surgeon with a special interest in this procedure compared with a public sector experience. This outcome would encourage the use of this procedure as a first choice in all patients.

Research Methods and Analysis

The study will be a retrospective cohort study of patients who underwent a Delorme's procedure for full-thickness rectal prolapse over the last 13 years. There will be two primary study sites: Groote Schuur Hospital (operations performed by various surgeons) and Kingsbury Hospital (operations performed by a single surgeon) - representing the public and private sector respectively. Patient data will be collected from electronic records/database (Kingsbury Hospital) and folders/op notes (GSH) and entered into a pro-forma spreadsheet. Each patient, or surviving carers, will be contacted telephonically in order to assess for recurrence of rectal prolapse as well as improvement in preoperative symptoms and functional results (constipation or faecal incontinence) using a widely accepted scoring system. The results of the study will be made available to the patients participating once completed.

Data Collection

Demographics

Age

Gender

Address

Telephone number

The incidence of recurrence after Delorme's procedure for full thickness rectal prolapse - a retrospective private-public cohort study.

Clinical Notes

Primary presenting complaint (bleeding, incontinence, discharge, prolapse sensation)

Duration of prolapse symptoms

Degree of rectal prolapse (mild, moderate, severe - still to be quantified)

Comorbidities

Fitness for anaesthetic (ASA category)

Smoking

Surgical notes

Type of anaesthetic

Position

Difficulty

Length of postoperative stay

Postoperative complications (30-day)

Follow up

Clinical result (resolution of prolapse)

Functional result (constipation, faecal incontinence)

Complications

Patient satisfaction

Telephonic Interview

Patient living or deceased (if deceased, history from closest relative/caregiver)

Satisfaction with long-term surgical outcome

Problems with constipation or faecal incontinence postop

Recurrence of rectal prolapse (based on subjective patient symptoms or clinical examination)

Length of time after primary operation of recurrence

Repeat operation

9. References

- A.A., A., J.-B., L., D.A., M. & D.A., N. 1996. Fecal incontinence: Transvaginal US evaluation of anatomic causes. *Radiology*. 199(2):529–532. DOI: 10.1148/radiology.199.2.8668806.
- Agachan, F., Pfeifer, J., Joo, J.S., Nogueras, J.J., Weiss, E.G. & Wexner, S.D. 1997. Results of perineal procedures for the treatment of rectal prolapse. *The American surgeon*. 63:9–12.
- Aitola, P.T., Hiltunen, K.M. & Matikainen, M.J. 1999. Functional results of operative treatment of rectal prolapse over an 11-year period: emphasis on transabdominal approach. *Diseases of the colon and rectum*. 42:655–660.
- Ashari, L.H.S., Lumley, J.W., Stevenson, A.R.L. & Stitz, R.W. 2005. Laparoscopically-assisted resection rectopexy for rectal prolapse: ten years' experience. *Diseases of the colon and rectum*. 48:982–987. DOI: 10.1007/s10350-004-0886-3.
- Azpiroz, F., Fernandez-Fraga, X., Merletti, R. & Enck, P. 2005. The puborectalis muscle. *Neurogastroenterology and motility : the official journal of the European Gastrointestinal Motility Society*. 17 Suppl 1:68–72. DOI: 10.1111/j.1365-2982.2005.00663.x.
- Beer-Gabel, M., Teshler, M., Barzilai, N., Lurie, Y., Malnick, S., Bass, D. & Zbar, A. 2002. Dynamic transperineal ultrasound in the diagnosis of pelvic floor disorders: Pilot study. *Diseases of the Colon and Rectum*. 45(2):239–248. DOI: 10.1007/s10350-004-6155-7.
- Boccasanta, P., Rosati, R., Venturi, M., Montorsi, M., Cioffi, U., De Simone, M., Strinna, M. & Peracchia, A. 1998. Comparison of laparoscopic rectopexy with open technique in the treatment of complete rectal prolapse: clinical and functional results. *Surgical laparoscopy & endoscopy*. 8(6):460–5. Available: <http://www.ncbi.nlm.nih.gov/pubmed/9864116> [2013, October 26].
- Boccasanta, P., Venturi, M., Stuto, A., Bottini, C., Caviglia, A., Carriero, A., Mascagni, D., Mauri, R., et al. 2004. *Stapled transanal rectal resection for outlet obstruction: a prospective, multicenter trial*. DOI: 10.1007/s10350-004-0582-3.
- Brodén, B. & Snellman, B. 1968. Procidentia of the rectum studied with cineradiography. *Diseases of the Colon & Rectum*. 11(5):330–347. DOI: 10.1007/BF02616986.
- Bump, R.C., Mattiasson, A., Bø, K., Brubaker, L.P., DeLancey, J.O., Klarskov, P., Shull, B.L. & Smith, A.R. 1996. The standardization of terminology of female pelvic organ prolapse and pelvic floor dysfunction. *American journal of obstetrics and gynecology*. 175:10–17. DOI: 10.1016/S0002-9378(96)70243-0.

The incidence of recurrence after Delorme's procedure for full thickness rectal prolapse - a retrospective private-public cohort study.

Chiarioni, G., Salandini, L. & Whitehead, W.E. 2005. Biofeedback benefits only patients with outlet dysfunction, not patients with isolated slow transit constipation. *Gastroenterology*. 129(1):86–97. Available: <http://www.ncbi.nlm.nih.gov/pubmed/16012938> [2013, November 22].

Chiarioni, G., Whitehead, W.E., Pezza, V., Morelli, A. & Bassotti, G. 2006. Biofeedback is superior to laxatives for normal transit constipation due to pelvic floor dyssynergia. *Gastroenterology*. 130(3):657–64. DOI: 10.1053/j.gastro.2005.11.014.

Choi, J.S., Hwang, Y.H., Salum, M.R., Weiss, E.G., Pikarsky, A.J., Nogueras, J.J. & Wexner, S.D. 2001. Outcome and management of patients with large rectoanal intussusception. *The American journal of gastroenterology*. 96:740–744.

Chow, P.K.H. & Ho, Y.H. 1996. Abdominal resection rectopexy versus Delorme's procedure for rectal prolapse: comparison of clinical and physiological outcomes. *International Journal of Colorectal Disease*. 11(4):201–202. DOI: 10.1007/s003840050046.

Ciocco, W.C. 2010. The Altemeier procedure for rectal prolapse: An operation for all ages. *Diseases of the Colon and Rectum*. 53(12):1618–1623. DOI: 10.1007/DCR.0b013e3181f22cef.

Ciocco, W.C. & Brown, A.C. 1993. Anterior resection for the treatment of rectal prolapse: a 20-year experience. *The American surgeon*. 59:265–269.

Collinson, R., Wijffels, N., Cunningham, C. & Lindsey, I. 2010. Laparoscopic ventral rectopexy for internal rectal prolapse: short-term functional results. *Colorectal disease : the official journal of the Association of Coloproctology of Great Britain and Ireland*. 12:97–104. DOI: 10.1111/j.1463-1318.2009.02049.x.

Corman, M.L., Carriero, A., Hager, T., Herold, A., Jayne, D.G., Lehur, P.-A., Lomanto, D., Longo, A., et al. 2006. Consensus conference on the stapled transanal rectal resection (STARR) for disordered defaecation. In *Colorectal disease : the official journal of the Association of Coloproctology of Great Britain and Ireland*. V. 8. 98–101. DOI: 10.1111/j.1463-1318.2005.00941.x.

Cutait, D. 1959. Sacro-promontory fixation of the rectum for complete rectal prolapse. *Proceedings of the Royal Society of Medicine*. (52):105.

D'Hoore, A. & Penninckx, F. 2006. Laparoscopic ventral recto(colpo)pey for rectal prolapse: Surgical technique and outcome for 109 patients. *Surgical Endoscopy and Other Interventional Techniques*. 20(12):1919–1923. DOI: 10.1007/s00464-005-0485-y.

D'Hoore, a, Cadoni, R. & Penninckx, F. 2004. Long-term outcome of laparoscopic ventral

The incidence of recurrence after Delorme's procedure for full thickness rectal prolapse - a retrospective private-public cohort study.

rectopexy for total rectal prolapse. *The British journal of surgery*. 91(11):1500–5. DOI: 10.1002/bjs.4779.

Deen, K.I., Kumar, D., Williams, J.G., Olliff, J. & Keighley, M.R. 1993. Anal sphincter defects. Correlation between endoanal ultrasound and surgery. *Annals of surgery*. 218(2):201–5. DOI: 10.1007/s00192-008-0667-y.

Deen, K.I., Grant, E., Billingham, C. & Keighley, M.R.B. 1994. Abdominal resection rectopexy with pelvic floor repair versus perineal rectosigmoidectomy and pelvic floor repair for full-thickness rectal prolapse. *British Journal of Surgery*. 81(2):302–304. DOI: 10.1002/bjs.1800810253.

Devadhar, D.S.C. 1965. A new concept of mechanism and treatment of rectal procidentia. *Diseases of the Colon & Rectum*. 8(1):75–77. DOI: 10.1007/BF02617054.

Dietz, H.P. & Steensma, A.B. 2005. Posterior compartment prolapse on two-dimensional and three-dimensional pelvic floor ultrasound: The distinction between true rectocele, perineal hypermobility and enterocele. *Ultrasound in Obstetrics and Gynecology*. 26(1):73–77. DOI: 10.1002/uog.1930.

Dvorkin, L.S., Chan, C.L.H., Knowles, C.H., Williams, N.S., Lunniss, P.J. & Scott, S.M. 2004a. Anal sphincter morphology in patients with full-thickness rectal prolapse. *Diseases of the colon and rectum*. 47(2):198–203. Available: <http://www.ncbi.nlm.nih.gov/pubmed/15043290> [2014, January 11].

Dvorkin, L.S., Chan, C.L.H., Knowles, C.H., Williams, N.S., Lunniss, P.J. & Scott, M.S. 2004b. Anal Sphincter Morphology in Patients With Full-Thickness Rectal Prolapse. *Diseases of the Colon & Rectum*. 47(2):198–203. DOI: 10.1007/s10350-003-0035-4.

Dvorkin, L.S., Gladman, M.A., Epstein, J., Scott, S.M., Williams, N.S. & Lunniss, P.J. 2005. Rectal intussusception in symptomatic patients is different from that in asymptomatic volunteers. *The British journal of surgery*. 92:866–872. DOI: 10.1002/bjs.4912.

Faccioli, N., Comai, A., Mainardi, P., Perandini, S., Moore, F. & Pozzi-Mucelli, R. 2010. Defecography: a practical approach. *Diagnostic and interventional radiology (Ankara, Turkey)*. 16:209–216. DOI: 10.4261/1305-3825.DIR.2584-09.1.

Farouk, R., Duthie, G.S., MacGregor, A.B. & Bartolo, D.C. 1994. Rectoanal inhibition and incontinence in patients with rectal prolapse. *The British journal of surgery*. 81(5):743–6. Available: <http://www.ncbi.nlm.nih.gov/pubmed/8044569> [2014, January 11].

Fazeli, M.S., Kazemeini, A.R., Keshvari, A. & Keramati, M.R. 2013. Delorme's Procedure: An Effective Treatment for a Full-Thickness Rectal Prolapse in Young Patients. *Annals of*

The incidence of recurrence after Delorme's procedure for full thickness rectal prolapse - a retrospective private-public cohort study.

coloproctology. 29(2):60–5. DOI: 10.3393/ac.2013.29.2.60.

Felt-Bersma, R.J.F., Tiersma, E.S.M. & Cuesta, M.A. 2008. Rectal prolapse, rectal intussusception, rectocele, solitary rectal ulcer syndrome, and enterocele. *Gastroenterology clinics of North America*. 37:645–668, ix. DOI: 10.1016/j.gtc.2008.06.001.

Fleming, F.J., Kim, M.J., Gunzler, D., Messing, S., Monson, J.R.T. & Speranza, J.R. 2012. It's the procedure not the patient: the operative approach is independently associated with an increased risk of complications after rectal prolapse repair. *Colorectal disease : the official journal of the Association of Coloproctology of Great Britain and Ireland*. 14(3):362–8. DOI: 10.1111/j.1463-1318.2011.02616.x.

Fleshman, J.W., Kodner, I.J. & Fry, R.D. 1989. Internal intussusception of the rectum: a changing perspective. *The Netherlands journal of surgery*. 41(6):145–8. Available: <http://www.ncbi.nlm.nih.gov/pubmed/2694021> [2014, January 06].

Gagliardi, G., Pescatori, M., Altomare, D.F., Binda, G.A., Bottini, C., Dodi, G., Filingeri, V., Milito, G., et al. 2008. Results, outcome predictors, and complications after stapled transanal rectal resection for obstructed defecation. *Diseases of the colon and rectum*. 51:186–195; discussion 195. DOI: 10.1007/s10350-007-9096-0.

Galili, Y. & Rabau, M. 1997. Comparison of polyglycolic acid and polypropylene mesh for rectopexy in the treatment of rectal prolapse. *The European journal of surgery = Acta chirurgica*. 163(6):445–8. Available: <http://www.ncbi.nlm.nih.gov/pubmed/9231856> [2013, October 27].

Glasgow, S.C., Birnbaum, E.H., Kodner, I.J., Fleshman, J.W. & Dietz, D.W. 2006. Preoperative anal manometry predicts continence after perineal proctectomy for rectal prolapse. *Diseases of the colon and rectum*. 49:1052–1058. DOI: 10.1007/s10350-006-0538-x.

Gouvas, N., Georgiou, P.A., Agalianos, C., Tan, E., Tekkis, P., Dervenis, C. & Xynos, E. 2015. Ventral colpoproctopexy for overt rectal prolapse and obstructed defaecation syndrome: a systematic review. *Colorectal Disease*. 17:34-46. DOI: 10.1111/codi.12751.

Harewood, G.C., Coulie, B., Camilleri, M., Rath-Harvey, D. & Pemberton, J.H. 1999. Descending perineum syndrome: audit of clinical and laboratory features and outcome of pelvic floor retraining. *The American journal of gastroenterology*. 94:126–130. DOI: S0002927098006637 [pii]r10.1111/j.1572-0241.1999.00782.x.

Heah, S.M., Hartley, J.E., Hurley, J., Duthie, G.S. & Monson, J.R. 2000. Laparoscopic suture rectopexy without resection is effective treatment for full-thickness rectal prolapse. *Diseases of the colon and rectum*. 43:638–643. DOI: 10.1007/BF02235579.

The incidence of recurrence after Delorme's procedure for full thickness rectal prolapse - a retrospective private-public cohort study.

Henry, M.M., Parks, A.G. & Swash, M. 1982. The pelvic floor musculature in the descending perineum syndrome. *The British journal of surgery*. 69:470–472.

Heymen, S., Scarlett, Y., Jones, K., Ringel, Y., Drossman, D. & Whitehead, W.E. 2007.

Randomized, controlled trial shows biofeedback to be superior to alternative treatments for patients with pelvic floor dyssynergia-type constipation. *Diseases of the colon and rectum*. 50(4):428–41.

DOI: 10.1007/s10350-006-0814-9.

Hiltunen, K.M., Matikainen, M., Auvinen, O. & Hietanen, P. 1986. Clinical and manometric evaluation of anal sphincter function in patients with rectal prolapse. *American journal of surgery*. 151:489–492. DOI: 10.1016/0002-9610(86)90110-8.

Ho, Y.H. & Goh, H.S. 1995. The neurophysiological significance of perineal descent. *International journal of colorectal disease*. 10:107–111. DOI: 10.1007/BF00341208.

Ihre, T. & Seligson, U. Intussusception of the rectum-internal proctodia: treatment and results in 90 patients. *Diseases of the colon and rectum*. 18(5):391–6. Available:

<http://www.ncbi.nlm.nih.gov/pubmed/1149581> [2013, November 23].

Jacobs, L.K., Lin, Y.J. & Orkin, B.A. 1997. The best operation for rectal prolapse. *The Surgical clinics of North America*. 77:49–70. DOI: 10.1016/S0039-6109(05)70532-6.

Jarrett, M.E.D., Emmanuel, A. V, Vaizey, C.J. & Kamm, M.A. 2004. Behavioural therapy (biofeedback) for solitary rectal ulcer syndrome improves symptoms and mucosal blood flow. *Gut*. 53:368–370. DOI: 10.1136/gut.2003.025643.

Jayne, D.G., Schwandner, O. & Stuto, A. 2009. Stapled transanal rectal resection for obstructed defecation syndrome: one-year results of the European STARR Registry. *Diseases of the colon and rectum*. 52(7):1205-12–4. DOI: 10.1007/DCR.0b013e3181a9120f.

Kairaluoma, M. V & Kellokumpu, I.H. 2005. Epidemiologic aspects of complete rectal prolapse. *Scandinavian journal of surgery : SJS : official organ for the Finnish Surgical Society and the Scandinavian Surgical Society*. 94(3):207–10. Available:

<http://www.ncbi.nlm.nih.gov/pubmed/16259169> [2014, January 11].

Kairaluoma, M. V., Viljakka, M.T. & Kellokumpu, I.H. 2003. Open vs. Laparoscopic Surgery for Rectal Prolapse. *Diseases of the Colon & Rectum*. 46(3):353–360. DOI: 10.1007/s10350-004-6555-8.

Karasick, S., Karasick, D. & Karasick, S.R. 1993. Functional disorders of the anus and rectum: findings on defecography. *AJR. American journal of roentgenology*. 160:777–782. DOI:

The incidence of recurrence after Delorme's procedure for full thickness rectal prolapse - a retrospective private-public cohort study.

10.1136/gut.45.2008.ii55.

Kim, D.S., Tsang, C.B., Wong, W.D., Lowry, A.C., Goldberg, S.M. & Madoff, R.D. 1999.

Complete rectal prolapse: evolution of management and results. *Diseases of the colon and rectum*. 42:460-466-469. DOI: 10.1007/BF02234167.

Kimmins, M.H., Evetts, B.K., Isler, J. & Billingham, R. 2001. The Altemeier repair: outpatient treatment of rectal prolapse. *Diseases of the colon and rectum*. 44(4):565–570.

Kuijpers, H.C. 1992. Treatment of complete rectal prolapse: To narrow, to wrap, to suspend, to fix, to encircle, to plicate or to resect? *World Journal of Surgery*. 16(5):826–830. DOI:

10.1007/BF02066977.

Launer, D.P., Fazio, V.W., Weakley, F.L., Turnhull, R.B., Jagelman, D.G. & Lavery, I.C. 1982.

The Ripstein procedure. *Diseases of the Colon & Rectum*. 25(1):41–45. DOI:

10.1007/BF02553547.

Law, P.J., Kamm, M.A. & Bartram, C.I. 1991. Anal endosonography in the investigation of faecal incontinence. *British Journal of Surgery*. 78(3):312–314.

Lechaux, J.P., Lechaux, D. & Perez, M. 1995. Results of Delorme's procedure for rectal prolapse. *Diseases of the Colon & Rectum*. 38(3):301–307. DOI: 10.1007/BF02055608.

Lee, S.-H., Lakhtaria, P., Canedo, J., Lee, Y.-S. & Wexner, S.D. 2011. Outcome of laparoscopic rectopexy versus perineal rectosigmoidectomy for full-thickness rectal prolapse in elderly patients. *Surgical endoscopy*. 25:2699–2702. DOI: 10.1007/s00464-011-1632-2.

Liberman, H., Hughes, C. & Dippolito, A. 2000. Evaluation and outcome of the delorme procedure in the treatment of rectal outlet obstruction. *Diseases of the colon and rectum*. 43:188–192. DOI:

10.1007/BF02236980.

Lindsey, I. 2010. Commentary: Best practice in rectal prolapse. *Colorectal disease : the official journal of the Association of Coloproctology of Great Britain and Ireland*. 12(6):512–4. DOI:

10.1111/j.1463-1318.2010.02264.x.

Lindsey, I. & Cunningham, C. 2004. Surgical treatment of rectal prolapse. *British journal of surgery*. 91(11):1389. DOI: 10.1002/bjs.4739.

Lindsey, I., Nugent, K. & Dixon, T. 2011. Internal rectal prolapse. In *Pelvic Floor Disorders for the Colorectal Surgeon*. Oxford: Oxford University Press. 93.

Longo, A. 2002. Stapled anopexy and stapled hemorrhoidectomy: two opposite concepts and procedures. *Diseases of the colon and rectum*. 45(4):571–2; author reply 572. Available:

The incidence of recurrence after Delorme's procedure for full thickness rectal prolapse - a retrospective private-public cohort study.

<http://www.ncbi.nlm.nih.gov/pubmed/12006945> [2014, January 11].

Luukkonen, P., Mikkonen, U. & Jarvinen, H. 1992. Abdominal rectopexy with sigmoidectomy vs. rectopexy alone for rectal prolapse: A prospective, randomized study. *International Journal of Colorectal Disease*. 7(4):219–222. DOI: 10.1007/BF00341225.

M.H., F. & A.G., M. 2003. Imaging fecal incontinence. *European Journal of Radiology*. 47(2):108–116. DOI: 10.1016/S0720-048X(03)00163-3.

Madbouly, K.M., Senagore, A.J., Delaney, C.P., Duepre, H.J., Brady, K.M. & Fazio, V.W. 2003. Clinically based management of rectal prolapse. *Surgical endoscopy*. 17(1):99–103. DOI: 10.1007/s00464-002-8511-9.

Madiba TE, Baig MK, W.S. 2005. Surgical management of rectal prolapse. *ARCH*. 140:63–73. DOI: 10.1007/s10151-011-0747-8.

Madoff, R.D. & Mellgren, A. 1999. One Hundred Years of Rectal Prolapse Surgery. *Diseases of the Colon & Rectum*. 42(4):441–450.

Marceau, C., Parc, Y., Debroux, E., Tiret, E. & Parc, R. 2005. Complete rectal prolapse in young patients: psychiatric disease a risk factor of poor outcome. *Colorectal disease : the official journal of the Association of Coloproctology of Great Britain and Ireland*. 7(4):360–5. DOI: 10.1111/j.1463-1318.2005.00762.x.

Marchal, F., Bresler, L., Ayav, A., Zarnegar, R., Brunaud, L., Duchamp, C. & Boissel, P. 2005. Long-term results of Delorme's procedure and Orr-Loygue rectopexy to treat complete rectal prolapse. *Diseases of the colon and rectum*. 48(9):1785–90. DOI: 10.1007/s10350-005-0088-7.

Mellgren, A., Schultz, I., Johansson, C. & Dolk, A. 1997. Internal rectal intussusception seldom develops into total rectal prolapse. *Diseases of the colon and rectum*. 40:817–820. DOI: 10.1007/BF02055439.

Melton, G.B. & Kwaan, M.R. 2013. Rectal prolapse. *The Surgical clinics of North America*. 93(1):187–98. DOI: 10.1016/j.suc.2012.09.010.

Mezwa, D.G., Feczko, P.J. & Bosanko, C. 1993. Radiologic evaluation of constipation and anorectal disorders. *Radiologic clinics of North America*. 31:1375–1393. DOI: 10.1016/S0889-8553(05)70167-9.

Mollen, R.M., Kuijpers, J.H. & van Hoek, F. 2000. *Effects of rectal mobilization and lateral ligaments division on colonic and anorectal function*. DOI: 10.1007/BF02237437.

Moschcowitz, A. 1912. The pathogenesis, anatomy and cure of prolapse of the rectum. *Surg*

The incidence of recurrence after Delorme's procedure for full thickness rectal prolapse - a retrospective private-public cohort study.

Gynecol Obstet. (15):7–21.

Oom, D.M.J., van Dijk, V.R.M., Gosselink, M.P., van Wijk, J.J. & Schouten, W.R. 2007. Enterocele repair by abdominal obliteration of the pelvic inlet: long-term outcome on obstructed defaecation and symptoms of pelvic discomfort. *Colorectal disease : the official journal of the Association of Coloproctology of Great Britain and Ireland.* 9:845–850. DOI: 10.1111/j.1463-1318.2007.01295.x.

Orrom, W.J., Bartolo, D.C., Miller, R., Mortensen, N.J. & Roe, A.M. 1991. Rectopexy is an ineffective treatment for obstructed defecation. *Diseases of the colon and rectum.* 34:41–46. DOI: 10.1007/BF02050205.

Parks, A.G., Porter, N.H. & Hardcastle, J. 1966. The syndrome of the descending perineum. *Proceedings of the Royal Society of Medicine.* 59(6):477–82. Available: <http://www.ncbi.nlm.nih.gov.ezproxy.uct.ac.za/pmc/articles/PMC1900931/> [2014, January 07].

Penninckx, F., D'Hoore, A., Sohier, S. & Kerremans, R. 1997. Abdominal resection rectopexy versus Delorme's procedure for rectal prolapse: a predictable outcome. *International Journal of Colorectal Disease.* 12(1):49–50. DOI: 10.1007/s003840050079.

Pescatori, M. & Gagliardi, G. 2008. Postoperative complications after procedure for prolapsed hemorrhoids (PPH) and stapled transanal rectal resection (STARR) procedures. *Techniques in coloproctology.* 12:7–19. DOI: 10.1007/s10151-008-0391-0.

Pescatori, M. & Quondamcarlo, C. 1999. A new grading of rectal internal mucosal prolapse and its correlation with diagnosis and treatment. *International journal of colorectal disease.* 14:245–249. DOI: 10.1007/s003840050218.

Pescatori, M., Interisano, A., Stolfi, V.M. & Zoffoli, M. 1998. Delorme's operation and sphincteroplasty for rectal prolapse and fecal incontinence. *International journal of colorectal disease.* 13:223–227. DOI: 10.1007/s003840050165.

Pescatori, M., Spyrou, M. & Pulvirenti d'Urso, A. 2007. A prospective evaluation of occult disorders in obstructed defecation using the "iceberg diagram". *Colorectal disease : the official journal of the Association of Coloproctology of Great Britain and Ireland.* 9:452–456. DOI: 10.1111/j.1463-1318.2006.01138.x.

Plusa, S.M., Charig, J.A., Balaji, V., Watts, A. & Thompson, M.R. 1995. Physiological changes after Delorme's procedure for full-thickness rectal prolapse. *British Journal of Surgery.* 82(11):1475–1478. DOI: 10.1002/bjs.1800821109.

Poen, a C., de Brauw, M., Felt-Bersma, R.J., de Jong, D. & Cuesta, M. a. 1996. Laparoscopic

The incidence of recurrence after Delorme's procedure for full thickness rectal prolapse - a retrospective private-public cohort study.

rectopexy for complete rectal prolapse. Clinical outcome and anorectal function tests. *Surgical endoscopy*. 10(9):904–908. DOI: 10.3109/13645709609153712.

Pomerri, F. & Muzio, P.C. 2008. *Rectal Prolapse*. D.F. Altomare & F. Pucciani, Eds. Milano: Springer Milan. DOI: 10.1007/978-88-470-0684-3.

Pomerri, F., Zuliani, M., Mazza, C., Villarejo, F. & Scopece, A. 2001. Defecographic measurements of rectal intussusception and prolapse in patients and in asymptomatic subjects. *AJR. American journal of roentgenology*. 176:641–645.

Pucciani, F., Boni, D., Perna, F., Bassotti, G. & Bellini, M. 2005. Descending perineum syndrome: are abdominal hysterectomy and bowel habits linked? *Diseases of the colon and rectum*. 48:2094–2099. DOI: 10.1016/S0739-5930(08)70267-8.

Quigley, E.M.M. 2013. Disorders of the pelvic floor and anal sphincters; a gastroenterologist's perspective. *Revista Médica Clínica Las Condes*. 24(2):293–298. DOI: 10.1016/S0716-8640(13)70161-5.

Raizada, V. & Mittal, R.K. 2008. Pelvic floor anatomy and applied physiology. *Gastroenterology clinics of North America*. 37:493–509, vii. DOI: 10.1016/j.gtc.2008.06.003.

Ramanujam, P.S. & Venkatesh, K.S. 1988. Perineal excision of rectal prolapse with posterior levator ani repair in elderly high-risk patients. *Diseases of the colon and rectum*. 31:704–706. DOI: 10.1007/BF02552589.

Rao, S.S. 1998. The technical aspects of biofeedback therapy for defecation disorders. *The Gastroenterologist*. 6:96–103.

Rao, S.S., Welcher, K.D. & Leistikow, J.S. 1998. Obstructive defecation: a failure of rectoanal coordination. *The American journal of gastroenterology*. 93:1042–1050. DOI: 10.1111/j.1572-0241.1998.00326.x.

Rao, S.S.C., Tuteja, A.K., Vellema, T., Kempf, J. & Stessman, M. 2004. Dyssynergic defecation: demographics, symptoms, stool patterns, and quality of life. *Journal of clinical gastroenterology*. 38(8):680–5. Available: <http://www.ncbi.nlm.nih.gov/pubmed/15319652> [2013, November 21].

Rao, S.S.C., Ozturk, R., De Ocampo, S. & Stessman, M. 2006. Pathophysiology and role of biofeedback therapy in solitary rectal ulcer syndrome. *The American journal of gastroenterology*. 101:613–618. DOI: 10.1111/j.1572-0241.2006.00466.x.

Rao, S.S.C., Seaton, K., Miller, M., Brown, K., Nygaard, I., Stumbo, P., Zimmerman, B. & Schulze, K. 2007. Randomized controlled trial of biofeedback, sham feedback, and standard therapy

The incidence of recurrence after Delorme's procedure for full thickness rectal prolapse - a retrospective private-public cohort study.

for dyssynergic defecation. *Clinical gastroenterology and hepatology : the official clinical practice journal of the American Gastroenterological Association*. 5(3):331–8. DOI:

10.1016/j.cgh.2006.12.023.

Ripstein, C. 1952. Treatment of massive rectal prolapse. *American journal of surgery*. (83):68–71.

Rothenhoefer, S., Herrle, F., Herold, A., Joos, A., Bussen, D., Kieser, M., Schiller, P., Klose, C., et al. 2012. DeloRes trial: study protocol for a randomized trial comparing two standardized surgical approaches in rectal prolapse - Delorme's procedure versus resection rectopexy. *Trials*. 13(1):155. DOI: 10.1186/1745-6215-13-155.

Sajid, M.S., Siddiqui, M.R.S. & Baig, M.K. 2010. Open vs laparoscopic repair of full-thickness rectal prolapse: a re-meta-analysis. *Colorectal disease : the official journal of the Association of Coloproctology of Great Britain and Ireland*. 12(6):515–25. DOI: 10.1111/j.1463-1318.2009.01886.x.

Samaranayake, C.B., Luo, C., Plank, A.W., Merrie, A.E.H., Plank, L.D. & Bissett, I.P. 2010. Systematic review on ventral rectopexy for rectal prolapse and intussusception. *Colorectal disease : the official journal of the Association of Coloproctology of Great Britain and Ireland*. 12:504–512. DOI: 10.1111/j.1463-1318.2009.01934.x.

Santoro, G.A., Wieczorek, A.P., Dietz, H.P., Mellgren, A., Sultan, A.H., Shobeiri, S.A., Stankiewicz, A. & Bartram, C. 2011. State of the art: An integrated approach to pelvic floor ultrasonography. *Ultrasound in Obstetrics and Gynecology*. 37(4):381–396. DOI: 10.1002/uog.8816.

Saranovic, D., Barisic, G., Krivokapic, Z., Masulovic, D. & Djuric-Stefanovic, A. 2007. Endoanal ultrasound evaluation of anorectal diseases and disorders: Technique, indications, results and limitations. *European Journal of Radiology*. 61(3):480–489. DOI: 10.1016/j.ejrad.2006.07.033.

Schwandner, O. & Fürst, A. 2007. DOI: 10.1007/s00053-007-7003-8.

Schwandner, O., Stuto, A., Jayne, D., Lenisa, L., Pigot, F., Tuech, J.-J., Scherer, R., Nugent, K., et al. 2008. Decision-making algorithm for the STARR procedure in obstructed defecation syndrome: position statement of the group of STARR Pioneers. *Surgical innovation*. 15(2):105–9. DOI: 10.1177/1553350608316684.

Senapati, a, Gray, R.G., Middleton, L.J., Harding, J., Hills, R.K., Armitage, N.C.M., Buckley, L. & Northover, J.M. a. 2013. PROSPER: a randomised comparison of surgical treatments for rectal prolapse. *Colorectal disease : the official journal of the Association of Coloproctology of Great Britain and Ireland*. 15(7):858–68. DOI: 10.1111/codi.12177.

The incidence of recurrence after Delorme's procedure for full thickness rectal prolapse - a retrospective private-public cohort study.

Shorvon, P.J., McHugh, S., Diamant, N.E., Somers, S. & Stevenson, G.W. 1989. Defecography in normal volunteers: results and implications. *Gut*. 30:1737–1749. DOI: 10.1136/gut.30.12.1737.

Sielezneff, I., Malouf, A., Cesari, J., Brunet, C., Sarles, J.-C. & Sastre, B. 1999. Selection criteria for internal rectal prolapse repair by delorme's transrectal excision. *Diseases of the Colon & Rectum*. 42(3):367–373. DOI: 10.1007/BF02236355.

Siproudhis, L., Bellissant, E., Juguet, F., Mendler, M.H., Allain, H., Bretagne, J.F. & Gosselin, M. 1998. Rectal adaptation to distension in patients with overt rectal prolapse. *The British journal of surgery*. 85:1527–1532.

Slawik, S., Soulsby, R., Carter, H., Payne, H. & Dixon, A.R. 2008. Laparoscopic ventral rectopexy, posterior colporrhaphy and vaginal sacrocolpopexy for the treatment of recto-genital prolapse and mechanical outlet obstruction. *Colorectal disease : the official journal of the Association of Coloproctology of Great Britain and Ireland*. 10:138–143. DOI: 10.1111/j.1463-1318.2007.01259.x.

Solomon, M.J., Young, C.J., Eysers, A.A. & Roberts, R.A. 2002. *Randomized clinical trial of laparoscopic versus open abdominal rectopexy for rectal prolapse*. DOI: 10.1046/j.0007-1323.2001.01957.x.

Sood, S.K., Garner, J.P. & Amin, S.N.O. 2008. *Spontaneous resolution of solitary rectal ulcer syndrome during pregnancy: report of a case*. V. 51. DOI: 10.1007/s10350-008-9268-6.

Speakman, C.T.M., Madden, M. V., Nicholls, R.J. & Kamm, M.A. 1991. Lateral ligament division during rectopexy causes constipation but prevents recurrence: Results of a prospective randomized study. *British Journal of Surgery*. 78(12):1431–1433. DOI: 10.1002/bjs.1800781207.

Sun, W.M., Read, N.W., Donnelly, T.C., Bannister, J.J. & Shorthouse, A.J. 1989. A common pathophysiology for full thickness rectal prolapse, anterior mucosal prolapse and solitary rectal ulcer. *British Journal of Surgery*. 76(3):290–295. DOI: 10.1002/bjs.1800760323.

Takahashi, T., Yamana, T., Sahara, R. & Iwadare, J. 2006. Enterocele: what is the clinical implication? *Diseases of the colon and rectum*. 49:S75–S81. DOI: 10.1007/s10350-006-0683-2.

Tou, S., Brown, S.R. & Nelson, R.L. 2015. Surgery for complete (full-thickness) rectal prolapse in adults. In *Cochrane Database of Systematic Reviews*. S. Tou, Ed. Chichester, UK: John Wiley & Sons, Ltd. DOI: 10.1002/14651858.CD001758.pub3.

Vaizey, C.J., Roy, A.J. & Kamm, M.A. 1997. Prospective evaluation of the treatment of solitary rectal ulcer syndrome with biofeedback. *Gut*. 41(6):817–820. DOI: 10.1136/gut.41.6.817.

The incidence of recurrence after Delorme's procedure for full thickness rectal prolapse - a retrospective private-public cohort study.

Walldén, L. 1953. Roentgen Examination of the Deep Rectogenital Pouch. *Acta Radiologica*. os-39(2):105–116. DOI: 10.1177/028418515303900203.

Wassef, R., Rothenberger, D.A. & Goldberg, S.M. 1986. Rectal prolapse. *Current problems in surgery*. 23(6):397–451. Available: <http://www.ncbi.nlm.nih.gov/pubmed/3522112> [2014, January 11].

Watts, a M. & Thompson, M.R. 2000. Evaluation of Delorme's procedure as a treatment for full-thickness rectal prolapse. *The British journal of surgery*. 87(2):218–22. DOI: 10.1046/j.1365-2168.2000.01342.x.

Wijffels, N., Cunningham, C., Dixon, A., Greenslade, G. & Lindsey, I. 2011. Laparoscopic ventral rectopexy for external rectal prolapse is safe and effective in the elderly. Does this make perineal procedures obsolete? *Colorectal Disease*. 13(5):561–566. DOI: 10.1111/j.1463-1318.2010.02242.x.

Wijffels, N.A., Collinson, R., Cunningham, C. & Lindsey, I. 2010. What is the natural history of internal rectal prolapse? *Colorectal disease : the official journal of the Association of Coloproctology of Great Britain and Ireland*. 12(8):822–30. DOI: 10.1111/j.1463-1318.2009.01891.x.

Winde, G., Reers, B., Nottberg, H., Berns, T., Meyer, J. & Bünte, H. 1993. Clinical and functional results of abdominal rectopexy with absorbable mesh-graft for treatment of complete rectal prolapse. *The European journal of surgery = Acta chirurgica*. 159(5):301–5. Available: <http://www.ncbi.nlm.nih.gov/pubmed/8103365> [2013, October 27].

Woods, R., Voyvodic, F., Schloithe, A.C., Sage, M.R. & Wattchow, D.A. 2003. Anal sphincter tears in patients with rectal prolapse and faecal incontinence. *Colorectal disease : the official journal of the Association of Coloproctology of Great Britain and Ireland*. 5(6):544–8. Available: <http://www.ncbi.nlm.nih.gov/pubmed/14617237> [2014, January 11].

Yoshioka, K., Ogunbiyi, O.A. & Keighley, M.R. 1998. Pouch perineal rectosigmoidectomy gives better functional results than conventional rectosigmoidectomy in elderly patients with rectal prolapse. *The British journal of surgery*. 85(11):1525–6. DOI: 10.1046/j.1365-2168.1998.00937.x.

Young, M.T., Jafari, M.D., Phelan, M.J., Stamos, M.J., Mills, S., Pigazzi, A. & Carmichael, J.C. 2015. Surgical treatments for rectal prolapse: how does a perineal approach compare in the laparoscopic era? *Surgical Endoscopy*. 29(3):607–613. DOI: 10.1007/s00464-014-3707-3.

Youssef, M., Thabet, W., El Nakeeb, A., Magdy, A., Abd Alla, E., Abd El Nabeey, M., Yamani Fouda, E., Omar, W., et al. 2012. Comparative study between Delorme operation with or without postanal repair and levatoroplasty in treatment of complete rectal prolapse. DOI:

The incidence of recurrence after Delorme's procedure for full thickness rectal prolapse - a retrospective private-public cohort study.

10.1016/j.ijvsu.2012.11.011.

Zbar, A., Takashima, S., Hasegawa, T. & Kitabayashi, K. 2002. Perineal rectosigmoidectomy (Altemeier's procedure): a review of physiology, technique and outcome. *Techniques in coloproctology*. (6):109–116.

CHAPTER 2: Publication-ready Manuscript

The incidence of recurrence after Delorme's procedure for full-thickness rectal prolapse

J. Plaskett and R. Baigrie

Department of Surgery, Groote Schuur Hospital, Cape Town

1. Introduction

Curative treatments of full-thickness rectal prolapse are exclusively surgical. More than 100 surgical techniques have been described during the last century with no accepted standard procedure (Brodén & Snellman, 1968). Most of these are solely of historical interest and only a few are in current use (Madoff & Mellgren, 1999). The surgical approach remains divided between abdominal and perineal, with the common aim being to correct the prolapse, restore normal bowel function, and avoid recurrence. Delorme's procedure is a perineal technique for the repair of full-thickness rectal prolapse, first described by the French military surgeon Edmond Delorme in 1900 (Delorme, 1900). Due to its relative safety and technical simplicity, as well low postoperative morbidity and mortality rates, it has remained a popular operative choice for those patients not fit enough to withstand an abdominal operation (Melton & Kwaan, 2013). Numerous retrospective series have reported high recurrence rates of up to 32% (Madiba TE, Baig MK, 2005), but due to its relative safety and technical simplicity, it has remained popular for elderly patients or those with significant comorbidity. The aim of this study was to contribute to the body of knowledge about this controversial operation by determining the recurrence rates and functional outcomes following primary and revision Delorme's procedures, and compare these outcomes in a multi-surgeon public hospital versus a single surgeon series in the private sector.

2. Patients and Methods

A search of all MEDLINE, PUBMED and Cochrane databases was performed on all studies reporting Delorme's procedure for rectal prolapse. The following search headings were used: rectal prolapse, full-thickness rectal prolapse, Delorme, Delorme's procedure. All abstracts, studies and

The incidence of recurrence after Delorme's procedure for full thickness rectal prolapse - a retrospective private-public cohort study.

citations were reviewed. No language restrictions were applied. The search included the period 1900 when the procedure was first described to present. A retrospective review was undertaken of all patients who underwent a Delorme's procedure between February 2001 and March 2014. Data was collected retrospectively from a comprehensive electronic patient database and patient folders. These included history, size, reducibility (spontaneous vs digital reduction), faecal incontinence, constipation, pain, and bleeding. Also recorded was the obstetric history and any history of associated pelvic floor disorders. Within the limits of retrospective data gathering, faecal incontinence was recorded according to Park's classification (incontinence to solid or liquid stool or flatus), and constipation recorded according to number of bowel movements per week and need for medication, modified from the scoring system proposed by Agachan et al (Agachan et al., 1996). Recurrence was defined as partial or complete full-thickness prolapse.

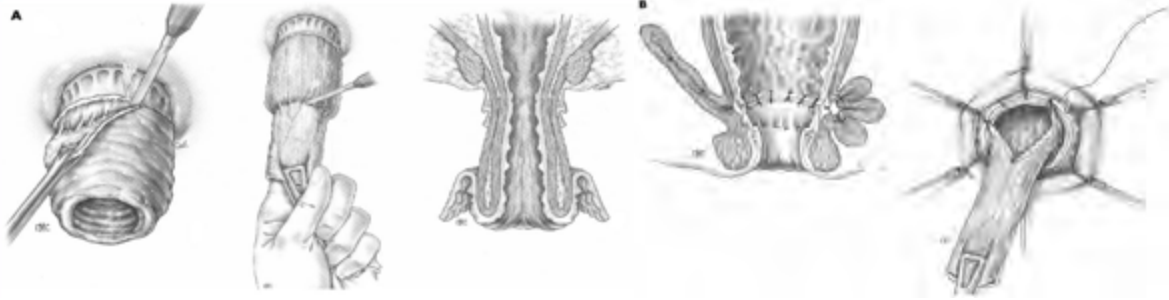
2.1 Surgical technique

In the public sector cohort, all operations were performed by six different colorectal fellows under supervision, and by a single colorectal subspecialist in the private cohort. The repair was performed based on the principles classically described without modifications (Delorme, 1900)(Binda & Serventi, 2008).

No bowel preparation was used preoperatively, but prophylactic antibiotics and venous thromboembolic prophylaxis were applied in all patients and bladder catheterization applied selectively. Patients were positioned in either the prone jack-knife or lithotomy position, and usually a Lone Star retractor was utilised. The rectal submucosa was infiltrated with a solution of 1:200 000 adrenaline and 0.25% bupivacaine in 0.9% saline, to reduce bleeding and assist in defining the mucosectomy plane. Commencing a few millimetres above the dentate line, mucosectomy was performed with needle-point diathermy and extended over the apex of the prolapsed segment until the limit of exposure was reached. After resecting the mucosal sleeve, the muscular tube was plicated with multiple 2.0 polygalactin 910 (Vicryl) sutures placed circumferentially between the mucosal edges (approximating to the hours of a clock). The prolapsed segment was then reduced as the sutures were tied. A final inspection of the intra-anal suture line allowed closure of any residual mucosal defects. Stool softener was provided postoperatively.

All procedures were performed under spinal or general anaesthesia.

The incidence of recurrence after Delorme's procedure for full thickness rectal prolapse - a retrospective private-public cohort study.



Source: Surgical Treatment of Complete Rectal Prolapse. J-L. Faucheron (2008)
http://www.jle.com/e-docs/00/04/42/3E/texte_alt_jlehp00412_gr4.jpg

2.2 Postoperative follow-up

Patients were routinely followed up within the first postoperative month and thereafter as required. Long-term follow up data was obtained telephonically, using a structured questionnaire, from all patients, their carer or general practitioner, who were interviewed regarding recurrence, constipation and incontinence.

2.3 Statistical analysis

IBM SPSS Statistical Software was used for all statistical analyses and graphic representations. Data are presented as mean and range. The chi-squared test was used for cohort comparison. Kaplan-Meier plots were used to calculate the probability of non-recurrence for each parameter examined. $P < 0.050$ was considered statistically significant.

3. Results

3.1 Patient preoperative characteristics

A total of 70 patients underwent Delorme's procedure during the study period described. There were 37 patients in the single surgeon cohort, and 33 in the multiple surgeon cohort (see table 1). The mean age was 71 years (range 20 – 91), with four (6%) patients under 50 years. Eight (11%) patients were male, with a mean age of 50 years (range 20 – 79). Sixty two (89%) patients were female with a mean age of 73 years (range 29 – 91).

Prior rectal prolapse surgery had been performed in 13 (19%) of the 70 patients, and 5 (7%) patients had undergone previous haemorrhoid surgery. Eight (11%) patients had undergone a previous Delorme's procedure, with 4 of these having undergone 2 or more Delorme's procedures prior to the index operation. Prolapse surgery in the 7 other patients included: 1 rectopexy, 1 Thiersch

The incidence of recurrence after Delorme's procedure for full thickness rectal prolapse - a retrospective private-public cohort study.

procedure, 1 partial mucosal resection, and 2 patients were unsure of their procedure. Twenty six (42%) had undergone a previous hysterectomy. Seventeen (24%) of the female patients had a parity of > 3, and 7 (10%) patients gave a history of a perineal tear during delivery.

Thirty eight (54%) patients had a large prolapse of >5cm, and 49 (70%) gave a history of prolapse exceeding 1 year. Preoperative risk factors included: 10 (14%) patients with previous spinal surgery or trauma; 17 (24%) with multiparity (3 or more); 7 (10%) with obstetric trauma; 5 (7%) with diabetes mellitus; and 18 (26%) with associated pelvic floor defects (see table 2).

Table 1

	Single surgeon	Multiple surgeons
Number of patients	37	33
Mean age	69	72
Male : Female	5 : 32	3 : 30
Other pelvic floor prolapse	9 (24%)	9 (27%)
Multiparity/obstetric difficulty	9 (24%)	11 (33%)
Size > 5cm	20 (54%)	18 (55%)

P > 0.05 for all

The most common preoperative symptom was the sensation of prolapse, either spontaneously or on defaecation (reported by all patients or their carers), rectal bleeding in 37 (53%), constipation in 14 (20%), and faecal incontinence in 39 (56%). Two patients (3%) presented with an irreducible prolapse. Overall, 66% of patients had bowel function disturbance attributed to their rectal prolapse.

The incidence of recurrence after Delorme's procedure for full thickness rectal prolapse - a retrospective private-public cohort study.

Table 2

Characteristic	Number of patients (%)	Number of recurrences
Sex		
Male	8 (11)	2
Female	62 (89)	14
ASA		
I	10 (14)	4
II	31 (44)	5
III	29 (41)	7
Previous prolapse surgery		
Delorme's	8 (11)	4
Other	5 (7)	0
Comcomitant pelvic floor disease	18 (26)	6
Parity		
<2	53 (76)	10
>2	17 (24)	6
Size of prolapse		
<5cm	32 (46)	6
>5cm	38 (54)	10
Duration of prolapse		
<1 year	21 (30)	6
>1 year	49 (70)	10
Previous hysterectomy	26 (37)	8
Previous spinal surgery or trauma	10 (14)	2
History of obstetric difficulty (vaginal tear/large baby)	7 (10)	0
Presenting complaint		
Faecal incontinence	39 (56)	6
Constipation	14 (20)	7
Rectal bleeding	37 (53)	4
Irreducible prolapse	2 (3)	0

The incidence of recurrence after Delorme's procedure for full thickness rectal prolapse - a retrospective private-public cohort study.

3.2 Surgical complications

There were 3 (4.3%) deaths within 30 days of surgery. A 51-year-old woman with severe scleroderma and preoperative end-stage renal failure, died of pneumonia at 7 days after operation, a 90-year-old woman with ischaemic heart disease and atrial fibrillation died after a perioperative myocardial infarction at 9 days, and a 79-year-old woman with ischaemic heart disease and congestive cardiac failure died of a myocardial infarction at 14 days. Major postoperative complications occurred in 6 (8.5%) patients; three (4%) patients had suture line dehiscence and bleeding in the 1st postoperative week requiring blood transfusion and resuturing in theatre, two (2.9%) patients had anaemia one day after operation and required a blood transfusion, and one (1.4%) patient suffered severe postoperative faecal impaction requiring a colectomy and temporary colostomy seven days after operation. Minor postoperative complications occurred in 6 (8.5%) patients; three (4%) patients had rectal bleeding recorded in hospital but did not require re-exploration, resuscitation or transfusion, one (1.4%) patient had urinary retention requiring short-term catheterization, another (1.4%) patient had severe rectal pain for 48 hours which resolved spontaneously, and one (1.4%) patient had postoperative confusion with mild hyponatraemia. All six patients with minor postoperative complications were managed conservatively.

3.3 Outcome following Delorme's procedure

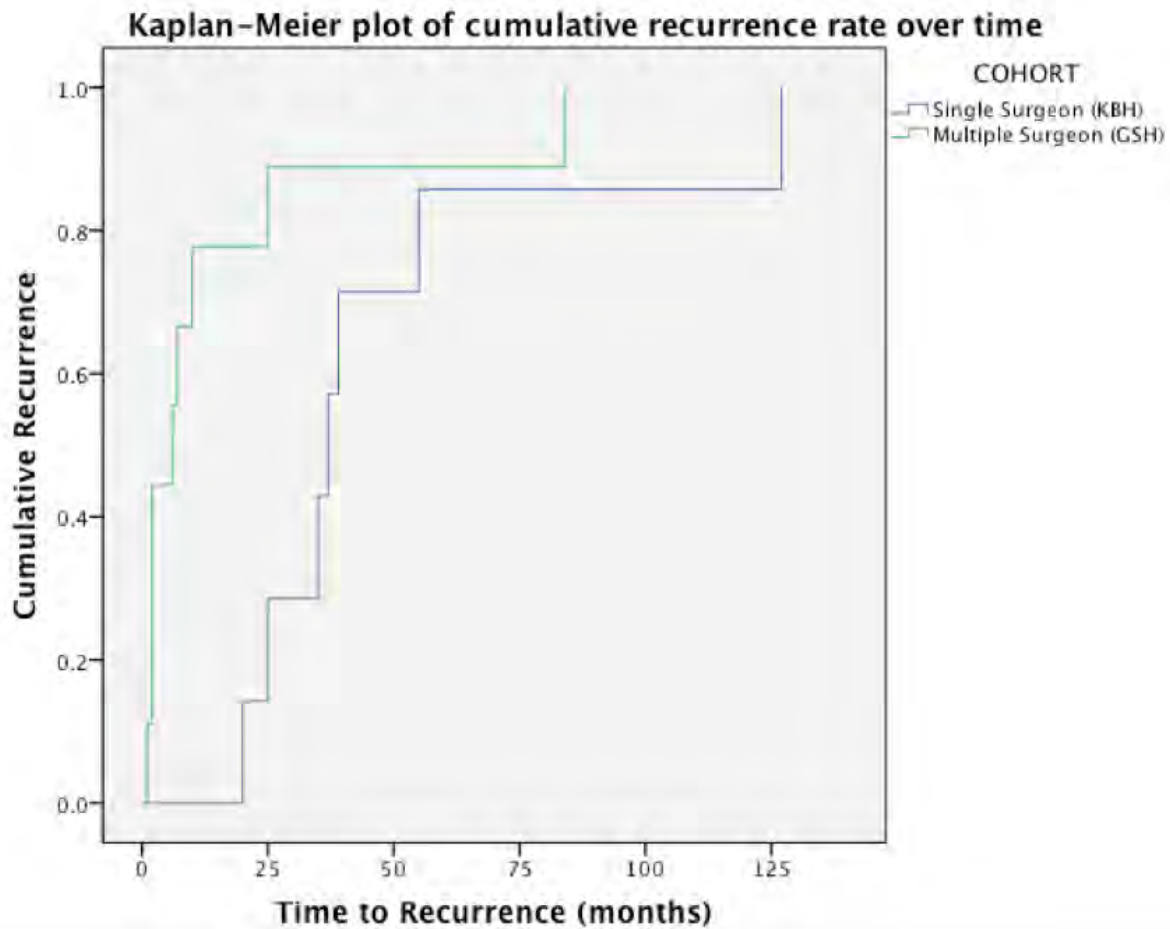
The mean length of hospital stay for all patients was 4 days, and no patients were readmitted within 30 days. Follow-up data were available for all 70 patients and the mean follow up was 58 months (range 0.3 - 154). Fifty five (79%) of the 70 patients were alive at the time of telephonic follow up. None of the deaths were related to prolapse or the surgery.

Recurrence occurred in 16 (23%) patients; seven (19%) in the single-surgeon cohort, and nine (27%) in the multi-surgeon cohort ($p=0.4$). Fourteen (23%) were female, and two (25%) male patients. The mean time to recurrence was 30 months (range 1 - 127); 48 months in the single-surgeon cohort, and 15 months in the multi-surgeon cohort ($p=0.3$). Recurrences ranged from small partial prolapse to large circumferential prolapse (see figure 1).

Of the 16 patients that developed recurrent prolapse, eight (50%) have undergone repeat prolapse procedures; two Altemeier's procedure, five a second Delorme's procedures, and one an abdominal rectopexy. Eight (50%) patients elected not to undergo further surgery as the recurrence was not sufficiently symptomatic (see figure 2).

The incidence of recurrence after Delorme's procedure for full thickness rectal prolapse - a retrospective private-public cohort study.

Figure 1

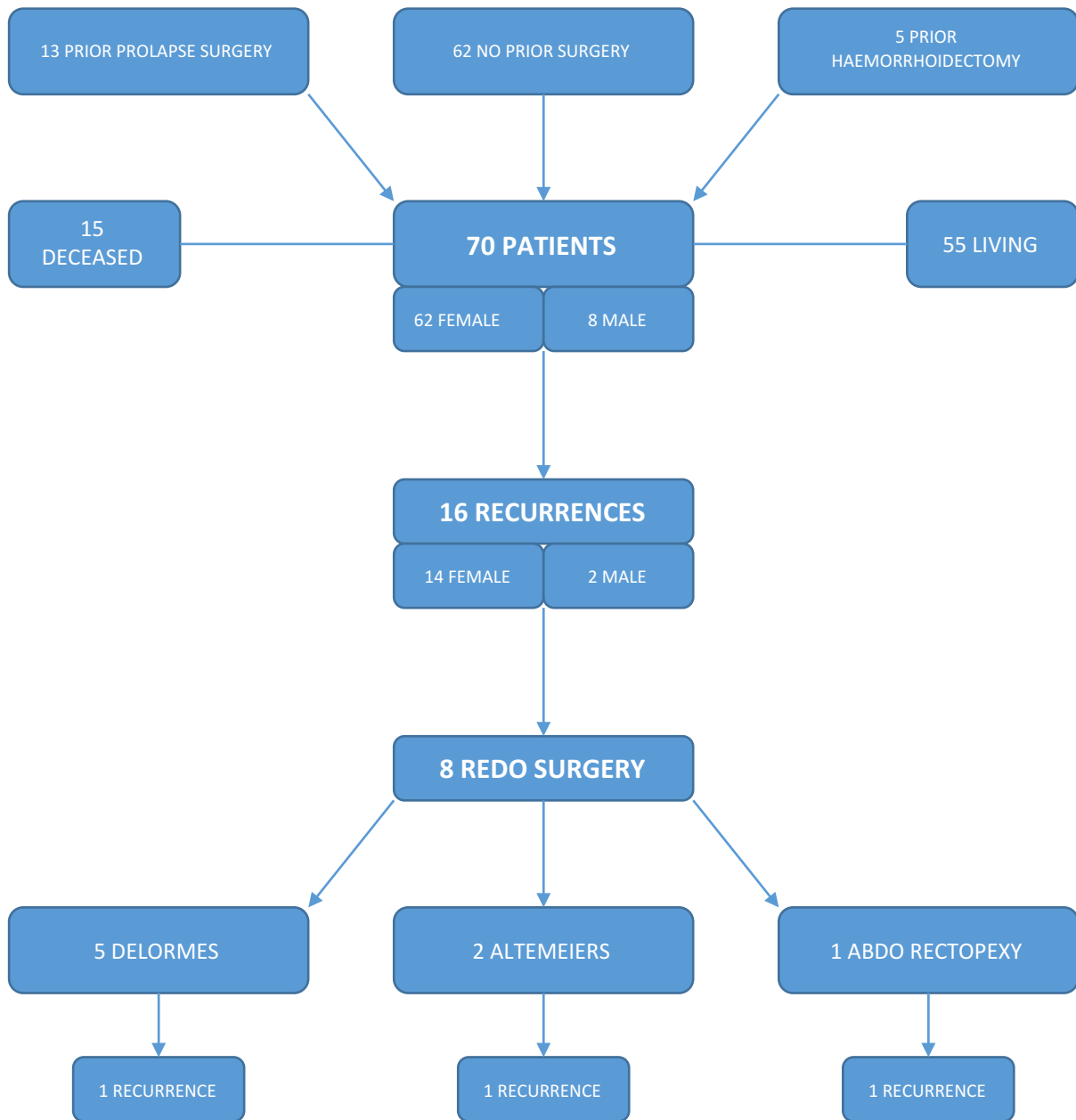


3.4 Changes in bowel function following Delorme's procedure

Of the 39 (56%) patients with preoperative incontinence, 23 (59%) reported complete resolution of their symptoms postoperatively, and 12 (31%) reported a improvement in their symptoms, with nine incontinent to liquid stool/flatus, and two with only minor PR discharge/leakage postoperatively. Incontinence in two patients was successfully managed with a sacral nerve stimulator. Fourteen (20%) patients reported constipation preoperatively with resolution of this symptom in 7 (50%) and improvement in 3 (21%) postoperatively. One patient continued to require rectal washouts and two patients needed regular laxatives. No new symptoms of constipation or faecal incontinence were reported.

The incidence of recurrence after Delorme's procedure for full thickness rectal prolapse - a retrospective private-public cohort study.

Figure 2



4. Discussion

Full-thickness rectal prolapse can be regarded as one end of a spectrum comprised of increasing degrees of prolapse from occult internal to complete external (Brodén & Snellman, 1968)(Wijffels et al., 2010)(Devadhar, 1965). Women above the age of 50 years are six times more likely than men to develop this condition (Jacobs, Lin & Orkin, 1997). This series confirms the demographics of rectal prolapse, with nearly ninety percent being female and over 70 years. These data also demonstrate Delorme's procedure to be safe, with only a 4% mortality in a geriatric population, with no other complications of any consequence. It has a low analgesic requirement and the short hospital stay is more frequently dictated by the patient's social circumstances than any clinical need.

An evidence-based single operation for all patients with rectal prolapse does not exist.

Improvements in safety with laparoscopic rectopexy coupled with the functional advantages of a ventral, nerve-sparing approach has asserted LVMR as the optimal abdominal prolapse repair, bringing the exact role of Delorme's perineal procedure into question (Wijffels et al., 2011). LVMR has a recurrence rate between 3 and 15% (Samaranayake et al., 2010)(D'Hoore, Cadoni & Penninckx, 2004)(Consten et al., 2015) and is a technically far more challenging procedure, especially in patients who have had other pelvic or prolapse surgery, often with mesh, resulting in a potentially difficult dissection. The use of mesh in pelvic surgery has been associated with some catastrophic outcomes (Evans et al., 2015)(Badrek-Al Amoudi, Greenslade & Dixon, 2013), making international news headlines, and resulting in high-profile medicolegal claims against manufacturers. Both units in this study practice LVMR in younger patients in view of its lower recurrence rate and the associated application of a colpopexy where appropriate. However, the mean age of prolapse patients means that for the majority of them an extended longevity of the repair is less of a requirement than these younger patients. Two (13%) of our fifteen deceased patients had a recurrence after 2 and 7 months respectively, with a mean follow-up of 31.5 months.

As acknowledged in a recent Cochrane review, there have been very few adequately designed randomized studies to establish superiority of one procedure over another (Tou, Brown & Nelson, 2015). PROSPER found no obvious difference in recurrence rates between abdominal and perineal approaches but was plagued by a high degree of selection bias. Due to the ability of the treating surgeons to allocate a patient to a particular approach, a great deal of patients were lost to an observational, non-randomized arm and only 49 patients were actually randomized between

The incidence of recurrence after Delorme's procedure for full thickness rectal prolapse - a retrospective private-public cohort study.

abdominal and perineal approaches by the end of the study. In addition, the majority of recruiting centres only recruited less than 10 patients. Long term follow-up results are still pending (Senapati et al., 2013). DeloRes, a multicenter study in Germany and Switzerland comparing laparoscopic resection rectopexy to Delorme's procedure, is still recruiting to meet its 2 x 65 design, assuming a recurrence rate of 20% after 2 years (Rothenhoefer et al., 2012). It seems clear that different approaches and techniques should no longer be judged solely by their reported recurrence rate, but rather considered in conjunction with their patient- and symptom-specific results too.

These data report that nearly 80% of patients are cured of their prolapse after more than 5 years of follow-up. Of the recurrences, half of the patients declined further surgery because they felt still sufficiently improved by their original surgery, so that revision surgery was required in only 10 percent. Previous studies have been limited in methodological quality and size, resulting in a highly variable recurrence rate has been quoted by recent large series in the literature (0-32%) (Madiba TE, Baig MK, 2005). This may be because of small patient numbers, difficulties with follow-up and assessing outcome in an elderly population, and variations in patient selection and severity of prolapse. Results of more recent studies have shown recurrence rates of between 12 and 16 percent, and have shown consistence with previous published experiences in terms of resolution of preoperative evacuatory symptoms and lack of serious complications (Lee et al., 2012)(Lieberth et al., 2009)(Fazeli et al., 2013)(Placer et al., 2015). In a randomized study of 82 patients, a lower recurrence rate of 2 percent was achieved in 41 patients with the addition of a post anal repair and levatorplasty, compared to 14 percent with a traditional Delorme's procedure. Follow-up was limited to only 1 year, however, and 40% of the group was male with a median age of 39 years (Youssef et al., 2012), making a comparison to our own experience difficult. This group's recurrence rate of 23 percent splits the two largest retrospective studies; namely a retrospective study of 101 patients with recurrence rate of 30% (Watts & Thompson, 2000), and another reporting a 13.5 percent recurrence rate in 85 patients (Lechaux, Lechaux & Perez, 1995). In this series, Delorme's procedure resulted in 59 percent of incontinent patients reporting cure and another 31 percent reporting an improvement. Of those with preoperative constipation, 50 percent reported its resolution and another 21 percent reported its improvement. These data are indicative of a good outcome for the two most important measures, bowel function and recurrence. In the four patients under 50, there has been a single recurrence during the period of follow up but our numbers are insufficient to draw any conclusions. Nevertheless, Delorme's procedure offers a high chance of success to a nulliparous young female with no risk to her fertility (Fazeli et al., 2013)(Watts & Thompson, 2000). While rarely reported, there is certainly a risk to fertility after LVMR, especially

The incidence of recurrence after Delorme's procedure for full thickness rectal prolapse - a retrospective private-public cohort study.

if there are intra-abdominal septic or mesh complications. Recurrence after LVMR has been managed with Delorme's procedure and vice versa, demonstrating the wisdom of not adopting a 'one size fits all' approach to posterior compartment prolapse.

There was no statistically significant difference in recurrence rates between the experienced colorectal specialist and the supervised trainees, although there appeared to be a trend in favour of the more experienced single surgeon. Most of the trainees were supervised by the same colorectal specialist managing the private sector cohort and the data demonstrate that trainees under supervision were able to achieve good results without a lengthy and potentially risky learning curve. This is a sharp difference from the learning curve of trainees in LVMR (Mackenzie & Dixon, 2014)(Mercer-Jones et al., 2014). The difference in time to recurrence, although not statistically significant, was longer in the private cohort. This may reflect an inferiority in technique in the supervised operation, thus contradicting the points made in the paragraph above, but the numbers are small and a type II error is possible. No reliable predictor of recurrence was found after repeated scrutiny of these data.

The strengths of this study include the large size of the study group with all consecutive patients over thirteen years included, with no patients lost to follow-up. The use of a comprehensive electronic database for more than half of the patients and a complete set of hospital folders for the remainder resulted in a near complete database of all data points. Potential weaknesses may be difficulties in following up elderly population by telephonic interview only (without clinical confirmation of prolapse recurrence and bowel function), heterogeneity of studied population, variability of length of follow-up.

5. Conclusion

This study demonstrates that Delorme's procedure is a low-risk, technically simple and low cost operation curing nearly 80 percent of rectal prolapse patients and improving symptoms in all. Its value in the management of the predominant group of elderly females is proven and it has been shown to be a valid alternative to abdominal rectopexy that should be discussed with all prolapse patients when counselling them on their operation of choice.

6. References

- Agachan, F., Chen, T., Pfeifer, J., Reissman, P. & Wexner, S.D. 1996. A constipation scoring system to simplify evaluation and management of constipated patients. *Diseases of the Colon and Rectum*. 39(6):681–685. DOI: 10.1007/BF02056950.
- Badrek-Al Amoudi, A.H., Greenslade, G.L. & Dixon, A.R. 2013. How to deal with complications after laparoscopic ventral mesh rectopexy: lessons learnt from a tertiary referral centre. *Colorectal disease : the official journal of the Association of Coloproctology of Great Britain and Ireland*. 15(6):707–12. DOI: 10.1111/codi.12164.
- Binda, G.A. & Serventi, A. 2008. Perineal Approach to External Rectal Prolapse: The Delorme Procedure. In *Rectal Prolapse*. Milano: Springer Milan. 89–95. DOI: 10.1007/978-88-470-0684-3_11.
- Brodén, B. & Snellman, B. 1968. Procidentia of the rectum studied with cineradiography. *Diseases of the Colon & Rectum*. 11(5):330–347. DOI: 10.1007/BF02616986.
- Consten, E.C.J., van Iersel, J.J., Verheijen, P.M., Broeders, I.A.M.J., Wolthuis, A.M. & D'Hoore, A. 2015. Long-term Outcome After Laparoscopic Ventral Mesh Rectopexy. *Annals of Surgery*. 262(5):742–748. DOI: 10.1097/SLA.0000000000001401.
- D'Hoore, a, Cadoni, R. & Penninckx, F. 2004. Long-term outcome of laparoscopic ventral rectopexy for total rectal prolapse. *The British journal of surgery*. 91(11):1500–5. DOI: 10.1002/bjs.4779.
- Delorme, E. 1900. Sur le traitement des prolapsus du rectum totaux par excision de la muqueuse rectale. *Bull Mem Soc Chir Paris*. (26):499–518.
- Devadhar, D.S.C. 1965. A new concept of mechanism and treatment of rectal procidentia. *Diseases of the Colon & Rectum*. 8(1):75–77. DOI: 10.1007/BF02617054.
- Evans, C., Stevenson, A., Sileri, P., Mercer-Jones, M., Dixon, A., Cunningham, C., Jones, O. & Lindsey, I. 2015. A Multicenter Collaboration to Assess the Safety of Laparoscopic Ventral Rectopexy. [Article]. *Diseases of the Colon & Rectum*. 58(8):799–807. DOI: 10.1097/DCR.0000000000000402.
- Fazeli, M.S., Kazemeini, A.R., Keshvari, A. & Keramati, M.R. 2013. Delorme's Procedure: An Effective Treatment for a Full-Thickness Rectal Prolapse in Young Patients. *Annals of coloproctology*. 29(2):60–5. DOI: 10.3393/ac.2013.29.2.60.
- Jacobs, L.K., Lin, Y.J. & Orkin, B.A. 1997. The best operation for rectal prolapse. *The Surgical clinics of North America*. 77:49–70. DOI: 10.1016/S0039-6109(05)70532-6.
- Lechaux, J.P., Lechaux, D. & Perez, M. 1995. Results of Delorme's procedure for rectal prolapse.

The incidence of recurrence after Delorme's procedure for full thickness rectal prolapse - a retrospective private-public cohort study.

Diseases of the Colon & Rectum. 38(3):301–307. DOI: 10.1007/BF02055608.

Lee, S., Kye, B., Kim, H., Cho, H. & Kim, J. 2012. Coloproctology Delorme ' s Procedure for Complete Rectal Prolapse : Does It Still Have It ' s Own Role ? *Coloproctology*. 28(1):13–18.

Lieberth, M., Kondylis, L.A., Reilly, J.C. & Kondylis, P.D. 2009. The Delorme repair for full-thickness rectal prolapse: a retrospective review. *American journal of surgery*. 197(3):418–23. DOI: 10.1016/j.amjsurg.2008.11.012.

Mackenzie, H. & Dixon, A.R. 2014. Proficiency gain curve and predictors of outcome for laparoscopic ventral mesh rectopexy. *Surgery (United States)*. 156(1):158–167. DOI: 10.1016/j.surg.2014.03.008.

Madiba TE, Baig MK, W.S. 2005. Surgical management of rectal prolapse. *ARCH*. 140:63–73. DOI: 10.1007/s10151-011-0747-8.

Madoff, R.D. & Mellgren, A. 1999. One Hundred Years of Rectal Prolapse Surgery. *Diseases of the Colon & Rectum*. 42(4):441–450.

Melton, G.B. & Kwaan, M.R. 2013. Rectal prolapse. *The Surgical clinics of North America*. 93(1):187–98. DOI: 10.1016/j.suc.2012.09.010.

Mercer-Jones, M.A., D'Hoore, A., Dixon, A.R., Lehur, P., Lindsey, I., Mellgren, A. & Stevenson, A.R.L. 2014. Consensus on ventral rectopexy: report of a panel of experts. *Colorectal disease : the official journal of the Association of Coloproctology of Great Britain and Ireland*. 16(2):82–8. DOI: 10.1111/codi.12415.

Placer, C., Enriquez-Navascués, J.M., Timoteo, A., Elorza, G., Borda, N., Gallego, L. & Saralegui, Y. 2015. Delorme's Procedure for Complete Rectal Prolapse: A Study of Recurrence Patterns in the Long Term. *Surgery research and practice*. 2015:920154. DOI: 10.1155/2015/920154.

Rothenhoefer, S., Herrle, F., Herold, A., Joos, A., Bussen, D., Kieser, M., Schiller, P., Klose, C., et al. 2012. DeloRes trial: study protocol for a randomized trial comparing two standardized surgical approaches in rectal prolapse - Delorme's procedure versus resection rectopexy. *Trials*. 13(1):155. DOI: 10.1186/1745-6215-13-155.

Samaranayake, C.B., Luo, C., Plank, A.W., Merrie, A.E.H., Plank, L.D. & Bissett, I.P. 2010. Systematic review on ventral rectopexy for rectal prolapse and intussusception. *Colorectal disease : the official journal of the Association of Coloproctology of Great Britain and Ireland*. 12:504–512. DOI: 10.1111/j.1463-1318.2009.01934.x.

Senapati, a, Gray, R.G., Middleton, L.J., Harding, J., Hills, R.K., Armitage, N.C.M., Buckley, L. & Northover, J.M. a. 2013. PROSPER: a randomised comparison of surgical treatments for rectal prolapse. *Colorectal disease : the official journal of the Association of Coloproctology of Great Britain and Ireland*. 15(7):858–68. DOI: 10.1111/codi.12177.

The incidence of recurrence after Delorme's procedure for full thickness rectal prolapse - a retrospective private-public cohort study.

Tou, S., Brown, S.R. & Nelson, R.L. 2015. Surgery for complete (full-thickness) rectal prolapse in adults. In *Cochrane Database of Systematic Reviews*. S. Tou, Ed. Chichester, UK: John Wiley & Sons, Ltd. DOI: 10.1002/14651858.CD001758.pub3.

Watts, a M. & Thompson, M.R. 2000. Evaluation of Delorme's procedure as a treatment for full-thickness rectal prolapse. *The British journal of surgery*. 87(2):218–22. DOI: 10.1046/j.1365-2168.2000.01342.x.

Wijffels, N., Cunningham, C., Dixon, A., Greenslade, G. & Lindsey, I. 2011. Laparoscopic ventral rectopexy for external rectal prolapse is safe and effective in the elderly. Does this make perineal procedures obsolete? *Colorectal Disease*. 13(5):561–566. DOI: 10.1111/j.1463-1318.2010.02242.x.

Wijffels, N.A., Collinson, R., Cunningham, C. & Lindsey, I. 2010. What is the natural history of internal rectal prolapse? *Colorectal disease : the official journal of the Association of Coloproctology of Great Britain and Ireland*. 12(8):822–30. DOI: 10.1111/j.1463-1318.2009.01891.x.

Youssef, M., Thabet, W., El Nakeeb, A., Magdy, A., Abd Alla, E., Abd El Nabeey, M., Yamani Fouda, E., Omar, W., et al. 2012. Comparative study between Delorme operation with or without postanal repair and levateroplasty in treatment of complete rectal prolapse. DOI: 10.1016/j.ijisu.2012.11.011.

The incidence of recurrence after Delorme's procedure for full thickness rectal prolapse - a retrospective private-public cohort study.

7. Appendix



UNIVERSITY OF CAPE TOWN

Department of Surgery

Departmental Research Committee

Professor Anwar Suleman Mall

J-45 Room Old Main Building, Groote Schuur Hospital,
Observatory 7925, South Africa

Tel (021) 406 6168/6232/6227 FAX (021) 448 6461

Email: Anwar.Mall@uct.ac.za

26th August 2013

Dr Jeremy Plaskett
Department of Surgery
Division of General Surgery
Groote Schuur Hospital
University of Cape Town

Dear Dr Plaskett,

RE: PROJECT 2013/097

PROJECT TITLE: The incidence of recurrence after Delormes procedure for full thickness rectal prolapse- a retrospective multicentre cohort study conducted in public and private sectors in Cape Town

The above proposal was reviewed by the Department of Surgery Research Committee and I am pleased to inform you that the committee approved the study.

Please use the above project number in all future correspondence.

Yours sincerely

A grey rectangular box containing the word "Signed" in a large, stylized, black font.

**PROFESSOR ANWAR S MALL
CHAIRMAN: RESEARCH COMMITTEE**

"OUR MISSION is to be an outstanding teaching and research university,
educating for life and addressing the challenges facing our society."

The incidence of recurrence after Delorme's procedure for full thickness rectal prolapse - a retrospective private-public cohort study.



UNIVERSITY OF CAPE TOWN
Faculty of Health Sciences
Human Research Ethics Committee



Room E52-24 Old Main Building
Groote Schuur Hospital
Observatory 7925
Telephone [021] 406 6492 • Facsimile [021] 406 6411
Email: Sumayah.ariel@uct.ac.za
Website: www.health.uct.ac.za/research/humanethics/forms

14 November 2013

HREC/REF: 686/2013

Dr J Plaskett
Colorectal Surgery
J-floor
OMB

Dear Dr Plasket

Project Title: THE INCIDENCE OF RECURRENCE AFTER DELORME'S PROCEDURE FOR FULL-THICKNESS RECTAL PROLAPSE- A RETROSPECTIVE PRIVATE/PUBLIC COHORT STUDY

Thank you for your letter dated 11 November 2013, addressing the issues raised by the Human Research Ethics Committee.

It is a pleasure to inform you that the HREC has **formally approved** the above mentioned study.

Approval is granted for one year until the 30 November 2014.


Please submit a progress form, using the standardised Annual Report Form, if the study continues beyond the approval period. Please submit a Standard Closure form if the study is completed within the approval period.

Please note that the on-going ethical conduct of the study remains the responsibility of the principal investigator

Please quote the HREC REF in all your correspondence.

Yours sincerely

Signed

 PROFESSOR M BLOCKMAN
CHAIRPERSON, HSF HUMAN ETHICS

Federal Wide Assurance Number: FWA00001637.

Institutional Review Board (IRB) number: IRB00001938

Hrec/ref:686/2013

The incidence of recurrence after Delorme's procedure for full thickness rectal prolapse - a retrospective private-public cohort study.

Pro-forma for retrospective review of patient folder/database

NAME:

DOB:

ADDRESS:

TEL:

PREOPERATIVE:

1. Sex:
2. Race:
3. Gravidity: *Number of children (any difficulties with deliveries - tears, large baby, episiotomy etc)*
4. Smoker: *this will be in clinical notes (social history) and anaesthetic notes*
5. BMI: *if mention of being overweight or ++BMI in notes anywhere*
6. Comorbidities (past medical hx): *all other illnesses being treated (will be in clinical notes and anaesthetic preop notes)*
7. Associated pelvic floor defects: *any mention of uterine prolapse or bladder problems / cystocele etc (might be in gynae or urology notes)*
8. Previous surgery (for rectal prolapse): *all previous operations, particularly gynae or bladder or prolapse surgery*
9. ASA score (I, II, III): *from anaesthetic notes (preop and intraop)*
10. Symptoms (constipation or faecal incontinence or pr bleeding): *any long history of constipation or incontinence to gas/liquid/solid stool. does the prolapse occur only during defecation or all the time? does it reduce spontaneously or must the patient manually reduce it?*
11. Duration of symptoms (number of prolapses) before surgery (primary or secondary operation): *how long have they had constipation/incontinence/prolapse*
12. Degree of rectal prolapse: *length measurement or size (apple, grapefruit etc)*
13. Ba-enema or colonoscopy findings: *will be done before operation or in the operation (sigmoidoscopy)*

OPERATIVE:

1. Date:
2. Type of anaesthetic (general or regional/spinal): *will be one of these two only (anaesthetic intraop record)*
3. Position: *will be lithotomy or prone jack-knife (anaesthetic note and operation note)*
4. Duration of procedure: *number of hours from anaesthetic record*
5. Length of mucosal resection: *this might be recorded in the operation note*
6. Procedural blood loss: *was a blood transfusion required in operation*
7. Intraoperative difficulties/complications: *from operation note or anaesthetic record*
8. Additions to basic Delorme's procedure (sphincteroplasty): *ignore this*

POSTOPERATIVE:

1. Length of stay (ICU/ventilation): *day-by-day record in clinical notes until discharge. was the patient in ICU?*
2. Transfusion requirements: *was there a blood transfusion after surgery?*
3. Complications (major or minor): *such as bleeding, pneumonia, urinary tract infection, myocardial infarction, stroke etc (in postop clinical notes)*
4. Recurrence (full-thickness/mucosal) (second operation): *while in hospital after operation*

The incidence of recurrence after Delorme's procedure for full thickness rectal prolapse - a retrospective private-public cohort study.

5. Mortality (30-day): *while in hospital after operation*

FOLLOW-UP:

1. Living or deceased (if deceased, postoperative survival length):
2. Period and frequency: *dates of follow up*
3. Complications (within 30 days OR 3 months of initial surgery): *any complications at follow up?*
4. Resolution/recurrence of symptoms (constipation or faecal incontinence & grade): *has the prolapse recurred or is it completely better? is there still constipation (better or worse)? is there still faecal incontinence (better or worse)?*
5. Recurrence (time to recurrence): *has the prolapse recurred (when? how bad? what symptoms? - like above)*

Reoperation: *was another operation done? - if so, record same information for 2nd/3rd operation as above*