



## CLINICAL IMAGES

## Protean appearance and behaviour of liver hydatids

Richard Pitcher

A 12-year-old boy was first seen in May 2003 for a tympanoplasty, when a peri-operative chest radiograph showed a calcified granuloma in the right lung (Figs 1a and 1b), but no other abnormality.

In September 2003 he was seen again, referred by his rural general practitioner, with a 3-week history of right upper quadrant pain, fever, anorexia and weight loss. He had had a non-productive cough for a week, was pyrexial (37.8°C) and tachypnoeic, with dullness to percussion and decreased breath sounds at the right pulmonary base. He had marked right upper quadrant abdominal tenderness with guarding and a 3 cm hepar, but was not jaundiced. His white cell count was  $14.9 \times 10^9/\text{ml}$  and his erythrocyte sedimentation rate (ESR) 140 mm/hour. Chest radiography revealed a markedly elevated right hemidiaphragm, with loss of clarity in its mid-portion and some right fissural thickening (Figs 2a and 2b). An ultrasound examination showed three mixed echogenicity liver lesions interpreted as abscesses (Fig. 3). One was located in the left lobe (6 cm diameter), and two were in the right lobe, measuring approximately 8 cm and 10 cm in diameter respectively. The abscess in segments 7 - 8 showed transdiaphragmatic rupture into the right pleural space (Fig. 4). During respiratory excursion, ultrasound showed abscess contents moving across this defect. A contrast-enhanced computed tomography (CT) scan of the liver (Figs 5a and 5b) showed thick fluid and septations in the lesion in segments 7 - 8, while homogeneous thick fluid was demonstrated in the other two. The presence of septations in one of the cysts raised the possibility of complicated hydatid disease.

At surgery infected hydatids were found at all three sites and diaphragmatic rupture was confirmed (3 cm diameter defect). Five hundred millilitres of pus was drained from the right pleural space, from which *Staphylococcus aureus* was cultured. An uneventful postoperative recovery was made.

### Comment

The difficulty distinguishing amoebic from pyogenic liver abscesses on ultrasound criteria is well recognised.<sup>12</sup> However,

complicated hydatid disease can also mimic liver abscesses and solid liver tumours.

The protean ultrasound appearance of hepatic hydatid was documented more than 20 years ago.<sup>3</sup> Five different appearances result from the pathophysiology of cyst formation

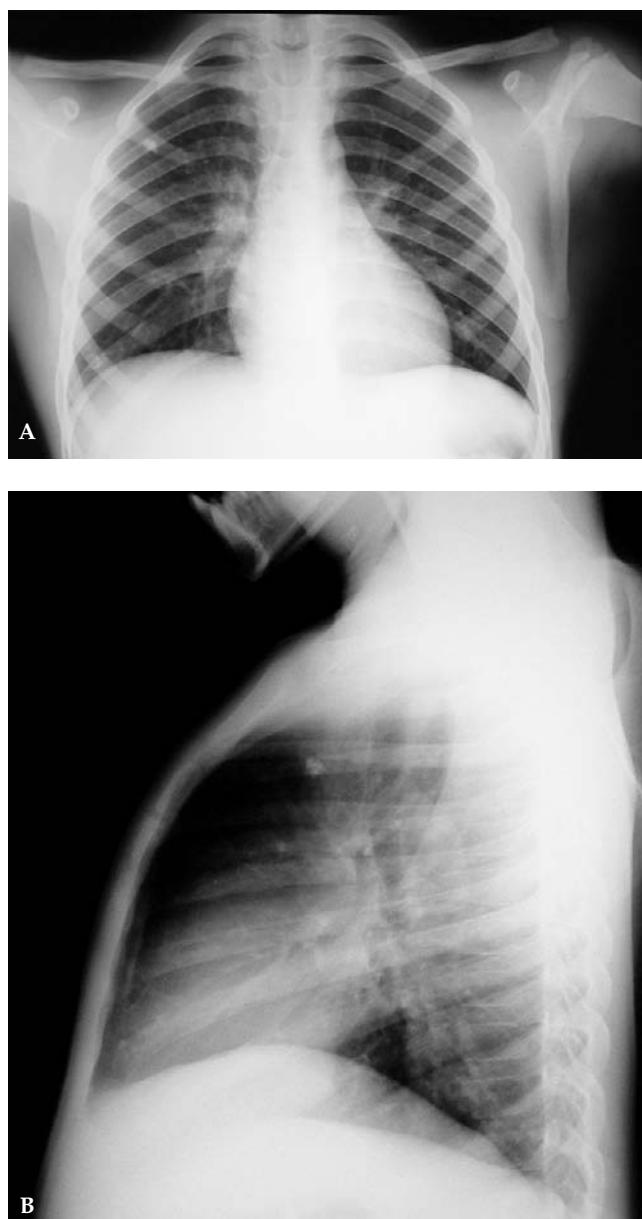


Fig. 1. Anteroposterior (A) and lateral (B) chest radiographs in May 2003, showing an isolated calcified granuloma in the right upper lobe, but no other abnormality.

*Richard Pitcher spent 10 years in solo private radiological practice on the Cape West Coast, returning to the public sector in 2001 to assume his current position as head of paediatric radiology at Red Cross War Memorial Children's Hospital in Cape Town. He has a particular interest in the role of ultrasound in sustainable health care delivery in developing countries.*

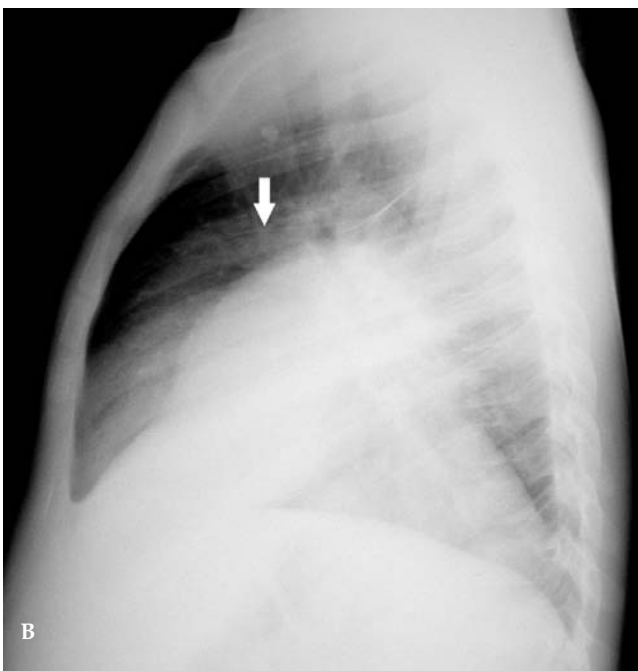
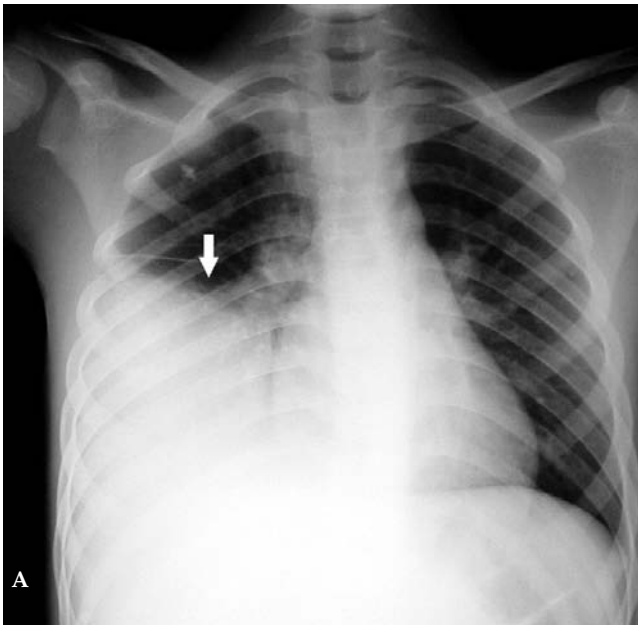


Fig. 2. Anteroposterior (A) and lateral (B) chest radiographs in September 2003, showing marked elevation of the right hemidiaphragm (arrow), with right-sided fissural thickening indicating an associated right-sided pleural effusion.

and degeneration.<sup>4</sup> The hydatid consists of three layers. The inner germinal layer, a single cell in thickness, is the true wall of the cyst and represents the viable parasite. It is responsible for formation of the cyst fluid and its own protective covering, the acellular laminated membrane, which ultimately forms the middle layer. The outer layer or pericyst is composed of host tissue collagenous response to the parasite. The germinal layer

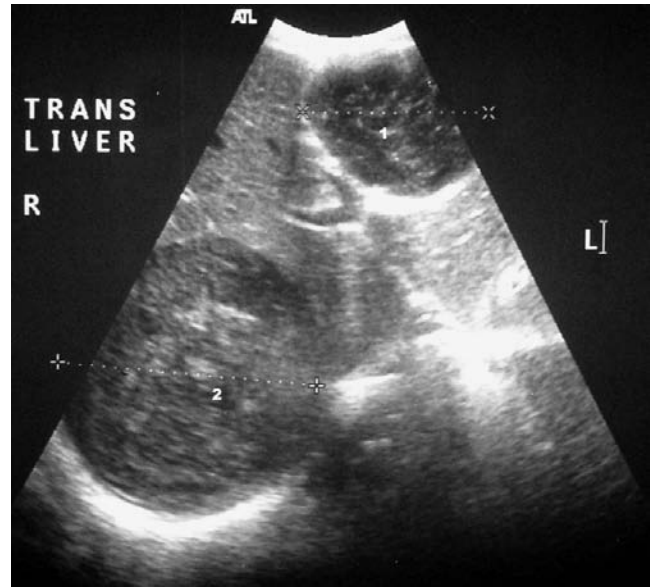

Fig. 3. Axial ultrasound scan of the liver demonstrating two mixed echogenicity lesions in the liver involving segments 3 and 4B of the left lobe (1) and segments 5 and 6 of the right lobe (2), interpreted as abscesses.

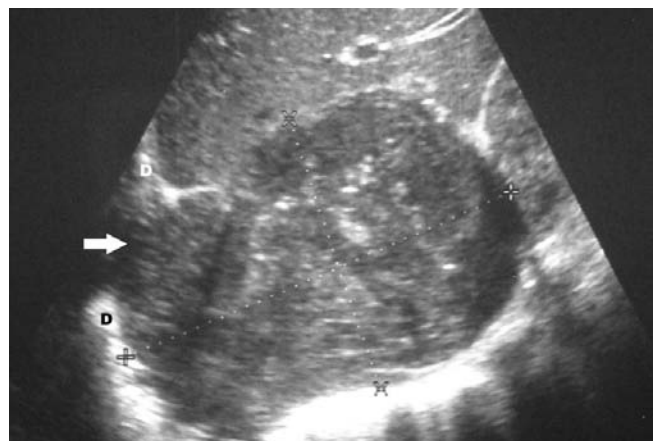


Fig. 4. Sagittal ultrasound scan of the right lobe of liver demonstrating a mixed echogenicity mass in segments 7 and 8, with an associated defect (arrow) in the right hemidiaphragm (D).

is avascular and nourished by a poorly understood mechanism of nutrient transfer across the laminated membrane and pericyst. Interruption to this nutrient supply may disrupt cyst integrity, manifest initially by breach in its inner layers, hence the classification of ultrasound findings (Fig. 6).

**Type I.** The cyst contains clear fluid and possibly a little dependent, bright sediment, the latter representing scolices referred to as 'hydatid sand'. This appearance implies a healthy cyst, with all three layers intact and closely applied. In this phase, the hydatid can mimic a simple liver cyst and grows at approximately 2 cm per annum.

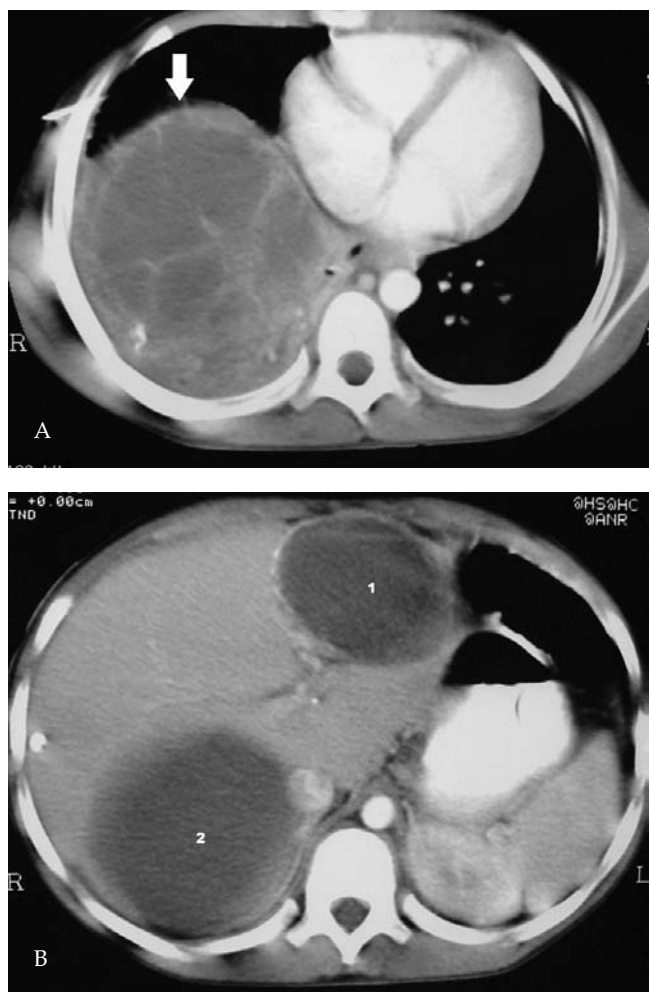


Fig. 5. A: Axial, contrast-enhanced CT scan of the liver demonstrating a large septated, cystic mass in segments 7 and 8 (arrow). B: Axial, contrast-enhanced CT scan of the liver, demonstrating homogeneous fluid in abscesses in segment 3 and 4B of the left lobe (1) and segment 5 and 6 of the right lobe (2).

**Type II.** There is a breach in the germinal layer and laminated membrane, which become separated from the intact pericyst. This is known as contained rupture. The detached membranes are seen to float in the clear cyst fluid constituting the ultrasound 'water-lily' sign which is characteristic and diagnostic of hydatid disease.

**Type III.** Scolices give rise to daughter cysts, the formation of which is interpreted as an attempt at self-preservation in the face of a threat to the parent cyst. These may expand to fill the parent cyst, forming a characteristic honeycomb pattern, typical of hydatid.

**Type IV.** This stage implies further degeneration of the inner two cyst membranes, as in the present case. Degradation products join scolices to form the so-called hydatid matrix, an amber, gelatinous substance that replaces the clear cyst fluid. On ultrasound examination, the matrix has diffuse internal echoes. This can mimic either a liver abscess or a solid lesion.

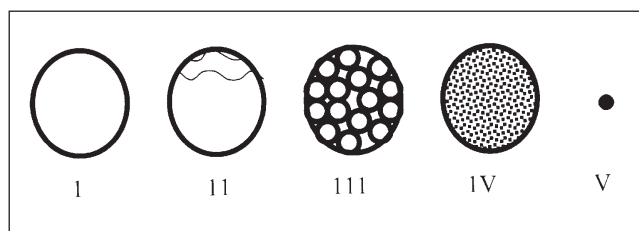


Fig. 6. Gharbi classification of the ultrasound appearances of liver hydatids.

The clinical context is important as the matrix in a sterile cyst has the same ultrasound appearance as the contents of an infected cyst.

**Type V.** Calcification of all layers of the cyst, which is the only stage where one can be certain of non-viability of the parasite.

Symptomatic hydatids are generally complicated, either by so-called communicating rupture (intrahepatic), direct rupture (intrahepatic, intrathoracic, intravisceral) or secondary infection, which occurs only after disruption of the pericyst.

Hepatic hydatid disease in adults has a 15% overall complication rate, with intrahepatic rupture in 10%, intrahepatic rupture and secondary infection each in 2% of cases, while transdiaphragmatic rupture occurs in only 1% of patients.<sup>5</sup> Hydatids share the potential for transdiaphragmatic rupture with other liver abscesses, typically amoebic, where complications have been documented in 15% of cases<sup>6</sup> but rarely with pyogenic liver abscesses.<sup>7</sup> The use of multiple imaging modalities generally increases diagnostic specificity, as reflected in our case. It has been shown that 87% of transdiaphragmatic ruptures of hepatic hydatids were correctly diagnosed pre-operatively using plain radiography and ultrasound.<sup>8</sup>

Ultrasound imaging has the potential to make a significant and sustained impact on health care delivery in Africa. Machines are relatively affordable, portable, require low maintenance, utilise no ionising radiation and a broad spectrum of medical personnel can be trained in their use.

- Oleszczuk-Raszke K, Cremin BJ, Fisher RM, Moore SW, Millar AJ. Ultrasonic features of pyogenic and amoebic hepatic abscesses. *Pediatr Radiol* 1989; 19: 230-233.
- Ahsan T, Jehangir MU, Mahmood T, et al. Amoebic versus pyogenic liver abscess. *Journal of the Pakistan Medical Association* 2002; 52: 497-501.
- Gharbi HA, Hassine W, Brauner MW, Dupuch K. Ultrasound examination of the hydatid liver. *Radiology* 1981; 139: 459-463.
- Lewall DB. Review: Hydatid disease: Biology, pathology, imaging and classification. *Clin Radiol* 1998; 53: 863-874.
- Erguney S, Tortum O, Taspinar AH, Ertem M, Gaziolu E. Complicated hydatid cysts of the liver. *Ann Chir* 1991; 45: 584-589.
- Meng XY, Wu JX. Perforated amoebic liver abscess: clinical analysis of 110 cases. *South Med J* 1994; 87: 985-990.
- Savinel E, Hazard C, Florin M, Degrave N, Delbar M. A case of pyogenic liver abscess complicated by rupture into the right pleural cavity. *Lille Medical* 1980; 25(1-2):18-21.
- Kabiri EH, El Maslout A, Benosman A. Thoracic rupture of hepatic hydatidosis (123 cases). *Ann Thorac Surg* 2001; 72: 1883-1886.