

The eye in systemic disease

M Lenake MBChB, FCOphth(SA) & N Du Toit MBChB, DipOphth(SA), FRCS(Ed), FCOphth(SA), MMed

To cite this article: M Lenake MBChB, FCOphth(SA) & N Du Toit MBChB, DipOphth(SA), FRCS(Ed), FCOphth(SA), MMed (2014) The eye in systemic disease, South African Family Practice, 56:1, 8-14, DOI: [10.1080/20786204.2014.10844577](https://doi.org/10.1080/20786204.2014.10844577)

To link to this article: <http://dx.doi.org/10.1080/20786204.2014.10844577>



© 2014 SAAFP. Published by Medpharm.



Published online: 27 May 2014.



Submit your article to this journal [↗](#)



Article views: 102



View related articles [↗](#)



View Crossmark data [↗](#)

The eye in systemic disease

Lenake M, MBChB, FCOphth(SA), Senior Registrar

Du Toit N, MBChB, DipOphth(SA), FRCS(Ed), FCOphth(SA), MMed, Senior Lecturer
University of Cape Town; Groote Schuur Hospital, Cape Town

Correspondence to: Nagib du Toit, e-mail: nagib.dutoit@uct.ac.za

Keywords: systemic disease, diabetic retinopathy, herpes zoster ophthalmicus, thyroid ophthalmopathy, drugs and the eye

Abstract

The eye is a unique organ which is often involved in systemic disease. Patients with systemic disease may first present with eye pathology, and patients with known systemic illnesses may need to have their eyes specifically checked for ocular complications. It is thus useful for the physician to be familiar with the ocular manifestations of common systemic diseases at primary care level. Diseases like diabetes, herpes zoster ophthalmicus and thyroid ophthalmopathy often involve the eyes, and if the eye signs are not identified early, the visual consequences can be devastating. Diabetic retinopathy is an important cause of blindness in this country. These, as well as common ocular manifestations of human immunodeficiency virus/acquired immune deficiency syndrome, syphilis, some dermatological conditions and the ocular side-effects of certain drugs, are discussed in this article. It is important for the primary care physician to be familiar with the spectrum of ocular involvement in systemic diseases since appropriate intervention and referral can be sight saving for the patient.

© Peer reviewed. (Submitted: 2013-04-24. Accepted: 2013-07-24). © SAAFP

S Afr Fam Pract 2014;56(1):8-14

Introduction

The eye is a unique organ comprising many different types of tissue. It is often involved in systemic disease. Patients with systemic disease may first present with eye pathology, and patients with known systemic illnesses may need to have their eyes specifically checked for ocular complications. It is thus useful for the physician to be familiar with the ocular manifestations of systemic diseases at primary care level. The need for an update in this field became apparent after a recent study on the primary health eye care knowledge of general practitioners.¹ This article is the fourth in a series which attempts to address this issue.

Approach to the patient

Knowledge of possible eye complications of common systemic diseases will dictate the direction which the eye assessment should take, and the part of the eye on which the examination should focus. Conversely, being familiar with the presenting eye symptoms of certain systemic diseases will facilitate diagnosis, possibly at an earlier stage than would otherwise occur. The diseases to be covered in this article and their ocular manifestations are listed in Table I.

Certain potentially life-threatening systemic illnesses have eye signs which may manifest before other common findings. The more common ones are listed in Table II.

Many systemic drugs cause ocular side-effects, while some ocular drugs have systemic side-effects. Familiarity with

these can prevent unnecessary complications (Table III). This list is not exhaustive.

Clinical conditions

Diabetes

Diabetic retinopathy

Diabetic retinopathy is the cause of blindness in approximately 2.5-million of the estimated 50-million blind people in the world. The vision 2020 protocol projects diabetic retinopathy and glaucoma to be the "emerging" causes of blindness in developing countries. Loss of vision in diabetes is most commonly caused by cataracts, vitreous haemorrhage, maculopathy, tractional retinal detachment or neovascular glaucoma.³

Risk factors for the development of diabetic retinopathy include:⁴

- *The duration of diabetes:* The most important factor. Duration of disease is the strongest predictor of proliferative diabetic retinopathy.
- *Poor control of diabetes:* Tight blood glucose control, particularly when instituted early, can prevent or delay development of, or progression to, diabetic retinopathy.
- *Pregnancy:* Sometimes associated with rapid progression of diabetic retinopathy. Predicating factors include greater pre-pregnancy severity of retinopathy, poor pre-pregnancy control of diabetes, control exerted too rapidly during the early stages of pregnancy, and the development of pre-eclampsia and fluid imbalance.

Table I: The more common systemic diseases with ocular involvement

Disease	More common ocular manifestations
Diabetes	Retinopathy, and third and sixth nerve palsies
HIV/AIDS	Herpes zoster ophthalmicus, microangiopathy, CMV retinitis, squamous cell carcinoma of conjunctiva and cranial nerve palsies
Thyroid eye disease	Proptosis, optic neuropathy, lid retraction, restrictive myopathies and soft tissue swelling
Syphilis	Uveitis, chorioretinitis and optic atrophy
Rheumatoid arthritis, SLE and other collagen vascular diseases	Scleritis, episcleritis and keratitis
Ankylosing spondylitis, psoriasis and other seronegative spondyloarthropathies	Uveitis
Eczema	Keratoconjunctivitis, cataracts and keratoconus

AIDS: acquired immune deficiency syndrome, CMV: cytomegalovirus, HIV: human immunodeficiency virus, SLE: systemic lupus erythematosus

- **Hypertension:** Tight control (blood pressure < 140/80 mmHg) is particularly beneficial in patients with type 2 diabetes with maculopathy.
- **Nephropathy:** If severe, is associated with worsening of diabetic retinopathy.

Screening for retinopathy in patients with diabetes should take place at puberty in type 1 (juvenile onset) as diabetic retinopathy rarely occurs before then, and at diagnosis for type 2 (adult onset). Fundoscopy (after pupil dilation) should be performed to detect microaneurysms, retinal haemorrhages (blot or flame-shaped), hard exudates, cotton wool spots, changes in the calibre of the retinal veins and new vessel formation. The classification of retinopathy and primary care management is illustrated in Figure 1, while some of the clinical findings can be visualised in Figures 2, 3 and 4.

The treatment of diabetic retinopathy requires a multidisciplinary approach. Good glycaemic control should be emphasised. Laser photocoagulation is applied to oedematous areas in diabetic maculopathy (to stop blood vessel leakage), and to ischaemic areas in proliferative diabetic retinopathy, in order to decrease the oxygen demand of the hypoxic retina because of thermal damage to it (Figure 5). Complications of proliferative changes include vitreous haemorrhage (Figure 6) from the friable new vessels on the retina or disc, and neovascular glaucoma from the new vessels on the iris growing into the angle and tractional retinal detachment. Retinal surgery is required for nonresolving vitreous haemorrhage and advanced proliferative retinopathy, e.g. traction threatening the macula (Figure 7).⁵ New adjunctive therapies in the management of diabetic retinopathy, especially maculopathy, include steroid and anti-vascular endothelial growth factor agents, both

Table II: Systemic diseases, where eye findings may help in making the diagnosis²

Disease	Ocular presentation
Myasthenia gravis	Ptosis and diplopia
Hyperlipidaemia	Xanthelasma, arcus cornealis and presenile cataract
Marfan's syndrome	Myopia, dislocated lens and retinal detachment
Haematological disease, e.g. anaemia	Retinal haemorrhages, Roth spots and cotton wool spots
Leukaemia and lymphoma	Uveitis, retinitis, optic nerve infiltration and orbital disease
Malignant hypertension	Disc swelling, retinal haemorrhages, hard exudates and cotton wool spots
Albinism	Myopia, astigmatism and nystagmus
Neurofibromatosis (type 1)	Eyelid neurofibromas and Lisch nodules on the iris
von Hippel-Lindau disease	Retinal capillary haemangioma

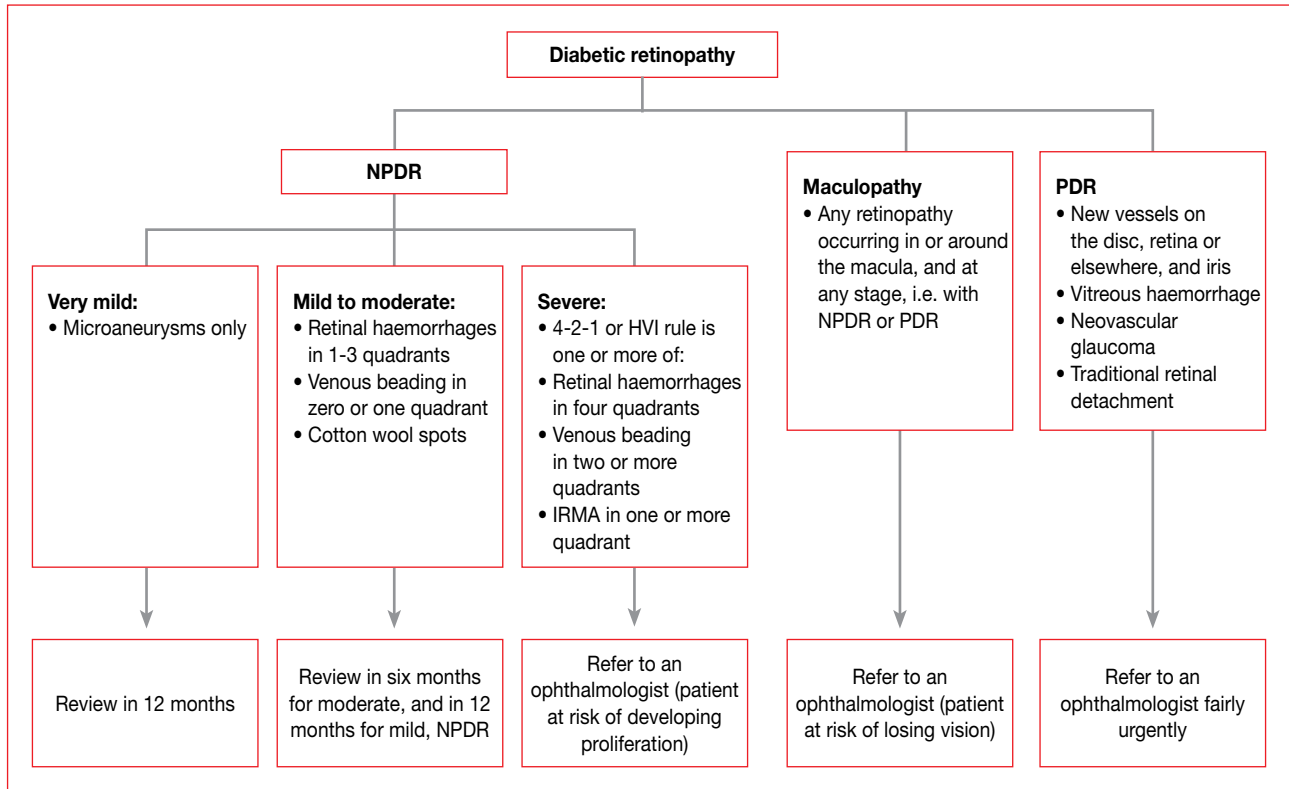
Table III: Drugs and the eye²

Systemic drugs	Ocular side-effects
Corticosteroids	Cataracts, glaucoma, and worsening of herpetic keratitis
Ethambutol, isoniazid and streptomycin (anti-tuberculosis)	Toxic optic neuropathy, with loss of central and colour vision
Chloroquine	Maculopathy, with loss of vision
Adrenaline and pseudoephedrine (in cold remedies), anticholinergics, antihistamines and atropine	Acute-angle closure glaucoma in susceptible individuals
Amiodarone	Vortex keratopathy (innocuous corneal deposits)
Digoxin	Xanthopsia (yellow vision)
Cidofovir and rifabutin (for HIV)	Uveitis
Ocular drugs	Systemic side-effects
Beta blockers (drops)	Fatigue and impotence. Generally contraindicated in patients with asthma, heart block and peripheral vascular disease
Acetazolamide (Diamox® tablets)	Lassitude, paraesthesiae, dyspepsia, renal stones and impotence
Alpha agonists (drops)	Drowsiness, and apnoea (in neonates)

HIV: human immunodeficiency virus

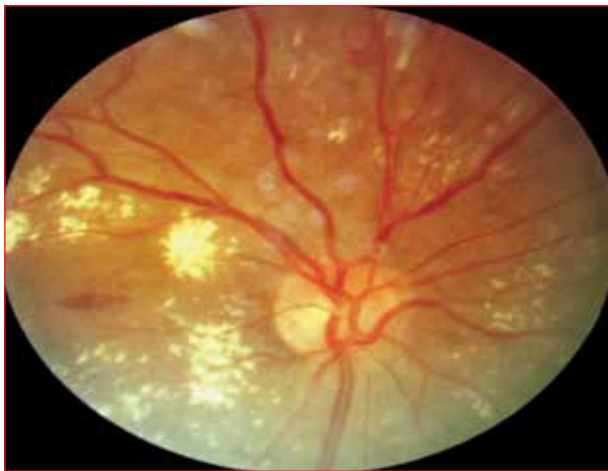
injected into the vitreous cavity. These agents target the inflammatory and neovascular pathways that are involved in the formation of macular oedema and neovascularisation.

Patients with diabetes are also at increased risk of other complications occurring elsewhere, but manifesting with ocular symptoms. Cranial nerve palsies may occur in patients with diabetes. Oculomotor (third) nerve palsy is the most common. It is the result of a microvasculopathy which involves the inner nerve fibres and spares the outer pupillary fibres. If it is complete and the pupil is spared, the patient



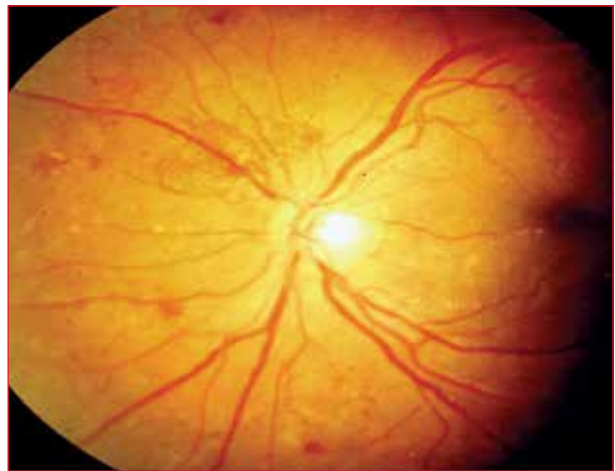
HVI: haemorrhages, venous beading; IRMA: intraretinal microvascular abnormalities; NPDR: nonproliferative retinopathy; PDR: proliferative retinopathy

Figure 1: Classification of diabetic retinopathy



Source: Division of Ophthalmology, University of Cape Town

Figure 2: Severe nonproliferative retinopathy



Source: Division of Ophthalmology, University of Cape Town

Figure 3: Proliferative diabetic retinopathy with new vessels on the retina or elsewhere

should be followed-up regularly for 6-12 weeks, while watching for resolution. If the pupil is involved, compression by an aneurysm or tumour is most likely, and urgent referral for neuroimaging and evaluation by a neurosurgeon is indicated.

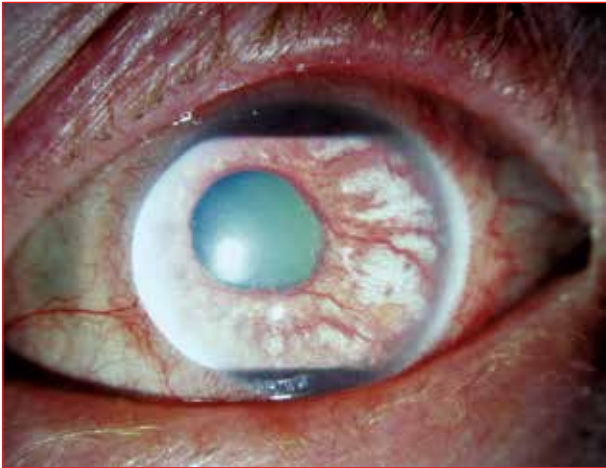Mucormycosis is a rare opportunistic infection caused by fungi which typically affects patients with diabetic ketoacidosis, and is aggressive and often fatal. It involves the sinuses and subsequently spreads to the orbit and brain. These patients require aggressive in-hospital management.

Human immunodeficiency virus

Herpes zoster ophthalmicus

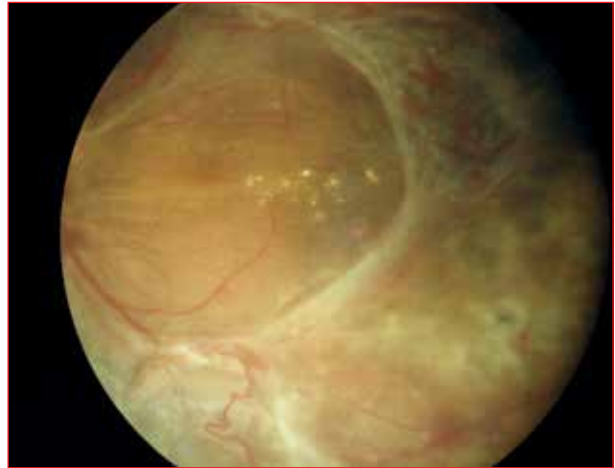The varicella zoster virus causes both chicken pox and herpes zoster (shingles). Mechanisms of ocular infection include:

- Direct viral invasion, which may lead to conjunctivitis and epithelial keratitis.
- Secondary inflammation, which may cause episcleritis, scleritis, keratitis, uveitis, optic neuritis and cranial nerve palsies. Inflammation of the eyelid skin and conjunctiva can heal with severe scarring, resulting in a dry ocular surface.



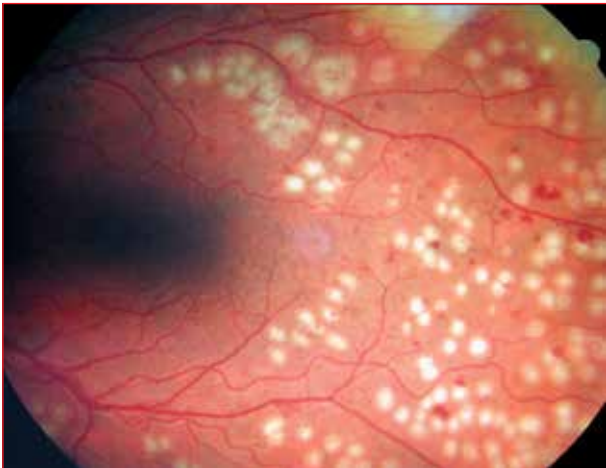Source: Division of Ophthalmology, University of Cape Town

Figure 4: New vessels on the iris



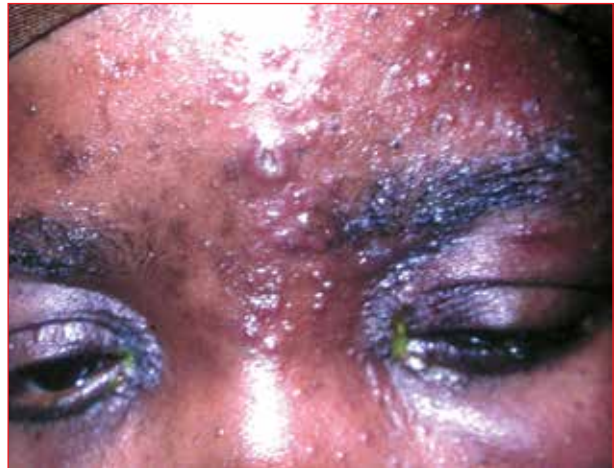Source: Division of Ophthalmology, University of Cape Town

Figure 7: Tractional complex causing striae over the macula



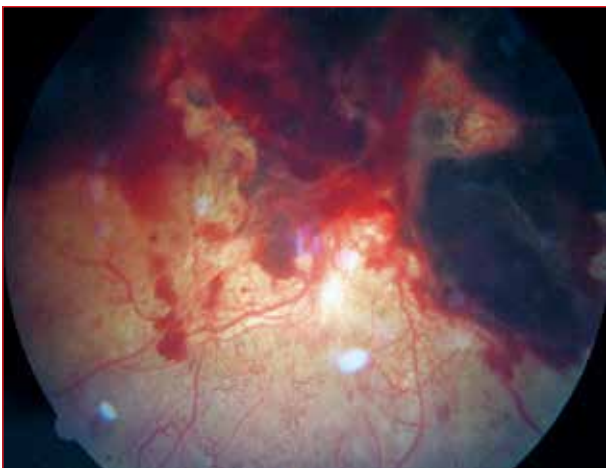
Source: Division of Ophthalmology, University of Cape Town

Figure 5: "Fresh" laser burns to the retina



Source: Division of Ophthalmology, University of Cape Town

Figure 8: Vesicles and pustules in herpes zoster ophthalmicus



Source: Division of Ophthalmology, University of Cape Town

Figure 6: New vessels on the retina or elsewhere with subhyaloid vitreous haemorrhage

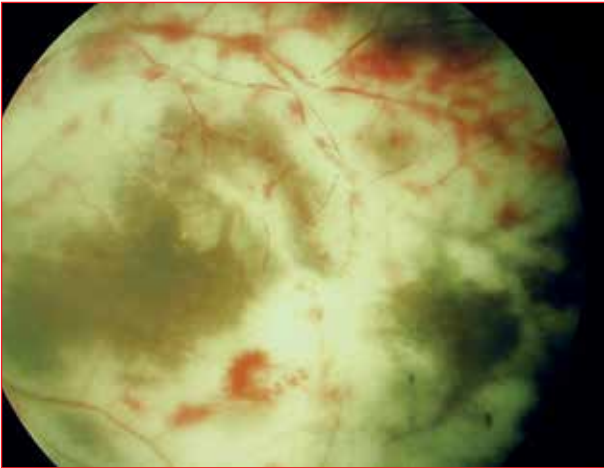- Reactivation, causing inflammation in the affected nerve, and resulting in corneal anaesthesia and neurotrophic keratitis.

The risk of ocular involvement is increased in human immunodeficiency virus (HIV) infection, and also when there

is involvement of the skin supplied by the external nasal nerve, a branch of the nasociliary nerve which supplies the tip, side and root of the nose. This is referred to as a positive Hutchinson's sign, and correlates strongly with ocular involvement and increasing age. It occurs most frequently in the sixth and seventh decades of life. Signs and symptoms are often more severe in the elderly. Herpes zoster ophthalmicus tends to be more severe in patients with HIV. It can also be an early indicator of HIV infection.^{4,6}

A prodromal phase, lasting 3-5 days, precedes the appearance of the rash. It is characterised by malaise, fever and headaches. Some patients may experience burning or tingling in the affected dermatome. The rash is initially erythematous. Groups of vesicles develop within 24 hours, and become confluent over 2-4 days. Vesicles become pustular (Figure 8) before drying after 2-3 weeks.

Treatment includes antiviral therapy with oral acyclovir 800 mg five times daily for 7-10 days. This should be started when the patient first presents. This reduces the severity of the acute episode and the risk of post-herpetic neuralgia. Adequate analgesia should be prescribed to target the neurogenic pain. Amitriptylline or a similar agent should be



Source: Division of Ophthalmology, University of Cape Town

Figure 9: Necrotic retina with vasculitis due to cytomegalovirus retinitis

used. Skin lesions should be treated with cool compresses and mechanical cleansing. Potassium permanganate dries the lesions well. Blepharitis or conjunctivitis can be treated with topical lubrication.⁷ Patients with shingles can transmit chickenpox. Therefore, contact with persons who are not immune, and those with immunodeficiency should be avoided until crusting of the lesions is complete.⁸

All patients with acute herpes zoster ophthalmicus and ocular involvement should be referred for ophthalmic evaluation.

Human immunodeficiency virus microangiopathy

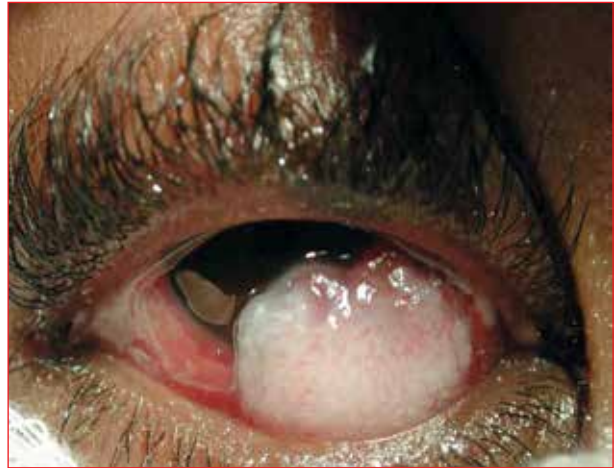This is the most common fundus finding, and is found in more than half of patients with acquired immune deficiency syndrome (AIDS). It is characterised by cotton wool spots, retinal haemorrhages and capillary abnormalities. It is asymptomatic and temporary.²

Cytomegalovirus retinitis

Cytomegalovirus retinitis is a common ocular opportunistic infection in patients with AIDS. It occurs in patients with very low CD4 T-cell counts (below 50/mm³). Its incidence and rate of progression has declined since the advent of antiretroviral therapy. There are two types of retinitis. The indolent form affects the retinal periphery and progresses slowly. The fulminant type is characterised by a necrotising retinitis, accompanied by a vasculitis, giving a classic "pizza pie" appearance (Figure 9). It is treated with weekly injections of gancyclovir until the retinitis has regressed. Vision will not improve if the optic nerve or fovea is involved. Therefore, early referral within a week is advised.²

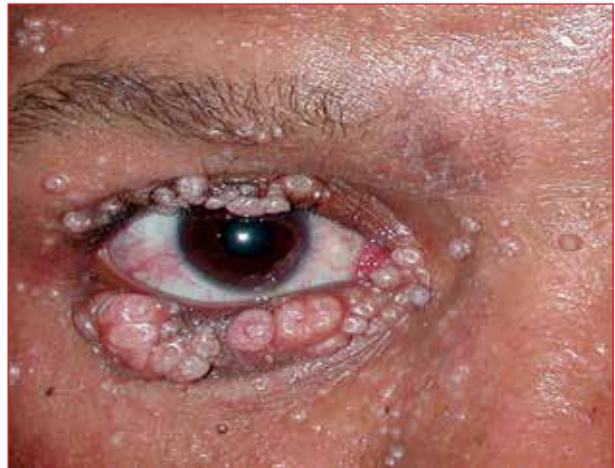Ocular tumours

Ocular surface squamous neoplasia is a spectrum of benign, premalignant and malignant epithelial lesions of the conjunctiva and cornea. These lesions tend to be unilateral and resemble an atypical pterygium, which grows rapidly, becomes very raised (Figure 10) and keratinised. Besides HIV infection, some other risk factors for development



Source: Division of Ophthalmology, University of Cape Town

Figure 10: Squamous carcinoma of the conjunctiva



Source: Division of Ophthalmology, University of Cape Town

Figure 11: Molluscum contagiosum lesions

include human papillomavirus type 16 infection and ultraviolet light exposure.²

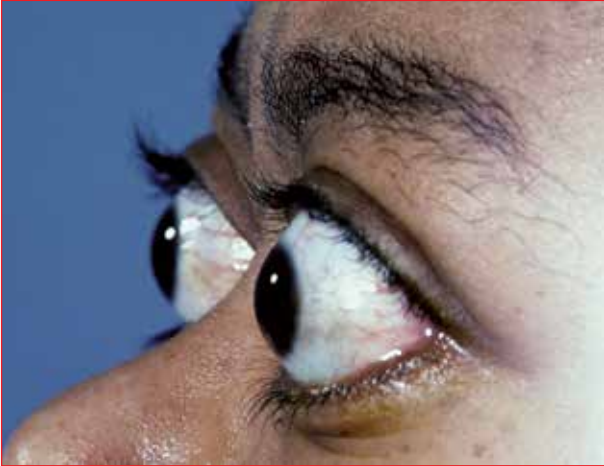Kaposi's sarcoma presents on the lid and/or conjunctiva as a flat, bright-red lesion that may mimic a subconjunctival haemorrhage. It responds very well to radiotherapy. Molluscum contagiosum appears on eyelid skin (Figure 11), and can also cause conjunctivitis.² It is treated by curettage of the lesions.

Cranial nerve palsy

Intracranial infection or inflammation such as tuberculosis or *Cryptococcus* can often result in cranial nerve palsies. The optic nerve may be primarily or secondarily involved in central nervous system disease. Other cranial nerves that are often affected in HIV infection are the oculomotor (III), trochlear (IV), abducens (VI) and facial (VII) nerves.²

Thyroid eye disease

Thyroid eye disease affects 25-50% of patients with Grave's disease, of which 5% have severe involvement. It may precede, coincide with or follow hyperthyroidism, and usually bears no relationship to the severity of thyroid



Source: Division of Ophthalmology, University of Cape Town

Figure 12: Proptosis (exophthalmos) in a patient with Grave's disease

dysfunction. The major clinical risk factor for developing thyroid eye disease is smoking. The greater the number of cigarettes smoked per day, the greater the risk. Conversely, giving up smoking reduces the risk. Women are five times more likely to be affected by thyroid eye disease than men. Radioactive iodine, used to treat hyperthyroidism, can worsen thyroid eye disease.⁴

The pathogenesis involves an organ-specific autoimmune reaction which produces inflammation of the extraocular muscles and inflammatory cellular infiltration of the orbital tissues (soft tissue, and fat and lacrimal glands). Clinical manifestations include soft tissue involvement, lid retraction, proptosis (Figure 12), optic neuropathy and restrictive myopathy.⁴ There are two stages in the development of the disease viz. a congestive (inflammatory) stage in which the eyes are red and painful (tends to remit within three years and only 10% develop serious long-term ocular problems); and a fibrotic (quiescent) stage in which the eyes are not inflamed, but may have a painless motility defect.

The European Group on Graves' Ophthalmopathy (EUGOGO) severity classification of thyroid eye disease is as follows.⁹

Mild disease

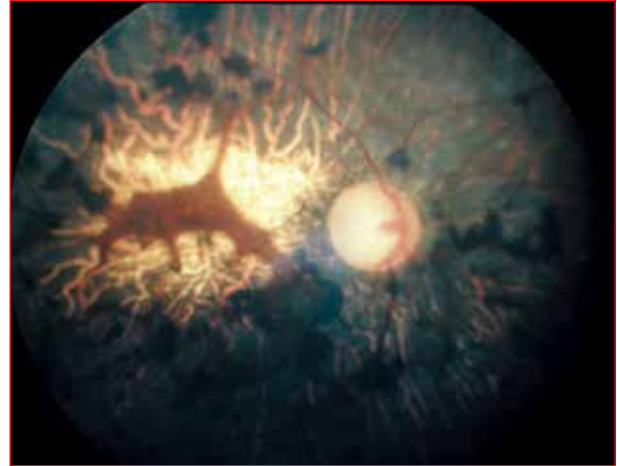
Mild disease has a minor impact on daily life and is insufficient to justify immunosuppressive or surgical treatment.

This group is characterised by:

- Mild soft tissue involvement.
- Mild lid retraction < 2 mm.
- Proptosis < 3 mm.
- No diplopia, nor optic neuropathy, nor signs of corneal exposure.

Moderate to severe disease

Moderate to severe disease is non-sight threatening, but has sufficient impact on daily life to justify immunosuppressive therapy.



Source: Division of Ophthalmology, University of Cape Town

Figure 13: Retinal appearance following syphilitic infection

It is characterised by:

- Moderate to severe soft tissue involvement.
- Lid retraction > 2 mm.
- Proptosis > 3 mm.
- Diplopia.

Severe disease

Severe disease includes optic neuropathy and/or corneal breakdown.

Management depends on the severity of disease and is often controversial. EUGOGO suggests the following:

- *Mild disease:* Lubricants must be used. Elevate the head of the bed, use ice packs and give selenium 200 µg/day (an antioxidant is needed for conversion of T4 to T3).¹⁰
- *Moderate disease:* Immunosuppressive therapy should be employed, using a systemic steroid for 6-12 weeks (radiotherapy may be included).
- *Severe disease (sight threatening):* A systemic steroid, followed by orbital decompression if there is no improvement having taken the steroid.

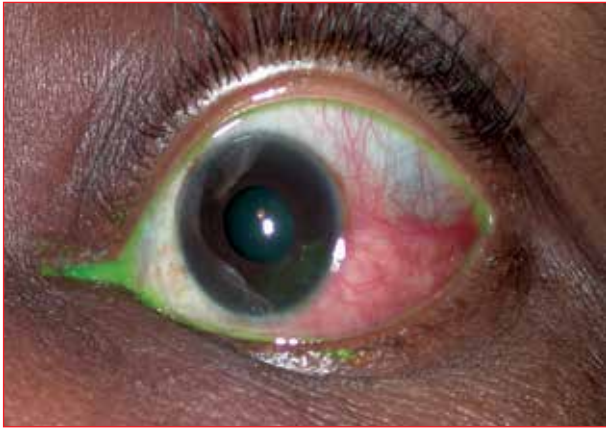Cosmetic surgery to the orbit, eyelids and muscles can be considered once the disease is in the quiescent phase.

Syphilis

Syphilis is regarded as "the great mimicker" and has been implicated in a variety of ocular pathologies. It has been associated with chancre of the lid, interstitial keratitis, uveitis and chorioretinitis (Figure 13), as well as optic neuritis and optic atrophy. The eye is considered to be part of the brain, and thus syphilis inside the eye is treated as neurosyphilis with intravenous penicillin for 10 days.² A lumbar puncture should also be performed to confirm the diagnosis.

Collagen vascular diseases

Diseases such as rheumatoid arthritis, systemic lupus erythematosus, Wegener's granulomatosis and other vasculitic disorders can cause various forms of ocular inflammation. These diseases can be associated with scleritis (Figure 14), episcleritis and immune-mediated



Source: Division of Ophthalmology, University of Cape Town

Figure 14: Scleritis in a patient with rheumatoid arthritis

keratitis. Management involves treating the systemic disease and referral for immunosuppressive therapy for the ocular condition.

Seronegative spondyloarthropathies

Rheumatoid factor-negative and human leukocyte antigen B27-positive conditions, such as ankylosing spondylitis, Reiter's syndrome and psoriasis, are often associated with a chronic, relapsing nongranulomatous uveitis, which can be severe. These patients should be referred for ophthalmic management as they often require intensive topical steroid therapy and careful follow-up.

Skin disease

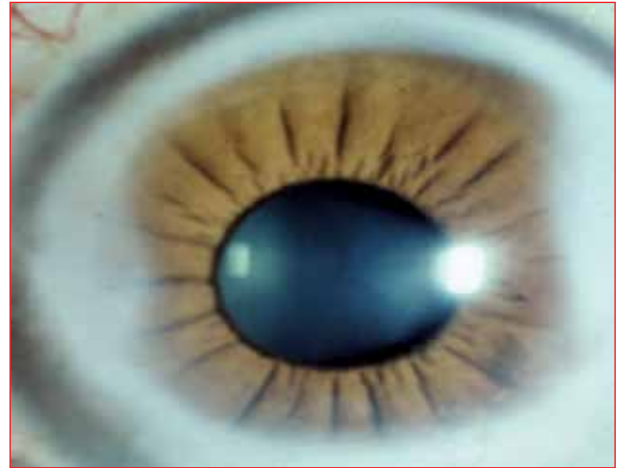Atopic conditions, such as eczema, are associated with atopic (allergic) conjunctivitis, cataracts, keratoconus and poor resistance to herpes simplex infection. Minor complaints can be treated symptomatically, but referral is indicated if vision is reduced. Stevens-Johnson syndrome and pemphigoid can destroy conjunctival goblet cells and lacrimal gland orifices, resulting in a very dry ocular surface and corneal scarring.² These patients require intensive lubrication in the acute phase, as well as early referral for ophthalmic management.

Systemic diseases where eye findings may help with the diagnosis

Many potentially life-threatening systemic illnesses have accompanying ocular signs which may help with the diagnosis (Table II). Rapid blood pressure reduction can result in ischaemic optic neuropathy in patients with malignant hypertension. Therefore, it is important to reduce blood pressure gradually during treatment.² Arcus cornealis (Figure 15) and xanthelasma in a younger patient can alert the clinician to hypercholesterolaemia and lead to early initiation of systemic therapy.

Drugs and the eye

Table III lists the important systemic drugs with ocular side-effects and vice versa.



Source: Division of Ophthalmology, University of Cape Town

Figure 15: Arcus cornealis secondary to hypercholesterolaemia

Conclusion

Systemic diseases like diabetes, herpes zoster ophthalmicus and thyroid ophthalmopathy often have ocular involvement, and if eye signs are not detected early, the visual consequences can be devastating. Diabetic retinopathy is the third leading cause of blindness in this country.² Therefore, it is important for the primary care physician to be familiar with the spectrum of ocular involvement in the systemic diseases that have been covered in this manuscript since appropriate intervention can be sight saving for the patient.

Acknowledgements

The Division of Ophthalmology, University of Cape Town, is thanked for providing permission to reproduce the clinical photographs.

Conflict of interest

There is no conflict of interest to declare.

References

1. Van Zyl LM, Fernandes N, Rogers, G, et al. Primary health eye knowledge among general practitioners in the Cape Town metropole. *S Afr Fam Pract*. 2011;53(1):52-55.
2. Du Toit N, Cook C. *The eye in systemic disease*. Cape Town: Juta, 2009, p. 58-65.
3. Viswanath K, Murray DD. Diabetic retinopathy: clinical findings and management. *Community Eye Health*, 2003;16(46):21-24.
4. Kanski JJ, Bowling B. *Clinical ophthalmology: a systematic approach*. 7th ed. London: Elsevier Saunders, 2011; p. 84-187.
5. Diabetic retinopathy study report no. 7: a modification of the Airlie House classification of diabetic retinopathy. *Invest Ophthalmol Vis Sci*. 1981;21:210-226.
6. Liesegang TJ. Herpes zoster virus infection. *Curr Opin Ophthalmol*. 2004;15(6):531-536.
7. Richards JC, Maartens G, Davids AJ. Course and complications of varicella zoster ophthalmicus in a high prevalence population (Cape Town, South Africa). *Eye (Lond)*. 2009;23(2):376-381.
8. Shaikh S, Ta CN. Evaluation and management of herpes zoster ophthalmicus. *Am Fam Physician*. 2002; 66(9):1723-1730
9. Bartalena L, Baldeschi L, Dickinson A, et al. Consensus statement of the European Group on Graves' Orbitopathy (EUGOGO) on management of GO. *Eur J Endocrinol*. 2008;158:273-285.
10. Duntas LH. The role of selenium in thyroid autoimmunity and cancer. *Thyroid*. 2006;16(5):455-460.