

Is total glossectomy for advanced carcinoma of the tongue justified?

ANTON C. VAN LIEROP, M.B. CH.B., F.C.O.R.L. (S.A.), M.MED. (ORL.)

OLA BASSON, B.SC. (MED.), M.B. CH.B., F.C.S. (S.A.) ORL.

JOHANNES J. FAGAN, M.B. CH.B., F.C.S. (S.A.), M.MED. (OTOL.)

Division of Otolaryngology, University of Cape Town

Summary

Total glossectomy (with or without total laryngectomy) followed by postoperative radiotherapy remains the principal treatment method for advanced base of tongue carcinoma. The procedure remains controversial owing to poor cure rates and the inevitable functional deficits associated with it. However, even though total glossectomy is a major surgical procedure that impacts on speech, deglutition and quality of life, it may offer patients the best chance of cure in many centres, especially in the developing world.

Methods. We did a retrospective chart review of all patients at Groote Schuur Hospital, Cape Town, who had undergone total glossectomy, with or without total laryngectomy, for stage IV squamous cell carcinoma (SCC) of the tongue between 1998 and 2004.

Results. Eight patients had a total glossectomy performed during the study period. At 2, 3 and 5 years 63%, 38% and 25% of patients respectively were alive without disease. No patient required permanent nasogastric or gastrostomy feeding, and all returned to a full oral diet. Three of 5 patients who had laryngeal preservation and could be assessed for speech had intelligible speech. All but 1 patient (88%) reported pain relief following surgical excision. Perineural invasion was present in 75%, and 38% had positive resection margins. Five patients had recurrence, 2 cervical, 1 local, and 2 local and cervical.

Conclusion. Advanced SCC of the tongue is a devastating disease causing severe pain and disorders of speech and swallowing. Total glossectomy (with or without total laryngectomy) and postoperative radiotherapy is a reasonable treatment option, particularly in the developing world setting. It has cure rates superior to primary radiotherapy, and provides motivated patients with excellent pain relief and a reasonable quality of life.

Cure rates for advanced tongue carcinoma are unsatisfactory despite advances in multimodality therapy, reconstruction, and rehabilitative techniques. The principal treatment options available for advanced tongue carcinoma are total glossectomy with postoperative radiotherapy, primary radical radiotherapy, or chemoradiotherapy.

Although chemoradiation has made great strides, it is generally not an option in the developing world owing

to expense, failure of patients to complete therapy, and inadequate expertise and support to deal with the consequences and complications of chemoradiation. Furthermore, in most centres positron emission tomography (PET) to monitor for recurrence is not available. More than 50% of the world's population lives in the developing world. Therefore, even though total glossectomy is a major surgical procedure that impacts on speech, deglutition and quality of life, it may offer patients the best chance of cure in many centres.

Aims

The purpose of this study was to determine the applicability of total glossectomy for treatment of stage IV tongue cancer in a developing world setting.

Methods

We did a retrospective chart review of all patients at Groote Schuur Hospital, Cape Town, who had undergone total glossectomy, with or without total laryngectomy, for stage IV squamous cell carcinoma (SCC) of the tongue between 1998 and 2004.

Results

Eight patients underwent total glossectomy (Table I). There were 6 males. Ages ranged between 33 and 72 years (mean 50 years). Patient 6 underwent total glossectomy for salvage following failed radiotherapy. The remaining patients had primary surgery and postoperative radiotherapy.

Three patients had total glossectomy performed in conjunction with total laryngectomy for tumour involving the pre-epiglottic space or larynx. Five patients (62%) had a marginal mandibulectomy, 1 required segmental mandibulectomy and 1 required partial pharyngectomy. All patients had bilateral neck dissections (modified neck dissection types I or II for palpable nodes, and selective neck dissection levels I - IV for N0 necks). Reconstruction of the oral defect was done with latissimus dorsi (4) or pectoralis major (2) pedicled flaps, radial free forearm flap (RFFF) (1) or rectus abdominis free flap (1). All patients except for patient 6 had postoperative radiotherapy. There were no immediate postoperative deaths.

Initial postoperative feeding was by nasogastric feeding tube. No patient required permanent nasogastric or

TABLE I. PATIENT DATA AND PROCEDURES PERFORMED

Patient	Age/sex	Clinical stage	Additional procedure	Reconstruction
1	33/M	T3N2b	Segmental mandibulectomy	Latissimus dorsi
2	43/F	T4N2c	Laryngectomy	Latissimus dorsi
3	55/M	T4N2b	Laryngectomy	Latissimus dorsi
4	46/M	T4N1		RFFF
5	47/M	T4N2c		Pectoralis major
6	72/M	T4N1	Previous radiation therapy	Pectoralis major
7	48/F	T4N0	Laryngectomy	Latissimus dorsi
8	54/M	T3N2b		Rectus abdominis

M = male; F = female; RFFF = radial free forearm flap.

gastrostomy feeding, and all patients returned to a full oral diet (Table II). Twenty-five per cent of patients managed a normal diet, 38% a soft diet, 25% thickened fluids and 12% only liquids.

Three of 5 patients who had laryngeal preservation and could be assessed for speech had intelligible speech. One returned to full-time employment. All but 1 of the patients (88%) reported pain relief following surgical excision.

Table III summarises pathological nodal status (pN), extracapsular spread (ECS), perineural invasion (PNI), resection margins, and patient outcome. PNI was present in 75%, and 38% had positive resection margins.

At 2, 3 and 5 years, 63%, 38% and 25% of patients respectively were alive without disease. The average survival for T3 tumours was 42 months and for T4, 34 months. Of the 5 patients with recurrence, 4 had cervical recurrence and 3 local recurrence. Two of these patients had both local and cervical recurrence. Of the 4 patients who developed cervical recurrence, 1 had had pN2, 2 pN1 and 1 pN0 disease.

Of the 3 patients who developed local recurrence, 2 had clear resection margins, but all 3 had PNI. Of 3 patients with positive resection margins 2 died, at 24 and 36 months respectively. The 3rd patient remains tumour free at 60 months.

Discussion

SCC is the most common malignancy affecting the tongue base, followed by lymphoma and minor salivary gland tumours.¹ The most important aetiological factors associated with SCC of the oropharynx are prolonged exposure to

tobacco and alcohol.² Alcohol and tobacco act synergistically, resulting in a greater risk than either one alone.³ Carcinoma involving the base of the tongue is usually advanced at the time of initial presentation, because it becomes symptomatic only at an advanced stage and examination of this area may be quite difficult. Tumours tend to spread quickly through the deep tongue muscles and across the midline to involve the entire tongue. Contraction of the genioglossus muscle may help to propel malignant cells through potential spaces within the intrinsic tongue muscles and into the lymphatic system.¹ Tumour spread often occurs posteriorly and inferiorly into the vallecula, the epiglottis and hence to the supraglottis and pre-epiglottic space¹ (Fig. 1).

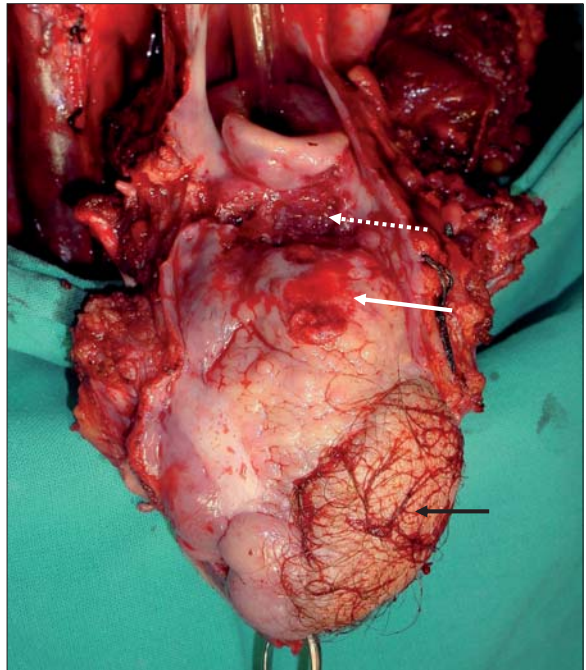


Fig. 1. Metachronous SCC in base of tongue (white arrow) extending to vallecula (broken white arrow), following prior RFFF for anterolateral SCC tongue (black arrow).

TABLE II. MORBIDITY FOLLOWING TOTAL GLOSSECTOMY

Patient	Swallowing	Speech
1	Normal diet	Intelligible speech
2	Liquids	Laryngectomy
3	Soft diet	Laryngectomy
4	Normal diet	Good speech
5	Thickened fluids	Not assessed
6	Thickened fluids	Not assessed
7	Soft diet	Laryngectomy
8	Soft diet	Good speech

Sir Donald Harrison described the clinicopathological features of tongue carcinoma in a landmark article in 1983.⁴ He reported a high incidence of PNI, as well as spread

TABLE III. CLINICOPATHOLOGICAL DATA

Patient	pN	ECS	pT	PNI	Margin	Follow-up (mo.)	Recurrence	Alive, AWD,DOD
1	N2b	+	T3	+	+	60	-	Alive
2	N0		T4	+	-	27	-	DOD
3	N2c	+	T4	+	+	36	Cervical	DOD
4	N0		T4	-	-	67	-	Alive
5	N1	-	T4	-	-	9	Cervical	DOD
6	N0		T4	+	-	23	Local, cervical	DOD
7	N2c	+	T4	+	-	8	Local	DOD
8	N1	+	T3	+	+	24	Local, cervical	DOD

pN, pT = pathological TNM stage; ECS = extracapsular spread; PNI = perineural invasion; AWD = alive with disease; DOD = dead of disease.

by local microembolisation along perivascular pathways, producing islands of invasive carcinoma beyond the reported 'histologically clear' resection margins. He concluded that aggressive surgery was warranted for advanced tongue carcinoma. In our series PNI was present in 75% of specimens. Our series showed a 40% local recurrence rate in cases reported as having histologically clear margins, but PNI had been present in all recurrences. PNI might therefore explain the high prevalence of local recurrence after tongue resections with negative margins (32 - 36%).⁴

Margins were involved in 38% of our specimens. Although in a developing world setting we have limited availability of frozen section, our positive/close margins are similar to that reported by others (13%, 50% and 54%).⁵⁻⁷ Nevertheless, of the 3 patients with involved margins, only 1 developed local recurrence, and all 3 patients survived at least 2 years, with 1 patient still alive after 5 years. It may be difficult to obtain clear margins in advanced tongue carcinoma, because it is difficult to clinically assess tumour size within the deep muscles of the tongue, and to distinguish the thick base of tongue tissue from tumour. Although a 2 cm surgical margin is desirable for SCC of the tongue, the adult tongue only measures about 11.5 cm x 6 cm. Hence a patient with a T3 (4 - 6 cm) or T4 (>6 cm) carcinoma may require total glossectomy to obtain adequate margins.⁴

The tongue has rich lymphatic drainage and there is no boundary to cross over to contralateral lymphatic channels.⁴ In our study cervical metastases were present in 63% of patients, and 25% had bilateral metastases. This corresponds with reports that approximately 70% of patients with SCC of the base of tongue have cervical metastases at initial presentation, 20 - 30% of which are bilateral.^{1,5,8}

We treat advanced, operable tongue base carcinoma with total glossectomy followed by postoperative radiotherapy. Reported 3-year survival following primary surgery with postoperative radiotherapy varies from 32% to 51% (average 40%),^{5,6,8,9} and 5-year survival rates from 12% to 41% (average 27%).^{5,7,8,9} Our 2-, 3- and 5-year survival rates of 63%, 38% and 25% compare favourably with the literature. We had no immediate postoperative deaths, while other series reported postoperative mortality rates of 3 - 6%.⁷⁻⁹ Total glossectomy can also be used for salvage following primary radiation failure, with reasonable success.⁵ Barry *et al.* found postoperative morbidity and functional outcomes to be the same in patients undergoing primary surgery compared with salvage surgery.⁵ The survival rates for patients undergoing

primary surgery were higher than for salvage surgery, although the results did not reach statistical significance.⁶ Chemoradiation with salvage surgery therefore remains an acceptable alternative in centres with facilities to monitor closely for recurrences.

Functional evaluation following total glossectomy includes speech, swallowing, oral intake and aspiration.⁹ Successful speech outcome in 50 - 100% of patients following total glossectomy with laryngeal preservation has been reported.¹⁰⁻¹² Although our data were incomplete, all patients who could be assessed and had had laryngeal preservation had intelligible speech. Successful swallowing in 57 - 100% of patients has been reported.^{7,10-12} All our patients returned to an oral diet and no patient had clinically significant aspiration. Although our patients' postoperative diet usually consisted of only liquid or soft food - similar to reports by others⁶ - this represented little change from the preoperative diet.

Discussion about postoperative morbidity must take cognisance of preoperative function and quality of life (QOL).¹³ Patients with advanced tongue carcinoma are often debilitated by pain and have problems with speech and deglutition. Our patients reported significant pain relief following total glossectomy (88%), as has been reported elsewhere.^{9,13} Ruhl *et al.* assessed QOL in patients who had undergone total glossectomy by utilising the performance status scale (PSS) and QOL questionnaires.⁵ Functional assessment using the PSS demonstrated significant deficits in speech and deglutition. QOL questionnaires revealed problems with eating, speaking, and socialising. However, the overall response demonstrated that these patients had adjusted to their deficits and had a good QOL. It was concluded that total glossectomy can result in meaningful survival and adequate QOL in selected, well-motivated patients with good emotional support and access to a skilled and professional rehabilitation team.⁸

The jury is still out on the survival benefits and morbidity of primary surgery versus radiotherapy for advanced tongue base SCC.¹⁴ Primary radiotherapy has the advantage of organ preservation, but survival rates have been disappointing for advanced base of tongue SCC.^{15,16} Barrett *et al.* compared treatment with surgical resection combined with external beam radiation therapy, external beam radiation therapy alone, and external beam radiation therapy combined with interstitial radiation.¹⁶ Although survival with both approaches remained <50%, local control and survival were better with surgical resection than with external

beam radiation. Functional status was better in long-term survivors treated non-surgically.¹⁶ Recently reported overall (52%) and disease-specific (67%) 5-year survival rates after combined external beam radiotherapy and brachytherapy for stage IV SCC have been encouraging,¹⁷ but morbidity associated with radical radiotherapy is not insignificant, and dysphagia requiring long-term nasogastric or enteral feeding is not uncommon. Robertson *et al.* reported good QOL after external beam irradiation followed by brachytherapy and neck dissection.¹⁵ However, they reported survival for advanced tongue base cancers treated with above modalities to be dismal, and only suggested this form of treatment for T1 and T2 tumours in which preservation of function and QOL was a priority.¹⁵

We employ a few key surgical steps to maximise functional (speech and deglutition) outcome of total glossectomy.

Upwardly convex floor of mouth (FOM). The reconstructed FOM must be upwardly convex in order to prevent saliva and food pooling in the mouth, and to facilitate oral transport and speech (Fig. 2). This requires a bulky musculocutaneous flap such as latissimus dorsi and pectoralis major pedicled flaps, or anterolateral thigh or rectus abdominis free flaps. As the muscle of the flap will atrophy, the flap must appear too bulky at the time it is inserted. A fasciocutaneous flap such as an RFFF does not provide adequate bulk. Doing a complete marginal mandibulectomy and suturing the flap to the gingivobuccal mucosa obliterates the lateral sulci in the mouth, and further

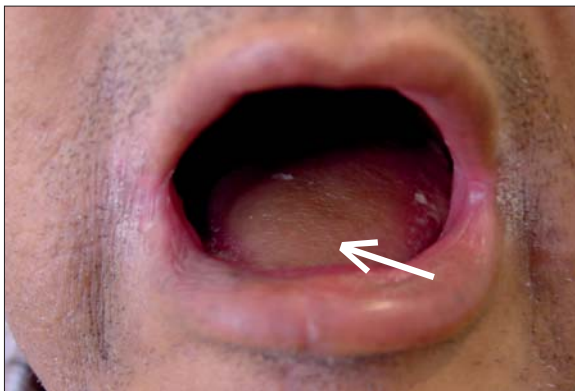

Fig. 2. Convex floor of mouth reconstructed with pectoralis major flap (white arrow).

improves function.

Reduce aspiration. When the larynx is preserved, take care to preserve the superior laryngeal nerves and any sensate posterior tongue mucosa possible. We perform a laryngeal suspension by suspending the hyoid bone to the mandibular arch, and thereby restore the larynx to its physiological position in an attempt to reduce aspiration and improve swallowing.⁷

Preserve larynx. An important decision that impacts on both speech and swallowing is whether to perform a concomitant laryngectomy. A total glossectomy with total laryngectomy makes the potential for acquiring good speech impossible, but has the advantage of preventing aspiration. When tumour involves the larynx, total laryngectomy is unavoidable. Harrison suggested that total laryngectomy be performed for most base of tongue tumours in order

to obtain adequate margins.⁴ We believe, like others, that laryngeal preservation is possible as long as the vallecula and pre-epiglottic space are free of disease.¹³ While laryngeal preservation makes speech possible, the risk of significant aspiration needs to be considered. Preserving the superior laryngeal nerve in patients undergoing total glossectomy is the most important factor in preventing aspiration.^{6,18} Good postoperative speech and swallowing rehabilitation can reduce aspiration even further.

Conclusions

Advanced SCC of the tongue is a devastating disease causing severe pain and disorders of speech and swallowing. Total glossectomy (with or without total laryngectomy) and postoperative radiotherapy is a reasonable treatment option, particularly in the developing world setting. It has cure rates superior to primary radiotherapy, and provides motivated patients with excellent pain relief and a reasonable quality of life.

Presented at the Annual Academic Meeting of the South African Society of Otorhinolaryngology, Head and Neck Surgery, November 2004, Port Elizabeth.

REFERENCES

- Watkinson JC, Gaze MN, Wilson JA, eds. Tumours of the oropharynx. In: *Stell and Maran's Head and Neck Surgery*. 4th ed. Oxford: Butterworth Heinemann, 2000: 319-334.
- Mashberg A, Boffette P, Winkelman R, *et al.* Tobacco smoking, alcohol drinking, and cancer of the oral cavity and oropharynx among US veterans. *Cancer* 1993; 72: 1369-1375.
- Seikaly H, Rassekh CH. Oropharyngeal cancer. In: Bailey BJ, ed. *Head Neck Surgery - Otolaryngology*. 3rd ed. Philadelphia: Lippincott, Williams & Wilkins, 2001: 1427-1441.
- Harrison D. The questionable value of total glossectomy. *Head Neck Surg* 1983; 6: 632-638.
- Barry B, Baujat B, Albert S, Nallet E. Total glossectomy without laryngectomy as first-line or salvage therapy. *Laryngoscope* 2003; 113: 373-376.
- Rodriguez R, Perry C, Soo KC, Shaw HJ. Total glossectomy. *Am J Surg* 1987; 154: 415-418.
- Bova R, Cheung I, Coman W. Total glossectomy: is it justified? *Aust NZ J Surg* 2004; 74: 134-138.
- Ruhl CM, Gleich LL, Gluckman JL. Survival, function, and quality of life after total glossectomy. *Laryngoscope* 1997; 107: 1316-1321.
- Gehanno P, Guedon C, Beatrice B, Depondt J. Advanced carcinoma of the tongue: total glossectomy without total laryngectomy. Review of 80 cases. *Laryngoscope* 1992; 102: 1369-1371.
- Donaldson RC, Skelly M, Paletta FX. Total glossectomy for cancer. *Am J Surg* 1968; 116: 585-590.
- Weber RS, Ohlms L, Bowman J, Jacobs R. Functional results after total or near total glossectomy with laryngeal preservation. *Arch Otolaryngol Head Neck Surg* 1991; 117: 512-515.
- Tiwari R, Karim AB, Greven AJ, Snow GB. Total glossectomy with laryngeal preservation. *Arch Otolaryngol Head Neck Surg* 1993; 119: 945-949.
- Davidson J, Brown D, Gullane P. A re-evaluation of total glossectomy. *J Otolaryngol* 1993; 22: 160-163.
- Van de Pol M, Levendag PC, de Bree RR, Franssen JH, Smeele LE. Radical radiotherapy compared with surgery for advanced squamous cell carcinoma of the base of tongue. *Brachytherapy* 2004; 3: 78-86.
- Robertson ML, Gleich LL, Barrett JL, Gluckman JL. Base-of-tongue cancer: survival, function, and quality of life after external-beam irradiation and brachytherapy. *Laryngoscope* 2001; 111: 1362-1365.
- Barrett WL, Gluckman JL, Wilson KM, *et al.* A comparison of treatments of squamous cell carcinoma of the base of tongue: surgical resection combined with external radiation therapy, external radiation therapy alone, and external radiation therapy combined with interstitial radiation. *Brachytherapy* 2004; 3: 240-245.
- Cano ER, Johnson JT, Carrara R, Agarwala S, Flickinger J. Brachytherapy in the treatment of stage IV carcinoma of the base of tongue. *Brachytherapy* 2004; 3: 41-48.
- Shedd DP, Scatliff JA, Kirchner JA. A cineradiographic study of postresectional alterations in oropharyngeal physiology. *Surg Gynecol Obstet* 1960; 110: 69-89.