



## Clinical lessons from an elderly man with amiodarone-induced interstitial lung disease

Brian Rayner

**To the Editor:** An 82-year-old man was in relatively good health despite a background of hypertension, chronic kidney disease stage 4 (estimated glomerular filtration rate 15 - 30 ml/min) and extensive vascular disease requiring carotid endarterectomy, coronary artery bypass grafting, repair of an abdominal aortic aneurysm, and stenting of both renal arteries. In May 2005 he developed rapid atrial flutter after an episode of acute coronary syndrome. He was successfully cardioverted to sinus rhythm. After a loading dose of amiodarone he continued on 200 mg daily, and remained in sinus rhythm.

In November 2005 he presented to his GP with symptomatic hypotension, lethargy and breathlessness on exertion but no orthopnoea or paroxysmal nocturnal dyspnoea. He failed to improve despite withdrawal of the antihypertensive treatment. He was reviewed by a cardiologist, who made a diagnosis of congestive heart failure based on the presence of peripheral oedema and inspiratory crackles mainly at the lung bases, and a markedly elevated pro-brain natriuretic peptide level of 4 242 pg/l (normal range < 125 pg/l). His echocardiogram, however, showed a reduced but unchanged ejection fraction of 48%. He was treated with diuretics, but was admitted to hospital a few days later with worsening symptoms of shortness of breath and pre-renal failure.

A chest radiograph and high-resolution computed tomography (CT) scan (Figs 1 and 2) was misreported as old asbestosis instead of acute interstitial lung disease. A previous chest radiograph and CT scan done in 1996 are shown for comparison (Figs 1 and 2). A repeat echocardiogram showed no change in the ejection fraction.

Amiodarone was withdrawn, but the patient continued to be managed for cardiac failure and remained critically ill. After intervention by the general practitioner, who questioned the diagnosis because the patient was more comfortable lying flat, the case was reviewed and the diagnosis was changed to amiodarone-induced interstitial lung disease. After starting high-dose steroids the patient made a slow and steady recovery. His shortness of breath improved and the inspiratory crackles resolved with clearing of the interstitial changes on the chest radiograph. However, even after 1 year of treatment

he has not returned to his previous baseline activities of daily living.

This case demonstrates a number of important clinical lessons.

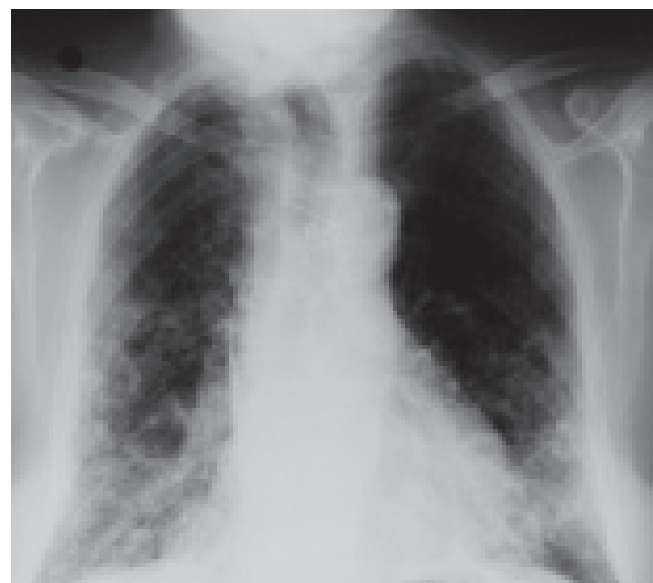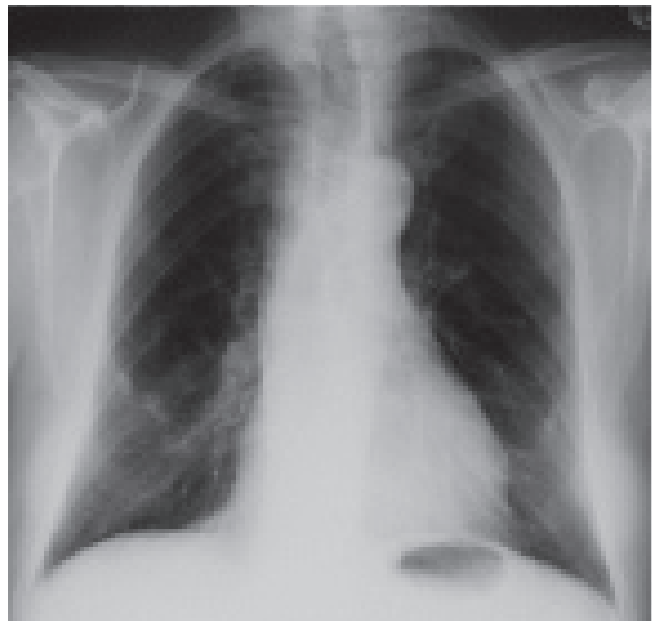


Fig. 1. Above: chest radiograph taken in 1996, showing cardiomegaly and old asbestos plaque. Below: the current film, showing cardiomegaly and interstitial changes mainly at the bases with no signs of cardiac failure.

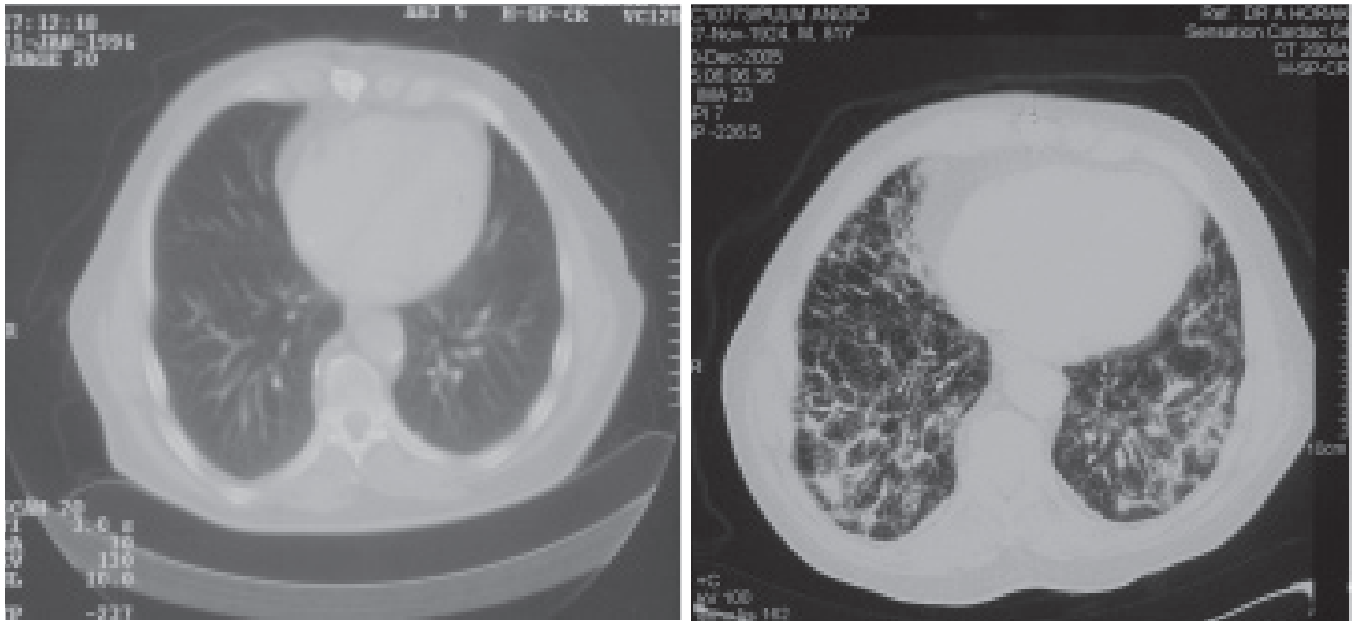


Fig. 2. Left: this CT scan of the chest was taken in 1996, and is normal. Right: the current scan, showing extensive interstitial changes consistent with a drug reaction.

1. Drug reactions and toxicity must always be considered in the differential diagnosis, especially in elderly patients because of altered pharmacokinetics and pharmacodynamics. The dosage of many commonly prescribed drugs, including amiodarone, often needs to be reduced.

2. Physicians should always critically review the need for ongoing treatment with potentially toxic drugs.

3. Basic symptoms and signs need to be carefully evaluated. Basal crackles can be a sign of both pulmonary oedema and interstitial lung disease, and more emphasis should have been placed on the lack of orthopnoea – an important symptom of left heart failure.

4. Over-reliance on a single laboratory value can lead to a wrong diagnosis. Pro-brain natriuretic peptide is elevated in heart failure, but it is not specific. A normal value is a good test for excluding heart failure.

5. The review of previous radiological tests is vitally important in any case evaluation.

Finally, the case illustrates many of the problems of clinching a diagnosis of amiodarone-induced interstitial lung disease in a patient with underlying heart disease, especially if left ventricular dysfunction is present.