

Situs inversus abdominalis and duodenal atresia

A case report and review of the literature

CRAIG BROWN, B.SC. (MED. SCI.) (HONS), M.B. CH.B.

ALP NUMANOGLU, M.B. CH.B., F.C.S. (S.A.)

HEINZ RODE, M.B. CH.B., M.MED. (SURG.), F.R.C.S. (EDIN.), F.C.S. (S.A.)

Department of Paediatric Surgery, Red Cross War Memorial Children's Hospital and University of Cape Town

DANIEL SIDLER, M.B. CH.B., F.C.S. (S.A.)

Department of Paediatric Surgery, Tygerberg Children's Hospital and Stellenbosch University, W. Cape

Summary

Fewer than 20 patients born with situs inversus and duodenal atresia have been reported in the literature. We present a patient with this condition. A newborn baby presented shortly after birth with persistent bilious vomiting. An abdominal radiograph showed a right-sided stomach bubble and a second bubble on the left – typical of duodenal atresia but with mirror image configuration. Laparotomy confirmed the diagnosis of situs inversus abdominalis, which was also demonstrated by contrast studies and ultrasound. Duodeno-duodenostomy was performed and the patient discharged on day 8 postoperatively.

Situs inversus is associated with other congenital malformations including splenic malformations, left-sided liver and cardiac abnormalities; it is rarely associated with duodenal atresia. Duodenal obstruction in the presence of situs inversus has been described, including obstruction due to a web, stenosis, pre-duodenal portal vein and complete atresia. The patient presented in this paper had a duodenal web in the second part of the duodenum. Before undertaking surgery it is important to establish the presence of associated gastrointestinal and cardiac abnormalities.

Gastro-intestinal and cardiac anomalies associated with intestinal situs inversus are extremely uncommon.^{1,2} There are less than 20 patients reported in the literature who were born with duodenal atresia in the setting of situs inversus.³ These patients can also have other associated intra-abdominal abnormalities. This case is presented to highlight the importance of identifying the duodenal atresia by means of the unusual double-bubble configuration, and to describe pre- and postoperative care of possible associated malformations.

Case report

A full-term HIV-exposed female baby was born by caesarean section. Her mother was unbooked and delivered at a regional hospital; she was a 24-year-old gravida 1, para 1, who was noticed to have polyhydramnios when she presented for delivery.

The baby weighed 2 340 g and her Apgar scores were 9 and 10. One day after birth she began to experience persistent bile-stained vomiting. On examination she had an ejection systolic murmur (grade 3/6) and all peripheral pulses were palpable. The abdomen was soft and not distended, and no masses were palpable. An abdominal radiograph showed the mirror image of a typical double-bubble configuration of duodenal atresia (Fig. 1). This was confirmed with a barium meal examination. An abdominal ultrasound scan was suggestive of situs inversus and a possible left-sided liver. Renal function and a full blood count were normal. An echocardiogram showed an interrupted inferior vena cava (IVC) with the azygos system in continuity with the superior vena cava (SVC), good-sized branch pulmonary arteries and left-to-right shunting of blood. The aortic arch was normal, vessels to the head and neck were intact and the coronary arteries were normal.

Anatomical findings at laparotomy confirmed situs inversus and atresia of the duodenum situated on the left side. The duodenum was in continuity at the site of atresia with the pancreas in the concavity of the duodenal loop (Fig. 2). The distal bowel was unused and small in calibre. Saline injection excluded distal atresias. The mesentery of the small bowel was unfixed and there were no other atresias noted in the small bowel. The colon was predominantly on the left side. The liver was in its normal anatomical position with the gallbladder arising from the right lobe. Portal structures and bile duct traversed the midline to enter the duodenum on the left inside. Both kidneys were normal and the spleen was on the right side with a single spleniculus situated inferiorly.

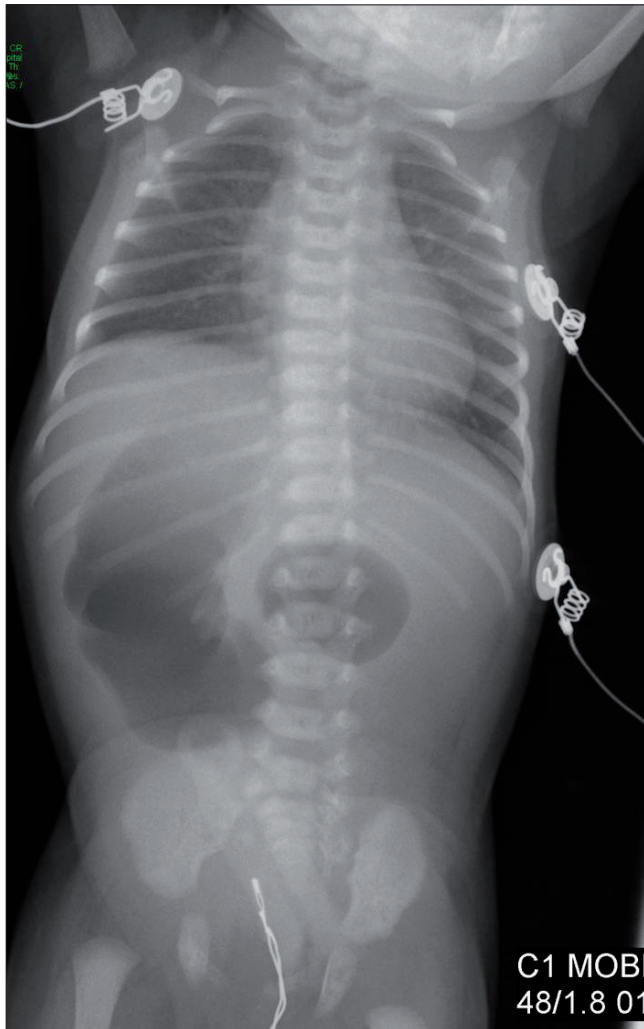


Fig. 1. Abdominal radiograph showing duodenal atresia with mirror image configuration of normal anatomy.

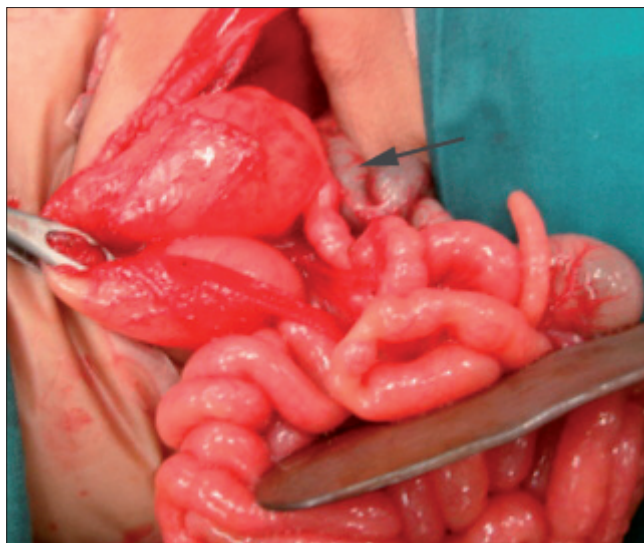

Fig. 2. Situs inversus of stomach with duodenal atresia (arrow).

The colon was mobilised and the duodenal atretic segment exposed. A routine diamond-shaped duodeno-duodenostomy was performed. Postoperatively the baby was kept on

intravenous broad-spectrum antibiotics and total parenteral nutrition. The postoperative course was uneventful. Oral sips started on day 3 and she was discharged on full feeds on day 8.

Discussion

The frequency of duodenal atresia ranges from 1 in 5 000 to 20 000 live births. An association with situs inversus is very uncommon. Situs inversus and splenic malformations can be seen in the form of asplenia (53%), polysplenia (42%), and a single right-sided spleen (5%).² At laparotomy the intra-abdominal organs, their orientation and any abnormalities should be carefully noted and necessary procedures undertaken. Associated abnormalities can include hypoplasia of the pancreas, biliary atresia, absence of the gallbladder and polycystic liver.² Our patient was examined with these in mind, and right-sided spleen and situs inversus of stomach and duodenum were the only abnormalities found.

Genetics and embryology of situs inversus are complex. Familial inheritance has been evident in some cases.¹ A number of environmental factors regarding laterality defects have also been suggested, including maternal diabetes and retinoic acid exposure.¹ Between 3% and 5% of patients with situs inversus have primary ciliary dyskinesia. Primary ciliary dyskinesia is an autosomal recessive condition. It is suggested that most heterotaxic disorders are multifactorial in their causation.⁴ Congenital heart defects are present in 5 - 10% of patients with situs inversus. Our patient had no family history of situs inversus.

The association of congenital duodenal obstruction with abdominal situs inversus has only been described in 20 patients. Data that could be extracted from the available literature are documented in Table I. The male-to-female ratio was equal. The spleen was found to be positioned on the right in the majority of patients. Although duodenal abnormalities include complete obstruction by a web, stenosis, obstruction due to pre-duodenal portal vein and complete atresia, most of the patients had complete atresia requiring duodeno-duodenostomy.^{3,4} Our patient had complete obstruction by a duodenal web in the second part of the duodenum distal to the opening of the bile ducts.

Fenestrated duodenal webs can present late. Abdominal pain, nausea or vomiting and failure to thrive associated with situs inversus and dilated bowel loops should prompt further investigation to look for partial obstruction.⁵

The most common intra-abdominal abnormalities seen with situs inversus are left-sided liver, asplenia or right-sided spleen and malrotation. The less common abnormalities are gastroschisis, biliary atresia and diaphragmatic hernia. The heart is the most commonly affected extra-abdominal organ in patients with situs inversus, and in this situation cardiovascular symptoms are usually the first ones that lead to detection of the abnormalities. It is important to establish the anatomy of the heart before performing any operative procedure. In our case an echocardiogram demonstrated normal cardiac structure but absence of the IVC. The latter is a well-documented association with polysplenia. Classically the azygos vein drains into the SVC.² Outcome therefore often depends on the other congenital abnormalities.

In conclusion, duodenal atresia and situs inversus are rare combinations. Outcome is excellent with appropriate management of possible associated abnormalities.

TABLE I. DUODENAL ATRESIA AND SITUS INVERSUS PATIENTS REPORTED IN THE LITERATURE

Study	Sex	Pre-sented	Spleen	Duodenum and colon	Heart	Surgery performed
Tryfonas <i>et al.</i> ⁶	M	1 d	Right	Duodenum obstructed, R-sided colon mirror image non-rotation	Levocardia	Side-to-side duodeno-jejunostomy + appendectomy
Chandran <i>et al.</i> ⁷	F	3 d	Right	Complete obstruction 2nd part. Duodenal atresia	Levoverted, IVC L	Duodenoplasty
Cacciaguerra <i>et al.</i> ⁸	M	1 yr	Right polysplenia	Left sided, Ladd's bands across 2nd part. Mirror image of 180° malrotation	Normal	Duodenoplasty
Nawaz <i>et al.</i> ³	F	2 d	Right	Malrotation of bowel	Fallot's tetralogy features	Side-to-side duodeno-duodenostomy + appendectomy
Nawaz <i>et al.</i> ³	F	4 d	Right	L side, duodenal diaphragm with central hole	Normal	Duodenotomy, side-to-side duodeno-duodenostomy, appendectomy
Ohno <i>et al.</i> ⁹	M	27 wks gest.	Right polysplenia	Duodenal stenosis, colon lying on 2nd part of duodenum	Dextrocardia + cardiac abnormalities	Duodeno-duodenostomy, Blalock-Taussig shunt, Glenn and Fontan procedures
Lee <i>et al.</i> ¹	*	*	*	Duodenal atresia	*	Duodeno-jejunostomy
Adeyemi ¹⁰	F	7 d	Right	Duodenal atresia, ring of pancreatic tissue surrounding 2nd part	*	Side-to-side duodeno-jejunostomy
Adeyemi ¹⁰	M	12 d	*	Duodenal atresia, annular pancreas around 2nd part of duodenum, mucosal diaphragm	Normal	Duodenoplasty, diaphragm excision
Adeyemi ¹⁰	M	8 d	Right	Duodenal atresia, complete annular pancreas surrounding duodenum	Normal	Side-to-side duodeno-jejunostomy
Ruben <i>et al.</i> ¹¹	*	*	Right (polysplenia)	*	Cardiomegaly, AV canal, absent IVC, L aortic arch	Mirror image porto-enterostomy
Akel <i>et al.</i> ¹²	F	6 d	*	Duodenal obstruction – mucosal diaphragm	*	Duodenoplasty + appendectomy
Fonkalsrud <i>et al.</i> ¹³	*	*	*	4 patients with SI, 2 duodenal atresia, 2 duodenal web	*	Unknown
Noack <i>et al.</i> ¹⁴	F	Birth	Asplenia	Situs ambiguus, Ivemark syndrome, duodenal stenosis	Complete AVSD	Unknown
Brown <i>et al.</i> (present series)	F	Birth	Right (polysplenia)	Duodenal atresia	Interrupted IVC	Duodeno-duodenostomy

*Information not available.

L = left; R = right; IVC = inferior vena cava; AV = atrioventricular; AVSD = atrioventricular septal defect.

REFERENCES

1. Lee SE, Kim HY, Jung SE, Lee SC, Park KW, Kim WK. Situs anomalies and gastrointestinal abnormalities. *J Pediatr Surg* 2006; 41(7): 1237-1242.
2. Bartram U, Wirbelauer J, Speer CP. Heterotaxy syndrome – asplenia and polysplenia as indicators of visceral malposition and complex congenital heart disease. *Biol Neonate* 2005; 88(4): 278-290.
3. Nawaz A, Matta H, Hamchou M, Jacobez A, Trad O, Al Salem AH. Situs inversus abdominis in association with congenital duodenal obstruction: a report of two cases and review of the literature. *Pediatr Surg Int* 2005; 21(7): 589-592.
4. Mordehai J, Cohen Z, Kurzbart E, Mares AJ. Preduodenal portal vein causing duodenal obstruction associated with situs inversus, intestinal malrotation, and polysplenia: A case report. *J Pediatr Surg* 2002; 37(4): E5.
5. Peetsold MG, Ekkelkamp S, Heij HA. Late presentation of a duodenal web in a patient with situs inversus and apple peel jejunal atresia. *Pediatr Surg Int* 2004; 20(4): 301-303.
6. Tryfonas GI, Chaidos C, Avtzoglou PP, Zioutis J, Klokaris A, Papanastopoulos A. Partial situs inversus: duodenal obstruction in a neonate with isolated levocardia. *J Pediatr Surg* 1992; 27(12): 1584-1586.
7. Chandran H, Upadhyay V, Pease PW. Multiple organ malrotation syndrome with duodenal atresia: a case report. *Pediatr Surg Int* 1999; 15(1): 61-62.
8. Cacciaguerra S, Gioviale M, Di Benedetto A. The importance of detailed diagnostic assessment in a case of partial situs inversus. *Pediatr Surg Int* 1998; 13(7): 531-532.
9. Ohno K, Nakamura T, Azuma T, et al. Evaluation of the portal vein after duodenoduodenostomy for congenital duodenal stenosis associated with the preduodenal superior mesenteric vein, situs inversus, polysplenia, and malrotation. *J Pediatr Surg* 2007; 42(2): 436-439.
10. Adeyemi SD. Combination of annular pancreas and partial situs inversus: a multiple organ malrotation syndrome associated with duodenal obstruction. *J Pediatr Surg* 1988; 23(2):188-191.
11. Ruben GD, Templeton JM Jr., Ziegler MM. Situs inversus: the complex inducing neonatal intestinal obstruction. *J Pediatr Surg* 1983; 18(6): 751-756.
12. Akel S, Halabi J, Shawis R. Abdominal situs inversus with congenital duodenal stenosis: rare association. *Eur J Pediatr Surg* 1998; 8(1): 55-57.
13. Fonkalsrud EW, Tompkins R, Clatworthy HW, Jr. Abdominal manifestations of situs inversus in infants and children. *Arch Surg* 1966; 92(5): 791-795.
14. Noack F, Sayk F, Ressel A, Berg C, Gembruch U, Reusche E. Ivemark syndrome with agenesis of the corpus callosum: a case report with a review of the literature. *Prenat Diagn* 2002; 22(11): 1011-1015.



VASSA

VASCULAR SOCIETY OF SOUTHERN AFRICA 2010 CONGRESS

Thursday 14 - Sunday 17 October 2010

KwaMaritane, North West Province

Congress Secretariat:

RSVP Events Management

Telephone: (011) 463-4063

Email: rsvp@yebo.co.za