



CLINICAL IMAGES

Persistent pain following ankle sprain: Bilateral accessory soleus muscles

M Neethling-du Toit, R V P de Villiers, E W Derman

A 22-year-old rugby player presented with persistent left ankle pain, especially with plantar-flexion during weight bearing, for 4 months following an innocuous lateral ankle sprain. The left ankle revealed reduced plantar-flexion range of motion with tenderness on palpation of the anterior-lateral ankle gutter and forced plantar flexion reproduced his discomfort.

Ultrasound demonstrated a left accessory soleus muscle (Fig. 1). Magnetic resonance imaging (MRI) of both ankles (Figs 2 and 3) showed a large accessory soleus muscle between the flexor hallucis longus muscle belly and the Achilles tendon inserting onto the posteromedial edge of the calcaneus via a thin tendinous insertion. A similar accessory soleus muscle with different insertion was demonstrated on the asymptomatic right ankle.

Following corticosteroid infiltration around the muscle sheath, brief immobilisation, physiotherapy and strengthening and ankle rehabilitation, he returned to sport after 4 weeks.

Discussion

Persistent ankle pain following ankle sprain remains a difficult diagnostic and management dilemma.¹ To our knowledge, this is the first report of a patient with bilateral accessory soleus muscles where a unilateral muscle injury caused persistent pain following minor ankle sprain. The accessory soleus muscle is a rare anatomical variation (0.7 - 10% of individuals²) usually presenting as a bulging soft-tissue mass postero-medially between the distal tibia and the Achilles tendon. It presents commonly in the second and third decades of life, when the muscle undergoes hypertrophy through sporting activity;³ five varieties of insertion sites have been described.³

Drs Neethling-du Toit and de Villiers work for Drs Van Wageningen and Partners at the Sports Science Orthopaedic Unit, Newlands, Cape Town. Professor Derman is affiliated to the UCT/MRC Research Unit for Exercise Science and Sports Medicine, Human Biology, University of Cape Town.

Corresponding author: EW Derman (wayne.derman@uct.ac.za)

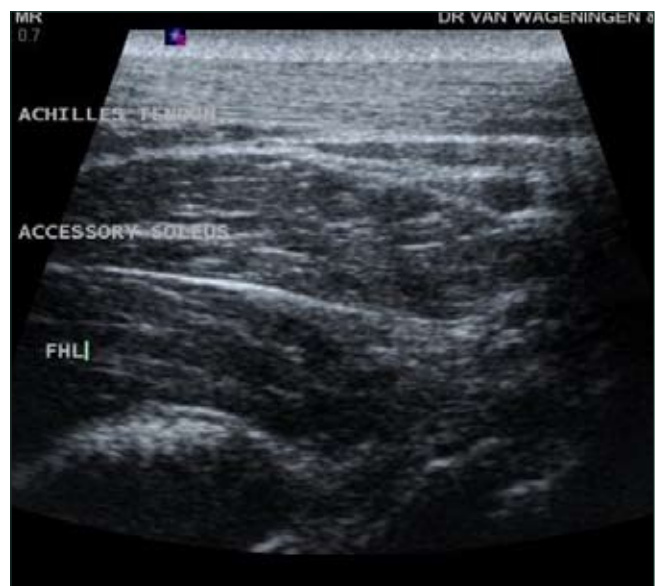

Fig. 1. Ultrasound of left accessory soleus muscle: same echogenicity and appearance as the underlying flexor hallucis longus muscle.

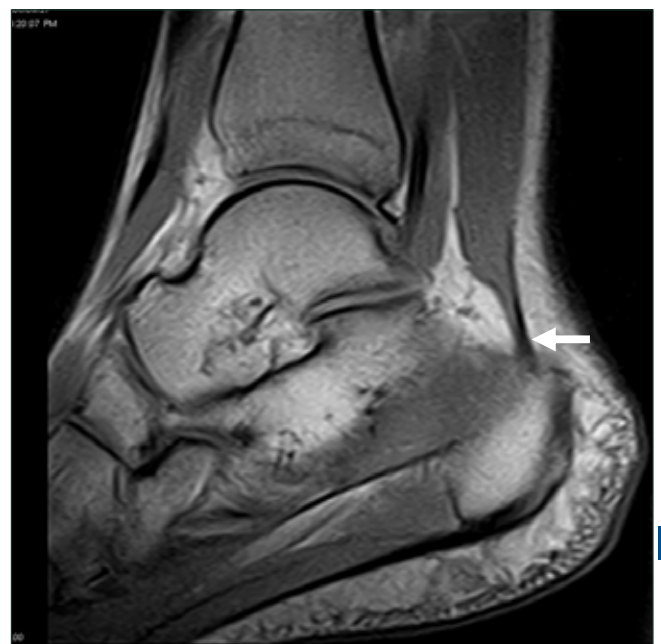

Fig. 2. Left ankle MRI: posteromedial insertion (arrow) of the accessory soleus muscle onto the calcaneus via a thin tendon.

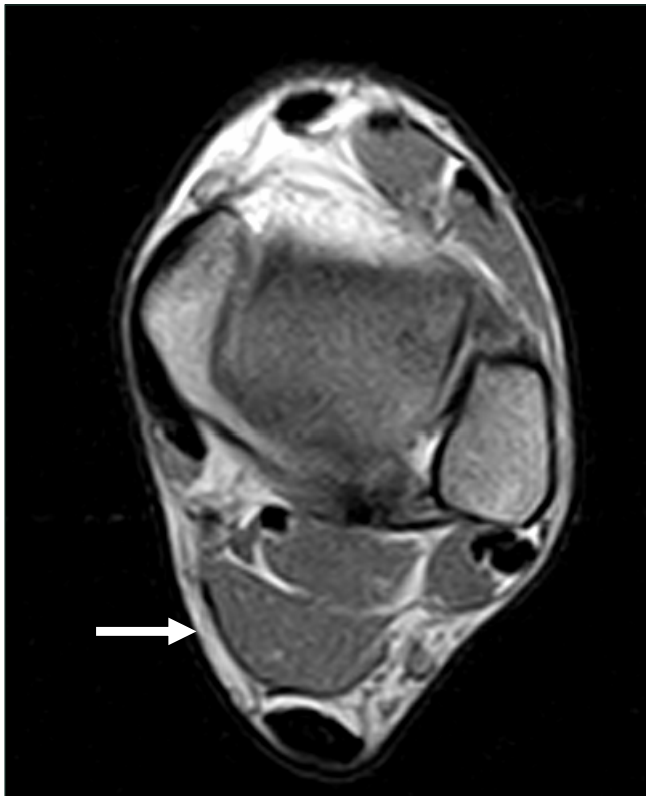


Fig. 3. MRI of accessory soleus muscle belly (arrow) lying between the Achilles tendon and the flexor hallucis longus muscle belly.

Ultrasound and MRI effectively demonstrate a soft-tissue mass anterior to the Achilles tendon. MRI is the examination of choice, enabling confirmation of the muscle injury and exclusion of other conditions. 25% of cases are asymptomatic and need no treatment. In symptomatic patients, treatment options include ultrasound-guided corticosteroid injection followed by rehabilitation, while surgical options include fasciotomy or excision of the accessory muscle. Heightened clinical awareness of the accessory soleus muscles and appropriate imaging studies yield definitive diagnosis.

1. Brukner P, Khan K. The difficult ankle. *Aust Fam Physician* 1991; 20: 919-930.
2. Kouvalchouk JF, Lecocq J, Parier J, Fischer M. The accessory soleus muscle: a report of 21 cases and a review of the literature. *Rev Chir Orthop Reparatrice Appar Mot* 2005; 91: 232-238.
3. Christodoulou A, Terzidis I, Natsis K, Gigis I, Pournaras J. Soleus accessorius, an anomalous muscle in a young athlete: case report and analysis of the literature. *Br J Sports Med* 2004; 38: e38.