

Clinical Outcomes Following Reduction and Pinning of Lesser Arc Injuries Without Repair of the Scapholunate Interosseous Ligament.

By

Thomas Hilton

HLTTH0004

Submitted to the University of Cape Town
in fulfillment of the requirements for the degree

Master of Medicine (MMed) Orthopaedic Surgery

Faculty of Health Sciences
University of Cape Town

Date of submission: 15 February 2016

Supervisor: Dr Michael Held
Consultant Orthopaedic Surgeon
Department of Orthopaedic Surgery
University of Cape Town

Co-supervisor: Dr Michelle Maree
Consultant Orthopaedic Surgeon
Department of Orthopaedic Surgery
University of Cape Town

The copyright of this thesis vests in the author. No quotation from it or information derived from it is to be published without full acknowledgement of the source. The thesis is to be used for private study or non-commercial research purposes only.

Published by the University of Cape Town (UCT) in terms of the non-exclusive license granted to UCT by the author.

Table of Contents

Declaration page

Abstract

1. Acknowledgements
2. List of Tables
3. List of Figures
4. Abbreviations
5. Part A: Introduction and Literature Review
 - a. Objectives
 - b. Methods
 - c. Background to research question
 - d. Wrist anatomy and biomechanics
 - e. Pathomechanics & classification of PLD's
 - f. PLD's as a clinical entity
 - g. Summary of the literature
 - h. Areas for further research
 - i. Aims
 - j. References
6. Part B: Manuscript in Article Format
 - a. Journal information
 - b. Title page
 - c. Abstract
 - d. Introduction
 - e. Methods
 - f. Results
 - g. Discussion
 - h. Conclusion
 - i. Tables and figures
 - j. Letter of submission
 - k. Contribution of co-authors
 - l. References
7. Appendices
 - a. HREC letter
 - b. Consent form
 - c. Scores
 - d. Instructions to authors Journal of Hand Surgery Asia-Pacific Volume

DECLARATION

I, Thomas Laurence Hilton, hereby declare that the work on which this dissertation is based is my original work and that neither the whole work nor any part of it has been, is being, or is to be submitted for another degree in this or any other university.

I empower the university to reproduce for the purpose of research either the whole or any portion of the contents in any manner whatsoever.

Signature:

Signed by candidate

Date: 15 February 2016

2. Abstract

Study Rationale

Purely ligamentous lesser arc, Mayfield grade 3 and 4, perilunate dislocations are uncommon. Current recommendations are for open reduction and repair of the interosseous ligaments. This study proposes a less invasive treatment with closed reduction where at all possible, with open performed if closed not achievable, and pinning alone without repair of the scapholunate interosseous ligament. We hope to show that equivocal, if not improved, results can be obtained when compared with current literature while still maintaining the ability to reconstruct the interosseous ligaments should wrist instability ensue.

Methods

Dislocations were reduced anatomically and held with buried k-wires which were removed at 6 weeks with no specific rehabilitation protocol observed. Subjective assessment included MAYO wrist scoring system, wrist range of movement, instability and grip strength testing. Radiological measurements included scapholunate distance, scapholunate angle, radiolunate angle and osteoarthritis.

Results

10 male patients, median age of 35, were followed-up for a median of 22 months. 7 patients underwent a closed reduction and anatomical pinning while 3 underwent open reduction due to unachievable reduction by closed means. All of these patients presented at a median of 14 days after the injury occurred. None of the patients had their scapholunate ligaments repaired or reconstructed. MAYO scores included, 3 excellent scores, 2 good scores and 5 fair scores. Instability was found clinically in 1 asymptomatic patient who had a positive Watson shift test. Radiological scores include a median scapholunate distance of 2mm, a scapholunate angle of 70° and a radiolunate angle of 15°. Osteoarthritis was found in 2 patients, all of whom were asymptomatic.

Discussion

Current recommendations in the literature are that PLDs should be reduced via an open surgical technique with repair of the SLIL and percutaneous pinning. However the results of this treatment strategy are not optimal and do not confer uniformly good results. We propose a closed anatomical reduction and percutaneous pinning of the PLD. Our study shows that the majority of patients will demonstrate good function and pain scores when managed this way. A smaller number of these injured wrists will go on to develop instability. However the advantage of our method over the current recommendations is that when this happens the reconstruction of the SLIL will be made easier through a naïve surgical field.

Conclusion

We recommend the closed reduction and anatomical pinning of a purely ligamentous lesser arc injury. This treatment strategy yields good results at medium term follow-up and preserves the option for the reconstruction of the scapholunate interosseous ligament should instability develop.

3. Acknowledgements

To my wife and family for their support and patience.

To all the lecturers of the Department of Orthopaedics at UCT for their enthusiastic approach to practicing and teaching Orthopaedics.

To Dr Held and Dr Maree for showing me commitment to my patients, teaching me how to interrogate the literature and making me an enthusiastic researcher. The careers of the Orthopaedic surgeons they mentor are testimony to their knowledge and dedication to teaching. I would like to thank Dr Held for his supervision of this project from its inception and his guidance in completing it for publication.

This work was inspired by Dr Michelle Maree whose knowledge and passion in the subject of Hand Surgery led to the question of how to improve the treatment of patients with a perilunate dislocation being asked, as well as the development of the treatment protocols for this injury that are now used in the Martin Singer Hand unit.

To my co-author Dr David Chivers who helped greatly in the initial conceptualization and protocol phase of this project as well as assisting with the challenging data collection, I give thanks.

I would like to thank Dr Michael Solomons who was invaluable during the review of the manuscript prior to submission for publication.

I would also like to acknowledge the assistance given to me by Henri Carrera in supervising the statistical analysis of this work.

4. List of tables

Literature Review Tables

Table 1: Comparison of treatment methods and outcomes of PLD's

Publication Ready Manuscript Tables

Table 1: Results of Entire Patient Cohort Including Subjective and Objective Assessments

Table 2: Comparison of the Literature - Treatment Methods and Outcomes

Table 3: Reasons for a Less Invasive Approach

5. List of figures

Publication Ready Manuscript Figures

Figure 1: Interpretive drawing of the scapholunate interosseous (SLI) ligament from the radial perspective with the radial styloid and scaphoid removed.

Figure 1: An illustration of the volar (A) and dorsal (B) intracapsular ligaments.

Figure 2: Showing stages of perilunate dislocation

Figure 4: Picture to show the lesser and greater arcs of the wrist

Figure 5: Picture to demonstrate radiolunate angle (Internet)

Figure 3: Picture to demonstrate scapholunate angle (Internet)

Publication Ready Manuscript Figures

Figure 1a and 1b: Postoperative X-rays to Show Anatomical Reduction and Wire Placement. Figure 1a shows an anterior-posterior x-ray of the wrist joint. Figure 1b shows a lateral x-ray of the wrist joint.

Figure 2: Flow Diagram to Summarise Treatment Protocol of Perilunate Dislocations (PLD)

6. Abbreviations

AP – Anteroposterior

CT – Computed tomography

DISI – Dorsal intercalated segment instability

LT - Lunotriquetral

MRI – Magnetic resonance imaging

PA – Posteroanterior

PLD – Perilunate dislocation

PLFD – Perilunate fracture dislocations

PROMs – Patient related outcome measures

RLA – Radiolunate angle

SL – Scapholunate

SLA – Scapholunate angle

SLAC – Scapholunate advanced collapse

SLD – Scapholunate distance

SLIL – Scapholunate interosseous ligament

SNAC – Scaphoid non-union advanced collapse

TSPLD – Trans-scaphoid perilunate dislocation

VISI – Volar intercalated segment instability

7. Part A: Introduction & literature review

Clinical Outcomes Following Reduction and Pinning of Lesser Arc Injuries Without Repair of the Scapholunate Interosseous Ligament.

This chapter was structured according to the following points:

- a. Objectives
- b. Methods
- c. Background to research question
- d. Wrist anatomy and biomechanics
- e. Pathomechanics & classification of PLD's
- f. PLD's as a clinical entity
- g. Summary of the literature
- h. Areas for further research
- i. References

a. Objectives

The objectives of this literature review are to:

- Clarify the definition, epidemiology, aetiology, patho-anatomy, clinical and radiographic features and natural history of perilunate dislocations.
- To research the treatment options used and critically analyse the literature reporting outcomes of these described methods
- To identify areas of potential future research

b. Methods

Google Scholar and Pubmed internet search engines were used to search online databases. The key strings 'perilunate dislocations', 'wrist instability', 'lesser arc injuries' and 'scapholunate interosseous ligament' were used to search for articles. Google Scholar produced 2830 results and Pubmed 932 articles. All articles not written in English and prior to

1960 were excluded. Of the remainder 39 were selected based on their relevance. Review articles on the subject were analysed and their references were researched.

The chapter on wrist instability in Green's Operative Hand Surgery was reviewed and the relevant references researched. All relevant articles were obtained from the University of Cape Town library either in hardcopy form or in digital format.

Quality of evidence

The evidence on the topic is limited to case studies and small case series due to the rarity of this injury. Any larger studies included a heterogeneous group of patients with similar injuries from which the lesser arc data was extracted. All the studies can be classified as levels IV and V of evidence and there is no higher level of evidence available on the topic.

c. Background research question

Lesser arc injuries or perilunate dislocations (PLD) are rare and have devastating consequences for the patient. The crux of these injuries is that the scapholunate interosseous ligament (SLIL) is torn which results in scapholunate dissociation. This in turn leads to carpal instability and scapholunate advanced collapse, which clinically manifests as an unstable and painful wrist affecting patient function.

The recent trend in the literature is to treat these injuries with open reduction, debridement, repair of the SLIL and anatomical pinning. This is largely due to the historic treatment of PLDs, i.e. plaster casting, which led to uniformly poor results. However the results of open treatment of PLDs has not yielded excellent results with many patients still developing wrist instability and requiring reconstruction of the SLIL.

d. Wrist anatomy and biomechanics

Carpal anatomy

It is crucial to understand carpal anatomy when treating wrist injuries. 'The human wrist is a product of millions of years of evolutionary adaptation that has culminated in a specialised unit that is able to accurately position the hand in a nearly hemispherical arc of movement.[1] The carpus consists of 8 carpal bones that are arranged in 2 rows. The distal row of the carpus, which includes the trapezium, trapezoid, capitate and hamate is relatively immobile due to strong intercarpal ligaments and its close approximation to the index and middle finger metacarpals. This row is considered part of the fixed hand unit and moves in response to the extrinsic musculotendinous forces created in the forearm.' [1]

The proximal row of the carpus includes the scaphoid, lunate and triquetrum, it is more mobile than its distal counterpart and accounts for most of wrist movement. There are no muscular or tendinous insertions on the proximal row thus making this an intercalated segment between the distal row and the radius.[1]

The ligaments of the wrist are categorised as intra-capsular or intra-articular. They can be further sub-divided into intrinsic or extrinsic ligaments. Extrinsic ligaments originate from the radius or ulna and insert onto the carpus. Intrinsic ligaments connect 2 carpal bones.[2] The SLIL is an intrinsic ligament and connects the scaphoid to the lunate at the dorsal, proximal and volar margins of the articulating surfaces making it C-shaped. Its 3 sub regions have different material and anatomic properties. It is thickest and strongest at its dorsal aspect which is its most critical component. It has the ability to resist translational, torsional and distractive moments. The palmar component is considerably thinner but has important contributions in rotation of the wrist.[2]

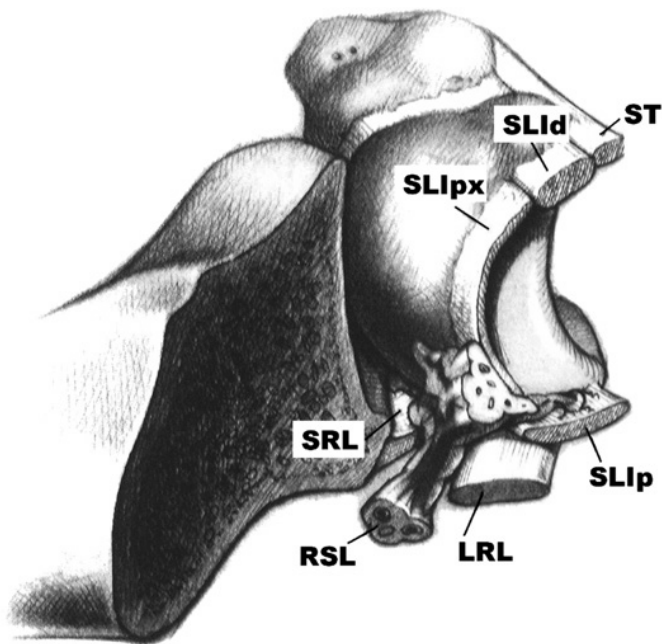


Figure 7: Interpretive drawing of the scapholunate interosseous (SLI) ligament from the radial perspective with the radial styloid and scaphoid removed. The SLI ligament is made up of dorsal (d), proximal (px), and palmar (p) regions. The palmar ligaments, attaching the lunate to the radius, are the long radiolunate (LRL) and short radiolunate (SRL). The scaphotriquetral (ST) and radioscapolunate (RSL) ligaments are also portrayed. [2]

The critical extrinsic ligaments arise from the radius and ulna and attach to the capitate and lunate. They can be found both on the dorsal and volar aspect of the wrist. There is an area of volar capsule that is weak between 2 of these ligaments, namely the ulnocapitate and the radioscapocapitate, through which the lunate may dislocate. This space is termed the space of Poirier.[2, 3]

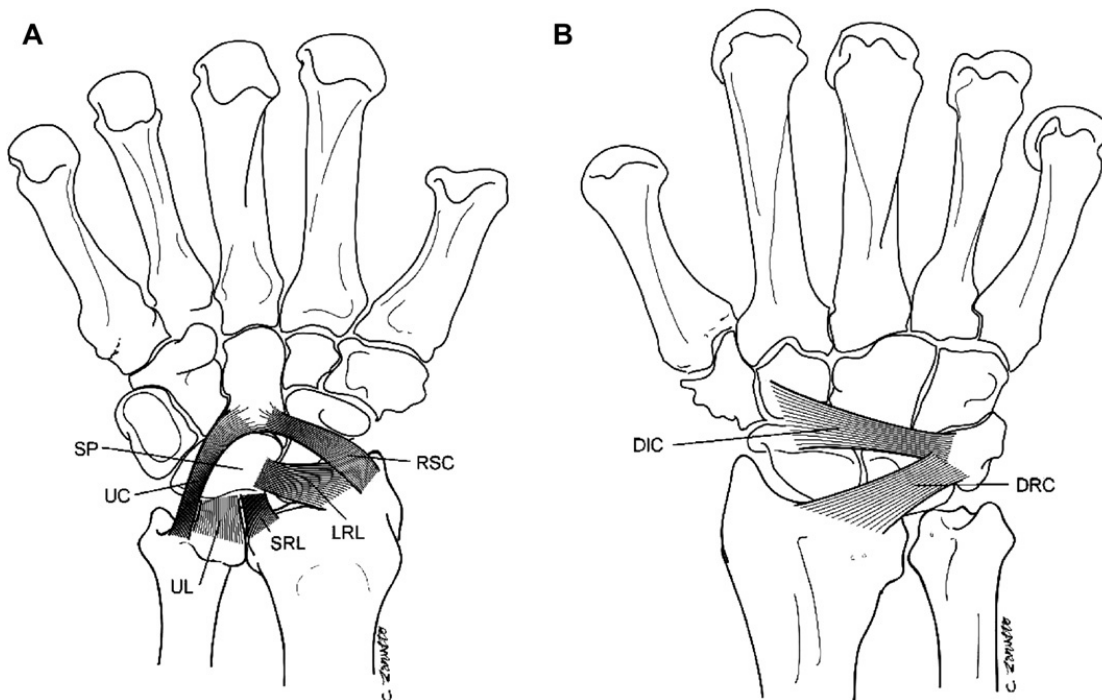


Figure 8: An illustration of the volar (A) and dorsal (B) intracapsular ligaments. The radioscaphocapitate (RSC) and ulnocapitate (UC) ligaments connect the capitate to the distal forearm. The long radiolunate (LRL), short radiolunate (SRL), and ulnolunate (UL) ligaments attach the lunate to the distal forearm. In between is the space of Poirier (SP), where the lunate may herniate through the capsule in a lunate dislocation. The main dorsal intracapsular ligaments are the dorsal intercarpal (DIC) and dorsal radiocarpal (DRC) ligaments. [2]

Wrist mechanics – Stability and movement

Stability

The SLIL is considered the primary stabiliser of the wrist and is supported by an envelope of secondary stabilisers which are orientated obliquely to the axis of wrist movement (flexion-extension). The secondary stabilisers are made up of the other intrinsic and extrinsic ligaments as described above. Both the primary and secondary stabilisers are important in maintaining normal scapholunate kinematics. Injury to just one of these ligaments is not enough in itself to cause instability but when multiple ligaments are injured instability may result. However should the SLIL alone be torn the secondary stabilisers in turn are vulnerable to attritional wear and thereby worsening the degree of

instability. This redundancy of the primary and secondary stabilisers explains why the rupture of a single ligament is insufficient to show instability or abnormalities in the posture of the scaphoid or lunate on statically filmed plain radiographs.[1, 2]

Movement

Apart from inferring stability to the wrist joint during motion the interosseous ligaments are important in contributing to the relative motion of one bone on another during wrist movement as although the proximal row moves in the same primary direction there is considerable multiplanar movement between the interosseous joints of this row.

There is disagreement concerning the individual contributions of the carpal bones to global wrist movement. This is important when trying to appreciate wrist mechanics in order to understand the consequences of injury and put together rehabilitation programmes. These programmes aim to reduce strains on the scapholunate interosseous ligament during post-injury or post-repair wrist motion. The controversies include whether the scaphoid can be considered to be kinematically part of the proximal carpal row or an independent coupling link between the two rows. Recently the concept of the dart throwers motion has come to the fore. This motion consists of a combination of flexion-extension and radioulnar deviation, i.e. radial-extension to ulnar flexion. It is an extremely functional motion that is used in a number of daily, sporting and recreational activities. However when the SLIL becomes incompetent movement between the two bones increases, which puts strain on the secondary stabilisers. Over time these ligaments undergo attritional wear which is thought to be the cause for dorsal intercalated instability of the wrist.[1]

Wrist instability

Scapholunate wrist instability is regarded as a spectrum of injury whose current definition is of a wrist that exhibits symptomatic dysfunction, is unable to bear loads and does not demonstrate normal kinematics throughout the complex arc of wrist motion.[1]

e. Pathomechanics & classification of PLD's

These injuries affect both soft tissues and bony elements of the wrist and present in 2 common patterns. The degree, duration and direction of the force dictates whether the injury will be a purely ligamentous, i.e. lesser arc injury or PLD, or whether it will be associated with a fracture, i.e. greater arc injury. Greater arc injuries are the more common injury pattern occurring up to 65% of the time.

The defining characteristic of these injuries is dorsal dislocation of the capitate head from the lunate concavity which remains in its anatomical position in the lunate fossa of the radius. A volar lunate dislocation is the final stage of a perilunate injury, the capitate has reduced from its dorsally dislocated position to become collinear with the radius thereby dislocating the lunate in the carpus.[3]

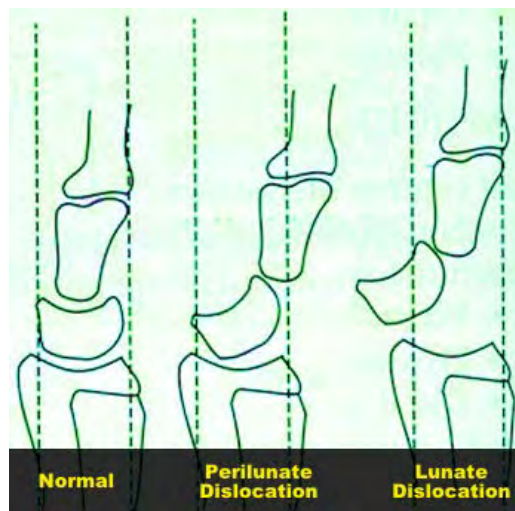


Figure 9: Showing stages of perilunate dislocation

Reproduced from Department of Emergency Medicine, School of Medicine, University of Maryland (https://umem.org/educational_pearls/2469). Accessed February 10th 2016.

The pathomechanics are of a specific loading pattern which has been described by Mayfield. The pattern is of a radial sided force exerted to a hyperextended wrist with a degree of ulnar deviation and intercarpal supination.[3] Mayfield was able to describe 4 stages of progressive ligamentous disruption.

Mayfield[4]

1. Disruption of scapholunate ligamentous complex.
2. Force propagates through space of Poirier and interrupts the lunocapitate connection.
3. Lunotriquetral connection violated and entire carpus separates from the lunate
4. Lunate dislocates from its fossa into the carpal tunnel and the capitate becomes collinear with the radius.

Herzberg further described these injuries.

Hertzberg [3, 4]

1. Lunate stays in its fossa (perilunate dislocation)
2. Lunate is dislocated from its fossa (lunate dislocation)
 - a. $< 90^{\circ}$ of lunate rotation
 - b. $> 90^{\circ}$ of lunate rotation

Both the Mayfield and Herzberg classifications are useful in trying to understand the various injury patterns and the sequence of pathomechanical forces and ligamentous or bony failures required to produce these various configurations.

f. PLD's as a clinical entity

PLD's almost always result from high energy trauma such as car accidents, falls from a height and some sporting activities. They occur most commonly in men with an average age of 30.[2, 5] Patients often have associated injuries, due to the high energy nature of the injury, which often take priority in the treatment ladder. The direction is dorsal 97% of the time and 10% are open.[3, 6]

On clinical examination a high index of suspicion needs to be maintained to correctly diagnose an acute isolated scapholunate dislocation. Tenderness is present but diffuse and often inhibits further testing. Soft tissue swelling is often severe and precludes the accurate diagnosis of a wrist effusion which in itself indicates a severe intra-articular wrist injury.

Neurovascular examination is usually normal except in severe injuries in which case the median nerve will be involved especially in lunate dislocations.

As much as 25% of these injuries can be missed on initial presentation and should this be the case patients may present with a sub-acute injury (1-6 weeks).[1-3, 6, 7] In this scenario they may complain of painful popping or clicking with wrist movement, decreased range of motion and grip strength and well localised pain of the scapholunate interval dorsally. The examination of these wrists should include the scaphoid shift test described by Watson. This test is used to elicit subtle degrees of scaphoid instability. This test may be falsely positive in up to a third of individuals due to ligamentous laxity. Should there be clinical suspicion of a ligament injury in these patients they should undergo ancillary imaging or arthroscopy.

Investigations

X-rays

Series includes: high quality posteroanterior (PA), lateral and anteroposterior (AP) clenched fist radiographs. Contralateral views may be obtained for comparison. The lateral should be true and should show either the scaphoid tubercle and pisiform maximally superimposed or collinearity between the radius, capitate and third metacarpal.

Measurement of angles if scapholunate dissociation is suspected

Measurement of intercarpal angles on static films is difficult with wide inter-observer variability and is therefore not routinely done or an approximation is performed. These lines are used to indicated instability either in the dorsal or volar plane.

One of these angles is the radiolunate angle which is a perpendicular line drawn from the lunate tangent. This angle determines the lunate posture in the sagittal plane. A radiolunate angle of more than 15 degrees in the volar direction is indicative of volar intercalated segment instability (VISI) and in the dorsal plane is indicative of dorsal

intercalated segment instability (DISI). A DISI is far more common in the scenario of a SLIL disruption.

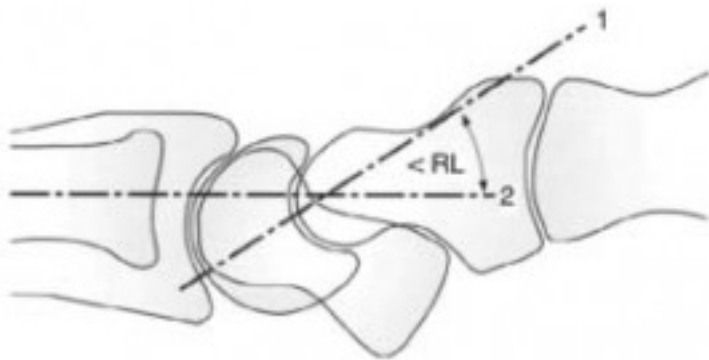


Figure 10: Picture to demonstrate radiolunate angle[8] (Internet)

The scapholunate angle is measured between the scaphoid tangent and the perpendicular to the lunate tangent. It normally measures 46 degrees (range 30 – 60). If above 70° it is suggestive of a flexed scaphoid or rotatory subluxation.

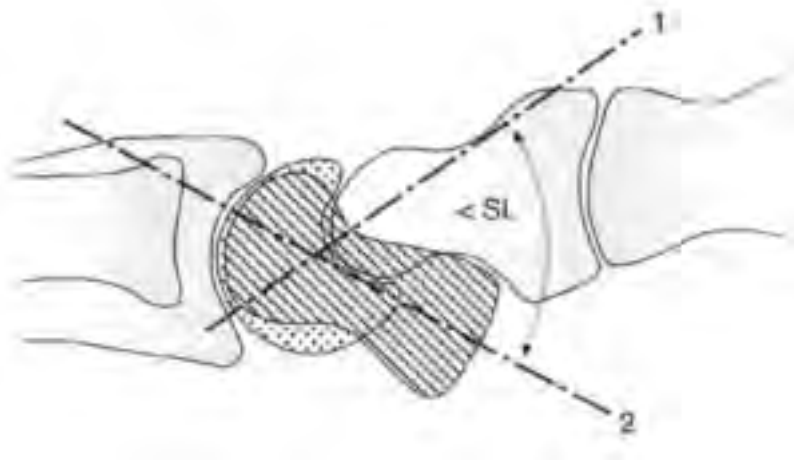


Figure 11: Picture to demonstrate scapholunate angle (Internet)

Other signs of advanced scapholunate instability on x-ray include scapholunate diastasis, a positive ring sign and foreshortening of the scaphoid on the PA film. For scapholunate diastasis a PA film or AP clenched fist may demonstrate a widening of the scapholunate joint in excess of the other intercarpal joints. 2-3mm is considered suspicious not diagnostic of dissociation. The scaphoid ring sign is seen on the PA view where the distal pole of the scaphoid tubercle overlaps the scaphoid waist. Foreshortening is seen when

the scaphoid is flexed more than 70° and it appears foreshortened on the PA film compared to the contralateral wrist.

Stress radiographs

These radiographs are used when instability is suspected clinically but static radiographs are normal. They include the AP clenched fist view, lateral full flexion and extension, full ulnar and radial deviation PA films and the carpal stress test.

The AP clenched fist may demonstrate pathologic scapholunate widening under axial load conditions. The wrist should be in neutral flexion-extension. The lateral views may show subtle differences in intercarpal motion but need to be compared to the contralateral uninjured wrist. The carpal stress test is performed with the thumb and index fingers under traction and may show a step-off at the scapholunate joint.

Ancillary studies

These studies are used to confirm a clinically suspected diagnosis of SLIL dissociation and should not be used in isolation. Treatment is still based on patient's symptoms and clinical examination. This is due to their relatively higher rate of false positives. Wrist arthrography which was previously deemed to be the most sensitive test for injury has been supplanted MRI or CT arthrography. However both arthrography and MRI give only anatomic evaluations without any functional information.

To better assess function status of the wrist cineradiology or simple fluoroscopy can be helpful in demonstrating abnormal wrist kinematics. However the gold standard to evaluate both anatomical, interosseous and extrinsic ligaments, and functional status is wrist arthroscopy. The ability to pass the arthroscope from the radiocarpal joint into the midcarpal joint through the scapholunate interval is termed the drive-through sign. This sign indicates a complete tear of the scapholunate ligament and laxity of its secondary stabilisers.

f. Summary of the literature

Conservative treatment of wrist instability

Historically PLDs were treated with closed reduction and casting in plaster of Paris however the results of this treatment were less than satisfactory.[9, 10] In the past decade there has been a big change in how these injuries are treated. It is now recommended in the literature that the standard of care for these injuries should include open reduction of the dislocation and repair or reconstruction of the SLIL, together with temporary stabilisation of the wrist joint with various fixation modalities described such as using K-wires/ screws /inter-osseous wires/interosseous sutures.[3, 7, 11] However there is no consensus in the literature about how to achieve this and no one method has been shown to outperform the others in terms of good medium or long term clinical results. Also although, according to the literature, the method of open reduction and repair of the SLIL has improved the outcome of these injuries compared to closed means, the results are still not convincing.

There is no debate that accurate reduction of the carpus is imperative to good long term outcome.[3] According to Adkison a more conservative method of treatment (plaster of paris) has high failure rates due loss of reduction of the carpus with time once the temporary fixation had been removed.[10] Failure to maintain reduction caused significant structural collapse and accelerated carpal osteoarthritis. From this the conclusion was that these injuries are inherently unstable, and reduction cannot be maintained with closed methods alone.[9, 10, 12]

It is this premise that has driven the more aggressive treatment of these injuries with open surgery being advocated to ensure a perfectly anatomical reduction, seeing is believing so to speak. There is also no debate as to the importance of the SLIL in normal wrist biomechanics.[1, 13-15] It has been described as the cruciate of the wrist and it has been proposed that its integrity is essential for normal wrist movement and stability.[1] It this stands to reason that its rupture will result in abnormal wrist biomechanics which will lead to instability of the carpus which in turn will result in accelerated post traumatic osteoarthritis.[3] The clinical manifestation of this will be pain, stiffness and weakness. However despite this there is no clear evidence to suggest that acute repair of the

scapholunate interosseous ligament (SLIL) is advantageous over accurate reduction and pinning alone.

In a following study Apergis compared 8 cases of closed reduction and casting alone, to 20 cases of open reduction and pinning. It must be noted that there was significant heterogeneity amongst his patient's injuries and their treatment. He concluded that perilunate fracture dislocations are too unstable to be treated with closed reduction and that open reduction presupposes reparation of the torn scapholunate ligament, to obtain normal carpal kinematics. However no comparison was made between closed reduction and casting, closed reduction with pinning and open reduction with pinning. Currently there is only one small study by Inoue and Kuwahata that compares closed reduction and pinning to open reduction and pinning. In this study they found no statistical difference in outcome between these two groups. [9]

In neither of the above papers did any of the patients with casting alone do well. The open reduction and pinning group had a 65% good outcome, with any poor outcomes in this group attributed to scaphoid injuries and their resulting non-unions.[12] The paper by Apergis was considered to be a landmark article on which many other articles have based their premise that open reduction should be the standard of care.

Open reduction, fixation and repair

Since these articles mentioned above the literature has moved on to assessing the outcomes of open reduction of the dislocation and repair of the scapholunate ligament. Of these papers, one by Forli et al [16] has the longest follow up with an average of 13 years (range, 10-25). He had a total of 11 patients with perilunate dislocations, all of whom underwent open reduction and internal fixation. 6 of the 11 had the dorsal SLIL repaired while the other 5 did not. A limitation of his study is that in his follow up he does not differentiate the outcomes between these two groups. He reports 3 excellent, 2 good, 5 fair and 1 poor, with an average Mayo score of 76 (range, 60 - 90). The mean range of motion (ROM) was 76% and grip strength 87% when these 2 parameters were compared to the uninjured side. At final follow-up only three patients showed no signs of osteoarthritis on x-ray. He concludes that there is a tendency for patients to show degenerative changes on

x-ray with time and that good reduction results in a better radiological score. While on the other hand poor reduction results in worse degenerative changes, but that this does not necessarily translate into a poor functional outcome.[16]

If we go deeper into the literature and look at methods of open reduction and repair Trumble uses a combined dorsal and volar approach to the wrist. [17] He routinely repairs the SLIL and protects it with a looped interosseous wire. The average of his 22 patient follow-up was 49 months. He assessed return to work and function, not pain. Only 10 of the 22 patients in his study returned to the same job. Sixteen patients returned to their previous level of activity but there is no further detail to this. The range of movement arc was 80% of the normal side and grip strength 77% of the uninjured side (See Table 1). He did not assess instability. Sixteen patients had to return to theatre to remove the broken interosseous wire. On x-ray however, there was no deterioration of scapholunate gap or scapholunate angle over time. The average scapholunate gap was 2.2mm and Scapholunate angle 49°. He did not comment on the presence or absence of osteoarthritis. No comment was made regarding integrity of the scapholunate ligament repair at time of wire removal. He believes his good results are because of the looped interosseous wire as k-wires do not provide the necessary compression across the scapholunate (SL) gap and cannot protect the ligament repair.

Table 2: Comparison of treatment methods and outcomes of PLD's

	Number of patients	Follow-up period	Average Mayo Wrist Score	Flexion / Extension Arc	Percentage of normal side	Grip	Percentage of normal side
Forli (2010)	11	10 - 25y	77	94°	76%	36kg	87%
*Trumble (2004)	22	49m	-----	106°	80%	35kg	77%
*Hildebrand (2000)	6	3y 1m	66	82°	57%	35kg	73%
*Sotereanos (1997)	3	2y 6m	65.5	89°	71%	23kg	77%
* All open +/- combined volar/dorsal							

Sotereanos et al looked at 11 patients with PLFD of which 3 had pure PLD.[18] All of his patients had open volar and dorsal reduction and pinning, and both dorsal and volar ligaments were repaired, and protected in a plaster cast for 8 weeks. Wires were removed at 3 months. Of the group with a pure PLD he achieved a Mayo wrist score of 1 excellent, 1 good and 1 fair result. The patient with the fair score developed a scapholunate advanced collapse (SLAC) wrist. One patient developed flexor adhesions but did not require tenolysis. Overall he was dissatisfied with his results.

Hildebrand et al had a total of 23 patients, 6 had an open reduction through a combined dorsal and volar approach.[19] Their results were very poor but in his groups he does not differentiate the patients with PLFD and PLD. Their average Mayo score was 66, Wrist ROM 57% and grip strength 73%. However, they had high complication rates and poor patient satisfaction. The complications included septic arthritis, pin tract sepsis, intractable pain requiring arthrodesis, arthrofibrosis and extensor pollicus longus (EPL) rupture.

g. Areas for further research

PLDs remain a treatment challenge to surgeons with the rarity of this injury making research difficult as even large referral centres might only see up to 4 cases per year. A focused multi-centered study on PLDs with higher numbers may assist with statistical analysis and therefore more reliable interpretation of results for treatment of this complex injury.

However when looking at the available literature it must be noted that the majority of papers compare a mixed cohort of patients. It reports outcomes of patients whose pathology ranges from isolated perilunate dislocations to perilunate fracture dislocations, which as a separate entity tend to have better outcomes than purely ligamentous lesser arc injuries as the SLIL is often still intact. To date there are no studies that have looked at the outcomes of isolated perilunate dislocations treated with closed / open reduction and K-wire fixation, alone, without repair of the SLIL

We acknowledge that these are high-energy injuries and that anatomical reduction is essential to a good outcome. Having said this we believe that an open procedure in a severely traumatised wrist, in order to repair a ligament that is most often of negligible integrity, as it has undergone tensile failure, is of little benefit. Also with a more conservative approach in the beginning one has the advantage of being able to reconstruct the SLIL at a later stage through a virgin surgical field should the patient develop instability and require reconstructive surgery. A further reason for not performing open surgery acutely is that in our experience, the SLIL is most often circumferentially torn and therefore suggest that it is of no benefit to only repair the dorsal ligament and leave the volar ligament which many of the current studies advocate. Those that do quote a combined volar and dorsal approach in order to repair both sides of the torn SLIL, often see arthrofibrosis as a result.

We believe that with attention to detail, an anatomical reduction can be performed closed and maintained sufficiently with pinning alone. Our results show that the majority of patients demonstrate good functional and pain scores. The few that go on to develop wrist instability may be reconstruct with relative ease through an unscarred surgical field.

i. References

1. Kuo, C.E. and S.W. Wolfe, *Scapholunate instability: current concepts in diagnosis and management*. The Journal of hand surgery, 2008. **33**(6): p. 998-1013.
2. Sauder, D.J., et al., *Perilunate injuries*. Hand clinics, 2010. **26**(1): p. 145-154.
3. Budoff, J.E., *Treatment of acute lunate and perilunate dislocations*. The Journal of hand surgery, 2008. **33**(8): p. 1424-1432.
4. Arner, M., *Green's operative hand surgery (Book)*. Acta Orthopaedica Scandinavica, 1999. **70**(4): p. 411-411.
5. Herzberg, G., *Perilunate and axial carpal dislocations and fracture-dislocations*. The Journal of hand surgery, 2008. **33**(9): p. 1659-1668.
6. Herzberg, G., et al., *Perilunate dislocations and fracture-dislocations: a multicenter study*. The Journal of hand surgery, 1993. **18**(5): p. 768-779.
7. Grabow, R.J. and L. Catalano, 3rd, *Carpal dislocations*. Hand Clin, 2006. **22**(4): p. 485-500; abstract vi-vii.
8. Cho, M.S., et al., *Assessment of four midcarpal radiologic determinations*. Surg Radiol Anat, 2006. **28**(1): p. 92-7.

9. Inoue, G. and Y. Kuwahata, *Management of acute perilunate dislocations without fracture of the scaphoid*. Journal of hand surgery (Edinburgh, Scotland), 1997. **22**(5): p. 647-652.
10. Adkison, J.W. and M.W. Chapman, *Treatment of acute lunate and perilunate dislocations*. Clin Orthop Relat Res, 1982. **(164)**(164): p. 199-207.
11. Blazar, P.E. and P. Murray, *Treatment of perilunate dislocations by combined dorsal and palmar approaches*. Tech Hand Up Extrem Surg, 2001. **5**(1): p. 2-7.
12. Apergis, E., et al., *Perilunate dislocations and fracture-dislocations. Closed and early open reduction compared in 28 cases*. Acta orthopaedica Scandinavica.Supplementum, 1997. **275**: p. 55-59.
13. Short, W.H., et al., *Biomechanical evaluation of the ligamentous stabilizers of the scaphoid and lunate: Part II*. J Hand Surg Am, 2005. **30**(1): p. 24-34.
14. Garcia-Elias, M., A.L. Lluch, and J.K. Stanley, *Three-ligament tenodesis for the treatment of scapholunate dissociation: indications and surgical technique*. J Hand Surg Am, 2006. **31**(1): p. 125-34.
15. Drewniany, J.J., A.K. Palmer, and A.E. Flatt, *The scaphotrapezial ligament complex: an anatomic and biomechanical study*. J Hand Surg Am, 1985. **10**(4): p. 492-8.
16. Forli, A., et al., *Perilunate dislocations and transscaphoid perilunate fracture-dislocations: a retrospective study with minimum ten-year follow-up*. The Journal of hand surgery, 2010. **35**(1): p. 62-68.
17. Trumble, T. and J. Verheyden, *Treatment of isolated perilunate and lunate dislocations with combined dorsal and volar approach and intraosseous cerclage wire*. The Journal of hand surgery, 2004. **29**(3): p. 412-417.
18. Sotereanos, D.G., et al., *Perilunate dislocation and fracture dislocation: a critical analysis of the volar-dorsal approach*. The Journal of hand surgery, 1997. **22**(1): p. 49-56.
19. Hildebrand, K.A., et al., *Dorsal perilunate dislocations and fracture-dislocations: questionnaire, clinical, and radiographic evaluation*. The Journal of hand surgery, 2000. **25**(6): p. 1069-1079.

8. Part B: Manuscript in article format

a. Journal information

Article submitted to:

The Journal of hand Surgery Asia-Pacific Volume

The Editor

Seoul National University Hospital
Room 8302
101 Daehak-ro Jongno-gu
Seoul 110-744
Republic of Korea

Phone: +82-2-2072-2360

Fax: +82-2-763-2360

E-mail: office@jhs-ap.org

Notes:

- Page numbers according to the journal have been omitted for the purpose of sequential numbering in the MMED submission.

b. Title page

Clinical Outcomes Following Reduction and Pinning of Lesser Arc Injuries Without Repair of the Scapholunate Interosseous Ligament.

Authors: Dr. T.L. Hilton, Dr. D. Chivers, Dr. M. Solomons, Dr. M. Held, Dr. M. Maree

Dr. Thomas L. Hilton MBChB(UCT), DA(SA), DipPEC(SA)

Corresponding author:

Home

11 Clive Street
Vredehoek
Cape Town
8000
Western Cape
South Africa

Work

Division of Orthopaedics Surgery
Groote Schuur Hospital
H49 OMB
Observatory
☎021 404 5118

tlhilton@hotmail.com

0027 (82) 796 7608

Dr. David Chivers MBChB(Wits)

Division of Orthopaedics Surgery
Groote Schuur Hospital
H49 OMB
Observatory
☎021 404 5118

megr@mweb.co.za

0027 82 903 7691

Dr. Michelle Maree MBChB(UCT), FCS (Orth)

Division of Orthopaedics Surgery
Groote Schuur Hospital
H49 OMB
Observatory

☎021 404 5118

mareemich@gmail.com

0027 82 358 8116

Dr. Michael Held MBChB(Germany), FCS(Orth), MMed(UCT)

Division of Orthopaedics Surgery

Groote Schuur Hospital

H49 OMB

Observatory

☎021 404 5118

Email.held@gmail.com

0027 84 447 8882

Dr. Michael Solomons MBChB(UCT), FCS(Orth)

Division of Orthopaedics Surgery

Groote Schuur Hospital

H49 OMB

Observatory

☎021 404 5118

docsol@iafrica.com

0027 82 784 3025

Ethics

Ethics approval obtained. Ethics number HREC REF: 226/2014.

University of Cape Town Human Research Ethics Committee

Old Main Building

Groote Schuur Hospital

Floor E52

Room 23

Observatory 7925

Conflict of interest

All named authors hereby declare that they have no conflicts of interest to disclose

Financial statement

No financial support was received for this study or publication including grants or pharmaceutical company support.

There was no commercial or financial involvement that might present an appearance of a conflict of interest related to the submission.

There was no sponsorship of the research that would prevent the authors publishing both positive and negative results or forbids the authors from publishing this research without the prior approval of the sponsor.

Funding Statement

This research received no specific grant from any funding agency in the public, commercial, or not-for-profit sectors.

Informed consent

Informed consent was taken from the patients prior to enrolment in the study and documented with the signing of a consent form.

c. Abstract

Introduction

Purely ligamentous lesser arc, Mayfield grade 3 and 4, injuries are uncommon. Current recommendations are for open reduction and repair of the interosseous ligaments. This study proposes a less invasive treatment with closed reduction where at all possible, with open performed if closed not achievable, and pinning alone without repair of the scapholunate interosseous ligament.

Methods

Dislocations were reduced anatomically and held with buried k-wires which were removed at 6 weeks with no specific rehabilitation protocol observed. Subjective assessment included MAYO wrist scoring system, wrist range of movement, instability and grip strength testing. Radiological measurements included scapholunate distance, scapholunate angle, radiolunate angle and osteoarthritis.

Results

10 male patients, median age of 35, were followed-up for a median of 22 months.

7 patients underwent a closed reduction and anatomical pinning while 3 underwent open reduction due to unachievable reduction by closed means. All of these patients presented at a median of 14 days after the injury occurred. None of the patients had their scapholunate ligaments repaired or reconstructed. MAYO scores included, 3 excellent scores, 2 good scores and 5 fair scores. Instability was found clinically in 1 asymptomatic patient who had a positive Watson shift test. Radiological scores include a median scapholunate distance of 2mm, a scapholunate angle of 70° and a radiolunate angle of 15°. Osteoarthritis was found in 2 patients, all of whom were asymptomatic.

Conclusion

The closed reduction and anatomical pinning of a purely ligamentous lesser arc injuries yields good results at medium term follow-up while preserving the option for the reconstruction of the scapholunate interosseous ligament should instability occur.

Level of Evidence IV

Keywords: Lesser arc, perilunate, scapholunate ligament, closed reduction

e. Introduction

Purely ligamentous lesser arc Mayfield type 3 and 4 injuries, i.e. perilunate and lunate dislocations, are uncommon. The scapholunate interosseous ligament (SLIL) is always involved in this injury. Historically, closed reduction and plaster casting of lesser arc injuries yielded poor outcomes.¹⁻³ Current approaches favour operative treatment with open reduction, internal stabilisation and repair of the important interosseous ligament.³⁻¹⁰ SLIL repair is thought to be critical to prevent carpal instability and post-traumatic osteoarthritis. However some studies have shown that despite careful reduction of the wrist and repair of the SLIL a high percentage still go on to develop abnormal radiological parameters and instability.¹¹ We feel that an open reduction, internal fixation and repair of the SLIL is unnecessary in the acute stage of this injury. We hypothesize that a less

invasive approach to the early treatment of these injuries will have good medium-term results in the majority of patients while minimising further trauma and still preserve the ability to perform more extensive surgery should instability develop.

f. Methods and materials

Following Research Ethics approval, a retrospective folder review of patients referred with acute hand and wrist trauma from 2011 to 2014 was performed. All patients were treated at a tertiary level, University hospital. 10 consecutive patients with purely ligamentous lesser arc Mayfield type 3 and 4 injuries, i.e. dorsal perilunate and volar lunate dislocations, were identified. Surgery was performed on the day of presentation under regional intra-venous or brachial block anaesthesia. All reductions were initially attempted closed. If closed wrist reduction failed, open reduction was performed. Surgery was performed by the Hand surgery registrar on-call with a consultant present. If senior cover was not available to perform the accurate reduction and wiring at the initial surgery, the wrist reduction was performed only. The definitive surgery, i.e. accurate scapholunate reduction (SL) and wiring, was performed on the next available list. If closed reduction was not possible emergently, the patient was splinted and the reduction and definitive surgery was performed the following day by the senior hand surgeon on duty. We found this only to be the case in injuries that presented late to the unit.

Method of reduction

Perilunate and lunate dislocations were reduced closed using Tavernier's manoeuvre¹². The technique used by the unit to perform an accurate and anatomic closed reduction was by one of two ways. If 2 surgeons were present, a percutaneous joystick manoeuvre, as described in Greens Operative Hand Surgery¹³, was used. If a single surgeon was present the lunate was manipulated to be co-linear with the capitate and radius and temporarily held with a smooth 1mm or 1.2mm K-wire from the radius to the lunate. The wrist was then gently

extended and ulnar deviated to reduce the flexed scaphoid and close the scapholunate (SL) gap. The definitive fixation was performed in a manner described below. We found the lunotriquetral (LT) joint to reduce anatomically once the lunate had been reduced. Thus it was not specifically repaired or wired, as it was not deemed that additional stabilisation was required. We feel that the majority of clinicians managing these injuries acknowledge that SLIL and the development of scapholunate advanced collapse (SLAC) is the major concern rather than problems with the ulna side of the wrist.

If closed wrist reduction was not possible, open reduction was performed through a dorsal approach described by Berger¹⁴ between the 3rd and 4th extensor compartments. Extensor pollicis longus (EPL) was released and a radially based capsular flap created, preserving the radiotriquetral ligament. All cartilaginous debris was removed and any cartilaginous damage to the scaphoid and capitate noted. An anatomic reduction was achieved of both the scapholunate and lunotriquetral articulations and the reduction was held in the same manner as described below. No attempt was made to repair the SLIL or the LT ligament.

It was imperative that an anatomical reduction of the SL and LT articulation was achieved and confirmed with intra-operative screening. A scapholunate (SL) gap less than 2mm, a scapholunate (SL) angle between 30° and 60° and a radiolunate angle of less than 10° was accepted as reduced.

The radial sensory nerve was protected by blunt dissection down to styloid. Two smooth percutaneous 1.6mm K-wires were placed just distal to the radial styloid, one from the scaphoid into the lunate to maintain the scapholunate reduction and one from the scaphoid into the capitate to prevent scaphoid flexion. The wires were cut short and buried beneath the skin. No wires were inserted from the triquetrum to the lunate.

All patients were placed in a below elbow thumb SPICA plaster in approximately 10 degrees of wrist flexion, for 6 weeks after which the plaster and wires were removed in theatre under local anaesthesia. Patients were referred to the

physiotherapy service to regain wrist motion, but with no structured rehabilitation or post-operative splinting protocol.

Follow-up and long term assessment

At the follow-up visits patients underwent subjective and objective clinical and radiological assessment. A subjective clinical assessment included perception of pain and return to function in terms of work and sport. The objective clinical assessment included tests for carpal instability, wrist range of movement and grip strength. The finger extension test and Watson shift test were used to assess for carpal instability. Wrist flexion and extension of the injured and uninjured side was measured using a hand held goniometer. Grip strength was measured in kilograms using the Jamar® Hydraulic Hand Dynamometer. To measure grip strength the patient was seated with the elbow flexed to 90 degrees, arm adducted and forearm in neutral. 3 readings were recorded, alternating with the normal side to prevent fatigue. The Mayo wrist score was calculated in order to quantify the functional outcomes of this treatment method and as a method for comparison between patient groups, i.e. open versus closed wrist reduction and between the groups who underwent two assessments.

Radiographic investigation included a clenched fist, neutral posterioranterior (PA) and a lateral view of the wrist. The scapholunate angle (SLA), scapholunate distance (SLD) and radiolunate angle (RLA) were measured using the digital measuring tools available with the Phillips iSite Enterprise radiology software. The presence of osteoarthritic changes of the radiocarpal and mid-carpal joints were also recorded. The senior author, using the same radiographic landmarks, performed all measurements. SL distance was measured as the distance between the scaphoid cortex and the lunate cortex at the centre of the scapholunate joint.¹⁵ The SL angle was measured between the longitudinal axis of the lunate (drawn perpendicular to a line joining the dorsal and volar poles of the lunate) and a line intersecting the volar cortices of the proximal and distance convexities.¹⁶

Statistical methods

Subject characteristics were summarized using descriptive statistics; for continuous variables, means and standard deviations are reported, and for categorical variables, counts and percentages are reported. Despite the small number of study subjects, the normality of the distribution of continuous data was assessed using the Shapiro Wilk Test. Normally distributed data was summarised using means and standard deviations and the means compared in the two groups using the Student's t-test. Skewed data was summarised using the median and range and the medians were compared using the Wilcoxon Rank-Sum/Mann Whitney U-test. Proportions in the two groups were compared using Fisher's exact test. The level of statistical significance was set at $p < 0.05$.

g. Results

The patient cohort included 10 patients with a median age of 35 years (Min 18, Max 53), all were male and all were right hand dominant. In 5 (50%) patients the right hand was injured. Six patients (60%) sustained their injury from a fall from a height while the remainder were motor vehicle injuries.

Of the 10 patients, 7 presented immediately after their injury and underwent successful closed reduction and anatomical wiring. 3 patients proceeded to open reduction after closed attempts failed and all 3 were found to have intra-substance tears intra-operatively. Of the 3 that required open reduction there was a significant delay to presentation and therefore surgery at a median of 14 days (Min 14, Max 21). All 10 patients returned at 6 weeks for removal of plaster and removal of wires. At final follow-up 1 of the 10 patient's x-rays were not available for analysis and this patient was excluded from the radiological assessment.

Table 1 reflects the entire cohort at final follow-up, median of 22 months (Min 4, Max 30). 9 of the 10 patients reported no pain with 1 patient reporting only mild, occasional pain. This was reflected in the Mayo score that showed an excellent score in 3 patients (30%), good in 2 (20%) and fair in 5 (50%). Sixty percent of

patients returned to work, while 20% were unemployed at time of follow-up but found work subsequently. Only 20% did not return to work and this was due to other injuries sustained.

One of the 10 patients had a positive Watson Scaphoid Shift test but was asymptomatic. No patients had a positive finger extension test. The wrist range of movement and grip strength of the total group, for the injured side, was 76% and 90% respectively compared to the normal side.

The good clinical instability scores were in contrast to the radiological variables with none being in the range that the study deemed acceptable at final follow-up. Again the small numbers prevented significant statistical correlation, however the poor radiological scores did not correlate with poor clinical scores. 2 of the 9 patients showed arthritic changes on x-ray at final follow-up but experienced no pain clinically.

There were no post-operative complications such as sepsis, broken metalware or arthrofibrosis.

Discussion

There is currently no disagreement in the literature concerning the importance of the scapholunate relationship in wrist biomechanics and whether accurate reduction of the carpus is imperative to favourable long-term outcome in PLD's.^{11,17-20} However there is controversy as to whether to achieve reduction via open or closed means and how to maintain the scapholunate relationship. There is no clear evidence to suggest that open reduction and acute repair of the SLIL is advantageous to closed reduction and pinning alone. Currently there is only one small study by Inoue and Kuwahata²¹, of 14 patients, that compares closed reduction and pinning to open reduction, SLIL repair and pinning. In this study no statistical difference in outcome between these two groups was found.²¹

Open treatment, including ligament repair, is aimed at preventing scapholunate advanced collapse, i.e. the SLAC wrist. The SLAC wrist is seen with acceleration of the post-traumatic osteoarthritis and wrist instability found with conservative treatment at long-term follow-up. However when looking at whether or not an open reduction and internal fixation, without repair of the SLIL, is beneficial to a good radiological score and functional outcome, a study by Forli et al¹¹, who has the longest follow up with an average of 13 years (range, 10-25). He concludes that there is a tendency for patients to show degenerative changes on x-ray with time and that good reduction, not necessarily the SLIL repair, results in a better radiological score. He also states that poor reduction results in worse degenerative changes however that this does not seem to translate into a poor functional outcome.¹¹ In our study we achieved anatomic reduction in 7 of 10 patients with closed manipulation, which is comparable to that of Adkison et al.³ Of these only 1 patient showed signs of osteoarthritis on x-ray follow-up and scored fair on the Mayo score with no pain, full range of movement and grip strength 93% compared to the uninjured side.

Open treatment of PLD's using dorsal or dorsal and volar combined incisions, for reduction and ligament repair have also shown poor results.^{7,22,23} Hildebrand et al.²⁴ performed an open reduction through a combined dorsal and volar approach on a mixed cohort of patients who sustained both PLDs and perilunate fracture dislocations (PLFDs).²⁴ Despite good Mayo scores and wrist range of movement they reported high complication rates and poor patient satisfaction. Trumble et al.²⁵ described combined dorsal and volar approach with repair of the SLIL, protected by a looped interosseous cerclage wire, to give better compression across the SL interval compared to k-wires.²⁵ This study reported good range of movement and grip strength when compared to the contralateral side and no deterioration of the SL gap or angle over time, in keeping with the work of Forli et al.¹¹ Unfortunately outcomes such as pain, instability or the incidence of osteoarthritis were not assessed and their results were equivocal with regard to return to work and function. In addition, more than half the patients required re-operation in order to remove broken metal-ware. No comment was made concerning the integrity of the SLIL repair at the second procedure. Apart from

equivocal results achieved with closed and open methods of treatment, implant failure, and other surgical complications such as flexor tendon adhesions, superficial and deep wound sepsis and arthrofibrosis should be taken into account when considering the open treatment of PLD's.^{1,22,24-26}

Table 2 compares this study with several other studies assessing the open treatment of these lesser arc injuries. The results of our study are comparable in most included fields. Table 3 summarises our rationale for a more conservative approach. The underlying premise is that some patients will do well without repair of the SLIL provided that anatomical reduction is achieved and maintained while the surrounding soft tissues heal. That is, not all patients go on to develop instability, precluding the need for potentially extensive yet unnecessary surgery in an already traumatised wrist. Those patients that do progress to develop symptomatic scapholunate dissociation select themselves out and are able to have an open reconstruction by one of the well described techniques with the added benefit of a relatively unscarred surgical field. Secondly the SLIL has undergone tensile failure resulting in a circumferential mid-substance tear of both the volar and dorsal ligaments. Repair is unlikely to yield a ligament of sufficient strength to maintain carpal dynamics once the patient is mobilised. In addition, repair of both the SLIL and LT ligaments would require a combined dorsal/volar approach respectively, increasing the likelihood of surgical complications.

A limitation of this study is its small number of patients, which makes statistical correlation with clinical results difficult. It should be reiterated however that this study looks at an uncommon and very specific injury pattern and its numbers are comparable to those found in current similar studies. Furthermore there are limited patient related outcome measures (PROMs) included in this study. Although not as comprehensive as some of the more recent PROMs such as the patient related wrist evaluation score, we did use the Mayo wrist score to assess functional outcomes. We chose this scoring system, as did many of the landmark articles on this topic, in order to achieve meaningful comparison with them. Potential bias exists in the study's interpretation of the postoperative x-rays. Only the senior surgeon in the study performed the analysis with no independent

control. However, this was a radiological assessment, based on objective criteria and it should be noted that the radiological parameters were not within normal range and reported as such, which speaks to their objectivity.

i. Conclusion

In conclusion the results of this study shows that the closed reduction and pinning of a purely ligamentous lesser arc injury or Mayfield type 3 and 4, yielded no poor results at medium term follow-up. Furthermore it would appear that there is no medium term benefit to repairing a ruptured SLIL. This approach minimises surgical trauma to the damaged wrist and preserves tissue planes for future surgery should it be required

j. Letter of submission

Dr Thomas Hilton

Orthopaedic Registrar

MB ChB (UCT) DA(SA) DipPEC(SA)

HPCSA : MP 0629863

Work address:

Division of Orthopaedics
Surgery
Groote Schuur Hospital
H49 OMB
Observatory
☎021 404 5118

Postal address:

11 Clive Steet
Vredehoek 8001
Mobile: 082 796 7608
Fax: 021 461 5831
Email: tlhilton@hotmail.com

01 October 2015

Editor

Journal of Hand Surgery Asia-Pacific Volume

Re: Letter of Submission

Title of submission

Clinical outcomes following reduction and pinning of lesser arc injuries without repair of the scapholunate interosseous ligament.

This letter is to certify that:

- All the authors have been actively involved in the planning and enactment of the study, and have also assisted with the preparation of the submitted article.
- The article has not been submitted elsewhere.
The references have been checked and are correct.
The authors have read the Submission Guidelines and the paper conforms to this Guide in all respects.

Yours truly,

Signed by candidate

Dr. Thomas L. Hilton (Corresponding author)

k. Contribution of co-authors

Dr Chivers contributed to the following:

1. Development of the study protocol
2. Application to the departmental research committee and ethics board.
3. Gathering of patient data
4. Writing-up of the manuscript for submission

Dr Michelle Maree contributed to the following:

1. Inception of the research idea
2. Gathering of patient data
3. Writing-up of the manuscript

Dr Michael Solomons contributed to the following:

1. Inception of the research idea
2. Writing-up of the manuscript

Dr Michael Held contributed to the following:

1. Inception of research idea
2. Writing-up of the article

I. References

- 1 Stanbury, S. J. & Elfar, J. C. Perilunate dislocation and perilunate fracture-dislocation. *J Am Acad Orthop Surg* **19**, 554-562, (2011).
- 2 Kardashian, G., Christoforou, D. C. & Lee, S. K. Perilunate dislocations. *Bull NYU Hosp Jt Dis* **69**, 87-96 (2011).
- 3 Adkison, J. W. & Chapman, M. W. Treatment of acute lunate and perilunate dislocations. *Clin Orthop Relat Res* (**164**), 199-207 (1982).
- 4 Grabow, R. J. & Catalano, L., 3rd. Carpal dislocations. *Hand Clin* **22**, 485-500; (2006).
- 5 Blazar, P. E. & Murray, P. Treatment of perilunate dislocations by combined dorsal and palmar approaches. *Techniques in hand & upper extremity surgery* **5**, 2-7 (2001).
- 6 Apergis, E., Maris, J., Theodoratos, G., Pavlakis, D. & Antoniou, N. Perilunate dislocations and fracture-dislocations. Closed and early open reduction compared in 28 cases. *Acta orthopaedica Scandinavica. Supplementum* **275**, 55-59 (1997).
- 7 Herzberg, G. *et al.* Perilunate dislocations and fracture-dislocations: a multicenter study. *J of Hand Surg Am* **18**, 768-779, (1993).
- 8 Su, C. J., Chang, M. C., Liu, Y. & Lo, W. H. Lunate and perilunate dislocation. *Zhonghua yi xue za zhi = Chinese medical journal; Free China ed* **58**, 348-354 (1996).
- 9 Martinage, A. *et al.* [Perilunate dislocations and fracture-dislocations of the wrist, a review of 14 cases]. *Chirurgie de la main* **27**, 31-39, (2008).
- 10 Cooney, W. P., Bussey, R., Dobyns, J. H. & Linscheid, R. L. Difficult wrist fractures. Perilunate fracture-dislocations of the wrist. *Clin Orthop Relat Res*, 136-147 (1987).
- 11 Forli, A., Courvoisier, A., Wimsey, S., Corcella, D. & Moutet, F. Perilunate dislocations and transscaphoid perilunate fracture-dislocations: a

- retrospective study with minimum ten-year follow-up. *J of Hand Surg Am* **35**, 62-68, (2010).
- 12 Tavernier, L. Les Deplacements Traumatiques du Semilunaire. *Thesis*, 138-139 (1906).
- 13 Arner, M. Green's operative hand surgery (Book). *Acta Orthop Scand* **70**, 411-411 (1999).
- 14 Berger, R. A., Bishop, A. T. & Bettinger, P. C. New dorsal capsulotomy for the surgical exposure of the wrist. *Ann Plast Surg* **35**, 54-59 (1995).
- 15 Suzuki, D. *et al.* Comparison of scapholunate distance measurements on plain radiography and computed tomography for the diagnosis of scapholunate instability associated with distal radius fracture. *J Orthop Sci* **19**, 465-470, (2014).
- 16 Maizlin, Z. V. & Vos, P. M. How to measure scapholunate and Cobb's angles on MRI and CT. *Journal of digital imaging* **25**, 558-561, (2012).
- 17 Kuo, C. E. & Wolfe, S. W. Scapholunate instability: current concepts in diagnosis and management. *J of Hand Surg Am* **33**, 998-1013, (2008).
- 18 Short, W. H., Werner, F. W., Green, J. K. & Masaoka, S. Biomechanical evaluation of the ligamentous stabilizers of the scaphoid and lunate: Part II. *J Hand Surg Am* **30**, 24-34, (2005).
- 19 Garcia-Elias, M., Lluch, A. L. & Stanley, J. K. Three-ligament tenodesis for the treatment of scapholunate dissociation: indications and surgical technique. *J Hand Surg Am* **31**, 125-134, (2006).
- 20 Drewniany, J. J., Palmer, A. K. & Flatt, A. E. The scaphotrapezial ligament complex: an anatomic and biomechanical study. *J Hand Surg Am* **10**, 492-498 (1985).
- 21 Inoue, G. & Kuwahata, Y. Management of acute perilunate dislocations without fracture of the scaphoid. *J of Hand Surg Eur* **22**, 647-652 (1997).
- 22 Souer, J. S., Rutgers, M., Andermahr, J., Jupiter, J. B. & Ring, D. Perilunate fracture-dislocations of the wrist: comparison of temporary screw versus K-wire fixation. *J of Hand Surg Am* **32**, 318-325, (2007).
- 23 Herzberg, G. Perilunate and axial carpal dislocations and fracture-dislocations. *J of Hand Surg Am* **33**, 1659-1668, (2008).

- 24 Hildebrand, K. A. *et al.* Dorsal perilunate dislocations and fracture-dislocations: questionnaire, clinical, and radiographic evaluation. *J of Hand Surg Am* **25**, 1069-1079 (2000).
- 25 Trumble, T. & Verheyden, J. Treatment of isolated perilunate and lunate dislocations with combined dorsal and volar approach and intraosseous cerclage wire. *J of Hand Surg Am* **29**, 412-417, (2004).
- 26 Knoll, V. D., Allan, C. & Trumble, T. E. Trans-scaphoid perilunate fracture dislocations: results of screw fixation of the scaphoid and lunotriquetral repair with a dorsal approach. *J Hand Surg Am* **30**, 1145-1152, (2005).

I. Tables & figures

Table 1: Results of Entire Patient Cohort Including Subjective and Objective Assessments

Subjective Clinical Assessment		
Pain		
None	n = 9	90%
Mild Occasional	n = 1	10%
Moderate, tolerable	n = 0	0%
Severe to intolerable	n = 0	0%
Mayo Wrist Score		
Excellent	n = 3	30%
Good	n = 2	20%
Fair	n = 5	50%
Poor	n = 0	0%
Return to work		
Yes	n = 6	60%
No	n = 2	20%
Unemployed*	n = 2	20%
*Both unemployed found work subsequent to injury		
Objective Clinical Assessment		
Watson Pivot Shift Test		
Positive	n = 1	10%
Negative	n = 9	90%
Finger Extension Test		
Positive	n = 0	0%
Negative	n = 10	100%
Range of Motion Arc**		
	Median (Min, Max)**	
Injured	109°(75°, 160°)	
Normal	143°(105°, 190°)	
** Injured Vs Normal Sign Rank Test p = 0.0078		

Grip Strength		
	Median (Min, Max)	
Injured	43kg (8kg, 96kg)	
Normal	48kg (28kg, 88kg)	
Radiological Assessment		
	Total (n = 9)	
Scapholunate Distance		
Injured (Median (Min, Max))	2mm (2mm, 5.9mm)	
Scapholunate Angle		
Injured (Median (Min, Max))	70° (43°, 92°)	
Radiolunate angle		
Injured (Median (Min, Max))	15° (0°, 27°)	
Osteoarthritis		
Yes	n = 2	22%
No	n = 7	78%

Table 2: Comparison of the Literature - Treatment Methods and Outcomes

	Number of patients	Follow-up period	Average Mayo Wrist Score	Flexion / Extension Arc	Percentage of normal side	Grip strength	Percentage of normal side
Forli (2010)	11	10 - 25y	77	94°	76%	36kg	87%
Study	10	4m - 30m	80	109°	76%	43kg	90%
*Trumble (2004)	22	49m	-----	106°	80%	35kg	77%
*Hildebrand (2000)	6	3y 1m	66	82°	57%	35kg	73%
*Sotereanos (1997)	3	2y 6m	65.5	89°	71%	23kg	77%
* All open +/- combined volar/dorsal							

Table 3: Reasons for a Less Invasive Approach

With a less invasive approach
<ul style="list-style-type: none"> • Avoids further surgical insult in an already traumatised wrist • Open and repair method results not unequivocally good • Open and repair method has its own set of complications • Preserve tissue planes for future surgery • Impractical to repair ligament primarily as undergone tensile failure

- Selects out group that will benefit from more extensive reconstructive surgery.

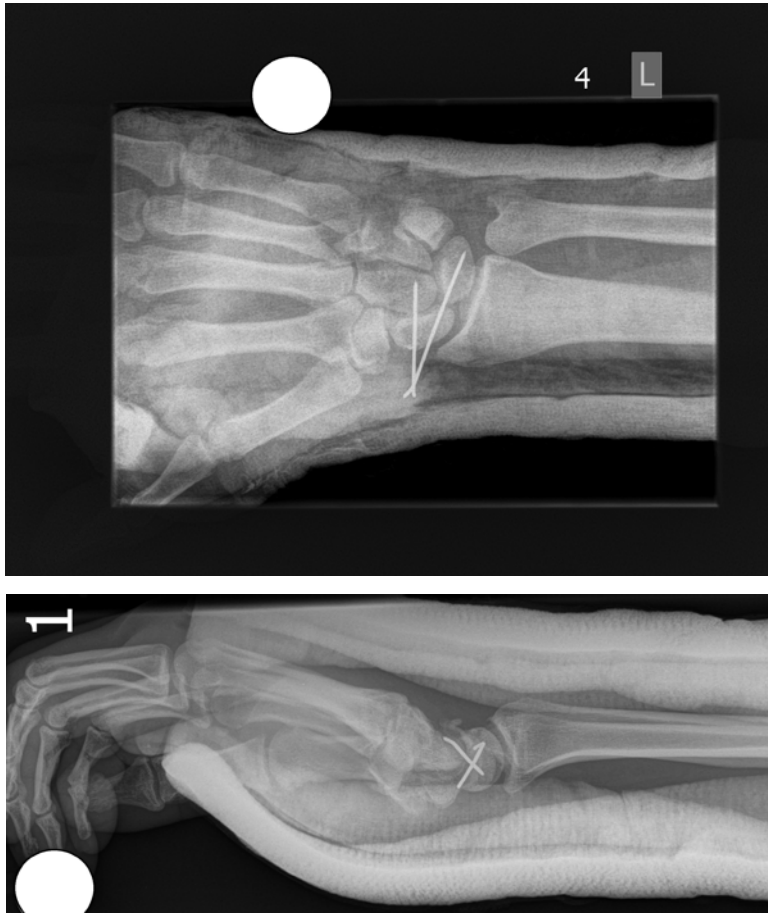

Figure 1a and 1b: Postoperative X-rays to Show Anatomical Reduction and Wire Placement

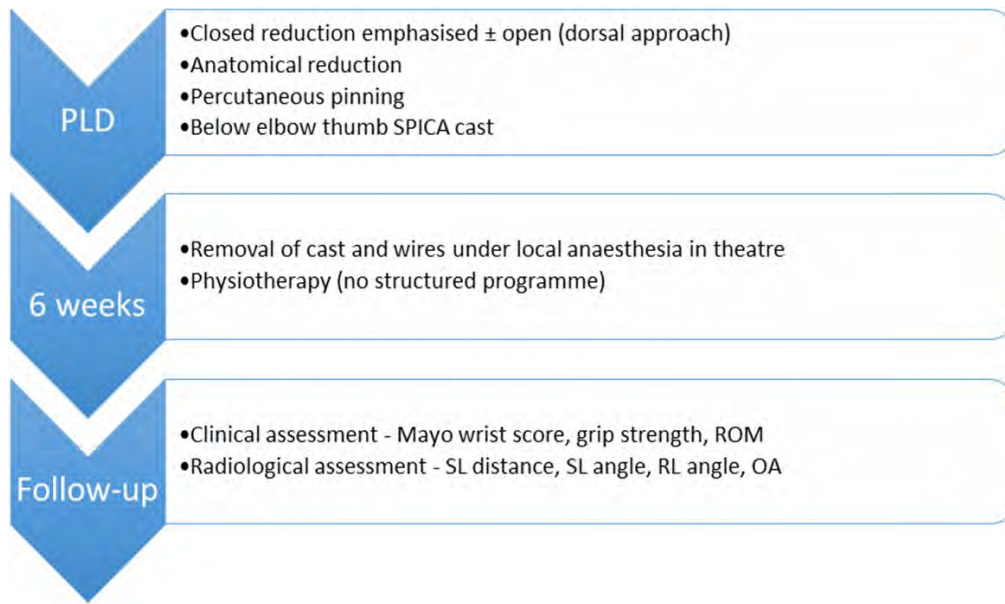


Figure 2: Flow Diagram to Summarise Treatment Protocol of Perilunate Dislocations (PLD)

9. Appendices

a. HREC letter



UNIVERSITY OF CAPE TOWN
Faculty of Health Sciences
Human Research Ethics Committee



Room E52-24 Old Main Building
Groote Schuur Hospital
Observatory 7925
Telephone [021] 406 6338 • Facsimile [021] 406 6411
Email: jamees.emjedi@uct.ac.za
Website: www.health.uct.ac.za/fhs/research/humanethics/forms

04 November 2014

HREC REF: 226/2014

Dr M Maree
C/o Dr D Chivers
Orthopaedics
H49
OMB

Dear Dr Maree

PROJECT TITLE: LONG TERM FOLLOW UP OF PATIENTS WITH ACUTE PERILUNATE/ LUNATE DISLOCATIONS TREATED WITH CLOSED OR OPEN REDUCTION AND K-WIRE BUT WITHOUT REPAIR OF THE SCAPHOLUNATE INTEROSSEOUS LIGAMENT

Thank you for your letter to the Faculty of Health Sciences Human Research Ethics Committee (HREC) dated 28 October 2014.

The HREC approves that Dr Thomas Hilton uses this study for his MMed degree.

Please note that the ongoing ethical conduct of the study remains the responsibility of the principal investigator.

Please quote the HREC reference no in all your correspondence.

Yours sincerely

Signed by candidate

PROFESSOR M BLOCKMAN
CHAIRPERSON, FHS HUMAN ETHICS

b. Patient consent form

Long term follow up of patients with acute perilunate /lunate dislocations treated with closed or open reduction and K-wire but without repair of the scapholunate interosseous ligament.

Authors: Dr T.L. Hilton, Dr D. Chivers, Dr M. Held, Dr M. Maree, Dr M. Solomons

HREC/Ref: 226-2014

Why is this study being done?

Perilunate injuries are complex, rare and difficult to treat. These injuries involve disruption of the ligaments in the wrist. This disruption of the ligaments results in the dislocation of the small bones in the wrist, which if left untreated will result in accelerated arthritis of the wrist, which is both painful and stiff.

This study is being done to assess the long term clinical and functional outcomes of perilunate /lunate dislocations treated conservatively at Groote Schuur hospital. The clinical outcomes measured would be the final range of movement of the wrist and grip strength. The functional assessment involves assessing your pain and ability to return to work or sporting activity. There are multiple ways of treating these injuries and we are comparing our results with other described methods.

Why are you being asked to take part?

These are rare injuries and more information is needed to better manage these problems.

How many people will take part in the study?

We estimate that roughly 15 people will be involved

What will happen if you decide to take part in the study?

All patients will have an x-ray which will be at no extra cost to you. Your wrist movement and function will be examined and scored. You will be asked to fill in a brief questionnaire.

This process will take approximately 45 min. You may be required to return for a further visit in future to undergo the same investigations, but you will be informed at the time of your initial follow up.

What are the risks and discomforts of this study?

There is no risk associated in participating in this study.

Are there any benefits to you for being in the study?

Being part of this study will not influence your management in any way and therefore there is no benefit to you directly. The benefit however will be for us as doctors as information gained through this study may help us in understanding of the management of this injury. You will not be paid to take part in this study.

What other choices do you have?

It is completely your choice to take part in the study.

What will happen when the study is over?

Once you have had your x-ray, completed the questionnaire and had the physical examination you will be finished with the study.

Will the results of the research be shared with you?

The overall results will be shared with you at the end of the study if you are interested. None of the personal details of any of the other people who were part of the study will be revealed.

Will you receive any reward (money or food vouchers) for taking part in this study?

You will not be paid for taking part in this study.

Who will see the information which is collected about you during the study?

All the information collected for this study will be kept anonymous and confidential. All information will be kept on computers which will be protected by a password. Only the research team will have access to this information. Part of the study is that these results

will be presented at congresses and in journals. No personal details of the patients from the study will be included in these presentations.

Who do I speak to (or contact) if I have any questions about the study?

You can speak to the study coordinator Dr David Chivers

Contact details: Dr David Chivers 082 903 7691/ megr@mweb.co.za

I, _____ hereby agree to participate in the research project. I understand that my participation in this study is entirely voluntary and can be withdrawn at any stage and this will not jeopardize or change any further treatment if required. I understand there will not be any financial compensation involved for participation in this research.

I agree to the use of my medical records and that the data collected will be reviewed by the doctors involved with the study. I agree to have my wrist examined and understand that this information will remain confidential but may be used for presentations and articles (on an anonymous basis.)

I understand that this research study has been approved by the Faculty of health Sciences Human Research Ethics Committee, University of Cape Town.

Tel: 021 406 6492 or Email: www.health.uct.ac.za/research/humanethics/

Patient:

Dr:

Date:

c. MAYO wrist score

www.orthopaedicscores.com Date of completion
September 20, 2014

Mayo Wrist Score

Clinician's name (or ref) Patient's name (or ref)

Please answer the following 12 multiple choice questions.
During the past 4 weeks.....

<p>Section 1 - Pain Intensity</p> <p><input type="radio"/> No pain</p> <p><input type="radio"/> Mild Occasional</p> <p><input type="radio"/> Moderate, tolerable</p> <p><input type="radio"/> Severe to intolerable</p>	<p>Section 2 - Functional Status</p> <p><input type="radio"/> Returned to regular employment</p> <p><input type="radio"/> Restricted employment</p> <p><input type="radio"/> Able to work, but unemployed</p> <p><input type="radio"/> Unable to work because of pain</p>
--	--

Section 3 (choose either 3a or 3b)	
<p>3a - Range of Motion (% of normal side)</p> <p><input type="radio"/> 100%</p> <p><input type="radio"/> 75-99%</p> <p><input type="radio"/> 50-74%</p> <p><input type="radio"/> 25-49%</p> <p><input type="radio"/> 0-24%</p>	<p>3b - If only injured hand examined</p> <p><input type="radio"/> Greater than 120 degrees</p> <p><input type="radio"/> 90-120 degrees</p> <p><input type="radio"/> 60-90 degrees</p> <p><input type="radio"/> 30-60 degrees</p> <p><input type="radio"/> less than 30 degrees</p>

<p>Section 4 - Grip strength % of normal</p> <p><input type="radio"/> 100%</p> <p><input type="radio"/> 75-100%</p> <p><input type="radio"/> 50-75%</p> <p><input type="radio"/> 25-50%</p> <p><input type="radio"/> 0-25%</p>	<p>The Mayo Wrist Score is <input style="width: 50px;" type="text" value="0"/></p> <p style="text-align: left;"> <input type="button" value="Print page"/> <input type="button" value="Close Window"/> <input type="button" value="Reset"/> </p> <p style="text-align: center;"> To save this data please print or <input type="button" value="Save As CSV"/> </p> <p style="font-size: small; text-align: center;">Nb: This page cannot be saved due to patient data protection so please print the filled in form before closing the window.</p>
---	---

Interpreting the Wrist Mayo Score

90-100 Excellent	80-90 Good	60-80 Satisfactory	Below 60 Poor
------------------	------------	--------------------	---------------

Reference for Score: Amadio PC, Berquist TH, Smith DK, Ilstrup DM, Cooney WP 3rd, Linscheldt RL. Scaphoid malunion. J Hand Surg [Am]. 1989 Jul;14(4):679-87. Link to pubmed

d. Instructions to authors for Journal of Hand Surgery Asia-Pacific Volume

Preparation of manuscript

Authors are required to submit their manuscripts after reading the following instructions. Any manuscript that does not conform to the following requirements will be considered inappropriate and may be returned.

A. General Requirements

- Manuscripts must be submitted as MS-Word files. The text should be typed in 12-point font and double-spaced with 2.5 margins all around.
- If a long-term follow-up is needed, given the scope of the study, it should be performed more than two years.
- All pages should be numbered sequentially, starting from the abstract.
- Use continuous numbering throughout the text from the abstract.
- To facilitate blind peer review, submit the manuscript as two separate files; Title page and blinded manuscript. In the text of the manuscript, the name of any author or institution should not be included.
- Measurements should be presented in accordance with the International System of Units (SI).
- Abbreviations should be minimized. When necessary, spell out the full term at the first time it appears in the text, add the abbreviation in parentheses, and use the abbreviation thereafter.
- To cite a reference with an author in the text, insert the author's surname only and the citation number in superscript (e.g., Brown¹). For a reference with two authors, list both names in the citation (e.g., Brown and Copper²). For a reference with three or more authors, use 'et al.' (e.g., Brown et al.³). The citation number should be included just behind of a period or a comma (e.g., described.³) not as described³).
- If two or more citation numbers are required, use separated numbers with a comma or a dash (e.g., Boyes¹⁻³, Chapman^{1,2,7}).

B. Title Page

The title page should contain the full title of the paper, the names of the authors and of the institutions, and institutional addresses. If authors are at different institutions, first present the institution where most of the work was carried out, and indicate individual departments and institutions by inserting a superscript letter just behind the author's name, and the same letter in front of the appropriate institution. The name, address, e-mail address, telephone, and fax number of the corresponding author should be placed in the lower portion of the title page. The title should be expressed briefly, clearly, and concisely.

C. Abstract

Each paper should start with an abstract not exceeding 300 words. The abstract should state the background, methods, results, and conclusions in each paragraph in a brief and coherent manner. Relevant numerical data should be included. Under the abstract, keywords should be inserted (maximum 5 words) and listed in the following order: anatomical name (illness), diagnosis, and treatment. Authors are recommended to use the MeSH database to find Medical Subject Heading Terms at <http://www.nlm.nih.gov/mesh/meshhome.html>. The abstract should be structured into the following sections.

1. 1) Background: The rationale, importance, or objective of the study should be described briefly and concisely in one or two sentences. The objective should be consistent with that stated in the Introduction
2. 2) Methods: The procedures conducted to achieve the objective of the study should be described in details, together with relevant details concerning how data were obtained and analyzed and how research bias was adjusted.
3. 3) Results: The most important results and analysis of the study should be presented in a logical manner with specific experimental data.
4. 4) Conclusions: The conclusions derived from the results should be described in one or two sentences, and must match up with the objective of the study.

D. Introduction

State the background or hypothesis that led to the initiation of the study. Lead systematically to the hypothesis of the study, and finally, to a restatement of the objectives of the study. Do not include conclusions in the Introduction.

E. Methods

Institutional review board (IRB) approval, when applicable, must be stated. Describe the study design (prospective or retrospective), inclusion and exclusion criteria, and the demographic data. Explanations of the experimental methods should be concise. The authors should include statistical methods with enough explanations.

F. Results

This section should include detailed reports on the data obtained from the study. All data in the text must be presented in a consistent manner throughout the manuscript.

G. Discussion

In the Discussion, data should be interpreted to demonstrate whether they affirm or refute the original hypothesis. Discuss elements related to the purpose of the study and present the rationales that support the conclusion drawn by referring to relevant literature. Care should be taken to avoid information obtained from books, historical facts, and irrelevant information. The strong and weak points of the study should be included.

H. Acknowledgments

All persons who have made substantial contributions, but who have not met the criteria for authorship, should be acknowledged here. All sources of funding for the study should be stated here explicitly.

I. References.

- The number of references is limited to 40 for original article and 10 for case report and technical note.
- The references should be numbered according to the citation order in the text (not alphabetically).
- All references must be cited in the text.
- Non-published findings and personal communications should not be included in the list of references.
- References to journal articles should conform to the journal title abbreviations used in the Index Medicus.
- List names of all authors when six or fewer. When seven or more, list only the first three names and add et al..

- Authors should be listed by surname followed by initials.
- Examples of references are as follows:
 1. 1) Journal article
Baek GH, Chung MS, Lee YH, Gong HS, Lee S, Kim HH. Ulnar shortening osteotomy in idiopathic ulnar impaction syndrome. *J Bone Joint Surg Am.* 2005;87(12):2649-54.
 2. 2) Book
Williams PL, Bannister LH, Berry MM, et al.. *Gray's Anatomy.* 38th ed. London: Churchill Livingstone; 1995: 861-2.
 3. 3) Chapter in a book
Kaplan EB, Spinner M. Important muscular variations of the hand and forearm. In: Spinner M editors. *Kaplan's functional and surgical anatomy of the hand.* Philadelphia: Lippincott; 1984: 335-49.
- For more on references, refer to the NLM Style Guide for Authors, Editors, and Publishers.

J. Table

- Tables should be numbered sequentially with Arabic numerals and given a brief title. Use capital letters for the first letter of each word in the title, except articles, prepositions, and conjunctions.
- Tables should be numbered in the order in which they are mentioned in the text.
- If an abbreviation is used in a table, it should be defined in a footnote below the table.
- Tables should be understandable and self-explanatory, without references to the text.

K. Figure Legends

- Illustrations should be numbered in the order in which they are mentioned in the text (e.g., Fig. 1).
- Each illustration should have a brief and specific legend, which should be listed on a separate manuscript page after references.
- Staining techniques used should be described. Photomicrographs with no inset scale should have the magnification of the print in the legend.

L. Illustrations

- Papers containing unclear photographic prints may be rejected.
- Each figure should be prepared in a separate file.
- The name of an image file should correspond to the number of the figure. If a figure contains two or more photographs, they should be assigned an Arabic numeral followed by letters in the English alphabet (e.g., Fig. 1A, Fig. 1B).
- Submit illustrations on-line in JPEG, TIFF or EPS format. Do not embed images into the text file. Figures may be halftone photographs or black on white line drawings. Color images will be accepted only when essential. Remove any writing that could identify a patient.
- If a manuscript is accepted for publication, the journal will request high quality figures in TIFF or EPS format. When using a digital camera, set the resolution to a minimum of 300 ppi (pixels per inch), and set the size of the image to 5 × 7 in (127 × 178 mm). Color and grayscale images, such as radiographs, must have a minimum resolution of 300dpi, and line art drawings must have a minimum resolution of 1200 dpi.

- Any illustrations previously published should be accompanied by the written consent of the copyright holder.