

University of Cape Town

# **Gunshot wounds to the male external genitalia**

By

**André van der Merwe**

Student number VMRAND006

A DISSERTATION SUBMITTED  
IN PARTIAL FULFILLMENT OF THE  
REQUIREMENTS FOR THE DEGREE

**MMed (UROLOGY)**

Supervisors: Prof Alan Pontin, Dr Dick Barnes

Division of Urology

Groote Schuur Hospital

Faculty of Health Sciences

University of Cape Town

*Date of submission February 2007*

---

The copyright of this thesis vests in the author. No quotation from it or information derived from it is to be published without full acknowledgement of the source. The thesis is to be used for private study or non-commercial research purposes only.

Published by the University of Cape Town (UCT) in terms of the non-exclusive license granted to UCT by the author.

<b><u>Index</u></b>	<b><u>Page</u></b>
<b>Declaration</b>	<b>3</b>
<b>Acknowledgements</b>	<b>4</b>
<b>Abstract</b>	<b>5</b>
<b>List of figures</b>	<b>7</b>
<b>Chapter 1: Literature Review</b>	<b>8</b>
<b>Chapter 2: Aim of the Study</b>	<b>19</b>
<b>Chapter 3: Materials and Methods</b>	<b>20</b>
<b>Chapter 4: Results</b>	<b>21</b>
<b>Chapter 5: Discussion</b>	<b>31</b>
<b>Chapter 6: Conclusion and Recommendations</b>	<b>37</b>
<b>References</b>	<b>38</b>
<b>Appendix</b>	<b>40</b>

University of Cape Town

## Declaration

I, André van der Merwe, hereby declare that the work on which this dissertation is based is my original work (except where acknowledgements indicate otherwise) and that neither the whole work nor any part of it has been, is being or is to be submitted for another degree in this or any other university.

I empower the university to reproduce for the purpose of research either the whole or any portion of the contents in any manner whatsoever.

Signed

Signed by candidate

Date

..... 18.5.2007 .....

## Acknowledgements

I firstly want to thank Professor A Pontin for encouraging me to submit a thesis for the MMed (Urol) degree after I became a Fellow of the College. of Urologists of South Africa - FC (Urol) SA in 2003. He identified this as one of the possible projects and his encouragement was always honest and guiding.

A very special word of thank you must go to Dr RD Barnes, Senior Specialist and supervisor - for his perusal of the manuscript with attention to the finest detail.

A debt of gratitude must also go to Dr FC Tyler, who acquired some of the study data during his registrar training at the University of Cape Town/Groote Schuur Hospital. Without the patient folder numbers and relevant details I would not have been able to trace the folders of the first few years of the study and the opportunity to collect this data and possibly publish this, as a first publication in Southern Africa on this topic, would have been lost.

Mrs L Burke, University of Cape Town secretary to the Division of Urology, is thanked for helping diligently with the data capture. She helped with this far beyond the call of duty – also after normal working hours.

I also want to acknowledge the help of the trainees (Specialist Registrars - of whom many are now esteemed consultant Urologists), who helped to care for these patients over the years while on the ward and in theatre. They are Drs A Bhorat, N Sekhu, J Lazarus, S Sinha, P de Bruin, J Coetzee, P Govender, and L Kaestner. Also the supernumerary registrars Drs P Nakangombe, A Al-Mamaari, W Otele and A Salako are thanked for their efforts and patient care towards the study group of patients. The hard working medical officers deserve appreciation for their work on these patients – Drs Cupido and Wright as well as the nursing staff of Ward F26 Groote Schuur Hospital.

Finally I must voice my heartfelt appreciation for the three most important people in my life – my wife Rina and sons Henry (4) and Theuns (1). Thank you for understanding and supporting me in preparing for this qualification.

## **Abstract**

**Introduction:** This is a retrospective study of male patients that suffered gunshot wounds to the external genitalia from August 1997 to September 2006. This study also reviews the literature and compares treatment methods locally and internationally.

**Materials and Methods:** Surgical Research Committee – and Ethical Committee approval was obtained. In total, 70 patient case notes were reviewed. Demographic and socio economic data (age, race, area of residence, marriage status, employment, possible relationship problems) were collected. Data regarding number and position of gunshots to genitalia were collected as well as associated injuries. The position of the penile injury as well as spermatic cord and testicular injuries were documented. Urethral injuries were documented according to the anatomical divisions of the urethra. The velocity of the missile was documented. Urine dipstick at initial evaluation was documented. Management at Groote Schuur Hospital, early and late complications (with special reference to erectile function) were studied. Follow-up time for each case was documented.

**Results:** Only one case involved a high velocity gunshot wound. The majority patients were Black (37 cases)(53%), unemployed (42 cases)(60%), and single (51 cases)(82%) in the 20-30 (29 cases)(40%) year old age group. The bulk of injuries took place during November and December months. The highest education that any patient had was a salesman. The townships of Khayelitsha and Mitchell's Plain produced the most referrals to Groote Schuur Hospital. Urine dipstick test were positive in 14 patients of whom only three had urethral injuries on further investigation. Four cases were investigated with micturating cysto-urethrography (MCUG) diagnosing one urethral injury. The scrotum was most commonly affected (24 cases), followed by penoscrotal (23 cases), and penile (23 cases). Of fourteen urethral injuries seen seven were treated with primary closure and one developed a stricture. The seven other urethral injuries were treated by urine diversion alone – one patient developed a stricture, but follow up was relatively short. Three cases needed bilateral orchidectomy. One patient with a penile gunshot developed chordee that spontaneously resolved on follow-up. One patient had poor erections and was treated with a vacuum device before disappearing from follow-up.

**Conclusions:** This study relate unmarried state and poor social circumstances to being risk factors for gunshot wounds to the genitalia and identified certain areas in Cape Town and certain months of the year where these injuries were more frequent. Urethral and corporeal injuries were relatively free of complications. The author concurs with current literature that early complete debridement and primary closure of all affected tissues including the urethra is optimal management to reduce the complication rate. Anatomical diagnosis is crucial to manage these injuries correctly. Follow up in this patient group was poor.

University of Cape Town

## List of figures

Figure 1: Temporary cavity formation.	Page 9
Figure 2. Anatomy of the penile corpora	Page 11
Figure 3. Number of cases of gunshot wounds to the external genitalia seen per year in the study population.	Page 21
Figure 4. Monthly variation of gunshots during the study period.	Page 21
Figure 5. Age distribution of the study population	Page 22
Figure 6. Racial distribution of the study population	Page 22
Figure 7. Residential areas around Cape Town affected by genital gunshot wounds.	Page 23
Figure 8. A gunshot traversing the glans and one corpus cavernosum	Page 24
Figure 9. A bullet residing in the bulbar area after a gunshot	Page 25
Figure 10. Total genital injuries – 89 injuries in total.	Page 26
Figure 11. Genital skin loss (a corporeal defect can also be seen at the arrow)	Page 28
Figure 12. “Tacking” sutures bringing together apparent skin loss	Page 28
Figure 13. Anatomical distribution of injuries sustained	Page 29
Figure 14. Associated injuries	Page 29
Figure 15. A later admission de-prioritising genital gunshot follow-up	Page 36

## **1. Incidence of gunshot wounds to genitalia**

The incidence of genital gunshot wounds is reported and linked to urological injuries. During wartime urological injuries vary from between 1 to 10 % of injuries and are nearly exclusively high velocity in nature. (1) The variation in incidence is dependent on the type of warfare conducted: during World War 1 trench fighting protected the urological organs to an extent, but during World War 2 missile fragment injuries increased and urological gunshots/missile injuries were as high as 6%. During the war in South Vietnam during the sixties the incidence of urological injuries was as high as 10% with the guerrilla fighting employed at the time (1). Genital missile injury as a percentage of urological injury was 29% in a series by Young during World War 1 and during World War 2 Culp and Kimbrough found 50 – 68 % of urological injuries were external genital injuries as quoted in Selikowitz (1977) (1). Selikowitz found 40 – 66% of urological injuries were genital injuries during the Vietnam War (1).

Low velocity war injuries from as early as 1861 during the American Civil (2) war caused 1497 reported cases of urological injury. External genital injury was also 40 % of urological injuries. Most wounds were inflicted by the dreaded Minié ball – a .58 calibre bullet that expanded on impact to cause wide tissue destruction (2). During peacetime, in the civilian population external genital injuries vary between 6 and 26 % of urological injuries seen and the incidence seems to be rising (3). The majority of these injuries are low velocity in nature. However, with increase in urban violence and the availability of military assault weapons, the urban urologist should have an understanding of high as well as low velocity injuries to the external genitalia (1).

## **2. Essential Ballistics**

Some understanding of high and low velocity missile ballistics is necessary to enable one to effectively understand and treat these injuries.

*Low velocity* missiles travel at speeds less than 1000 feet/second. The major effect is along the projectile's tract - also called permanent cavity as reported by Hopkinson (1967) and quoted by Selikowitz (1). Tissue is compressed in front of

the propagating bullet and tissue damage occurs due to shearing and compression as the missile forces through the tissue as reported by Hopkinson (1967) and quoted by Selikowitz (1).

*High velocity* bullets like the Russian AK47 or American M16 travel at speeds greater than 3200feet/second (muzzle velocity) and cause damage by almost an explosive effect of temporary cavity (seen in figure 1) formation as seen by Amato (1972) and quoted by Selikowitz (1).

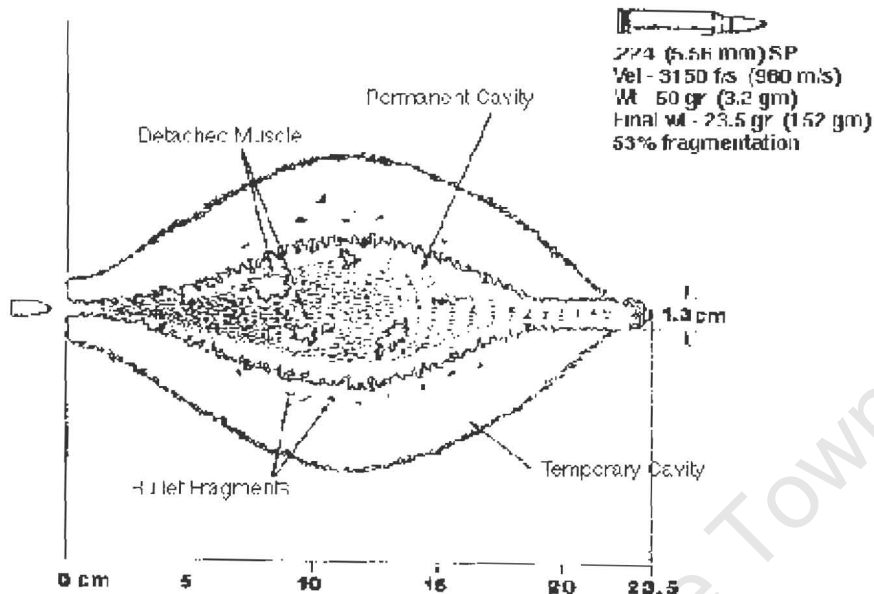


Figure 1: Temporary cavity formation - From ML Fackler MD, Division of Trauma Research Presidio of Trauma, California

The cavity produced persists after the bullet has passed and pressure in the cavity may be greater than 100 atmospheres and change to sub-atmospheric pressure as the cavity undulates and finally dampens out and tissue damage is caused away from the tract in an explosive manner as vessels and axon sheaths tear and larger vessels thrombose and tissues are destroyed as reported by Rich (1977) and quoted by Selikowitz (1). The stability created by spinning increases bullet contact velocity, range and accuracy by reducing aerodynamic drag and therefore the tendency to tumble as reported by Hopkinson (1967) and quoted by Selikowitz (1). These motions are known as precession and nutation and form a combined movement known as yaw: the deviation of a bullet's longitudinal axis from the midline of flight trajectory as reported by Hopkinson (1967) and quoted by Selikowitz (1).

Under spinning conditions the bullet is relatively stable unless the overturning moment increases so much that it causes the missile to tumble (1).

The energy (E) liberated in tissue increases by the square of the velocity (V) and is described by the formula  $E=MV^2/2$  where M=mass (1). However this, will be the total amount of energy liberated if the bullet were to stop at the skin level and as exit wounds normally occur, the energy released would be the difference between the entry and exit energies (1). The rate of deceleration determines the amount of energy released and thus the amount of tissue damage done (1). The rate of deceleration depends on the tissue resistance/density, the missile mass, and the presenting area of the missile and drag coefficient (Cd). Energy is released at each tissue plane and the bullet may start to fragment and tumble, increasing the release of energy as the bullet rapidly decelerates (the detailed formulae are beyond the scope of this discussion). It is therefore possible to appreciate that tissue damage in external genitalia is potentially severe as the tissues are relatively dense (corpora and testis for example) and the multiple tissue planes (see next anatomy section) increase energy release (1). Despite the reduction in speed, the deformation/fragmentation and modification of spin with tumbling produce increased exit energy, causing exit wounds to be larger than entry wounds (1). It is possible that thrombosis of the penile or testicular blood supply could happen as a consequence of the cavitation effect high velocity bullets have on the "pedicle" blood supply of the penis and neural damage may occur by the same mechanism - as reported by Rich (1977) and quoted by Selikowitz (1).

### 3. Essential Applied Anatomy

The size of the penis is relatively smaller under the influence of adrenaline during sympathetic stimulatory situations (the so called “fight or flight” state). This might be protective against injury.

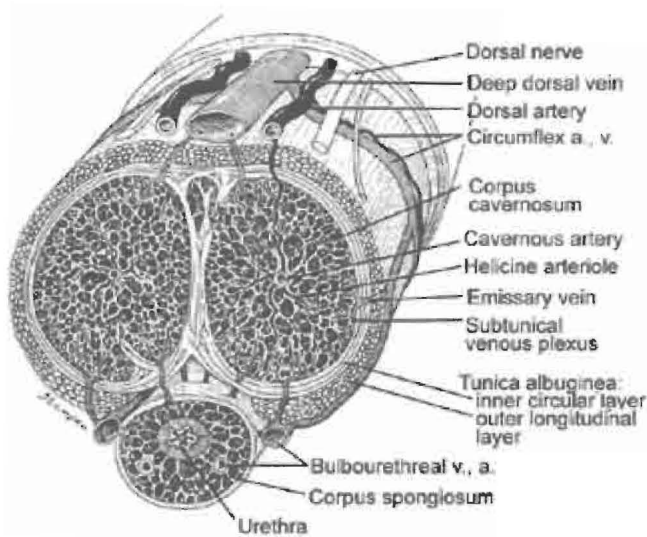


Figure 2. Anatomy of the penile corpora. (Picture obtained from [www.webmd.com](http://www.webmd.com))

However, the multiple tissue planes, as seen on the schematic cross section in Figure 2, (skin, Buck’s fascia, corpora cavernosa, corpus spongiosum, urethra with lumen) encourage energy release and may cause a missile to change from yaw to tumble with potential increase in energy release and tissue destruction. (4) Morbidity could be divided into:

*Vascular damage:* The penile artery, a branch of the internal pudendal artery, supplies blood in a pedicle fashion – proximal damage could lead to distal impairment with necrosis of distal tissues. It is known that pudendal artery damage from a gunshot wound may cause vascular impotence. This can be rectified by surgical vascular reconstruction (5).

*Neurological damage:* The cavernosal nerves that run along the side of the urethra in the pelvic diaphragm fan out over the penis in a varied manner (some nerve bundles stay together and in other cases they may fan out uniformly). Bullet damage (high or low velocity) may damage these nerves and impair the initiation and maintenance of erection. Sensation to the skin of the penis is from the genito-

femoral nerve (L1-nerve root) and transection of these nerves at proximal penile level may impede sensation.

*Corporeal damage:* The corpora cavernosa and corpus spongiosum consist of a fine criss-cross lattice of collagen. This lattice functions to allow expansion as well as elongation and rigidity (with intra-corporeal pressure above systolic blood pressure). Injury to the collagen heals with fibrosis and causes penile chordee/curvature during erection that may hinder intercourse.

*Urethral damage:* Injury to the urethra may in addition to the above (the urethra is surrounded by spongiosal tissue) also lead to urine extravasation into the corpora that initiates chemical inflammation and enhances fibrosis. Fibrosis around the urethra creates urethral stricture disease with potential dire obstructive consequences.

*Testis injury:* The testis has a pedicle blood supply via the testicular, cremasteric and vasal arteries. The length of the cord gives mobility to the testis to act as a protective mechanism against direct trauma. This is unlikely to be of benefit with gunshot wounds to the cord. The cremasteric muscle (cremasteric reflex) may also pull the testis into a high scrotal position or into the inguinal canal to offer some protection as well. The tunica albuginea is also tough, offering protection (6). Damage to the cord could affect all the vessels, causing vascular necrosis of the testis. Fertility may be affected by injury to the vas deferens as well as direct testicular injury, which is known to reduce the sperm motility even after partial bilateral testis injury as shown by Husmann (7) and Cass (8). The testis may burst on missile impact, rupturing the delicate tubular structure of the seminiferous tubules (1).

*Scrotal injury:* The scrotum has an excellent blood supply from anastomosis of the terminal branches of the superficial external pudendal arteries and deep external pudendal arteries (from the femoral artery). It consists of loose skin overlying the dartos muscle with no subcutaneous fat layer. This makes the scrotum extremely pliable and scrotal skin lost from gunshot wounds can usually be re-approximated with near impunity. However, this makes the scrotum expand with haematoma formation into the loose tissues. As the scrotum is a dependent and moist part of the body, a swollen scrotum is at risk for infection (9). Infection may spread deep to the superficial fascia (of Colles) of the perineum. This fascia is continuous with the superficial fascia of the anterior abdominal wall (Scarpa's fascia) as well as

Buck's fascia of the penis. The loose areolar tissue beneath these fasciae is an excellent culture medium for infection to spread and may cause necrotizing fasciitis even to the level of the nipples on the anterior abdominal wall (where Scarpa's fascia adheres)(10).

#### **4. Demography and Socio-economic status of patients**

There is no information in the English literature on the social conditions, employment or marital status of the study objects, or the reason for the gunshot injury. Husmann (7) has reported an increase in these injuries with increase in drug trafficking.

#### **5. Presentation**

In one study the average age of patients with external gunshot injuries is 24 years and they present within one hour (11). Targeting the external genitalia as primary target occurred in 100% in a series of 10 patients (12). This will lead to less associated injuries than during wartime, as Selikowitz found (3). Complete loss of the phallus may occur during high velocity injury (3). A history of handgun use in a civilian setting involves almost exclusively low velocity bullets (7). A history of delay in presentation should be sought, as complications would be more likely to ensue (3), (12). There may also be a history of a previous genital gunshot injury (12). Difficulty in voiding should alert to a possible urethral injury (13). It is seldom documented whether the genitalia were the target of the assault.

Associated injuries occur in the majority of cases (83% in Gomez's series) and are the likely cause in case of life threatening haemorrhage (11), (14). Three out of four patients seen by Jolly presented with haemorrhagic shock after low velocity injuries (15). Associated injuries may therefore dictate the way these patients present, i.e. involvement of thighs, hands, bowel, vascular structures, chest and buttocks (14). High velocity injuries will present with more associated injuries and more destruction of the genitalia (3), (14). The penis and/or scrotum may be severely swollen and some part of the genital skin may obviously be missing with high velocity gunshots. The scrotum may also be swollen from haematoma and the testis or cord may be visible. Willis reported 2 cases of testicular rupture with a non-penetrating gunshot wound to the scrotum (16). The scrotum was massively swollen and the diagnosis made at exploration. Blood may be visible at the

external urethral meatus or urine dipstick test may be positive for blood with urethral injury. However, this is not always the case, as Miles reported that one out of three patients with blood at the meatus had no urethral injury on retrograde urethrogram (12). Haematuria or inability to void must alert one to a possible concomitant bladder injury. A urine diagnostic dipstick test is compulsory (9), although not seen as helpful by Miles (12). Inspection of the external genitalia will suffice to give clues about the need for further investigations/exploration. Bruised corpora could easily be mistaken for necrotic tissue, as pointed out by Corriere (17).

## **6. Special investigations**

The focus should be to exclude associated injuries and to make an anatomical diagnosis regarding the penis, urethra, testis and scrotum. Relevant imaging is done in cases where chest or abdominal injury is suspected.

*Penile imaging:* Cavemosography, as performed for fracture of the penis, is not a recommended test, as prompt surgical exploration will reveal corporeal defects and interpretation is difficult for the inexperienced radiologist (3). Ultrasound of the penis may prove helpful to diagnose a bullet lodged in the corpus cavernosum (18).

*Urethral imaging:* The use of the “diagnostic catheter” in urethral trauma (blunt) was condemned by Mitchell in 1968 (19). This practice is also not recommended in penetrating trauma. by Morey et al (20). Retrograde urethrography is recommended for all penetrating external genital injuries by Morey et al’s Consensus Panel on external genital injury (20). Ultrasonography should be seen as an investigative tool for the evaluation of urethral trauma currently and has no role in the evaluation of possible gunshot injury to the urethra (21).

*Scrotal/Testis imaging:* The use of *Scrotal* ultrasound (SUS) is controversial, but is the most sensitive and specific method for detecting scrotal injury. It is proposed that all such injuries be explored immediately without wasting time on imaging (20). However if a ‘graze’ of the scrotum by a bullet is to be treated conservatively (12), an SUS should be done. Testicular rupture/penetration can be diagnosed with accuracy with a 5, 7,5 or 10MHz probe as long as the testis can be palpated and the scrotal haematoma is not large. Heterogeneity of the echo-pattern of the testis should be seen as diagnostic of tunica albuginea disruption. Even

small intra-testicular haematomas should be seen as evidence of rupture. Extruded seminiferous tubules can also be seen as disturbance of the contour of the testis on SUS. Haematocoeles can also be distinguished from hydroceles (22). However, the diagnostic accuracy of SUS is user dependent and must be interpreted in conjunction with the clinical findings (20). MRI is unlikely to be clinically useful in this setting of bullet injury to the scrotum as it is time consuming and only possibly indicated for cases of blunt testicular trauma (23).

*Cystoscopy:* Some do not advocate cystoscopy at the time of surgery (12), but others feel it is critically important (7).

## **7. Treatment options**

The aim of treatment should be to preserve as much function as possible (erectile function, prevent chordee, protect fertility/gonads) (20).

The type of weapon used (handgun or rifle), location and extent of injury determine the management. It is suggested that all wounds be surgically explored (20), although some feel that the superficial penile abrasion may be treated by simple dressing without formal exploration (12). Cass suggests *principles of management* applicable to all cases, irrespective of anatomical site: lavage, remove foreign bodies, haemostasis, primary repair of tissues (such as urethra, testis and corpora), excision of non-viable tissue and placement of drains. A grossly contaminated wound should be left open (24).

### ***Treatment of penile gunshot wounds***

High velocity injuries usually result in the loss of the phallus (3).

Bullets that lodge in the penis are removed by some (25) and left in situ by others (18) (case report - this patient regained normal sexual function one month after the incident!). Hall (25) suggested pertinent findings suggestive of corporeal injury from the bullet:

1. Palpable corporeal defects
2. Expanding haematoma
3. Significant bleeding via the bullet holes.

Abrasion gunshot wounds to the penis may be closed without exploration, according to Miles (12), but it is suggested in a consensus review (2004) that all penetrating penile injuries be explored (20).

A circumferential incision at the level of the coronal sulcus and degloving of the skin of the penile shaft provides good exposure to the corpora for closure of defects with non-absorbable interrupted buried sutures (12). Deep sutures and clamping of the corpora must be avoided to prevent chordee post operatively. The wounds must be vigorously irrigated to remove gunpowder grains, pieces of plastic, bullet fragments and other foreign bodies (11). McAninch advises that debridement of penile wounds and corpora may be kept to a minimum due to the excellent blood supply of the penis. Penile skin defects may be primarily closed; wounds grafted or left open to close secondarily when sepsis is controlled (26). The split thickness graft from the thigh should be relatively thick (0,018 inch) to disallow hair growth and minimise scar contracture (27).

#### ***Treatment of Urethral gunshot wounds***

Mitchell (1968) was the first to suggest the concept of delayed treatment for urethral injuries (blunt in his case) in some circumstances (e.g. severe trauma). This was presented at a British Urological Association meeting and severely contested by members of the audience (19). Primary debridement and closure of the wound with suprapubic catheter diversion is advocated by some authors for all types of urethral injuries with delayed closure of the urethra (12). Weaver found that the urethra may regenerate if a bridge of normal urethral tissue remains or is placed across a gap in the urethra. This may be the basis of success for primary closure of the urethra (28). According to a consensus statement (2004) *anterior urethral* injuries (bulbar and pendulous urethra) are treated with primary closure in the stable patient (7), (21). This could be technically difficult and should only be attempted in the stable patient with no severe injuries to the non-genital organs. The urethra is closed with a fine absorbable suture material making sure of over-closure of the spongiosum and overlying tissues to reduce fistula formation. The meatus should be closed with care primarily or, if time does not permit, it should have a formal meatoplasty to prevent the morbid complication of spraying of the “blunderbuss” meatus. Larger defects in the urethra requiring grafts or flaps should be left open and the urethra spatulated like a first stage urethroplasty for interim reconstruction (urine to be diverted). Contaminated wounds should be left open and urine diverted (21). *Posterior urethral* injuries (membranous and prostatic urethra) are uncommon individually, but may be part of abdominal gunshot wounds and co-morbidity can be expected, especially in high velocity

injuries. Therefore primary repair is unlikely to be an option (3), (21). A scrotal gunshot wound traversing the proximal (posterior) urethra has been reported to heal completely by supra-pubic drainage alone (29). This type of injury usually needs interim reconstructive surgery after 3 -6 months (12), (21).

#### ***Treatment of Testicular gunshot wounds***

Viable testicular tissue should be salvaged when possible as endocrine function is usually maintained and the psychological benefit of preserving the native testis is seen as substantial (20). Bilateral testicular injury is a threat to fertility as well as normal androgen levels needed for erectile function. Bilateral testis injury is associated with poor sperm count, low motility, abnormal forms as well as low levels of serum testosterone (8). Husmann found low testosterone levels with new onset impotence after a unilateral testis injury; however pre-incident levels of testosterone were not available (7). Therefore all attempts should be made to salvage a damaged testis and if possible epididymal/testicular sperm expression and preservation in a sperm bank should be considered (9). Transected cord vessels must be ligated (20). Severed vas deferens should be ligated and a micro-surgical vaso-vasostomy done as an interim procedure (20).

#### ***Treatment of Scrotal gunshot wounds***

High velocity wounds may disrupt and destroy large parts of the scrotal skin. The pliable scrotal skin may be re-approximated with near impunity; however infection in humid climates seems to be common (3). Troublesome voluminous haematomas are described that may need evacuation (18). In cases of total loss of scrotal skin (e.g. shotgun injury) the scrotum may be reconstructed by flaps based on the external pudendal and medial circumflex arteries. It was found that sperm count decreased after scrotal reconstruction, although semen volume remained normal (27). This is expected as 90% of the volume of the ejaculate comes from the prostate and seminal vesicles.

### **8. Complications**

- a) *Mortality* has not been reported from pure genital gunshot wounds.
- b) *Major haemorrhage* is likely to be from non-genital organ injury (11) (14).
- c) *Catheter* related problems (blockages and dislodgements) were reported by Gomez (11).
- d) *Urethral strictures* and *sepsis* are more common after delay in presentation.

*e) Erectile dysfunction and chordee* do not appear to be common problems after gunshot wounds to the external genitalia (12). Hall found that 6% (3/45) patients were impotent and that two out of the 45 cases developed significant curvature of the penis. He concluded that over-debridement might have played a role in the two patients with chordee (25).

*f) Fertility* may be affected as discussed above.

### **9. Long-term follow-up**

Long-term follow-up is unsatisfactory due to poor patient compliance (12). Of the close to 200 penile gunshots to the penis reported by 1995, only 37 could be followed up for erectile dysfunction (25). Gomez found that follow-up was poor in the assault group, but not in the accidental injury group of patients who were compliant (11).

University of Cape Town

## **Chapter 2 Aim of the Study**

The aim of this study was to do a retrospective audit on gunshot wounds to the male genitalia in the referral area of Groote Schuur Hospital (teaching hospital to the University of Cape Town).

University of Cape Town

### **Chapter 3 Materials and Methods**

Surgical Research Committee and Ethical Committee approval was obtained in writing - indicating that the study will be submitted for a higher degree in Urology. In total, the author reviewed 70 patient case notes. Not all the data could be found on all the patients and numbers (n) are indicated in the Results section to show how many patients' data could be found on a particular topic.

Data collected by Dr Tyler in the earlier part of the study were validated and added to by studying the relevant microfilms in the Medical Records Department in Groote Schuur Hospital. The case notes studied consisted of hard copy folders or microfilms. Data were obtained from the ambulance records, account details, nursing notes and doctors' notes. The data were filled in on a data sheet. The data were then captured using a dedicated Microsoft Access Form. Queries were run from the Form and analysed as can be seen in the Results section. Demographic and socio-economic data (age, race, area of residence, marriage status, employment, possible relationship problems) were collected. Data regarding number and position of gunshots to the genitalia were collected as well as associated injuries. The position of the penile injury as well as spermatic cord and testicular injuries were documented. Urethral injuries were documented according to the anatomical divisions of the urethra. The velocity of the missile was documented. Urine dipstick at initial evaluation was documented. Management at Groote Schuur Hospital, early and late complications (with special reference to erectile function) were studied. Follow-up time for each case was documented.

## Chapter 4 Results

### Incidence n = 68

The number of these injuries seen per year is shown in Figure 3 (1997 (7 cases) and 2006 (5 cases) were excluded as these study years were incomplete: from August 1997 to September 2006.).

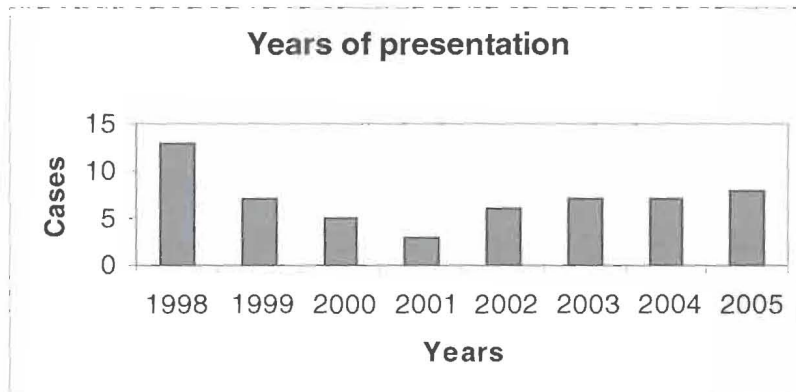


Figure 3 Number of cases of gunshot wounds to the external genitalia seen per year in the study population.

### Months of year (n=68)

The number of cases seen relative to the month of the year is shown in Figure 4..

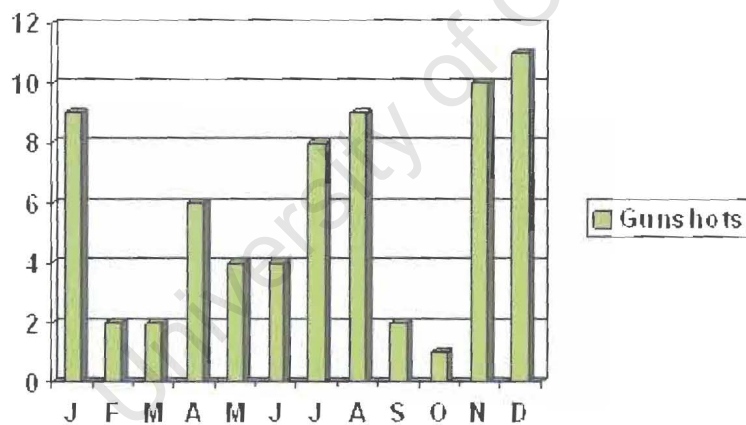


Figure 4. Monthly variation of gunshots during the study period.

January – 9, February – 2, March – 2, April – 6, May – 4, June – 4, July – 8, August – 9, September – 2, October – 1, November – 10, December – 11.

**Age of the study population n=67**

The age distribution of the study population is shown below and in Figure 5:

15-19 year old group: (22.4%)

20-29 year old group: (40.3%)

30-39 year old group: (27%)

41-50 year old group: (10.3%)

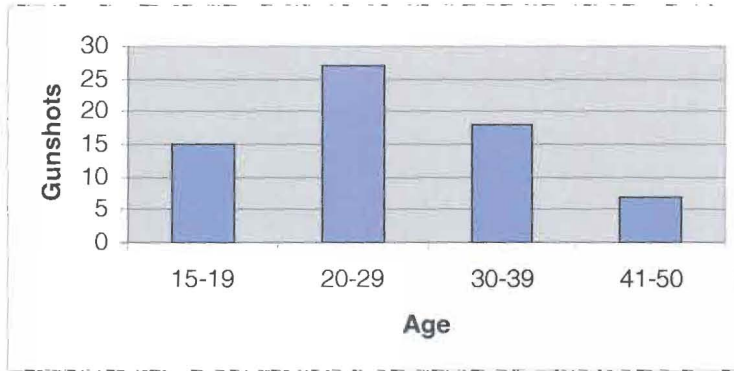


Figure 5. Age distribution of the study population

**Race (n = 70)**

The majority of patients were Black (53%), followed by Mixed Race patients (44%) and the minority of patients were White (3%) as demonstrated by figure 6.

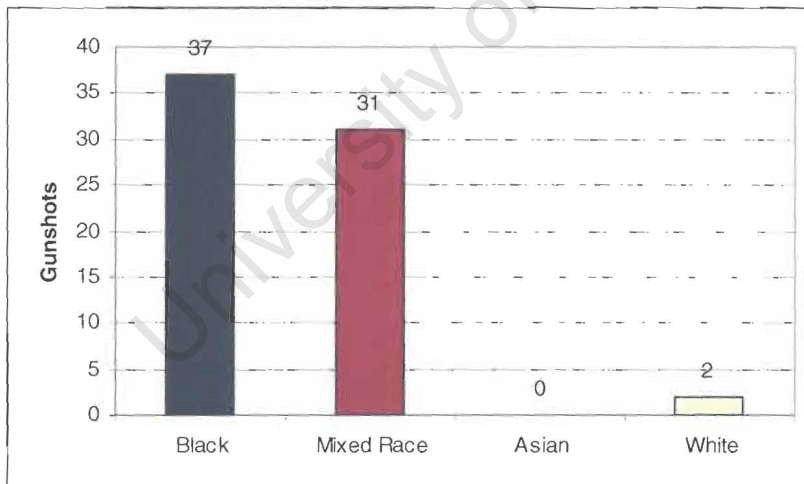


Figure 6. Racial distribution of the study population

### Employment (n = 70)

The unemployment rate was 60% (42 cases). The highest level of employment was a salesman, followed by assistant panel beater, security guard and taxi driver.

### Marital status n=62

The majority were single – 51 (82%) and 11 patients were married (18%). The age range for married patients were 17 – 44 years (average age 31 years). The unemployment rate among married men was 6/11 (54%).

### Residential areas affected n=62

The residential areas from which the patients came were Khayelitsha – 17, Mitchells Plain – 12, Guguletu – 11, Athlone – 4, Manenberg – 3, Langa – 2, Nyanga – 2, Kenilworth – 1 and Pelican Park – 1. This is demonstrated in part by the map below in figure 7:

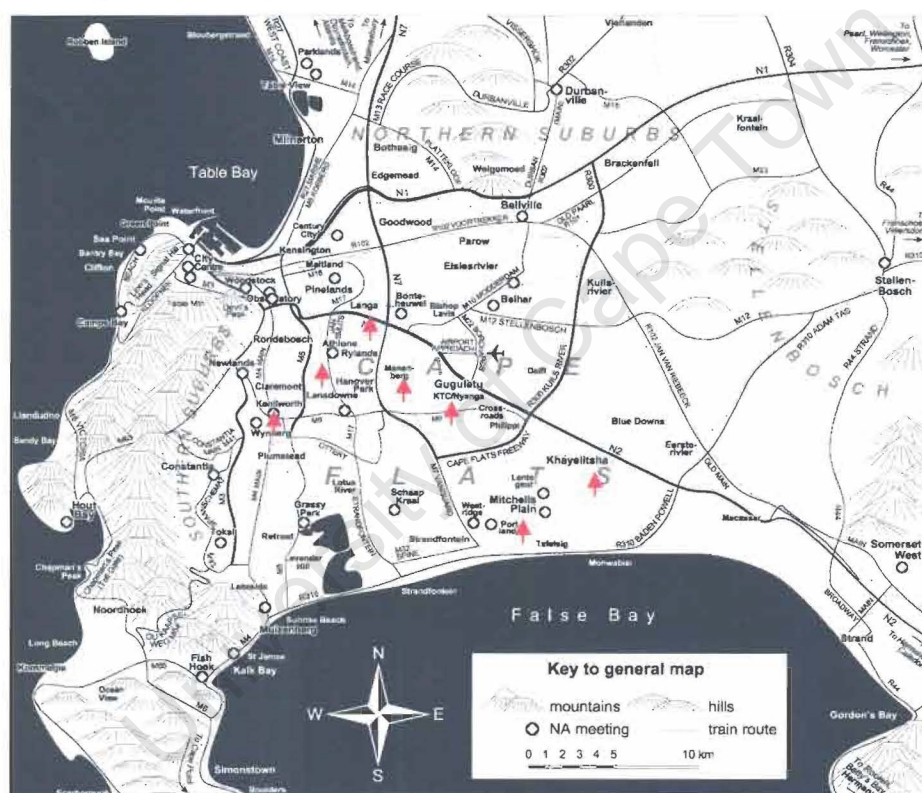


Figure 7. Residential areas around Cape Town affected by genital gunshot wounds.

**Referral sources: n=62**

Primary (Day Hospital) referrals were 41 cases (66%) and secondary level hospital referrals (e.g. GF Jooste Hospital or New Somerset Hospital) were 21(34%).

**Reason for gunshot n=7**

The attending ambulance person, triage nurse, attending trauma doctor or attending urologist in 59 patients, did not document the reason for the incident. In the 7 patients when it was documented there were 2 assaults, 4 robberies and 1 self-inflicted injury.

**Velocity**

Only 1 patient sustained a high velocity gunshot wound and 69 suffered low velocity gunshot wounds

**Position**

Penile gunshots were found in 23 cases (5 urethral injuries).

Peno-scrotal gunshots were found in 23 cases (7 urethral injuries).

Scrotal gunshots were found in 24 cases (2 urethral injuries).

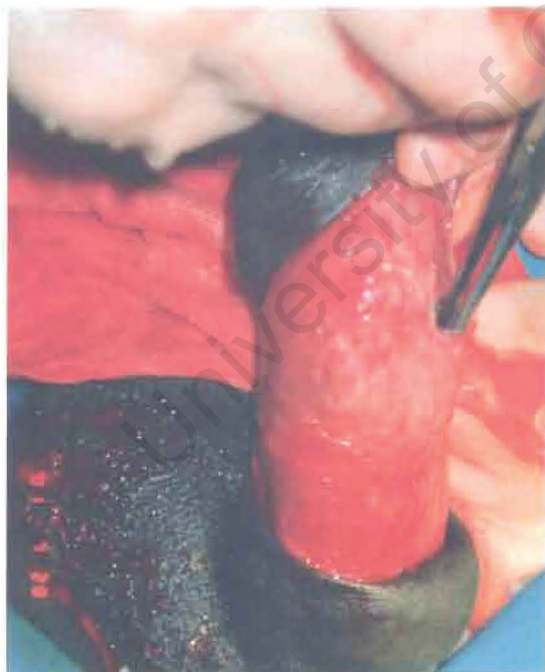

Figure 8. A gunshot traversing the glans and one corpus cavernosum

**Number of shots to genitalia** n=69

65 cases suffered one shot only to the genitalia. Four cases suffered two shots to the genitalia of which 1 had bilateral testis injury, 2 had urethral injuries and 2 had wound infections in the post-operative period. (Please note that the rest of the study will reveal that 3 other patients suffered bilateral testis injury, but this was after a single bullet wound.) There were a total number of 73 gunshots to the genitalia.

**Dipstick Urine** n=67

This routine test was either not documented or done in 45 cases (67%). It was done in 22 cases. It tested positive for blood in 15 patients: 6 had urethral injuries (40%) on further investigation. Dipstick test was negative for blood in 7 patients: 2 had urethral injury (28%) on further investigation.

**Radiological Studies**

Only 4 cases were investigated with micturating cysto-urethrography (the recommended test for these injuries in all cases) (20). These four studies led to only one urethral injury being diagnosed. A further 8 urethral injuries were diagnosed in the non-investigated group by means of cystoscopy. Scrotal ultrasound was used in 2 cases – in both cases this was a helpful test and gave valuable information about the injured state of the testis.

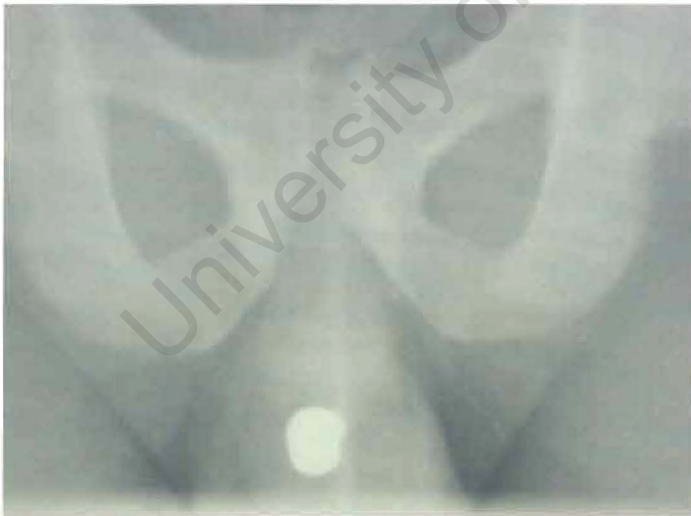

Figure 9. A bullet residing in the bulbar area after a gunshot

Urine diversion away from the injured site was the only treatment in 3 bulbar urethral cases (one case developed a stricture), in 3 penile urethra cases (no strictures developed) and 1 glandular injury that did not develop a stricture.

*Spermatic cord injuries:*

Unilateral spermatic cord injuries occurred in 16 cases. This was associated with 3 unilateral- and 3 bilateral orchidectomies (six orchidectomies resulting from the spermatic cord injury) (the contralateral testis was also injured in some of the orchidectomy cases resulting from spermatic cord gunshot and is reported next – also see “orchidectomies” to clarify data). One case of spermatic cord injury had to be taken back to theatre for bleeding and evacuation of a voluminous haematoma. There were 2 cases of bilateral spermatic cord injuries treated in 1 case with a unilateral orchidectomy. No bilateral orchidectomies were done.

*Testis injuries:*

There were 17 unilateral- and 4 bilateral testis injuries (total 25 testis injuries). This resulted in 5 orchidectomies from the unilateral group. The 4 patients that suffered injuries to both testes: 1 patient had a bilateral orchidectomy and 3 had a unilateral orchidectomy. Bilateral testicular gunshot injuries led to a unilateral orchidectomy in all cases and one case (25%) needed a bilateral orchidectomy.

*Orchidectomies*

There were 10 unilateral and 3 bilateral orchidectomies (16 testes removed). On follow-up of the patients with bilateral orchidectomies, 2 patients did not attend their appointments and the remaining patient is under the care of the Division of Endocrine Medicine to manage his an-orchid state. There were 16 testes removed out of 25 testicular injuries (combined bilateral and unilateral) and 16 spermatic cord injuries to give an overall orchidectomy rate of 38% for spermatic cord and testicular injuries. Sperm count and testosterone levels were not checked.

*Genital skin injuries*

Due to the pliability of the skin no major skin losses were seen as demonstrated by figure 11 and 12 shown before and after “tacking” sutures applied to loosely approximate skin edges to reduce tension and allow drainage between individual sutures if needed.

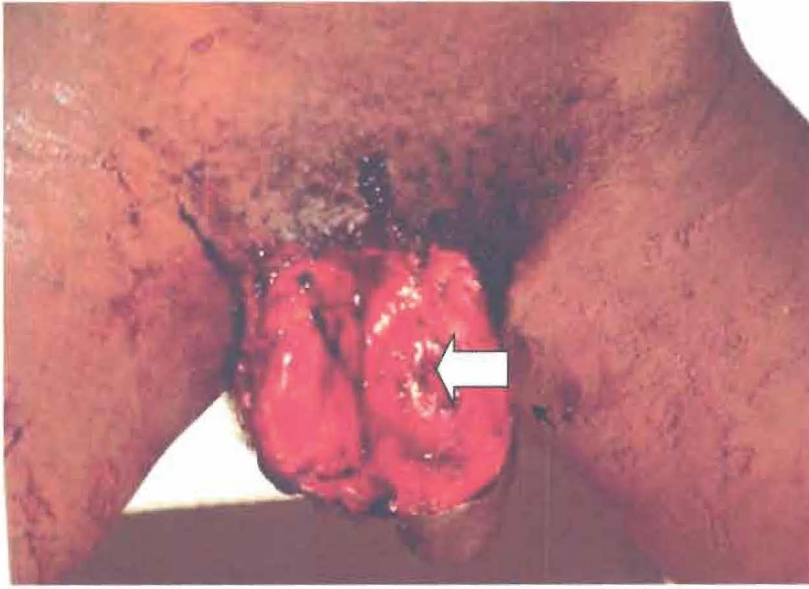


Figure 11. Genital skin loss (a corporeal defect can also be seen at the arrow)

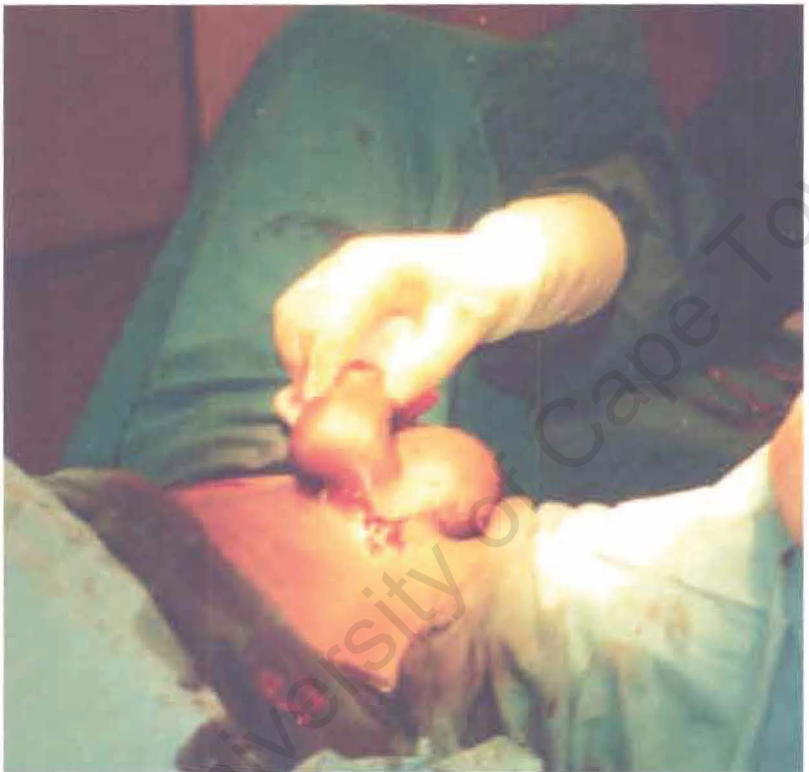
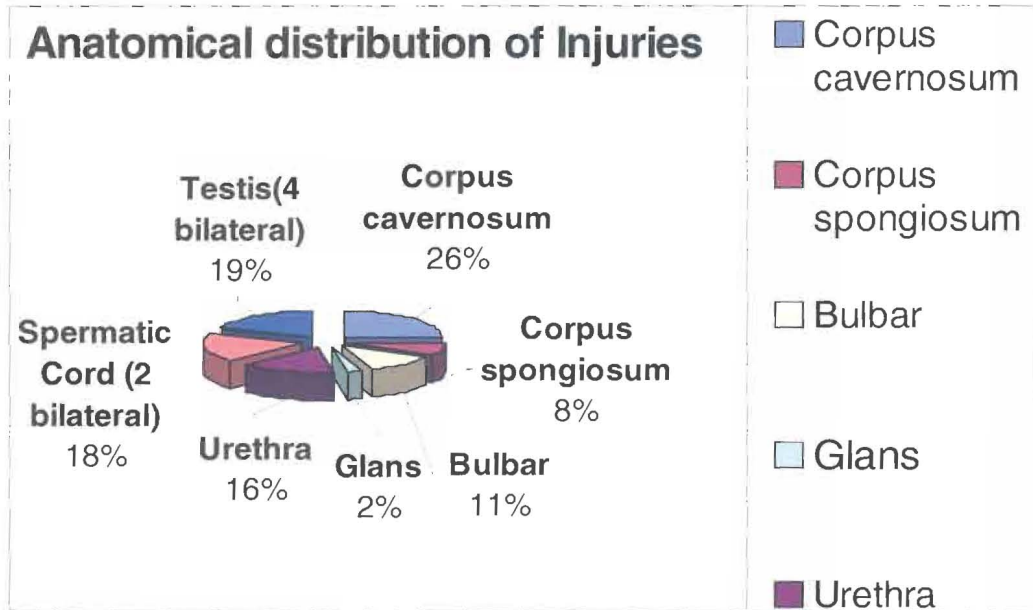


Figure 12. "Tacking" sutures approximating apparent skin loss (in the same patient)

**Anatomical distribution of injuries to genitalia**

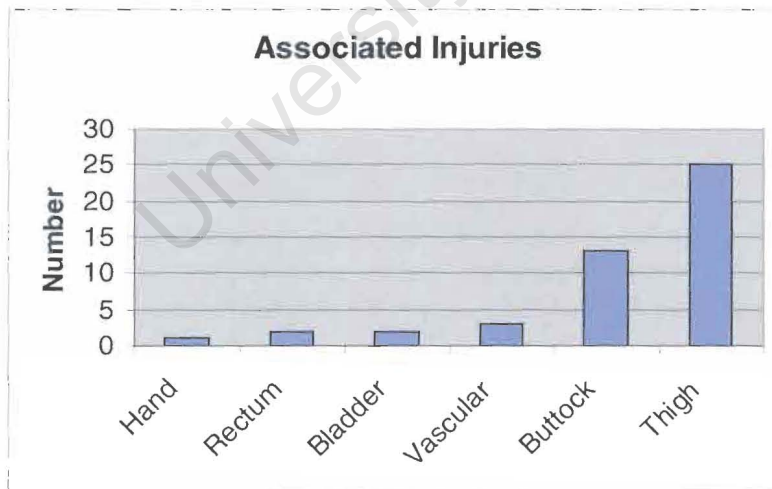


**Figure 13.** Anatomical distribution of injuries sustained to the external genitalia in this study population.

The risk of injury to the corpus cavernosum is the highest and to the lowest to the glans during a gunshot wound to the genitalia as demonstrated in figure 13.

**Associated Injuries**

The most common injury (figure 14) was the thigh in 25 cases, buttock in 13 cases, vascular injuries in 3 cases, rectum and bladder in 2 cases each and 1 hand injury.



**Figure 14.** Associated injuries

### **Complications**

The most common *early complications* (while still in hospital) included raised temperature (above 38°C) in 20 cases, significant wound infection (prolonging hospital stay or needing special attention) in 4 cases and bleeding in 1 case (the patient had to be returned to theatre to control the bleeding from the spermatic cord and drain the voluminous scrotal haematoma).

The most common *late complications* (seen in Out Patient Department after discharge) were wound infection in 5 cases and urethral strictures in 2 patients. Erectile function was only documented in 15 cases. One patient was impotent and referred to the Erectile Dysfunction Clinic where he was assessed to be treated with a vacuum device before disappearing from follow-up. One patient had chordee, but normal rigid erections. This patient was booked for a corporeal plication procedure, but after 3 months waiting for his surgery he informed the attending doctor that his symptoms had disappeared spontaneously. In 13 cases normal erectile function was documented.

### **Hospital stay**

The range was 1 – 8 days with the average – 3.5 days.

### **Follow-up**

Follow-up was available in 37 patients (54%) and ranged between 2 weeks and 18 months. The average length of follow-up was 3.3 months ranging between 2 weeks and 18 months. Thirty-one patients (46%) had no follow-up documented in the case notes.

## Chapter 5 Discussion

In this study the incidence of external genital gunshot wounds has decreased from 1998 (13 cases) to 2001 – 2 cases and then increased again to 9 cases in 2005. This differs from the literature (3) where it is suggested that there is a rising incidence of these injuries with gang violence and drug trafficking. This difference may be due to statistical variation or due to a possible deficiency in data recording during the study time. This study was done in peacetime and the patients were civilians. These injuries might have been much more common during wartime as will be the same as for any type of gunshot injury during war time (1).

The months of the year that injuries took place have not been documented in the English literature. The peak incidences seen in Figure 3 coincide with the school holidays in the area of the study population. However, the numbers are too small to make any definite conclusions.

The ages of the study population agree with those of the literature (11) with the majority of patients younger than 30. However, there were also fifteen teenagers affected with the youngest one being 15 years old.

Black and Mixed Race patients (Figure 6) were far more affected than Asians and Whites. After discussion with the Public Relations Department at Groote Schuur Hospital (Ms Pollio telephone 021 404 2188) it emerged that Mixed Race patients are most frequently seen at Groote Schuur Hospital followed by Black patients. It was also stated that the number of patients from the township of Kayelitsha increase constantly with time. This may coincide with gang violence and poverty, which hampers segments of these racial groups. The fact that no Asians were involved is difficult to explain – it may be related to the fact that the low percentage of Asians seen at Groote Schuur Hospital, socio-economic or possibly religious and cultural influences.

Unemployment was found in 60%. This is a consequence of poverty due to poor education and training. One can deduce from the study results that those who have employment have low socio-economic status jobs. One can speculate that this type

of genital violence seems to be confined to the community socio-economic group, but accurate data on gunshot wounds to other parts of the body does not exist. Richer people might also have medical insurance and visit private hospitals. This would mean that they could not be included in this study and the poorer groups being perceived solitarily affected by genital gunshot wounds.

The majority of these patients were single (82%). This may be a reflection of the age of the patients. They are also at an age where sexual function is very important to them. This may make the genitalia a target. It is not apparent from this study why they were shot or why the genitalia were the target.

The residential areas affected do not follow the general perception in Cape Town that Manenberg is the most severely affected township. Khayelitsha (17 cases), Mitchells Plain (12 cases) and Guguletu (11 cases) were far more affected than Manenberg (3 cases). The exact total population of these townships are not known to work out the incidence per township. It can also be seen that these areas roughly follow the N2 highway approaching Cape Town.

The referral sources were a different pattern to what is prescribed by the regional government (Primary Hospital must refer to Secondary Hospital, which then refers to Tertiary Hospital). Primary Hospitals referred to our University Hospital in 66% of cases – with patients literally referred past the secondary level hospitals. This is possibly explained by the lack of urological knowledge at the secondary hospital level.

Like in the series of Gomez (11) it is not clear if the genitalia were the prime target in the assault. There was only one patient with a high velocity injury. This reflects the civilian nature of the study population where the use of handguns would be more common. The 69 low velocity injuries were thus likely to be from the use of handguns and would agree with the study of Husmann (7).

The anatomical position of the injuries was nearly equally distributed between the penis, peno-scrotal and scrotal gunshot wounds (23, 23 and 24 cases).

The number of shots to the genitalia was only one shot in the vast majority (65 cases). There was no previous history of genital gunshots, as in the study of Miles (12). Four patients suffered two gunshots to the genitalia – all four had more serious injuries as a result (one orchidectomy resulted, 2 urethral injuries, 2 wound infections).

The dipstick urine test is recommended (20), (21). This was unfortunately not performed in 67% (45 cases). This is a worrying finding for a Tertiary Trauma Centre. However, of the 15 patients where it did test positive for blood, there were only six urethral injuries indicating that this test was unreliable. The test was negative in 7 patients. Two of these patients still had urethral injuries diagnosed by rigid cystoscopy under general anaesthesia. Flexible cystoscopy was not used and may be interesting to evaluate in a further study. It appears thus that in our series urine dipstick test has less value to predict a urethral injury than reported in the literature (20), (21). Miles (12) agrees that urine dipsticks are not helpful in the evaluation of these patients.

Special investigations: A micturating cysto-urethrogram (MCUG) is recommended in all cases of penetrating genital injury (20), (21). However, only four of these investigations were done during the study period. Only one urethral injury was diagnosed with MCUG. Eight urethral injuries were diagnosed by cystoscopy at the time of exploration. Scrotal ultrasound (SUS) was used twice and in both cases provided valuable information on the state of the testis making scrotal exploration unnecessary. This seems to be an under-utilized special investigation in this setting as it may save theatre time. No penile ultrasound or cavernosogram was performed.

Penile injuries were treated according to the general recommendations in the literature with debridement and closure of the corpora cavernosa after washing of the wound with anti-septic fluid (15), (20). A bullet lodged in the penis (one patient) was removed by us, but Ficcaro (18) reports a case where a bullet was left in the corpora cavernosum at the penile base and recovery was not affected. No urethral injuries occurred when the bullet tract traversed the glans and corpora – (out of seven cases). The tissue planes might be guiding the bullet away from the

urethra and the low velocity nature of the missile may explain this. There were no penile skin grafts needed as suggested by McAninch. Even large skin defects were closed/re-approximated due to the loose genital skin.

There were only 14 urethral injuries in the studied groups. This may also be a reflection of how missiles may follow tissue planes. Urine diversion as treatment was used in seven cases with stricture disease developing in only one case. This demonstrated that urine diversion is an acceptable method of treatment in this population in contrast to the guidelines in the literature (7), (13), (21). However the author still recommends primary closure of these injuries as numbers are small and there is superior evidence in the literature for primary closure of the urethra (7), (13), (21). The seven urethral injuries that were primarily closed developed a meatal stricture in one case. It is known that meatal injuries of any kind are difficult to manage and even though there are only two cases, urine diversion seems an attractive option in a meatal injury resulting from gunshot. Meatoplasty may have to be performed at a later stage.

Injuries to sixteen spermatic cords resulted in 6 orchidectomies. This is a relatively low number and may be related to the triple blood supply of the testis (4). High velocity injury to the cord is likely to result in more orchidectomies as discussed by Selikowitz (1).

Testicular injury per se does not indicate that an orchidectomy should necessarily be done. Twenty-five testicular (17 unilateral- and 4 bilateral) injuries resulted in ten orchidectomies (40%). This compares relative favourably with the literature that indicates an orchidectomy rate of up to 62% for testicular injuries (11). Those patients who sustained bilateral testis injuries all lost at least one testicle and one patient lost 2 testicles. There is thus a 100% chance to have at least one orchidectomy when both testicles were injured with gunshot.

Genital skin injuries were never found to be problematic in this study population, where low velocity injuries dominated. Thus no skin grafts were needed and no wounds were left open to heal by secondary intention. The author agrees with McAninch that the excellent blood supply of the genitalia allows for the healing of the genital skin even when stretched covering skin defects (26).

The associated injuries that caused the most morbidity were rectal (3 cases) and vascular injuries (2 cases). This is in agreement with Salvatierre (14). The buttock

and thigh were the most frequently affected, but did not cause any severe morbidity. We agree with Gomez (11) that life-threatening haemorrhage is unlikely to be genital in origin, despite the excellent blood supply of the external genitalia.

The complications from the study population are similar to those in the literature. There was no mortality from gunshot to the genitalia. Urethral strictures and sepsis (only four cases in the study period) were uncommon, as also reported by Miles (12).

Erectile function was poorly documented in this study. When it was documented only one out of 15 cases suffered from impotence and one had chordee, but rigid erections. This is in agreement with Hall who reported 3/45 cases of penile gunshot to be impotent and only 2/45 had chordee (25).

Fertility and testosterone levels were not assessed in the study population when indicated e.g. post bilateral testis injury. The reason for this is not clear, but may possibly be related to the cost conscious doctors in government service.

The long-term and even short-term follow-up of the patients in this study group was poor as only 60% returned to clinic for check-up. This is in agreement with Hall (12) and Miles (25) who found poor compliance for similar study populations. One may assume that these patients would return to hospital only if they had significant morbidity and are unlikely to return for follow-up if not bothered by their previous genital trauma. As these study subjects live in violent circumstances, more violent and morbid trauma may have to be dealt with and hospital follow-up is de-prioritised. This is demonstrated by the picture below taken from the microfilm record of one of the study subjects. The injury occurred about 6 months after the genital gunshot. The patient survived the episode, but this was his last recorded hospital admission.

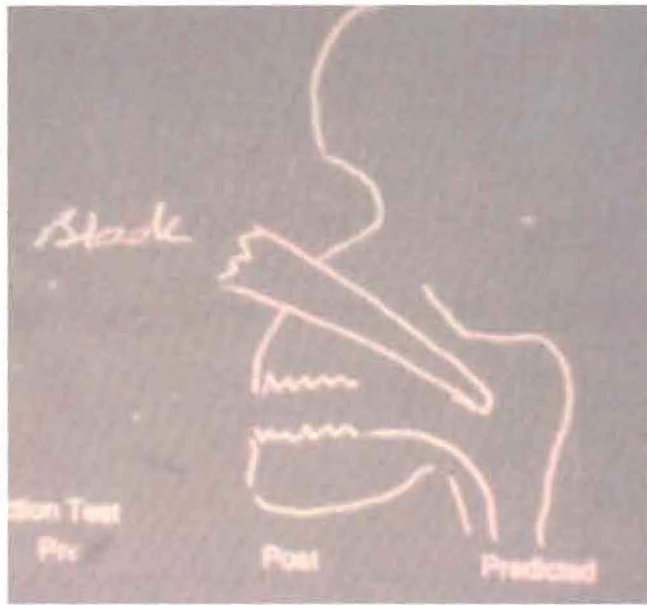


Figure 13. A later admission de-prioritising genital gunshot follow-up

---

University of Cape Town

## Chapter 6 Conclusion and Recommendations

Herman Melville is quoted in (3) regarding the Vietnam War: “*In view of this battle one may ask – what separates the enlightened man from the savage? Is civilization a thing distinct, or is it an advanced stage of barbarism?*”

It would make sense to try to prevent these injuries. However, they are likely to keep occurring and may well drastically increase in number if another war breaks out in our civilized world.

Gunshots to the external genitalia are shown to have relatively low morbidity. The recommendations from this study and from a perusal of the literature are that an *anatomical diagnosis* is crucial to successful management of these patients and can be summarised:

1. **Penis gunshot:** Explore all cases under anaesthetic and do cystoscopy. Urine dipstick is not helpful. Micturating cysto-urethrogram (MCUG) is also not helpful despite being widely recommended.
2. **Urethral gunshot:** Close primarily with fine absorbable suture material at exploration. Urine diversion is an acceptable form of treatment if exploration is rushed due to associated injuries.  
Posterior urethral injuries should have temporary urine diversion as first line treatment.  
Meatal injuries should be treated with urine diversion and interim formal surgical repair by an experienced surgeon if necessary.
3. **Scrotal gunshot wounds:** Ultrasound of the scrotum is an under-utilised test and should be used more to diagnose testis rupture. Scrotal gunshot wounds should be explored and cystoscopy performed in 100% of cases to exclude urethral and testis injury.

#### 4. References

1. Selikowitz SM. Penetrating high velocity genitourinary injuries – Part 1. *Urol* 1977; 9: 371 - 6
2. Herr HW. Urethral injuries in the Civil War. *J Urol* 2005; 173: 1090 - 1093
3. Selikowitz SM. Penetrating high velocity genitourinary injuries – Part 2. *Urol* 1977; 9: 493 - 9
4. Brooks JD. Urogenital Anatomy in Wein Campbell's Urology, Seventh Edition, Chapter 1, page 41 - 2
5. Machtens S. Erectile dysfunction in relation to traumatic pelvic injuries or pelvic fractures. *BJU Int* 2001; 87: 441-8.
6. Cass AS. Testicular trauma. *J Urol* 1983; 129: 299 - 300
7. Husmann DA. Management of low velocity gunshot wounds to the anterior urethra: the role of primary repair versus urinary diversion alone. *J Urol* 1993; 150: 70 - 2
8. Cass AS. Bilateral testicular injury from external trauma. *J Urol* 1988; 140: 1435 - 6
9. Van der Horst C. Male genital injury: diagnostics and treatment. *BJU Int* 2004; 93: 927 - 30
10. McMinn RMH. Last's Anatomy, regional and applied. Ninth Edition, page 406 – 411.
11. Gomez RG. Gunshot wounds to the male external genitalia. *J Urol* 1993; 150: 1147 - 9
12. Miles BJ. Management of penile gunshot wounds. *Urol* 1990; 36: 318 - 21
13. Blumberg N. Anterior urethral injuries. *J Urol* 1969; 102: 210 - 3
14. Salvatierra O Jnr. Vietnam experience with 252 war injuries. *J Urol* 1969; 101: 615 - 20
15. Jolly BB. Gunshot wounds to the male external genitalia *Urol Int* 1994; 53: 92 - 6
16. Willis DL. Non-penetrating gunshot injury as a cause of testicular rupture. *J Urol* 1988; 140: 1543 - 4
17. Corriere JN. Comment. *J Urol* 1993; 150: 72.
18. Ficarra V. Penetrating trauma to the scrotum and corpora cavernosa caused by gunshot. *Urol Int* 1999; 63: 192 - 4
19. Mitchell JP. Injuries to the urethra. *BJU* 1968; 40: 649 - 70
20. Morey AF, Metro MJ, Carney KJ, Millar KS, McAninch JW. Consensus on genito-urinary trauma: external genitalia. *BJU Int* 2004; 94(4): 507 - 15

21. Chapple C. Consensus statement on urethral trauma. BJU Int 2004 ; 93 : 1195 – 202
22. Lupetin AR. The traumatized scrotum: Ultrasound evaluation. Radiol 1983; 148: 203 - 7
23. Muglia V. Magnetic resonance imaging of scrotal diseases: when it makes the difference. Urol 2002; 59: 419 - 23
24. Cass AS. Male genital injuries from external trauma. BJU 1985; 57: 467 - 70
25. Hall JS. Management of gunshot injuries to the penis and anterior urethra. J Trauma 1995; 38(3): 439 - 43
26. McAninch JW. Major traumatic and septic genital injuries. J Trauma 1984; 24(4): 291 - 8
27. McAninch JW. Management of genital skin loss. Uro Cl N Am 1989; 16(2): 387 - 97
28. Weaver RG. Clinical aspects of urethral regeneration. J Urol 1965; 93: 247 - 255
29. Katz R. Resolution of posterior urethral rupture caused by gunshot injury, treated by suprapubic drainage alone. BJU Int 1997; 80: 498 - 99

**Appendix**

Data sheet used to collect data

<b><u>Gsw Ext Genitalia Study Data Sheet</u></b>	
<b>Date entered:</b>	
<b>Study Nr:</b>	<b>Tel Nr:</b>
<b>Hospital No/Label.</b>	<b>Primary ref:</b>
<b>Race:</b>	<b>Secondary ref:</b>
<b>Date of Presentation:</b>	
<b>Delay in presentation:</b>	<b>More than 50km</b>
<b>ref:</b>	
<b>Age:</b>	
<b>Reason for being Shot:</b>	<b>Velocity:</b>
<b>Town:</b>	<b>Dipstix:</b>
<b>Married:</b>	
<b>Relationship problems:</b>	
<b>Employment:</b>	
<b>No. Shots to Body:</b>	
<b>No. Shots to Genitalia:</b>	
<b>No. Of Testis Injured:</b>	
<b>Specific Radiological Tests prior to surgery:</b>	<b>F/U</b>
<b>investigations:</b>	
<b>Urethro-cystoscopy:</b>	

**Bladder Injury:**

**Penis Injury(C/G/Skin):**

**Spermatic cord injury:**

**Scrotal Haematoma:**

**Level of Urethral Injury:**

**Assoc. Injuries:**

**Repairs:**

**Complications(Incl. temp):**

**Follow-up**

**Complications**

**Hospital Stay:**

**F/U Time:**

**Erectile Dysfunction:**

**Testosterone**

**Level:**

**Curve:**

**Voiding:**

University of Cape Town