

**Accuracy of Plain Radiographs for Diagnosing Histologically
Proven Malignant Bone Lesions**

Erhardt Gerber

GRBERH001

University of Cape Town

A research report submitted to the Faculty of Health Sciences, University of the Cape Town, Cape Town, in partial fulfilment of the requirements for the degree of Master of Medicine in diagnostic and interventional radiology.

Cape Town, 2016

The copyright of this thesis vests in the author. No quotation from it or information derived from it is to be published without full acknowledgement of the source. The thesis is to be used for private study or non-commercial research purposes only.

Published by the University of Cape Town (UCT) in terms of the non-exclusive license granted to UCT by the author.

Declaration

I, Erhardt Gerber, declare that this research report is my own work. It is being submitted for the degree of MMed FCRAD (diag) at the University of the Cape Town, Cape Town. It has not been submitted before for any degree or examination at this or any other University.

DR ERHARDT GERBER:

On this 31st day of December 2016.

I dedicate this research to my parents Jan and Petro Gerber for giving me the opportunity and financial back up as a teenager to study medicine. I have huge respect for them and love them a lot.

To Professor Beningfield and his consultants at Groote Schuur hospital for the guidance and teaching.

To Doctor Gerry Cappaert from George who created an interest and love for all things related to “bones, muscles and tendons”.

Publications and presentations

This work has never been published or presented at a congress.

Abstract

INTRODUCTION:

The diagnosis of primary bone tumours is based on a combination of clinical-, radiological- and histopathological findings (triple approach). Plain films form an integral part in the exclusion of malignant lesions and diagnosis of benign lesions. Plain films also play a cardinal role in the initial diagnosis of malignant bone tumours, staging and treatment planning in the management of aggressive/malignant bone lesions. Few studies have been performed where the radiologist's interpretation of plain films is tested against the histopathological diagnosis.

AIM:

1. To determine the spectrum of bone tumours and their relative frequency in patients presenting to a tertiary hospital in South Africa and, using a systematic approach, to determine the sensitivity and specificity of plain film interpretation in the diagnosis of bone lesions presumed to be aggressive.
2. To calculate the radio-pathology correlation of bone tumours.
3. To determine the Interobserver agreement in plain film interpretation of bone tumours.
4. To calculate the positive predictive value (PPV) and negative predictive values (NPV) for aggressive/malignant bone tumour of 8 radiological signs and to calculate the cumulative effect of multiple radiological signs in determining the yield for malignant bone tumours

METHOD:

A retrospective review of histo-pathological reports of all biopsies performed on suspected aggressive bone lesions during a 3-year-period from 2012-2014 was performed. The plain films of the patients who underwent bone biopsies (on suspected aggressive lesions) were interpreted by 4 qualified general radiologists, who used a predetermined standardised format for data capture.

The sensitivity and specificity of the readers' interpretation of the plain film as "benign/non aggressive" or "aggressive / malignant" were calculated against the histology and the inter-rater agreement of the 4 readers was calculated using the Fleiss Kappa values.

RESULTS:

Of the 88 suspected "aggressive/malignant" bone tumours that fulfilled the inclusion criteria, 43 were infective/malignant bone lesions and 45 benign on histology.

Using a predetermined set of criteria, reader sensitivity in the diagnosis of malignancy/infective bone lesions, ranged from 93-98% with specificity of 53-73%.

Calculated Kappa values showed substantial agreement between radiological interpretation and final histology results

The average Kappa value was 0.43, indicates "moderate agreement" between the readers' plain film interpretation. The 4 radiological signs with the highest PPV are: ill-defined border, wide zone of transition, cortical destruction and malignant periosteal reaction. The presence of all 4 of these signs on plain film has a 100% yield for a malignant bone tumour or infective lesion

CONCLUSIONS:

The use of a systemic approach in the interpretation of bone lesions on plain film yields high sensitivity but low specificity for malignancy and infection. The presence of benign bone lesions with aggressive plain film appearance necessitates continuation of the triple approach to the diagnosis of primary bone tumours.

Acknowledgements

My thanks go to:

- Doctor Hosking and his staff at the Orthopaedic Oncology Clinic Groote Schuur Hospital for making their patients' data available for the completion of this project.
- The 4 radiologists who gave up their time and effort as readers.
- Professors Tracy Kilborn, Savvas Andronikou and Jeanette Parkes for their input and advice.
- Professor Martin Kidd of the University of Stellenbosch who assisted with the statistical analysis.
- The staff at Melta electronics for their help in copying and printing.

Table of Contents

Declaration.....	ii
Publications and presentations.....	iv
Abstract.....	v
Acknowledgements.....	viii
List of Figures	xi
List of Tables.....	xii
1. Introduction	1
1.1. Relevant Clinical findings in bone tumours.....	2
1.2 Imaging of bone tumours.....	3
1.3 Plain film imaging features of bone lesions	4
1.4 Characterisation of bone lesions on plain film.....	8
1.5 Characterisation of bone lesions on Magnetic Resonance Imaging (MRI).....	9
1.6 The role of biopsy.....	9
1.7 Similar studies from the literature	11
1.8. Aim of study.....	15
1.9. Research design	16
1.10. Population	16
1.11 Study objectives	16
1. 12 Reliability and validity	17
2. Materials and Methods.....	18
2.1. Inclusion and exclusion criteria	18
2.2. Data collection	19

2.3. Statistical analysis	19
2.4 Bias	22
3. Results	23
b. Radiological interpretation	27
4. Discussion.....	36
4.1. Histological spectrum of all biopsied lesions	36
4.2 Inter-observer reliability/Reliability of radiographic interpretation	39
4.3. Implications of the study findings / Current applications	43
4.3. Limitations of the current study.....	45
4.4. Future applications.....	46
5. Conclusion	47
Appendix A: Plain film imaging features of bone lesions	49
Appendix C Technical guideline for open biopsy(28)	50
Appendix D: Ethics Clearance Certificate and extension of ethics clearance.....	52
Appendix E: Data collection sheet.....	54
Appendix F Interpretation of Kappa values (40)	56
Appendix G: Histology of soft tissue tumours in the 23 patients.....	57
5. References.....	59

List of Figures

Figure 1: Age distribution of the patient who had bone biopsies.....	24
Figure 2: Comparison between different readers' interpretations of plain films	27
Figure 3: Positive and negative predictive values of individual signs used	34

List of Tables

Table 1.4 Bone lesions with characteristic features.....	8
Table 1.7.1.. Table 1.7.1. Similar studies in the literature that compared the percentage of benign vs. malignant bone tumours in biopsied series within developing countries.....	12
Table 1.7.2 Table 1.7.2. Similar studies in the literature comparing the percentage of benign vs. malignant bone tumours in biopsied series within developed countries.....	13
Table 1.7.3 Similar study with correlation between radiology and specific bone tumour diagnosis.....	14
Table 1.7.4 Similar study with Computer aided detection (CAD) of lytic benign.....	15
Table 3.1 Histology of bone tumours in those patients for whom plain film was not available for review.....	26
Table 3.2 Summary of histologically malignant and infective lesions (n=43).....	27
Table 3.3 Summary of histologically benign lesions (n=45).....	27
Table 3.4 2x2 table of sensitivity and specificity for reader 1.....	29
Table 3.5 2x2 table of sensitivity and specificity for reader 2.....	30
Table 3.6 2x2 table of sensitivity and specificity for reader 3.....	30
Table 3.7 Overall sensitivity and specificity of combined radiological opinion.....	31
Table 3.8: Interobserver reliability.....	32
Table 3.9 Positive and negative predictive values for radiological signs according to readers 1-3 and majority.....	33

Table 3.10 2X2 table to demonstrate how PPV and NPV were calculated for cortical destruction

vote.....34

Table 3.11 Cumulative yield of the 4 “major” radiological signs.....36

1. Introduction

Incidence and prevalence:

Primary malignant bone lesions are uncommon in Africa and the rest of the world, with most bone tumours being benign (1). The most common malignant bone lesions are metastatic bone deposits (2). Primary malignant bone tumours are the sixth most common cancer in children, while in teenagers and young adults, they are the third most common, with only leukaemia and lymphomas being more common (3). The true incidence of benign bone tumours is not known, as most patients are asymptomatic and these lesions are usually discovered incidentally on plain film (4). Benign bone lesions occur roughly a hundred times more frequently than primary bone tumours (4).

A large number of primary malignant bone lesions affect young adults and adolescents, causing significant morbidity and mortality (5). In a survey conducted by the National Cancer Register of South Africa in 2007, 111 males and 97 females were diagnosed with primary bone malignancy. Of these 50% (72 males and 47 females) were under the age of 30 (6).

Histological findings:

Primary bone tumours are classified according to their cytological features and cellular products) into 3 categories:

- benign,
- malignant (primary and metastatic bone tumours)
- non-neoplastic including infective and lesions due to metabolic causes (3,4).

For many of these malignant lesions including osteosarcoma and Ewing sarcoma, improved surgical techniques and multidisciplinary management have resulted in improved prognosis and limb salvage (5).

The diagnosis of primary bone tumours is based on a combination of clinical (1.1), radiological (1.2-1.5) and histopathological findings (1.6) (triple approach) (6).

1.1. Relevant Clinical findings in bone tumours

Incorporation of the clinical history and examination findings into the radiological decision-making process, improves diagnostic certainty. The following clinical factors need to be addressed when assessing a patient with a bone tumour:

- Age: Certain bone tumours occur largely or, in some cases, *only* in certain age groups (Appendix A).
- Past history: A bone lesion in a patient with known primary malignancy is likely to represent a metastasis (2). A history of trauma is important when distinguishing between parosteal osteosarcoma and myositis ossificans as the imaging findings and histology are similar with the potential for inappropriate treatment with chemo radiation and amputation.
- A history of penetrating trauma can also guide the clinician to the possibility of direct bacterial inoculation with subsequently osteomyelitis rather than primary bone tumour.
- Presenting complaint: The presence or absence of pain, the presence of night pain, swelling, loss of function as well as systemic complaints such as fever and weight loss are important determinants in refining the differential diagnosis.

- Clinical examination: The detection of a mass, local signs of infection, focal neurological deficit and inability to weight bear (possible pathological fracture) should be assessed.
- Biochemistry: A knowledge of any biochemical indicators of infection such as a raised erythrocyte sedimentation rate (ESR), C-reactive protein or white cell count or increased bone cell activity e.g. blood Alkaline phosphatase levels (6).

1.2 Imaging of bone tumours

In the diagnosis of aggressive bone lesions, imaging features are important for the initial diagnosis and subsequent management (7). Even with the availability of advanced cross sectional imaging methods including multi-detector Computerised Tomography (CT) and increased field strength Magnetic Resonance imaging (MRI), the plain film imaging features best correlate with the final histological diagnosis (8).

Plain radiographs should be evaluated using a standardised system of assessment as set out in 1.3 (12) below and Appendix E (10). CT and MRI provide additional information: CT, in evaluating the cortex and matrix (11) and MRI in determining the intramedullary and soft tissue extent, and in the detection of skip lesions (4).

Some benign/non-aggressive lesions have characteristic plain film features and can be diagnosed easily and affordably using plain film. It is important for the radiologist to be familiar with the plain film features of the most common benign bone tumours, as recognition of benign features on plain film may avoid unnecessary further imaging and biopsy (12,13) .

A “wait and watch” approach to these lesions is recommended.

Biopsy is indicated if the lesion is considered to have an ‘aggressive’ radiological appearance (7,14).

Benign and malignant bone tumours often share similar plain film features. Common benign and non-neoplastic lesions that can mimic tumours include: Brodie abscess, osteomyelitis, tuberculosis, pseudocyst, fibrous dysplasia, stress fracture, avulsion fracture in healing stage, bone infarct, periosteal desmoid, Brown tumour, sarcoidosis of the bone and pseudotumour in haemophilia. The plain film similarities between these lesions and true malignancies result in unavoidable bone biopsy (15).

At our center, careful review of plain film is the initial step in the work up for a suspected bone lesion. Where there are aggressive, malignant or equivocal features, MRI is obtained. Once primary bone malignancy has been established histologically, further imaging in the form of CT and or PET /CT and technetium bone scan are obtained to exclude metastatic dissemination.

1.3 Plain film imaging features of bone lesions

Undiagnosed bone lesions can be classified as either aggressive or benign (non-aggressive) tumours. Biopsy is indicated if a bone lesion has an aggressive appearance , which includes

- i) ill defined margin
- ii) wide zone of transition,
- iii) cortical expansion and destruction
- iv) malignant periosteal reaction (12).

See 1.3 e ii and f below for further explanation.

When attempting to make a diagnosis on plain film radiography alone, several variables should be considered. These include:

a. *Age:*

Certain lesions are more common in certain age groups (9).

See Table A in appendix for lesions that tend to be age specific.

b. *Site:*

Certain bone tumours have predilections for either the diaphysis, metaphysis, and epiphysis as well as for certain bones, example the sacrum, clivus or posterior elements of the spine (9).

See diagram B in appendix for description of lesions that tend to occur at specific sites in the bone.

c. Solitary versus Multiple lesions

Multiplicity indicative of metastatic deposits or myeloma (9).

d. *Size* of the lesion:

Larger lesions are usually more aggressive (9) .

e. *Tumour matrix:*

Bone matrix is defined as the intercellular substance of bone tissue consisting of collagen fibres, ground substance and inorganic salts like calcium. Most lesions do not produce matrix, but if tumour matrix is present, it gives an additional clue to the diagnosis.

i. Matrix Types:

Osteosarcoma has “cloudy amorphous” new bone formation.

Fibrous dysplasia has “ground glass” matrix

Chondroid lesions have “rings and arcs” type matrix.

Intramedullary infarcts produce “smoke up the chimney” matrix (9).

ii. Absence of matrix (Lucent lesions):

Lodwick et al classified the plain film appearance of lucent bone lesions as ‘geographic’, ‘moth eaten’ or ‘permeative’.

In order of increasing aggressiveness Lodwick classified lucent lesions into 3 types:

Type 1 - Geographic: Described as a single lesion with a distinct rim/margin (16) and is further subdivided by the lesion’s margins:

1a: Sclerotic margin

1b: Well-defined margin

1c: Poorly defined margin

Type 2 - Moth eaten: represents confluence of multiple small lytic regions of variable size in trabecular and cortical bone and is indicative of metastatic disease.

Type 3 - Permeative: demonstrates multiple elongated holes along the cortex- commonly occurring in Ewing’s sarcoma and myeloma where there is no effect on the outline of the bone (9).

f. Local behaviour of the lesion

i. Margin:

The lesion's margin is a good indicator of the growth rate. It most accurately reflects the benign or aggressive nature of the bone tumour (18)(19).

Based on the radiographic appearance of the margin/ rim, Enneking classified lesions of bone as:

-Latent: characterised by a thick reactive rim of bone around the tumour.

-Active: where a thin cortical shell forms around the lesion, usually in an expansile lesion.

-Aggressive: characterised by the absence of reactive bone due to rapid growth. This usually leads to a wide zone of transition on plain film (9,17).

ii. Periosteal reaction:

The periosteal reaction may provide additional information about the bone lesion.

Periosteal reaction is indicative of involvement of the outer cortex by the tumour.

Malignant periosteal reactions include "onion skin" appearance and "sunburst" or "Codman's triangle" periosteal reaction appearance (12).

iii. Cortical destruction

Complete destruction may be seen in high-grade malignant lesions, but also in locally aggressive benign lesions like EG and osteomyelitis. More uniform cortical bone destruction can be found in benign and low-grade malignant lesions.

Endosteal scalloping of the cortical bone can be seen in benign lesions like Fibrous Dysplasia and low-grade Chondrosarcoma (12).

1.4 Characterisation of bone lesions on plain film

In the evaluation of solitary bone lesions, one of the following 2 approaches can be taken:

- i. Analytical approach: By using a systematic analytic approach that is dependent on various radiographic features or signs, the nature of a bone lesion can be established (9,16).
- ii. “Spot” diagnosis or “Aunt Minnie”: Where the reader has seen the lesion in the past and knows what the diagnosis is (9).

The “spot diagnosis” approach requires extensive musculoskeletal knowledge and experience.

The following bone lesions have very characteristic imaging features allowing accurate diagnosis by an experienced reader.

Table 1.4 Bone lesions with characteristic features (9)

Bone lesion	Characteristic imaging findings
Bone island	Dense sclerotic focus with a spiculated margin. The lesion has trabeculae that is continuous with adjacent bone.
Exostosis	Benign bone growth extending outward from the surface of the bone e.g. Surfers ear and subungual exostosis.
Osteoma	Small smooth homogeneous dense lesion, with a well-defined spherical margin that is attached to underlying bone.
Osteoid osteoma	Characterised by a dense or lucent nidus, that is surrounded by reactive medullary sclerosis and a periosteal reaction.
Osteoblastoma	Predominantly lytic eccentric lesion, that is common in the spine and sacrum. It expands bone, with surrounding reactive sclerosis.
Enchondroma	Well-defined oval or lobulated eccentric lytic lesion, causing cortical expansion and “popcorn” type calcifications.
Chondroblastoma	Eccentric spherical or lobular lytic lesion, with fine sclerotic margin, centred within the epiphysis
Osteochondroma	Continuous bony outgrowth from the normal cortex that may be pedunculated or sessile.
Non-ossifying fibroma	Oval shaped lobulated lesion within the cortex, with ‘soap bubbly appearance’ usually affecting the tibia.
Giant cell tumour	Eccentric lytic lesion within the subchondral bone that has a well-defined non-sclerotic margin. Poorly defined margin indicates aggressive nature.
Vertebral	Round lucent lesion within the vertebral body that has a “polka-

haemangioma	dot" or stippled appearance.
-------------	------------------------------

1.5 Characterisation of bone lesions on Magnetic Resonance Imaging (MRI)

- a. Determining focal extent (including cortical breakthrough), local staging and intra-tumoral necrosis and haemorrhage.
- b. Detection of "skip" lesions not visible on other image modalities.
- c. Assessment of neurovascular bundle and joint involvement not possible with plain film or CT.
- d. Evaluation of effectiveness and follow-up of treatment of bone tumours (18).
- e. Distinguishing between medullary infarcts, healing stress fractures, metastatic deposits and round-cell tumours (in symptomatic patients with normal plain films) (19).
- f. To direct biopsy, in order to increase yield and avoid complications (19).

Despite these advantages, MRI is of limited value in predicting bone tumour histology and may lead to overestimation of the aggressiveness, due to marrow and soft tissue oedema. It is important to remember that the interpretation of MRI may be difficult post biopsy, because of the change in appearance due to surgical field haematoma, oedema and reactive fibrosis (19).

1.6 The role of biopsy

It is widely accepted that open biopsy is the gold standard for obtaining tissue samples for histological diagnosis (20–23). Although associated with risk

(spillage of tumour cells, potential morbidity, high cost and time needed for the procedure) biopsy is a critical step in the management of musculoskeletal tumours (20,24).

A comprehensive multicentre review of 329 patients who underwent open biopsies found that 10 % were non-representative or technically poor. 17% were complicated by cellulitis, wound sepsis, dehiscence and soft tissue infection requiring skin graft and surgical flaps. The optimum treatment plan had to be altered as a result of biopsy complications in 18% and 5% had unnecessary amputation as a result of biopsy complications.

Biopsy-related problems occurred three to five times more frequently when the biopsy was performed at a referring institution rather than in a specialist treatment centre (25).

The same authors repeated the study more than a decade later and included 597 patients, with no significant change in the results (26). These studies highlight the risk of bone biopsy and the need for specialist care in the management of these lesions (23,27).

In a more recent prospective study conducted at a specialist centre using stringent guidelines (Appendix C), Biau et al (28) reported a low risk and complications rate for incision biopsy.

Core needle biopsy decreases morbidity, costs and time and results in fewer complications. Its accuracy has been reported to be more than 90% (25). It may be performed under local anaesthesia in the outpatient setting or, as is our practice, in theatre under general anaesthesia. Immediate in- theatre frozen section ensures a representative sample.

Fine needle aspirate (FNA) of musculoskeletal tumours has shown promising results and may be used as an alternative to core biopsy with accuracy between 80-90% (2)(29)(30)(31). The principle of FNA is much the same as core needle biopsy but has the advantage of using a thinner needle and requires only local anaesthetic. It may therefore be performed in the clinician's office or radiological department.

Unlike the specimens obtained with open core biopsy, the specimen obtained from FNA allows assessment of cytology only (i.e. cellular composition) as opposed to full histology with associated reduction in both sensitivity and specificity (30)(31)(32).

1.7 Similar studies from the literature

Several previous studies have examined the relative rates of biopsy proven benign and malignant bone lesions, though few have specifically compared imaging findings and biopsy outcome. In those studies that examined pre-biopsy imaging, there was very poor positive predictive value for malignancy (50 -75 %) (29-36).

Two studies reviewed the imaging, clinical findings and allowed discussion between consultant and with orthopaedic surgeons. Vijay included MRI imaging in assessment. Both studies had relative high sensitivity and specificity in the accuracy of image interpretation and final histological diagnosis (Table 1.7.3)

One study made use of computer-aided detection in the final diagnosis of lytic benign bone lesions. Using computer programming and the systematic approach by Lodwick(16) , they had high sensitivity and relative high specificity when correlated with the final histological diagnosis (Table 1.7.4).

These are summarised in Tables 1.7.1.and 1.7.2.

Table 1.7.1. Similar studies in the literature that compared the percentage of benign vs. malignant bone tumours in biopsied series within developing countries

Author	Nnodu 2006(33)	Giwa / Obalum 2009(34)	Chakrabarti 2012(35)	Rhutso 2013(32)
Number of patients and period of study	96(5 years)	242 (25 years)	51 (1 year)	98 (3 years)
Country	Lagos, Nigeria	Lagos, Nigeria	Kolkata, India	Manipur, India
Benign number	29/30%	130 /242 (54%)	20/51 (39%)	41/98 (42%)
Malignant/Aggressive number	58/60% (9% had inadequate cytology results)	112/242 (46%)	31/51 (61%)	21%(primary bone tumours+37% infections/98 (59%)
Gender distribution	57 males (59%) 39 females (41%)	144 males (60%)/98 females (40%)	33 males (65%)/18 female (35%)	50 males (51%)/48 females (49%)
Age distribution	4-76, with mean age of 31,5	2 nd decade (36%)	10-78	2 nd decade 43%3 rd decade 32% (75% <30 years)
Site distribution	Femur and tibia	Not mentioned	Femur, followed by tibia	Femur, followed by tibia
Biopsy technique	Fine needle and open biopsy	Not mentioned	Fine needle + Open biopsy	Not mentioned
Type of imaging	X-rays only	Not mentioned	X-ray, CT and MRI	Not mentioned
Comments	3 biopsies had no cytology result and 6 insufficient samples	10 cases/year. Authors attributed it to culture and possibility of alternative medicine		Large number (36/98=37%) of osteomyelitis

--	--	--	--	--

Table 1.7.2. Similar studies in the literature comparing the percentage of benign vs. malignant bone tumours in biopsied series within developed countries.

Author/date	Akerman 1976 (30)	Bommer 1997 (31)	Jelenek 2002 (29)	Musculo 2003 (36)
Number of patients	150 (17 years)	385 (18 years)	110 (8 years)	25 (18 years)
Country	Lund, Sweden	Houston, Texas	Washington, USA	Buenos Aires, Argentina
Benign number	39/77 (51%)	157/385 (41%)	33/110 (30%)	11/25 (44%)
Malignant number	38/77 (49%) (73 metastatic)	215 (56%) 11 'suspicious' cytology 2 cases were inconclusive	77/110 (70%)	14/25 (56%)
Gender distribution	Not mentioned	Male (56%): Female (44%) 1,25:1	44 males (40%)/66 females (60%)	18 males (72%)/7 females (28%)
Age distribution	Not mentioned	(5-94)	Mean age 38 (8-84)	Mean age 27 (15-55)
Site distribution	Not mentioned	Predominantly Spine (49 %), then ileum, sacrum, ribs and femur	Not mentioned	In close proximity to the knee. 15 cases distal femur
Biopsy technique and by whom		CT guided FNA by radiologist	85 cases CT guided 25 cases Fluoro-guided by MSK Radiologist	Core needle biopsy (0,8 mm) by the cytologist

Type of imaging	Plain film	Not mentioned	CT/MRI	Initially plain film. MRI were done on review after initial misdiagnosis
Purpose of study	To determine the diagnostic accuracy of image guided percutaneous core needle biopsy	To determine the reliability, areas of diagnostic difficulty and limitations of FNAB in bone tumours	To determine the diagnostic accuracy of image guided percutaneous core needle biopsy	Review the 25 referred cases (including radiographs) that were incorrectly diagnosed as sports injuries and the effect of the intra-articular procedure on the final management.

Table 1.7.3 Similar study with correlation between radiology assessment and specific bone tumour diagnosis

	Vijayaragharan(37)	Negash (38)
Author		
Number of patients and period of study	212 2 year	205 5 years
Country	India	Ethiopia
Benign number	65 (31%)	57%
Malignant/Aggressive number	147 (69%) comprising of: chronic osteitis= 30% out of 147 TB =14% Primary malignant tumours=29% Metastases =27%	43%
Gender distribution	Male: female =58%: 42%	Male: female =51%: 49%
Age distribution	2 nd decade= 20% 6 th decade= 17%	7-55, with commonest group 15-29
Site distribution	Not mentioned	Predominantly long bones, but Included facial bones

		(n=41) and spine (n=1)
Biopsy technique	Amputation and image guided biopsy	Not mentioned
Type of imaging	Plain film and MRI	Plain film
Comments	Sensitivity 82% Specificity 78%	Sensitivity 94% Specificity 77%

Table 1.7.4 Similar study with computer aided detection (CAD) of lytic benign bone tumours.

Author	Milan Samarzinski (39)
Number of patients and period of study	120 Cases collected over 7 year period.
Country	Macedonia
Benign number	120
Malignant/Aggressive number	0
Gender distribution	Male: female =58%: 42%
Age distribution	6-79 mean age: 27,4 years
Site distribution	Not mentioned
Biopsy technique	Not mentioned
Type of imaging	Plain film
Comments	Only reviewed benign lytic lesions. Using CAD 72% radio-pathological concordance in final histological diagnosis

1.8. Aim of study

1. To determine the spectrum of bone tumours and their relative frequency in patients presenting to a tertiary hospital in South Africa and, using a systematic approach, to determine the sensitivity and specificity of plain film interpretation in the diagnosis of bone lesions presumed to be aggressive.
2. To calculate the radio-pathology correlation of bone tumours.
3. To determine the Interobserver agreement in plain film interpretation of bone tumours.

4. To calculate the positive predictive value (PPV) and negative predictive values (NPV) for aggressive/malignant bone tumour of 8 radiological signs and to calculate the cumulative effect of multiple radiological signs in determining the PPV for malignant bone tumours

1.9. Research design

This was (a) retrospective descriptive case series and (b) an agreement study comparing assessment of malignancy on plain film imaging with histopathological diagnosis on biopsy.

1.10. Population

The study population comprised adult patients (13 and older) who had a bone biopsy performed at Groote Schuur hospital during a 36 month period between 2012- 2014.

1.11 Study objectives

- To identify the population of patients who have undergone bone lesion biopsy in one tertiary referral centre in South Africa during a 3-year period.
- To determine the frequency in each of the categories and subtypes defined as 'malignant', 'benign', 'infection' and 'inconclusive' based on histology.
- To review the pre-biopsy plain films on these patients.

- To determine the sensitivity and specificity of reports generated by 4 independent specialist radiologists using an objective scoring system in the interpretation of the plain film.
- To determine the positive predictive value of the individual signs for a “malignant/aggressive” histology result.
- To determine inter-observer agreement between 4 consultant general radiologists with regard to pre-determined individual radiological features reported and with respect to the final diagnosis given.
- To determine the sensitivity and specificity in the categorisation of the plain film findings as either “benign” or “malignant/aggressive” when the “majority vote” is considered (see below).
- To determine the false negative reporting rate i.e. the number of bone lesions incorrectly characterised as “benign/non aggressive” but where histology confirmed a “malignant/aggressive” lesion.
- To determine the frequency of tuberculosis and other infective osteitis on histology and culture.

1.12 Reliability and validity

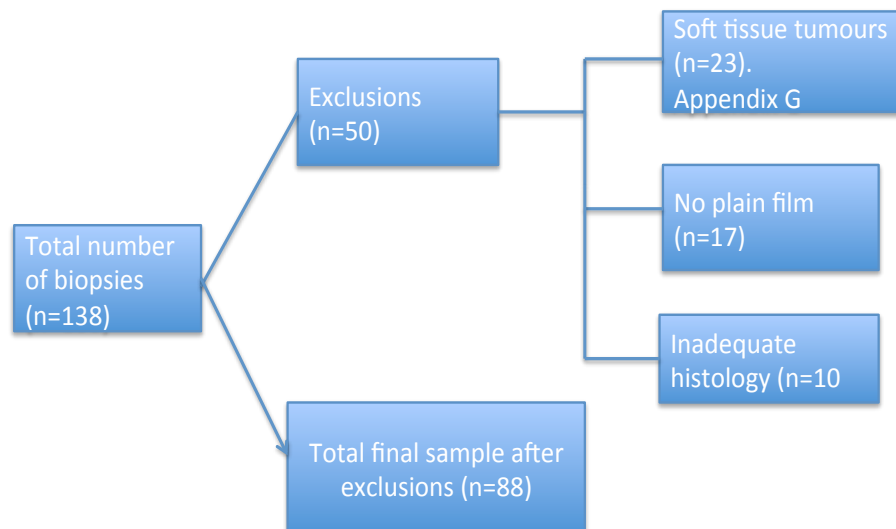
- Plain Film imaging is universally used as a screening tool in the assessment of bone lesions.
- Previously validated data denoting features suspicious for bone malignancy on plain film are used in this study (9)(16)(17)(19).
- The study design used four readers to allow a majority panel decision and thereby improve reliability.

2. Materials and Methods

2.1. Inclusion and exclusion criteria

- All patients of age 13 years and older, who had undergone a bone biopsy in the Hosking's' Tumour and Sepsis Orthopaedic firm at Groote Schuur hospital, were considered for inclusion during the time period of 1 January 2012 till 31 Dec 2014.
- Only those patients with an available histology report and imaging in the form of plain films of the affected area were included.
- Patients with inadequate or inconclusive histology were excluded from the study.
- Patients with biopsies that yielded histology results of soft tissue (non-osseous) tumours were excluded (See flow chart 2.1 for breakdown of exclusions).

Flow chart 2.1 Number of biopsies with exclusions



2.2. Data collection

- Four general radiologists with approximately the same seniority/expertise (5 years post-graduation experience) were recruited.
- None of the images had been reviewed by any of the panel prior to the study.
- Plain X-ray films were anonymised and assigned a case number.
- The images were stored on a removable USB device and issued to each consultant to be reviewed independently.
- At the time of review the radiologist was required to complete a data collection sheet (appendix E) and to categorise the bone lesion as either “benign,” “aggressive/malignant” or “Inconclusive”.
- The readers were not instructed as to the number of positive/ negative radiological signs, which would constitute an aggressive or benign lesion or inconclusive categorization.

2.3. Statistical analysis

Histology:

- Results were expressed as frequencies and percentages for categorical variables.
- Histology results were categorised into 2 groups: Benign lesions, malignant lesions and infection and the frequency of particular histology was recorded for each category.

Pooled results using the majority vote system:

- For each case a final radiological diagnostic decision was generated using a majority rule: 2 or 3 out of 3 taken as a majority decision.
- The four radiologists are referred to as “Reader 1”, “Reader 2”, “Reader3” and “Reader 4”. Readers 1-3 are the principal readers, with their results used for data analysis and calculation of the “majority rule”. See below
- All 88 cases were analysed by all 4 readers but Reader 4’s findings were utilised only for statistical analysis where no consensus was reached by the first 3 readers i.e. where one reader interpreted the findings as malignant, a second reader as benign and the third reader reported the same film as inconclusive.
- In the event of a three way split in diagnosis between readers 1, 2 and 3, the fourth reader’s decision determined the majority vote.
- Reader 4 was not more experienced than readers 1-3, but the role of reader 4 was solely to avoid a “split vote”.

Radio-pathological correlation:

- Sensitivity and specificity were calculated for the readers independently and for the “majority vote.”
- To avoid the possible devastating consequences of missing a malignant bone tumour, equivocal or inconclusive final decisions were grouped together with “Malignant” as *positive* findings in calculating sensitivity and specificity, as a delay in diagnosis of a malignant bone tumour, can lead to local spread, neurovascular involvement and metastases . Early diagnosis of bone tumour has a potential good

outcome with limb salvageable surgery. Delayed diagnosis can have potential devastating consequences with increase in morbidity and mortality from amputation, chemotherapy and debilitating lung and brain metastases (5).

- “Non-aggressive” final decisions have been categorised as *negative* findings.
- Radio-pathological correlation was determined between the majority vote’s final decisions and the final histology using the Kappa statistic. (Appendix F)

Inter-observer agreement:

- Inter-observer agreement was determined for the readers’ final decisions using the Kappa statistic (Cohen Kappa value) (40). (Appendix E)
- The Kappa values were calculated based on the final decision of the readers, including the 3 different categories (Non-aggressive, Aggressive, Inconclusive) to determine inter-rater concordance.
- A weighted Kappa value (41) was also determined for inter-rater concordance when the inconclusive final decisions were grouped together with the Aggressive final decisions as *positive* and benign final decisions group together as *negative*.

Positive- (PPV) and negative predictive values (NPV) of individual signs:

- The 8 radiological signs (Appendix E) were assessed by readers in a systematic way to reach a final decision as to whether a lesion was benign, malignant or inconclusive.
- By correlating readers’ 1-3 interpretation and the pooled results (by using the majority vote method) of each individual sign (1-8) with the final histology, a PPV

and NPV were calculated. A PPV, NPV and false negative value (FN) for each sign in 88 cases were calculated for the pooled results.

- For each of the 88 cases, a majority vote was calculated for each of the 8 individual signs as either benign or aggressive findings.
- The majority vote was calculated in the same manner as above when calculating the final decision, with split votes determined by Reader 4
- Concordance between the majority vote on the individual signs and the final histology was determined.
- The positive predictive value (PPV) and Negative Predictive value (NPV) of the individual signs were calculated.
- The cumulative effect of grouping the 4 radiological signs with the highest PPV and NPV together were also determined to calculate the yield for aggressive tumours and to determine the accuracy in exclusion of benign tumours.

2.4 Bias

- Readers reviewed imaging independently and were blinded to each other and to the histology results.
- No discussion was allowed.

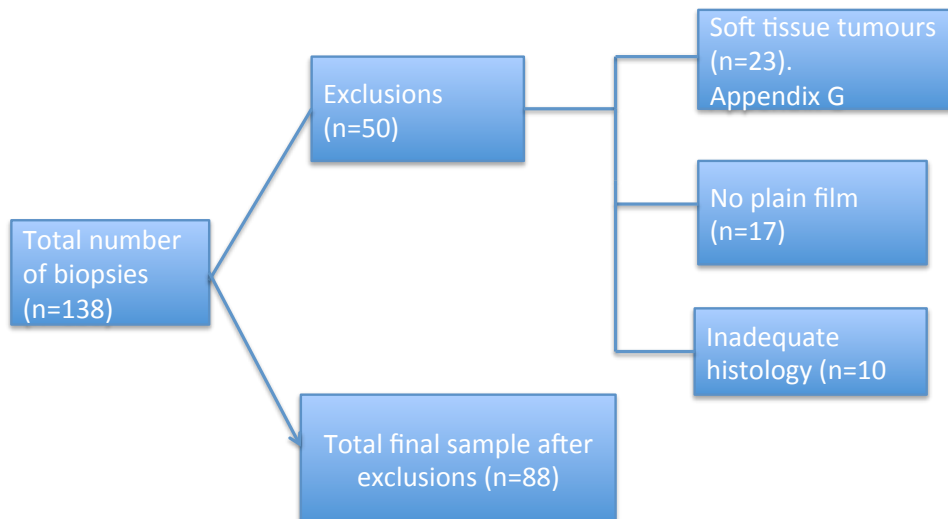
3. Results

Demographics

The original data set comprised 138 histology results, with 138 bone biopsies performed during the period of 1-Jan 2012 to 31 Dec 2014. Ten (10) patients were excluded on the basis of inadequate histological samples, 23 patients had histologically proven soft tissue (non-osseous) lesions (appendix G) and 17 patients for whom no imaging was available were excluded from the study (Table 3.1)

(Flow chart 3.1 gives a breakdown of the exclusions).

FLOW CHART 3.1: Number of biopsies with exclusions



The plain film images of 88 patients who fulfilled the inclusion criteria were reviewed.

52% were male and 48% were female.

The mean and median ages for these patients were 36 and 33 years respectively (range 13 to 81 years). Forty-five percent (40/88) were under the age of 30 years (Figure 1).

Figure 1: Age distribution of the patient who had bone biopsies

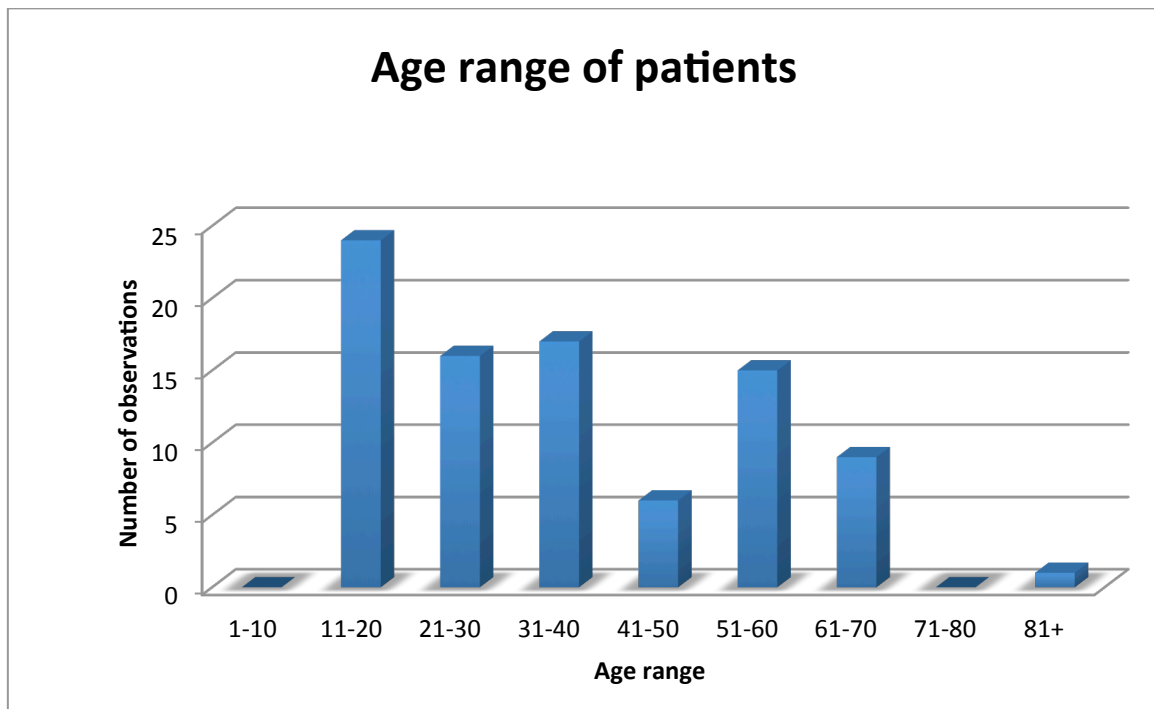


Table 3.1 Histology of bone tumours in those patients for whom plain film was not available for review

(n=17)

Benign lesions (total 8)	Number
“No evidence of malignancy”	4
Intra-osseus lipoma	1
Infected osteochondroma	1
Haemangioma	1
Giant cell tumour	1 (benign)
Aggressive/malignant (Total 9)	
Metastasis	3
Giant cell tumour	2 (aggressive)
Ewing sarcoma	1
Osteosarcoma	1
Osteomyelitis	1
Hydatid proximal femur	1

Please note that the relevance of table lies in the first aim of the study “To determine the spectrum of bone tumours and their relative frequency in patients” over a 3 year period.

These patient had no plain films for review, but still had bone biopsies and histology results and were included to calculate the total number of bone lesions and break down over the 3 year period.

Of the final data set of 88 bone lesions where plain film was available for radiological review, 43(49%) were found to be malignant or infective on biopsy. Of these, 31 were primary malignant bone tumours, 7 were infective and 5 metastatic. 45(51%) lesions were histologically benign.

These findings are summarized in Table 3.2 and Table 3.3

Table 3.2 Summary of histologically malignant /aggressive infective lesions (n=43).

Malignant/Aggressive (Total n=43)	43
Osteosarcoma	11
Giant cell tumour	5
Metastasis	5
TB	5
Myeloma	4
B-cell lymphoma	2
Fibrosarcoma	2
Langerhans cell Histiocytosis	2
Chondrosarcoma	1
Biphasic synovial Ca	1
Ewing	1
Chronic osteitis	1
Acute osteomyelitis	1
Sacral chordoma	1
Undifferentiated pleomorphic sarcoma	1

Table 3.3 Summary of histologically benign lesions (n=45)

Benign (Total n=45)	45
No malignancy	9
Giant cell tumour (with no aggressive features)	7
Osteochondroma	6
Simple bone cysts	4
Synovial chondromatosis	3
Chondroblastoma	3
Fibroma	2
Pigmented villonodular synovitis	2
Haemangioma	2
Benign Cartilage neoplasm	1
Xanthomatosis	1
Well differentiated chondroid lesion	1
Gout	1
Lipoma	1
Fibrous dysplasia	1
Subungual exostosis	1

b. Radiological interpretation

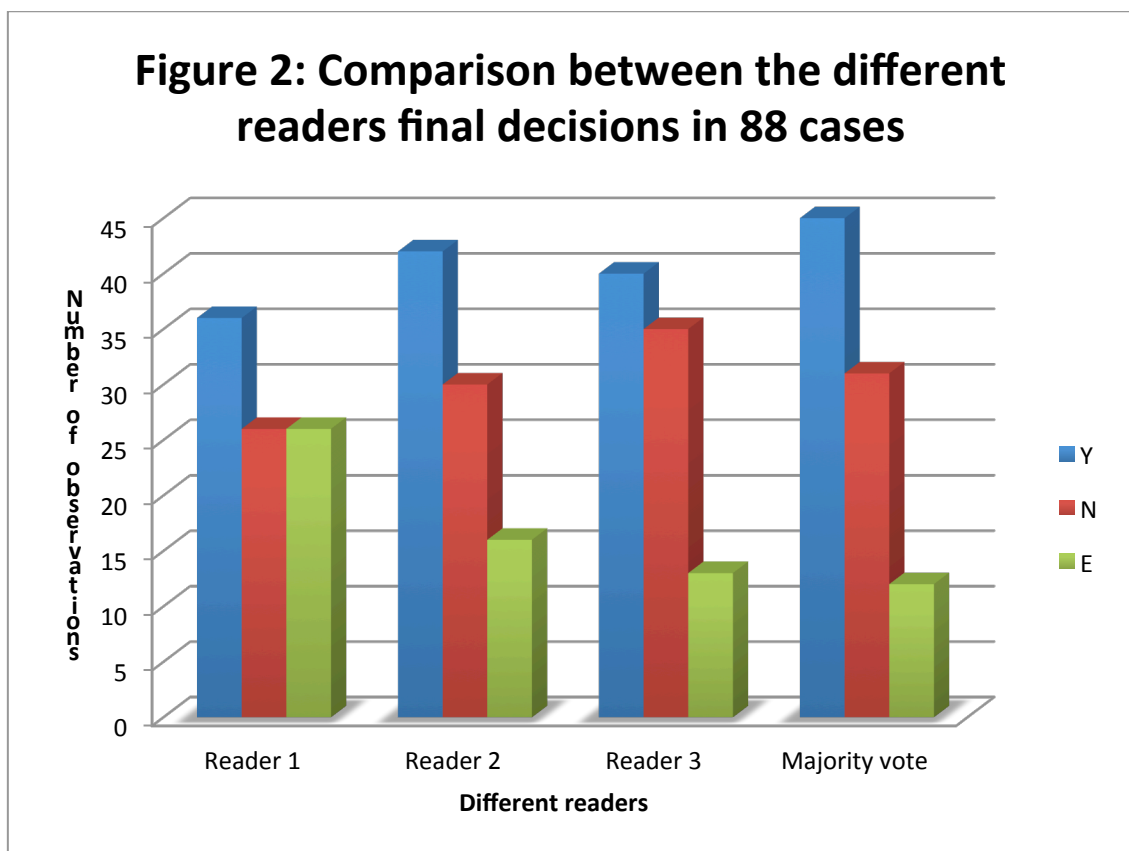
i. Radio-pathological correlation

Out of the 88 cases, 70 had radio-pathological correlation with an overall sensitivity of 80% and a kappa value of 0,61 demonstrating substantial agreement between plain film interpretation and the final histology

ii. Individual results by readers

A summary of the different readers' interpretations of the 88 cases are contained in Figure 2.

Figure 2: Comparison between different readers' interpretations of plain films



*Y= aggressive; N=Benign and E= Equivocal

Reader 1 categorised 36 lesions (41% of the total sample) as aggressive /malignant, 26 (30%) of plain films as benign, and thought the findings were inconclusive in 26(30%). Combining the aggressive and inconclusive findings resulted in a sensitivity of 98% and specificity of 56%. Table 3.4 demonstrates how the sensitivity and specificity for reader 1 were calculated.

Table 3.4 2x2 table of sensitivity and specificity for reader 1

	Malignant Histology (n=43)	Benign Histology (n=45)	Total interpretations (n=88)
Positive/Inconclusive plain film interpretation	42	20	62
Benign plain film interpretation	1	25	26
	43	45	88

Reader 2 categorised 42 lesions as aggressive /malignant (48% of the total sample), (30/34%) of plain films as benign, and thought the findings were inconclusive in 16(18%) Combining the aggressive and inconclusive findings resulted in a sensitivity of 93% and specificity of 60% for reader 2. (Table 3.5)

Table 3.5 2x2 table of sensitivity and specificity for reader 2

	Malignant histology (n=43)	Benign Histology (n=45)	Total interpretations (n=88)
Positive/inconclusive plain film interpretation	40	18	58
Negative plain film interpretation	3	27	30

Reader 3 categorised 40 lesions as aggressive /malignant (45% of the total sample), (35/40%) of plain films as benign and thought the findings were inconclusive in 13(15%). Combining the aggressive and inconclusive findings resulted in a sensitivity of 95% and specificity of 73%. (Table 3.6)

Table 3.6 2x2 table of sensitivity and specificity for reader 3

	Malignant histology (n=43)	Benign Histology (n=45)	Total interpretations (n=88)
Positive/Inconclusive plain film interpretation	41	12	53
Negative plain film interpretation	2	33	35

ii. Combined results (the majority vote)

When the plain film interpretations were combined via the majority vote method, 45 (51%) of lesions were assessed as aggressive /malignant , 31(35%) as benign and 12(14%)

were assessed as inconclusive. This resulted in an overall sensitivity of 95% and specificity of 64%. (Table 3.6)

Table 3.7 Overall sensitivity and specificity of combined radiological opinion

	Malignant histology (n=43)	Benign histology (n=45)	Total interpretations (n=88)
Positive/inconclusive plain film interpretation	41	16	57
Negative plain film interpretation	2	29	31

In each of the 6 cases of “tied” votes between readers 1-3, reader 4 either characterised the lesion as Equivocal or malignant/aggressive, explaining the higher frequency of malignant/aggressive interpretations by the “majority vote” compared to the individual readers.

iii. Inter-observer variability.

Taking the 3 variables (Aggressive, Inconclusive and Non-aggressive) in the final decision (Appendix E) into consideration; an overall moderate agreement between the readers was calculated by using the kappa value. Using a weighted kappa value when combining the inconclusive final decisions and Aggressive/Malignant decisions as *positive* interpretations and benign interpretations as *negative* interpretations, leads to a higher Interobserver agreement as there are only 2 variables, with values bordering between moderate to substantial agreement (Table 3.6).

Due to the probability that the agreement between 2 observers may be due to chance, the 95th centile confidence intervals are also given. The 95th centile is therefore a statistical value indicating 95% certainty that the true kappa value lies between the upper- and lower limit.

Table 3.8: Inter observer reliability

Rater 1	Rater 2	Kappa	LL 95%	UL95%	Weighted kappa	LL 95%	UL 95%
Overall		0,43	0,33	0,53	0,57	0,36	0,74
Reader 1	Reader2	0,43	0,30	0,54	0,63	0,42	0,80
Reader 1	Reader 3	0,39	0,26	0,52	0,48	0,28	0,65
Reader 2	Reader 3	0,46	0,32	0,60	0,59	0,39	0,77
Variables included Reader 1 Reader 2 Reader 3							

LL= Lower limit

UL= Upper limit

iv. Predictive values of the 8 radiological signs.

A summary of the complete set of PPV and NPV are summarised in table 3.10. The 4 signs with the highest PPV and NPV are the same for all 3 readers and the majority vote. In

order of decreasing PPV value: malignant periosteal reaction (90%) has the highest PPV, cortical destruction (81%) and wide zone of transition (81%) have the second highest PPV, with ill-defined margin (77%) the fourth highest. The signs with the highest NPV values also in order of decreasing value are: Ill-defined margin (80%), wide zone of transition (75%), cortical destruction (73%) and malignant periosteal reaction (64%). (These will be referred to as “major signs” in the rest of the discussion).

Table 3.10 Positive and negative predictive values for radiological signs according to readers 1-3 and majority vote.

	Reader1 PPV/NPV	Reader 2 PPV/NPV	Reader 3 PPV/NPV	Majority vote PPV/NPV
Sign 1: Lytic lesion	55/59	56/73	49/51	54/59
Sign 2: ill-defined margin	79/80	73/67	81/82	77/80
Sign 3: wide zone of transition	86/87	83/69	81/82	81/75
Sign 4: malignant periosteal reaction	95/66	86/63	71/96	90/64
Sign 5: Cortical destruction	83/81	78/68	84/76	81/73
Sign 6: Eccentric location	37/40	43/46	70/83	38/44
Sign 7: Multiple lesions	53/52	69/56	57/53	56/53
Sign 8: Either absent or chondroid matrix	54/48	66/38	46/43	44/45

An example is included of the 2X2 table + calculation for determining PPV and NPV of cortical for destruction as interpreted by the majority vote (Table 3.10)

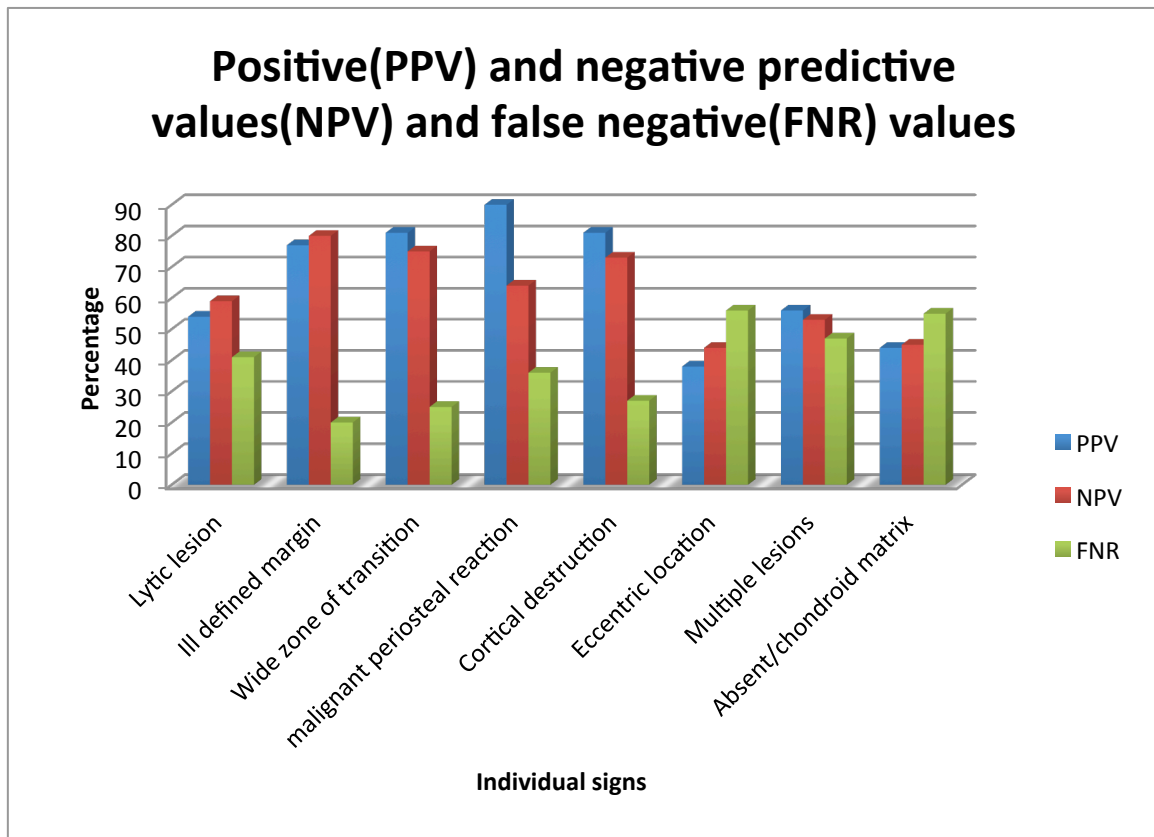
$$PPV = 29 / (29+7) \times 100 = 81\%$$

$$NPV = 38 / (38+14) \times 100 = 73\%$$

Table 3.10 2X2 table to demonstrate how PPV and NPV were calculated for cortical destruction.

	Malignant histology (n=43)	Benign histology (n=45)
Positive plain film interpretation of radiological sign (n=36)	29	7
Negative plain film interpretation of radiological sign (n=52)	14	38

Figure 3: Positive and negative predictive values of individual signs used



Calculating the pooled results, does not lead to higher values, due to inter rater variability

The presence of all 4 major signs results is associated with 100% PPV in predicting malignancy or infection. (Table 3.10)

The number of “major signs” present in the *infective* bone lesions are included in Table 3.10.

Example is given how yield was calculated when none of the 4 major signs were present.

42 lesions (47% of total sample size), had no major signs according to the readers

35/42 (83%) had benign histology, 4/42 (10%) had malignant histology and 3/42 (7%) had bone infections.

Table 3.11 Cumulative yield of the 4 “major” radiological signs

The proportion of major signs present by majority vote (n=4)	Number of interpretation (Total n =88)	Malignant /infective lesion (n=43)	Benign histology (n=45)	Malignant /infective lesion(%)	Infective bone lesions (n=7)
0	42	7	35	16	3
1	8	4	4	50	0
2	9	4	5	44	1
3	12	11	1	92	2
4	17	17	0	100	1

4. Discussion

4.1. Histological spectrum of all biopsied lesions

Total histology over 3 years:

Of the 105 bone lesions biopsied over a 3 year period at our institution, there were equivalent numbers of benign and malignant /infective (8) lesions. Five (5) of these were attributable to tuberculosis and 3 to chronic bacterial osteomyelitis.

Osteosarcoma was the most common malignant lesion (11%). Non-aggressive Giant cell tumour and osteochondroma were the 2 most common benign bone tumours (8% and 6% respectively).

These findings are consistent with other studies performed on the African continent. In a large Nigerian study, Obalum (34) found 54% of reviewed biopsies were benign and 46% malignant. The most common benign lesion in their series was osteochondroma (15%), with the most common malignant lesion being osteosarcoma (27%). The mean age of patients in their study was 25 years and the peak incidence of biopsied bone lesions was found in the second decade. (34)

A second Nigerian study found 30% of biopsies to be benign, 49% histologically malignant, (including 28% metastatic deposits and 17% osteosarcomas).

9% of this series had inconclusive histology (33).

The higher incidence of infective lesions and relatively higher rate of osteogenic sarcoma compared with our study may be explained by the fact that the mean age of their sample

was 32 years and included a higher proportion of children. Our study did not include patients younger than 13 years as they are treated at an affiliated dedicated paediatric institution. The higher prevalence of metastases may be due to the inclusion of rib, vertebra and large number of pelvic lesions when compared to the current study.

In a recent series in India, Rhutso (32) also found that the most common malignant tumour was osteosarcoma (7%) with osteochondroma (22%) being the commonest benign bone lesion. Their study revealed a surprisingly high prevalence of chronic osteomyelitis comprising 37% of their aggressive appearing lesions resulting in a disproportionately high rate of malignant and infective lesions (58%).

Our study had a significantly lower prevalence of osteomyelitis (8%) This may due to the fact that osteomyelitis is more common in children than in the adult population (41) and that patients under the age of 13 were excluded from our study. Another explanation may be that at our institution the diagnosis of chronic osteomyelitis is based largely on clinical, biochemical, microbiology (pus swab from draining sinuses) and imaging including plain film, CT, MRI and nuclear medicine studies, rather than biopsy.

Similar results have been reported in the developed world. In a study of more than 100 biopsy specimens, Jelenek 2002 (29) had a significant higher percentage yield for malignant histology (70% vs. 49%). The most common malignant and benign tumours were similar to our study., with osteosarcoma being more common (18% vs. our 11%) and non-aggressive giant cell tumour (15% vs. our 8%). The mean age of their study population was 38 slightly higher that ours (38 vs. 36). These differences may be

explained by the fact that Jelenek exclusively analysed the histology of primary bone tumours and excluded metastases, infections, inflammatory and metabolic diseases.

Tuberculosis and osteitis:

In our series we described 5 (5%) cases of histologically confirmed osseous tuberculosis (TB). Extra pulmonary TB is seen in 1-3% of patients with Tuberculosis in the developed world and approximately 10% in countries such as South Africa where TB is endemic. Moreover the risk of TB is 20-37 higher in patients with human Immunodeficiency virus (HIV). The relatively low rate of skeletal TB in our series may be due the fact that skeletal TB is rare, when compared to pulmonary TB and TB lymphadenitis (42)(43). Most osseous TB (50%) affects the spine while 15% of cases present as septic arthritis of the hip (44). Spinal biopsies and joint aspirates were not included in our series. Finally Tuberculosis of the spine and large joints are more common in children and young adults (43) and patients under 13 years were excluded in our series.

It is important to note that 2 of the 7 (29%) histologically proven infective lesions (one chronic bacterial osteitis and the other tuberculous osteitis) were interpreted as non-aggressive on plain film. In the absence of clinical suspicion of infection, there is a likelihood that these lesions would not have been regarded as sufficiently concerning to warrant biopsy and diagnosis would have been delayed.

4.2 Inter-observer reliability/Reliability of radiographic interpretation

High rate of inconclusive interpretations by the readers

Reader 1 interpreted 30% reader 2: 18% and reader 3: 15% of all the plain films as “inconclusive” in other words not convincing for aggressive or non-aggressive plain film findings, with the majority vote classifying 12% as inconclusive.

The following reasons for this high rate is proposed:

- The readers did not want to commit without the assistance of cross sectional imaging.
 - The readers may have thought that the lesions had benign features, but did not want to commit in the absence of clinical history, in the patient above 40 years of age.
 - The readers were just ask to analyse the plain films and were blinded to the fact that the lesions were biopsied. They may have interpreted the plain film finding as benign, but were still suspicious as to the inclusion of the plain films in the series and chose the “safe” option “Inconclusive-probably needs biopsy” See Appendix E
 - The imaging findings of the plain film were confusion with aggressive and non-aggressive findings, with readers again afraid to commit without cross sectional imaging.
 - The readers are unfamiliar with features of aggressive findings as set out in section 1.3.
- This may also be explained the moderate inter -reader agreement (see below).

Interobserver agreement:

To our knowledge, no other published study has attempted to document inter-observer correlation in predicting malignancy based on radiographic plain film review. Kappa values of between 0.39 and 0.46 indicate only moderate inter-reader agreement, even in the setting of predetermined criteria. When the malignant/aggressive- and inconclusive

interpretations were combined as *positive* findings versus the benign plain film findings as *negative findings*, the inter-observer agreement improved to 0,48 -0,63 indicating moderate to substantial agreement between the 3 readers (Appendix F).

In retrospect the role of the fourth reader was unnecessary as this reader's interpretation did not make a statistical difference due to the following reasons:

-The fourth reader was introduced to avoid a split decision between reader 1-3, but inconclusive findings were grouped together with malignant/aggressive findings in calculating statistics, resulting in 2 variables between 3 readers. Therefore split decisions with 3 variables between 3 readers were not possible.

-In calculating the PPV and NPV the readers only had 2 choices: the presence or absence of a radiological sign., resulting again only in 2 variables between 3 readers.

Radio-pathological correlation

The kappa value of 0,61 indicates substantial agreement, with overall sensitivity of 80% between the plain film interpretation and final histology. This finding is low when compared with similar studies performed by Vijayaraghavan and Negash.

Vijayaraghavan (2)(37) also correlated the correlation between exact histological diagnosis with the radiological interpretation based on Lodwick's (18) method of classification and calculated an 80% case correlation

The high correlation between imaging and final diagnosis in their study may be attributable to a larger sample size and the fact that they reviewed the clinical data, plain film, CT and MRI and had discussions on the cases

Negash (38) reported a case correlation of 84% with an agreement (kappa) of 0,82 which is thought to be due to the inclusion of MRI findings and consensus decision making at combined clinical and radiological incorporation meetings.

Sensitivity and Specificity of readers

Using set criteria, sensitivity was high (ranging between 93% and 98%) in correctly diagnosing malignant /infective lesion on plain film. When using the “majority vote” the sensitivity was 95%, with the only 2 infective lesions that would have been missed /misinterpreted (both representing chronic osteomyelitis).

There was no statistically significant difference between the sensitivity of the individual readers and the pooled sensitivity using the majority vote method. This suggests an understandable reluctance to categorically call a lesion benign given the serious implications of missing a malignancy or infection.

Specificity (correctly diagnosing a benign bone tumour on plain film) of the readers in the current study ranged from 53% to 73%. This averaged out to 64% when using the “majority vote”. The true specificity cannot be calculated since the majority of bone lesions with benign features are not biopsied. This is either because patients are asymptomatic or because malignancy has been excluded in referral centers. Not infrequently a benign lesion has aggressive plain film features and only rarely does a lesion have typically benign “leave-alone” plain film features.

Another explanation for the low specificity was the frequent (in up to one third of cases) selection of the “Inconclusive” option. These cases were grouped together with those

described as “aggressive’ leading to a higher number in “positive” findings when statistics were calculated.

Predictive value of radiological signs for malignancy and infection.

Assessing a single radiological sign has some value in calculating the PPV and NPV, with high PPV for malignant tumours and infection in the presence of an ill defined margin, a wide zone of transition, malignant periosteal reaction and cortical destruction. However 20% of lesions were interpreted as having a wide zone of transition or cortical destruction and turned out to yield benign histology

The overall low positive and negative predictive values in the other 4 radiological signs (“lytic lesion”, “eccentric location”, “multiple lesions” and “absent or chondroid matrix”) can be explained by the following factors:

- Not all of the 8 plain film signs of aggressive lesions will be present in an aggressive bone lesion, for example: multiple lesions seen predominantly in metastatic deposits..
- Malignant lesions may be sclerotic or lytic
- Malignant lesions may have lucent, chondroid or osteoid matrix.
- Lesions like giant cell tumours, non-ossifying fibroma and chondroblastoma may have eccentric location.
- Benign lesions may mimic aggressive lesions, by having aggressive features.
- The matrix of the lesion does not determine the aggressiveness of the lesion but rather guides the reader to a differential diagnosis eg. cartilage bone forming tumour (chondroid matrix); osteoid matrix in osteosarcoma, osteomyelitis,

osteoid osteoma and ground glass matrix in fibrous lesions like fibrous dysplasia (9,11).

- In retrospect in determining if a bone tumour is aggressive or benign, the radiological sign on the matrix composition should have been replaced by “presence or absence of a soft tissue component”

In our study the PPV (for malignancy or infection) increased proportionately with an increase in the number of positive radiological signs. If 3 signs were present the PPV was 97%. Where there were 4 major signs, the PPV was 100%. Unfortunately the absence of any of the major signs did not exclude malignancy or infection, but had a combined yield of 10% for malignant bone tumour and infection.

Accurate radio- pathological correlation is seen in other body systems e.g. using the Breast Imaging and Reporting Data System (BIRADS) classification(45) there is 97% concordance when comparing malignant features on mammography and confirmation on percutaneous breast biopsy findings such as calcifications, margin of the mass, architectural distortion, skin thickening, nipple retraction, lymph nodes and ultrasound features such as a mass that is “taller than wide” to determine the BIRADS classification (45) .

4.3. Implications of the study findings / Current applications

Even in experienced hands, the interpretation of plain films for the diagnosis of primary malignant bone tumours can be confusing and very difficult. In this study where data was

obtained from a tertiary hospital with a specialised oncology clinic and experienced orthopaedic surgeons and musculoskeletal radiologists, half of the biopsied lesions were benign. It also stresses the fact that lesions with benign histology can have aggressive plain film imaging findings

Incorrect plain film interpretation may lead to failure of appropriate referral and investigation and may have serious consequences for the patient and for society. Delay in treatment as a result of under-diagnosis must be balanced against the financial implications of time off work, loss of income and surgically related morbidity and mortality that may result from unnecessary surgical treatment.

This study serves to highlight:

- Substantial agreement between plain film findings and final histology
- High false negative- and low positive predictive values of single radiology signs for malignant and infective bone lesions.
- Moderate Interobserver reliability of the readers.
- The high percentage of “equivocal” interpretations of the individual readers ranging from 15-30%.
- The well recognised fact that benign lesions can have aggressive radiological features (15).

4.3. Limitations of the current study

- a) Small sample number. Although the National Health Laboratory stores the previous 5 years of histological results, the Hospital PACS system was introduced only in 2012, allowing review of only 3 years of plain films.
- b) Malignant bone lesions are relatively uncommon.
- c) Plain films of patients referred for biopsy from outside institutions were not universally available for review.
- d) The study group is heavily skewed to include patients whose plain films had bone lesions with aggressive imaging features, since patients with benign appearing lesions on initial plain film assessment would not have been referred for further assessment and biopsy.
- e) This may have resulted in an underestimation of the true prevalence and incidence in the referral region.
- f) Children below the age of 13 years are managed at a dedicated paediatric centre and were not recruited into this study. This may have falsely lowered the prevalence of malignant bone tumours and infective bone lesions in the study population, but would not have been a confounder for the radiological assessment part of the study.
- g) Due to the fact that MRI imaging was not included in this study, the readers may have used a more conservative approach as cross sectional imaging is usually available to aid in making the diagnosis.

4.4. Future applications

- There are few studies evaluating the concordance between imaging and histopathological diagnosis in bone lesions. The current study only evaluated plain radiograph interpretation and further research of this kind should include the evaluation of the contribution of MRI to improving the sensitivity and specificity of imaging in identifying malignant bone lesions.
- Vijay, Negash, Samardzinski (2)(38)(39) all had “substantial-“ to “nearly perfect” radio-pathological correlation (based on Appendix F) on the final diagnosis of bone tumours. A significant difference between the current study and previous studies mentioned, are the fact that they discussed the imaging (plain film, CT and MRI) findings in combined radiology and orthopaedics meetings. A combined weekly meeting at our institution will aid in higher sensitivity and specificity in bone tumour characterization, improve registrar training and ultimately leading to better management of patient’s with bone tumours.
- This study could also be repeated with inclusion of classical “leave- alone-bone-lesions” like fibrous dysplasia, osteoid osteoma, non-ossifying fibroma etc. (lesions that do not need biopsy) as controls, for assessment of readers’ knowledge in identifying benign bone lesions.
- A larger review study is recommended to assess plain film features that include lytic or sclerotic lesions, wide zone of transition, cortical destruction, ill-defined margin, malignant periosteal reaction and soft tissue component, with scoring system that include the presence of multiple radiological signs to derive a similar system to the BIRADS system.

- This will lead to further categorization of bone tumours and ultimately improved confidence of clinicians and radiologists in their assessment and recommendations on follow-up and need for further imaging investigations or biopsy.

5. Conclusion

Primary malignant bone tumours are rare tumours. In this study of 31 primary malignant bone tumours, described over a 3-year period, the distribution of histology was similar to that reported in the literature both in the developed and developing world.

The most common primary malignant tumour being osteosarcoma and the most common biopsied benign lesions include giant cell tumour and osteochondroma.

Substantial agreement between radiology and pathology was again confirmed.

Moderate agreement was found between the 3 readers in the interpretation of plain films, demonstrating some inter-observer variability in interpreting aggressive plain film findings of bone lesions.

This study demonstrates high sensitivity in diagnosing primary malignant bone tumours using an established systematic review schema in the interpretation of plain film. This confirms the usefulness of plain film as a screening tool.

Although the true specificity of this diagnostic approach cannot be calculated due to the fact that most benign lesions do reach biopsy, the low specificity may be attributed to the fact that benign bone lesions often have plain film findings that mimic aggressive lesions.

The absence of any of the 4 “major radiological signs” has a low yield (10%) for malignancy.

Even in the hands of experienced readers, the diagnosis of primary malignant tumours can be a difficult diagnosis as shown in this study with equal number benign and infective/malignant bone lesions detected on plain film. This finding of low specificity is consistent with other studies performed in developing countries.

In summary our study shows that systematic plain film analysis is a necessary screening tool in detecting malignant bone tumours, but that the fear of missing malignancy results in a large number of unnecessary biopsies.

A combined clinico-radiological and histopathological approach with regular follow-up and MRI in selected cases may allow more accurate diagnosis and better management of patients.

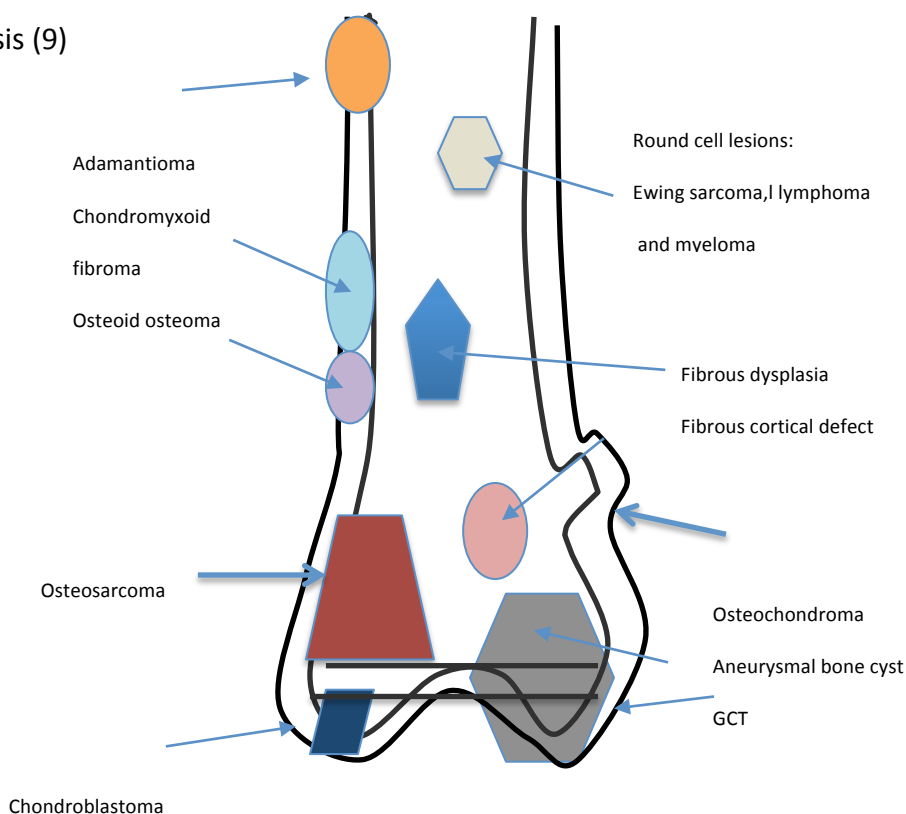
Appendix A: Plain film imaging features of bone lesions

When attempting to make a diagnosis on plain film radiography alone, several parameters should be considered including:

A. Table indicating common lesion during certain age periods (9)

AGE	Tumour
0-10 years	Eosinophilic granuloma,
11-20 years	Ewing's sarcoma, primary osteogenic sarcoma
30-50 years	lymphoma
>50 years	Multiple myeloma, secondary osteogenic sarcoma, metastases

B. Diagram indicating the position of various common bone lesions and their relation to the physis (9)



Appendix C Technical guideline for open biopsy(28)

1. use a tourniquet
2. the biopsy tract should be close to an extensile incision and in line with the extensile incision, should a limb salvage procedure through a wide resection become necessary.
3. use the involved compartment for the biopsy tract
4. avoid developing planes
5. avoid neurovascular bundles

6. aim for a representative specimen
7. confirm representative specimen on frozen section
8. obtain a significant amount of tissue
9. release tournique before closure and aim for meticulous haemostasis
10. when using a drain the exit should be close to and in line with the incision

Appendix D: Ethics Clearance Certificate and extension of ethics clearance



UNIVERSITY OF CAPE TOWN
Faculty of Health Sciences
Human Research Ethics Committee



Room E52-24 Old Main Building
Groote Schuur Hospital
Observatory 7925
Telephone [021] 406 6338 • Facsimile [021] 406 6411
Email: shuretta.thomas@uct.ac.za
Website: www.health.uct.ac.za/fhs/research/humanethics/forms

24 December 2014

HREC REF: 892/2014

Prof S Andronikou
Division of Radiology
C-16
NGSH

Dear Prof Andronikou

PROJECT TITLE: CONCORDANCE OF IMAGING STUDIES AGAINST HISTOLOGY FOR CATEGORIZATION OF BONE LESIONS (Student -E Gerber)

Thank you for submitting your study to the Faculty of Health Sciences Human Research Ethics Committee for review.

It is a pleasure to inform you that the HREC has **formally approved** the above-mentioned study.

Approval is granted for one year until the 30th December 2015.

Please submit a progress form, using the standardised Annual Report Form if the study continues beyond the approval period. Please submit a Standard Closure form if the study is completed within the approval period.

(Forms can be found on our website: www.health.uct.ac.za/fhs/research/humanethics/forms)

Please quote the HREC REF in all your correspondence.

We acknowledge that the student, Erhardt Gerber will also be involved in this study.

Please note that the ongoing ethical conduct of the study remains the responsibility of the principal investigator.

Yours sincerely

PP TuBurgess

PROFESSOR M BLOCKMAN
CHAIRPERSON, FHS HUMAN RESEARCH ETHICS COMMITTEE

Federal Wide Assurance Number: FWA00001637.

Institutional Review Board (IRB) number: IRB00001938

This serves to confirm that the University of Cape Town Human Research Ethics Committee complies to the Ethics Standards for Clinical Research with a new drug in patients, based on the Medical Research Council (MRC-SA), Food and Drug Administration (FDA-USA), International Convention on Harmonisation Good Clinical Practice (ICH GCP) and Declaration of Helsinki guidelines.

HREC 892/2014

HUMAN RESEARCH ETHICS COMMITTEE

29 JUL 2016



UNIVERSITY OF CAPE TOWN

FACULTY OF HEALTH SCIENCES

HEALTH SCIENCES FACULTY
UNIVERSITY OF CAPE TOWN

Human Research Ethics Committee



FHS016: Annual Progress Report / Renewal

HREC office use only (FWA00001637; IRB00001938)			
This serves as notification of annual approval, including any documentation described below.			
<input checked="" type="checkbox"/> Approved	Annual progress report	Approved until/next renewal date	30/07/17
<input type="checkbox"/> Not approved	See attached comments		
Signature Chairperson of the HREC		Date Signed	30/7/16

Comments to PI from the HREC

Principal Investigator to complete the following:

1. Protocol information

Date (when submitting this form)	28 July 2016		
HREC REF Number	892/2014	Current Ethics Approval was granted until	30 Dec 2015
Protocol title	Accuracy of Plain radiographs for diagnosing histologically proven malignant bone lesions.		
Protocol number (if applicable)			
Are there any sub-studies linked to this study?	<input type="checkbox"/> Yes <input checked="" type="checkbox"/> No		
If yes, could you please provide the HREC Ref's for all sub-studies? Note: A separate FHS016 must be submitted for each sub-study.			
Principal Investigator	Erhard Gerber		
Department / Office Internal Mail Address	Div of Diagnostic Radiology erhardtgerber@yahoo.com		
1.1 Does this protocol receive US Federal funding?	<input type="checkbox"/> Yes	<input checked="" type="checkbox"/> No	
1.2 If the study receives US Federal Funding, does the annual report require full committee approval?	<input type="checkbox"/> Yes	<input checked="" type="checkbox"/> No	
1.3 Has sponsorship of this study changed? If yes, please attach a revised summary of the budget.	<input type="checkbox"/> Yes	<input checked="" type="checkbox"/> No	

082 855 4817

1.1 For radiologist

CASE 1

FOR THE FOLLOWING X-RAY; PLEASE INDICATE THE MOST APPROPRIATE IMAGING FEATURE CONCERNING THE BONE LESION AND MARK FINAL DECISION BELOW

	YES	NO
1. LYTIC LESION		
2. ILL-DEFINED MARGIN		
3. WIDE ZONE OF TRANSITION		

4. MALIGNANT PERIOSTEAL REACTION		
5. CORTICAL DESTRUCTION		
6. ECCENTRIC LOCATION		
7. MULTIPLE LESIONS		
8. ABSENT-OR CHONDROID MATRIX		

FINAL DECISION:

1. MALIGNANT/AGGRESSIVE
(REQUIRES BIOPSY)

2. BENIGN/ 'LEAVE ALONE'
NOT REQUIRING BIOPSY

3. INCONCLUSIVE
(PROBABLY NEEDS BIOPSY)

Appendix F Interpretation of Kappa values (40)

Kappa	Interpretation
<0	Poor agreement
0-0,2	Slight agreement
0,21-0,4	Fair agreement
0,41-0,6	Moderate agreement
0,61-0,8	Substantial agreement
0,81-1	Almost perfect

Appendix G: Histology of soft tissue tumours in the 23 patients

Benign (Total 6)	Number
Gouty tophi	1
Intramuscular cavernous haemangioma	1
Haemangioma/angioliopoma	1
Subacute synovitis	1
Intramuscular myxoma	1
Plantar fibromatosis	1
Sarcoma (Total number 17)	
Pleomorphic-	2
Malignant fibro histiocytic-	2
Biphasic synovial-	2
Spindle cell-	1
Acral myxo-inflammatory fibroblastic-	1
Low grade-	1
Pleomorphic lipomatous-	1

Leiomyosarcoma-	1
Residual clear cell-	1
Grade 2-3 sarcoma	1
Recurrent atypical lipomatous tumour	1
Myxoid liposarcoma	1
Atypical lipoma	1
Rhabdomyosarcoma	1

5. References

1. Dodge O. Bone Tumours in Uganda Africans. *Bone Tumours Uganda Africans* [Internet]. 1964;18(4):627–33. Available from:
<http://www.ncbi.nlm.nih.gov/pmc/articles/PMC2071170/>
2. Lima PMDA, Oliveira MP, da Silva HJ, de Mello RJV. The role of cytology in the diagnosis of musculoskeletal neoplasms: systematic review. *Acta Ortop Bras* [Internet]. 2012 Jan;20(1):48–52. Available from:
<http://www.pubmedcentral.nih.gov/articlerender.fcgi?artid=3718411&tool=pmcentrez&rendertype=abstract>
3. Siegel RL, Miller KD JA. Cancer Statistics. *CA Cancer J Clin*. 2015;65(1):5–29.
4. O’ Donnell P. Evaluation of focal bone lesions: basic principles and clinical scenarios. *Imaging* [Internet]. 2003;15(4):293–323. Available from:
<http://www.birpublications.org/doi/abs/10.1259/img.15.4.150298?journalCode=img>
5. Ferguson WS GA. Current treatment of osteosarcoma. *Cancer Invest*. 2001;19(3):292–315.
6. Letson D, Falcone R, Muro-Cacho CA. Pathology Update PATHOLOGIC AND RADIOLOGIC FEATURES OF PRIMARY BONE TUMORS.
7. Costelloe CM, Madewell JE. Radiography in the initial diagnosis of primary bone tumors. *AJR Am J Roentgenol* [Internet]. 2013 Jan [cited 2014 Sep 30];200(1):3–7. Available from: <http://www.ncbi.nlm.nih.gov/pubmed/23255735>
8. Miller TT. Bone tumors and tumorlike conditions: Analysis with conventional radiography. *Radiology*. 2008;246(3):662–74.
9. Sanders TG, Parsons TW. Radiographic imaging of musculoskeletal neoplasia.

- Cancer Control [Internet]. 2001;8(3):221–31. Available from:
<http://www.ncbi.nlm.nih.gov/pubmed/11378648>
10. van der Woude H, Smithuis R. Bone tumor-Systemic approach and differential diagnosis [Internet]. Radiology Assistant. 2010. Available from:
<http://www.radiologyassistant.nl/en/p494e15cbf0d8d/bone-tumor-systematic-approach-and-differential-diagnosis.html>
 11. AD Massengill, LL Seegers JE. The role of plain radiograph, computerized tomography and magnetic resonance in sarcoma evaluation. Hematol Oncol Clin North Am [Internet]. 1995;9(3):571–604. Available from:
<http://www.ncbi.nlm.nih.gov/pubmed/7649943>
 12. Yildiz C, Erler K, Atesalp AS BM. Benign bone tumours in children. Curr Opin Pediatr. 2003;15:58.
 13. Wyers MR. Evaluation of pediatric bone lesions. Pediatr Radiol. 2010;40:468.
 14. T Berquist, M Dalinka NA et al. Bone tumors: American College of Radiology-ACR appropriateness criteria. Radiology [Internet]. 2000 [cited 2014 Sep 30];215:261–4. Available from: <http://pubs.rsna.org/doi/pdf/10.1148/6.2.122>
 15. Gould CF, Ly JQ, Lattin GE Jr, Beall DP SJ. Bone tumor mimics: avoiding misdiagnosis. Curr Probl Diagn Radiol [Internet]. 2007;36(3):124–41. Available from: <http://www.ncbi.nlm.nih.gov/pubmed/17484955>
 16. Lodwick GS, Wilson AJ, Farrell C, Virtama P DF. Determining growth rates of focal lesions of bone from radiographs. Radiology [Internet]. 1980;134(3):577–83. Available from: <http://www.ncbi.nlm.nih.gov/pubmed/6928321>
 17. Enneking WF, Spanier SS GM. A system for the surgical staging of musculoskeletal sarcoma. Clin Orthop Relat Res [Internet]. 1980;153(6):106–20. Available from:

- <http://www.ncbi.nlm.nih.gov/pubmed/7449206>
18. Baweja S, Arora R, Singh S, Sharma A, Narang P, Ghuman , Kapoor KS PS. Evaluation of bone tumors with magnetic resonance imaging and correlation with surgical and gross pathological findings. *Indian J Radiol Imaging*. 2006;16(4):611–8.
 19. M Sundaram RM. MR imaging of tumor and tumorlike lesions of bone and soft tissue. *Am J Roentgenol* [Internet]. 1990;155(4):817–24. Available from: <http://www.ncbi.nlm.nih.gov/pubmed/2119115>
 20. Dalén BPM, Meis-Kindblom JM, Sumathi VP, Ryd W, Kindblom L-G. Fine-needle aspiration cytology and core needle biopsy in the preoperative diagnosis of desmoid tumors. *Acta Orthop* [Internet]. 2006 Dec [cited 2014 Sep 30];77(6):926–31. Available from: <http://www.ncbi.nlm.nih.gov/pubmed/17260203>
 21. Fleshman R, Mayerson J, Jr PEW. Fine-Needle Aspiration Biopsy of High-Grade Sarcoma- a report of 107 cases. *Cancer* [Internet]. 2007;111(6):491–8. Available from: <http://www.ncbi.nlm.nih.gov/pubmed/17941014>
 22. Ng VY, Thomas K, Crist M, Wakely PE, Mayerson J. Fine needle aspiration for clinical triage of extremity soft tissue masses. *Clin Orthop Relat Res* [Internet]. 2010 Apr [cited 2014 Sep 30];468(4):1120–8. Available from: <http://www.pubmedcentral.nih.gov/articlerender.fcgi?artid=2835602&tool=pmcentrez&rendertype=abstract>
 23. Yang YJ, Damron TA. Comparison of Needle Core Biopsy and Fine-Needle Aspiration for diagnostic accuracy in Musculoskeletal lesions. *Arch Pathol Lab Med* [Internet]. 2004;128(7):759–64. Available from: <http://www.ncbi.nlm.nih.gov/pubmed/15214827>
 24. Jorda M, Rey L, Hanly a, Ganjei-Azar P. Fine-needle aspiration cytology of bone:

- accuracy and pitfalls of cytodiagnosis. *Cancer* [Internet]. 2000 Mar 25;90(1):47–54.
Available from: <http://www.ncbi.nlm.nih.gov/pubmed/10692216>
25. Mankin HJ, Lange TA SS. The hazards of biopsy in patients with malignant primary bone and soft-tissue tumors. *J bone Jt Surg* [Internet]. 1982 Oct;64(8):1121–7.
Available from: <http://www.ncbi.nlm.nih.gov/pubmed/7130225>
 26. Mankin HJF, Mankin CJLST, Simon MA. The Hazards of the Biopsy, Revisited FOR THE MEMBERS OF THE MUSCULOSKELETAL TUMOR SOCIETY*. *J bone Jt Surg*. 1996;Vol 78-A(5):656–63.
 27. Gerrard GH RK. *Classic papers in Orthopaedics* [Internet]. 1st ed. Paul A. Banaszkiwicz, Deary F. Kader, editors. London: Springer; 2014. 491-3 p. Available from: http://link.springer.com/chapter/10.1007/978-1-4471-5451-8_129
 28. Biau DJ, Weiss KR, Bhumbra RS, Davidson D, Brown C, Wunder JS, et al. Using the CUSUM test to control the proportion of inadequate open biopsies of musculoskeletal tumors tumor. *Clin Orthop Relat Res*. 2013;471(3):905–14.
 29. Jelinek JS, Murphey MD, Welker J a, Henshaw RM, Kransdorf MJ, Shmookler BM, et al. Diagnosis of primary bone tumors with image-guided percutaneous biopsy: experience with 110 tumors. *Radiology* [Internet]. 2002 Jun;223(3):731–7.
Available from: <http://www.ncbi.nlm.nih.gov/pubmed/12034942>
 30. Akerman M, Berg N, Person M. Fine needle aspiration biopsy in the evaluation of tumor-like lesions of bone. *Acta Orthop Scand (Acta Orthop Scand)* [Internet]. 1976;47(2):129–36. Available from:
<http://informahealthcarehttp://informahealthcare.com/doi/pdf/10.3109/17453677608989707.com/doi/pdf/10.3109/17453677608989707>
 31. Bommer KK, Ramzy I, Mody D. Fine-needle aspiration biopsy in the diagnosis and

- management of bone lesions: a study of 450 cases. *Cancer* [Internet]. 1997;81(3):148–56. Available from: <http://www.ncbi.nlm.nih.gov/pubmed/9196013>
32. Laishram R, Rhutso Y, Sharma LdC, Debnath K. Histopathological evaluation of bone tumors in a tertiary care hospital in Manipur, India. *J Med Soc* [Internet]. 2013 [cited 2014 Sep 30];27(2):135. Available from: <http://www.jmedsoc.org/text.asp?2013/27/2/135/121591>
 33. Nnodu OE, Giwa SO, Eyesan SU AF. Fine needle aspiration cytology of bone tumours-the experience from the National Orthopaedic and Lagos University Teaching Hospital. *Cytojournal*. 2006;3(1):16.
 34. Obalum D, Giwa S, Banjo A, Akinsulire T. Primary bone tumours in a tertiary hospital in Nigeria: 25 year review. *Niger J Clin Pract* [Internet]. 2009 [cited 2014 Sep 30];12(2):169–72. Available from: <http://www.ajol.info/index.php/njcp/article/download/45403/28886>
 35. S Chakrabarti, AS Datta MH. Critical Evaluation of Fine Needle Aspiration Cytology as a Diagnostic Technique in Bone Tumors and Tumor-like Lesions. *Asian Pacific J Cancer Prev*. 2012;13(7):3031–5.
 36. Muscolo DL, Ayerza MA, Makino A, Costa-paz M, Aponte-tinao LA. Tumors about the knee misdiagnosed as athletic injuries. *J bone Jt Surg Am* [Internet]. 2003;85(7):1209–14. Available from: <http://jbjs.org/content/85/7/1209.long>
 37. Vijayaraghavan L, Radhakrishnan N, Author C. Lytic Lesions of Bone: A Histopathological and Radiological Correlative Study. *Acad Med J India* [Internet]. 2015;283(3):83–7. Available from: www.medicaljournal.in
 38. Negash BE, Admasie D, Wamisho BL, Tinsay MW. Bone tumors at Addis Ababa

- University, Ethiopia: Agreement between radiological and histopathological diagnoses, a 5-year analysis at Black-Lion Teaching Hospital. *Int J Med Med Sci* [Internet]. 2009;1(4):119–25. Available from: <http://www.academicjournals.org/IJMMS>
39. Milan Samardziski, George Zafiroski, Vesna Janevska DM, Žaneta Popeska. Computer assisted diagnosis of benign bone tumours. *Radiol Oncol* . 2004;38(3):165–9.
 40. Viera AJ GJ. Understanding interobserver agreement. *Fam Med*. 2005;37(5):360–3.
 41. Castellazzi L, Mantero M, Esposito S. Update on the management of pediatric acute osteomyelitis and septic arthritis. *Int J Mol Sci*. 2016;17(6):855.
 42. Tseng C-C, Huang R-M, Chen K-T. Tuberculosis Arthritis: Epidemiology, Diagnosis, Treatment. *Clin Res Foot Ankle* . 2014;2(2):131–7.
 43. Kumar Garg R, Singh Somvanshi D. Spinal tuberculosis: A review. *J Spinal Cord Med* . 2011;34(5):440–54.
 44. Horowitz DL, Katzap E, Horowitz S, Barilla-Labarca M-L. Approach to Septic Arthritis. *Am Fam Physician* [Internet]. 2011;84(6):653–60. Available from: www.aafp.org/afp
 45. Liberman L, Drotman M, Morris EA, Latrenta LR, Abramson AF, Zakowski MF, et al. Imaging – Histologic Discordance at Percutaneous Breast Biopsy An Indicator of Missed Cancer. *Cancer* [Internet]. 2000;89(12):2538–46. Available from: [http://onlinelibrary.wiley.com/doi/10.1002/1097-0142\(20001215\)89:12%3C2538::AID-CNCR4%3E3.0.CO;2-%23/abstract](http://onlinelibrary.wiley.com/doi/10.1002/1097-0142(20001215)89:12%3C2538::AID-CNCR4%3E3.0.CO;2-%23/abstract)

