

**Endoscopic Resection and Post-Operative Brachytherapy in the Treatment of  
Sinonasal Melanoma**

**Abdulrauf I Alhadad, MBChB, FCORL (SA)**

Registrar, Division of Otorhinolaryngology, Faculty of Health Sciences, University of Cape Town

**Darlene Lubbe, MBChB, FCORL (SA)**

Associate Professor, Division of Otorhinolaryngology, Faculty of Health Sciences, University of  
Cape Town

**Address for Correspondence**

Abdulrauf I Alhadad

Division of Otorhinolaryngology

University of Cape Town

H53 OMB Groote Schuur Hospital

Observatory

Cape Town

South Africa

7925

Email: [raufibraheem@gmail.com](mailto:raufibraheem@gmail.com)

Phone: +27-79-450-9566

Fax: +27-21-448-8865

The copyright of this thesis vests in the author. No quotation from it or information derived from it is to be published without full acknowledgement of the source. The thesis is to be used for private study or non-commercial research purposes only.

Published by the University of Cape Town (UCT) in terms of the non-exclusive license granted to UCT by the author.

**DECLARATION**

I, *Abdulrauf Alhadad*, hereby declare that the work on which this dissertation/thesis is based is my original work (except where acknowledgements indicate otherwise) and that neither the whole work nor any part of it has been, is being, or is to be submitted for another degree in this or any other university.

I empower the university to reproduce for the purpose of research either the whole or any portion of the contents in any manner whatsoever.

Signature:

Signed by candidate

Date: 4/October/2019

## Introduction and literature review

Primary mucosal sinonasal melanoma accounts for 0.5-2% of all melanomas, 4% of head and neck melanomas and 4-8% of all sinonasal malignancies.<sup>1-7</sup> They have an equal gender distribution and usually occur in patients in their 6<sup>th</sup>-7<sup>th</sup> decade of life.<sup>8</sup> Sinonasal melanomas are rare, aggressive tumours often associated with a poor prognosis due to advanced stage disease at presentation. Regional and distant metastases are present at presentation in a third of cases.<sup>7</sup> Mean 5-year survival is 0-46%.<sup>9</sup> The vast majority (80%) arise from the nasal vault (lateral nasal wall and nasal septum). The remainder are of sinus origin, with the maxillary sinus most commonly involved.<sup>10</sup> Those arising from the nasal vault have a better prognosis and 5-year survival.<sup>11</sup>

### Epidemiology

Interestingly, the incidence of mucosal melanoma is higher in areas where the incidence of cutaneous melanoma is lower. Both variants occur more commonly in Caucasian populations, although 7% of mucosal melanomas occur in Afro-Caribbean populations compared to just 0.8% of cutaneous melanomas.<sup>12-14</sup> The incidence of mucosal melanoma has remained relatively constant, while that of cutaneous melanoma has risen on average 1.4% per year over the last decade in the United States of America (USA).<sup>15</sup>

### Aetiology

Melanomas arise from melanocytes, a derivative of neural crest cells, which migrate to the site of origin during embryogenesis.<sup>16, 12</sup> Risk factors for sinonasal melanoma remain unclear, although pre-existing mucosal melanosis has been linked to oral mucosal melanoma.<sup>18</sup> An association with sinonasal melanoma has yet to be demonstrated. Various authors have suggested that occupational exposure to formaldehyde (present in paints, adhesives, cosmetics, textiles and tobacco smoke) is a possible risk factor.<sup>11, 19-21</sup> Ultraviolet A (UVA) and ultraviolet B (UVB) radiation play an integral role in the pathogenesis of most cutaneous melanomas through a variety of mechanisms, including direct melanocyte DNA damage or stimulation of melanocyte cell division, suppression of cutaneous immunity and free radical synthesis.

Roughly 40% of melanomas exhibit activating mutations responsible for structural changes in the B-Raf protein, responsible for intracellular cell signaling and ultimately cell division and differentiation. A number of gene mutations (*CDKN2A*, *RB1*, *CDK4*, *BRAF*, *KIT*, *NRAS*) have been implicated in both the sporadic and hereditary variants of melanoma. The frequency of different gene mutations varies between cutaneous and sinonasal melanoma, and site of melanoma.<sup>22-26</sup> Those mutations linked to UV radiation occur less frequently in the sinonasal variant, supporting the distinct nature and aetiology of sinonasal melanomas (which is unlikely to be related to sun exposure).

### Clinical presentation

Patients with sinonasal melanoma are often asymptomatic in the initial stages of the disease. However, with tumour growth, presenting complaints include unilateral or bilateral nasal obstruction, epistaxis, rhinorrhoea, hyposmia, epiphora, frontal headaches and facial pain. Proptosis and ophthalmoplegia with diplopia signal orbital involvement. These are late symptoms with an average delay in presentation varying from 1 month to two years.<sup>27</sup> Mucosal lesions are usually pigmented, although non-pigmented, amelanotic melanomas are also possible. Independent clinical predictors of poorer survival include advanced patient age, large tumours and the nodal status or presence of distant metastases at diagnosis.<sup>28-29</sup>

### Diagnosis

Thorough history taking and clinical examination are important in the workup of sinonasal masses. The macroscopic appearance of sinonasal melanoma on anterior rhinoscopy or nasendoscopy varies from classical bluish-black mucosal lesions, to pale yellow or translucent polypoid masses in the amelanotic variant.<sup>30</sup> Identifying the primary site often proves difficult as disease is usually widespread, sometimes with satellite lesions. Nodal assessment for regional disease (10-50% at presentation)<sup>31-32</sup> and workup for distant metastases (40-76% at presentation<sup>33-34</sup>) are also important considerations. Thorough dermatological assessment for skin metastases is also required.<sup>31</sup>

Histopathology, with immunohistochemistry, is the gold standard in confirming the diagnosis of sinonasal melanoma. Diagnosis, based on histopathology alone, can prove difficult and is prone to error.<sup>31</sup> Following histological confirmation of melanoma, various imaging modalities are employed to stage the disease. Computed tomography (CT) scanning usually demonstrates a soft tissue mass, with or without associated bony erosion. Magnetic resonance imaging (MRI) is useful in assessing tumour bulk and extent, especially orbital and intracranial involvement, as well as to differentiate between tumour mass and fluid/secretions within the sinuses. Positron emission tomography (PET) scanning is a useful adjunct in assessing for distant metastases and local recurrence.<sup>11</sup>

Independent predictors of poor survival on histology of sinonasal melanoma include:

- Vascular invasion
- Necrosis
- Polymorphous tumour cell population

Histological features of little prognostic significance in sinonasal melanoma (unlike cutaneous melanoma) include:<sup>35-36</sup>

- Tumour thickness
- Level of invasion
- Ulceration
- Mitotic index
- Nerve involvement

### Staging

In 1970, Ballantyne<sup>37</sup> described 3 stages of mucosal melanoma of the head and neck, based on tumour spread:

- Stage I            Local; confined to the primary site
- Stage II          Regional; regional lymph node involvement
- Stage III         Disseminated; systemic metastases

The disadvantage of this staging system was that the extent of local disease and depth of invasion was not quantified. To overcome these shortcomings, Parsad et al.<sup>38</sup> modified the Ballantyne staging system in 2004 to include 3 subgroups of stage I disease, taking depth of invasion into account:

- Level I            Melanoma in situ or microinvasion
- Level II          Invasion of lamina propria only
- Level III         Deep tissue invasion

This sub-classification never gained universal acceptance and failed to correlate with prognosis in various studies.<sup>39</sup>

The American Joint Committee on Cancer (AJCC) published a TNM staging system for mucosal melanoma in 2002, revised in 2009, to reflect the aggressive behaviour of these tumours. The 2009 system, proposed by Patel and Shah<sup>40</sup>, is a specific classification for mucosal melanoma of the head and neck and depends on tumour size and extent. If the mucosal lesion is identified clinically, tumour stage will be at least T3. As such, T1 and T2 tumours cannot be identified clinically.

TNM staging system for sinonasal melanoma (2009):

#### Primary Tumour (T)

- Tx: Primary tumour cannot be evaluated
- T3: Disease restricted to mucosa
- T4a: Moderately advanced disease: tumour involving soft tissue, cartilage, bone, overlying skin
- T4b: Very advanced disease: tumour involving brain, dura mater, skull base, cranial nerves (IX, X, XI, and XII), masticator space, carotid artery, prevertebral space, or mediastinal structure

#### Regional Lymph Nodes (N)

- Nx: Regional lymph nodes cannot be evaluated
- N0: No evidence of regional nodal metastases
- N1: Regional nodal metastases

## Distant Metastases (M)

- M0: No distant metastases
- M1: Distant metastases

In 2016, Houette et al.<sup>41</sup> compared the prognostic value of the 2002 and 2009 TNM staging systems. The 2009 staging system allows for more homogenous patient groups and clearly distinguishes moderately advanced T3 disease from very advanced T4 disease, with a very poor prognosis. The non-specific AJCC 2002 Clinical Staging Manual has better prognostic value and the authors conclude that this system should not be abandoned.

## Treatment options

Various modalities are employed in the management of sinonasal melanoma. Surgery is regarded as the primary treatment modality<sup>42</sup>, but the roles of neck dissection, adjuvant radiotherapy and chemotherapy remain controversial.

## **Surgery**

The goal of surgery in sinonasal melanoma is local tumour resection with wide margins. Despite aggressive surgery, local recurrence occurs in 29-79% of patients.<sup>43-48</sup> Complete resection is a surgical challenge and it is often impossible to achieve adequate margins due to tumour extent and the fact that tumour often abuts vital anatomical structures. Incomplete resection has been shown to be a predictor of poor survival.<sup>49-50-29</sup> Surgical resection is occasionally considered following a course of neo-adjuvant radiation therapy or chemotherapy, when the tumour has more favourable dimensions and surgery is more likely to achieve adequate surgical margins.

Surgical options for local control include<sup>51</sup>:

- Endoscopic resection without dural excision
- Endoscopic resection with transnasal craniectomy
- Combined cranio-endoscopic resection
- Trans-facial external approaches

Outcome after endoscopic resection has been found to be comparable or better than the more aggressive external craniofacial approaches. The most important surgical prognostic factor is the presence of clear surgical margins.<sup>52</sup>

In the N0 neck, prophylactic neck dissection is not indicated as the incidence of occult nodal metastasis is low (<10%). However, regional lymph node metastasis is associated with very high mortality rate.<sup>53</sup>

Konuthula et al. analysed the outcomes of patients with sinonasal melanoma registered on the American National Cancer Data Base (NCDB). In their analysis of 695 patients between 2004 and 2010, they found no statistically significant difference in 5-year survival between those managed with neck dissection and those managed without.<sup>29</sup>

### **External Beam Radiotherapy (EBRT)**

Historically, sinonasal melanoma was regarded as a radio-resistant tumour. Recently, however, studies have suggested that radiotherapy may improve local control, with little effect on overall survival. No randomised controlled trial has been done in this regard.<sup>7,53-55</sup>

### **Chemotherapy**

Unlike cutaneous melanoma, sinonasal melanoma has a poor response to systemic treatment with either chemotherapy (mainly cisplatin and actinomycin D) or biochemotherapy (based on a biotherapeutic agent e.g. interferon, interleukin-2). Biochemotherapy may be useful in the adjuvant setting. Chemotherapy is most commonly used in the setting of palliative treatment or in cases where surgery is contraindicated.<sup>56-57</sup>

### **Brachytherapy**

To our knowledge, Harris, et al.<sup>58</sup> were the first to report on the use of post-operative brachytherapy to prevent local recurrence after endoscopic resection of sinonasal melanoma. A special applicator was designed to fit the nasal cavity and was inserted into the nasal cavity under general anaesthesia, delivering 60 Gy radiation dose over 5 days (a similar dose delivered via intensity-modulated radiation therapy is usually delivered over a period of 6 weeks). Their patient was a 46-year-old female with pT4 sinonasal melanoma (AJCC 2009) who underwent endoscopic tumour resection at the authors' institution. Intra-operatively, she was noted to have possible microscopic disease left on the dura. She received postoperative brachytherapy to treat the dura in the region of the involved cribriform plate. After 13 years of follow up at our institution, repeat PET scan showed no local recurrence or distant metastases.

Basel Al Kadah et al.<sup>59</sup> published their experience with silicone brachytherapy applicators in 20 patients (January 2001-January 2013) with different sinonasal and nasopharyngeal cancers after endoscopic tumour resection. One patient in the study had mucosal melanoma. Tumour control was achieved in 13 patients, seven patients experienced local recurrence and the overall 2-year survival was 57.3%. Their recommendation was that larger patient numbers were required to assess the efficacy of this method.

Nikolaos Tselis et al.<sup>60</sup> published their experience in treating four cases of inoperable, recurrent head and neck cancer with CT-guided interstitial high-dose rate brachytherapy. This included one patient with sinonasal melanoma, a 52-year-old male with T3N0M0 (AJCC 2009) disease. Initially treated with maxillofacial resection and adjuvant immunotherapy, he developed irresectable local recurrence after 4 months and was treated with chemoradiotherapy. Despite this, he presented with disease progression after six months. This patient then received brachytherapy and local control was achieved for a total of 31 months thereafter.

### **Justification**

The potential benefit of brachytherapy following endoscopic sinonasal tumour resection should be explored. If adjuvant brachytherapy is found to offer survival benefit in sinonasal melanoma, it could expand the current treatment armamentarium and be incorporated into treatment regimens.

Our retrospective study aims to reveal how this technique could potentially:

- Prevent local tumour recurrence
- Improve local control and overall survival
- Minimize duration of treatment (as compared to external beam radiation therapy)
- Lower complication rate

### **Aims**

This study aims to evaluate the use of brachytherapy after endoscopic resection of sinonasal malignant mucosal melanomas. The primary outcome is to determine local tumour control rates and overall survival. A survival analysis will be performed using the Kaplan–Meier method with Greenwood formula for standard error.

Secondary outcomes are to explore the side effects and risks of sinonasal brachytherapy, including the effect of brachytherapy on surrounding anatomical structures.

### **Research design and methods:**

An eleven-year retrospective analysis of all sinonasal malignant melanomas (2004-2015) managed with endoscopic resection and adjuvant brachytherapy, by a single surgeon (Prof D Lubbe), in both her state and private practices will be carried out. Patients will be identified from departmental records and oncology databases. A minimum duration of follow up of two years will be required. All patient lost to follow up will be contacted.

The following data will be collected and analysed:

- Patient age
- Patient gender
- Details of clinical presentation
- Tumour imaging
- Tumour staging
- Treatment received (type and duration)
- Complications following treatment
  - Immediate/acute
    - General: fatigue, nausea and vomiting, diarrhoea
    - Pain
    - Local tissue toxicity: swelling, inflammation, haemorrhage, sloughing
  - Delayed/long term
    - Tissue fibrosis/necrosis
    - Second primary malignancy
- Follow up (clinical and imaging)

- Local control rate will be assessed clinically and with imaging; overall survival will be calculated

#### Inclusion criteria

- Patients with sinonasal malignant melanoma managed with endoscopic resection and adjuvant brachytherapy between 2004 and 2015
- Minimum of 2 years follow up following completion of brachytherapy regimen
- Patients >18 years of age
- Adequate record keeping

#### Exclusion criteria

- Patients <18 years of age
- Patients lost to follow up
- Inadequate record keeping
- Patients unable to complete the prescribed brachytherapy dose/duration

#### **Outcomes:**

This paper will be one of the largest published series on sinonasal mucosal melanoma in the present literature. With the addition of brachytherapy to the treatment regimen, we will investigate whether or not local tumour control rate and overall survival is better than that described for other treatment modalities. The role of brachytherapy has not been investigated in the treatment of sinonasal mucosal melanoma but may represent an important addition to current practice.

#### **Privacy and confidentiality:**

Only the principal investigator and study supervisor will have access to patient medical records for the purposes of data collection. Data will be recorded on an electronic data sheet on a computer that is password protected. Strict confidentiality will be maintained. No patient names will be divulged and no patient identifiers will be visible in any of the images used.

#### **Risks and benefits:**

Patients enrolled in the study will incur no risk or benefit. Knowledge gained from this research may benefit others in the future.

#### **Ethical considerations:**

Ethics approval will be sought from the University of Cape Town Human Research Ethics Committee.

**Autonomy**

Not applicable in this study.

**Beneficence**

Should this study demonstrate benefit of brachytherapy in the management of sinonasal melanoma, this modality could be offered to other patients and improve local control rates and survival.

**Non-maleficence**

No potential harm to study population.

**Justice**

All patients meeting the inclusion criteria will be included in the study, the results of which will be dispersed within the medical fraternity locally and internationally, ensuring distributive justice.

**Informed consent:**

This is not necessary due to the retrospective nature of the study.

**Timeline:**

The anticipated data collection duration is three months.

**Stakeholder and reporting:**

The results of the study will be reported back to the Division of Otolaryngology at Groote Schuur Hospital as a formal report. It will also form part of an MMED study and submitted for publication in a reputable journal.

## References:

1. Iversen K, Robins RE. Mucosal malignant melanomas. *Am J Surg*. 1980;139(5):660-664. <http://www.ncbi.nlm.nih.gov/pubmed/7468915>. Accessed July 19, 2017.
2. Freedman HM, DeSanto LW, Devine KD, Weiland LH. Malignant melanoma of the nasal cavity and paranasal sinuses. *Arch Otolaryngol*. 1973;97(4):322-325. <http://www.ncbi.nlm.nih.gov/pubmed/4699540>. Accessed July 19, 2017.
3. Manolidis S, Donald PJ. Malignant mucosal melanoma of the head and neck: review of the literature and report of 14 patients. *Cancer*. 1997;80(8):1373-1386. <http://www.ncbi.nlm.nih.gov/pubmed/9338460>. Accessed July 19, 2017.
4. Chiu NT, Weinstock MA. Melanoma of oronasal mucosa. Population-based analysis of occurrence and mortality. *Arch Otolaryngol Head Neck Surg*. 1996;122(9):985-988. <http://www.ncbi.nlm.nih.gov/pubmed/8797564>. Accessed July 19, 2017.
5. Chang AE, Karnell LH, Menck HR. The National Cancer Data Base report on cutaneous and noncutaneous melanoma: a summary of 84,836 cases from the past decade. The American College of Surgeons Commission on Cancer and the American Cancer Society. *Cancer*. 1998;83(8):1664-1678. <http://www.ncbi.nlm.nih.gov/pubmed/9781962>. Accessed July 19, 2017.
6. Kingdom TT, Kaplan MJ. Mucosal melanoma of the nasal cavity and paranasal sinuses. *Head Neck*. 17(3):184-189. <http://www.ncbi.nlm.nih.gov/pubmed/7782202>. Accessed July 19, 2017.
7. Dauer EH, Lewis JE, Rohlinger AL, Weaver AL, Olsen KD. Sinonasal melanoma: A clinicopathologic review of 61 cases. *Otolaryngol Neck Surg*. 2008;138(3):347-352. doi:10.1016/j.otohns.2007.12.013
8. Gilain L, Houette A, Montalban A, Mom T, Saroul N. Mucosal melanoma of the nasal cavity and paranasal sinuses. *Eur Ann Otorhinolaryngol Head Neck Dis*. 2014;131(6):365-369. doi:10.1016/j.anorl.2013.11.004
9. Kardon DE, Thompson LDR. Sinonasal mucosal malignant melanoma: Report of an unusual case mimicking schwannoma. *Ann Diagn Pathol*. 2000;4(5):303-307. doi:10.1053/adpa.2000.17888
10. Miettinen M. Sinonasal Tract and Nasopharyngeal Melanomas Staging System. *Am J Surgery*. 2003;27(5):594-611.
11. Clifton N, Harrison L, Bradley PJ, Jones NS. Malignant melanoma of nasal cavity and paranasal sinuses: report of 24 patients and literature review. *J Laryngol Otol*. 2011;125(5):479-485. doi:10.1017/S0022215110002720
12. Koch SE, Lange JR. Amelanotic melanoma: the great masquerader. *J Am Acad Dermatol*. 2000;42(5 Pt 1):731-734. <http://www.ncbi.nlm.nih.gov/pubmed/10775846>. Accessed July 19, 2017.
13. Liversedge RL. Oral malignant melanoma. *Br J Oral Surg*. 1975;13(1):40-55. <http://www.ncbi.nlm.nih.gov/pubmed/1096931>. Accessed July 19, 2017.
14. Goldman S, Glimelius B, Pålman L. Anorectal malignant melanoma in Sweden. Report of 49 patients. *Dis Colon Rectum*. 1990;33(10):874-877. <http://www.ncbi.nlm.nih.gov/pubmed/1698595>. Accessed July 19, 2017.

15. About the Cancer Statistics Review - SEER Publications.  
<https://seer.cancer.gov/publications/csr.html>. Accessed July 19, 2017.
16. Goldman JL, Lawson W, Zak FG, Roffman JD. THE PRESENCE OF MELANOCYTES IN THE HUMAN LARYNX. *Laryngoscope*. 1972;82(5):824-835. doi:10.1288/00005537-197205000-00009
17. Clifton N, Harrison L, Bradley PJ, Jones NS. Malignant melanoma of nasal cavity and paranasal sinuses: report of 24 patients and literature review. *J Laryngol Otol*. 2011;125(05):479-485. doi:10.1017/S0022215110002720
18. Manganaro AM, Hammond HL, Dalton MJ, Williams TP. Oral melanoma: case reports and review of the literature. *Oral Surg Oral Med Oral Pathol Oral Radiol Endod*. 1995;80(6):670-676. <http://www.ncbi.nlm.nih.gov/pubmed/8680974>. Accessed July 19, 2017.
19. Sari UÖ, Isma \_\_, Yilmaz I, et al. BRAF, NRAS, KIT, TERT, GNAQ/GNA11 mutation profile analysis of head and neck mucosal melanomas: a study of 42 cases. 2016:1-7. doi:10.1016/j.pathol.2016.09.065
20. Holmstrom M, Lund VJ. Malignant melanomas of the nasal cavity after occupational exposure to formaldehyde. 1991:10-13.
21. Garzino-Demo P, Fasolis M, Maggiore GMLT, Pagano M, Berrone S. Oral mucosal melanoma: a series of case reports. *J Cranio-Maxillofacial Surg*. 2004;32(4):251-257. doi:10.1016/j.jcms.2003.12.007
22. Cohen Y, Rosenbaum E, Begum S, et al. Exon 15 BRAF Mutations Are Uncommon in Melanomas Arising in Nonsun-Exposed Sites. *Clin Cancer Res*. 2004;10(10):3444-3447. doi:10.1158/1078-0432.CCR-03-0562
23. Beadling C, Jacobson-Dunlop E, Hodi FS, et al. KIT Gene Mutations and Copy Number in Melanoma Subtypes. *Clin Cancer Res*. 2008;14(21):6821-6828. doi:10.1158/1078-0432.CCR-08-0575
24. Carvajal RD, Antonescu CR, Wolchok JD, et al. KIT as a Therapeutic Target in Metastatic Melanoma. *JAMA*. 2011;305(22):2327. doi:10.1001/jama.2011.746
25. Schoenewolf NL, Bull C, Belloni B, et al. Sinonasal, genital and acrolentiginous melanomas show distinct characteristics of KIT expression and mutations. *Eur J Cancer*. 2012;48(12):1842-1852. doi:10.1016/j.ejca.2012.02.049
26. Turri-Zanoni M, Medicina D, Lombardi D, et al. Sinonasal mucosal melanoma: Molecular profile and therapeutic implications from a series of 32 cases. *Head Neck*. 2013;35(8):1066-1077. doi:10.1002/hed.23079
27. Lund VJ, Howard DJ, Harding L, Wei WI. Management options and survival in malignant melanoma of the sinonasal mucosa. *Laryngoscope*. 1999;109(2 Pt 1):208-211. doi:10.1097/00005537-199902000-00007
28. Jethanamest D, Vila PM, Sikora AG, Morris LGT. Predictors of survival in mucosal melanoma of the head and neck. *Ann Surg Oncol*. 2011;18(10):2748-2756. doi:10.1245/s10434-011-1685-4
29. Konuthula N, Khan MN, Parasher A, et al. The presentation and outcomes of mucosal melanoma in 695 patients. *Int Forum Allergy Rhinol*. 2016;7(1):99-105. doi:10.1002/alr.21831
30. García Teno M, Ariza Toledo MA, Sánchez Legaza E, Báez JM, Sierra Galera G, Oliva

- Domínguez M. [Epithelioid amelanotic melanoma of the nose and paranasal sinuses]. *An Otorrinolaringol Ibero Am.* 1999;26(4):393-400.  
<http://www.ncbi.nlm.nih.gov/pubmed/10520279>. Accessed July 19, 2017.
31. Enée V, Houliat T, Truilhé Y, Darrouzet V, Stoll D. [Malignant melanoma of the nasosinal mucosa. Retrospective study apropos of 20 cases]. *Rev Laryngol Otol Rhinol (Bord)*. 2000;121(4):243-250. <http://www.ncbi.nlm.nih.gov/pubmed/11233707>. Accessed July 19, 2017.
  32. Mané J, Stoll D, Delaunay MM, Traissac L. [Melanoma of the ORL mucosa]. *Rev Laryngol Otol Rhinol (Bord)*. 1992;113(3):179-183.  
<http://www.ncbi.nlm.nih.gov/pubmed/1344532>. Accessed July 19, 2017.
  33. Loree TR, Mullins AP, Spellman J, North JH, Hicks WL. Head and neck mucosal melanoma: a 32-year review. *Ear Nose Throat J.* 1999;78(5):372-375.  
<http://www.ncbi.nlm.nih.gov/pubmed/10355199>. Accessed July 19, 2017.
  34. Vinel V, Dehesdin D, Marie JP. [Melanoma of the nasal fossae and sinuses, apropos of a series of 7 cases]. *Rev Laryngol Otol Rhinol (Bord)*. 1990;111(1):61-65.  
<http://www.ncbi.nlm.nih.gov/pubmed/2130402>. Accessed July 19, 2017.
  35. Kim D-K, Kim DW, Kim SW, Kim D-Y, Lee CH, Rhee C-S. Ki67 antigen as a predictive factor for prognosis of sinonasal mucosal melanoma. *Clin Exp Otorhinolaryngol.* 2008;1(4):206-210. doi:10.3342/ceo.2008.1.4.206
  36. Prasad ML, Patel S, Hoshaw-Woodard S, et al. Prognostic factors for malignant melanoma of the squamous mucosa of the head and neck. *Am J Surg Pathol.* 2002;26(7):883-892.  
<http://www.ncbi.nlm.nih.gov/pubmed/12131155>. Accessed July 19, 2017.
  37. Ballantyne AJ. Malignant melanoma of the skin of the head and neck. An analysis of 405 cases. *Am J Surg.* 1970;120(4):425-431. <http://www.ncbi.nlm.nih.gov/pubmed/5507326>. Accessed July 19, 2017.
  38. Prasad ML, Patel SG, Huvos AG, Shah JP, Busam KJ. Primary mucosal melanoma of the head and neck. *Cancer.* 2004;100(8):1657-1664. doi:10.1002/cncr.20201
  39. Shuman AG, Light E, Olsen SH, et al. Mucosal Melanoma of the Head and Neck. *Arch Otolaryngol Neck Surg.* 2011;137(4):331. doi:10.1001/archoto.2011.46
  40. Patel S SJ. Part 2, Head and neck sites. In: Edge SB, Byrd DR, Carducci MA, Compton CA, eds. *AJCC Cancer Staging Man.* 2009;7th edn(New York: Springer).
  41. Houette A, Gilain L, Mulliez A, Mom T, Saroul N. Prognostic value of two tumour staging classifications in patients with sinonasal mucosal melanoma. *Eur Ann Otorhinolaryngol Head Neck Dis.* 2016;133(5):313-317. doi:10.1016/j.anorl.2016.05.008
  42. Penel N, Mallet Y, Mirabel X, Van JT, Lefebvre J-L. Primary mucosal melanoma of head and neck: prognostic value of clear margins. *Laryngoscope.* 2006;116(6):993-995. doi:10.1097/01.mlg.0000217236.06585.a9
  43. Meleti M, Leemans CR, de Bree R, Vescovi P, Sesenna E, van der Waal I. Head and neck mucosal melanoma: Experience with 42 patients, with emphasis on the role of postoperative radiotherapy. *Head Neck.* 2008;30(12):1543-1551. doi:10.1002/hed.20901
  44. Bachar G, Loh KS, O'Sullivan B, et al. Mucosal melanomas of the head and neck: The Princess Margaret Hospital experience. *Head Neck.* 2008;30(10):1325-1331. doi:10.1002/hed.20878
  45. Krengli M, Masini L, Kaanders JHAM, et al. Radiotherapy in the treatment of mucosal

- melanoma of the upper aerodigestive tract: Analysis of 74 cases. A Rare Cancer Network study. *Int J Radiat Oncol*. 2006;65(3):751-759. doi:10.1016/j.ijrobp.2006.01.016
46. Nakashima JP, Vi&eacute;gas CM, Fassizoli AL, et al. Postoperative Adjuvant Radiation Therapy in the Treatment of Primary Head and Neck Mucosal Melanomas. *ORL*. 2008;70(6):344-351. doi:10.1159/000163029
  47. Owens JM, Roberts DB, Myers JN. The Role of Postoperative Adjuvant Radiation Therapy in the Treatment of Mucosal Melanomas of the Head and Neck Region. *Arch Otolaryngol Neck Surg*. 2003;129(8):864. doi:10.1001/archotol.129.8.864
  48. Temam S, Mamelle G, Marandas P, et al. Postoperative radiotherapy for primary mucosal melanoma of the head and neck. *Cancer*. 2005;103(2):313-319. doi:10.1002/cncr.20775
  49. Lee SP, Shimizu KT, Tran LM, Juillard G, Calcaterra TC. Mucosal melanoma of the head and neck: the impact of local control on survival. *Laryngoscope*. 1994;104(2):121-126. doi:10.1288/00005537-199402000-00001
  50. Penel N, Mallet Y, Mirabel X, Van JT, Lefebvre J-L. Primary mucosal melanoma of head and neck: prognostic value of clear margins. *Laryngoscope*. 2006;116(6):993-995. doi:10.1097/01.mlg.0000217236.06585.a9
  51. Villaret AB, Yakirevitch A, Bizzoni A, et al. Endoscopic transnasal craniectomy in the management of selected sinonasal malignancies. *Am J Rhinol Allergy*. 2010;24(1):60-65. doi:10.2500/ajra.2010.24.3397
  52. Fernando L?opez, MD, PhD, 1 2, Juan P. Rodrigo, MD, PhD, 1, 2 Antonio Cardesa, MD, PhD, 3 Asterios Triantafyllou, FRCPath, PhD 4, Kenneth O. Devaney, MD, JD, 5 William M. Mendenhall, MD, 6 Missak Haigentz Jr, MD, 7 Primo?z Strojjan, MD, PhD 8, et al. Update on primary head and neck mucosal melanoma. *Head Neck*. 2016;38:147–155.
  53. Benlyazid A, Thariat J, Al E. Postoperative Radiotherapy in Head and Neck Mucosal Melanoma. *Arch Otolaryngol Head Neck Surg*. 2014;136(12):1219-1225.
  54. Lazarev S, Gupta V, Hu K, Harrison LB, Bakst R. Mucosal melanoma of the head and neck: A systematic review of the literature. *Int J Radiat Oncol Biol Phys*. 2014;90(5):1108-1118. doi:10.1016/j.ijrobp.2014.03.042
  55. Krengli M, Masini L, Kaanders JHAM, et al. Radiotherapy in the treatment of mucosal melanoma of the upper aerodigestive tract: Analysis of 74 cases. A Rare Cancer Network study. *Int J Radiat Oncol Biol Phys*. 2006;65(3):751-759. doi:10.1016/j.ijrobp.2006.01.016
  56. Bossi P, Saba NF, Vermorken JB, et al. The role of systemic therapy in the management of sinonasal cancer: A critical review. *Cancer Treat Rev*. 2015;41(10):836-843. doi:10.1016/j.ctrv.2015.07.004
  57. Cheng Y-F, Lai C-C, Ho C-Y, Shu C-H, Lin C-Z. Toward a Better Understanding of Sinonasal Mucosal Melanoma: Clinical Review of 23 Cases. *J Chinese Med Assoc*. 2007;70(1):24-29. doi:10.1016/S1726-4901(09)70296-5
  58. Harris T, Stannard C, Lubbe D. Endoscopic Resection and Postoperative Brachytherapy in the Treatment of Sinonasal Melanoma. *J Case Reports Med*. 2014;3:1-3. doi:10.4303/jcrm/235844
  59. Kadah B Al, Niewald M, Papaspyrou G, Dzierma Y, Schneider M, Schick B. Customized individual applicators for endocavitary brachytherapy in patients with cancers of the nasal cavity, sinonasal region and nasopharynx. *Eur Arch Oto-Rhino-Laryngology*. 2016;273(6):1543-1547. doi:10.1007/s00405-015-3636-3

60. Nikolaos Tselis, MD, PhD, 1\* Efstratios Karagiannis, MD, 2 Christos Kolotas, MD, PhD, 3 Mehran Baghi, MD, PhD, 4 Natasa Milickovic, PhD 5, Nikolaos Zamboglou, MD P. Image-guided interstitial high-dose-rate brachytherapy in the treatment of inoperable recurrent head and neck malignancies: An effective option of reirradiation. *Wiley Online Libr.* 2017;Head Neck(39):E61-E86. [wileyonlinelibrary.com](http://wileyonlinelibrary.com).

# Endoscopic Resection and Post-Operative Brachytherapy in the Treatment of Sinonasal Melanoma

## Abstract

**Background:** Sino-Nasal Melanomas (SNM) are rare, aggressive tumours often associated with a poor prognosis due to advanced stage disease at presentation. Mean 5-year survival is 0-46%.

Various treatment modalities are used in the management of SNM. Surgery is regarded as the primary treatment modality, but therapy remains controversial. Complete resection is a surgical challenge and it is often impossible to achieve adequate margins due to the fact that tumour often abuts vital anatomical structures. Incomplete resection has been shown to be a predictor of poor survival. Harris et al. (2014) were the first to report on the use of post-operative brachytherapy in an attempt to prevent local recurrence after endoscopic resection of SNM.

**Methods:** A retrospective analysis of all patients undergoing endoscopic resection of SNMs and receiving adjuvant brachytherapy in a single surgeon's practice between August 2004 and May 2014 was carried out. Outcome measures included local control rate and 5-year overall survival estimated by Kaplan-Meier analysis. The incidence of regional and distal recurrence (metastases) was calculated

**Results:** Five cases of sinonasal melanoma (3 males 2, females) were managed with endoscopic resection and adjuvant brachytherapy. Patients were followed up for a median duration of 61 months (32-154 months) following adjuvant Brachytherapy. Local control was achieved in four out of five patients (80%). Three out of five patients developed distant metastasis. Median time to metastasis was 54 months. One patient received immunotherapy after diagnosis of distant metastasis (BRAF positive). Three out of five patients (60%) died from the complications of distant metastases of sinonasal melanoma. Median survival time following adjuvant Brachytherapy was 61 months (32-154 months). Five-year survival rate was 40% (95% CI 5.2% - 75.3%).

**Conclusion:** This is the only case series describing the use of brachytherapy following endoscopic resection of sinonasal melanoma. Our case series, albeit small, describes a local control rate and 5-year survival comparable with the best reported in the literature. Adjuvant brachytherapy represents a novel approach and potentially a useful addition to the adjuvant therapy armamentarium. The advantages of brachytherapy include a favourable side-effect profile and a shorter duration of treatment, while delivering a dose of radiation similar to that of Conventional Radiotherapy. Further studies are necessary to define the role of brachytherapy in sinonasal melanoma.

## Introduction

Primary mucosal sinonasal melanoma accounts for 0.5-2% of all melanomas, 4% of head and neck melanomas and 4-8% of all sinonasal malignancies.<sup>1-7</sup> They have an equal gender distribution and usually occur in patients in their 6<sup>th</sup>-7<sup>th</sup> decade of life.<sup>8</sup> Sinonasal melanomas are rare, aggressive tumours often associated with a poor prognosis due to advanced stage disease at presentation. Regional and distant metastases are present at presentation in a third of cases.<sup>7</sup> Mean 5-year survival is 0-46%.<sup>9</sup> The vast majority (80%) arise from the nasal vault (lateral nasal wall and nasal septum). The remainder are of sinus origin, with the maxillary sinus most commonly involved.<sup>10</sup> Those arising from the nasal vault have a better prognosis and 5-year survival.<sup>11</sup>

Interestingly, the incidence of mucosal melanoma is higher in areas where the incidence of cutaneous melanoma is lower. Both variants occur more commonly in Caucasian populations, although 7% of mucosal melanomas occur in Afro-Caribbean populations compared to just 0.8% of cutaneous melanomas.<sup>12-14</sup> The incidence of mucosal melanoma has remained relatively constant, while that of cutaneous melanoma has risen on average 1.4% per year over the last decade in the United States of America (USA).<sup>15</sup>

Melanomas arise from melanocytes, a derivative of neural crest cells, which migrate to the site of origin during embryogenesis.<sup>12,16</sup> Risk factors for sinonasal melanoma remain unclear, although pre-existing mucosal melanosis has been linked to oral mucosal melanoma.<sup>17</sup> An association with sinonasal melanoma has yet to be demonstrated. Various authors have suggested that occupational exposure to formaldehyde (present in paints, adhesives, cosmetics, textiles and tobacco smoke) is a possible risk factor.<sup>11-20</sup> Ultraviolet A (UVA) and ultraviolet B (UVB) radiation play an integral role in the pathogenesis of most cutaneous melanomas through a variety of mechanisms, including direct melanocyte DNA damage or stimulation of melanocyte cell division, suppression of cutaneous immunity and free radical synthesis.

Patients with sinonasal melanoma are often asymptomatic in the initial stages of the disease. However, with tumour growth, presenting complaints include unilateral or bilateral nasal obstruction, epistaxis, rhinorrhoea, hyposmia, epiphora, frontal headaches and facial pain. Proptosis and ophthalmoplegia with diplopia signal orbital involvement. These are late symptoms with an average delay in presentation varying from 1 month to 2 years.<sup>21</sup> Mucosal lesions are usually pigmented, although non-pigmented, amelanotic melanomas are also possible. Independent clinical predictors of poorer survival include advanced patient age, large tumours and the nodal status or presence of distant metastases at diagnosis.<sup>22-23</sup>

Thorough history taking, and clinical examination are important in the workup of sinonasal masses. The macroscopic appearance of sinonasal melanoma on anterior rhinoscopy or nasendoscopy varies from classical bluish-black mucosal lesions, to pale yellow or translucent polypoid masses in the amelanotic variant.<sup>24</sup> Identifying the primary site often proves difficult as disease is usually widespread, sometimes with satellite lesions. Nodal assessment for regional disease (10-50% at presentation)<sup>25-26</sup> and workup for distant metastases (40-76% at presentation<sup>27-28</sup>) are also important considerations. Thorough dermatological assessment for skin metastases is also required.<sup>25</sup>

Histopathology with immunohistochemistry is the gold standard in confirming the diagnosis of sinonasal melanoma. Diagnosis based on histopathology alone can prove difficult and is prone to error.<sup>25</sup> Following histological confirmation of melanoma, various imaging modalities are employed to stage the disease. Computed tomography (CT) scanning usually demonstrates a soft tissue mass, with or without

associated bony erosion. Magnetic resonance imaging (MRI) is useful in assessing tumour bulk and extent, especially orbital and intracranial involvement, as well as to differentiate between tumour mass and fluid/secretions within the sinuses. Positron emission tomography (PET) scanning is a useful adjunct in assessing for distant metastases and local recurrence.<sup>11</sup>

In 1970, Ballantyne described three stages of mucosal melanoma of the head and neck, based on tumour spread (local, regional and disseminated).<sup>29</sup> The disadvantage of this staging system was that the extent of local disease and depth of invasion was not quantified. To overcome these shortcomings, Parsad et al.<sup>30</sup> modified the Ballantyne staging system in 2004 to include 3 subgroups of stage I disease, taking depth of invasion into account. This sub-classification never gained universal acceptance and failed to correlate with prognosis in various studies.<sup>31</sup>

The American Joint Committee on Cancer (AJCC) published a TNM staging system for mucosal melanoma in 2002, revised in 2009 (unchanged 2017) to reflect the aggressive behavior of these tumours. The 2009 system, proposed by Patel and Shah,<sup>32</sup> is a specific classification for mucosal melanoma of the head and neck and depends on tumour size and extent. If the mucosal lesion is identified clinically, tumour stage will be at least T3. As such, T1 and T2 tumours cannot be identified clinically. In 2016, Houette et al.<sup>33</sup> compared the prognostic value of the 2002 and 2009 TNM staging systems. The 2009 staging system allows for more homogenous patient groups and clearly distinguishes moderately advanced T3 disease from very advanced T4 disease, with a very poor prognosis. The non-specific AJCC 2002 Clinical Staging Manual has better prognostic value, however, and the authors conclude that this system should not be abandoned.

Literature guiding the management of sinonasal melanoma is limited to retrospective case series, precluding a robust assessment of outcomes. Best current practice is evolving and incorporates surgical resection, external beam radiotherapy (EBRT), chemotherapy, immunotherapy and targeted therapy in various combinations. Oncological outcomes of endonasal endoscopic resection and open resection are comparable.<sup>34</sup> The role of adjuvant therapy, however, remains controversial. Despite sinonasal melanoma having the reputation of being a radioresistant tumour, the addition of adjuvant EBRT has recently been shown to improve local control rates and has become the standard of care.<sup>7,35-37</sup> Chemo- and immunotherapy may improve survival but are not routinely administered and are associated with significant morbidity.<sup>38-40</sup> Therapies targeting the specific gene mutations common to mucosal melanoma are currently being investigated in clinical trials and may contribute to management of sinonasal melanoma in the future.

The authors' unit has previously reported on the use of brachytherapy in the management of sinonasal melanoma.<sup>41</sup> To our knowledge, this is the only case series on the matter in the literature.

## **Materials and methods**

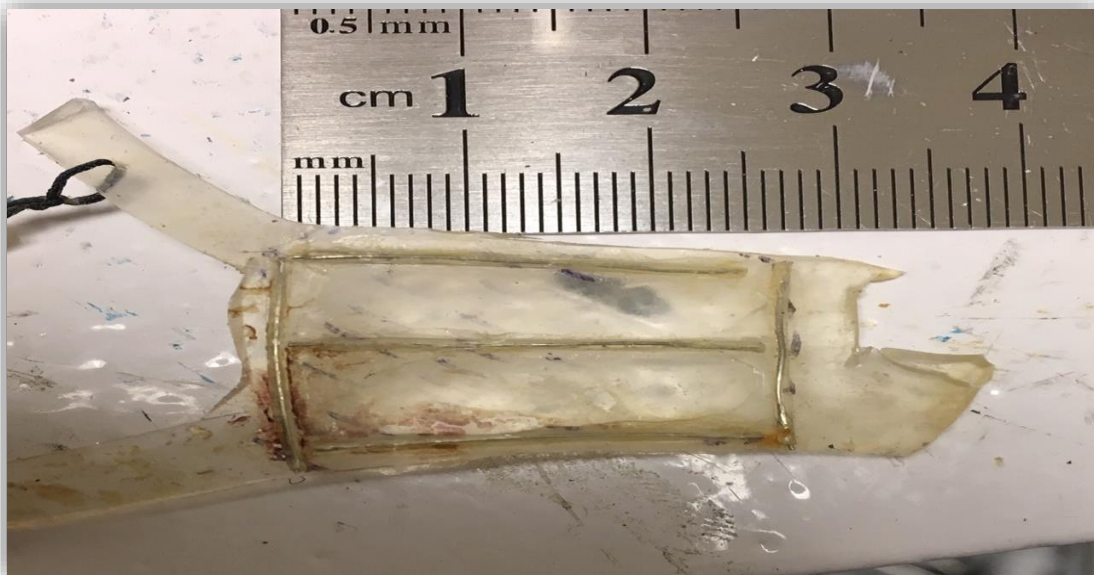
Ethics approval was obtained from the University of Cape Town Human Research Ethics Committee. Patients with sinonasal melanoma, undergoing endoscopic resection (DL single surgeon) and adjuvant brachytherapy between August 2004 and May 2014, were identified from an oncology database. Five patients were included in the series (Table 1). All patients underwent imaging (CT scan and MRI) following diagnosis. Tumours were staged according to the AJCC TNM staging system for mucosal melanoma (2009).<sup>32</sup>

Following endoscopic tumour resection, brachytherapy was administered to the nasal cavities via an applicator. In all but one case, a 3mm silicone sheet was cut to match the contour of the nasal cavity and plastic tubes containing Iridium-192 were glued to the surface of the silicone applicator (Figure 1). Dose

was measured 5mm from the surface of the implant (51-55 Gy in 51-100 hours). In one case, a 24 carat gold applicator with surface Iodine-125 seeds was used (60 Gy in 105 hours, measured at 2mm from the surface of the applicator).

Patients were followed up with regular flexible nasendoscopy, with the addition of positron emission tomography (PET) scanning at time of diagnosis and on follow-up to assess for local recurrence and distant metastasis. Follow up CT/MRI scans were requested if suspicious lesions were identified clinically/endoscopically or on PET-CT. Lesions clinically and/or radiologically suspicious of recurrence were biopsied.

A retrospective analysis of outcomes was carried out. Outcome measures included local control rate and 5-year overall survival estimated by Kaplan-Meier analysis. The incidence of regional and distal recurrence (metastases) was calculated. Analyses were conducted using STATA statistical software (v13.0, StataCorp LLC, TX, USA).



**Figure 1: Silicone sheet glued with plastic tubes filled with Iridium 192**

## Results

Five cases of sinonasal melanoma (3 males, 2 females) were managed with endoscopic resection and adjuvant brachytherapy over a 10-year period (Table 1). Patient age ranged from 30 to 73 years (median 57 years). Epistaxis was the presenting complaint in four out of five cases. One case presented with unilateral nasal obstruction. Local disease was staged as T4b in three cases, T4a in one case and T3 in one case at initial diagnosis. All cases were staged as NOM0 at diagnosis. Two patients had previously undergone endoscopic surgical resection of sinonasal melanoma, one with incomplete resection (T4a) and the other with local recurrence following resection and conventional radiotherapy (T4b).

Patient	1	2	3	4	5	Summary
Age at presentation	30 years	46 years	57 years	70 years	73 years	<b>Median age 57 (30 – 73)</b>
Gender	Male	Female	Female	Male	Male	<b>3 Males; 2 females</b>
Comorbidities	Skin melanoma excised 2008	Hyper-thyroidism	Colon cancer (resected 2015)	Hypertension; ischemic heart disease (myocardial infarction 2013)	Ischemic heart disease	
Clinical presentation	July 2012: Epistaxis; offensive rhinorrhea; postnasal drip	August 2004: Epistaxis	January 2013: Epistaxis; bloody rhinorrhea	April 2008: Epistaxis	May 2014: Left nasal obstruction	<b>4 out of 5 had epistaxis</b>
Stage	T3N0M0	T4bN0M0	T4aN0M0	T4bN0M0	T4bN0M0	<b>1 was T3N0M0</b>
Previous surgery	None	None	Incomplete resection	Multiple surgical resections	None	<b>2 had surgery before</b>
Surgery dates	August 2012	December 2005	March 2013	February 2011	December 2014; October 2015; June 2017	
Complications	None	Cerebrospinal fluid (CSF), immediate repair	Nasal crusting	None	Massive epistaxis	
Adjuvant brachytherapy	October 2012: 59 Gy/100hr	December 2005: 60 Gy/105hr	May 2013: 55 Gy/100hr	April 2011: 54.6 Gy/78hr	March 2015: 51 Gy/ 51 Hr	
BRAF	Positive	Not tested	Negative	Negative	Positive	
Follow up imaging	CT, MRI, PET-CT	CT, MRI PET-CT, US	CT, MRI, PET-CT	CT, MRI, PET-CT	CT, MRI, PET-CT	
Local control	Yes 72 months	Yes 154 months	Yes 61 months	Yes 32 months	No recurrence after 7 months	
Distant metastasis	No 72 months	No 154 months	After 54 months. Spinal metastasis	After 15 months Multiple abdominal metastasis	After 24 months. Bone metastasis (Hips, Pelvis, Humerus and Sternum)	<b>2 had no metastases</b>
Survival following treatment	72 months	154 months	61 months	32 months	41 months	

**Table 1: Patients undergoing endoscopic resection of sinonasal melanoma, followed by adjuvant brachytherapy**

## Local control

Local control was achieved in four out of five patients (80%) undergoing endoscopic surgical resection of sinonasal melanoma followed by adjuvant brachytherapy (Figure 2). Patients were followed up for a median duration of 61 months (32-154 months) following adjuvant brachytherapy. One patient developed local recurrence of disease 7 months following adjuvant Brachytherapy after primary resection and again at 14 months following secondary resection. Median disease-free duration was 61 months (range 7-154 months).

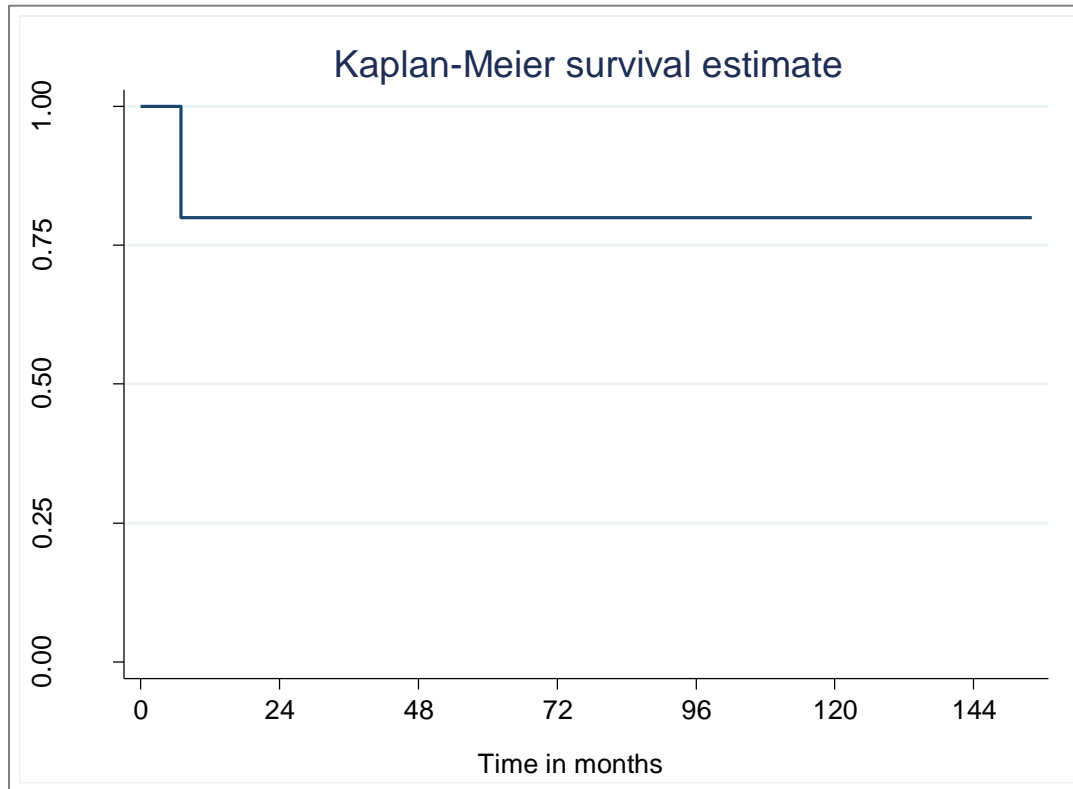


Figure 2: Kaplan-Meier estimates for local control

## Metastasis

Three out of five patients developed distant metastasis. Median time to metastasis following adjuvant Brachytherapy was 54 months (range 15-154 months). (Figure 3). One patient received immunotherapy after diagnosis of distant metastasis (BRAF positive).

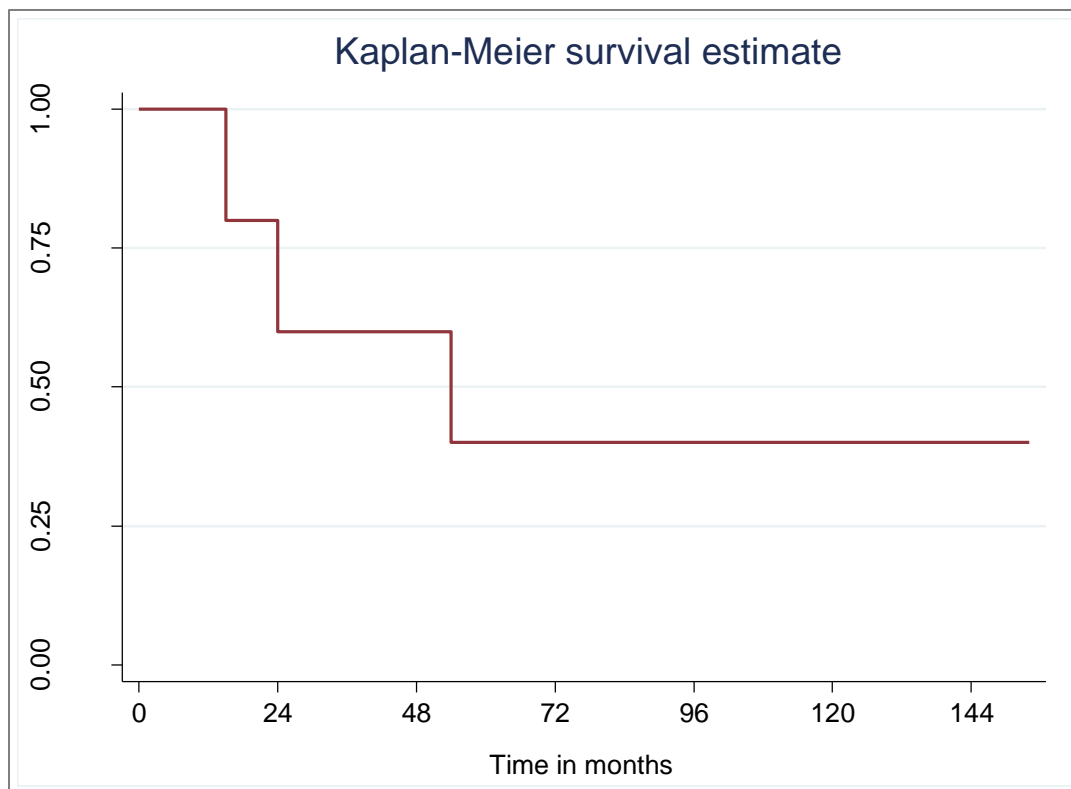


Figure 3: Kaplan-Meier estimate for time to metastasis

### Survival

Three out of five patients (60%) died from the complications of distant metastases of sinonasal melanoma. Median survival time following adjuvant Brachytherapy was 61 months (32-154 months). Five-year survival rate was 40% (95% CI 5.2% - 75.3%) (Figure 4).

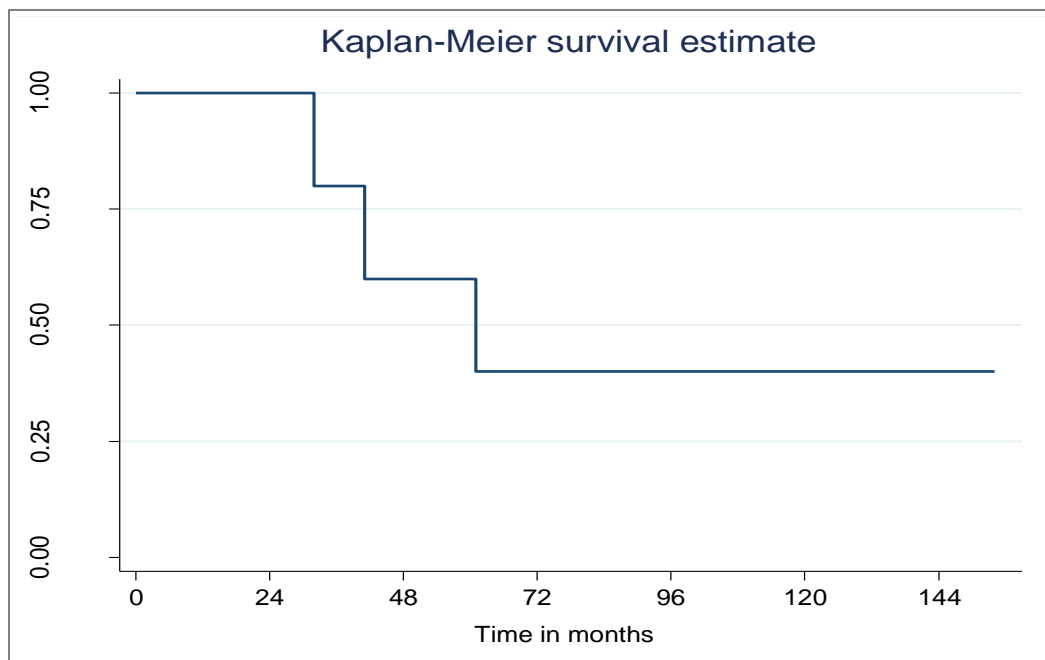


Figure 4: Kaplan-Meier estimate of overall survival during the follow up period

### **Complications following endoscopic resection and adjuvant brachytherapy**

One patient developed a CSF leak during endoscopic resection of sinonasal melanoma as the dura mater was infiltrated with tumour. The leak was repaired immediately. One patient developed minimum nasal crusting postoperatively and another required blood transfusion following severe postoperative epistaxis immediately after surgery.

### **Discussion**

Brachytherapy is an effective local treatment for select head and neck cancers, delivering high-dose radiation to a limited tissue volume, while sparing normal surrounding structures through steep dose reduction. Local tumour control rates are generally good and the side effect profile is preferable to that of EBRT.<sup>42,43</sup> Brachytherapy has applications as both a primary and adjuvant form of treatment in the context of malignant head and neck tumours. It can also be used in cases of tumour recurrence in a previously irradiated site and in combination with EBRT to offer a radiation dose boost.<sup>44</sup>

A study by Stannard et al. at our institution describes nine patients with minor salivary gland tumours of the soft and/or hard palate with positive resection margins or unfavorable histopathology, managed with adjuvant Iodine-125 Brachytherapy seed implants postoperatively. Implants were well tolerated, delivering a median dose of 65 Gy over a median duration of 120 hours. No local or regional recurrences were reported after a median follow up of 50 months.<sup>45</sup> The same author reported on 114 patients with oral cavity/oropharynx squamous cell carcinoma managed with Iodine-125 brachytherapy following tumour resection. Median doses of 59.2 Gy and 22.7 Gy were administered without concurrent EBRT or as a dose boost together with EBRT respectively. Local tumour control rates were 80.7% at 5 years and 80% at 10 years. Brachytherapy was also found to be a cost-effective intervention as it is considerably less expensive than a course EBRT.<sup>46</sup>

To our knowledge, Harris, et al.<sup>41</sup> (at our institution) were the first to report on the use of postoperative brachytherapy in an attempt to reduce local recurrence after endoscopic resection of sinonasal melanoma. Kadah et al.<sup>47</sup> published their experience with silicone brachytherapy applicators in 20 patients with a spectrum of sinonasal and nasopharyngeal cancers after endoscopic tumour resection. Only one patient in the study had mucosal melanoma. Tumour control was achieved in 13 patients, seven patients experienced local recurrence and the overall 2-year survival was 57.3%. Their recommendation was that larger patient numbers were required to assess the efficacy of this method. Tselis et al.<sup>48</sup> published their experience in treating four cases of inoperable, recurrent head and neck cancer with CT-guided interstitial high-dose rate brachytherapy. This included one patient with sinonasal melanoma, a 52-year-old male with T3N0M0 (AJCC 2009) disease. Initially treated with maxillofacial resection and adjuvant immunotherapy, he developed irresectable local recurrence after 4 months and was treated with chemoradiotherapy. Despite this, he presented with disease progression after six months. This patient then received brachytherapy and local control was achieved for a total of 31 months thereafter.

Our cases had a special brachytherapy applicator inserted and removed from the nasal cavities under general anesthesia, with simultaneous biopsy of any suspicious lesions identified. Radiation doses ranged from 51 to 60 Gy over 51 to 105 hours. Similar doses of intensity-modulated radiation therapy are usually delivered over a period of six weeks. Brachytherapy was well tolerated and no side-effects were reported. Despite encouraging local control rates and overall survival, our retrospective case series comprised only five patients. Further studies are required to define the role of brachytherapy in the context of sinonasal melanoma.

Despite aggressive surgical treatment of sinonasal melanoma and the addition of adjuvant radiotherapy, local recurrence rates reported in the literature range from 29-79%.<sup>52-53,39,54-56</sup> In our small series of patients receiving adjuvant brachytherapy, local recurrence occurred in just one of five cases (20%). Local control was achieved in 80% of cases at a median follow up period of 61 months.

Current management of sinonasal melanoma is associated with a 5-year survival of 0-46%.<sup>9</sup> Our 5-year survival of 40% compares favorably with the literature. Kadah et al. reported an overall 2-year survival of 57.3% after surgery and post-operative brachytherapy in the context of different sinonasal malignancies.<sup>47</sup> Our 2-year survival rate was 100%. In keeping with the findings of Konuthula et al. Patients who developed distant metastasis had a poorer prognosis.<sup>23</sup> Other factors independently predicting poorer survival include advanced patient age, large tumours, regional metastasis and the histological findings of vascular invasion, necrosis and polymorphous tumour cell populations.<sup>22-23,57, 49</sup>

The management of sinonasal melanoma remains controversial and continues to evolve. Treatment options are discussed below.

## **Surgery**

Complete resection is a surgical challenge and it is often impossible to achieve adequate margins due to tumour extent and the fact that tumour often abuts vital anatomical structures. Incomplete resection has been shown to be a predictor of poor survival.<sup>50-51,23</sup> Surgical resection is occasionally considered following a course of neo-adjuvant radiation therapy or chemotherapy, when the tumour has more favorable dimensions and surgery is more likely to achieve adequate surgical margins.

Surgical options for local control include endoscopic resection without dural excision, endoscopic resection with transnasal craniectomy, combined cranio-endoscopic resection and trans-facial external approaches.<sup>4</sup> Outcome after endoscopic resection has been found to be comparable or better than the more aggressive external craniofacial approaches. The most important surgical prognostic factor is the presence of clear surgical margins.<sup>34</sup>

In the N0 neck, prophylactic neck dissection is not indicated as the incidence of occult nodal metastasis is low (<10%). However, regional lymph node metastasis is associated with very high mortality rate.<sup>35</sup>

Konuthula et al. analyzed the outcomes of patients with sinonasal melanoma registered on the American National Cancer Data Base (NCDB). In their analysis of 695 patients between 2004 and 2010, they found no statistically significant difference in 5-year survival between those managed with neck dissection and those managed without.<sup>23</sup>

## **EBRT**

Historically, sinonasal melanoma was regarded as a radio-resistant tumour. Recently, however, studies have suggested that radiotherapy may improve local control, with little effect on overall survival. No randomized controlled trial has been done in this regard.<sup>7,35-37</sup>

## **Systemic treatment**

A number of gene mutations (*CDKN2A*, *RB1*, *CDK4*, *BRAF*, *KIT*, *NRAS*) have been implicated in both the sporadic and hereditary variants of melanoma. Roughly 40% of cutaneous melanomas and 10-20% of mucosal melanomas.<sup>58</sup> exhibit activating mutations responsible for structural changes in the BRAF protein, responsible for intracellular cell signaling and ultimately cell division and differentiation. The frequency of different gene mutations varies between cutaneous and sinonasal melanoma, and site of melanoma.<sup>59-63</sup> Those mutations linked to UV radiation occur less frequently in the sinonasal variant, supporting the distinct nature and aetiology of sinonasal melanomas (which is unlikely to be related to sun exposure). In BRAF-mutant melanoma, targeted therapy (combining BRAF-inhibitors and immunotherapy) can target the BRAF driver mutation in tumour cells and sensitize the immune system to target tumour. Studies investigating targeted therapy have shown encouraging results, even suggested the potential for long-term control in advanced and metastatic disease.<sup>64</sup>

Unlike cutaneous melanoma, sinonasal melanoma has a poor response to systemic treatment with either chemotherapy (mainly cisplatin and actinomycin D) or biochemotherapy (based on a biotherapeutic agent e.g. interferon, interleukin-2). Chemotherapy is most commonly used in the setting of palliative treatment or in cases where surgery is contraindicated.<sup>38-39</sup> A meta-analysis of 39 studies showed no significant effect on overall survival by adding postoperative radiotherapy, but that survival was improved with the addition of adjuvant chemotherapy.<sup>40</sup>

One patient in our series received systemic immunotherapy for BRAF-mutant sinonasal melanoma with systemic metastasis. A number of immunotherapeutic agents have been developed and are administered in various regimens, either as a single agent or in combination. A 2018 case report by Philipp et al. described their experience managing a case of c-KIT and BRAF positive sinonasal melanoma with advanced local recurrence and cervical lymph node metastasis after surgery, post-operative radiotherapy and low dose interferon. Complete resolution of disease was achieved with combined immunotherapy (ipilimumab and nivolumab).<sup>65</sup> A pooled analysis by D'Angelo et al. suggested improved efficacy of combination therapy (nivolumab plus ipilimumab) compared to either agent administered alone.<sup>66</sup>

## **Conclusion**

Sinonasal melanomas are rare, aggressive tumours with an unpredictable response to treatment and a poor prognosis. Diagnosis is usually followed by aggressive multimodal management in an attempt to achieve local control and improve outcomes. Maximal therapy usually entails surgical resection and

adjuvant radiotherapy, with the roles of chemotherapy, immunotherapy and targeted therapies evolving. To our knowledge, this is the only case series describing the use of brachytherapy following endoscopic resection of sinonasal melanoma. Our case series, albeit small, describes a local control rate and 5-year survival comparable with the best reported in the literature. Adjuvant brachytherapy represents a novel approach and potentially a useful addition to the adjuvant therapy armamentarium. The advantages of brachytherapy include a favourable side-effect profile and a shorter duration of treatment, while delivering a dose of radiation similar to that of conventional radiotherapy. Further studies are necessary to define the role of brachytherapy in sinonasal melanoma.

## References

1. Iversen K, Robins RE. Mucosal malignant melanomas. *Am J Surg*. 1980;139(5):660-664. <http://www.ncbi.nlm.nih.gov/pubmed/7468915>. Accessed July 19, 2017.
2. Freedman HM, DeSanto LW, Devine KD, Weiland LH. Malignant melanoma of the nasal cavity and paranasal sinuses. *Arch Otolaryngol*. 1973;97(4):322-325. <http://www.ncbi.nlm.nih.gov/pubmed/4699540>. Accessed July 19, 2017.
3. Manolidis S, Donald PJ. Malignant mucosal melanoma of the head and neck: review of the literature and report of 14 patients. *Cancer*. 1997;80(8):1373-1386. <http://www.ncbi.nlm.nih.gov/pubmed/9338460>. Accessed July 19, 2017.
4. Chiu NT, Weinstock MA. Melanoma of oronasal mucosa. Population-based analysis of occurrence and mortality. *Arch Otolaryngol Head Neck Surg*. 1996;122(9):985-988. <http://www.ncbi.nlm.nih.gov/pubmed/8797564>. Accessed July 19, 2017.
5. Chang AE, Karnell LH, Menck HR. The National Cancer Data Base report on cutaneous and noncutaneous melanoma: a summary of 84,836 cases from the past decade. The American College of Surgeons Commission on Cancer and the American Cancer Society. *Cancer*. 1998;83(8):1664-1678. <http://www.ncbi.nlm.nih.gov/pubmed/9781962>. Accessed July 19, 2017.
6. Kingdom TT, Kaplan MJ. Mucosal melanoma of the nasal cavity and paranasal sinuses. *Head Neck*. 17(3):184-189. <http://www.ncbi.nlm.nih.gov/pubmed/7782202>. Accessed July 19, 2017.
7. Dauer EH, Lewis JE, Rohlinger AL, Weaver AL, Olsen KD. Sinonasal melanoma: A clinicopathologic review of 61 cases. *Otolaryngol Neck Surg*. 2008;138(3):347-352. doi:10.1016/j.otohns.2007.12.013
8. Gilain L, Houette A, Montalban A, Mom T, Saroul N. Mucosal melanoma of the nasal cavity and paranasal sinuses. *Eur Ann Otorhinolaryngol Head Neck Dis*. 2014;131(6):365-369. doi:10.1016/j.anorl.2013.11.004
9. Kardon DE, Thompson LDR. Sinonasal mucosal malignant melanoma: Report of an unusual case mimicking schwannoma. *Ann Diagn Pathol*. 2000;4(5):303-307. doi:10.1053/adpa.2000.17888
10. Miettinen M. Sinonasal Tract and Nasopharyngeal Melanomas Staging System. *Am J Surgery*. 2003;27(5):594-611.
11. Clifton N, Harrison L, Bradley PJ, Jones NS. Malignant melanoma of nasal cavity and paranasal sinuses: report of 24 patients and literature review. *J Laryngol Otol*. 2011;125(5):479-485. doi:10.1017/S0022215110002720
12. Koch SE, Lange JR. Amelanotic melanoma: the great masquerader. *J Am Acad Dermatol*. 2000;42(5 Pt 1):731-734. <http://www.ncbi.nlm.nih.gov/pubmed/10775846>. Accessed July 19, 2017.
13. Liversedge RL. Oral malignant melanoma. *Br J Oral Surg*. 1975;13(1):40-55. <http://www.ncbi.nlm.nih.gov/pubmed/1096931>. Accessed July 19, 2017.
14. Goldman S, Glimelius B, Pålman L. Anorectal malignant melanoma in Sweden. Report of 49 patients. *Dis Colon Rectum*. 1990;33(10):874-877. <http://www.ncbi.nlm.nih.gov/pubmed/1698595>. Accessed July 19, 2017.

15. About the Cancer Statistics Review - SEER Publications.  
<https://seer.cancer.gov/publications/csr.html>. Accessed July 19, 2017.
16. Goldman JL, Lawson W, Zak FG, Roffman JD. THE PRESENCE OF MELANOCYTES IN THE HUMAN LARYNX. *Laryngoscope*. 1972;82(5):824-835. doi:10.1288/00005537-197205000-00009
17. Manganaro AM, Hammond HL, Dalton MJ, Williams TP. Oral melanoma: case reports and review of the literature. *Oral Surg Oral Med Oral Pathol Oral Radiol Endod*. 1995;80(6):670-676.  
<http://www.ncbi.nlm.nih.gov/pubmed/8680974>. Accessed July 19, 2017.
18. Sari UÖ, Isma\_\_ , Yilmaz I, et al. BRAF, NRAS, KIT, TERT, GNAQ/GNA11 mutation profile analysis of head and neck mucosal melanomas: a study of 42 cases. 2016:1-7.  
doi:10.1016/j.pathol.2016.09.065
19. Holmstrom M, Lund VJ. Malignant melanomas of the nasal cavity after occupational exposure to formaldehyde. 1991:10-13.
20. Garzino-Demo P, Fasolis M, Maggiore GMLT, Pagano M, Berrone S. Oral mucosal melanoma: a series of case reports. *J Cranio-Maxillofacial Surg*. 2004;32(4):251-257.  
doi:10.1016/j.jcms.2003.12.007
21. Lund VJ, Howard DJ, Harding L, Wei WI. Management options and survival in malignant melanoma of the sinonasal mucosa. *Laryngoscope*. 1999;109(2 Pt 1):208-211.  
doi:10.1097/00005537-199902000-00007
22. Jethanamest D, Vila PM, Sikora AG, Morris LGT. Predictors of survival in mucosal melanoma of the head and neck. *Ann Surg Oncol*. 2011;18(10):2748-2756. doi:10.1245/s10434-011-1685-4
23. Konuthula N, Khan MN, Parasher A, et al. The presentation and outcomes of mucosal melanoma in 695 patients. *Int Forum Allergy Rhinol*. 2016;7(1):99-105. doi:10.1002/alr.21831
24. García Teno M, Ariza Toledo MA, Sánchez Legaza E, Báez JM, Sierra Galera G, Oliva Domínguez M. [Epithelioid amelanotic melanoma of the nose and paranasal sinuses]. *An Otorrinolaringol Ibero Am*. 1999;26(4):393-400. <http://www.ncbi.nlm.nih.gov/pubmed/10520279>. Accessed July 19, 2017.
25. Enée V, Houliat T, Truilhé Y, Darrouzet V, Stoll D. [Malignant melanoma of the nasosinal mucosa. Retrospective study apropos of 20 cases]. *Rev Laryngol Otol Rhinol (Bord)*. 2000;121(4):243-250.  
<http://www.ncbi.nlm.nih.gov/pubmed/11233707>. Accessed July 19, 2017.
26. Mané J, Stoll D, Delaunay MM, Traissac L. [Melanoma of the ORL mucosa]. *Rev Laryngol Otol Rhinol (Bord)*. 1992;113(3):179-183. <http://www.ncbi.nlm.nih.gov/pubmed/1344532>. Accessed July 19, 2017.
27. Loree TR, Mullins AP, Spellman J, North JH, Hicks WL. Head and neck mucosal melanoma: a 32-year review. *Ear Nose Throat J*. 1999;78(5):372-375.  
<http://www.ncbi.nlm.nih.gov/pubmed/10355199>. Accessed July 19, 2017.
28. Vinel V, Dehesdin D, Marie JP. [Melanoma of the nasal fossae and sinuses, apropos of a series of 7 cases]. *Rev Laryngol Otol Rhinol (Bord)*. 1990;111(1):61-65.  
<http://www.ncbi.nlm.nih.gov/pubmed/2130402>. Accessed July 19, 2017.
29. Ballantyne AJ. Malignant melanoma of the skin of the head and neck. An analysis of 405 cases.

- Am J Surg.* 1970;120(4):425-431. <http://www.ncbi.nlm.nih.gov/pubmed/5507326>. Accessed July 19, 2017.
30. Prasad ML, Patel SG, Huvos AG, Shah JP, Busam KJ. Primary mucosal melanoma of the head and neck. *Cancer.* 2004;100(8):1657-1664. doi:10.1002/cncr.20201
  31. Shuman AG, Light E, Olsen SH, et al. Mucosal Melanoma of the Head and Neck. *Arch Otolaryngol Neck Surg.* 2011;137(4):331. doi:10.1001/archoto.2011.46
  32. Patel S SJ. Part 2, Head and neck sites. In: Edge SB, Byrd DR, Carducci MA, Compton CA, eds. *AJCC Cancer Staging Man.* 2009;7th edn(New York: Springer).
  33. Houette A, Gilain L, Mulliez A, Mom T, Saroul N. Prognostic value of two tumour staging classifications in patients with sinonasal mucosal melanoma. *Eur Ann Otorhinolaryngol Head Neck Dis.* 2016;133(5):313-317. doi:10.1016/j.anorl.2016.05.008
  34. Fernando Lopez, MD, PhD, 1, 2, Juan P. Rodrigo, MD, PhD, 1, 2 Antonio Cardesa, MD, PhD, 3 Asterios Triantafyllou, FRCPath, PhD 4, Kenneth O. Devaney, MD, JD, 5 William M. Mendenhall, MD, 6 Missak Haigentz Jr, MD, 7 Primož Strojjan, MD, PhD 8, et al. Update on primary head and neck mucosal melanoma. *Head Neck.* 2016;38:147–155.
  35. Benlyazid A, Thariat J, Al E. Postoperative Radiotherapy in Head and Neck Mucosal Melanoma. *Arch Otolaryngol Head Neck Surg.* 2014;136(12):1219-1225.
  36. Lazarev S, Gupta V, Hu K, Harrison LB, Bakst R. Mucosal melanoma of the head and neck: A systematic review of the literature. *Int J Radiat Oncol Biol Phys.* 2014;90(5):1108-1118. doi:10.1016/j.ijrobp.2014.03.042
  37. Krengli M, Masini L, Kaanders JHAM, et al. Radiotherapy in the treatment of mucosal melanoma of the upper aerodigestive tract: Analysis of 74 cases. A Rare Cancer Network study. *Int J Radiat Oncol Biol Phys.* 2006;65(3):751-759. doi:10.1016/j.ijrobp.2006.01.016
  38. Bossi P, Saba NF, Vermorken JB, et al. The role of systemic therapy in the management of sinonasal cancer: A critical review. *Cancer Treat Rev.* 2015;41(10):836-843. doi:10.1016/j.ctrv.2015.07.004
  39. Cheng Y-F, Lai C-C, Ho C-Y, Shu C-H, Lin C-Z. Toward a Better Understanding of Sinonasal Mucosal Melanoma: Clinical Review of 23 Cases. *J Chinese Med Assoc.* 2007;70(1):24-29. doi:10.1016/S1726-4901(09)70296-5
  40. Gore MR, Zanation AM. Survival in sinonasal melanoma: A meta-analysis. *J Neurol Surgery, Part B Skull Base.* 2012;73(3):157-162. doi:10.1055/s-0032-1301400
  41. Harris T, Stannard C, Lubbe D. Endoscopic Resection and Postoperative Brachytherapy in the Treatment of Sinonasal Melanoma. *J Case Reports Med.* 2014;3:1-3. doi:10.4303/jcrm/235844
  42. Shibuya H. Current status and perspectives of brachytherapy for head and neck cancer. *Int J Clin Oncol.* 2009;14(1):2-6. doi:10.1007/s10147-008-0859-y
  43. Yamazaki H, Yoshida K, Yoshioka Y, et al. High dose rate brachytherapy for oral cancer. *J Radiat Res.* 2013;54(1):1-17. doi:10.1093/jrr/rrs103
  44. Wierzbicka M, Bartochowska A, Strnad V, et al. The role of brachytherapy in the treatment of squamous cell carcinoma of the head and neck. *Eur Arch Oto-Rhino-Laryngology.*

2016;273(2):269-276. doi:10.1007/s00405-014-3332-8

45. Stannard CE, Hering E, Hough J, Knowles R, Munro R, Hille J. Post-operative treatment of malignant salivary gland tumours of the palate with iodine-125 brachytherapy. *Radiother Oncol*. 2004;73(3):307-311. doi:10.1016/j.radonc.2004.09.001
46. Stannard C, Maree G, Tovey S, Hunter A, Wetter J. Iodine-125 brachytherapy in the management of squamous cell carcinoma of the oral cavity and oropharynx. *Brachytherapy*. 2014;13(4):405-412. doi:10.1016/j.brachy.2014.02.443
47. Kadah B Al, Niewald M, Papaspyrou G, Dzierma Y, Schneider M, Schick B. Customized individual applicators for endocavitary brachytherapy in patients with cancers of the nasal cavity, sinonasal region and nasopharynx. *Eur Arch Oto-Rhino-Laryngology*. 2016;273(6):1543-1547. doi:10.1007/s00405-015-3636-3
48. Nikolaos Tselis, MD, PhD, 1\* Efstratios Karagiannis, MD, 2 Christos Kolotas, MD, PhD, 3 Mehran Baghi, MD, PhD, 4 Natasa Milickovic, PhD 5, Nikolaos Zamboglou, MD P. Image-guided interstitial high-dose-rate brachytherapy in the treatment of inoperable recurrent head and neck malignancies: An effective option of reirradiation. *Wiley Online Libr*. 2017;Head Neck(39):E61-E86. wileyonlinelibrary.com.
49. Prasad ML, Patel S, Hoshaw-Woodard S, et al. Prognostic factors for malignant melanoma of the squamous mucosa of the head and neck. *Am J Surg Pathol*. 2002;26(7):883-892. <http://www.ncbi.nlm.nih.gov/pubmed/12131155>. Accessed July 19, 2017.
50. Lee SP, Shimizu KT, Tran LM, Juillard G, Calcaterra TC. Mucosal melanoma of the head and neck: the impact of local control on survival. *Laryngoscope*. 1994;104(2):121-126. doi:10.1288/00005537-199402000-00001
51. Penel N, Mallet Y, Mirabel X, Van JT, Lefebvre J-L. Primary mucosal melanoma of head and neck: prognostic value of clear margins. *Laryngoscope*. 2006;116(6):993-995. doi:10.1097/01.mlg.0000217236.06585.a9
52. Meleti M, Leemans CR, de Bree R, Vescovi P, Sesenna E, van der Waal I. Head and neck mucosal melanoma: Experience with 42 patients, with emphasis on the role of postoperative radiotherapy. *Head Neck*. 2008;30(12):1543-1551. doi:10.1002/hed.20901
53. Bachar G, Loh KS, O'Sullivan B, et al. Mucosal melanomas of the head and neck: The Princess Margaret Hospital experience. *Head Neck*. 2008;30(10):1325-1331. doi:10.1002/hed.20878
54. Nakashima JP, Vi&eacute;gas CM, Fassizoli AL, et al. Postoperative Adjuvant Radiation Therapy in the Treatment of Primary Head and Neck Mucosal Melanomas. *ORL*. 2008;70(6):344-351. doi:10.1159/000163029
55. Owens JM, Roberts DB, Myers JN. The Role of Postoperative Adjuvant Radiation Therapy in the Treatment of Mucosal Melanomas of the Head and Neck Region. *Arch Otolaryngol Neck Surg*. 2003;129(8):864. doi:10.1001/archotol.129.8.864
56. Temam S, Mamelle G, Marandas P, et al. Postoperative radiotherapy for primary mucosal melanoma of the head and neck. *Cancer*. 2005;103(2):313-319. doi:10.1002/cncr.20775

57. Kim D-K, Kim DW, Kim SW, Kim D-Y, Lee CH, Rhee C-S. Ki67 antigen as a predictive factor for prognosis of sinonasal mucosal melanoma. *Clin Exp Otorhinolaryngol*. 2008;1(4):206-210. doi:10.3342/ceo.2008.1.4.206
58. Sullivan R, LoRusso P, Boerner S, Dummer R. Achievements and Challenges of Molecular Targeted Therapy in Melanoma. *Am Soc Clin Oncol Educ B*. 2015;35:177-186. doi:10.14694/EdBook\_AM.2015.35.177
59. Cohen Y, Rosenbaum E, Begum S, et al. Exon 15 BRAF Mutations Are Uncommon in Melanomas Arising in Nonsun-Exposed Sites. *Clin Cancer Res*. 2004;10(10):3444-3447. doi:10.1158/1078-0432.CCR-03-0562
60. Beadling C, Jacobson-Dunlop E, Hodi FS, et al. KIT Gene Mutations and Copy Number in Melanoma Subtypes. *Clin Cancer Res*. 2008;14(21):6821-6828. doi:10.1158/1078-0432.CCR-08-0575
61. Carvajal RD, Antonescu CR, Wolchok JD, et al. KIT as a Therapeutic Target in Metastatic Melanoma. *JAMA*. 2011;305(22):2327. doi:10.1001/jama.2011.746
62. Schoenewolf NL, Bull C, Belloni B, et al. Sinonasal, genital and acrolentiginous melanomas show distinct characteristics of KIT expression and mutations. *Eur J Cancer*. 2012;48(12):1842-1852. doi:10.1016/j.ejca.2012.02.049
63. Turri-Zanoni M, Medicina D, Lombardi D, et al. Sinonasal mucosal melanoma: Molecular profile and therapeutic implications from a series of 32 cases. *Head Neck*. 2013;35(8):1066-1077. doi:10.1002/hed.23079
64. Hu-Lieskovan S, Robert L, Moreno BH, Ribas A. Combining targeted therapy with immunotherapy in BRAF-mutant melanoma: Promise and challenges. *J Clin Oncol*. 2014;32(21):2248-2254. doi:10.1200/JCO.2013.52.1377
65. Philipp M, Frischhut N, Tschachler A, et al. Pseudoprogression with subsequent complete response and severe thrombocytopenia to checkpoint inhibitor immunotherapy in a patient with advanced mucosal melanoma of the sinonasal cavity. *Anticancer Drugs*. 2018;29(9):914-918. doi:10.1097/CAD.0000000000000664
66. D'Angelo SP, Larkin J, Sosman JA, et al. Efficacy and safety of nivolumab alone or in combination with ipilimumab in patients with mucosal melanoma: A pooled analysis. *J Clin Oncol*. 2017;35(2):226-235. doi:10.1200/JCO.2016.67.9258