

## Surgical management of stress incontinence in women: The role of the family practitioner

G Rienhardt MBChB, BSc (Hons), M. Med (O&G), FCOG (SA) & P De Jong MBChB, M.Med (O&G), FCOG (SA), FRCOG.

To cite this article: G Rienhardt MBChB, BSc (Hons), M. Med (O&G), FCOG (SA) & P De Jong MBChB, M.Med (O&G), FCOG (SA), FRCOG. (2005) Surgical management of stress incontinence in women: The role of the family practitioner, South African Family Practice, 47:1, 31-37, DOI: 10.1080/20786204.2005.10873168

To link to this article: <http://dx.doi.org/10.1080/20786204.2005.10873168>



© 2005 SAAFP. Published by Medpharm.



Published online: 15 Aug 2014.



Submit your article to this journal [↗](#)



Article views: 19



View related articles [↗](#)

# Surgical management of stress incontinence in women: The role of the family practitioner

## Part 2: Surgical procedures and their sequelae

**Rienhardt G**, MBChB, BSc (Hons), M.Med (O&G), FCOG (SA)  
Consultant, Urogynaecology Unit, University of Stellenbosch and Tygerberg Hospital.

**De Jong P**, MBChB, M.Med (O&G), FCOG (SA), FRCOG.  
Consultant, Female Continence Clinic, University of Cape Town and Groote Schuur Hospital, and Christiaan Barnard Memorial Hospital, Cape Town.

Reprint requests to: Dr G Rienhardt, P O Box 19072, Tygerberg, 7505

**Keywords:** Genuine stress incontinence, Surgery.

### Abstract

The surgical management of stress incontinence in women should encompass a combined approach by the family practitioner and the specialist. This review, in two parts, discusses the place of the family practitioner in this process. The continence mechanism, pre-operative counselling, appropriate surgical procedures, post-operative complications and aftercare are all discussed, to enable the family practitioner to provide adequate support to the patient. (*SA Fam Pract 2005;47(1): 31-37*)

### INTRODUCTION

In part 1 we emphasized the importance of the thorough clinical evaluation of a female patient with genuine stress incontinence by the family practitioner before specialist referral.

The anatomy of the continence mechanism was discussed, as well as points pertaining to the evaluation of the patient. Some common fallacies were dispelled and pre-referral responsibilities of the practitioner were outlined.

We now move on to the specific procedures which a specialist might perform, and their consequences for the patient.

Obviously the specialist chooses the procedure best suited to the patient's problem, but it is most important that the family practitioner has a basic knowledge of the common surgeries for GSI so that a patient's questions can be answered. Patients are often overawed by the specialist's discussion of the procedure with them and fail to register the details. Ideally, an information leaflet should be provided, but this is often not the case. Table I summarizes the points which

are integral to pre-operative counselling.

**Table I:** Pre-operative counselling

1. How the procedure is performed
2. Success rate
3. Complications: Short and long term
4. The immediate post-operative (hospital) phase

The main surgical procedures will now be discussed (see Table 2 for summary) and their success rates mentioned. Finally, counselling of the pre-operative patient will be explained.

### A. REDUNDANT PROCEDURES

- **ANTERIOR COLPORRHAPHY / ANTERIOR VAGINAL REPAIR**

**Table II:** Surgical procedures for GSI

Classification	Procedure
A. Redundant Procedures	Anterior colporrhaphy Needle suspension
B. Current Procedures	Colposuspension Suburethral sling
C. Procedures for special indications	Pubovaginal sling Bulking agents Artificial sphincter

This procedure, dating from the beginning of the last century, was used until recently by mainly the mature generation surgeons to correct both cystoceles and GSI. A stitch high up under the urethra, called the Kelly plication, elevated the bladder neck to produce continence. In this era of evidence – based medicine, anterior colporrhaphy has been shown in a number of trials to have only a transient effect on continence<sup>1</sup>. This effect lasts for months rather than years. The procedure should therefore no longer be performed for GSI, but it does still have an important place in the management of anterior vaginal wall prolapse i.e. cystocele. The operation is not discussed any further here.

### • NEEDLE BLADDER NECK SUSPENSION

This procedure, which was developed over 40 years ago, attempts to stabilise the bladder neck by suspending the vaginal tissue on both sides of it, from the rectus fascia of the anterior abdominal wall.

There have been numerous modifications of the technique and they go by the names of Pereyra, Raz and Stamey, to name the most popular.

These procedures all employ the same principle:

Two 2cm vertical incisions are made on either side of the bladder neck in the anterior vaginal wall and

a tunnel under the pubic ramus, into the space of Retzius, is created. A "purse string" nylon suture is inserted on the inside in the vaginal tissue around the incisions. Two 1cm skin incisions are then made suprapubically on the anterior abdominal wall.

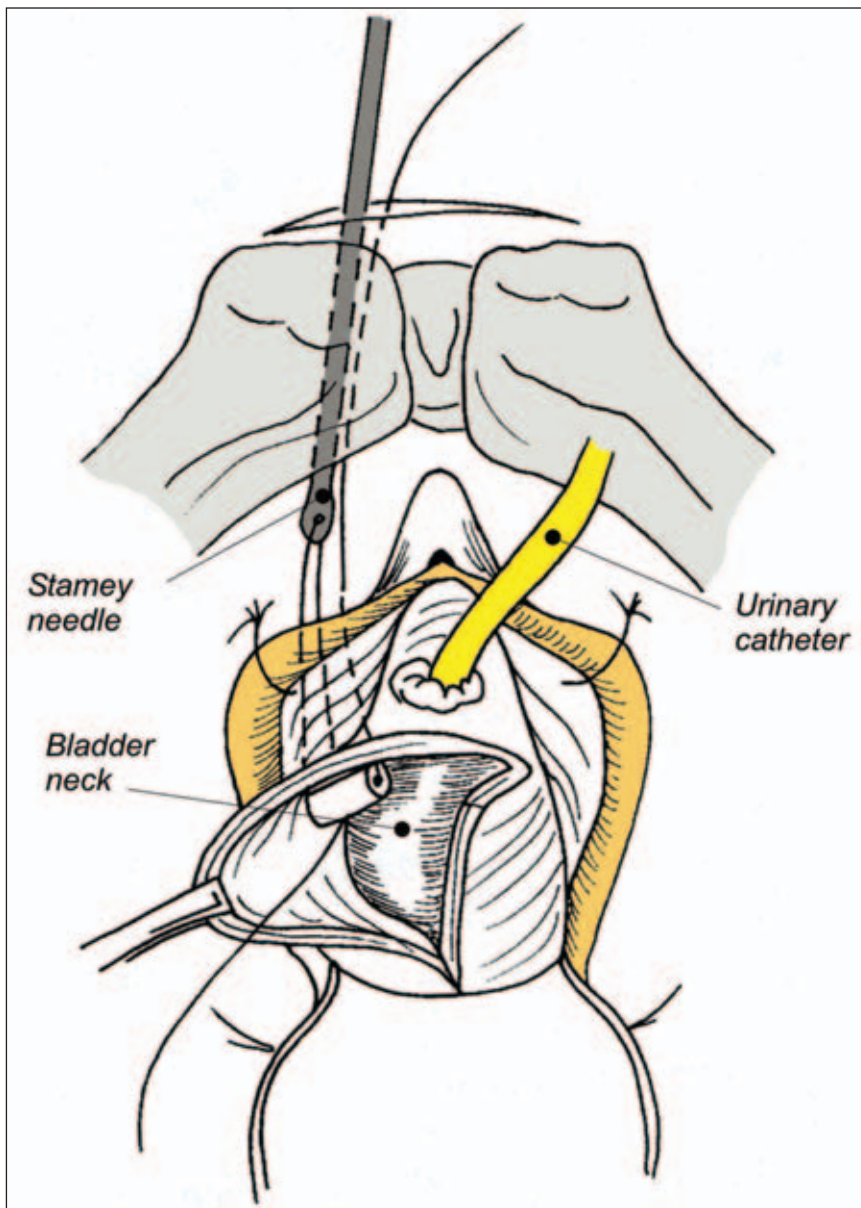
A needle (similar to a knitting needle), with an eye at one end, is pushed downwards from the suprapubic incision, behind the symphysis pubis, through the vaginal incision. With two needle passes on either side of the suprapubic incision, the two ends of the nylon suture are transferred to the anterior abdominal wall and tied over the rectus sheath.

The process is repeated on the contralateral side. Elevation is obtained on tying the sutures, and the incisions are closed. Instead of a "purse string" suture, a silastic bib can also be used to provide bladder neck elevation. (Figure 1)

Success rate: The shortcomings of this procedure are that the sutures can break, or the vaginal end of the suture can 'cheese-wire' through the tissue. This occurs mainly in patients who are still active. The success rate has been reported as poor, with a continence rate of 6-10% at 10 years<sup>2</sup>.

The procedure should therefore be reserved for the older, frail, inactive patient.

Figure 1: Schematic representation of a needle suspension procedure.



(Source: G Rienhardt. Disorders of the Urinary Tract. Clinical Gynaecology. H J Odendaal et al 2001. With permission from Juta's.)

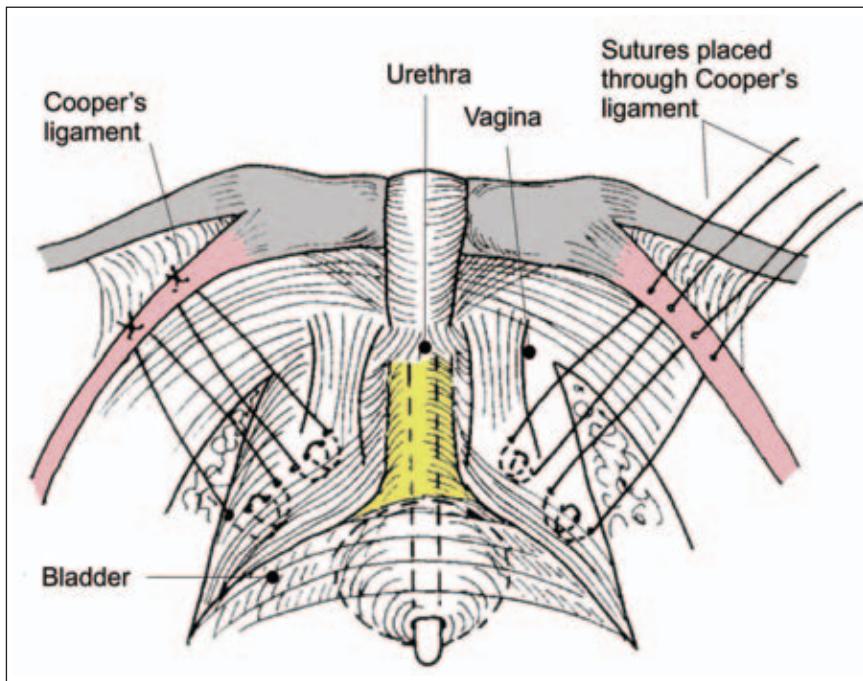
### B. CURRENT PROCEDURES

#### • (BURCH) COLPOSUSPENSION

The colposuspension originated in 1960 and has developed into the gold standard for surgery for GSI because of its analysis by research and its track record of durability. It is still widely popular, despite an onslaught on its credentials by the less invasive suburethral slings.

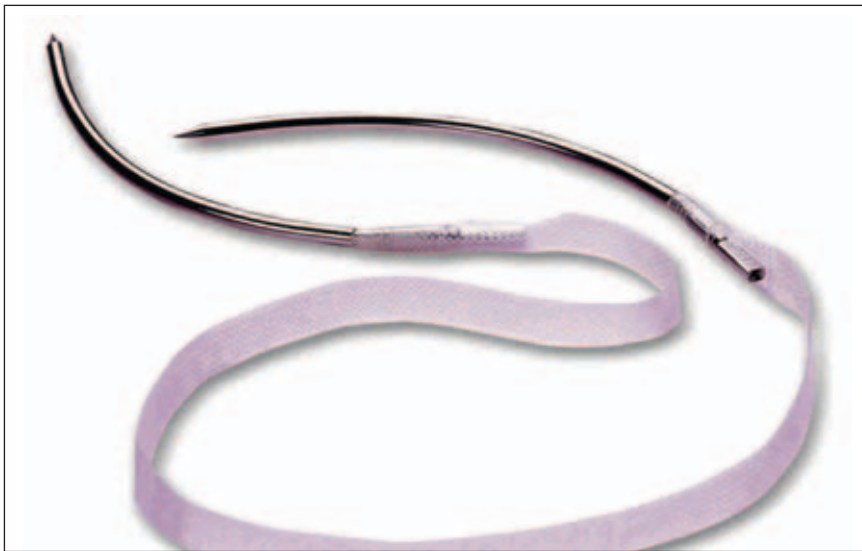Through a short, directly suprapubic transverse incision, the space of Retzius (or prevesical space) is entered. This is an entirely extraperitoneal approach and the pelvis is not entered. Through blunt dissection with the surgeon's fingers, the space is developed and the bladder neck identified. The bladder itself is mobilised medially in this region through gentle traction, and the underlying vaginal fascia exposed. Two permanent sutures are placed on each side, on either side of the bladder neck, into this fascia. They are anchored in Cooper's ligament (the iliopectineal ligament) which runs on the inside top edge of the superior pubic ramus. (Figure 2) Knotting the sutures elevates the bladder neck and places it behind the symphysis pubis, against which it is compressed with raised intra-abdominal pressure. A drain is frequently placed in the operation area, and a suprapubic bladder catheter inserted, before closure of the wound. The procedure takes about 30 – 45 minutes to complete. Catheter clamping, to check on bladder function, takes place

**Figure 2:** Schematic representation of the space of Retzius at Burch colposuspension.



(Source: G Rienhardt. Disorders of the Urinary Tract. Clinical Gynaecology. H J Odendaal et al 2001. With permission from Juta's.)

**Figure 3:** A photograph depicting the kit used for suburethral sling placement, in this case a TVT.



(Photograph courtesy of Gynecare/ Johnson & Johnson)

from day 3 (by which time the drain has been removed) and the patient normally goes home by day 4 or 5. Alternatively, a transurethral catheter is inserted and kept for two days. If residual urine volumes at this stage are still high, the patient can be taught clean intermittent self-catheterisation and discharged.

A variant of this procedure is the one performed laparoscopically. The principles are similar, but because of

minimal access used, the patient can go home the day after surgery. This kind of laparoscopic surgery is, however, limited to those surgeons with additional training and special skills.

Colposuspension has a short-term success rate of 85-90%<sup>3</sup> with success at 15-20 years being in the order of 70%<sup>4</sup>. Because of its inherent obstructive nature, the procedure may lead to longer-term voiding dysfunction

(12.5%)<sup>3</sup> detrusor instability (9.6%)<sup>3</sup> and also genital prolapse (14%),<sup>5</sup> the latter because of a realignment of the vaginal axis.

Colposuspension remains a tried and tested option and skilled surgeons use small incisions, meticulous technique and limited elevation of the bladder neck to shorten hospital stay markedly, and reduce complications.

#### • SUBURETHRAL SLINGS

The advent of this procedure, using a minimally invasive technique, has been a great advance in surgery for GSI. Accumulating scientific evidence will probably lead to this option becoming the 'gold standard' in the near future.

The concept of placing a synthetic (polypropylene, or prolene) sling around the mid-urethra in a tension-free way, was proposed about 10 years ago. The underlying philosophy was to provide midurethral support where the urethral closure pressure was greatest.

A recent publication<sup>6</sup> discusses in some detail the four sling types available in SA at present. The operative principle is the same but the sling material does vary between manufacturers. Placement of the sling is mainly via the vagina (discussed below), but can also be from a suprapubic approach.

The midurethra is identified and a 1cm vertical incision is made over it in the anterior vaginal wall, with some minor dissection. The device comes as a kit (See Figure 3) and consists of a 40cm sling with a curved steel needle attached at each end. The needles are inserted on both sides of the urethra, under the inferior pubic ramus, and upwards, laterally to the pubic symphysis, to appear directly suprapubically about 5cm apart. After each needle placement, cystoscopy is performed to check on potential bladder perforation. The needles are then pulled through and cut off, leaving the tape in situ. The tape is finally positioned and the important tension adjustment made before the redundant tape is trimmed suprapubically. The tape is not sutured, but relies on the 'velcro effect' of the material and fibroblast ingrowth within 48 hours to stabilise it. The incision is closed and the patient can go home later that afternoon, if performed under local

anaesthesia, or otherwise the following morning, after normal voiding has occurred. The suburethral sling has a wide scope for use, but its indication for repeat surgery and the pipestem urethra needs further evaluation.

Short-term cure rates have been reported to be in excess of 90% with a recent 7-year follow up study<sup>7</sup> showing a 80% subjective and objective cure rate.

A large number of these procedures have been performed in South Africa to date and an awareness of complications<sup>8</sup> is essential.

Intra-operative complications include bladder perforation (5%), which is managed conservatively by the surgeon and is inconsequential. Significant bleeding, resulting from major vascular injury, is rare but can occur and can be life-threatening. Bowel injuries have also been reported.

Post-operative problems include voiding dysfunction, (5%), resulting from the sling being placed too tightly, recurrent urinary tract infections (11%) and overactive bladder symptoms requiring anticholinergic therapy (12%). The use of a mesh prosthesis leads to unique complications: tape erosion and infection occur in fewer than 1% of cases. This complication may require re-operation of the patient.

New products are appearing on the market, claiming to be safer without compromising efficacy. One such option is a tape, which is placed through the obturator foramina, thus avoiding the retropubic space and its associated vasculature. Its final role has yet to be determined.

There are clear advantages to suburethral slings, namely a minimally – invasive technique, a short hospital stay, and a rapid return to mobility. On the other hand, the slings are expensive and morbid intra- and post operative complications can occur in inexperienced hands.

A recent prospective, randomised trial compares TVT (a suburethral sling variant, manufactured by Gynecare) to colposuspension and at 2-year follow-up<sup>9</sup> has confirmed equivocal efficacy and a significantly high rate of re-operation for prolapse (mainly posterior vaginal compartment) after colposuspension. Five year follow up results of this trial are awaited.

### C. PROCEDURES FOR SPECIAL INDICATIONS

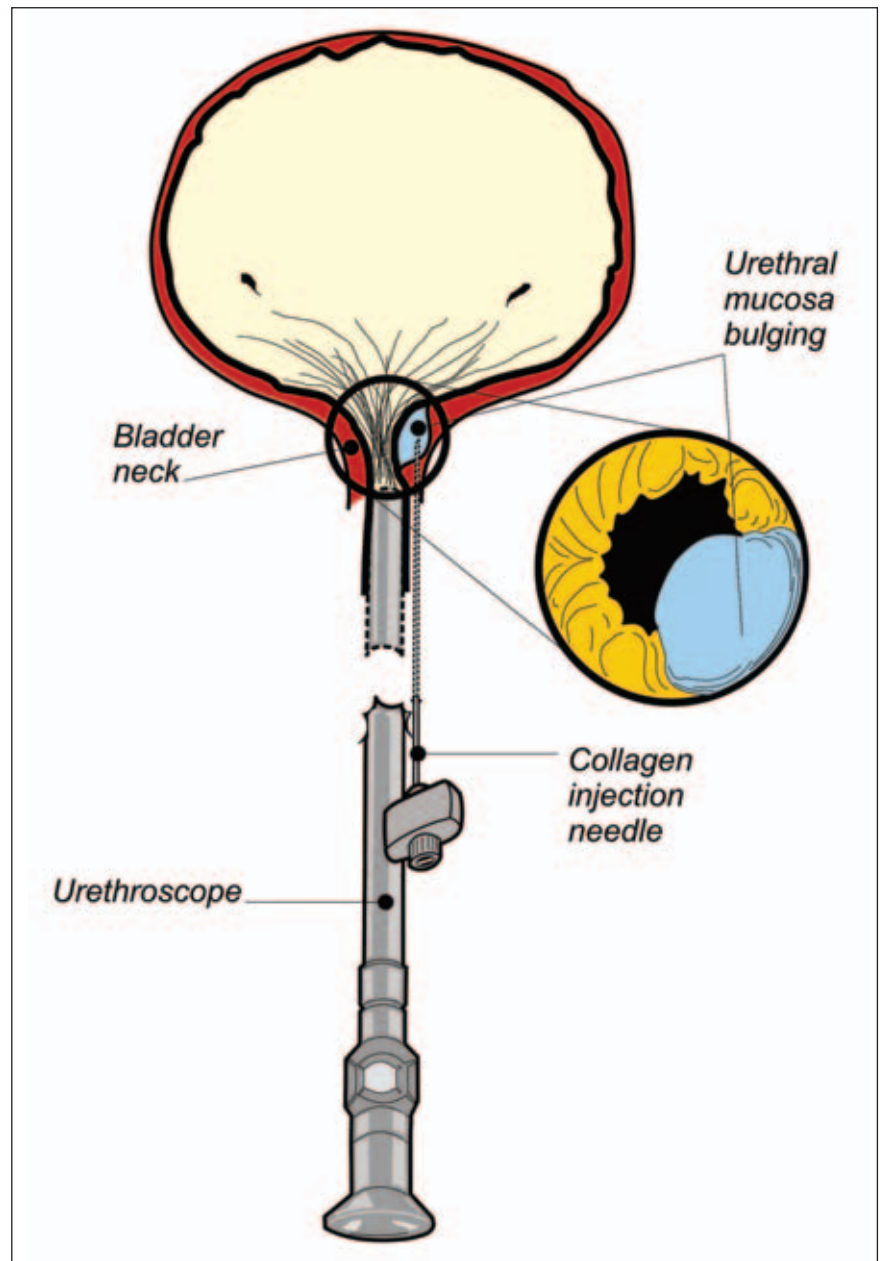
As these procedures are far less common, they are not discussed in any detail. Practitioners should be aware of these, however.

#### • URETHRAL BULKING AGENTS

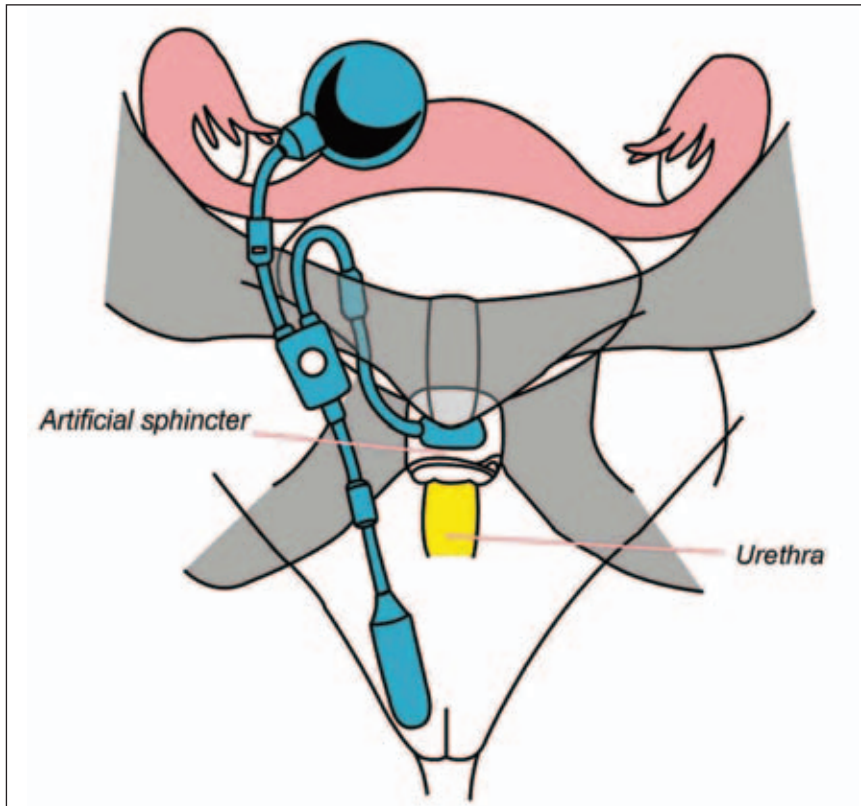
Bulking agents are an expensive, minimally invasive option for patients who are too frail for more comprehensive surgery, for patients with intrinsic sphincter dysfunction, and for those who require surgery but have not yet completed their families.

It involves injecting a bulking agent – be it purified bovine collagen or silicone – into the area around the bladder neck, using a cystoscope, or extraurethrally, with a spinal-type needle. The injected substance ‘bulks up’ the area around the bladder neck and occludes the opening into the urethra. (Figure 4) The procedure is expensive, relatively easy to perform with few complications, can be repeated regularly under local anaesthesia. However, with present technology, it is not very successful. The objective cure rate after 2 years is 50%<sup>10</sup>. The search continues for safer, new materials which last longer.

Figure 4: Collagen being injected at the bladder neck under cystoscopic control.



**Figure 5:** An artificial urinary sphincter, placed around the urethra just distal to the bladder neck, shown schematically.



**Table III:** Specific complications of surgery for genuine stress incontinence

Intra-operative	Immediately post-operative
Haemorrhage	Urinary tract infection
Bladder perforation	Haematoma formation
Nerve injury	Wound infection
Bowel perforation	Urinary retention

#### • PUBOVAGINAL SLINGS

These are the forerunners of the modern suburethral sling. They are extensive, morbid procedures, with a high success rate but some serious potential complications.

The technique involves either a suprapubic, or a combined suprapubic – vaginal approach. A strip of suspensory material – either autologous (the patient's own rectus sheath or fascia lata), heterologous (cadaver donor dura mater) or synthetic (silastic) – is used to suspend the bladder neck. The bladder is often opened to identify the bladder neck accurately, and the sling has to be placed around the bladder neck. The tension of this sling needs to be optimal, otherwise the patient will have voiding difficulty at best, or retention at worst. The latter could mean

permanent self catheterisation. The sling can erode, if it is synthetic, or fail if it is the patient's own tissue.

As this procedure is usually reserved for repeat surgery and patients with intrinsic sphincter deficiency, the surgical dissection can be quite difficult.

The success rate of primary surgery is 94% and for secondary surgery 86%.<sup>3</sup>

#### • ARTIFICIAL URINARY SPHINCTER

Implantation of such a device is a technically difficult procedure reserved for women with severe stress incontinence and numerous previous failed attempts at surgical cure. It is rarely performed and very expensive.

It involves an inflatable cuff being placed around the proximal urethra,

during laparotomy. A reservoir – which can inflate the cuff – is placed in the pelvis, and a pump is inserted into one of the labia majora. (Figure 5). By manipulating the labial pump, the patient can inflate (causing temporary obstruction) or empty the cuff and thus regulate voiding and continence.

Apart from equipment failure, other problems include infection and erosion. Obviously, if the device works well, the success rate is 100%.

#### COUNSELLING AND AFTERCARE

Although this is a most important duty of the surgeon, the family practitioner must be knowledgeable about potential intra-operative and immediate post-operative complications. These are summarised in Table 3.

These are in addition to general complications which can be sequelae of any gynaecological surgery.<sup>11</sup>

The family practitioner must also be aware of specific medium to long term problems associated with incontinence surgery so that the patient may be counselled about these sequelae. Also, the family practitioner is often the first professional to be confronted, should these complications occur, so he/she must be aware of them.

Although most of these complications apply to all the procedures mentioned, we will discuss in more detail only those pertaining to colposuspension and suburethral slings.

#### • Voiding dysfunction

Most incontinence procedures are obstructive. It takes the detrusor some days to 'settle down' after colposuspension and to overcome the partial obstruction. The patients will be subjected to catheter drill in hospital for most procedures, excluding suburethral slings. This involves repeated clamping of the suprapubic catheter which has been inserted at operation, in order to measure the volume of urine voided in the normal way, and the measurement of the residual urine until satisfactory (generally volumes less than 100ml). It is then removed.

Suprapubic catheters can be left in for up to 6 weeks if problems persist.

Thereafter patients should be taught clean intermittent self-catheterisation. Voiding dysfunction after placement of a suburethral sling should be rare, but can occur, as discussed previously. If such a patient has sustained voiding dysfunction, the sling should be surgically divided.

Long term voiding dysfunction can have serious sequelae, with large urine residuals causing recurrent urinary tract infection and potential upper tract damage.

- **Overactive bladder (OAB) symptoms**

About 10% of patients develop de novo instability following colposuspension. This is best treated with anticholinergic medication if it does not settle within 3 months. If it is severe and compromises quality of life significantly, as in an absolute minority, the patient should be offered a "take-down" procedure i.e. re-operation is performed and the stitches are cut. This also is an option for patients still in retention more than 6 weeks following colposuspension - a rare event. Patients who have had a suburethral sling procedure may also experience some urgency, best treated medically. A number of these problems can be addressed at the level of family practice by telephonic contact and discussion with the responsible surgeon, prior to re-referral.

If a patient who has a suburethral sling placed, presents with resistant OAB symptoms and microscopic haematuria, the possibility of a mesh erosion into the bladder has to be borne in mind. Under such circumstances the patient must be referred back to the surgeon for confirmatory cystoscopy and mesh removal.

By not tying the sutures too tightly at colposuspension, (which prevents over-elevation of the bladder neck), the surgeon can reduce the incidence of voiding dysfunction and de novo detrusor instability<sup>12</sup>.

- **Prolapse**

As mentioned previously, patients who have had a colposuspension are prone

to developing posterior compartment prolapse. (This is significantly not a problem in patients who have had a suburethral sling inserted). They should be warned that a second procedure may be required to correct prolapse.

- **Infection and erosion**

This complication is particularly relevant to patients who have had synthetic mesh implanted (suburethral sling). Some suburethral slings are more prone to this complication than others, although it remains rare. A mesh erosion would present with a blood-tinged vaginal discharge, sometimes malodorous. On gynaecological examination the erosion is often clearly evident. The surgeon would have to trim the mesh and close the vaginal epithelium. If there is overwhelming local infection, the mesh would have to be removed.

### **Further post-operative counselling would entail the following:**

- **Resumption of physical activity**

A patient should not drive for 3 weeks after a general anaesthetic. After colposuspension, the patient can resume light activity after hospital discharge and full activity (work) after a month. This is to facilitate the formation of fibrosis. After the insertion of a suburethral sling, patients are usually discharged very quickly and can resume full activity within 2 weeks. Patients should be warned that they should avoid heavy lifting for at least 3 months (there is no definite evidence for this, but it makes sense!), preferably for the rest of their lives. They should avoid sexual intercourse for 6 weeks following surgery.

- **Pelvic floor muscle exercises**

These should be taught pre-operatively and be a lifelong responsibility post-operatively.

- **Lifestyle changes**

Patients should discontinue smoking, lose weight and keep any respiratory disease (chronic bronchitis, asthma) under tight control.

## **CONCLUSIONS**

Family practitioners have an important role to play in the identification, pre-referral counselling and post-operative management of patients with genuine stress incontinence.

By being aware of the surgical options available and also the potential complications of the various procedures, the family practitioner can ensure that a fully informed patient has a positive approach to the treatment of this distressing and incapacitating problem.✎

**See CPD Questionnaire, page 38**

## **References**

1. Bergman A, Elia O. Three surgical procedures for genuine stress incontinence: A five year follow-up of a prospective randomised study. *Am J Obstet Gynecol* 1995;173:66-71.
2. Kevelighan E, Aagaard J, Balasubramaniam B, Jarvis G. Stamey endoscopic bladder neck suspension: a 10 year follow-up study. 28<sup>th</sup> Congress of the Royal College of Obstetricians and Gynaecologists. 1998:Abstracts:47.
3. Jarvis GJ. Surgery for genuine stress incontinence. *Br J Obstet Gynaecol* 1994;101:371-374.
4. Alcalay M, Monga A, Stanton S. Burch colposuspension - a 10-20 year follow-up. *Br J Obstet Gynaecol* 1995;81:281-290.
5. Wiskind A, Creighton S, Stanton S. The incidence of genital prolapse after the Burch colposuspension. *Am J Obstet Gynecol* 1992;167:399-405.
6. De Jong P. Stress incontinence in women: new surgical options. *S Afr Med J* 2002;8:43-46.
7. Nilsson CGN, Rezapour M, Falconer C. 7 Years follow-up of the Tension Free Vaginal Tape (TVT) procedure. Abstracts of the 28<sup>th</sup> Annual Meeting of the International Urogynecological Association, October 2003, Buenos Aires, Argentina. S35.
8. Karram MM, Segal JL, Vassallo BJ, Kleeman SD. Complications and untoward effects of the Tension Free Vaginal Tape procedure. *Obstet Gynecol* 2003; 101: 929-932.
9. Ward KL, Hilton P. A randomised trial of Colposuspension and Tension Free Vaginal Tape (TVT) for primary genuine stress incontinence - 2 year follow-up. Abstracts of the 26<sup>th</sup> Annual Meeting of the International Urogynecological Association, December 2001, Melbourne, Australia. S7.
10. Herschorn S, Steele D, Radonski S. Follow-up of intra-urethral collagen for female stress incontinence. *J Urol* 1996;156:1305-1309.
11. Read M, James M. Immediate postoperative complications following gynaecological surgery. *Obstet Gynaecologist* 2002;4:29-35.
12. Bombieri L, Freeman R, Perkins E, Williams M, Shaw S. Why do women have voiding dysfunction and de novo detrusor instability after colposuspension? *Br J Obstet Gynaecol*, 2002; 109: 402-412.

## **Suggested further reading**

1. *Clinical Urogynaecology*. Eds. S Stanton, A Monga. 2<sup>nd</sup> Ed. Churchill Livingstone, London, 2001.
2. *Urogynaecology and Reconstructive Pelvic Surgery*. Eds. M Walters, M Karram. 2<sup>nd</sup> Ed. Mosby Inc, St Louis, 1999.
3. *Female urinary incontinence*. P de Jong, M Brink, A Pontin, G Rienhardt. 2<sup>nd</sup> Ed. UCT Press, Cape Town 2000.