

**EVISCERATION
AND
SYMPATHETIC
OPHTHALMIA:
IS THERE A RISK?**

by

**Nagib du Toit
(DTTNAG001)**

**Submitted to the University of Cape Town
In partial fulfilment of the requirements for the
degree of M Med (Ophthalmology) CHM7031W**

**Faculty of Health Sciences
University of Cape Town**

**Date: 15 August 2006
Supervisor: Prof ADN Murray (Division of
Ophthalmology, U.C.T.)**

The copyright of this thesis vests in the author. No quotation from it or information derived from it is to be published without full acknowledgement of the source. The thesis is to be used for private study or non-commercial research purposes only.

Published by the University of Cape Town (UCT) in terms of the non-exclusive license granted to UCT by the author.

The copyright of this thesis vests in the author. No quotation from it or information derived from it is to be published without full acknowledgement of the source. The thesis is to be used for private study or non-commercial research purposes only.

Published by the University of Cape Town (UCT) in terms of the non-exclusive license granted to UCT by the author.

DECLARATION PAGE

DECLARATION

I, Nagib du Toit, hereby declare that the work on which this dissertation is based, is my original work (except where acknowledgements indicate otherwise) and that neither the whole work nor any part of it has been, is being, or is to be submitted for another degree in this or any other university.

I empower the university to reproduce for the purpose of research either the whole or any portion of the contents in any manner whatsoever.

Signed by candidate

Signature:

Signature removed

Date: August 2006

CONTENTS

(1) THE LINK BETWEEN EVISCERATION AND SYMPATHETIC OPHTHALMIA

(a) Introduction.....	Page 4
(b) Enucleation.....	Page 5
(c) Evisceration.....	Page 6
(d) Ocular trauma.....	Page 8
(e) Sympathetic Ophthalmia.....	Page 9
(f) Reports linking evisceration and Sympathetic Ophthalmia.....	Page 15
(g) Studies which refute the risk.....	Page 17
(h) Conclusion.....	Page 18

(2) THE RISK OF SYMPATHETIC OPHTHALMIA FOLLOWING EVISCERATION FOR PENETRATING EYE INJURIES AT GROOTE SCHUUR HOSPITAL

(a) Introduction.....	Page 21
(b) Aim.....	Page 21
(c) Methods.....	Page 22
(d) Results.....	Page 23
(e) Discussion.....	Page 29
(f) Conclusion.....	Page 32
(g) Acknowledgements.....	Page 34

(3) BIBLIOGRAPHY

(a) Methods of literature search.....	Page 35
(b) References.....	Page 35

EVISCERATION AND SYMPATHETIC OPHTHALMIA:

IS THERE A RISK?

This paper addresses the above controversy (with respect to evisceration of the globe following trauma) by reviewing current literature on the subject and by studying trauma cases at a tertiary university hospital for possible answers. The first section consists of a discussion which is based on a literature review of the subject, while the second contains the details of a retrospective study which was conducted in the Eye Department at Groote Schuur Hospital (GSH).

(I) THE LINK BETWEEN EVISCERATION AND SYMPATHETIC OPHTHALMIA

(A) INTRODUCTION

This question is posed in relation to the theory that there is a definite risk of sympathetic ophthalmia (SO) occurring after evisceration for ocular trauma and that it is safer to perform an enucleation in this situation.

Sympathetic Ophthalmia is a rare, but devastating eye condition that occurs bilaterally in the form of a panuveitis. This occurs following penetrating or perforating ocular trauma to one eye. The eye that has been traumatised is referred to as the 'exciting eye' and the fellow eye, which also becomes severely inflamed, is the 'sympathising eye'. Sympathetic Ophthalmia is most likely related to an auto-immune response to uveal antigen and usually occurs 4-8 weeks after the precipitating traumatic event.

In order to facilitate the answering of the question regarding the risk of SO after evisceration in trauma cases, some background information on the indications for removal of the eye is needed.

Removal of the eye or its contents may be indicated¹:

- after such severe ocular trauma that there is little hope of recovering any useful vision in the injured eye
- to control pain in a blind eye – most commonly from end-stage neovascular glaucoma, chronic uveitis or previous trauma
- to treat certain intraocular malignancies, mostly retinoblastoma in children and choroidal melanoma in adults
- to resolve endophthalmitis which is unresponsive to medical therapy (with a poor visual prognosis)
- to improve the cosmesis of a disfigured or phthisical eye (if a cosmetic scleral shell cannot be tolerated).

Removal of the eye can be achieved by both evisceration and enucleation, but evisceration may be more suited to certain indications and enucleation to others. The advantages and disadvantages of each procedure will be explained later.

After a brief mention of the history and advantages of enucleation, a summary of the relevant facts with regard to evisceration follows. Then, SO will be briefly reviewed and the controversy surrounding the occurrence of sympathetic ophthalmia following evisceration for ocular trauma described.

(B) ENUCLEATION

Enucleation involves removal of the entire globe, including transection of the optic nerve, while preserving other orbital tissues. According to Moshfeghi,² it may be the oldest operation in ophthalmology, possibly dating back to 2600 BC in China. The first 'modern' enucleation is thought to have been performed by Lange in 1555. His technique involved passing a hook through the globe to obtain traction, followed by sharp dissection to sever the globe from the orbit. A more anatomic approach to globe removal,

involving dissection and removal of the extraocular muscles was adopted by O'Ferral in Dublin and Bonnet in Paris, in the 1840's.²

Enucleation allows for complete histologic examination of the eye and optic nerve, eliminates any concern that surgery might contribute to the risk of SO in the fellow eye (since all uveal tissue is removed) and is always the procedure of choice if the nature of intraocular pathology is unknown or intraocular tumour suspected.

(C) EVISCERATION

Evisceration was first introduced by Beer in 1817. While performing an iridectomy, an expulsive haemorrhage occurred. The eye was lost and he removed the remaining intra-ocular contents. The outcome was reported as being cosmetically acceptable and thus evisceration became the preferred method for removal of the eye for most of the 19th century. In 1884, Mules improved the procedure by placing a spherical glass implant into the scleral cavity. Mules had hoped that clearance of the contents of the globe would prevent SO. In 1887, Frost reported a series of patients who developed SO after evisceration; with the result that evisceration was nearly abandoned.³ Frost did, however, adopt Mules' idea of orbital implants, and so the current enucleation operation evolved from an innovation in evisceration surgery. Despite the initial concerns about SO, evisceration has become increasingly popular in recent years.⁴⁻⁶

Evisceration involves removal of the intraocular contents i.e. uvea, retina, vitreous, lens and sometimes cornea; leaving the optic nerve, sclera and extra-ocular muscles intact. A ball implant is usually placed within the intrascleral cavity (or in the intraconal space behind the sclera – Harrison DC, unpublished data). Early evisceration techniques included removal of the cornea, but in 1939, Burch introduced evisceration with corneal preservation, thus allowing larger implants and enhancing orbital volume. This technique does carry the risk of corneal necrosis later on. Burch placed his scleral incision anterior to the superior rectus insertion. This was later modified by Hughes, who placed his incision posterior to the insertion of the superior rectus muscle.⁷

Stephenson,⁷ states that Hughes' evisceration technique has become very popular in recent times. A conjunctival incision is made about 4mm posterior to the limbus (superiorly) and the superior rectus muscle is identified and disinserted. A scleral incision is made 2mm behind the muscle insertion. Uveal tissue is removed with a curette and if desired, any remaining uveal pigment can be denatured with a sponge soaked in 70% alcohol. Haemostasis can be achieved by pressure or cautery and is greatly aided by a retrobulbar injection of long-acting local anaesthetic along with adrenaline (which also helps in the control of post-operative pain and swelling).² Adequate haemostasis is important in minimizing soft tissue oedema, facilitating proper placement of the implant and decreasing post-operative pain. Endothelial cells are removed from the inner corneal surface. Typically, a 16mm ball implant is accommodated in the scleral cavity. The sclera is closed, superior rectus replaced and tenon/conjunctival layers approximated.^{2,7}

When the viability of the cornea is in doubt due to trauma or disease, a 360-degree peritomy is done and the cornea excised. The scleral opening is enlarged obliquely (to avoid the rectus muscles). A 12-14mm ball implant can usually be inserted. Larger implants can also be used, even with the cornea excised and without causing undue tension on the wound, if radial relaxing incisions are placed in the posterior sclera ('expansion sclerotomies').⁷ The risk of extrusion of the implant does still exist, however.

Postoperatively, the fornices can be maintained by a scleral conformer. A compressive patch helps to decrease the potential for postoperative haemorrhage. Some surgeons recommend the routine use of systemic antibiotics postoperatively, while most do use topical antibiotic ointment. The socket is usually ready to accept a permanent prosthesis about 6 weeks after surgery. It is also essential to note that polycarbonate safety glasses should be prescribed to all monocular patients and appropriate counseling is necessary.⁸

Advantages of evisceration include⁸:

- Less disruption of orbital anatomy, with reduced risks of fat atrophy and further loss of orbital volume.
- Good motility of the prosthesis, since the extraocular muscles remain attached to the scleral coat of the globe (although motility may be similar following enucleation).
- Better treatment of endophthalmitis because drainage of the ocular contents can occur without invasion of the orbit, resulting in reduced chances of contamination of the orbit.
- It may be performed under a local anaesthetic when general anaesthesia is contra-indicated, as it is less invasive.
- Technically, a simpler procedure.

Disadvantages are²:

- Potential dissemination of unsuspected intraocular malignancy, which should be ruled out by ultrasonography prior to surgery.
- Possibility of sympathetic ophthalmia, which could theoretically occur after partial removal of choroidal antigens.
- Less complete specimen for pathological examination.

(D) OCULAR TRAUMA

Penetrating ocular trauma is a leading indication for removal of the eye. In a review of many different studies, Moshfeghi² found that there are several factors at the initial assessment of a trauma case that can be used to predict the likelihood of enucleation or evisceration eventually being required.

These are²:

- poor visual acuity (light perception or no light perception)
- presence of a dense afferent pupil defect

- wound length of greater than 10mm
- blunt (as opposed to sharp) trauma
- being a young male.

During the initial exploration, the trend amongst surgeons is to try to spare a traumatized eye, since the patient may be disorientated, under the influence of mind-altering substances or may not have had enough time to come to terms with the injury and the need for removal of the eye. These are all factors that affect the patient's ability to give fully-informed consent immediately after trauma.² On the other hand, in these times of cost cutting and increasing efficiency in medical management, such a policy may be frowned upon and there may be an inclination to remove the eye primarily.⁸ Primary enucleation or evisceration may be indicated in those patients where closure of the globe is impossible, as may occur with gunshot injuries to the eye,⁹ or when

- the affected eye has no light perception and
- a total afferent pupil defect is present and
- there is prolapsed uvea and retina in the wound or
- wounds are longer than 20mm or extend posterior to the equator of the globe and
- the fellow eye is normal and the patient is alert and co-operative.²

These factors lead to poor vision in the long-term and enucleation is eventually required in the majority of cases.¹⁰

(E) SYMPATHETIC OPHTHALMIA

Sympathetic Ophthalmia is a very rare, bilateral, granulomatous panuveitis which occurs after penetrating injury (traumatic or surgical) to one eye. There are also reports of SO occurring after non-penetrating ocular surgery.¹¹ The traumatized eye is referred to as the exciting or sympathogenic eye and the fellow eye as the sympathizing eye. The condition is potentially devastating in a functionally monocular patient.⁸

Gasch et al.,¹¹ in a review of the history of SO, note that over 2000 years ago, Hippocrates described that an injury to one eye can lead to disease in the other eye. Also, Louis Braille, who developed the writing system of Braille, may have lost his vision from SO – two years after a penetrating injury to one eye, vision in the other eye gradually deteriorated. The first written reference to SO appeared in 1000 AD.¹¹ Multiple reports cited the disease in the eighteenth and nineteenth centuries, but it was only in 1840 that the first comprehensive clinical description of SO was written by William Mackenzie, who also named the disease ‘Sympathetic Ophthalmitis’. In 1905, Ernst Fuchs wrote a report of the classic histopathological description of SO.¹¹

The incidence of SO has been estimated at 0.1-0.3% after ocular trauma and about 0.02% after ocular surgery.² In a series of 105 cases of SO, Lubin et al. found that penetrating trauma accounted for most cases.¹² A review article on SO by Chu,¹³ confirms that trauma was found to be the major cause in most reported series. However, Kilmartin, in a prospective population-based study in the UK, found that SO was more frequently associated with ocular surgery than trauma.¹⁴ Some authors report that the incidence of SO is decreasing, while others have shown that the incidence has been stable over the past century and rates of SO ranging from 0.001% to 2.0% of traumatized eyes have been quoted.^{15,16} Improvements in the management of ocular trauma and surgical techniques, as well as increased knowledge of the disease and an enhanced ability to diagnose other ocular inflammatory diseases may account for a decrease in the number of reported cases of SO.^{11,13}

The prevalence of SO is higher in male than female patients. This is attributable to the fact that males have a higher incidence of ocular trauma. In post-surgical cases of SO, the incidence shows no gender difference.^{12,17} Although SO is reported to be extremely rare amongst the Australian Aborigines, there is no racial predisposition and SO occurs in all age groups.¹⁵ Genetic predisposition may contribute to the development of SO, since the expression of the HLA-A11 antigen and other haplotypes have been found more frequently in SO cases.¹³

Sympathetic Ophthalmia has been reported to occur between 5 days and 66 years after ocular injury, but the shortest interval with clinical as well as histopathological supportive data is 10 days. Sixty-five percent of cases of SO develop between 2 weeks and 2 months after the initial injury and 90% of cases occur within the first year.¹¹ Patients usually have persistent inflammation of the exciting eye, with insidious onset of symptoms and signs of uveitis in the sympathizing eye. Early disease may be characterized by difficulties with accommodation and blurring of vision, due to involvement of the ciliary body, pain and photophobia. The disease usually progresses to bilateral, granulomatous panuveitis with the following signs¹⁸:

- ciliary injection, mutton-fat keratic precipitates, aqueous cells and flare, iris thickening and posterior synechiae
- vitreous cells and haze
- retinal vessel sheathing, papillitis and choroidal infiltration
- in approximately 33% of patients, the fundus periphery exhibits multiple, small, yellowish-white lesions corresponding to Dalen-Fuch's nodules (which is a histological finding and will be discussed below)
- the severity of ocular inflammation may vary from mild to severe.

Atypical presentations involving only mild, transient, non-granulomatous inflammation have been reported. In these cases, early enucleation of the exciting eye or ongoing immunosuppression was the rule.¹¹ Extraocular manifestations in the form of vitiligo, poliosis, alopecia, dysacusis, meningism and cerebrospinal fluid (CSF) pleocytosis (i.e. features very similar to those of Vogt-Koyanagi-Harada (VKH) syndrome) may occur.¹⁷

Complications include rubeosis iridis, pupillary membranes, secondary glaucoma, cataract, macular oedema, exudative retinal detachment, choroidal neovascularisation, chorioretinal scarring, optic atrophy and phthisis bulbi.^{11,18,19} These sequelae usually indicate a poor visual prognosis. Without adequate treatment, the disease runs a prolonged course with recurrent inflammation and eventual blindness.¹¹

Fundus Fluorescein Angiography (FFA) is a helpful investigation. On FFA, leakage occurs in acute disease, reflecting an exudative process and retinal vasculitis. Dalen-Fuch's nodules (which have not disrupted the RPE), appear as hypofluorescent spots in early disease, but show up as hyperfluorescent window defects later in the disease process when the overlying RPE has been disrupted. There is often late staining of the optic nerve head. Electrophysiological changes have also been reported.¹³

The pathological features of SO are similar in the exciting and sympathizing eyes. The uvea becomes thickened by a diffuse, non-necrotizing, granulomatous infiltrate consisting of lymphocytes, with interspersed granulomas composed of aggregates of epithelioid cells and some giant cells. In severe or untreated disease, the infiltrate may contain eosinophils and plasma cells. Phagocytosis of pigment granules by epithelioid cells occurs and lymphocytes form aggregates around the vortex veins. The choriocapillaris and retina (with the exception of retinal vessels) are spared in most cases.¹² Dalen-Fuch's nodules are characteristic, but not pathognomonic of SO, since they also occur in VKH syndrome and sarcoidosis.¹¹ Prevalence of these nodules seems to vary according to the severity of SO, with rates of 25-36% being reported in less severe disease and 100% in severe disease. Dalen-Fuch's nodules are about 60-700µm in diameter and found mainly in the fundal mid-periphery. They form between Bruch's membrane and the retinal pigment epithelium (RPE) and are composed of histiocytic cells intermixed with depigmented RPE cells.²⁰ In atypical cases or advanced disease, focal inflammation of the uvea, retinitis, involvement of the choriocapillaris and optic nerve inflammation occur.¹²

The exact cause of SO is unknown, but Elschnig first suspected immunologic mechanisms.¹⁵ Immunohistopathological findings suggest that a T-lymphocyte mediated, delayed (type IV) hypersensitivity reaction is involved in the pathogenesis. The predominant hypothesis is that a penetrating injury to one eye leads to a situation where an immune reaction to a uveal self-antigen occurs. Extraocular manifestations suggest that a generalized sensitization against melanin-containing tissues occurs in certain

individuals. Some authors have identified retinal antigens that may be responsible.¹¹ It is thought that perforating injury allows intraocular antigens to leave their usual 'immune-privileged' site via the conjunctival lymphatics, while also permitting the entry of pathogens which upgrade the local immune response. This situation leads to the bypassing of immunosuppressant mechanisms in genetically predisposed individuals, with resultant inflammation.²¹ This theory does not, however, explain the low prevalence of SO relative to ocular trauma; and also after filtration surgery, which exposes uveal tissue to conjunctival lymphatics, as well as the actual occurrence of SO after non-penetrating ocular procedures.¹¹

A history of accidental or surgical uveal trauma is essential in diagnosing SO because the clinical findings are not pathognomonic. Sarcoidosis and VKH syndrome most closely resemble SO, but syphilis, phacoanaphylactic endophthalmitis, lymphoma, multifocal choroiditis, ocular toxoplasmosis and idiopathic anterior uveitis are also included in the differential diagnosis.¹¹ Patients with VKH syndrome have serous retinal detachment, optic nerve involvement and extraocular manifestations more frequently than those with SO.¹⁷

The treatment of SO by Mackenzie, who initially described the condition, included mercury (taken orally) and leeches applied to the conjunctiva.¹⁵ Prompt enucleation of the injured eye, before sensitization or autoimmune response develops, is known to be preventative of SO. The critical period is thought to be within 10-14 days of the injury. The origin of this rule is unclear, but according to Albert, it seems to be attributed to Verhoeff in 1927.¹⁵ Reports of treatment of SO by enucleation of the exciting eye within 2 weeks of the onset of signs in the sympathizing eye have also been published. Results ranging from control of inflammation with fewer recurrences and improved visual outcome, to no benefit have been reported.¹⁵ If any potential for useful vision in the injured eye exists, enucleation should not be performed, since the exciting eye may eventually become the eye with better vision. Otherwise enucleation, as part of therapy, can be considered.²² Nevertheless, enucleation as a therapeutic intervention in SO, is

performed less frequently in recent times. Enucleation of the exciting eye in order to confirm the histological diagnosis of SO, has also been reported.¹⁴

Since the advent of treating SO with corticosteroids, the once dismal prognosis of SO has improved.¹³ Corticosteroids are the mainstay of treatment. They can be used topically, by periocular injection, orally or intravenously depending on the extent and severity of disease. Studies have shown improved visual outcome in the majority of patients treated with corticosteroids.¹¹ Depending on the severity of inflammation, doses ranging from 0.5-2.0mg/kg/day have been used. As long as the inflammation remains under control, the dose can be tapered by 5mg/week. However, a maintenance dose of 5-10mg/day is usually required for several months.²³

Cyclosporine is used when there is a poor response to steroids, when steroids are contraindicated, or as a steroid-sparing agent in patients who require high doses of steroids to remain in remission. Cyclosporine is a potent inhibitor of T-lymphocyte function and is thus useful in the immunomodulation of SO. The successful use of alternative second-line agents such as azathioprine, methotrexate, chlorambucil, cyclophosphamide and FK506 has been reported in the treatment of SO.¹¹ All the above agents are potentially toxic and patients must be appropriately monitored.

There is, however, no consensus as to the optimal method or agent to be used in the treatment of SO, but most authors agree that early and aggressive therapy plays a major role in optimizing visual outcome.¹³ With appropriate treatment, studies show that a visual acuity of 20/60 or better can be sustained.¹¹ Long-term follow-up, even years after quiescence, is required because of the chronic, relapsing nature of the condition. Any patient with a history of SO also needs adequate immunosuppressant cover when undergoing any ocular surgical procedure.

(F) REPORTS LINKING EVISCERATION AND SO

This section of the discussion will be confined to those cases of SO which have been reported to occur after evisceration for severe ocular trauma and which form the basis of the theory which is being questioned.

In 1887, Frost reported a series of patients who developed SO after evisceration, according to Migliori.³ It is not clear what the indications for evisceration were in these cases. Albert,¹⁵ notes that the literature is full of data regarding the occurrence of SO, but that the value is dubious, since pathological proof of SO was usually lacking. Particularly in the older literature, SO was often confused with a variety of other forms of uveitis. Today, ophthalmologists' impressions and even current textbooks are still based on these observations, however flawed they may be.

Recently, the controversy regarding SO following evisceration was re-ignited by a paper, written in 1972 by Green et al.²⁴ The article describes 4 cases of histologically proven SO which occurred after evisceration. In 3 of the 4 cases, evisceration was done on a traumatized eye. The first case was seen in 1969, 23 days after trauma that had ruptured the left globe and caused uveal incarceration. An evisceration was performed (although an enucleation had been planned) and the patient developed SO 15 days later. The second case was seen in 1968, but there was no history of trauma and it will therefore not be discussed. The third case was seen, in 1948, for a ruptured right globe following trauma. The patient underwent an evisceration (after refusing an enucleation) 7 days after trauma and then developed SO 23 days after surgery. The fourth case was seen in 1926, following trauma that had resulted in a panophthalmitis. The patient had the left globe eviscerated 15 days after the injury and developed SO 20 days later.

In discussing Green's article, Ruedemann noted that the 23 days for which uveal tissue was incarcerated in the scleral wound in the first case, was 'too long'²⁴; and under such circumstances, the "uveal cells cannot be removed in toto". As far as the third case is

concerned, Green reported that all the uveal tissue may not have been removed at evisceration, since pigment was found in the 'enucleated' scleral shell when microscopic examination of the pathology specimen was performed. He also notes that in each of the cases, the operating note clearly states that a vigorous attempt was made to remove all the uveal tissue, except in the third case. In both the first and fourth cases, the 23 and 15 day periods after injury (before surgery was performed) may have been long enough to allow sensitization to uveal antigens. It is thus clear that all of Green's cases, in which eviscerations were performed following ocular trauma, were atypical in some way.

Ruedemann himself wrote an article on the subject of SO after evisceration (in 1964) and according to Green,²⁴ apparently found 47 cases of SO, but was "reluctant to accept the diagnosis" for some or other reason. Ruedemann, however, stated that in the 30 years or more that he had been doing eviscerations, he had not seen one case of SO. Green, in a reply to Ruedemann's comments, admits that the SO in his cases may have been initiated by the original trauma and not the evisceration itself, but that the evisceration certainly "did not prevent the development of SO". Of interest, Green reported that, "Hopelessly traumatized eyes in younger persons, when the eye is treated immediately or in two stages a few days apart are most suitable for evisceration." This scenario is very similar to that encountered at Groote Schuur Hospital (GSH) at present. Also of note is that normally uveal melanocytes are found in the scleral lamellae and within scleral canals, which are not accessible for removal by the evisceration technique.²⁴ This minor amount of residual uveal pigment may not contain enough of an antigenic load to incite an immune response, however.

It is also noteworthy that 6 cases of SO (all developing after evisceration) were reported in the Japanese literature in 1965.²⁵ Unfortunately, no further comment can be made on this paper, as neither the translation nor the abstract are available. In 1997, a French study reported 5 cases of SO, of which 2 occurred after evisceration.²⁶ However, it is not clear whether the eviscerations were done for ocular trauma or how long after injury the eviscerations were performed.

(G) STUDIES WHICH REFUTE THE RISK

In 1985, Walter reported on the findings of a questionnaire sent out by the American Society of Ophthalmic Plastic and Reconstructive Surgery. One of the subjects of the questionnaire related to the occurrence of SO after evisceration. There were 140 respondents, all of whom had never seen a case of SO after evisceration.⁶ This type of study does not carry much weight, however.

Levine retrospectively studied 90 cases of evisceration from two hospital centres over a 35-year period.⁵ Of these, 51 returned for follow-up and not one case of SO was identified. It is not clear how many of these eviscerations were done following trauma. As part of this study, Levine, et al. conducted a survey of the American Societies of Oculoplastic Surgery, Uveitis, and Ophthalmic Pathology. The survey respondents reported a total of 841 eviscerations. Amongst these 5 cases of SO were recalled, of which 3 were post traumatic. The authors did not seem to accept the cases as being true SO, since no definitive clinical or pathological evidence was supplied and the cases were reported anecdotally. They therefore concluded that their findings suggested that, "Evisceration is a safe procedure with a low risk of SO". Bilyk⁸ notes that this type of conclusion characterizes the controversy surrounding the issue of SO following evisceration.

In a recent retrospective study, Gurdal, et al. reviewed the medical records of 217 patients with penetrating ocular injuries, who had either evisceration or enucleation in order to determine the incidence of SO and to evaluate the complications of surgery.²⁷ The patients were followed up for an average period of 10 years and the interval between injury and surgery for each patient was also documented. They found that complications after enucleation were significantly higher than after evisceration. No cases of SO were documented in patients who underwent primary evisceration or enucleation, but a single case of uveitis occurred in a patient who had primary repair. They concluded that, "Evisceration may be the procedure of choice if primary repair cannot be performed". It

is also worthwhile to note that, according to Migliori, in several retrospective studies involving over 3000 eviscerations, not one case of SO was identified.¹

(H) CONCLUSION

Primary enucleation is thought to eliminate the risk of SO completely.⁹ The incidence of SO in fellow eyes, following penetrating ocular trauma to eyes that were not enucleated, has been estimated at 0.19%.¹⁵ Therefore, according to classical teaching, in severely traumatized eyes secondary enucleation (following primary repair) within the first 10-14 days may be considered if the risk of SO and harm to the remaining eye is judged to be greater than the likelihood of recovering useful vision in the traumatized eye. In a review article on eye injuries in the twentieth century, the authors report that with the better understanding of the pathophysiology of ocular trauma and improved surgical techniques today, SO appears to be uncommon and earlier fears of this complication seem to have been exaggerated.¹⁶

As pointed out by Bilyk,⁸ a careful review of the literature does not reveal conclusive evidence regarding the risk of sympathetic ophthalmia after evisceration. Unfortunately, strong opinions on sides holding opposing views have led to unfounded statements and occasional over-interpretation of data. A theoretically increased risk of SO should be considered in all cases, but must be viewed in the light of the fact that SO is rare and any perceived risk remains hypothetical.

One major problem with any trial or survey involving evisceration and SO is that a rare entity is being studied among a relatively low number of surgical cases. This leads to the danger of either under- or over-estimating the risk due to the interpretation of data with insufficient case numbers.⁸ There is also the variable factor of previous ocular surgery in any series – SO can occur after anterior or posterior segment surgery. Thus, any study of evisceration and trauma-related SO should exclude eyes that underwent other procedures, thereby further reducing the potential number of acceptable cases to be studied and

making interpretation even harder. Bilyk therefore concludes that without the knowledge of the potential risk of SO, one cannot effectively persuade or dissuade patients from undergoing globe removal.

There is a case report describing histologically proven SO in an eye enucleated 4 weeks after a penetrating injury.²⁸ This patient, like 2 of Green's patients, underwent surgery beyond the 10-14 day 'critical period'. It is thus likely that the risk of SO occurring is not dependent on whether enucleation or evisceration was performed, but is rather related to the time period between primary repair and subsequent evisceration or enucleation and to the genetic susceptibility of the individual. It is also possible that the question of whether the eye was removed primarily or secondarily after trauma may be important - since removal of the antigenic load may be achieved before the immune system becomes sensitized. These theories still need to be tested however. It is also clear that as much of the uveal tissue as possible needs to be removed at the time of surgery, since leaving any tissue behind increases the risk of SO, as was found by Green and as reported recently in a patient who developed SO after evisceration for a shrapnel injury.^{24,29} Reports tend not to mention whether enucleations or eviscerations were performed primarily or secondarily in the trauma cases in their different series, although Green's trauma cases were all primarily eviscerated.

It is not considered good practice to primarily remove an eye after trauma unless all the criteria mentioned earlier (in the section on ocular trauma) apply. At GSH, however, primary evisceration is often done due to the large number of severe ocular injuries seen every week, the constraints on theatre lists and staff and the perception that some patients may develop a painful, blind eye and require further surgery anyway. A recent study of the epidemiology of penetrating eye injuries at a tertiary, university hospital in the USA revealed that 390 injuries were seen over an 11-year period, with more than half of the cases being referred from outlying hospitals.³⁰ At GSH, approximately 1400 cases have been seen from 1995 to 2004 (Du Toit N, unpublished data).

Bilyk⁸ has suggested that Hansen, et al. who retrospectively reviewed 1028 cases of enucleation and evisceration over a 20-year period, might be able to shed light on the subject by using their database to study the rate of SO in the enucleation and evisceration groups.

At GSH, the next step to be taken should be to analyze data on ocular trauma, eviscerations and SO to see whether any further information can be gained on the subject. The information gained may help to make the answer to the question that has been posed a little clearer.

University of Cape Town

(2) THE RISK OF SYMPATHETIC OPHTHALMIA FOLLOWING EVISCERATION FOR PENETRATING EYE INJURIES AT GROOTE SCHUUR HOSPITAL

(A) INTRODUCTION

It is perceived that the risk of SO is eliminated if the severely injured eye is removed as a primary procedure; and decreased if secondary removal (following primary repair and within 10-14 days after the initial insult) is performed.⁹ It is also thought to be safer to remove the eye by enucleation (removal of the entire globe) rather than by evisceration (removal of the contents of the globe only). Some reports indicate that an evisceration is unsafe, since uveal tissue may be left behind and act as the source of the immune response leading to SO.^{2,3} This opinion is primarily based on a controversial paper published by Green in 1972.²⁴ Evisceration does, however, have definite advantages over enucleation, as it is a technically simpler surgical procedure and it makes the subsequent fitting of an ocular prosthesis easier.⁸ Although eviscerations are currently the method of choice for removal of severely traumatised eyes at some centres in the world, this practice is not entirely evidence-based and is still generally frowned upon. Evisceration may become the preferred and accepted procedure for removal of the globe following trauma if it can be conclusively shown that the risk of SO after evisceration is negligible and less than the figures quoted in the literature.

(B) AIM

To prove that the risk of SO following penetrating ocular trauma in cases where eviscerations were performed is low and no higher than that estimated to follow enucleation. The incidence of SO is quoted as 0.19% (range 0.1 – 0.3%) after ocular trauma in which primary enucleation was not performed.¹⁵ Many cases of penetrating ocular trauma are seen at GSH every year (on average 2-3 cases per week) – a much higher incidence than that which occurs at other centres in the world.^{10,29} Those patients, who have a poor prognosis for visual recovery as well as irreparable damage, undergo a primary evisceration; while those in whom primary repair was possible, but nevertheless

subsequently develop a persistently painful, blind eye or a cosmetically unacceptable phthisis bulbi (shrunken globe), undergo a secondary evisceration. At GSH, the incidence of SO following ocular trauma appears to be extremely low. By analysing our data over a 10-year period, we hoped to demonstrate that the risk of SO is minimal or non-existent following evisceration, and thus contribute to resolving this world-wide controversy as well as providing evidence for the safe performance of evisceration in trauma cases.

Secondary aims included analysing the data to assess for any difference in the incidence of SO following primary versus secondary evisceration. This issue has only been superficially addressed in the ophthalmic literature – most papers report the results following secondary removal of the globe. In most centres, enucleations or eviscerations are done secondarily, except in the very severe cases where primary repair is impossible.

There are definite criteria to be fulfilled before primary evisceration can be considered appropriate.² Assessment to determine whether the patients who had undergone primary evisceration conformed to these guidelines, in terms of visual acuity (VA) and the presence of an afferent pupil defect (APD), was also performed.

(C) METHODS

A retrospective study was performed to identify all those patients who were admitted to the Eye Department at GSH following penetrating ocular trauma from the beginning of 1995 to the end of 2004 (a 10-year period). From this group, patients who underwent surgery for penetrating or perforating injuries (corneal, scleral or corneo-scleral) were identified and compared to those who had no surgery. The records of those who had surgery were analyzed in order to separate those who underwent repair from those who underwent primary (or secondary) evisceration. After classifying patients into different groups according to type of surgery, the incidence of SO following penetrating trauma was assessed. The risk of SO after evisceration was evaluated by looking for cases of SO in those patients who underwent primary or secondary evisceration following trauma.

The difference between the incidence of SO following primary versus secondary evisceration as well as the incidence of SO in patients who underwent primary repair (without evisceration or enucleation) was assessed.

Other factors that were recorded and analyzed included the time between injury and presentation (since a longer period between injury and presentation could lead to an increased risk of SO), the length of the follow up period after penetrating trauma (as most cases of SO occur within a year of injury) and the ophthalmic evaluation of the affected and fellow eyes, in terms of visual acuity (VA) and the presence of an afferent pupil defect (APD), at presentation and at last follow up.

(D) RESULTS

A total of 1392 patients who had suffered penetrating eye injuries were identified and included in the study. Of these patients, 1383 (99.4%) underwent surgery on admission i.e. either primary repair or primary removal of the globe. Of the surgical group, 889 (64.3%) underwent primary repair, 491 (35.5%) had primary eviscerations and 3 (0.2%) had primary enucleations. A single patient had primary repair in one eye and primary evisceration in the other. Of the patients who initially had primary repair, 11 later underwent secondary evisceration. For various reasons, 9 patients did not have surgery at all (*figure 1*).




Figure 1. Breakdown of initial treatment of patients admitted with penetrating trauma.

Two cases of SO were identified. Both these patients had not had any surgery for their penetrating injuries. This meant that the incidence of SO following penetrating trauma at GSH was 0.14%. There were no cases of SO identified in the groups who had primary evisceration, primary repair or secondary evisceration. The short follow up period of some of the patients presented a problem however.

Follow up periods were broken up into different groups on the basis of previous review articles indicating that two-thirds of cases of SO occur within the first 2 months after injury and that 90% of cases occur within the first year.¹¹ Using these periods as categories, only 635 (45.6%) of all patients were found to have been followed up for at least 2 months and of these, only 175 (12.6%) for 1 year or more (*figure 2*).

Attendance for follow up was found to be similar in the different surgical categories. Patients who had primary repair were found to have been followed up for at least 2 months in 411/889 (46.2%); and for 1 year or more in 123/889 cases (13.8%). In the primary evisceration (and enucleation) group, 221/494 cases (44.7%) were followed up for at least 2 months, while only 51/494 cases (10.3%) attended for 1 year or longer. Of the total 1392 cases, 438 (31.5%) attended follow up for 2 weeks or less – most were last seen on the day of discharge from the ward; and 319 (22.9%) were followed up for a period between 2 weeks and 2 months.




Figure 2. Follow up periods of all cases after admission.

The time between injury and presentation was found to be very variable. The period was not recorded in 250/1392 patients (18%); 306/1392 patients (22%) presented on the day of injury; 490/1392 (35.2%) presented 1 day after injury; and in total, 1124 (80.7%) presented within the 2 week 'critical period' of the initial injury. Only 18 (1.3%) patients presented beyond 14 days. One patient presented 6 years after injury to the eye. In general, the time from presentation to surgery was 24 to 72 hours after admission, since penetrating injuries are treated as emergencies.

Only 3 patients, because of the nature of their injuries, had primary enucleations. One of these had sustained a gunshot wound to the globe, the second had a stab wound which had also transected the optic nerve and in the third case, the reason for enucleation (rather than evisceration) was not clear. Assessment of records revealed 9 cases of penetrating eye trauma in which no surgery was performed. Four of these 9 patients had absconded from the ward after admission (before surgery could be performed) and were never seen again. Two patients presented late after injury with wounds that were well apposed and healing satisfactorily with no uveal prolapse, so no surgery was performed. The first of the two presented 7 days after injury and the second, 5 months after the initial trauma. One patient had a small, full thickness corneal laceration which was treated conservatively with a bandage contact lens.

Two patients who, interestingly, had not had any surgery following their injuries and presented with uveitis were identified - both of these were diagnosed as having SO. The first of the two cases of SO was seen in 1997. She was a 44 year old female patient, who presented with a 5-month history of decreased vision in her right eye. She gave a history of penetrating trauma to her left eye in 1991, with no subsequent surgery or repair being done. Her visual acuities were perception of light (PL) on the right and no light perception (NPL) on the left. She had a scarred anterior segment on the left side with distorted anatomy from the previous trauma. On the right, there were signs of uveitis - ciliary injection, keratic precipitates, cells in the anterior chamber, occlusion and seclusion of the pupil and iris bombe, but no increase in intraocular pressure. There was

no view of the fundus. The patient was presumed to have SO and was started on treatment – subconjunctival injection of ‘Mydracaine’ and betamethasone as well as atropine drops. The patient was lost to follow up and only returned for admission 3 months later. At this stage, acuity on the right had improved to Hand Movements, although the patient was not on any treatment. Findings were much the same as before, except that she was also noted to have a cataract. The patient was admitted to the eye ward. Investigations did not reveal any other underlying cause and she was therefore started on oral prednisone as treatment for SO, with a view to cataract surgery as soon as the inflammation had settled. The patient developed psychosis on the steroids, however, and the steroids had to be stopped. She was transferred to the district hospital from which she was originally referred and further management at an outlying eye unit was arranged. She did not attend for follow up.

The second case of SO was that of a female patient who was first seen in 1998 when she was 34 years old. She had sustained blunt trauma to her right eye 3 months earlier and presented with a 3-day history of pain in her left eye. Her visual acuities were hand movements (HM) on the right and 6/12 on the left. She had a dense APD on the right, with a superiorly drawn-up pupil, a large area of subconjunctival pigment superiorly and a lower intraocular pressure than the left – all suggesting previous globe rupture. She had evidence of uveitis on the right as well as a cataract which obscured any view of her fundus. The eye was assessed as being pre-phthisical. On the left, she had signs of uveitis with lots of cells and fibrin in the anterior chamber, keratic precipitates, a small area of posterior synechiae, moderate vitreous cells and retinal striae in the inferior macular area. There were no obvious Dalen-Fuch’s nodules, however. A diagnosis of SO was made and despite being informed about the condition and the necessary treatment, the patient refused admission and promised to return the following day. The patient was given a subconjunctival injection of betamethasone and ‘Mydracaine’ as well as topical steroid and atropine drops.

Unfortunately, she only returned for admission a month later with acuities of PL on the right and HM on the left. On the left, her cornea was oedematous, the uveitis had worsened, the synechiae had increased and there was now no view of her fundus. She was started on intravenous, followed by oral prednisone, in addition to the above treatment. She was investigated for other possible underlying causes for uveitis and the only positive finding was possible previous pulmonary tuberculosis – now inactive. She was therefore given oral isoniazid as prophylaxis. The inflammation gradually improved during her 14-day stay in the eye ward, but was complicated by iris bombe and raised intraocular pressure due to occlusion of the pupil which necessitated laser iridotomy and later surgical iridectomy. She was eventually discharged from the ward on oral and topical steroids. She then developed a flare up of uveitis about 3 weeks later which required readmission and repeat intravenous pulsed methylprednisolone, as well as oral chlorambucil as a steroid-sparing agent. About 3 months later, her vision had improved to 6/18 and the uveitis was under control. She was finally weaned off all systemic treatment about 18 months later. At that stage, she was noted to have a phthisical globe on the right and an uncorrected acuity of 6/9 on the left, despite the development of early lens opacities.

Patients who were found to present with non-navigable vision (worse than finger counting) in their affected eyes in the two surgical groups were as follows. Of the 494 patients who underwent primary evisceration (or enucleation), 354 (71.7%) had a presenting VA of NPL in the involved eye, 121 (24.5%) had a VA of PL in the involved eye, 7 patients (1.4%) presented with HM vision and regrettably visual acuity in the involved eye was not recorded in 12 cases (2.4%). There were no patients with vision better than HM. Of the 889 patients who had primary repair, 60 (6.7%) presented with a VA of NPL in the involved eye, 315 (35.4%) had a VA of PL in the involved eye, 213 (24%) presented with HM vision and VA in the involved eye was not recorded in 24 patients (2.7%) (*figure 3*). The rest all had acuities of counting fingers (CF) or better.

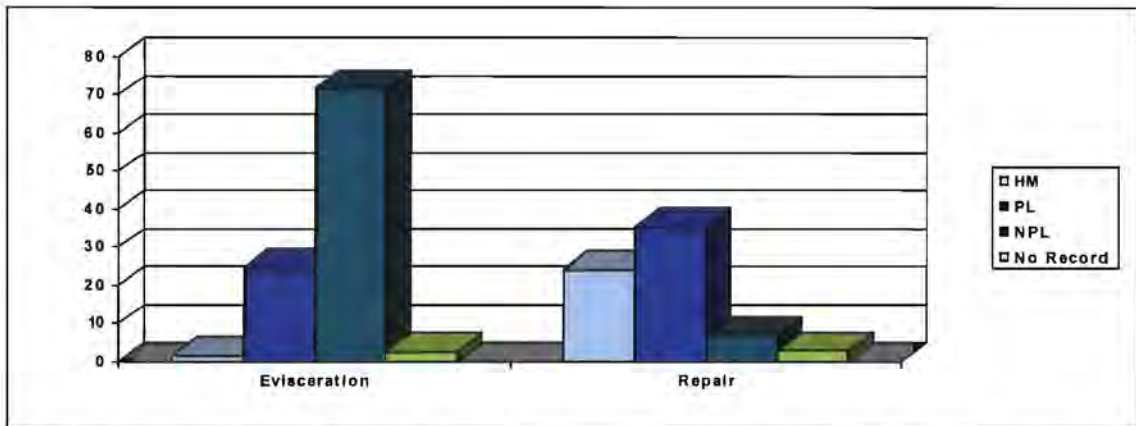


Figure 3. Presenting VA's (<CF) of patients in Evisceration group compared to patients in Repair group (in percentages).

Acuity of the uninvolved eye at last follow up was not recorded in 138/1392 cases (9.9%). Of the remaining cases, 1092 patients (78.4%) had an uncorrected VA of 6/12 or better – regarded as functional vision (of which 508 had normal or better than normal acuity). It was found that 67 patients (4.8%) had uncorrected vision of less than 3/60 in the better eye and were therefore blind according to the World Health Organisation's definition of blindness (based on VA only). Of the patients who underwent evisceration, 387 (78.3%) had a VA of 6/12 or better, 17 (3.4%) had vision worse than 3/60 and VA in the uninvolved eye was not recorded in 55 cases (11.1%). Of those who had primary repair, 699 (78.6%) had a VA of 6/12 or better, 49 (5.5%) were worse than 3/60 and there was no record of VA in the uninvolved eye in 80 cases (9%) (figure 4).

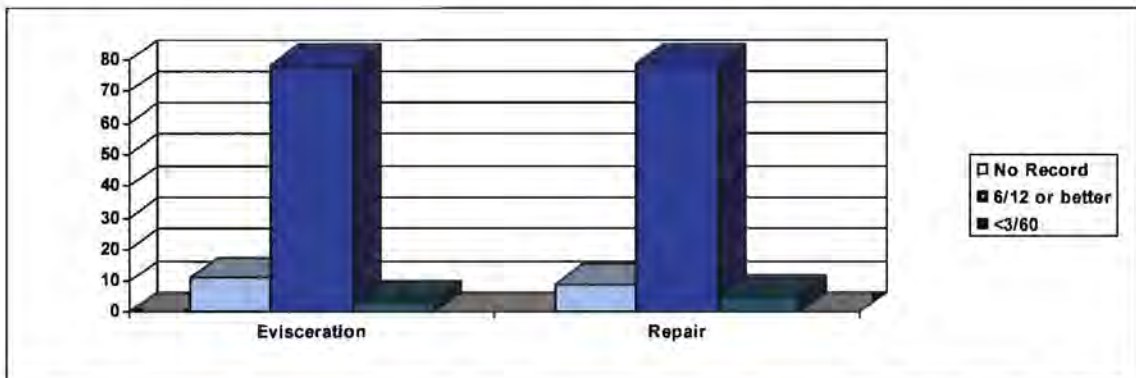


Figure 4. Percentage of patients with functional vision versus blindness in Evisceration and Repair groups.

The presence of an APD was found in 695 (49.9%) of all cases, 403 patients (29%) were found to have no APD and the presence or absence of an APD was not recorded in 294 cases (21.1%). Of the patients who underwent evisceration, 397 (80.4%) were found to have an APD, 6 (1.2%) no APD and in 91 cases (18.4%) this finding was not recorded. In the group who had primary repair, 295 (33.2%) had an APD, 396 (44.5%) had no APD and in 198 cases (22.3%) there was no record (*figure 5*).

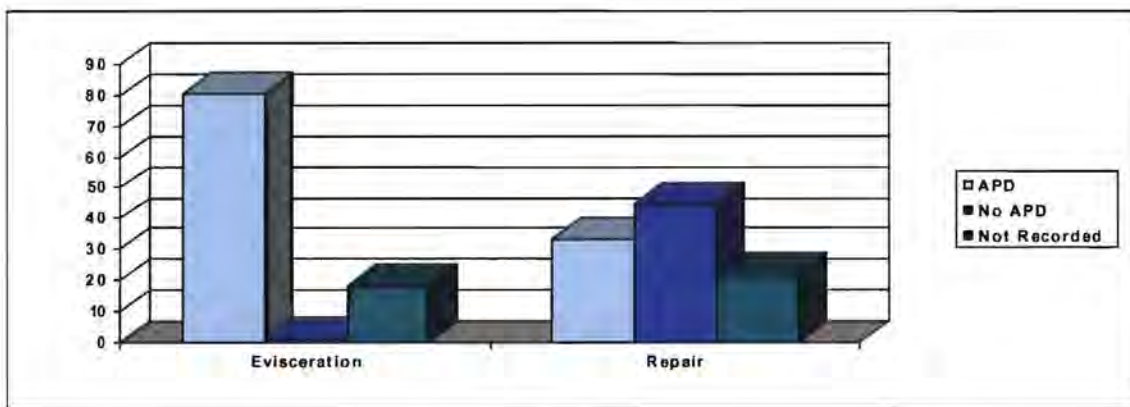


Figure 5. Percentage of patients with or without APD in Evisceration versus Repair groups.

Patients who were found to have a complete (total) APD (i.e. had no apparent function in the anterior visual pathway) in the 2 surgical groups were as follows: 200/494 (40.5%) in the primary evisceration group and 34/889 (3.8%) in the primary repair group. It was also interesting to note that out of the 11 patients who initially had primary repair done and later required secondary evisceration, only 3 patients (27.3%) initially presented with a VA of NPL and only 1 (9.1%) had a total APD at first presentation.

(E) DISCUSSION

Most of the 1392 patients, who were admitted with penetrating eye injuries, underwent primary repair and about a third had primary evisceration. The incidence of SO following penetrating injury was found to be 0.14%. Although neither of the cases were histologically proven to be SO, the diagnosis of SO was most likely as other causes were excluded by appropriate investigations. This figure is in keeping with the rate of 0.1 –

0.3% quoted by Migliori in a review article.¹ It is interesting that both these cases were found in the group of 9 patients who had not undergone surgery and did not present following their initial injuries, but only once they lost vision in their only remaining eyes.

No cases of SO were found in the groups who had primary repair, primary evisceration or secondary evisceration. Unfortunately, it is not possible to statistically prove that 'SO does not occur after evisceration' from this finding. As SO occurs in about 2 out of every 1000 penetrating eye injuries, an extremely large number of cases is required to give power to the study and make the result conclusive – as also noted by Bilyk.⁸ Even though this study contains a large number of cases (1392 cases of penetrating eye trauma, including 502 cases of evisceration), it is still not large enough to draw such a conclusion. Statistical analysis was therefore not performed and this study became descriptive in nature.

Another problem which limits the significance of the finding (that there were no cases of SO in patients who had evisceration) is the lack of adequate follow up in most cases. It has been shown that 90% of cases of SO occur within a year of the initial eye injury and two-thirds of cases within the first 2 months.¹¹ Only a little more than a tenth of all our patients were followed up for more than a year and just under a half for at least 2 months. It is thus difficult to conclude that the absence of SO in our patients was actually due to the fact that SO did not occur. In both the evisceration and primary repair groups, similar percentages of patients (10.3 and 13.8% respectively) were found to attend follow up for a year or more.

In a patient who has only one seeing eye, however, it would seem reasonable to assume that this patient would present for follow up if pain and loss of vision were to be experienced in that eye – as occurred in the 2 patients with SO in this series. Unfortunately, this is an unproven clinical assumption. An attempt was made to contact the patients who had been eviscerated and subject them to a telephonic questionnaire to

establish whether they had experienced any eye problems and their reasons for not attending. Together with other data, patients' addresses and telephone numbers had also been captured during the setting up of our data base. Nevertheless, a pilot attempt at contacting some of the patients proved unsuccessful and this idea was therefore abandoned.

It also should be borne in mind that 3.4% of the patients who underwent primary evisceration were legally blind at their last follow up visits. It is interesting to note that almost a third of our patients were last seen on the day that they were discharged from the ward.

Although it was hoped that a difference between the incidences of SO following primary versus secondary evisceration would be demonstrated, this was not possible as not one case of SO was found in either group. There was also a large discrepancy between the numbers in the two groups (491 versus 11).

In one of the patient's with SO, the VA of 6/9 in the sympathizing eye at last follow up appears to be in keeping with Kilmartin's finding that with prompt treatment, the prognosis in SO is relatively favorable, with 75% of patients in the UK achieving VA of 6/12 or better at one year.¹⁴

The criteria to be considered before primary evisceration can be reasonably entertained as an option are²:

- the affected eye has no light perception and
- a total afferent pupil defect is present and
- there is prolapsed uvea and retina in the wound or
- wounds are longer than 20mm or extend posterior to the equator of the globe and

- the fellow eye is normal and the patient is alert and co-operative (to give informed consent).

Assessment to see how well the patients who had undergone primary evisceration conformed to the first 2 criteria of these guidelines revealed that 71.7% of these patients presented with a VA of NPL and only 40% had a total APD. This may suggest a low threshold for performing evisceration in our department, but also gives an indication of the inaccuracy of VA assessment in the acute trauma setting, since every patient with definite NPL vision should have a total APD.

Another alarming finding was the number of cases with inadequately recorded pertinent findings. For example, 18% of all cases had no record of time between injury and presentation; 18.4% of evisceration cases did not have a record of the presence or absence of APD; and inexplicably, 2.4% of patients who were eviscerated had no record of VA in the involved eye at presentation -- in these cases one can only assume that acuities were measured, but that somehow the findings were not recorded. A recommendation for improved note keeping will have to be made continually.

It is worth noting that according to records of VA at the last follow up visit, most of our patients maintained functional vision (in the uninvolved eye) following their penetrating eye injuries, but that 4.8% of all patients also had poor vision in the uninvolved eye and were blind.

(F) CONCLUSION

Reports on the incidence of SO following penetrating eye trauma have been variable. Bilyk⁸ reported a rate of 0.2 – 0.5%, while Migliori¹ reported 0.1 – 0.3% more recently. Albert¹⁵ quoted an incidence of 0.19%. In this study, a rate of 0.14% was found. This finding therefore seems to be similar to rates found in other studies.

Despite the large number of patients included in the study, no cases of SO were identified either after evisceration (primary and secondary) or after primary repair. This confirms the rarity of SO, although the lack of adequate follow up detracts from this finding.

The low frequency of sympathetic ophthalmia may be explained by a low prevalence of genetic predisposition as well as the ability of the aqueous humor to suppress immune cell function through the actions of certain anti-inflammatory agents, e.g. transforming growth factor-beta.^{11,18} These or other immunosuppressive mechanisms may become disrupted leading to SO in certain cases. Sympathetic Ophthalmia after trauma appears to be becoming increasingly rare. It is reasonable to speculate that timely presentation to medical facilities and improved surgical techniques may be responsible for the disappearance of SO.¹⁶

Benefits of evisceration over enucleation include ease of surgery, better stability and motility, and cosmetic advantages. The overwhelming majority of surveyed ocularists nominated evisceration as their choice of procedure for patients who require removal of an eye.³¹ Although evisceration has become increasingly popular in recent years, enucleations are still performed more commonly than eviscerations.⁵ Ruedemann reported about 200 eviscerations over an 18-year period with no cases of SO found.³² Strampelli and Valvo reported no cases of SO from a series of 1000 eviscerations done over 20 years.³³ In this study, there were no cases of SO found in 502 eviscerations following ocular trauma. As pointed out by Green,²⁴ SO may occur due to uveal tissue remaining behind in scleral emissary channels. Nevertheless, evisceration is still an acceptable choice of procedure with a negligible risk of SO and good cosmetic results. This statement is echoed by Gurdal,²⁷ who also notes that enucleation has a role in trauma cases where severe disruption makes evisceration impossible, but that evisceration with careful removal of uveal tissue does not commonly predispose to SO and therefore should be the procedure of choice.

The authors of a report on a case of SO following a shrapnel injury suggest that it may be prudent to choose enucleation in cases where the injury is so extensive as to make removal of all residual uveal tissue difficult. According to them, evisceration can be reserved for cases of irreparable ocular trauma where damage is more limited. In their case, however, they conclude that the extent of the shrapnel injury might have resulted in residual uveal tissue in the orbit even with enucleation.²⁹

Although this study has its limitations, it would appear that evisceration after severe ocular trauma is an acceptable and safe option with a very low risk of developing SO. However, a multicentric study with an extremely large number of subjects who underwent evisceration would be required to confirm the assumption that has been made here.

(G) ACKNOWLEDGEMENTS

The following people provided the assistance which made the completion of this document possible. Their help therefore needs to be acknowledged and appreciated:

- Dr J. Richards and Dr M. Motala for assistance with setting up the data base.
- Miss P. Luiters and Dr M. Motala for help with data capturing.
- Prof A. Murray for advice on layout and style.

(3) BIBLIOGRAPHY

(A) METHODS OF LITERATURE SEARCH

A search of the MEDLINE-PUBMED database was conducted using the key words *evisceration*, *sympathetic ophthalmia*, *enucleation* and *ocular trauma*. Additional references were taken from the bibliographies of these references. References were evaluated for their pertinence to the topic.

(B) REFERENCES

1. Migliori, ME. Enucleation versus evisceration. *Curr Opin Ophthalmol*. 2002; 13:298-302.
2. Moshfeghi DM, Moshfeghi AA, Finger PT. Enucleation. *Surv Ophthalmol*. 2000; 44:277-301.
3. Cytryn AS, Perman KI. Evisceration. In: Migliori ME, editor. *Enucleation, evisceration and exenteration of the eye*. Boston: Butterworth-Heinemann; 1999. p. 105-12.
4. Hansen AB, Petersen C, Heegaard S, et al. Review of 1028 bulbar eviscerations and enucleations: changes in aetiology and frequency over a 20-year period. *Acta Ophthalmol Scand*. 1999; 77:331-5.
5. Levine MR, Pou CR, Lash RH. The 1998 Wendell Hughes Lecture. Evisceration: is sympathetic ophthalmia a concern in the new millennium? *Ophthal Plast Reconstr Surg*. 1999; 15:4-8.
6. Walter WL. Update on enucleation and evisceration surgery. *Ophthal Plast Reconstr Surg*. 1985; 1:243-52.
7. Stephenson CM. Evisceration. In: Hornblass A, editor. *Oculoplastic, Orbital and Reconstructive Surgery*. Baltimore: Williams & Wilkins; 1990. p. 1194-9.
8. Bilyk, JR. Enucleation, evisceration and sympathetic ophthalmia. *Curr Opin Ophthalmol*. 2000; 11:372-85.

9. Lyon DB, Dortzbach RK. Enucleation and evisceration. In: Shingleton BJ, editor. Eye trauma. St Louis: Mosby Year-Book, Inc.; 1991. p. 109-21.
10. McCormack P. Penetrating injury of the eye. *Br J Ophthalmol*. 1999; 83:1101-2.
11. Gasch AT, Foster CS, Grosskreutz CL, et al. Postoperative sympathetic ophthalmia. *Int Ophthalmol Clin*. 2000; 40:69-84.
12. Lubin JR, Albert DM, Weinstein M. Sixty-five years of sympathetic ophthalmia: a clinicopathologic review of 105 cases (1913-1978). *Ophthalmology* 1980; 87:109-21
13. Chu DS, Foster CS. Sympathetic ophthalmia. *Int Ophthalmol Clin*. 2002; 42(3):179-85.
14. Kilmartin DJ, Dick AD, Forrester JV. Prospective surveillance of sympathetic ophthalmia in the UK and Republic of Ireland. *Br J Ophthalmol*. 2000; 84:259-63.
15. Albert DM, Diaz-Rohena R. A historical review of sympathetic ophthalmia and its epidemiology. *Surv Ophthalmol*. 1989; 34:1-14.
16. Wong TY, Seet MB, Ang CL. Eye injuries in twentieth century warfare: a historical perspective. *Surv Ophthalmol*. 1997; 41:433-59.
17. Goto H, Rao NA. Sympathetic ophthalmia and Vogt-Koyanagi-Harada syndrome. *Int Ophthalmol Clin*. 1990; 30:280-5.
18. Ramadan A, Nussenblatt RB. Visual prognosis and sympathetic ophthalmia. *Curr Opin Ophthalmol*. 1996; 7:39-45.
19. Kinyoun JL, Bensinger RE, Chuang EL. Thirty-year history of sympathetic ophthalmia. *Ophthalmology* 1983; 90:59-65.
20. Font RL, Fine BS, Messmer E, et al. Light and electron microscopic study of Dalen-Fuch's nodules in sympathetic ophthalmia. *Ophthalmology* 1983; 90:66-75.
21. Rao NA, Robin J, Hartmann D, et al. The role of penetrating wound in the development of sympathetic ophthalmia. *Arch Ophthalmol*. 1983; 101:102-4.

22. Power WJ, Foster CS: Update on sympathetic ophthalmia. *Int Ophthalmol Clin.* 1995; 35:127-37.
23. Towler HMA, Lightman W. Sympathetic ophthalmia. *Int Ophthalmol Clin.* 1995; 35:31-42.
24. Green WR, Maumenee AE, Sanders TE, et al. Sympathetic uveitis following evisceration. *Trans Amer Acad Ophthalmol Otolaryngol.* 1972; 76:625-44.
25. Ikui H, Ueno K. Six cases of sympathetic ophthalmia developing after evisceration. *Nippon Ganka Kyo* 1965; 16(8):458-67. MEDLINE
26. Tachfouti S, Kherrmane A, Cherkaoui O, et al. Sympathetic ophthalmia: Apropos of five cases. *J Fr Ophthalmol* 1997; 20(7):515-20. Abstract-MEDLINE
27. Gurdal C, Erdener U, Irkec M, et al. Incidence of sympathetic ophthalmia after penetrating eye injury and choice of treatment. *Ocul Immunol Inflamm.* 2002; 10(3):223-7.
28. Dreyer WB, Zegarra H, Zakov ZN, et al. Sympathetic ophthalmia. *Am J Ophthalmol.* 1981; 92(6):816-23.
29. Freidlin J, Pak J, Tessler H, et al. Sympathetic Ophthalmia after injury in the Iraq War. *Ophthal Plast Reconstr Surg.* 2006; 22(2):133-4.
30. Dada T, Ray M, Tandon R, et al. The epidemiology and diagnosis of penetrating eye injuries. *Acad Emerg Med.* 2002; 9(3):209-13.
31. Timothy NH, Freilich DE, Linberg JV. Evisceration versus enucleation from the ophthalmologist's perspective. *Ophthal Plast Reconstr Surg.* 2003; 19(6):417-20.
32. Ruedemann AD. Sympathetic Ophthalmia after evisceration. *Trans Am Ophthalmol Soc.* 1963; 61:274-314.
33. Strampelli B. and Valvo A: Durable mobility of ocular prosthesis: late results of a personal technique with 18 years experience. *Am J Ophthalmol.* 1966; 62:634.