

**Resection of biliary mucinous cystic neoplasms**  
**Study of a single institutional cohort**  
**and a literature review**

by

**CHRISTO (JC) KLOPPERS**

KLPCHR003

Submitted as a minor dissertation in partial fulfilment of the requirements for the degree

**MASTER OF PHILOSOPHY (SURGICAL GASTROENTEROLOGY)**



Department of Surgery: Surgical Gastroenterology

Faculty of Health Sciences

UNIVERSITY OF CAPE TOWN

**Supervisors: Professors Jake Krige and Eduard Jonas**

Date of submission: 15 August 2017

The copyright of this thesis vests in the author. No quotation from it or information derived from it is to be published without full acknowledgement of the source. The thesis is to be used for private study or non-commercial research purposes only.

Published by the University of Cape Town (UCT) in terms of the non-exclusive license granted to UCT by the author.

## Declaration

I, **Jacobus Christoffel Kloppers**, hereby declare that the work on which this dissertation/thesis is based is my original work (except where acknowledgements indicate otherwise) and that neither the whole work nor any part of it has been, is being, or is to be submitted for another degree in this or any other university.

I empower the university to reproduce for the purpose of research either the whole or any portion of the contents in any manner whatsoever.

Signature: 

Signed by candidate
---------------------

Date: 15 August 2017

## Acknowledgements

To my supervisors: Professors Jake Krige and Eduard Jonas, for their mentorship.

To my parents: Johan and Fransie, for my talents.

To my family: Michelle, Hannes and George, from whom I borrowed time for this project.

## Table of contents

<b>Part A: Study protocol</b>	pg. 5
<b>Part B: Structured literature review</b>	
Literature search strategy	pg. 9
Objectives of literature review	pg. 10
Definition and classification	pg. 10
Pathology	pg. 14
Clinical presentation	pg. 15
Special investigations	pg. 17
Treatment	pg. 20
Prognosis	pg. 22
Summary and future perspectives	pg. 22
References	pg. 23
<b>Part C: Publication ready original manuscript</b>	
Title page	pg. 27
Abstract	pg. 28
Article	pg. 29
References	pg. 38
<b>Part D: Supporting documents</b>	
Abbreviations and acronyms	pg. 41
Index of tables and figures	pg. 42
Author guidelines of South African Journal of Surgery	pg. 43
Departmental Research Committee approval	pg. 47
Human Research Ethics Committee approval	pg. 48

## Part A - Study protocol

Study Title: **Resection of biliary mucinous cystic neoplasms: Study of a single institutional cohort and a literature review**

Principal investigators: **Profs E Jonas and JEJ Krige**

Co-investigator: **Dr JC Kloppers**

### **Introduction and background:**

Intrahepatic biliary cystadenoma was initially described in 1887 with the first resection performed in 1892. In 1958 Edmondson defined strict criteria as definition of cystadenoma which included the lesion to be multilocular with ovarian-like stroma. In 1994 Devaney et al. evaluated the pathology of 70 cases and observed the presence of ovarian stroma to be inconsistent and proposed that biliary cystadenomas could occur with or without ovarian stroma.<sup>1,2</sup> The World Health Organization Classification of Tumours 3<sup>rd</sup> Edition published in 2000 described the disease entity biliary cystadenomas and cystadenocarcinomas.<sup>3</sup> There however remains confusion in the literature and biliary cystadenomas were reclassified in the 4<sup>th</sup> Edition published in 2010 as biliary mucinous cystic neoplasms (BMCNs), either non-invasive or invasive. BMCNs have no biliary communication and should have ovarian-like stroma to confirm the diagnosis.<sup>4</sup> Biliary cystadenomas are rare and account for less than 5% of all cystic lesions. As more incidental simple cysts are diagnosed, this number is likely to shrink.<sup>5</sup>

More than 90% of all BCMNs occur in females. Many studies with more than 10 patients include only women.<sup>4,6</sup> This almost exclusive female predominance suggests a hormonal influence. The age of presentation is highly variable but peaks around the 4<sup>th</sup> and 5<sup>th</sup> decade. Patients may be asymptomatic with the cystic neoplasm diagnosed incidentally on

imaging or during surgery for a different indication. It is likely that a significant percentage of BCMNs are mistaken for simple hepatic cysts and left untreated.<sup>7</sup>

Formal surgical resection with negative margins remains the recommended treatment. Appropriate surgical strategies include liver resection or enucleation depending on the individual patient, anatomic position of the cyst, and surgeon experience.<sup>8,9</sup>

BMCNs are complex problems and should be the primary diagnostic consideration in middle aged women who have well encapsulated multilocular cystic liver tumours. The histologic classification has evolved considerably and surgical resection still offers optimal treatment. Due to the unpredictable malignant risk and tendency for late recurrence, these patients also need long term follow up.<sup>10,11</sup>

### **Objectives:**

The aim is to study the:

1. The profile of patients with a BMCNs
2. The operative procedure and outcomes in a large South African referral centre.

### **Methods:**

Data from a departmental and faculty registered prospective liver resection database will be used to identify patients who underwent surgery for BMCNs in the HPB Surgical Unit at Groote Schuur Hospital during a 15 year period (1999 to 2015). This registry has been

approved by the Human Research Ethics Committee (HREC) (R024/2014). The data will be retrospectively analyzed.

An estimate of 15 patients will be evaluated. Patient's age, gender, symptoms and signs will be recorded. The size and location of the liver lesion will be studied.

The following parameters regarding the operative procedure will be collected:

- Type of resection (formal liver resection, resection by enucleation, partial resection)
- Use of inflow occlusion
- Need for intra-operative transfusion
- Frozen section taken
- Drain use or not
- Operative time in minutes
- ICU stay in days and hospital stay in days
- Final histology
- Outcome and follow up of patient

This will largely be a descriptive study which would require minimal statistical analysis.

**Ethical considerations:**

Only data from the HREC approved database (R024/2014) will be used. No risks to the patients are anticipated and patient records will be treated confidentially with only the principal investigator having access. Any reports or publications resulting from the research will maintain the anonymity of the individual study participants.

## **Budget:**

Apart from basic stationery, no expenses are anticipated.

## **References:**

1. Emre A, Serin KR, Ozden I, et al. Intrahepatic biliary cystic neoplasms: Surgical results of patients and literature review. *World J Gastroenterol*. 2011;17(3):361-365.
2. Devaney K, Goodman ZD, Ishak KG. Hepatobiliary cystadenoma and cystadenocarcinoma. A light microscopic and immunohistochemical study of 70 patients. *Am J Surg Pathol*. 1994;18(11):1078-1091.
3. Kishida N, Shinoda M, Masugi Y, et al. Cystic tumor of the liver without ovarian-like stroma or bile duct communication: Two case reports and a review of the literature. *World J Surg Oncol*. 2014;12:229-7819-12-229.
4. Choi HK, Lee JK, Lee KH, et al. Differential diagnosis for intrahepatic biliary cystadenoma and hepatic simple cyst: Significance of cystic fluid analysis and radiologic findings. *J Clin Gastroenterol*. 2010;44(4):289-293.
5. Kloppers JC, Krige JEJ, Bernon M, Thomson SR. Nomenclature for neoplastic biliary cysts : Review. *South African Gastroenterology Review*. 2016;14(1):19-23.
6. Wang K, Kong F, Dong M, Zhou J, Li Y. Diagnosis and treatment of intrahepatic biliary cystadenoma: Experience with 14 cases in a single center. *Med Oncol*. 2014;31(11):274-014-0274-3. Epub 2014 Oct 7.
7. Borhani AA, Wiant A, Heller MT. Cystic hepatic lesions: A review and an algorithmic approach. *AJR Am J Roentgenol*. 2014;203(6):1192-1204.
8. Ratti F, Ferla F, Paganelli M, Cipriani F, Aldrighetti L, Ferla G. Biliary cystadenoma: Short- and long-term outcome after radical hepatic resection. *Updates Surg*. 2012;64(1):13-18.
9. Martel G, Alsharif J, Aubin JM, et al. The management of hepatobiliary cystadenomas: Lessons learned. *HPB (Oxford)*. 2013;15(8):617-622.
10. Manouras A, Markogiannakis H, Lagoudianakis E, Katergiannakis V. Biliary cystadenoma with mesenchymal stroma: Report of a case and review of the literature. *World J Gastroenterol*. 2006;12(37):6062-6069.
11. Chen YW, Li CH, Liu Z, Dong JH, Zhang WZ, Jiang K. Surgical management of biliary cystadenoma and cystadenocarcinoma of the liver. *Genet Mol Res*. 2014;13(3):6383-6390.

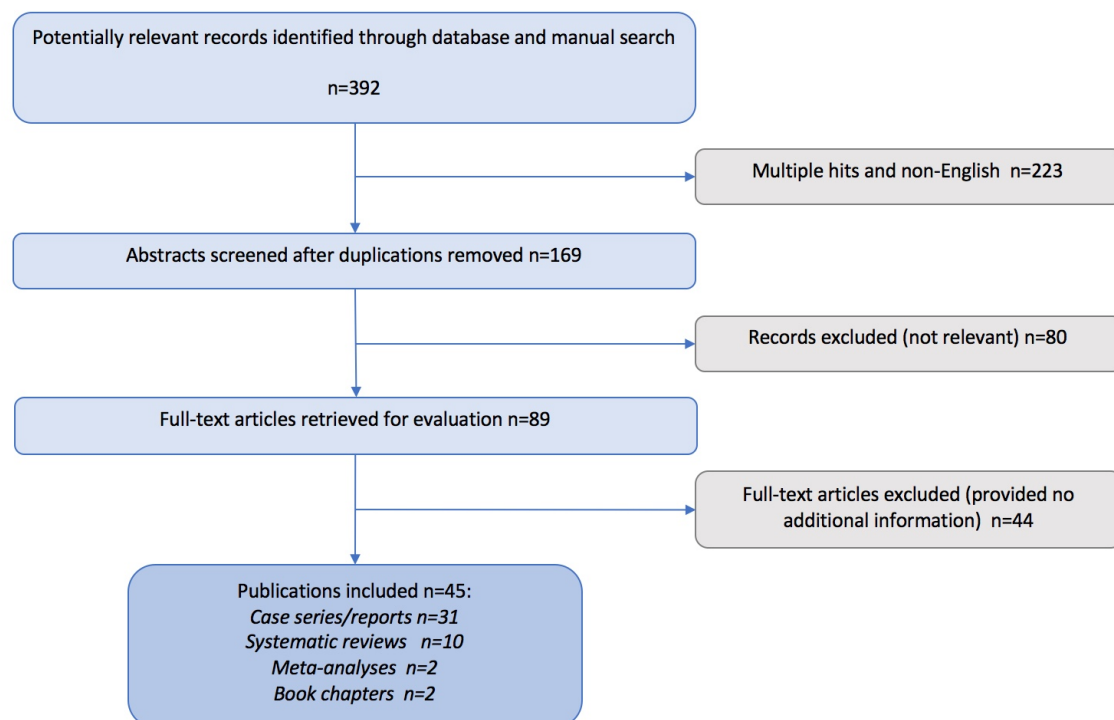
## Part B - Structured literature review

### Biliary mucinous cystic neoplasms of the liver

#### Literature search strategy

A structured literature review was performed searching the electronic databases of Pubmed and Google Scholar using the search thread (*mucinous biliary cystic neoplasms*) OR (*biliary cystadenoma*) OR (*biliary cystadenocarcinoma*) OR (*ovarian stroma*). Additional manual searches of the Cochrane Library, National Comprehensive Cancer Network guidelines and World Health Organization publications were also performed. References were cross checked. Only human studies in English were included.

Figure 1: Algorithm for literature search



## **Objectives of literature review**

Liver cysts are commonly encountered in clinical practice and with the widespread use of liver ultrasound and cross sectional imaging are identified as an incidental finding with increasing frequency.<sup>1</sup> The differential diagnosis includes a spectrum of lesions, from benign lesions with little clinical significance to malignant tumours.<sup>2</sup> The incidence of the different cysts depends on the population studied. In the South African context the more commonly encountered cystic lesions are simple liver cysts, abscesses and hydatid cysts. Biliary mucinous cystic neoplasms (BMCNs) account for less than 5% of liver cysts and as more incidental simple cysts are identified on imaging, the ratio is likely to decline.<sup>3</sup> The first account of an intrahepatic biliary cystadenoma was published in 1887 with the first resection performed in 1892.<sup>4</sup> This literature review aims to describe the evolution in interpretation of the histopathological features, to outline the diagnostic features in the context of the differential diagnosis and to detail management of these uncommon tumours.

## **Definition and classification**

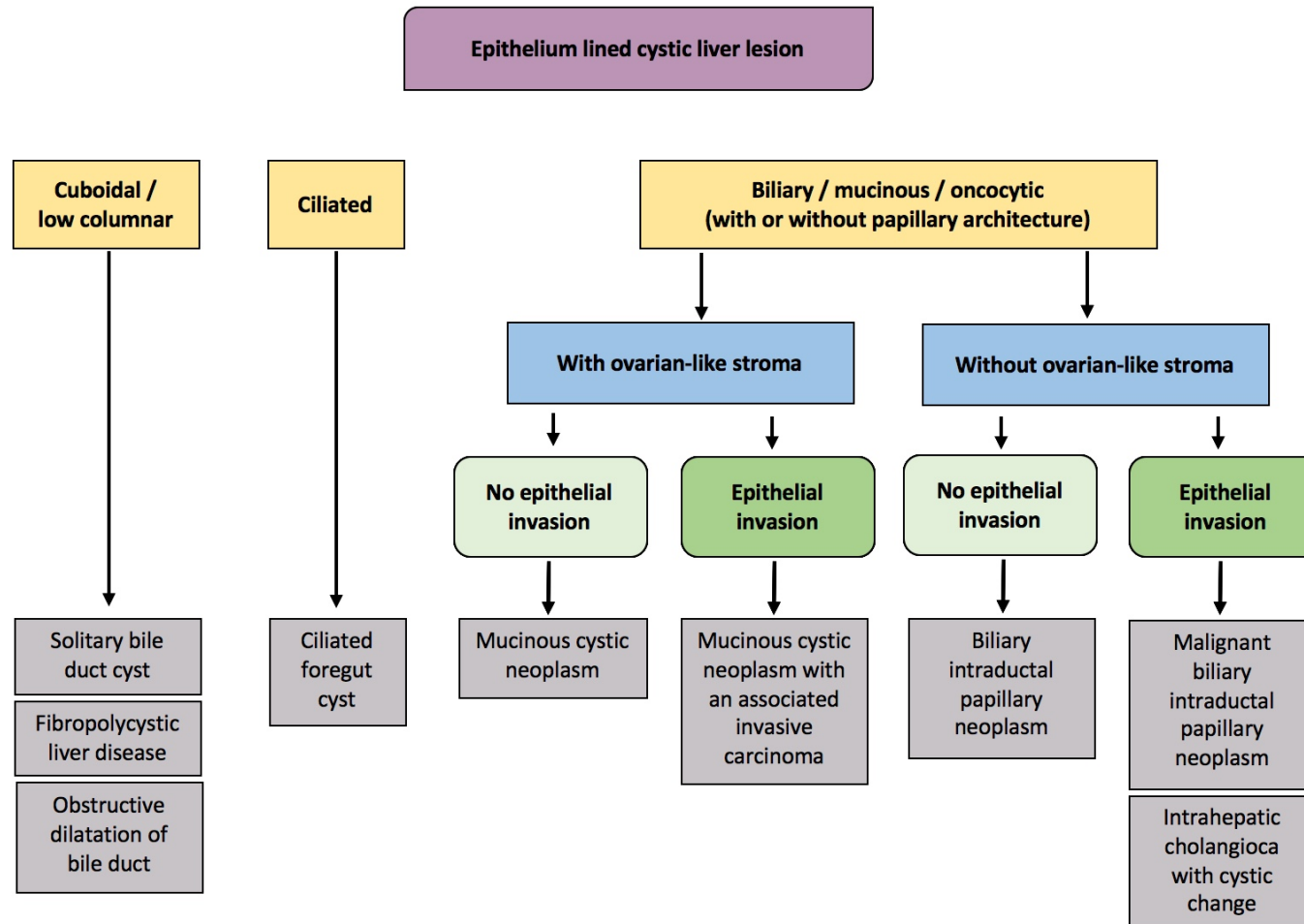
In 1958 Edmondson defined strict criteria for the diagnosis of biliary cystadenoma, namely the presence of ovarian-like stroma (OS) surrounding a multilocular cystic liver lesion.<sup>4</sup> In 1994 Devaney et al. noted in a pathological review of 70 cases that the presence of OS was inconsistent and suggested that biliary cystadenomas may occur with or without OS being present.<sup>5</sup> In 2000 the World Health Organization defined the terms biliary cystadenoma and cystadenocarcinomas to describe the benign and malignant components of the disease entity.<sup>6,7</sup> The classification was revised in 2010 suggesting the following definition: "Mucinous cystic neoplasms (MCNs) are cyst-forming epithelial neoplasms, usually with no

communication with the bile ducts, composed of cuboidal to columnar epithelium with variable mucin production and associated with ovarian-type sub-epithelial stroma.” BMCNs are subdivided into non-invasive and invasive (previously known as biliary cyst-adenocarcinoma).<sup>8,9</sup> The neoplasms without OS are classified as intraductal papillary neoplasms (IPNs) of the bile ducts with marked cystic changes. As bile duct communication which is required for defining IPNs is seldom present, this classification is still incomplete. Neoplasms without OS and BDC do not fit into either description. The nomenclature is summarized in Table 1. Consensus has not been reached and there are still numerous reports of cystadenomas without OS and the nomenclature of the 2000 WHO classification is still widely used.

**Table 1. Comparison World Health Organization (WHO) classification of mucinous cystic liver neoplasms<sup>6,8,10</sup>**

<b>WHO 2000</b>	<b>WHO 2010</b>	
<b>Prior nomenclature</b>	<b>Current nomenclature</b>	<b>Key Features</b>
Biliary cystadenoma	Non-invasive biliary mucinous cystic neoplasm (ni-BMCN)	Needs ovarian-like stroma No bile duct communication
Biliary cystadenocarcinoma	Invasive biliary mucinous cystic neoplasm (i-BMCN)	Needs ovarian-like stroma No bile duct communication
Not previously classified	Intraductal papillary mucinous neoplasm – biliary type (IPMN-B)	No ovarian-like stroma Needs bile duct communication

Figure 2. Pathological diagnostic algorithm for epithelium lined cystic liver lesions (*Adapted from: WHO Classification of Tumours of the Digestive System, Fourth Edition*)<sup>8</sup>



## Pathology

BMCNs occur as large solitary, multiloculated complex cysts with internal septations and mural nodularity, surrounded by a dense cellular fibrostroma.<sup>11,12</sup> Size varies from 2cm to 40cm at presentation, with mean sizes of around 15cm being reported.<sup>3,13,14</sup> The majority of cysts are centrally located in the liver but may occur in the right or left hemi-livers.<sup>9</sup>

BMCNs are usually globular, with a smooth external surface and a smooth or trabeculated inner lining. The cyst usually contains clear mucinous fluid but may be bile stained, even in the absence of a distinct biliary communication.<sup>12,15</sup> BMCNs are characterized by three histological layers, namely:<sup>15-17</sup>

- an inner biliary-type epithelial layer containing cuboidal to columnar cells which may produce mucin;
- a layer of dense undifferentiated mesenchymal cells resembling OS deep to the epithelial lining; the stromal cells are spindle-shaped and usually immunoreactive with vimentin, alpha-smooth muscle actin and less frequently estrogen and progesterone receptors;
- a dense outer collagenous layer, consisting of connective tissue, separates the cyst from liver parenchyma and often provides a surgical plane for enucleation.

## **Clinical presentation**

The vast majority of BMCNs occur in women. This female predominance suggests a hormonal influence.<sup>18</sup> The age at presentation varies but the peak occurs in the 4<sup>th</sup> and 5<sup>th</sup> decades.<sup>19</sup> Patients may be asymptomatic with the cystic lesion discovered incidentally on imaging or during surgery for other indications.<sup>20-22</sup> Symptomatic patients present with an insidious onset of symptoms due to the slow growing nature of the tumour.<sup>12,19</sup> Vague upper abdominal pain and fullness are common presenting symptoms.<sup>23</sup> It may be accompanied by dyspepsia, anorexia, nausea and a palpable abdominal mass.<sup>24</sup> Jaundice due to biliary obstruction caused by compression of the tumour is uncommon.<sup>25</sup> Complications, for example cyst rupture, bacterial infection, intracystic haemorrhage and inferior vena cava obstruction are rare.<sup>26-28</sup> In Table 2 key clinical and biochemical features that may aid in characterizing cystic lesions of the liver are presented.

**Table 2. Clinical and biochemistry characteristics of the most common cystic lesions of the liver<sup>10</sup>**

Cystic lesion	Demography	Clinical picture	Blood/cyst fluid analyses
<b>Non-infective</b>			
<b>Simple cyst</b>	Non specific	Vague RUQ pain Incidental	Non specific
<b>Biliary MCN</b>	Middle age females	Epigastric or RUQ pain Palpable mass Could be asymptomatic	Non specific Unlike MCNs of pancreas, aspiration not helpful
<b>Polycystic disease</b>	Genetic predisposition	Generally asymptomatic RUQ pain	Renal dysfunction if kidneys involved
<b>Biliary hamartoma (Von Meyenburg complex)</b>	Non specific	Mostly asymptomatic Incidental	Non specific
<b>Caroli's disease</b>	Congenital disease	Recurrent attacks of RUQ pain Cholangitis	Non specific
<b>Infective / Parasitic</b>			
<b>Hydatid (echinococcal cyst)</b>	Endemic area	Asymptomatic or RUQ pain Hepatomegaly Occasionally jaundice	Positive serology (False negative in 20%)
<b>Pyogenic abscess</b>	Abdominal sepsis Biliary intervention IV drug users	Pyrexia and rigors Severe RUQ pain Weight loss Systemically unwell	Elevated infective markers (WCC) Positive cyst and/or blood cultures
<b>Amoebic abscess</b>	Endemic area	High fever Severe RUQ pain	ELISA positive (90% sensitivity) Typical "anchovy paste" appearance of abscess content

RUQ: Right upper quadrant

## Special investigations

Liver function tests are usually normal, but elevated bilirubin, alkaline phosphatase (ALP) and gamma-glutamyl transpeptidase (GGT) may occur with intra- or extrahepatic biliary duct compression.<sup>9</sup> Serum tumour markers are of limited diagnostic value. Wang et al. found in a series of 30 patients that carbohydrate antigen 19-9 (CA 19-9) was elevated in only 57.1% of the cases.<sup>13</sup> If hydatid disease is suspected, full blood count, serology and immunological testing may be helpful.<sup>29</sup> Unlike carcinoembryonic antigen (CEA) and CA 19-9, a tumour-associated glycoprotein 72 (TAG 72) concentration of more than 25 units/ml differentiated hepatic simple cysts from mucinous cysts with a sensitivity and a specificity of 0,79 and 0,97 respectively in a recent study of 27 mucinous liver cysts.<sup>30</sup> However, TAG 72, also known as CA 72-4 is not universally available and the results of this small cohort has not been replicated. Fine needle aspiration and cyst fluid analysis have thus not been proven to influence the management and may be potentially harmful in that malignant cells may disseminate in patients with an invasive BMCN.<sup>12,14</sup>

Differentiating BMCNs from other cystic lesions in the liver are primarily imaging-based.<sup>12,31</sup> Ultrasound (US), computed tomography (CT) and magnetic resonance imaging (MRI) characteristics of the most common cystic liver lesions are shown in Table 3. US may be able to confidently diagnose BMCNs if the characteristic findings, a well-demarcated, mostly multilocular hyperechogenic mass, which may have septae and with characteristic papillary projections from the cyst wall are present.<sup>9</sup> It is particularly helpful in distinguishing BMCNs from simple cysts, typically well demarcated with anechoic unilocular fluid-filled spaces with imperceptible walls and posterior acoustic enhancement and hydatid liver disease especially in the presence of daughter cysts, hydatid sand and typical septae.<sup>32</sup>

CT and MRI are useful for more accurate characterization of lesions. Common BMCN features on CT include low-density, well defined, lobulated, multilocular, thick-walled cystic lesions with internal septa and occasionally mural nodules.<sup>9,14</sup> The presence of intrahepatic or extrahepatic bile duct dilatation is usually also evident. Mild central intrahepatic dilation is often a feature of BMCNs, due to compression of the bile duct.<sup>33</sup>

On MRI BMCNs are typically well-defined lesions that do not enhance after the administration of intravenous gadolinium. On T1-weighted sequences the cysts show low signal intensity, whereas on T2 weighted sequences a very high intensity signal is seen. However, no MRI parameters can confidently predict the presence of OS.<sup>32</sup> Cross-sectional imaging furthermore allows better morphological assessment and orientation, including appraisal of segmental engagement of the lesion as well as determining proximity to vital vascular and biliary structures, information that is crucial for optimal surgical planning.<sup>34</sup>

US, CT or MRI findings cannot reliably distinguish non-invasive from invasive BMCNs and all lesions should be treated as potentially malignant.<sup>35-37</sup>

**Table 3. US, CT and MRI characteristics of the most common cystic liver lesion<sup>10</sup>**

Cystic lesion	US	CT	MRI \ MRCP
<b>Simple cyst</b>	Single or multiple Well circumscribed anechoic structure with enhancement of the posterior wall	Well-defined Attenuation (0–15 HU) similar to water No enhancement with contrast	Well-defined T1: hypointense T2: hyperintense
<b>Biliary MCN</b>	Single Anechoic mass with occasional internal septations or papillary projections	Complex solitary well-defined, multilocular Occasional upstream bile duct dilatation Internal septations, enhancement of walls	Multilocular mass Septated Homogeneous high (T2) signal intensity
<b>Polycystic disease</b>	Multiple Hypoechoic Thin-walled cysts of varying sizes	Multiple simple cysts	T1: Very low signal intensity T2: Homogeneous high signal intensity
<b>Biliary hamartoma (Von Meyenburg complex)</b>	Multiple Variable because of the small lesion size	Multiple, small (< 15 mm), round or irregular scattered cysts Predilection for the subcapsular region	Multiple, tiny cystic lesions with irregular borders MRCP - no biliary communication
<b>Caroli's disease</b>	Multiple of varying size Dilated cystic structures which communicate with the biliary tree	Cystic and usually have a central enhancing component, the “central dot” sign	MRCP - demonstrates communication between the Caroli's cysts and the biliary tee
<b>Hydatid (echinococcal cyst)</b>	Single or multiple Purely cystic to solid-appearing lesions Daughter cyst or echogenic debris	Well-defined, hypo-attenuating lesion with a distinguishable wall Daughter cyst identified in majority Calcification in mature cysts	T2 sequence: Pericyst has a hypointense rim Hydatid debris is markedly hyperintense Daughter cysts are hypointense
<b>Pyogenic abscess</b>	Single or multiple Anechoic mass with well-defined or indistinct borders and may possibly contain echogenic debris or gas	Iso- to hypo-attenuating compared with background liver on the unenhanced phase Peripheral rim of enhancement	Variable signal intensity Peri-lesional oedema
<b>Amoebic abscess</b>	Single or multiple Hypoechoic round or oval lesions Show low-level internal echoes and posterior acoustic enhancement	Slightly higher attenuation than water Smooth or nodular borders Thick wall that typically enhances	The central portion appears cystic The ring exhibits variable intensities on T1- and T2-weighted imaging

## Treatment

The prerequisite for optimal management of BMCNs is accurate pre-operative diagnosis. A BMCN misdiagnosed as a simple cyst and treated as such, usually aspiration or deroofting, will recur. The mainstay of treatment for BMCNs is complete resection. Incomplete resection will result in recurrence, requiring re-operation with the morbidity associated with re-operation.<sup>9,14</sup> Techniques such as aspiration, internal drainage, intracystic sclerosant injection and incomplete resection have recurrence rates of 90-100%.<sup>38,39</sup> In the largest single centre series to date, Chen et al. reported treatment and outcome in 39 patients. All patients were treated surgically, seven of whom were incorrectly diagnosed before surgery. These included four patients in whom the cysts were diagnosed as simple hepatic cysts, two diagnosed as abscesses and one diagnosed as intrahepatic bile duct stones. Liver resection was performed in 17 patients (eight right and nine left hemi-hepatectomies) and enucleation was performed in 22 patients. In all patients with pre-operative symptoms the symptoms resolved after surgery. There were no major complications or mortalities. At a median of 20 months follow up one patient presented with recurrence.<sup>24</sup>

Thomas et al. describe two patients with large BMCNs in whom fenestration and complete fulguration was used successfully. In one patient with an invasive BMCN, a formal resection of the main lesion was performed and a satellite lesion was unroofed with fulguration of the internal cystic lining with argon beam coagulation. The other patient with a 16 cm lesion in the right liver underwent laparoscopic exploration with fenestration and fulguration of the cyst bed. Neither of the patients developed recurrent disease at five and one years follow-up respectively. The series, however, is too small to recommend this as a routine treatment method, but could be an option for BMCNs in difficult anatomical positions.<sup>40</sup>

Koffron et al. proposed a laparoscopic approach to BMCNs after successfully treating 22 patients laparoscopically with only one recurrence on a mean 16 months follow-up. Cognizant of previous reports of recurrence after fenestration and marsupialization, the authors performed the widest possible marsupialization in patients where complete resection was precluded by proximity to central biliary structures or large vessels. In the 11 patients treated in this fashion the small portion of the remaining cyst wall was left untreated. The short follow-up in the study, however, is of concern.<sup>41</sup>

There is a single case report of a transplant for a symptomatic BMCN that involved the central biliary and vascular structures. An unsuccessful attempt at resection resulted in a non-reconstructable intrahepatic biliary injury that warranted a transplant.<sup>42</sup>

Complete surgical resection with negative margins remains the recommended treatment.<sup>43,44</sup> This is achieved by formal liver resection for peripheral lesions and those limited to a hemi-liver or enucleation in centrally located lesions that involve vital vascular and/or biliary structures. A laparoscopic approach is acceptable but should not be pursued relentlessly at the cost of a non-radical resection.

## **Prognosis**

The prognosis in completely resected BMCNs is excellent, with 10 year survival approaching 100%.<sup>9</sup> Recurrences after complete resection of cysts are seen in less than 10% of patients.<sup>4,24</sup> Older age, male gender and shorter duration of symptoms on presentation are associated with a higher possibility of invasive BMCNs.<sup>13</sup> All patients should be followed up after resection for BMCNs with abdominal ultrasound. There are no clear guidelines or consensus on follow-up regarding the modality and frequency. In patients who would be candidates for re-intervention most authors suggest follow up with non-radiation modalities (US or MRI) at 6 to 12 month intervals for a duration of 3 to 5 years.<sup>14,15,23,40,45</sup>

## **Summary and future perspectives**

BMCNs are complex liver lesions and should be considered in middle aged women who have well encapsulated multilocular cystic liver tumours. While the histologic classification has evolved considerably, further refinements are required, specifically addressing the issue of lesions without OS. This should resolve some of the current controversies and will facilitate standardized reporting. Complete surgical resection, although often complex due to central location of lesions, provides curative treatment. Due to the unpredictable malignant risk and tendency for late recurrence patients with BMCNs need careful long-term follow up.

## References

1. Carrim ZI, Murchison JT. The prevalence of simple renal and hepatic cysts detected by spiral computed tomography. *Clin Radiol*. 2003;58(8):626-629.
2. Borhani AA, Wiant A, Heller MT. Cystic hepatic lesions: A review and an algorithmic approach. *AJR Am J Roentgenol*. 2014;203(6):1192-1204.
3. Choi HK, Lee JK, Lee KH, et al. Differential diagnosis for intrahepatic biliary cystadenoma and hepatic simple cyst: Significance of cystic fluid analysis and radiologic findings. *J Clin Gastroenterol*. 2010;44(4):289-293.
4. Emre A, Serin KR, Ozden I, et al. Intrahepatic biliary cystic neoplasms: Surgical results of 9 patients and literature review. *World J Gastroenterol*. 2011;17(3):361-365.
5. Devaney K, Goodman ZD, Ishak KG. Hepatobiliary cystadenoma and cystadenocarcinoma. A light microscopic and immunohistochemical study of 70 patients. *Am J Surg Pathol*. 1994;18(11):1078-1091.
6. Wittekind C, Fisher HP, Ponchon T. Bile duct cystadenoma and cystadenocarcinoma. In: Hamilton SR, Aaltonen LA, eds. *WHO pathology and genetics of tumours of the digestive system*. 3rd ed. ; 2000:182-183.
7. Kishida N, Shinoda M, Masugi Y, et al. Cystic tumor of the liver without ovarian-like stroma or bile duct communication: Two case reports and a review of the literature. *World J Surg Oncol*. 2014;12:229-7819-12-229.
8. Thsui WMS, Adsay NV, Crawford JM, Hruban R, Kloppel G, Wee A. Mucinous cystic neoplasms of the liver. In: Bosman FT, Carneiro F, Hruban RH, Theise ND, eds. *WHO classification of tumours of the digestive system*. 4th Edition ed. ; 2010:236-259.
9. Simo KA, Mckillop IH, Ahrens WA, Martinie JB, Iannitti DA, Sindram D. Invasive biliary mucinous cystic neoplasm: A review. *HPB (Oxford)*. 2012;14(11):725-740.
10. Kloppers JC, Krige JEJ, Bernon M, Thomson SR. Nomenclature for neoplastic biliary cysts : Review. *South African Gastroenterology Review*. 2016;14(1):19-23.
11. Buetow PC, Buck JL, Pantongrag-Brown L, et al. Biliary cystadenoma and cystadenocarcinoma: Clinical-imaging-pathologic correlations with emphasis on the importance of ovarian stroma. *Radiology*. 1995;196(3):805-810.

12. Manouras A, Markogiannakis H, Lagoudianakis E, Katergiannakis V. Biliary cystadenoma with mesenchymal stroma: Report of a case and review of the literature. *World J Gastroenterol*. 2006;12(37):6062-6069.
13. Wang C, Miao R, Liu H, et al. Intrahepatic biliary cystadenoma and cystadenocarcinoma: An experience of 30 cases. *Dig Liver Dis*. 2012;44(5):426-431.
14. Arnaoutakis DJ, Kim Y, Pulitano C, et al. Management of biliary cystic tumors: A multi-institutional analysis of a rare liver tumor. *Ann Surg*. 2015;261(2):361-367.
15. Soares KC, Arnaoutakis DJ, Kamel I, et al. Cystic neoplasms of the liver: Biliary cystadenoma and cystadenocarcinoma. *J Am Coll Surg*. 2014;218(1):119-128.
16. Albores-Saavedra J, Cordova-Ramon JC, Chable-Montero F, Dorantes-Heredia R, Henson DE. Cystadenomas of the liver and extrahepatic bile ducts: Morphologic and immunohistochemical characterization of the biliary and intestinal variants. *Ann Diagn Pathol*. 2015;19(3):124-129.
17. Gomez-Martin C, Rodriguez A, Malon D, Cortes-Funes H. Biliary cystadenocarcinoma with mesenchymal stroma. *Clin Transl Oncol*. 2010;12(3):234-237.
18. Kim HH, Hur YH, Koh YS, Cho CK, Kim JW. Intrahepatic biliary cystadenoma: Is there really an almost exclusively female predominance? *World J Gastroenterol*. 2011;17(25):3073-3074.
19. Hernandez Bartolome MA, Fuerte Ruiz S, Manzanedo Romero I, et al. Biliary cystadenoma. *World J Gastroenterol*. 2009;15(28):3573-3575.
20. Martel G, Alsharif J, Aubin JM, et al. The management of hepatobiliary cystadenomas: Lessons learned. *HPB (Oxford)*. 2013;15(8):617-622.
21. Fiamingo P, Veroux M, Cillo U, Basso S, Buffone A, D'Amico DF. Incidental cystadenoma after laparoscopic treatment of hepatic cysts: Which strategy? *Surg Laparosc Endosc Percutan Tech*. 2004;14(5):282-284.
22. Hara H, Morita S, Sako S, et al. Hepatobiliary cystadenoma combined with multiple liver cysts: Report of a case. *Surg Today*. 2001;31(7):651-654.
23. Ratti F, Ferla F, Paganelli M, Cipriani F, Aldrighetti L, Ferla G. Biliary cystadenoma: Short- and long-term outcome after radical hepatic resection. *Updates Surg*. 2012;64(1):13-18.

24. Chen YW, Li CH, Liu Z, Dong JH, Zhang WZ, Jiang K. Surgical management of biliary cystadenoma and cystadenocarcinoma of the liver. *Genet Mol Res.* 2014;13(3):6383-6390.
25. Teoh AY, Ng SS, Lee KF, Lai PB. Biliary cystadenoma and other complicated cystic lesions of the liver: Diagnostic and therapeutic challenges. *World J Surg.* 2006;30(8):1560-1566.
26. Lempinen M, Halme L, Numminen K, Arola J, Nordin A, Makisalo H. Spontaneous rupture of a hepatic cystadenoma and cystadenocarcinoma: Report of two cases. *J Hepatobiliary Pancreat Surg.* 2005;12(5):409-414.
27. Lewis WD, Jenkins RL, Rossi RL, et al. Surgical treatment of biliary cystadenoma. A report of 15 cases. *Arch Surg.* 1988;123(5):563-568.
28. Catto JW, Madan M, Alexander DJ. Hepatobiliary cystadenoma presenting with intermittent inferior vena caval obstruction. *J Hepatobiliary Pancreat Surg.* 1999;6(3):324-326.
29. Shaw JM, Bornman PC, Krige JE. Hydatid disease of the liver. *S Afr J Surg.* 2006;44(2):70-2, 74-7.
30. Fuks D, Voitot H, Paradis V, Belghiti J, Vilgrain V, Farges O. Intracystic concentrations of tumour markers for the diagnosis of cystic liver lesions. *Br J Surg.* 2014;101(4):408-416.
31. Vogt DP, Henderson JM, Chmielewski E. Cystadenoma and cystadenocarcinoma of the liver: A single center experience. *J Am Coll Surg.* 2005;200(5):727-733.
32. Bakoyiannis A, Delis S, Triantopoulou C, Dervenis C. Rare cystic liver lesions: A diagnostic and managing challenge. *World J Gastroenterol.* 2013;19(43):7603-7619.
33. Sato M, Watanabe Y, Tokui K, et al. Hepatobiliary cystadenocarcinoma connected to the hepatic duct: A case report and review of the literature. *Hepatogastroenterology.* 2003;50(53):1621-1624.
34. Pedrassa BC, da Rocha EL, Kierszenbaum ML, Bormann RL, Torres LR, D'Ippolito G. Uncommon hepatic tumors: Iconographic essay - part 1. *Radiol Bras.* 2014;47(5):310-316.
35. Hai S, Hirohashi K, Uenishi T, et al. Surgical management of cystic hepatic neoplasms. *J Gastroenterol.* 2003;38(8):759-764.

36. Zhang FB, Zhang AM, Zhang ZB, Huang X, Wang XT, Dong JH. Preoperative differential diagnosis between intrahepatic biliary cystadenoma and cystadenocarcinoma: A single-center experience. *World J Gastroenterol*. 2014;20(35):12595-12601.
37. Doussot A, Gluskin J, Groot-Koerkamp B, et al. The accuracy of pre-operative imaging in the management of hepatic cysts. *HPB (Oxford)*. 2015;17(10):889-895.
38. Tsiftsis D, Christodoulakis M, de Bree E, Sanidas E. Primary intrahepatic biliary cystadenomatous tumors. *J Surg Oncol*. 1997;64(4):341-346.
39. Fairchild R, Reese J, Solomon H, Garvin P, Esterl R. Biliary cystadenoma: A case report and review of the literature. *Mo Med*. 1993;90(10):656-657.
40. Thomas KT, Welch D, Trueblood A, et al. Effective treatment of biliary cystadenoma. *Ann Surg*. 2005;241(5):769-73; discussion 773-5.
41. Koffron A, Rao S, Ferrario M, Abecassis M. Intrahepatic biliary cystadenoma: Role of cyst fluid analysis and surgical management in the laparoscopic era. *Surgery*. 2004;136(4):926-936.
42. Romagnoli R, Patrono D, Paraluppi G, et al. Liver transplantation for symptomatic centrohepatic biliary cystadenoma. *Clin Res Hepatol Gastroenterol*. 2011;35(5):408-413.
43. Wang K, Kong F, Dong M, Zhou J, Li Y. Diagnosis and treatment of intrahepatic biliary cystadenoma: Experience with 14 cases in a single center. *Med Oncol*. 2014;31(11):274-014-0274-3. Epub 2014 Oct 7.
44. Wu JM, Wu YM, Ho MC, Hu RH, Lee PH. Surgical treatment of biliary cystadenomas. *Int Surg*. 2008;93(6):373-376.
45. Lee CW, Tsai HI, Lin YS, Wu TH, Yu MC, Chen MF. Intrahepatic biliary mucinous cystic neoplasms: Clinicoradiological characteristics and surgical results. *BMC Gastroenterol*. 2015;15(1):67-015-0293-3

## Part C - Publication ready original manuscript

### Resection of biliary mucinous cystic neoplasms of the liver: A prospective cohort series of 13 consecutive patients

JC Kloppers, JEJ Krige, MM Bernon, S Burmeister, E Jonas, SR Thomson, PC Bornman

Surgical and Medical Gastroenterology Units, Departments of Surgery and Medicine, University of Cape Town Health Sciences Faculty, Groote Schuur Hospital, Anzio Road, Observatory 7925, Cape Town, South Africa

#### Correspondence to:

JC Kloppers

Department of Surgery

University of Cape Town Health Sciences Faculty

Anzio Road

Observatory 7925

Cape Town

SOUTH AFRICA

Tel: +27-21-404 3042

e-mail: christo.kloppers@uct.ac.za

**Running head:** Biliary mucinous cystic neoplasm

**Key words:** Biliary mucinous cystic neoplasm, biliary cystadenoma, liver cysts, benign liver tumours, ovarian stroma

## **Abstract:**

**Background:** Biliary mucinous cystic neoplasms (BMCNs) are uncommon neoplastic septated intrahepatic cysts which are often incorrectly diagnosed and have the potential for malignant transformation.

**Aim:** The aim of this study was to assess the outcome of surgical resection of BMCNs.

**Methods:** Data from a departmental and faculty registered prospective liver surgery database was used to identify patients who underwent surgery at Groote Schuur and the University of Cape Town Private Academic Hospitals for BMCN from 1999 to 2015. Standard demographic variables including age and gender were documented as well as detailed pre-operative imaging, location and size, operative treatment, extent of resection, histology, post-operative complications using the Clavien-Dindo classification and long-term outcome.

**Results:** Thirteen female patients (median age 45 years) had surgery. Eleven were diagnosed by computer tomography scan after investigation of abdominal pain or a palpable mass. Two were jaundiced. One cyst was found incidentally during an elective cholecystectomy. Five cysts were located centrally in the liver. Before referral three cysts were treated inappropriately with percutaneous aspiration or drainage and two were treated with operative deroofting. Six patients had anatomical liver resections and seven patients had non anatomical liver resections of which two needed ablation of residual cyst wall. One patient needed a biliary-enteric reconstruction to treat a fistula of the left hepatic duct. Median operative time was 183 minutes (range: 130-375). No invasive carcinoma was found on histology. There was no operative mortality. One surgical site infection was treated and one patient developed an intra-abdominal collection one month post-operatively. Two patients developed recurrent BMCN after 24 months.

**Conclusion:** BMCNs should be considered in middle aged women who have well encapsulated multilocular liver cysts. Treatment of large central BMCNs adjacent to vascular and biliary structures in particular may require technically complex liver resections and are best managed in a specialized hepato-pancreatico-biliary unit

## **Introduction**

Biliary mucinous cystic neoplasms (BMCNs) are uncommon multilocular hepatic cysts which account for less than 5% of liver cysts.<sup>1</sup> BMCNs are often incorrectly diagnosed and have the potential for malignant transformation.<sup>2</sup> Clear guidelines are scant and publications are limited to small case series of BMCNs.<sup>3,4</sup> Most occur in middle-aged women. Patients may be asymptomatic and the tumours are often discovered incidentally during imaging or at laparotomy. Management is complicated because accurate identification of the invasive form before surgery is seldom possible. The potential for malignant transformation and the tendency to recur, particularly when treated with techniques other than complete excision, are of concern in these tumours. In this study, we describe the surgical treatment of 13 patients with BMCNs from a single tertiary center.

## **Materials and Methods**

A retrospective analysis of a prospectively maintained database of all liver surgery at Groote Schuur and the University of Cape Town Private Academic Hospitals between 1999 and 2015 was performed to identify all patients with a histological confirmed BMCN, based on the WHO diagnostic criteria.<sup>5</sup> Patient demographics, clinical presentation and detailed pre-operative imaging characteristics of the tumour, including intrahepatic location were recorded. The extent of the surgical procedure was detailed and included operative time and blood transfusion requirements. Post-operative complications were documented according to the Clavien-Dindo (CD) classification.<sup>6</sup> Patients were planned for routine six monthly follow up. Initial surveillance investigation was abdominal ultrasound and additional investigations, for example CT or MRI were performed as clinically indicated. Descriptive analyses were used to characterize the study population. The registry for liver

resections (R024/2014) and the analysis of this subgroup (735/2016) were approved by the, Faculty of Health Sciences Human Research Ethics Committee of the University of Cape Town.

## **Results**

During the study period 457 liver resections were performed of which 13 were for BMCN. All 13 were females with a median age of 45 years (range 22-74). The clinical characteristics are summarized in Table 1. Ten patients presented with abdominal pain, eight had a palpable mass and two were jaundiced. In 12 patients the presumptive diagnosis was made on preoperative imaging (CT=11, US = 1) while one cyst was found incidentally during an elective laparoscopic cholecystectomy (Figure 1). Median cyst size was 13 cm (range 2.5-30 cm) and most occurred centrally in the liver, abutting the hilar bilio-vascular structures. Three patients had percutaneous aspiration of cysts before referral. In two patients inappropriate deroofing was performed before referral. In one, treated as a simple cyst, histology confirmed a BCMN, while in the other a persistent bile leak after deroofing required a formal liver resection.

The operative technique and procedure were adapted to the cyst size and location and proximity of the cyst to vital structures in the porta hepatis, the hepatic veins and the inferior vena cava (Table 2) (Figure 2). In two patients in whom the back wall of the BCMN was adherent to major vascular structures, as much of the cyst wall as could be safely resected was removed and the residual inner cyst surface was ablated with argon beam coagulation. In one patient with a complex centrally located cyst in whom the left hepatic duct communicated with the cyst cavity, a biliary-enteric reconstruction with a Roux-en-Y

loop was performed. Four patients had bile leaks identified during surgery that were oversewn. Two patients had postoperative complications. In one patient a CD grade II surgical site infection was successfully treated with antibiotics and in the other a grade IIIa intra-abdominal collection required radiological percutaneous drainage one month after surgery. Four patients had frozen section performed on the cyst wall intra-operatively, all confirming mucinous neoplasms. None of the patients had invasive BCMN on histology (Figure 3).

All patients had a follow-up visit after surgery, but long term follow-up more than 1 month was only possible in 7 patients with a median follow up of 12 months (range 1-24 months). Two patients developed recurrent disease after 24 months. Both recurrences presented with symptoms which triggered cross sectional imaging. One recurred after partial resection with ablation of the remnant cyst wall and declined further surgery. The other who recurred after a formal resection was treated with percutaneous aspiration and ethanol injection because of a high operative risk. She remains symptom free after eight years.

**Table 1. Clinical characteristics of patients**

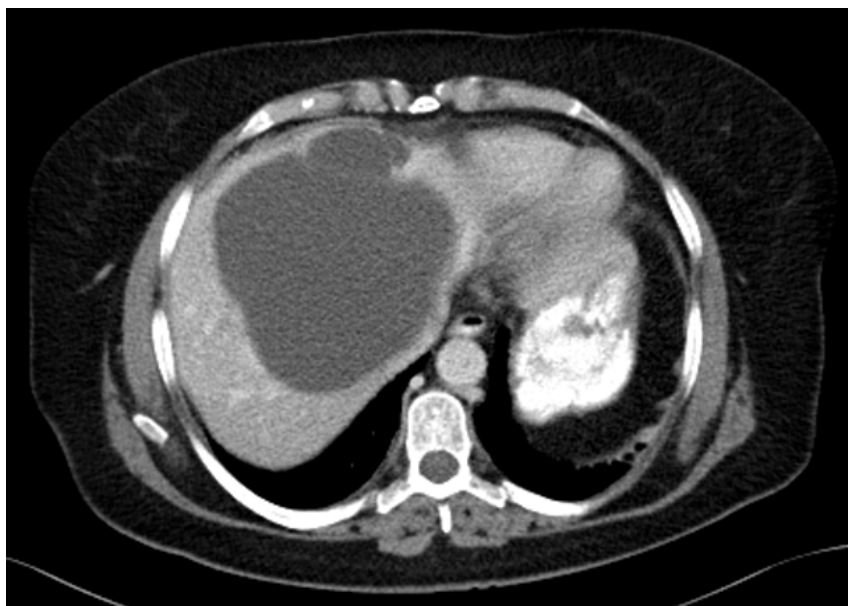<b>Patient</b>	<b>Age</b>	<b>Symptoms</b>	<b>Clinical Signs</b>	<b>Maximum diameter (cm)</b>	<b>Location (segments)</b>
1	46	RUQ pain	Jaundice and epigastric mass	15	Central (4,5)
2	47	N and V, LOW	Palpable epigastric mass	25	Right (5,6)
3	39	RUQ pain	None	2,5	Right (5)
4	48	Epigastric discomfort	Palpable epigastric mass	NA	Central (2,3,4,5)
5	74	Epigastric discomfort	None	NA	Left (2,3)
6	22	RUQ pain	Jaundice and epigastric mass	12	Central (4,5)
7	32	Biliary colic	None	10	Left (3)
8	45	Abdominal distention	Palpable epigastric mass	21	Central (4,5,6)
9	35	RUQ pain	Previous surgery	8	NA
10	56	RUQ pain	Palpable epigastric mass	10	Right (5)
11	44	Epigastric discomfort	NA	NA	Right (5,6)
12	38	Abdominal distention	Palpable epigastric mass	30	Central (4,5,8)
13	63	Epigastric discomfort	Palpable epigastric mass	14	Left (2,3)

RUQ: right upper quadrant; N and V: nausea and vomiting; LOW: loss of weight; NA: not available

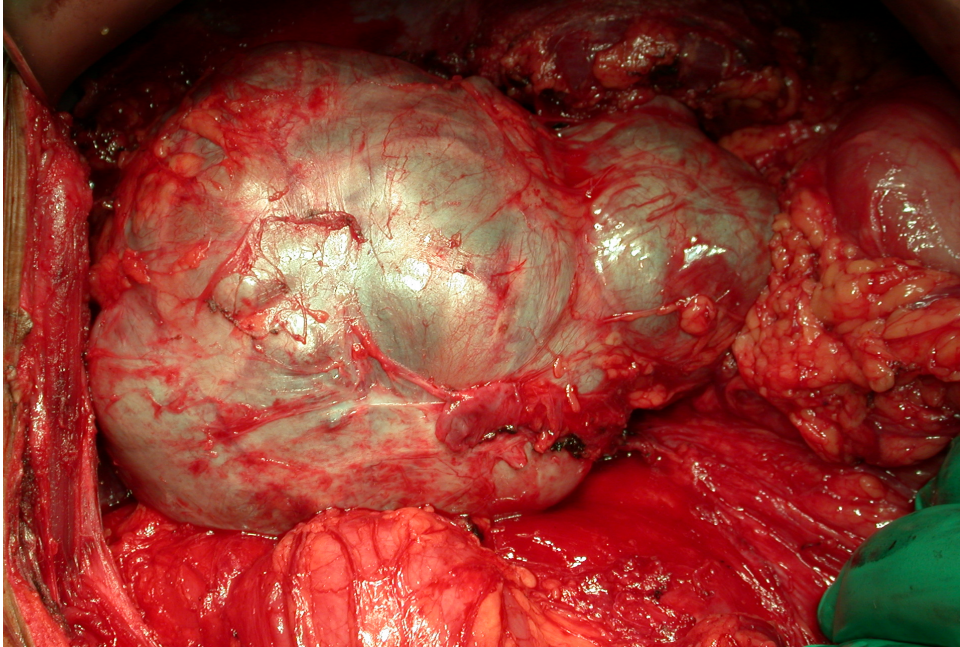
**Table 2. Operative procedures (n = 13)**

Operation	
Anatomical liver resection	6
Non-anatomical liver resection	
Complete	5
Incomplete resection with ablation	2
Inflow occlusion	2
Intra-operative blood transfusion	1
Intra-operative frozen section performed	4
Drain	11
Operative time (minutes), median (range)	183 (130-375)
ICU stay (days), median (range)	2 (1-3)
Hospital stay (days), median (range)	7 (5-8)

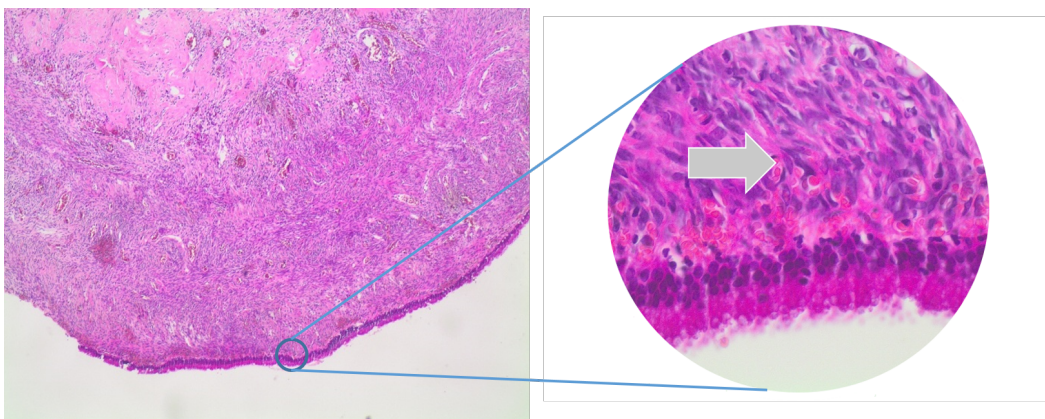
**Figure 1.** CT axial image of patient 8 demonstrated a typical central placed complex liver cyst



**Figure 2.** Operative picture of BMCN before resection



**Figure 3.** Low and high power histology slides of a BMCN wall with the arrow indicating the ovarian-like stroma



## Discussion

In this study all patients were females with a median age of 45 years which is in keeping with the literature that reports a female BCMN preponderance of 90%, typically in the fourth and fifth decades of life.<sup>7</sup> The majority of patients presented with cyst-related symptoms as summarized in table 1. Some BMCNs in our series were mistaken for simple cysts which led to inappropriate initial treatment, including aspiration and deroofting. Patients with incomplete initial resection develop recurrent symptoms and are at risk for malignant transformation, and thus require definitive surgery for complete resection.<sup>2,8</sup> Older age, male gender and shorter duration of symptoms on presentation are associated with a greater risk of invasive BMCN.<sup>9</sup>

Abdominal ultrasound typically shows well-demarcated, mostly multilocular hyperechogenic cystic lesions, which may show septae and characteristic papillary projections from the cyst wall.<sup>10</sup> As in our patients, common features on CT include low-density, well defined, lobulated, multilocular, thick-walled cystic lesions with internal septa and occasionally mural nodules.<sup>5,10</sup> CT also provides additional information regarding the anatomic relation of cysts to major vessels and bile ducts as well as surrounding structures. MRI/MRCP may be of value in assessing proximity to the intrahepatic biliary system and possible biliary communication of cysts.<sup>11</sup> In most of our patients the typical imaging findings of a large, solitary multiloculated complex liver cyst with internal septation and nodularity was present. Most cysts occurred centrally in the liver, straddling right and left lobes and in close relation to the porta hepatis.

Serum markers were not routinely done to aid with the diagnosis in our series, which is in keeping with the results of Wang et al. who in a series of 30 patients found that CA 19-9 to

be elevated in only 17 patients.<sup>12</sup> CA 19-9 was available in four patients of our patients with only one being elevated. Fine needle aspiration with cyst fluid analysis was not used in this current study because of potential harm in disseminating malignant cells and has not been proven to change the management plan.<sup>11</sup>

As in our study only a minority of patients present with complications such as jaundice, cyst rupture, bacterial infection or intracystic hemorrhage. Rare complications such as biliary fistulae and inferior vena cava obstruction have been described.<sup>4</sup> Although all the patients in this study had benign features on histology, malignant change has been reported in up to 10% of patients.<sup>13</sup>

The only appropriate surgical strategy for treatment of BMCNs is complete resection with negative margins, either as anatomical or non-anatomical liver resection, depending on the position of the cyst and the relationship to vital structures. The complexity of management is illustrated in a global multi-centre analysis of 248 patients in which 10% of patients had malignant transformation to cystadenocarcinoma and 18.3% recurred after inadequate surgery.<sup>13</sup> In the largest single-centre cohort of 39 patients seven were misdiagnosed before initial surgery. Liver resection was performed in 17 patients (eight right and nine left hemihepatectomies) and enucleation was performed in 22 patients. At a median follow-up of 20 months one patient presented with recurrence.<sup>3</sup> In our series six patients had anatomical resections and seven had non-anatomical resections while two of these needed ablation of residual cyst wall (Table 2). Alternative techniques such as aspiration, internal drainage, intratumoral sclerosant application and incomplete resection result in recurrence rates of 90 to 100%. Intra-operative frozen section of the cyst wall has not been shown to alter the operative procedure as the biopsy could be non-representative.<sup>14</sup> There is a single case

report of a liver transplant for a central symptomatic BMCN involving the main vasculobiliary structures.<sup>15</sup>

As in our series, the short-term operative morbidity in published series is low and the prognosis in completely resected BMCNs is excellent.<sup>1,12,16</sup> Even though recurrence after an adequately treated cysts is less than five percent, follow-up with abdominal ultrasound after resection is recommended.

### **Conclusion**

BMCNs should be considered in middle aged women who have well encapsulated multilocular liver cysts. Treatment of large central BMCNs adjacent to vascular and biliary structures in particular may require technically complex and challenging liver resections and are best managed in a specialized hepato-pancreatico-biliary unit.

### **Conflicts of interest**

The authors declare no conflict of interest.

## References:

1. Simo KA, Mckillop IH, Ahrens WA, Martinie JB, Iannitti DA, Sindram D. Invasive biliary mucinous cystic neoplasm: A review. *HPB (Oxford)*. 2012;14(11):725-740.
2. Martel G, Alsharif J, Aubin JM, et al. The management of hepatobiliary cystadenomas: Lessons learned. *HPB (Oxford)*. 2013;15(8):617-622.
3. Chen YW, Li CH, Liu Z, Dong JH, Zhang WZ, Jiang K. Surgical management of biliary cystadenoma and cystadenocarcinoma of the liver. *Genet Mol Res*. 2014;13(3):6383-6390.
4. Manouras A, Markogiannakis H, Lagoudianakis E, Katergiannakis V. Biliary cystadenoma with mesenchymal stroma: Report of a case and review of the literature. *World J Gastroenterol*. 2006;12(37):6062-6069.
5. Kloppers JC, Krige JEJ, Bernon M, Thomson SR. Nomenclature for neoplastic biliary cysts : Review. *South African Gastroenterology Review*. 2016;14(1):19-23.
6. Dindo D, Demartines N, Clavien PA. Classification of surgical complications: A new proposal with evaluation in a cohort of 6336 patients and results of a survey. *Ann Surg*. 2004;240(2):205-213.
7. Kim HH, Hur YH, Koh YS, Cho CK, Kim JW. Intrahepatic biliary cystadenoma: Is there really an almost exclusively female predominance? *World J Gastroenterol*. 2011;17(25):3073-3074.
8. Emre A, Serin KR, Ozden I, et al. Intrahepatic biliary cystic neoplasms: Surgical results of 9 patients and literature review. *World J Gastroenterol*. 2011;17(3):361-365.
9. Xu MY, Shi XJ, Wan T, et al. Clinicopathological characteristics and prognostic factors of intrahepatic biliary cystadenocarcinoma. *Chin Med J (Engl)*. 2015;128(9):1177-1183.
10. Doussot A, Gluskin J, Groot-Koerkamp B, et al. The accuracy of pre-operative imaging in the management of hepatic cysts. *HPB (Oxford)*. 2015;17(10):889-895.
11. Choi HK, Lee JK, Lee KH, et al. Differential diagnosis for intrahepatic biliary cystadenoma and hepatic simple cyst: Significance of cystic fluid analysis and radiologic findings. *J Clin Gastroenterol*. 2010;44(4):289-293.
12. Wang C, Miao R, Liu H, et al. Intrahepatic biliary cystadenoma and cystadenocarcinoma: An experience of 30 cases. *Dig Liver Dis*. 2012;44(5):426-431.

13. Arnaoutakis DJ, Kim Y, Pulitano C, et al. Management of biliary cystic tumors: A multi-institutional analysis of a rare liver tumor. *Ann Surg*. 2015;261(2):361-367.
14. Soares KC, Arnaoutakis DJ, Kamel I, et al. Cystic neoplasms of the liver: Biliary cystadenoma and cystadenocarcinoma. *J Am Coll Surg*. 2014;218(1):119-128.
15. Ahanatha Pillai S, Velayutham V, Perumal S, et al. Biliary cystadenomas: A case for complete resection. *HPB Surg*. 2012;2012:501705.
16. Thomas KT, Welch D, Trueblood A, et al. Effective treatment of biliary cystadenoma. *Ann Surg*. 2005;241(5):769-73; discussion 773-5.

## Part D - Supporting documents

<i>Addendum A: Abbreviations and acronyms</i>	pg. 41
<i>Addendum B: Index of tables and figures</i>	pg. 42
<i>Addendum C: Author guidelines of South African Journal of Surgery</i>	pg. 43
<i>Addendum D: Departmental Research Committee approval</i>	pg. 47
<i>Addendum E: HREC Approval</i>	pg. 48

## Abbreviation and acronyms

BCA	biliary cystadenoma
BCAC	biliary cystadenocarcinoma
BDC	bile duct communication
BMCN	biliary mucinous cystic neoplasm
Ca 19-9	carbohydrate antigen 19-9
CEA	carcinoembryonic antigen
cm	centimeter
CT	computer tomography
ELISA	enzyme-linked immunosorbent assay
GSH	Groote Schuur Hospital
HREC	Human Research Ethics Committee
HU	Hounsfield unit
IPMN	intraductal papillary mucinous neoplasm
IPN	intraductal papillary neoplasm
ICU	intensive care unit
IV	intravenous
MCN	mucinous cystic neoplasm
ml	milliliter
MRI	magnetic resonance imaging
MRCP	magnetic resonance cholangiopancreatography
OS	ovarian-like stroma
SAJS	South African Journal of Surgery
TAG	tumour-associated glycoprotein
UCT	University of Cape Town
UCTPAH	University of Cape Town Private Academic Hospital
US	ultrasound
WCC	white cell count
WHO	World Health Organization

## Index of tables and figures

### PART B

Figure 1:	Algorithm for literature search	pg. 9
Table 1:	Comparison WHO Classification of mucinous cystic liver neoplasms	pg. 12
Figure 2:	Pathological diagnostic algorithm for epithelium lined cystic liver lesions	pg. 13
Table 2:	Clinical and biochemistry characteristics of cystic lesions of the liver	pg. 16
Table 3:	US, CT and MRI characteristics of the most common cystic liver lesions	pg. 19

### PART C

Table 1:	Clinical characteristics of patients	pg. 32
Table 2:	Operative procedures (n = 13)	pg. 33
Figure 1:	CT axial image of a typical central placed complex liver cyst	pg. 33
Figure 2:	Operative picture of BMCN before resection	pg. 34
Figure 3:	Low and high power histology slides of a BMCN wall with OS	pg. 34

## Author guidelines of South African Journal of Surgery

### **Authorship**

Named authors must consent to publication. Authorship should be based on substantial contribution to:

- (i) conception, design, analysis and interpretation of data;
- (ii) drafting or critical revision for important intellectual content; and
- (iii) approval of the version to be published. These conditions must all be met (uniform requirements for manuscripts submitted to biomedical journals; refer to [www.icmje.org](http://www.icmje.org)).

### **Conflict of interest**

Authors must declare all sources of support for the research and any association with a product or subject that may constitute conflict of interest.

### **Research ethics committee approval**

Provide evidence of Research Ethics Committee approval of the research where relevant.

### **Protection of patient's rights to privacy**

Identifying information should not be published in written descriptions, photographs, and pedigrees unless the information is essential for scientific purposes and the patient (or parent or guardian) gives informed written consent for publication. The patient should be shown the manuscript to be published.

### **Ethnic classification**

References to ethnic classification must indicate the rationale for this.

### **Manuscripts**

Shorter items are more likely to be accepted for publication, owing to space constraints and reader preferences.

Original articles not exceeding 3 000 words, with up to 6 tables or illustrations, are usually observations or research of relevance to surgery. References should preferably be limited to no more than 15. Please provide a structured abstract not exceeding 250 words, with the following recommended headings: *Background, Objectives, Methods, Results, and Conclusion.*

### **Manuscript preparation**

Refer to articles in recent issues for the presentation of headings and subheadings. If in doubt, refer to 'uniform requirements' - [www.icmje.org](http://www.icmje.org). Manuscripts must be provided in UK English.

Qualification, affiliation and contact details of ALL authors must be provided in the manuscript and in the online submission process.

Abbreviations should be spelt out when first used and thereafter used consistently, e.g. 'intravenous (IV)' or 'Department of Health (DoH)'.

Scientific measurements must be expressed in SI units except: blood pressure (mmHg) and haemoglobin (g/dl). Litres is denoted with a lowercase 'l' e.g. 'ml' for millilitres). Units should be preceded by a space (except for %), e.g. '40 kg' and '20 cm' but '50%'.

Greater/smaller than signs (> and 40 years of age'. The same applies to  $\pm$  and  $^{\circ}$ , i.e. '35 $\pm$ 6' and '19 $^{\circ}$ C'.

Numbers should be written as grouped per thousand-units, i.e. 4 000, 22 160...

Quotes should be placed in single quotation marks: i.e. The respondent stated: '...'

Round brackets (parentheses) should be used, as opposed to square brackets, which are reserved for denoting concentrations or insertions in direct quotes.

### **General formatting**

The manuscript must be in Microsoft Word or RTF document format. Text must be single-spaced, in 12-point Times New Roman font, and contain no unnecessary formatting (such as text in boxes, with the exception of Tables).

## Illustrations and tables

If tables or illustrations submitted have been published elsewhere, the author(s) should provide consent to republication obtained from the copyright holder.

Tables may be embedded in the manuscript file or provided as 'supplementary files'. They must be numbered in Arabic numerals (1,2,3...) and referred to consecutively in the text (e.g. 'Table 1'). Tables should be constructed carefully and simply for intelligible data representation. Unnecessarily complicated tables are strongly discouraged. Tables must be cell-based (i.e. not constructed with text boxes or tabs), and accompanied by a concise title and column headings. Footnotes must be indicated with consecutive use of the following symbols: \* † ‡ § ¶ || then \*\* †† ‡‡ etc.

Figures must be numbered in Arabic numerals and referred to in the text e.g. '(Fig. 1)'.

Figure legends: Fig. 1. 'Title...' All illustrations/figures/graphs must be of high resolution/quality: 300 dpi or more is preferable but images must not be resized to increase resolution. Unformatted and uncompressed images must be attached as 'supplementary files' upon submission (not embedded in the accompanying manuscript). TIFF and PNG formats are preferable; JPEG and PDF formats are accepted, but authors must be wary of image compression. Illustrations and graphs prepared in Microsoft Powerpoint or Excel must be accompanied by the original workbook.

## References

Authors must verify references from the original sources. *Only complete, correctly formatted reference lists will be accepted.* Reference lists must be generated manually and **not** with the use of reference manager software. Citations should be inserted in the text as superscript numbers between square brackets, e.g. These regulations are endorsed by the World Health Organization,<sup>[2]</sup> and others.<sup>[3,4-6]</sup> All references should be listed at the end of the article in numerical order of appearance in the Vancouver style (not alphabetical order). Approved abbreviations of journal titles must be used; see the List of Journals in Index Medicus. Names and initials of all authors should be given; if there are more than six

authors, the first three names should be given followed by et al. First and last page, volume and issue numbers should be given. Wherever possible, references must be accompanied by a digital object identifier (DOI) link and PubMed ID (PMID)/PubMed Central ID (PMCID). Authors are encouraged to use the DOI lookup service offered by [CrossRef](#).

*Journal references:* Price NC, Jacobs NN, Roberts DA, et al. Importance of asking about glaucoma. *Stat Med* 1998;289(1):350-355. [<http://dx.doi.org/10.1000/hgjr.182>] [PMID: 2764753]

*Book references:* Jeffcoate N. *Principles of Gynaecology*. 4th ed. London: Butterworth, 1975:96-101. *Chapter/section in a book:* Weinstein L, Swartz MN. Pathogenic Properties of Invading Microorganisms. In: Sodeman WA jun, Sodeman WA, eds. *Pathologic Physiology: Mechanisms of Disease*. Philadelphia: WB Saunders, 1974:457-472.

*Internet references:* World Health Organization. *The World Health Report 2002 - Reducing Risks, Promoting Healthy Life*. Geneva: World Health Organization, 2002. <http://www.who.int/whr/2002> (accessed 16 January 2010).

*Other references (e.g. reports)* should follow the same format: Author(s). Title. Publisher place: publisher name, year; pages. Cited manuscripts that have been accepted but not yet published can be included as references followed by '(in press)'. Unpublished observations and personal communications in the text must not appear in the reference list. The full name of the source person must be provided for personal communications e.g. '(Prof. Michael Jones, personal communication)'

## **Proofs**

A PDF proof of an article may be sent to the corresponding author before publication to resolve remaining queries. At that stage, only typographical changes are permitted; the corresponding author is required, having conferred with his/her co-authors, to reply within 2 working days in order for the article to be published in the issue for which it has been scheduled.

## Addendum D: Departmental Research Committee approval



**UNIVERSITY OF CAPE TOWN**

---

### Department of Surgery

#### Departmental Research Committee

**Dr Timothy Pennel**

D24 Office, Groote Schuur Hospital,  
Observatory 7925, South Africa

Tel (021) 406 6168/6232/6227 Fax (021) 448 6461

Email: [tim.pennel@uct.ac.za](mailto:tim.pennel@uct.ac.za)

26<sup>th</sup> September 2016

Dr J Kloppers

Department of Surgery  
Groote Schuur Hospital  
University of Cape Town

Dear Dr Kloppers

RE: PROJECT 2016/075

PROJECT TITLE: Resection of biliary mucinous cystic neoplasms: A series of -- patients and a literature review

The above proposal has been reviewed by the Department of Surgery Research Committee. I am pleased to inform you that the committee approved the scientific merit of the study, and endorse the protocol for submission to the relevant ethics committee.

Please use the above project number in all future correspondence.

Yours sincerely

**Signed**

DR TIMOTHY PENNEL

CHAIRMAN: RESEARCH COMMITTEE

"OUR MISSION is to be an outstanding teaching and research university,  
educating for life and addressing the challenges facing our society."

## Addendum E: Faculty Ethics Committee approval



**UNIVERSITY OF CAPE TOWN**  
**Faculty of Health Sciences**  
**Human Research Ethics Committee**



Room E52-24 Old Main Building  
Grootte Schuur Hospital  
Observatory 7925  
Telephone [021] 404 7682 • Facsimile [021] 406 6411  
Email: [nosi.tsama@uct.ac.za](mailto:nosi.tsama@uct.ac.za)  
Website: [www.health.uct.ac.za/fhs/research/humanethics/forms](http://www.health.uct.ac.za/fhs/research/humanethics/forms)

18 October 2016

**HREC REF: 735/2016**

**Prof E Jonas**  
General Surgery  
E23 GIT Clinic  
NGSH

Dear Prof Jonas

**PROJECT TITLE: RESECTION OF BILIARY MUCINOUS CYSTIC NEOPLASMS: STUDY OF A SINGLE INSTITUTIONAL COHORT AND LITERATURE REVIEW: LINKED TO R024/2014(M.Phil.-candidate-J Kloppers)**

Thank you for submitting your study to the Faculty of Health Sciences Human Research Ethics Committee for review.

It is a pleasure to inform you that the HREC has **formally approved** the proof of concept for phase 1 of the above-mentioned study.

**Approval is granted for one year until the 30<sup>th</sup> October 2017.**

Please submit a progress form, using the standardised Annual Report Form if the study continues beyond the approval period. Please submit a Standard Closure form if the study is completed within the approval period.

(Forms can be found on our website: [www.health.uct.ac.za/fhs/research/humanethics/forms](http://www.health.uct.ac.za/fhs/research/humanethics/forms))

*We acknowledge that the student Dr JC Kloppers will be involved in this study.*

Please note that for all studies approved by the HREC, the principal investigator **must** obtain appropriate institutional approval before the research may occur.

**Please quote the HREC REF in all your correspondence.**

Please note that the ongoing ethical conduct of the study remains the responsibility of the principal investigator.

Yours sincerely

*Signed*

**PROFESSOR M BLOCKMAN**  
**CHAIRPERSON, FHS HUMAN RESEARCH ETHICS COMMITTEE**  
Federal Wide Assurance Number: FWA00001637.

HREC 735/2016