

THE DIVERSITY OF MALIGNANT RHABDOID TUMOURS

A morphological, immunohistochemical and ultrastructural review of cases from the
Red Cross Children's Hospital and Groote Schuur Hospitals.

BY

COLIN MOSTERT

Dissertation submitted in fulfilment of Part III M.Med. (Anat.Path)

University of Cape Town, November 1994

Supervisor: Professor R.O.C. Kaschula.

Department of Anatomical Pathology.

The copyright of this thesis vests in the author. No quotation from it or information derived from it is to be published without full acknowledgement of the source. The thesis is to be used for private study or non-commercial research purposes only.

Published by the University of Cape Town (UCT) in terms of the non-exclusive license granted to UCT by the author.

ACKNOWLEDGEMENTS

I wish to express my sincere thanks and appreciation to the following persons:

Professor R.O.C. Kaschula, my supervisor, for his advice and guidance.

Malcolm Emms for his invaluable assistance in the ultrastructural examination of these cases.

Professor Jaskiewicz for allowing me to work on material from the two liver tumours that were referred to him.

Susie Cooper for her assistance in drafting this manuscript.

DECLARATION

I, Haidee Maxine Williams, hereby declare that the work on which this dissertation/thesis is based is my original work (except where acknowledgements indicate otherwise) and that neither the whole work nor any part of it has been, is being, or is to be submitted for another degree in this or any other university.

I empower the university to reproduce for the purpose of research either the whole or any portion of the contents in any manner whatsoever.

Signature:

Signed by candidate

Date: 27/3/09

DEDICATION

This dissertation is dedicated to my wife Janette for her invaluable support.

ABSTRACT

Malignant rhabdoid tumours of the kidney are rare childhood neoplasms. Extra-renal rhabdoid tumours are known to have a distinctive biological behaviour and do not always occur in the paediatric age group. As the histogenesis of rhabdoid tumours, and their apparent relationship to nephroblastoma is still unclear, careful assessment of new cases is required. This investigation illustrates diverse ultrastructural, light microscopic and immunohistochemical findings. These features are related to each other and to the biological behaviour of renal rhabdoid tumours, and six extra-renal lesions with rhabdoid features obtained from the Pathology Archives of the Red Cross Children's Hospital and Groote Schuur Hospital. In this series primitive epithelial elements are a dominant feature, but ultrastructural features of one renal tumour suggest diverse differentiation. The extra-renal lesions investigated include three undifferentiated rhabdoid lesions, a primitive neuro-ectodermal tumour, a malignant epithelioid Schwannoma and a possible undifferentiated hepatocellular carcinoma; all showing areas of extensive rhabdoid differentiation.

Pseudo-rhabdoid cells in an additional two cases were also examined. These particular tumours were a nephroblastoma and a fibro-lamellar carcinoma of the liver. These rhabdoid tumour mimics were ultrastructurally different from true rhabdoid cells.

Strong immunohistochemical co-expression of Vimentin and cytokeratin in rhabdoid tumour cell inclusions has been noted by previous investigators. (Vogel, 1984) (Gansler, 1991), (Berry, 1992). We speculate that the predominant line of differentiation in renal rhabdoid tumours is epithelial although, as in nephroblastoma multiple lines of differentiation may occur. The extra-renal lesions appear to represent more than one entity, but once again epithelial or neuro-epithelial differentiation appears to be present. Ultrastructural examination is a more useful investigation than immunohistochemistry because of inherent non-specific uptake of antibodies by the filamentous cytoplasmic inclusions.

ABBREVIATIONS

Malignant Rhabdoid Tumour of the kidney	MRTK
Extra-renal rhabdoid tumour	ERRT
Malignant epithelioid Schwannoma	MES
Primitive neuro-ectodermal tumour	PNET
Wilms tumour	WT
Bone-metastasizing renal tumour of childhood	BMRTC
Congenital mesoblastic nephroma	CMN
Cystic nephroma (Multilocular renal cyst)	CN
Peri-lobular nephrogenic rests	PLNR
Intra-lobular nephrogenic rests	ILNR
Filamentous cytoplasmic inclusions	FCIs
Renal cell carcinoma	RCC
Transitional cell carcinoma	TCC

**ABBREVIATIONS USED FOR ANTIGENS
DETECTED BY IMMUNOHISTOCHEMICAL METHODS**

alpha-1-antitrypsin	alpha-1-AT
alpha-1-antichymotrypsin	alpha-1-ACT
alphafoetoprotein	alpha FP
Carcino-embryonic antigen	CEA
Cytokeratins (high molecular weight)	CK (HMW)
Epithelial membrane antigen	EMA
Factor VIII related antigen	F8
Glial fibrillary acidic protein	GFAP
Hepatitis B surface antigen	HBsAg
Neurofilament proteins	N/fil
Neurone specific enolase	NSE

TABLE OF CONTENTS

Dedication.

Acknowledgements.

Declaration.

Abbreviations.

Index.

List of tables. List of cases. List of statistics.

List of figures.

INDEX

1.	INTRODUCTION	Page 1
1.1	The place of Malignant Rhabdoid Tumour of the kidney MRTK in relationship to other renal neoplasms. A brief review of renal neoplasia in childhood.	1
1.1.1	The Spectrum of embryonal tumours of the kidney.	1
1.1.1a	Wilms tumour. WT.	1
1.1.1a1	Ultrastructural features of W.T.	2
1.1.1b	Congenital Mesoblastic Nephroma CMN.	3
1.1.1b1	Ultrastructural features of C.M.N.	4
1.1.1c	Cystic nephroma (multilocular renal cyst) CN.	4
1.1.1d	Ossifying tumour of the infantile kidney.	5
1.1.1e	Bone Metastasizing Renal Tumour of Childhood. BMRTC.	5
1.1.1e1	Ultrastructural features of BMRTC.	6
1.1.1f	Malignant Rhabdoid Tumour of the Kidney. MRTK.	6
1.1.2	Other renal tumours occurring in the paediatric age group.	8
1.1.2a	Renal cell carcinomas RCCs	8
1.1.2a1	Common non-papillary RCCs.	10
1.1.2a2	Papillary RCCs.	10
1.1.2a3	Chromophobe RCCs.	10
1.1.2a4	Renal "oncocytomas".	11
1.1.2b	Carcinomas of the collecting ducts and renal pelvis.	11
1.1.2b1	The Bellini duct carcinoma.	11
1.1.2b2	transitional cell carcinoma of the renal pelvis.	12
1.1.2c	Ultrastructural features of renal carcinomas.	13
1.1.3	Other miscellaneous renal neoplasms.	13
1.1.3a	Neuro-epithelial tumours and carcinoids.	13
1.1.3b	Primary renal lymphomas.	14
1.1.3c	Renal sarcomas.	14
1.2	The embryology of the kidney.	15
1.3	Histogenesis of particular renal neoplasms.	18
1.3.1	Wilms tumour WT	18
1.3.2	Congenital Mesoblastic Nephroma. CMN.	21
1.3.3	Cystic Nephroma (Multilocular renal cyst). CN.	21
1.3.4	Bone metastasizing renal tumour of childhood. BMRTC	22
1.3.5	Malignant Rhabdoid Tumour of the kidney. MRTK	22
1.4	Extra-renal rhabdoid tumours.	27

2.	METHODOLOGY	29
2.1	Case selection.	29
2.2	Processing of material.	30
2.2.1	Light microscopy.	30
2.2.2	Immunohistochemistry.	31
2.2.3	Ultrastructural studies. (Electron microscopy).	33
3.	RESULTS	36
3.1	Malignant Rhabdoid Tumour of the kidney. MRTK	36
3.1.1	Clinical data.	36
3.1.2	Pathology.	38
3.1.2a	Gross morphology.	38
3.1.2b	Light microscopy.	38
3.1.2c	Immunohistochemistry.	42
3.1.2d	Ultrastructural examination.	44
3.2	Extra-renal Rhabdoid Tumours. ERRT	52
3.2.1	Clinical data.	52
3.2.2	Pathology.	54
3.2.2a	Gross morphology.	54
3.2.2b	Light microscopy.	54
3.2.2c	Immunohistochemistry.	64
3.2.2d	Ultrastructural examination.	69
4.	DISCUSSION	79
4.1	Malignant Rhabdoid Tumour of the Kidney. MRTK.	79
4.1.1	MRTK Cases 1 to 3.	79
4.1.2	MRTK Case 4.	80
4.2	Extra-renal Rhabdoid Tumours. ERRT.	83
4.2.1	Paravertebral tumours and malignant epithelioid Schwannomas.	83
4.2.2	Primitive neuro-ectodermal tumours (Atypical teratoid tumours).	85
4.2.3	Rhabdoid tumours of the liver.	88
4.2.4	Malignant rhabdoid tumours of the perineum and pelvis.	94
4.3	General Considerations.	96
4.3.1	Malignant Rhabdoid Tumour of the Kidney. MRTK.	96
4.3.2	Extra-renal Rhabdoid Tumours. ERRT.	100
4.4	Cytogenetic aspects.	103
4.5	Clinical considerations.	106
5.	CONCLUSION AND RECOMMENDATIONS	108
5.1	Conclusion.	108
5.2	Recommendations.	109

LIST OF TABLES:

TABLE	PAGE
1. Primary antibodies used in the immunohistochemical investigations.	32
2. Clinical data. Renal rhabdoid tumours. MRTK	37
3. Immunohistochemical results. MRTK	43
4. Clinical data. Extra-renal rhabdoid lesions. ERRT	53
5. Immunohistochemistry (For intermediate filaments). Extra-renal rhabdoid lesions. ERRT	65
6. ERRTs. Immunohistochemistry (for antigens other than intermediate filaments). Key for table 6	66 67
 List of cases used in this thesis (MRTK and ERRT)	 34
List of other cases of interest.	35
Statistical findings. (Distribution of paediatric renal tumours at the Red Cross Children's Hospital) (1958 - 1993).	36

LIST OF FIGURES (illustrations)

Category	Pages
Light microscopy MRTK	40 - 41
Ultrastructural findings MRTK	45 - 50
Light microscopy ERRT	57 - 63
Ultrastructural Findings ERRT	72 - 77
Case of interest. Hepatoblastoma with rhabdoid features	90 - 91
Case of interest. WT with areas of transformation into a RCC	101
Case of interest WT with “pseudorhabdoid cells”	107

1. INTRODUCTION

1.1 The place of malignant rhabdoid tumour of the kidney MRTK in relationship to other renal neoplasms. A brief review of renal neoplasia in childhood.

1.1.1 The spectrum of embryonal tumours of the kidney.

Rhabdoid tumours need to be understood in relation to other renal neoplasms; and to extra-renal tumours that may mimic them. In order to discuss the topic, it is first necessary to review the spectrum of renal tumours in children. The nature of extra-renal rhabdoid tumours also needs to be assessed. Current concepts on the embryology of the kidney, and the proposed histogenesis of certain renal neoplasms also have to be discussed. This thesis concentrates on defining the nature of malignant rhabdoid tumours, and includes a detailed morphological immunohistochemical and ultrastructural investigation of the cases available in our department. Research involving this rare tumour is relevant because it may contribute to a better understanding of renal tumours in general. In order to place the topic into the correct perspective, a brief overview of the spectrum of renal tumours was undertaken.

1.1.1a Wilms tumour.

WT was the first entity described (Eberth, C.J., 1872) (Eve, F.S., 1882) and is the commonest of these neoplasms accounting for over 90% of renal tumours in childhood (Mierau, 1989). The classical WT is a triphasic neoplasm consisting of blastemal, epithelial and stromal components.

New aggressive chemotherapeutic regimens in combination with surgery have resulted in significant cure rates for this once uniformly lethal neoplasm. As a result it has become necessary to classify and separate out other childhood renal neoplasms that follow a different clinical course to WT.

WT, itself, has been subdivided up into several categories with differing biological behaviour. Tumours with a tubular predominance have a better outcome than blastemal ones (Variend, 1984). Teratoid WTs also behave favourably and display

a wide variety of tissues including adipose tissue, squamous epithelium, cartilage and numerous glandular structures (Variend, 1984). Anaplastic nephroblastoma (Beckwith, 1978) is characterised by enlarged and hyperchromatic nuclei and atypical multipolar mitotic figures. This subtype has a poor prognosis particularly if anaplasia is diffuse. WTs containing more than 30% striated muscle have been designated as foetal rhabdomyomatous nephroblastoma (Wigger, 1976). They often occupy the central portion of the kidney, extend polypoid projections into the renal pelvis, occur predominantly in young male infants and are bilateral in one-third of patients. (Wigger, 1976). They probably represent part of the spectrum of WTs that arise from intralobular nephrogenic rests ILNR. (Beckwith, 1990).

Another entity that has recently been described is cystic (papillary) partially differentiated nephroblastoma. (Joshi, 1989) (Joshi, 1990). This is a low-grade malignancy with virtually no metastatic potential; but local recurrences and local infiltration occur frequently after initial surgical resection. The lesion appears to be a well differentiated form of WT, and lies in the grey zone between cystic nephroma CN (multilocular renal cyst) and an overt WT.

Histologically this lesion consists of large thin-walled epithelial lined cysts surrounded by active cellular immature stromal tissue containing blastemal elements. This mesenchymal lining is often thrown up into papillary folds of tissue. (Joshi, 1990).

1.1.1a1 Ultrastructural features of WT.

Schmidt (1982), Mierau (1987, and Mierau (1989) have described the ultrastructural characteristics of embryonal renal tumours, and this has contributed to the resolution of difficult diagnostic problems.

Briefly a few key points that have often been demonstrated in WTs include:-

1. The presence of well developed desmosomes even in monophasic stromal or blastemal WTs.

2. The presence of flocculent coating that surrounds the tumour cells
3. The presence of cilia in much larger numbers than that seen in most childhood tumours. This may be explained by the fact that cilia are a feature of the normal developmentally mature human kidney.
4. Tight junctions may be seen in developing tubular structures.
5. "Paired atypical cisternae" (Tannenbaum, 1971) are almost constantly found in mitotic cells of WT; but are only very rarely found in the tumour cells of other neoplasms. These cisternae are apposed to one another and are composed of residual nuclear membrane elements within the nuclear sap.
6. The cells of WT rather commonly display varying numbers of large phagolysosomes although this is not of great diagnostic significance (Mierau, 1987).

1.1.1b Congenital Mesoblastic Nephroma. CMN.

This term was coined by Bolande (1967) for a group of purely mesenchymal renal neoplasms of hilar origin occurring within the first year of life, and accounting for over 50% of the neoplasms in this age group. In addition to spindle-shaped mesenchymal cells these tumours contain ectatic lymphatic and vascular spaces, occasional foci of cartilage and extra-medullary haematopoiesis and entrapped renal tissue. These tumours generally have an excellent prognosis, although local recurrences may occur.

A rare variant of this which usually occurs around one year of age, and is hypercellular, with atypia, necrosis and a high mitotic rate is termed cellular congenital mesoblastic nephroma. Some of the lesions can metastasise (Gonzalez-Crussi, 1981). A monophasic stromal WT and a BMRTC are difficult to distinguish from an atypical/malignant CMN.

1.1.1b2 Ultrastructural features of CMN.

The appearances of the spindle cells in CMN are compatible with fibroblastic differentiation and myofibroblastic differentiation (Mierau, 1987). These two cell types have also been described by Favara (1968). The nuclear membranes of the fibroblasts were indented or folded, with evenly distributed chromatin and slight clumping along the nuclear membranes. Nucleoli were generally, but not always, inconspicuous. Well developed rough endoplasmic reticulum and golgi apparatus were also present.

Mierau (1987) describes characteristic dichotomous branching of the rough endoplasmic reticulum in this lesion. Lipid droplets, small numbers of lysosomal-like structures and occasional 25 nm in diameter microtubules were noted within the cytoplasm (Favara, 1968). He also described typical myo-epithelial cells with thin filaments underneath the nuclear membranes. These filamentous areas were usually stippled with dense bodies. Vesicles larger than pinocytotic vesicles were observed, and smaller type pinocytotic vesicles were noted on rare occasions. Clumping of nuclear chromatin under the nuclear membrane was conspicuous in these cells. The myofibroblastic cells were almost completely surrounded by "basement membranes" (?basal laminae). Characteristic zonula occludens-like junctional complexes between smooth muscle cells were rarely observed. A predominance of poorly differentiated mesenchymal cells were often present.

1.1.1c Cystic Nephroma (Multilocular renal cyst). CN.

This is a rare intra-renal cystic epithelial lesion characterised by a solitary, fluid filled main cyst subdivided into multiple non-communicating secondary locules. The ultrastructure indicates the tubular elements in these lesion represent dilated collecting ducts (Mierau, 1987).

1.1.1b Ossifying tumour of the infantile kidney.

This rare benign entity was described in 1980 (Chatten, 1980). This unusual lesion appears to arise at the junction between the urothelium and the renal medulla in the first few months of life. The central core of the neoplasm consists of dense bone. The neoplastic cells are more plump than osteoblasts, and have bland cytological features with no significant mitotic activity. A mildly infiltrative irregular border of more cellular soft tissue is evident around the central mass of bone. No cartilage, skeletal muscle or epithelial differentiation is evident (Chatten, 1980). There is speculation that this lesion may arise from the urothelial lining (Chatten, 1980).

1.1.1e Bone metastasizing renal tumour of childhood. BMRTC

This lesion is also known as a clear cell sarcoma of the kidney. This tumour which accounts for approximately 4% of renal paediatric neoplasms shows aggressive behaviour, a propensity for widespread metastases to bones and was first described in 1978 (Marsden, 1978). The neoplasm is made up of small rather undifferentiated tumour cells with a high nucleo-cytoplasmic ratio, and open vesicular chromatin. Occasional groups of cells within the neoplasm contain clear vacuoles within their cytoplasm, although this is not usually a predominant feature of the lesion. Parallel arrays of thin branching vessels within the stroma of this neoplasm are an important diagnostic criterion. The tumour displays a wide variety of architectural growth patterns including the typical pattern with polygonal clear cells, epithelioid, trabecular neurilemmoma-like, hyalinised, cystic and angiectatic forms (Marsden, 1980). The presence of a number of these patterns in different areas of the tumour is an important diagnostic feature. Recent aggressive chemotherapeutic regimens have produced similar cure and salvage rates to those for unfavourable histology WTs.

1.1.1e1 Ultrastructural features of BMRTC.

The clear cell appearance of this tumour corresponds to a rather peculiar electron-lucent cytoplasm on ultrastructural examination (Mierau 1989). This cytoplasm contains very few organelles, and although these lesions exhibit no specific ultrastructural features, their distinctive electron microscopic appearance usually allows easy identification. (Mierau, 1987). BMRTC often forms loose cord-like arrangements of cells on electron microscopy, and the cells often display broad blunt cytoplasmic processes (Mierau, 1989). Sometimes more slender processes are apparent (Mierau, 1989). BMRTC often displays a significant amount of collagen between the tumour cells whereas WT does not. BMRTC generally lacks the flocculent extracellular substance seen in WT (Mierau, 1989).

1.1.1f Malignant rhabdoid tumour of the kidney. MRTK.

MRTK is a well defined, highly malignant neoplasm that afflicts infants and young children. The entity was first described in 1978 (Beckwith, 1978). The neoplastic cells contain large nuclei with prominent eosinophilic macronucleoli, and single hyaline cytoplasmic inclusions. They show strong immunohistochemical staining for vimentin. In addition they usually also stain for cytokeratins and for epithelial membrane antigen EMA (Gansler, 1991) (Berry, 1992). Ultrastructurally the inclusions consist of irregular whorls of intermediate filaments. These filamentous cytoplasmic inclusions FCIs and/or macronucleoli have also occasionally been noted in other renal tumours apart from rhabdoid tumour, however, but in these cases other components to the tumour make the diagnosis obvious (Weeks, 1991). Such tumours include WT, TCC, RCC, collecting duct carcinoma, CMN, neuro-epithelial lesions and carcinoids (Weeks, 1991). This will be discussed in more detail later in the thesis (see Discussion).

MRTKs account for 1-2% of renal paediatric neoplasms (Mierau, 1989). Analysis of 111 rhabdoid tumours from the American National Wilms Tumour Study Centre revealed various growth patterns, which have no bearing on prognosis, but which need to be recognised by the pathologist to avoid confusion with other renal neoplasms (Weeks, 1989):-

1. Classical. Solid sheets of tumour cells.
2. Sclerosing (fibrotic, osteosarcomatous or chondroid).
3. Epithelioid
Trabecular, mucoid, alveolar or pseudoglandular.
4. Spindled.
Broad fascicles, myxoid, haemangiopericytomatous, storiform or palisaded.
5. Lymphomatoid. Solid or histiocytoid.
6. Vascular.

BMRTC-like or paragangliomatous. (Weeks, 1989)

This is important as the management of different entities varies considerably. Nearly all cases of MRTK fortunately display fairly uniform cytological features.

The histogenesis of the various non-Wilms renal neoplasms is not clear, and their relationship to one another and to WT is not understood. Rhabdoid tumours are a particularly interesting group, as extra-renal tumours with phenotypically identical cells have been described in many parts of the body. Such sites include the bladder (Hams, 1987) (Carter, 1989), vulva (Perrone, 1989), limbs (Kent, 1987), inguinal area/perineum (Tsuneyoshi, 1985), liver (Foschini, 1992), (Chang, 1989) (Parham, 1988), heart (Small, 1985), thymus (Lemos, 1978), orbit (Walford, 1992), nasopharynx (Batsakis, 1988), paravertebral area (Lynch, 1983), abdomen (Tsokos, 1989), adnexae (Tsokos, 1989), prostate (Ekfors, 1985), lacrimal gland (Niffenegger, 1992), tongue (Patron, 1988), and central nervous system (Biggs, 1987),

(Biegel, 1989) (Bonnin, 1984) (Chang, 1989). Patients with tumours at these sites have shown a wide age range. Ultrastructural examination of several extra-renal tumours has suggested a diverse histogenesis, which is covered in detail later on in this dissertation (see discussion).

Complicating the matter even further is the fact that characteristic rhabdoid cells have been found in malignant melanoma (Bittesini, 1992), epithelioid sarcomas (Molenaar, 1989), myxoid chondrosarcomas (Tsuneyoshi, 1987), mesotheliomas (Tsuneyoshi, 1987), transitional cell carcinomas (Harris, 1987) and colonic carcinoma (Chetty, 1993). In addition FCIs have been demonstrated in poorly differentiated endometrioid and thyroid carcinomas (McNutt, 1985). The ERRTs also show varying architectural patterns with common, classical and spindle celled arrangements (Tsuneyoshi, 1987). A sclerotic pattern can also be present (own observations) (Tsokos, 1989).

As a result of these findings it has become necessary to document the range of morphological and ultrastructural expression of rhabdoid tumours, and to correlate this with their behaviour to gain further understanding of their underlying pathology. The emphasis of this thesis has been based upon a careful evaluation of the renal and extra-renal tumours with rhabdoid features in our archives, as we have an unusually high proportion of extra-renal neoplasms displaying this rare phenomenon. We feel it is important to contribute to a better definition and understanding of this entity because of the therapeutic implications involved.

1.1.2 Other renal tumours occurring in the paediatric age group.

1.1.2a Renal cell carcinomas.

Renal cell carcinomas are rare lesions in children but have been described at all ages (Leuschner, 1991) (O'Brien, 1980) (Lack, 1985). These tumours show clear

evidence of epithelial differentiation either at the light microscopic or ultrastructural level (O'Brien, 1980), and have been classified in various ways in the previous literature.

The most common subtype is the classical clear cell variant. A smaller proportion of these tumours have scanty cytoplasm and have predominantly tubulo-papillary architecture. Assessment of the stage of these tumours (Robson, 1969) appears to be the most important factor in their prognosis.

Once the stage has been determined, nuclear grading systems as determined by Fuhrman, (1982) or Thoenes (1986) seem to have some prognostic value. Poorly differentiated sarcomatous forms of renal cell carcinoma do occur, but with clear cut epithelial differentiation either on ultrastructure or elsewhere in the tumour on light microscopy. Complex morphological classification systems have evolved, reaching their climax in the paper produced by Thoenes (1986). Briefly the tumours here are described on the basis of three different sets of criteria; namely cytological appearance, architectural growth and nuclear grade. The cytological types include clear, chromophobe, chromophilic (basophilic or eosinophilic), oncocytic and spindle shaped/pleomorphic cellular forms. Unfortunately this classification is difficult to reproduce, and there appears to be much overlap between the different entities.

Fortunately the picture appears to have been somewhat simplified by a recent cytogenetic classification (Kovacs, 1993). It appears that most renal cell epithelial neoplasms can be divided into four main groups on this basis:

1.1.2a1 Common non-papillary renal cell carcinomas with deletion of chromosome 3p.

These account for about 80% of cases, appear to be malignant from the outset and are characterised by the loss of chromosome 3p sequences, rearrangement of the chromosome 5q region and loss of chromosome 14q sequences.

1.1.2a2 Papillary renal cell neoplasms.

Papillary renal cell tumours with scanty cytoplasm account for about 10% of renal epithelial cell neoplasms. These often show psammoma bodies and are adenomas if they have a combined trisomy of chromosomes of 7 and 17, as well as the loss of a Y chromosome. When additional trisomies such as 16, 12 or 20 appear, the lesions behave in a malignant manner. Using the size of a renal epithelial tumour to draw a distinction between an adenoma and carcinoma is now obsolete if cytogenetic studies are available.

1.1.2a3 Chromophobe renal cell carcinoma.

These contribute about 5% of renal epithelial cell tumours, and are composed of a solid growth of neoplastic cells showing a pale, reticular cytoplasm which stains with Hale's acid iron colloid. Sarcomatous transformation of chromophobe cells is unusual. Electron microscopic studies reveal a variable number of mitochondria and unusual invaginated vesicles in the cytoplasm. The latter are thought to be pathognomonic of this neoplasm (Thoenes, 1986). The cells often show mirror image double nuclei. The only three cases karyotyped up until now show a chromosome number of less than 40, with variable allelic losses in combinations not compatible with the previous two entities (Kovacs, 1988) (Kovacs, 1992'1). Analysis

of the mitochondrial DNA shows a gross alteration in restriction pattern in some cases (Kovacs, 1992'2).

1.1.2a4 Renal oncocytoma.

This accounts for about 5% of renal epithelial cell tumours in adults. It consists of sheets of large cuboidal cells characterised by eosinophilic granular cytoplasm and uniform round nucleoli (Hamperl, 1962) (Klein, 1976). These tumours are circumscribed, with or without a capsule. Central myxoid/fibrotic scarred areas are common. A mixed population of cells with normal and abnormal karyotypes is present in most renal oncocytomas. Recent chromosomal changes have not yet been identified. A change in mitochondrial DNA restriction patterns appears to be present (Kovacs, 1989). A mutation here may account for the densely packed sheets of abnormally large mitochondria noted on ultrastructural examination (Thoenes, 1986). These tumours are benign, and do not show any significant cytological aberration. No clear cell component is evident.

Carcinomas distinct from these entities arise in the distal collecting ducts and renal pelvis.

1.1.2b Carcinomas of the collecting ducts and renal pelvis.

1.1.2b1 The Bellini duct carcinoma.

Occasional cases of papillary renal cell carcinoma have appeared with atypical hyperplastic changes in the adjacent collecting epithelium (Mancilla-Jimenez, 1976), leading these authors to postulate that some papillary renal cell carcinomas may arise in collecting duct epithelium. Another three cases of atypical papillary carcinoma with an infiltrative growth and a desmoplastic stromal response have

also been labelled as Bellini duct carcinomas (Cromie, 1979) (O'Brien, 1980) (Hai, 1982).

Fleming described six cases (Fleming, 1986). Macroscopically these are firm grey or white ill-defined lesions of the renal pelvis and medulla without large areas of necrosis. Well differentiated papillary formations appear to be present in some parts of the tumour, with bland nuclei, and a high nucleo-cytoplasmic ratio. Delicate fibrovascular cores are present. The invasive areas of the tumour show considerable nuclear pleomorphism, a desmoplastic stromal response and marked intra-tubular invasion. In some cases papillae project into cystic spaces to form glomeruloid structures. These are aggressive tumours occurring predominantly in adults. Perineural invasion is a prominent feature (Fleming, 1986).

They mark with *Ulex europaeus* lectin, and with monoclonal antibodies against cytokeratin 13. *Ulex europaeus* (Rumpelt, 1991) and cytokeratin 13 (Moll, 1989) are both markers for transitional epithelium. *Ulex europaeus* also marks the distal collecting duct epithelium of normal kidneys (Rumpelt, 1991).

1.1.2b2 Transitional cell carcinomas of the renal pelvis.

These have a papillary architecture and stratified epithelial lining typical of transitional cell carcinomas of the bladder and other sites in the urogenital tract. These lesions and normal pelvic urothelium will express cytokeratin 13, which does not appear in the nephron (Achstaetter, 1985).

Although numerous other immunohistochemical markers and lectins delineate specific parts of the mature nephron, the sites of expression unfortunately vary during nephrogenesis. The patterns noted in renal cell carcinomas also show considerable overlap, making it impossible to determine whether these lesions are

of proximal or distal tubular origin. A notable example is the pattern of staining with epithelial membrane antigen, which only stains the distal convoluted tubules, collecting ducts and urothelium of the mature kidney; but which is expressed in most renal cell carcinomas. (Fleming, 1985).

1.1.2c Ultrastructural features of renal carcinomas.

All renal cell carcinomas show well developed basement membranes on ultrastructural examination and tubular and acinar structures are often evident. The common non-papillary carcinomas can often be identified even in metastases because of complex cytoplasmic processes on their lateral and basal borders reminiscent of the spaces involved in active transport in normal mature epithelium. Fairly well developed cell junctions and tight junctions are often found in the group, although fully developed desmosomes are unusual (in our experience). Intracytoplasmic lumina are often evident, and the luminal surface of the cells often shows numerous micro-villi and pinocytotic vesicles (Ghadially, 1985).

The papillary carcinomas contain much less cytoplasm and lipid vacuoles, and lack the complex cytoplasmic interdigitations. They demonstrate moderately well developed fairly long cell junctions in many cases (own observations). Mucin secreting adenocarcinomas and squamous cell carcinomas of the renal pelvis also occur.

1.1.3 Other miscellaneous renal neoplasms.

1.1.3a Neuro-epithelial tumours and carcinoids.

Rare entities occurring in the kidney include neuro-epithelial tumours and carcinoids which can mimic rhabdoid tumours because of the filamentous cytoplasmic inclusions (Weeks, 1991). Distinguishing features include the presence of subtle

compartmentalization and a “salt and pepper” type nuclear chromatin in at least some areas (Weeks, 1991). In occasional cases neural rosettes or foci of ganglionic differentiation can be found.

In some cases light microscopy is inconclusive, and ultrastructural studies are essential in establishing the correct diagnosis. Neuritic cell processes and occasional dense core granules may be evident. In other cases the diagnosis may depend on the presence of numerous dense core granules only. Although neurone specific enolase is a fairly non-specific marker, it is usually positive in these cases (Weeks, 1991).

1.1.3b Primary renal lymphomas.

Primary renal lymphomas also occasionally occur. These may be confused with rhabdoid tumours if they contain conspicuous nucleoli. They should nearly always mark for leucocyte common antigen or other lymphoid markers, however, and the absence of FCIs and any form of cell junction will be helpful in arriving at the correct diagnosis (Weeks, 1991).

1.1.3c Renal sarcomas.

Very rare primary sarcomas of the kidney have also been described in adult patients. These include leiomyosarcoma (Ng ,1985) of which we have one case in our records at Groote Schuur Hospital, malignant Schwannoma (Fein, 1965), malignant fibrous histiocytomas (Scriven, 1984), liposarcomas and malignant haemangiopericytomas (Farrow, 1968), angiosarcoma (Allred, 1981), osteosarcomas (Micolonghi, 1984), chondrosarcomas (Nativ, 1985), mesenchymal chondrosarcomas (Malhotra, 1984) and malignant mesenchymomas (Mead, 1982).

The list of tumours outlined in the proceeding discussion is by no means complete and omits several benign entities. An attempt has been made to describe the

lesions that may be confused with rhabdoid tumours, or that will enter into a discussion of the histogenesis of MRTK. It must be emphasised again that rhabdoid cells have been described in poorly differentiated transitional cell carcinomas and also in Wilms tumours and occasional neuro-epithelial and carcinoid tumours.

1.2 The embryology of the kidney.

The nephrogenic cord and mesonephric or Wolffian duct developed from the intermediate mesenchyme of the embryo. The most cephalic parts of these bilateral paraxial mesenchymal cords form the pronephros, which soon regresses. Only transitory rudiments of the pronephros remain in the lower cervical and upper dorsal segments in the fourth week of intra-uterine life. The pronephros has disappeared by the fifth week of gestation (Willis, 1958).

The larger parts of the length of these nephrogenic cords then goes on to form the mesonephros. The mesonephros has developed by the end of the second month of gestation (Willis, 1958). Small nephrogenic tubules with glomeruloid bodies communicate directly with the mesonephric or Wolffian duct, and appear to have some excretory function in the foetus (Willis, 1958). The cephalic segments of the mesonephros begin to regress before the caudal ones are fully developed. In the second half of the second month all of the mesonephric glomeruli atrophy in cranio-caudal order and all that remains are a few non-functioning vestiges attached to the epididymis (Willis, 1958).

The ureteric bud which is also of mesenchymal origin, appears by the fifth week from the hind end of the Wolffian duct (Willis, 1958). The Wolffian duct reaches the cloaca by the end of the fourth week of gestation (Willis, 1958). Transitional epithelium develops in the ureteric bud in the second and third months of gestation (Willis, 1958).

The condensation of nephrogenic cord that develops around each of the two ureteric buds is known as the metanephros. The ureteric bud divides into up to 12 generations of tubules; with the earlier generation forming the renal calyces and the later generations the collecting ducts. The ureteric bud continues to branch into collecting ducts until the end of the sixth month of gestation (Willis, 1958).

The primitive metanephric stroma condenses around the collecting ducts to form blastemal caps. These blastemal condensations then develop into renal vesicles, and later differentiate into nephrons under the influence of factors from the ureteric bud. This differentiation into nephrons first commences at about the 8th week of gestation (Willis, 1958). It appears, however, that the metanephric cap may have already lost its capacity to differentiate into organs other than renal tissue even prior to the inductive influence of the ureteric bud (Mierau, 1987).

Once the developing nephrons become attached to the developing collecting ducts, the ampullae no longer stimulates new nephronic development but, instead then stimulates the remaining nephrogenic mesenchyme to form the supporting stroma.

Changes also appear to take place in the way the nephrons are formed as the kidney develops, indicating that the nature of the inductive signals changes subtly during maturation. It is not surprising that errors in communication sometimes occur considering the complexity of the system (Mierau, 1987).

The cells of the nephrogenic mesenchyme initially express vimentin, and not cytokeratins. Later the ureteric bud and developing nephrons express both groups of antigens, and finally cytokeratins are the dominant intermediate filaments expressed in the renal vesicles (Mierau, 1987).

Ultrastructurally desmosome-like junctions become apparent even before basement membrane-like material is deposited within the blastemal cap. The basement membrane deposits can be shown to contain the glycoprotein laminin on immunohistochemical examination. Fibronectins and types I and III collagen originally present in the cells disappear as the blastemal cap organises itself into cords and central lumina of epithelial tissue (Mierau, 1987). A ring of basement membrane develops around the outside of the tubules. Basement membrane surrounding the other surfaces of the cells is resorbed.

The nephronic vesicle quickly develops from a comma-shaped body into an S-shaped structure, which then differentiates segmentally to form the various components of the nephron. This process occurs in a particular sequence. The glomerulus initially develops from the lower portion, and then proximal tubules appears out of the middle portion. The distal tubules finally develop from the upper segment (Mierau, 1987). The mature nephron, unlike the renal vesicle, is almost devoid of intermediate filaments (Mierau, 1987).

Another separate set of inductive stimuli appear to be required for the vascularisation of the glomerular tufts. Vimentin once again becomes the predominant intermediate filament expressed in this region (Mierau, 1987).

The renal lobe which consists of a medullary pyramid and its overlying cortex represents the basic scaffold of metanephric differentiation. The first nephrons to develop within a lobe are those at the cortico-medullary junction, and the last to develop at around the time of birth of a term infant are those immediately beneath the renal capsule (Potter, 1953). It appears that the metanephric blastema is capable of differentiating into more types of epithelial and mesenchymal tissue at the stage of development of the early nephrons. Once the later subcortical nephrons develop, the blastema is limited to differentiate into the few mature

components that combine to make a nephron (Beckwith, 1990). The inductive influences affecting the nephrogenesis during the early stages of lobar development must therefore be somewhat different to those occurring when the lobe is almost complete (Beckwith, 1990).

1.3 Histogenesis of particular renal neoplasms.

1.3.1 Wilms tumour WT.

The development of WT mimics or recapitulates both normal and abnormal sequences of development in a remarkable manner. Beckwith has generated a workable and reproducible classification of the precursor lesions of WT, which has clarified many conceptual difficulties relating to the histogenesis of the tumour. The account which follows is based primarily upon the information summarised in his publication (Beckwith, 1990), except where specifically stated otherwise.

An aberration in normal nephrogenesis leads to the development of a nephrogenic rest. A nephrogenic rest is defined as a focus of abnormally persistent nephrogenic cells, retaining some cells that could potentially be induced to form a WT.

Nephroblastomatosis is now defined as diffuse or multifocal presence of nephrogenic rests. If multiple synchronous WTs develop, the presence of pre-existing nephroblastomatosis can be inferred even if it is no longer visible.

Nephrogenic rests can be subdivided into two major categories; peri-lobar nephrogenic rests PLNR and intra-lobar nephrogenic rests ILNR. Occasional intermediate forms do occur indicating a developmental continuum in certain cases. The PLNRs appear to arise later in development and are situated around the edges of the lobes. Sites of occurrence therefore not only include subcapsular region, but also the borders between adjacent lobes, and the junction between cortex and the renal sinuses. PLNRs usually have sharply circumscribed borders, and consist

either predominantly of blastema, or mature tubular elements. Stroma when present is often sclerotic.

ILNRs are usually situated in the middle of the lobes, but may occur anywhere including the subcapsular area and the junctions with the renal calyces; which is logical as they represent an aberration early on in the development of the lobe. Another distinguishing characteristic is that the edges of ILNRs are ill-defined, and immature stroma often predominates. The range of epithelial structures is often more varied.

PLNRs occur in approximately 1% of neonatal autopsies, and are often multiple. ILNRs are considerably rarer, and are usually single.

The foci of nephroblastomatosis can be further classified according to the activity of the cells in the rest, and can be divided into the following categories:-

1. Dormant rests. These are of microscopic size and are composed of blastemal or other embryonal cell types. Mitoses are rare.
2. Maturing sclerosing and obsolescent rests. Differentiating epithelial or stromal cells occur in maturing rests. Stromal hyalinisation is present in sclerosing or obsolescent rests.
3. Hyperplastic rests are grossly visible lesions with the same shape as the original dormant rests. They may also show involutional change.
4. Neoplastic rests. These may occur within any of the above three rest types, and are identified by the presence of one or more spherical expanding nodular lesions which compress the surrounding parenchyma. These neoplastic rests may be subdivided into:-

(a) Adenomatous rests, in which the nodules contain only well differentiated cells with few or absent mitoses. Structures such as papillary adenomata can sometimes arise within PLNRs.

(b) Nephroblastomatous rests. These are neoplastic nodules of any size composed of crowded embryonal cells identical to Wilms tumour. Mitoses are frequent.

The presence of multiple rests or nephroblastomatosis may either be predominantly perilobular, intralobular or a combination of the two. On rare occasions the bean-shaped structure of the kidney is preserved but the parenchyma demonstrates no mature well-formed nephrons. (Universal nephroblastomatosis). PLNRs often occur in otherwise normal children, and seldom give rise to WT. Multiple PLNRs are associated with Beckwith-Weidemann and hemihypertrophy syndromes (Beckwith, 1990). These two syndromes incidentally are also associated with an 11p15 chromosomal deletion (the WT2 gene) situated close to an insulin growth factor II like protein (Scott, 1985).

PLNRs are often multiple, and bilateral synchronous WTs therefore are occasionally associated with them.

ILNRs are only usually found in conjunction with WT, indicating that they are unstable because they have developed early on in embryogenesis. ILNRs are associated with an 11p13 deletion (Francke, 1979), (Ferrell, 1980). This deletion alters an early growth response EGR mammalian polypeptide. This protein is an autosomal recessive tumour suppresser gene which binds to a regulatory DNA sequence. This gene at 11p13 has been labelled WT1 and also appears to be important in the development of the gonads. ILNRs and WTs and the WT1 gene are associated with aniridia, the WAGR complex (Wilms tumour, aniridia, genito-urinary abnormalities and mental retardation); and with the Drash syndrome (Hermaphroditism, nephrotic syndrome and WT) (Beckwith, 1990).

Because ILNRs have a high propensity to undergo malignant transformation; metachronous contra-lateral WTs sometimes develop because in rare instances several of these rests are present. ILNRs are ill-defined lesions often seen in relation to a WT, and it is important

Because ILNRs have a high propensity to undergo malignant transformation; metachronous contra-lateral WT's sometimes develop because in rare instances several of these rests are present. ILNRs are ill-defined lesions often seen in relation to a WT, and it is important therefore to distinguish them from the irregular invasive border that can occasionally be found in WT (Beckwith, 1990).

The WT that develops from ILNR is often more varied than that originating in a PLNR. This is logical as the capacity for diverse differentiation is more likely to develop in an abnormality arising early on in embryogenesis. WT from ILNRs often displays heterologous elements such as skeletal muscle, and may demonstrate pelvicalyceal and glomerular differentiation (Beckwith, 1990). The differentiation in WT from PLNRs is often confined to blastemal and epithelial differentiation, with occasional primitive glomeruloid bodies (Beckwith, 1990).

1.3.2 Congenital mesoblastic nephroma. CMN

Wigger (1975) interpreted the cells of CMN to represent elements of "secondary mesenchyme", or embryonic renal tissue no longer capable of differentiating into nephronic epithelium. The alternative theory that these tumours represent nephrogenic mesenchyme rising previous to, or in the absence of the inductive influence of the ureteric bud (Kumar, 1986). This view point seems more likely because the mesenchymal tissue in these lesions is rather immature (Mierau, 1987).

1.3.3 Cystic nephroma (Multilocular renal cyst). CN

This lesion may possibly arise in a manner somewhat the reverse of that proposed for CMN. At a slightly later stage in embryogenesis faulty feedback from the nephrogenic mesenchyme to the ureteric bud may inhibit terminal differentiation of the collecting system, and lead possibly to the development of CMN (Mierau, 1987). The ultrastructure of these lesions is suggestive of dilated collecting ducts (Mierau, 1987).

The fact that CMN and CN both show an arrest in induction and maturation whilst they are still monophasic entities suggests that the aberration and development may possibly occur at an earlier stage than that in WT (Mierau, 1987).

1.3.4 Bone metastasizing renal tumour of childhood. BMRTC.

The histogenesis of this cytologically monomorphic and immature primitive looking lesion, and its relationship to WT are not established (Mierau, 1987).

1.3.5 Malignant rhabdoid tumour of the kidney. MRTK.

These are cytologically monomorphic undifferentiated sarcomas of uncertain histogenesis.

Their precise site of origin within the process of nephrogenesis is not clear, as lesions with similar phenotype also have been described in many other parts of the body.

Light microscopic examination has not been helpful in establishing their histogenesis. Both the renal and extra-renal tumours appear to share many interesting ultrastructural characteristics, which have generated various conflicting theories as to their histogenesis. These findings will now be discussed together with other supporting investigations such as immunohistochemistry where appropriate and cell culture studies where these have been available.

Aggregates of tonofilament-like bundles suggestive of epithelial differentiation have been noted within the cytoplasmic inclusions of both MRTK and ERRT cells (Tsuneyoshi, 1985) (Weeks, 1989) (Weeks, 1994) (Tsokos, 1989).

Whilst this suggests epithelial differentiation, well defined epithelial features such as mature desmosomes with peripheral tonofilament insertions have not been observed. External laminae has also been noted around the tumour cells of a few cases (Weeks, 1989) (Tsokos, 1989).

Continuous or reduplicated basal lamina was also seen in a single case (Tsokos, 1989).

Whilst this once again suggests epithelial differentiation, external laminae also occurs around some mesenchymal cells such as smooth muscle, and around Schwann cells which may be of

mesenchymal origin. Primitive cell junctions have been noted in most rhabdoid tumours. These do not in themselves imply any particular line of differentiation. One renal rhabdoid tumour has shown focal primitive cytoplasmic processes with neuro-secretory granule-like structures suggesting neuro-epithelial differentiation (Tsokos, 1989). Intracytoplasmic microtubules have been noted in an ERRT and a MRTK (Lynch, 1983). Microtubules themselves do not necessarily imply neuro-tubular differentiation, as they also occur in components of the cytoskeleton of actively growing cells such as fibroblasts and myofibroblasts (Favara, 1968). They possibly play an important role in intra-cellular transport in such cells.

Immunohistochemical investigations have often been used in an attempt to elucidate the histogenesis of rhabdoid cells. This approach is considerably less satisfactory than ultrastructural examination because the cytoplasmic inclusions show non-specific mopping up of antibodies, which makes interpretation very difficult and subjective. (Own observations) (Weeks, 1989) (Berry, 1992). Strong granular staining of the inclusions for vimentin and cytokeratins does, however, indicate genuine antigenic expression. Interestingly S100 protein, glial fibrillary acidic protein GFAP and neuro-filament markers NF appear to be genuinely expressed in a smaller proportion of both the renal and extra-renal rhabdoid tumours. This has been noted in renal tumours (Weeks, 1989). GFAP and S100 expression were also recorded in extra-renal rhabdoid tumours that were negative for NSE and neuro-filaments NF (Kent, 1987). An orbital rhabdoid tumour showed weak staining for S100 and NSE (Walford, 1992). A rhabdoid tumour in the liver stained with neural cell adhesion molecule and showed focal S100 positive staining (Foschini, 1992).

A neoplasm with rhabdoid cells in the bladder showed positive staining for NSE (Harris, 1987). An epithelioid sarcoma (Molenaar, 1989) showed focal staining for S100 protein.

APUDomas and neuro-endocrine tumours from both the neuro-ectoderm and the intestine have also been shown to occasionally contain whorled FCIs, but nearly always in association with easily found neuro-secretory granules (Weeks, 1991). Whorls of intermediate filaments in several such tumours corresponded to the immunohistochemical expression of neuro-filament proteins on light microscopy (McNutt, 1985). Cytokeratins were expressed diffusely in the cytoplasm of some of these tumours (McNutt, 1985). Renal hilar neuro-endocrine tumours described by Weeks (1991) expressed NSE in their whorled filamentous inclusions.

The first documented association of MRTK and primary brain tumours appeared in the literature in 1984 (Bonnin, 1984). This series of cases included six MRTKs and one WT, and all were associated with central nervous system neoplasms. The brain tumours were the presenting lesions in some cases, and the renal lesions in others.

The primary brain tumours associated with MRTK were three cerebellar medulloblastomas, one cerebral neuroblastoma, one microscopic and infiltrative pineoblastoma that was only apparent at autopsy, and one tumour resembling a subependymal giant cell astrocytoma. This last lesion is intriguing. Unlike typical subependymal giant cell astrocytomas it contained a high mitotic rate. No ultrastructural examination was performed. We have observed that rhabdoid cells in brain tumours are phenotypically very similar to the tumour cells in subependymal giant cell astrocytoma in some cases. The WT in the series was associated with a posterior fossa medullo-epithelioma with focal ependymoblastomatous differentiation.

Palmer (1981) reported on twenty patients with MRTK and associated brain tumours. Twelve of these brain tumours were biopsy proven second primaries and included ten medulloblastomas, one astroblastoma and one ependymoblastoma. Sotelo-Avila (1986) noted an association between three MRTKs and intracranial masses.

Histology was obtained from the brain of one of these patients, and the

intracranial lesion turned out to be a PNET. Howat (1986) described a PNET of the third ventricle with focal astrocytic differentiation that developed in a child six months after a MRTK. This brain tumour contained no FCIs on ultrastructural examination, and the neoplastic cells in the brain were positive for GFAP. The MRTK did not express this antigen. Other cases of MRTK associated with medulloblastoma have also been described (Gansler, 1991).

Many other brain tumours have been noted in association with MRTK.

Unfortunately in many cases there is no histological confirmation. MRTK by itself also has a propensity to metastasise to the brain. Bonnin (1984) describes four biopsy proven brain metastases in a series of twenty MRTKs with central nervous system lesions. Many neuro-secretory granules were present in these lesions, together with fine cellular processes. This information together with the occasional secretion of parathyroid-like hormones by renal rhabdoid tumours (Mayes, 1984) has led to the plausible suggestion that neuro-epithelial differentiation maybe present in these lesions. As described an association between MRTK and central nervous system tumours has been noted on several occasions.

A possible histiocytic histogenesis was proposed for some of the first cases of rhabdoid tumours described. These cases were published during the period where a trend to implicate histiocytes in the histogenesis of many malignant neoplasms was in vogue. A large variety of lymphomas were originally thought to be of histiocytic histogenesis. Most of these are now known to be of T- or B-cell origin. The evidence for a histiocytic origin is circumstantial, and not that convincing. Both renal and extra-renal rhabdoid tumour cells nearly always contain lysosomal bodies on ultrastructural examination, but so do the blastemal cells of WT (Weeks, 1989). WT clearly does not have a histiocytic origin. Lysosomal bodies are also visible within the cytoplasm of the epithelial cells of the proximal convoluted tubules of the kidney, and in many other diverse cell types. Diffuse dot-like positivity for lysozyme

alpha I antitrypsin and alpha I antichymotrypsin have been repeatedly noted in the cytoplasm of many rhabdoid cells (Weeks, 1989). (Own observations). This staining presumably correlates either to the lysosomal bodies or to proteinaceous bodies within the cisternae of rough endoplasmic reticulum.

Gonzalez-Crussi (1982) noted that suspensions of the tumour cells from two MRTKs formed EAC rosettes with sensitised sheep red blood cells. This investigation is used to detect complement receptors in haematological preparations, and can be used to identify T-cells.

Such tests are very rarely carried out on soft tissue neoplasms, however, and the significance of this finding is therefore debatable. Ingestion of Zymosan granules by the same tumour cells does not imply a particular histogenesis, as many different cells are involved in pinocytosis and active transport. Ingested proteinaceous droplets are often seen in the cells of poorly differentiated sarcomas. (Own experience). Lemos (1978) reported on an a malignant thymic tumour in an infant with poorly cohesive cells fulfilling the diagnostic criteria for an ERRT. These cells showed erythrophagocytosis, and were distinctly positive for CD1 antigen.

Unfortunately thymic epithelial cells often contain lymphocytes within their cytoplasm, so erythrophagocytosis may not necessarily imply a histiocytic histogenesis even if one is certain that the phenomenon is occurring in the tumour cells and not in admixed reactive macrophages. Thymic epithelial cells themselves also tend to show the phenomenon of emperipolesis.

Both Lemos (1978), Gonzalez-Crussi (1982) and subsequent investigators have noted complex villous-like interdigitations on the borders of rhabdoid cells, but these do not resemble true filopodia and do not necessarily imply a histiocytic histogenesis. We are not aware of any convincing ultrastructural evidence of skeletal muscular differentiation in rhabdoid tumours in the literature, although rhabdomyosarcomas

have occasional cells with filamentous cytoplasmic inclusions (Kodet, 1991).

Immunohistochemical evidence of myoglobin and desmin positive staining of the cytoplasmic inclusions has occasionally been documented (Weeks, 1989). These results have not been convincing, and myoglobin antibody staining in particular is notoriously difficult to interpret because of heavy background artefact. Rhabdoid filamentous inclusions also non-specifically mop many antibodies leading to dubious results, as previously discussed. Although the precise histogenesis of MRTK has not yet been established, the majority of these tumours probably represent a single clinico-pathological entity, because they all present within a narrow age range in young infants (Weeks, 1989). Most also appear to arise in the hilum or medulla of the kidney, and nearly all of these tumours carry a dismal prognosis.

1.4 Extra-renal rhabdoid tumours.

The picture with ERRT is unfortunately far more complex. Whilst a few tumours in the literature are totally undifferentiated and morphologically indistinguishable from MRTK, the majority display subtle poorly differentiated features indicating an alternative diagnosis. Characteristic rhabdoid cells have been found in malignant melanomas (Bittesini, 1992), epithelioid sarcomas (Molenaar, 1989) (Tsuneyoshi, 1987), myxoid chondrosarcomas (Tsuneyoshi, 1987), mesotheliomas (Tsuneyoshi, 1987) and malignant epithelioid Schwannomas (Morgan, 1985) (DiCarlo, 1986). In addition, intracytoplasmic whorls of intermediate filaments expressing vimentin and cytokeratin have been demonstrated in poorly differentiated endometrioid and thyroid carcinomas (McNutt, 1985). A poorly differentiated colonic carcinoma with a rhabdoid phenotype has also been described (Chetty, 1993).

It appears that the rhabdoid cell is a phenotype that can be encountered in several extra-renal tumours. It is still possible that a minority of totally undifferentiated

ERRTs may represent a distinct clinico-pathological entity like their renal counterparts appear to do. Further research will, hopefully, either confirm or refute this possibility.

As a result of these discoveries it has become necessary to document the range of morphological and ultrastructural expression of both MRTK, and extra-renal lesions displaying a rhabdoid phenotype.

2. METHODOLOGY.

2.1 Case selection.

This is unfortunately a retrospective study because of the rarity of both MRTK and extra-renal lesions demonstrating a rhabdoid phenotype. MRTK accounts for less than 2% of renal paediatric neoplasms (Mierau, 1987). The risk of developing Wilms tumour in childhood is approximately 1 per 10,000 infants (Beckwith, 1990). The incidence of MRTK can therefore be calculated to be less than 1 per 500,000 infants.

All renal neoplasms in the archives of the Red Cross Children's Hospital Pathology Department were reviewed from January 1958 to December 1993 to establish the breakdown of the different tumours present. The light microscopic features and diagnosis were reviewed in each case. Rhabdoid tumour was first described as an entity in 1978 (Beckwith, 1978), and prior to this lesions would have been labelled as WTs. Blocks from lesions that appeared to represent rhabdoid tumours were retrieved. Sections cut from these blocks were submitted for further immunohistochemical examination, and others were restained with haematoxylin and eosin when necessary. After 1989 it had been the policy of the Red Cross Children's Hospital to submit representative tissue from all renal neoplasms for electron microscopic examination. Unfortunately several of the more interesting lesions arrived in the Department before this policy was instituted. If tissue from important tumours had not been submitted in glutaraldehyde for ultrastructural examination; the original formalin (Carson's) fixed tissue was obtained, if still available, and sampled for electron microscopy. If no other material was available, the original blocks were dewaxed and processed for ultrastructural examination. The extra-renal lesions include a diverse mixture of tumours, and were only included in the study if they contained large areas of cells demonstrating a rhabdoid

phenotype. The entity of malignant rhabdoid tumour had not yet been encoded in the Snomed system on our computers at the time of this study, and there was no systematic method of searching the archives to retrieve these cases.

This series of extra-renal cases was compiled through discussion of interesting problems at both the Red Cross Children's Hospital and Groote Schuur Hospital in the period 1991 - 1994. Not all poorly differentiated cases are submitted for electron microscopy during routine surgico-pathological diagnosis; and not all cases examined with electron microscopy are diligently reviewed for isolated FCIs. An attempt has been made to obtain ultrastructural material on all cases that demonstrated light microscopic features suggestive of rhabdoid differentiation. (Over this four year period). We are not in a position, however, to determine the true instance of this phenomenon in all the extra renal tumours in our archives. The clinical data and staging criteria for each case were secured from the hospital records, and where necessary by discussion with the appropriate clinicians.

2.2 Processing of material.

2.2.1 Light microscopy.

Haematoxylin and eosin stained frozen sections have been performed on one of the MRTKs (Case 1) and on Cases 1 and 4 of the ERRTs. Case 3 in the ERRT series was an intracranial tumour and brain smears were immediately fixed in absolute methanol and stained with haematoxylin and eosin. Case 5 was a liver tumour that was examined by fine needle percutaneous aspiration biopsy prior to surgery. The slides from the fine needle aspiration procedure were spray fixed before drying with a cytological fixative (Fencott cytological fixative - ether-alcohol with poly-ethylene glycol.) These slides were stained by the Papanicolaou method. The renal tumours and extra-renal lesions in the recent archives had all been fixed in 10% buffered formalin. One block of tissue was taken for every centimetre of greatest diameter of the renal tumours.

This method of sampling satisfies the NWTS guidelines (Kaschula, 1996) A minimum of 10 blocks had been submitted for each case even if the tumour was less than 10 cm in diameter. This method of sampling unfortunately did not apply to a lesion that arrived in the Department in 1958 which was identified as a rhabdoid tumour on review. Only two blocks were taken from this tumour, which had been intuitively labelled at the time as an “unusual anaplastic WT” long before the entity of MRTK had been described, and before guidelines for adequate tumour sampling had been established.

The tissue of the case seen in 1958 had been fixed in unbuffered 10% formalin. All tissue blocks in this series were processed to wax blocks, cut to 3 - 4 micrometers and the slides were stained with haematoxylin and eosin for routine analysis.

The number of blocks taken from the ERRTs depended on the amount of tissue obtained from each case, and small fragmented biopsies were submitted in several instances.

Special stains included Periodic Acid Schiff (PAS) with and without diastase predigestion in cases 1, 3 and 4 of the MRTK series, and with case 1 of the ERRTs. Reticulin stains were performed on MRTK cases 3 and 4 and on ERRT cases 3, 5 and 6. Sections from MRTK case 3 were also stained with the PERL's, palmgren and victoria blue stains.

2.2.2 Immunohistochemistry.

The slide mounted sections were dewaxed, and the endogenous peroxidase was blocked in 1% hydrogen peroxide/methanol. The sections were then digested using trypsin for 5 - 10 minutes before they were washed in 0,05 molar phosphate buffered saline (PBS) at pH 7.2. Microwave antigen retrieval was, however, used for desmin and synaptophysin. Detection of EMA required no antigen retrieval. Optimally diluted primary antibodies were applied and incubated overnight (or according to specifications) at 4°C after rinsing in 0,5 molar PBS. The biotinylated secondary antibodies were then applied and incubated for 10-20 minutes at room temperature. The

TABLE: 1

**PRIMARY ANTIBODIES USED IN THE
IMMUNOHISTOCHEMICAL INVESTIGATIONS**

Antigen specificity of antibody	Clonality	Commercial source	Dilution	Method of antigen retrieval used
Vimentin	Monoclonal	Dako	1/200	T
F8	Polyclonal	Dako	1/200	T
Muramidase	Polyclonal	Dako	1/200	T
alpha-1-AT	Polyclonal	Dako	1/1500	T
alpha-1-ACT	Polyclonal	Dako	1/1500	T
CD68 (KPI)	Monoclonal	Dako	1/1000	T
Mac 387	Monoclonal	Dako	1/150	T
Myoglobin	Polyclonal	Dako	prediluted	T
Desmin	Monoclonal	Dako	1/10	M
SMA	Monoclonal	Dako	1/1000	T
CK (HMW)	Polyclonal	Dako	1/1000	T
CAM 5,2 (CK8,18,19)	Monoclonal	Becton Dickinson	Prediluted	T
EMA	Monoclonal	Dako	1/10	N
GFAP	Polyclonal	Dako	1/300	T
NSE	Monoclonal	Dako	1/100	T
S100	Polyclonal	Dako	1/200	T
N/fil (NF 70 NF 200)	Monoclonal	Sanbio	1/10	T
Synaptophysin	Monoclonal	Dako	1/10	T
alpha-FP	Polyclonal	Dako	1/200	T
HBsAg	Monoclonal	Biogenics	1/100	T
CEA	Monoclonal	Dako	1/125	T

Method of antigen retrieval used.

T = Predigestion with trypsin.
M = Microwave retrieval.
N = No antigen retrieval used.

sections were stained with diaminobenzidine and counterstained with haematoxylin. The primary antibodies used are listed in table 1.

2.2.3 Ultrastructural studies (electron microscopy).

Small representative portions of all of the recent renal tumours, and cases 1-6 of the extra-renal series had been fixed in 3% collidine buffered glutaraldehyde, post-fixed in 1% collidine buffered osmium tetroxide, and then processed into Spurr's resin.

Semi-thin toluidine blue sections from each case were viewed under the light microscope to ensure that the tissue was adequately preserved and representative of the tumour. The presence of other cell types was identified under the light microscope and documented in order to facilitate ultrastructural interpretation of the material. All important toluidine blue stained semi-thin sections were photographed and correlated with the ultrastructural findings. This allowed for more careful meaningful interpretation of material, particularly when mixtures of cells are present.

Material was extracted from the blocks of case 2 of the MRTK series and case 6 of the ERRT lesions. These samples of tissue were dewaxed before being processed for electron microscopy. The blocks from case 2 of the MRTK series were 34 years old.

LIST OF SURGICAL CASES USED IN THIS THESIS

1. Malignant Rhabdoid Tumour of the Kidney.

Case:- Surgical Specimen No.

1.	SD 993/85	RxH
2.	SD 4/58	RxH
3.	SD 665/93	RxH
4.	SD 1193/88	RxH

2. Extra-renal Rhabdoid Tumours.

Case:	Surgical Specimen No	Anatomical location	*Diagnosis/Prognosed diagnosis
1.	SD 621/87 RxH	Paravertebral	
2.	SD 920/93 RxH	Paravertebral	
3.	SD 176/93		
	SD 416/91 & 413/91 RxH	Paravertebral	M.E.S.
4.	SD 973/93 RxH	Cerebrum	ATT
5.	SD 5685/92 GSH	Liver	HCC
6.	SD 9099/93 GSH	Vulva	

Abbreviations:

RxH Red Cross Hospital

GSH Groote Schuur Hospital

* Diagnosis/ Prognosed diagnosis (if other than undifferentiated ERRT)

MES = Malignant epithelioid Schwannoma.

ATT = Atypical teratoid tumour (Originally diagnosed as a PNET)

HCC = Poorly differentiated hepatocellular carcinoma.

**LIST OF OTHER SURGICAL CASES INCLUDED
IN THE DISCUSSION (BUT NOT EVALUATED IN DETAIL BECAUSE
THE PRIMARY DIAGNOSIS WAS OBVIOUSLY NOT THAT OF A RHABDOID
TUMOUR)**

Case.		Diagnosis.
SD 383/94	RxH	Hepatoblastoma
SD 2015/93	GSH	Fibro-lamellar carcinoma
SD 1060/93		
(and 14369/92)	GSH	Myo-epithelioma of the salivary glands.
SD 577/83	RxH	WT with lysosomal bodies mimicing a rhabdoid tumour.
SD 1193/92	RxH	Renal cell carcinoma RCC arising in a WT.

3. RESULTS.

The statistical breakdown of renal tumours encountered in children at the Red Cross Children's Hospital (1 January, 1958 - 31 December, 1993).

Diagnosis	No of Cases	Percentage.
WT	237	82,3
BMRTC	29	10,0
CMN	12	4,2
MRTK	4	1,4
RCC	6	2,1
Total No of cases:	288	100

MRTK accounts for 1,4% of the total number of renal neoplasms encountered in our series of patients. This is compatible with the experience elsewhere in the world where MRTK accounts for between 1-2% of all renal tumours in children. An interesting feature is the excessive number of BMRTCs in the Red Cross series. BMRTC accounted for 10% of the tumours in this series. The experience in the literature indicates that BMRTC accounts for approximately 4-6% of renal neoplasms in children elsewhere in the world. Our data indicates that MRTK and renal cell carcinoma in childhood are both extremely rare neoplasms.

3.1 Malignant rhabdoid tumour of the kidney. MRTK

3.1.1 Clinical data.

The clinical data is summarised in Table 2. The age at diagnosis varied between 4 months and 35 months. Three of the patients were male and one was a female in this particular series. The prognosis in all cases was dismal with a survival ranging between 3 and 6 months after diagnosis despite aggressive chemotherapy in two of the patients.

TABLE 2.

CLINICAL DATA.

RENAL RHABDOID TUMOURS (MRTK)

CASE	1.	2.	3.	4.
SEX	M	M	M	M
AGE IN MONTHS	35	32	4	19
DISEASE STAGE	3	1	1	4
SURGICAL REMOVAL	INCOMPLETE	COMPLETE	COMPLETE	INCOMPLETE
MANAGEMENT	CHEMOTHERAPY	RADIOTHERAPY	NIL	CHEMOTHERAPY
SURVIVAL IN MTHS	3	5	3 - died with brain met. Or second CNS primary.	6

3.1.2 Pathology.

3.1.2a Gross morphology. MRTK.

The renal tumours were all large fleshy masses that arose in the hilum of the kidney and spread into the overlying cortex (average diameter 11.5 cm). Cases 1, 2 and 3 were rather ill-defined with infiltrative edges. Interestingly case 4 was a well defined mass macroscopically resembling a WT. All neoplasms showed foci of necrosis macroscopically. There were no distinctive diagnostic features on macroscopic examination.

3.1.2b Light microscopy. MRTK.

Cases 1, 2 and 3 all contain numerous cells with the classic features of MRTK. The tumour cells contain large prominent pale staining vesicular nuclei, with prominent single nucleoli and some peripheral chromatin condensation. The majority of tumour cells in each case contain large, single hyaline glassy cytoplasmic inclusions, which sometimes indent the nucleus. The inclusions are weakly PAS positive and diastase resistant. Multinuclearity of the tumour cells is not a feature.

Cases 1 and 3 have small nests and thin trabeculae of tumour cells set within a hyalinised collagenous stroma, with a growth pattern rather reminiscent of the sclerotic variant of BMRTC. This resemblance is particularly striking in case 3, which also demonstrates areas of clear cell change in the cytoplasm, and areas of vascularity on the reticulin rather similar to that noted in BMRTC. Parts of case 3 appear to distinctly chondroid with metachromatic staining alcian material on an alcian blue preparation and lacunae like spaces. The alcian blue material disappeared, however, on pre-treatment with hyaluronidase. The collagen is so sclerotic and dense in some areas that it almost has an osteoid-like quality. Solid nests of tumour cells in a few areas of case 3 show central necrosis, degeneration

and cellular drop-out mimicing pseudo-tubules or acini. The resemblance to BMRTC in this case is heightened by the presence of occasional, presumably entrapped renal tubules.

The cytology of the malignant cells is obviously that of a rhabdoid tumour, however, and this feature distinguishes this lesion from a BMRTC.

The reassigned case from 1958 (case 2) contains monotonous sheets of characteristic rhabdoid cells but the inclusions are more evident in some foci than others. (Fig.1)

Case 4 is a notably unusual neoplasm, which apparently originated in the renal medulla. The tumour cells are suggestive of rhabdoid cells, but the growth pattern is distinctly epithelioid. The neoplastic cells demonstrate eccentric cytoplasmic eosinophilic inclusions. Macronucleoli are, however, only visible in a proportion of the tumour cells. Nests and cords of tumour cells are present in blood vessels, and in the perineural spaces and within the renal tubules (Figs 3 and 4). The gross impression of prominent tubular invasion extending up into the cortex is confirmed on the reticulin stain. Both the PAS and reticulin stains show retention of the tubular basement membranes, and neoplastic cells are visible within distended Bowman's spaces. In focal areas degenerative changes are evident which take the form of perinuclear clearing of the cytoplasm reminiscent of renal cell carcinoma. (Fig. 5)

Focal necrosis and associated small haemorrhages are also evident. There is an isolated focus of malignant epithelioid cells containing darkly eosinophilic, PAS positive intracytoplasmic globules of varying size. These globules are somewhat reminiscent of the protein deposits seen in the convoluted tubules of kidneys with the nephrotic syndrome. This curious phenomenon was first reported in 1989 (Fischer, 1989).

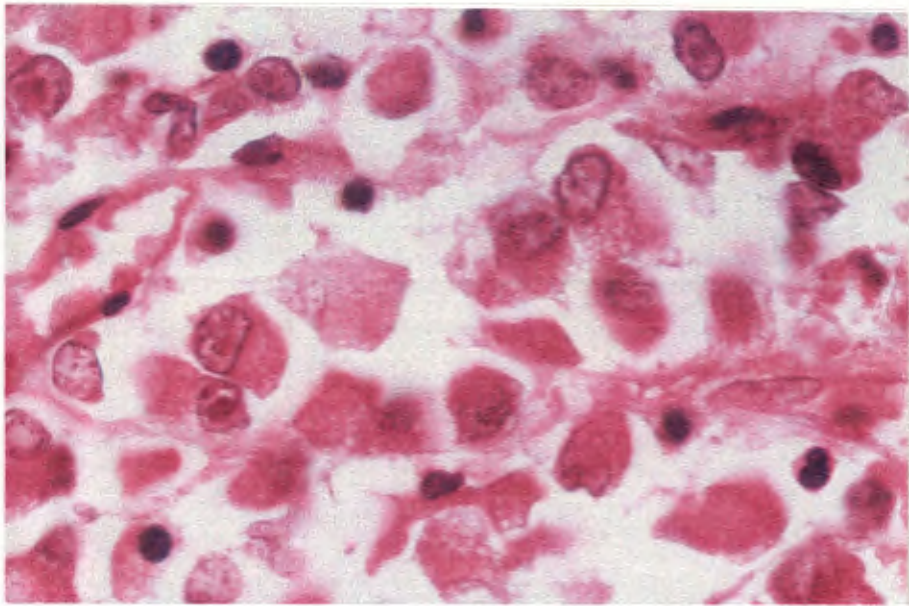


Fig. 1 Case 2 MRTK. This neoplasm was originally diagnosed as “an anaplastic variant of WT” in 1958. Review of the slides revealed an MRTK with monomorphic sheets of cells containing prominent eosinophilic macronucleoli and large eosinophilic cytoplasmic inclusions (H+E x 1242)

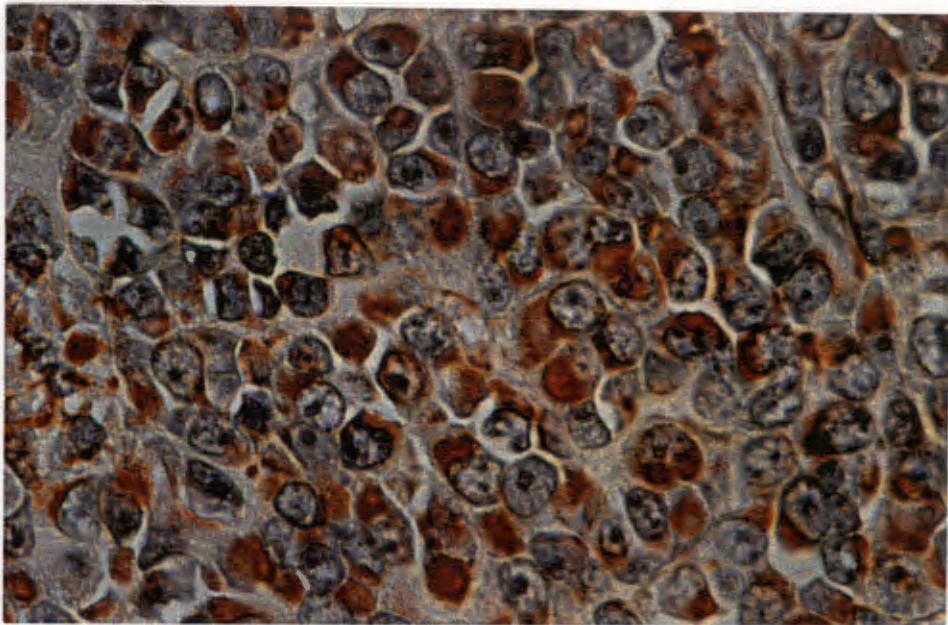


Fig.2 Case 2 MRTK. There is intense granular positive staining for vimentin within the FCIs (ABC x 497)

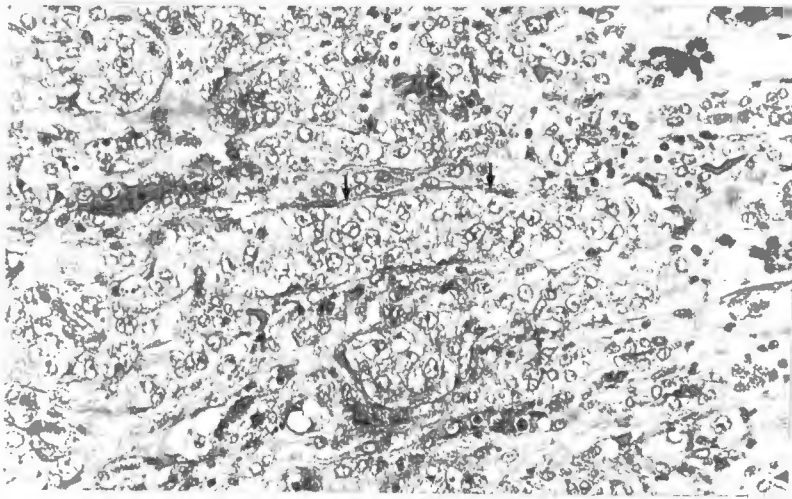


Fig.3 Case 4: Tumour invasion of renal cortex occurring along the renal tubules, arrows. (H&E x 128)

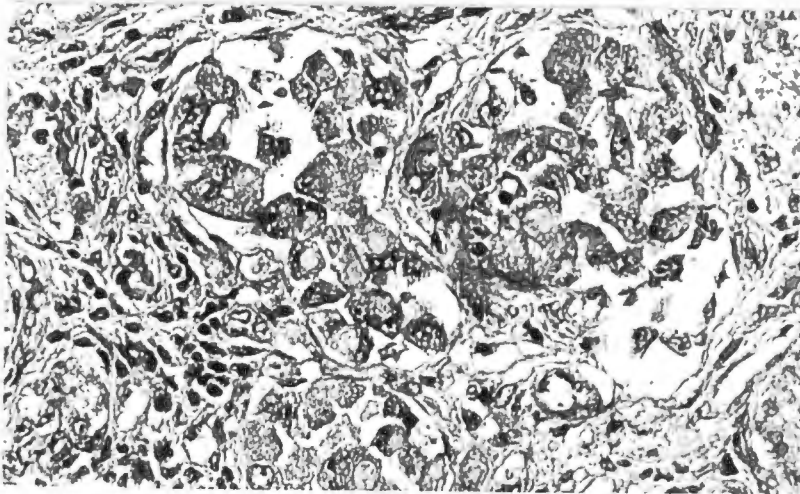

Fig.4 Case 4: A high power view of the tumour cells within tubular or vascular spaces showing the characteristic cytology or rhabdoid cells. (H&E x 400)

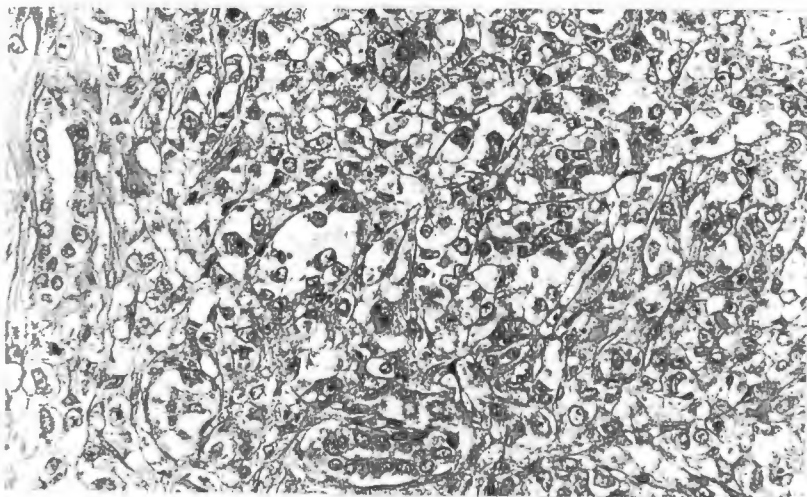


Fig.5 Case 4: A focus of tumour closely resembled clear cell carcinoma of the kidney. Surviving renal tubules are present (bottom centre and left). (H&Ex 160).

3.1.2c Immunohistochemistry. Renal Rhabdoid Tumours.

The cytoplasmic inclusions in all cases stain strongly for vimentin, with a crisp granular pattern of staining seen even in the sections recut from the 34 year old block of case 2. (Fig 2).

In the interpretation of immunohistochemical results only crisp granular staining of inclusions was accepted as positive. Diffuse muddy staining was discarded. This occurs with many of the antibodies, but particularly with myoglobin and is attributed to non-specific mopping up of the stain by the cytoplasmic inclusions.

The cells in cases 1 - 3 are positive for epithelial membrane antigen EMA. The tumour cells in case 4 are negative for EMA. Weak staining for CAM 5,2 is present in the cells of case 4. Case 3 demonstrates very scanty and focal CAM 5,2 staining, which is nevertheless fairly convincing. The other two tumours were negative for CAM 5,2, and none of the tumours appear to express polyclonal high molecular weight cytokeratin antigens. Nuclear and intracytoplasmic staining for S100 was noted in case 4, and case 3 showed fairly strong staining of some of the inclusions for this antibody. GFAP is expressed fairly strongly within the FCIs of 50% of the cells in case 4 in the absence of significant background staining. No convincing staining with antibodies to neurofilament proteins is apparent in any of these cases, although strong passive uptake is evident adjacent to necrotic foci in case 3. Positive staining of the inclusions for NSE were apparent in cases 3 and 4. Markers for alpha 1 anti-trypsin and alpha 1 anti-chymotrypsin show small positive granules within the cytoplasm both inside and outside the FCIs in cases 1, 2 and 3. The pattern of staining with these two antibody preparations correspond to the lysosomal bodies noted on ultrastructural examination. Interestingly muramidase was only expressed in case 1, and even in this instance in a rather equivocal manner. The

TABLE: 3

IMMUNOHISTOCHEMICAL RESULTS MRTK

CASE NO	1	2	3	4(MRTK with epithelioid features)
Vimentin	+	+	+	+
CAM 5,2	-	-	+	(+)
CK (HMW)	-	-	-	-
GFAP	-	-	-	+ (50% of cells)
N/fil	-	-	-	-
Desmin	-	- (1)	-	-
EMA	+	+	-	+
S100	-	-	+(3)	+/-
NSE	-	+	+(2)	-
Synaptophysin	-	-	-	-
Mac 387	+/-	-	-	-
Muramidase	+/-	-	-	-
alpha-1-AT	+(2)	+(2)	+(2)	-
alpha-1-ACT	+(2)	+(2)	+(2)	-
F8	-	-	-	-
SMA	-	-	+	-

Key:

- (1) Strong non-specific passive uptake of stain.
- (2) Staining of peripheral cytoplasm but not the FCIs.
- (3) Nuclear staining as well as cytoplasmic staining.
- +/- Inconclusive.
- (+) Very few tumour cells are positive.

results of the immunohistochemical investigations for MRTK are summarised in table 3.

Case 3 appears to express actin in its FCIs. This is interesting as there appear to be spindly density within the FCIs on electron microscopy. (Figs 9 and 10).

3.1.2d Ultrastructural examination.

Large cytoplasmic whorls of intermediate filaments are present in cases 1, 2 and 3.

Entrapped organelles such mitochondria are often present between these intermediate filaments. The whorls in case 2 are moderately well preserved, which is remarkable considering the fact that the material had been extracted from a 34 year old wax block. (Fig 8). The cells from all the tumours display isolated primitive cell junctions, lysosomal bodies and moderate numbers of free ribosomes. Scanty lamellae of rough endoplasmic reticulum and golgi apparatus are visible.

Case 1 contains isolated organelles resembling prelysosomes at the periphery of the inclusions. Unusual tubular inclusions of unknown origin are also present in this case. (Fig 7). They have dense borders and a longitudinal fibrillary matrix.

Structures suggestive of spindly densities appear to be present in FCIs of case 3 which raises the possibility of smooth muscle differentiation. (Figs 9 and 10). Pinocytotic vesicles and external laminae are not, however, visible.

Intermediate filament cytoplasmic inclusions are only present in very few of the tumour cells in case 4, which is the unusual neoplasm with epithelioid characteristics. The inclusions that are present consists of very loosely formed haphazard aggregates of intermediate filaments, unlike the tight concentric whorls noted in the other three cases. (Fig 11). Case 4 also shows extensive invasion of renal tubules on light microscopy and has some additional unusual ultrastructural features.

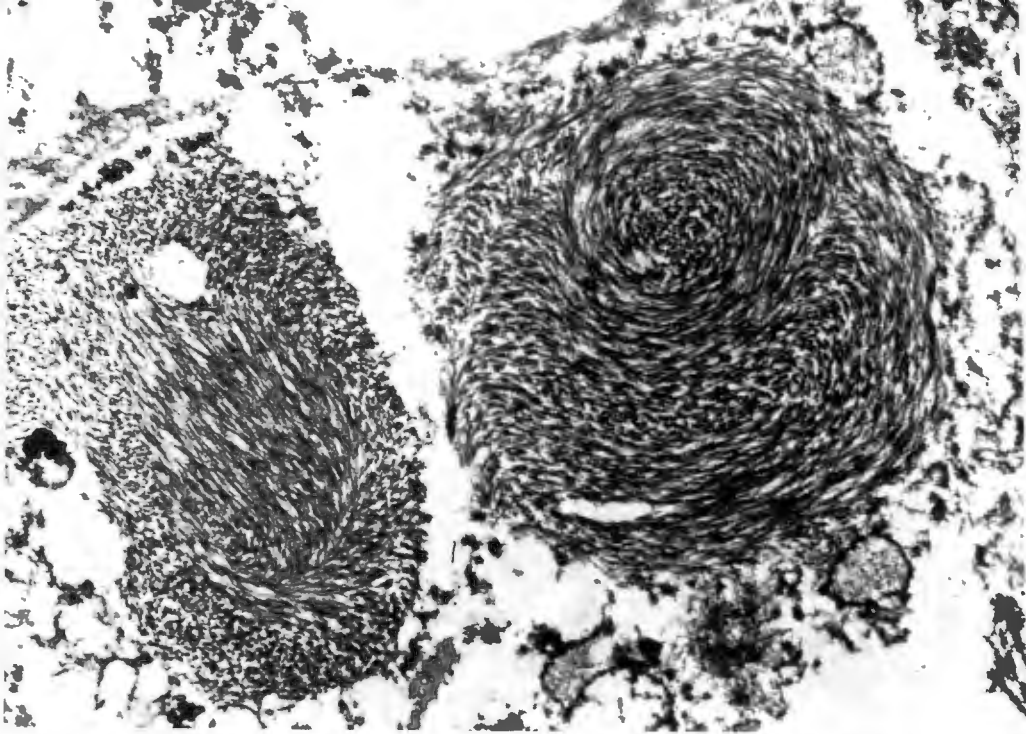


Fig.8 Case 2 MRTK. Relatively well preserved FCIs are present. Tissue in these 34 year old paraffin blocks was dewaxed and then processed for electron microscopy. (x 14560)

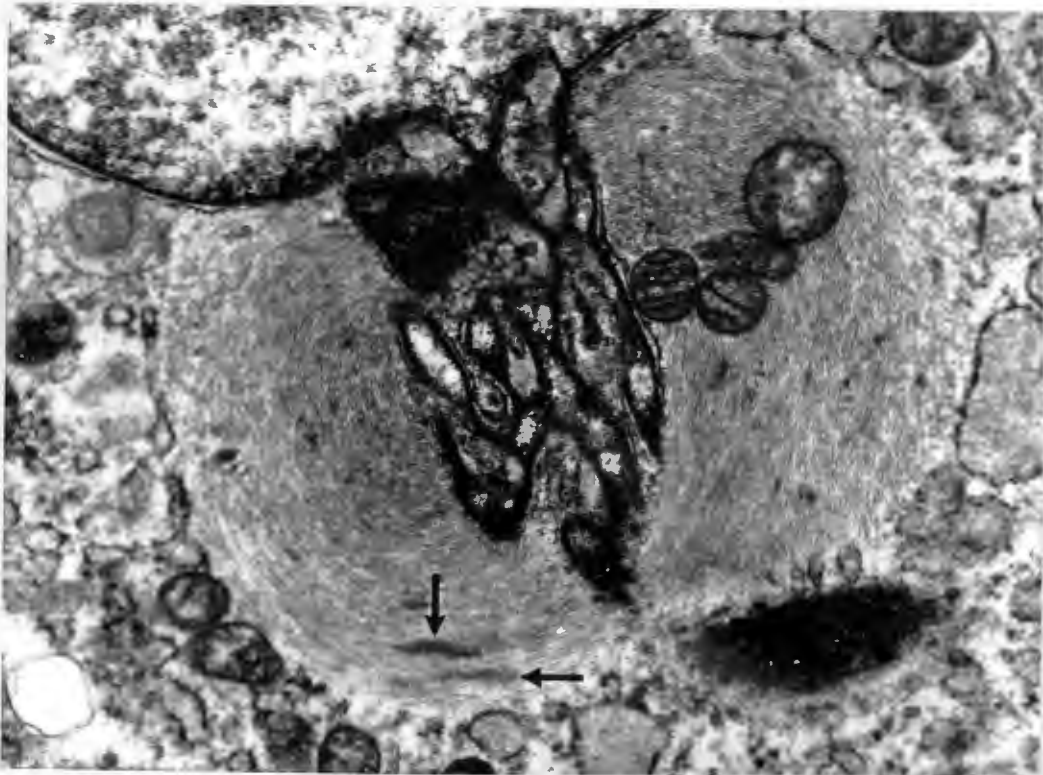


Fig.9 Case 3 MRTK. An FCI is present with an entrapped central cluster of mitochondria. Spindly densities appear to be present (arrows). (X 20800)

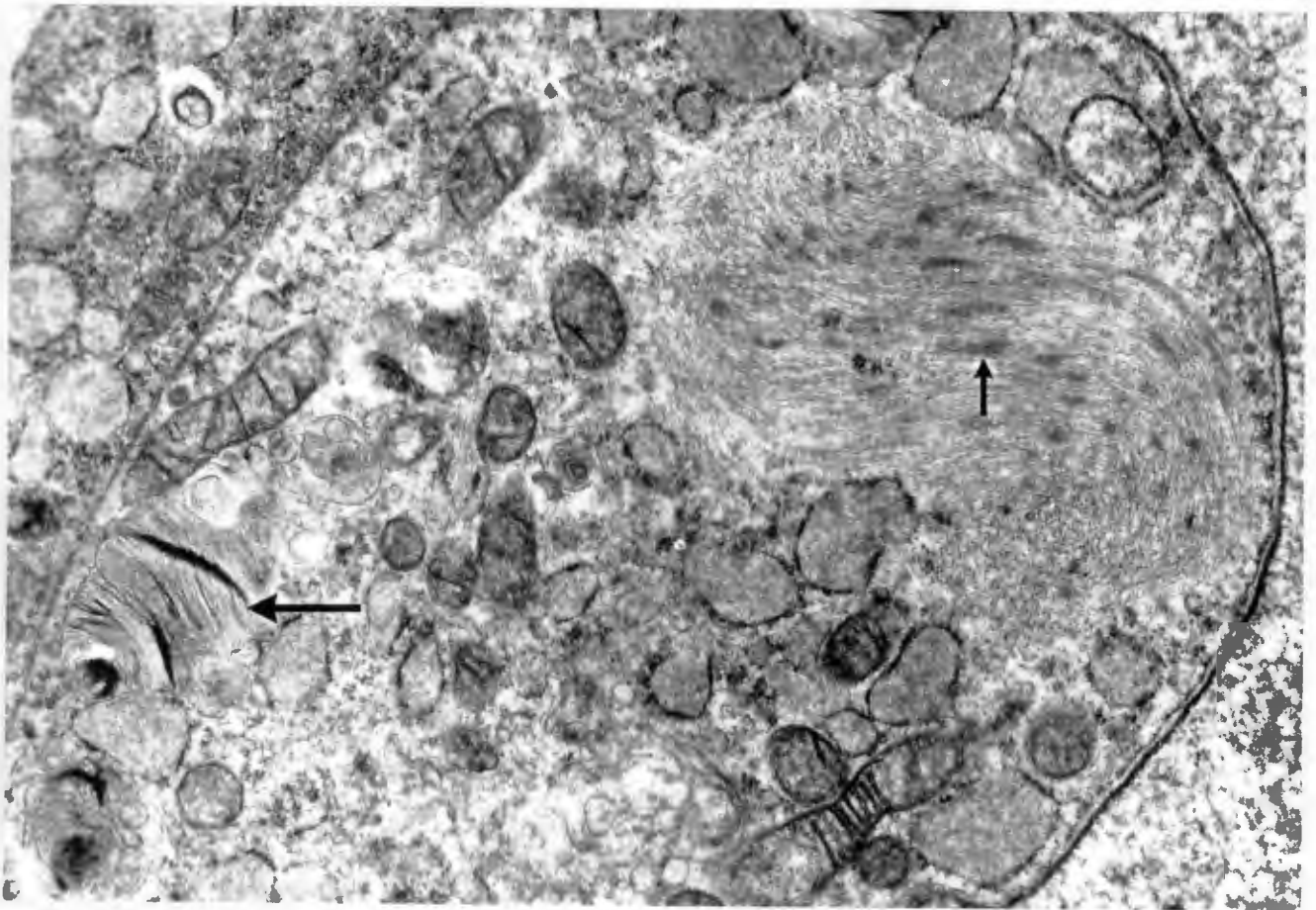


Fig.10 Case 3 MRTK. A large FCI is present. An intracytoplasmic phospholipid deposit is also present (large arrow). Spindly densities also appear to be present (small arrow). (x 28800)

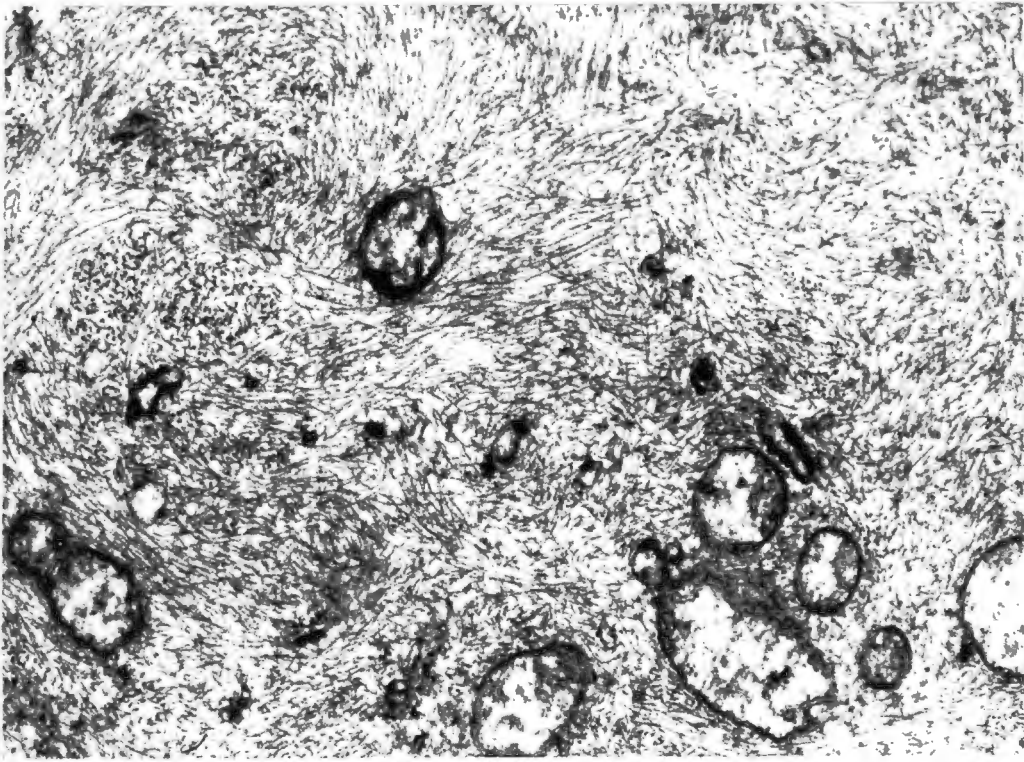


Fig.11 Case 4 MRTK. Loosely arranged whorls of intermediate filaments are present within the cytoplasm of some of the tumour cells. Entrapped mitochondria and fragments of rough endoplasmic reticulum are evident. (x 25600)

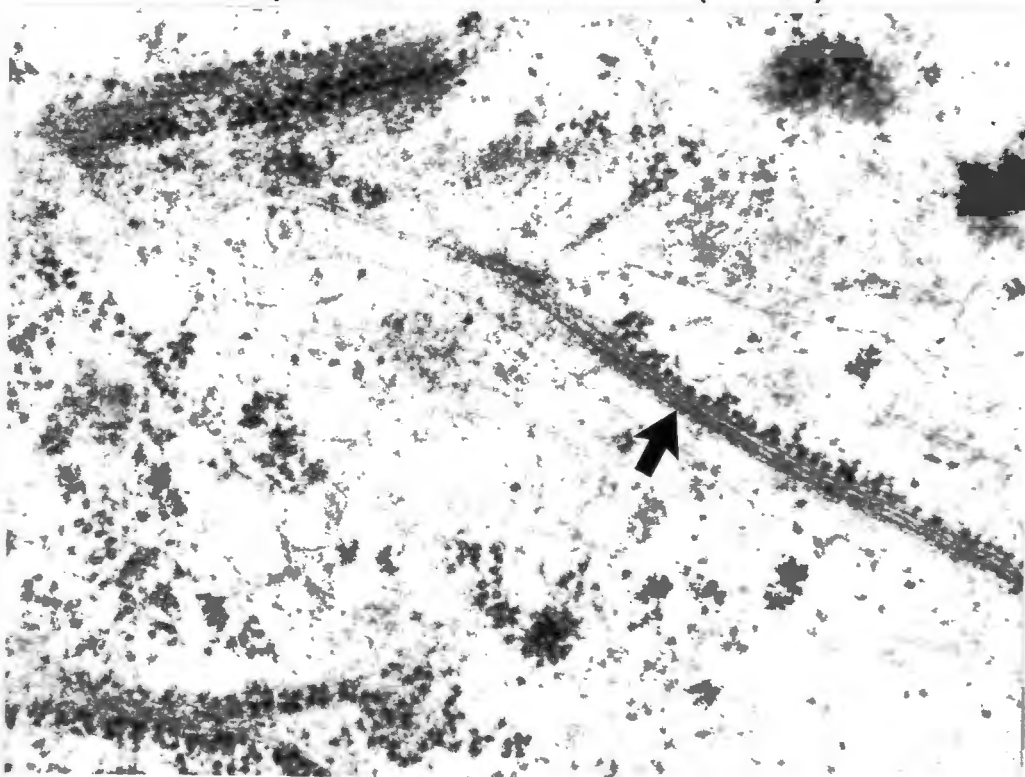


Fig.12 Case 4 MRTK. Thick and thin filaments with single file ribosomes suggest muscular differentiation. (x 48600)

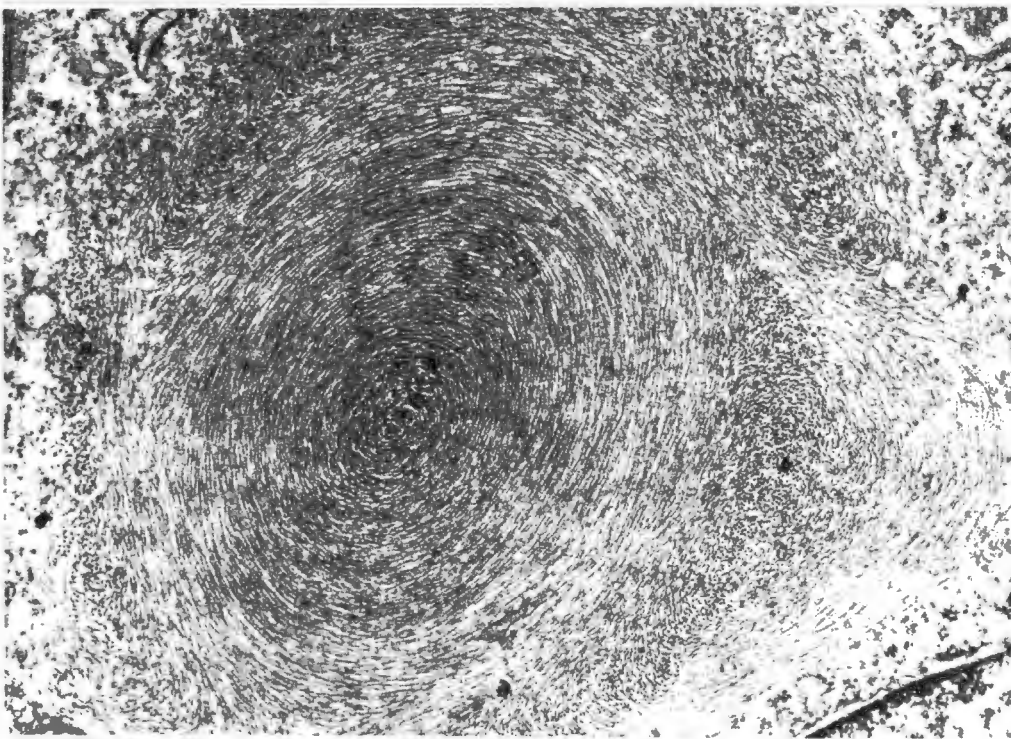


Fig.6 Case 1 MRTK. Demonstrating a large intracytoplasmic whorl of intermediate filaments (x 25 600)

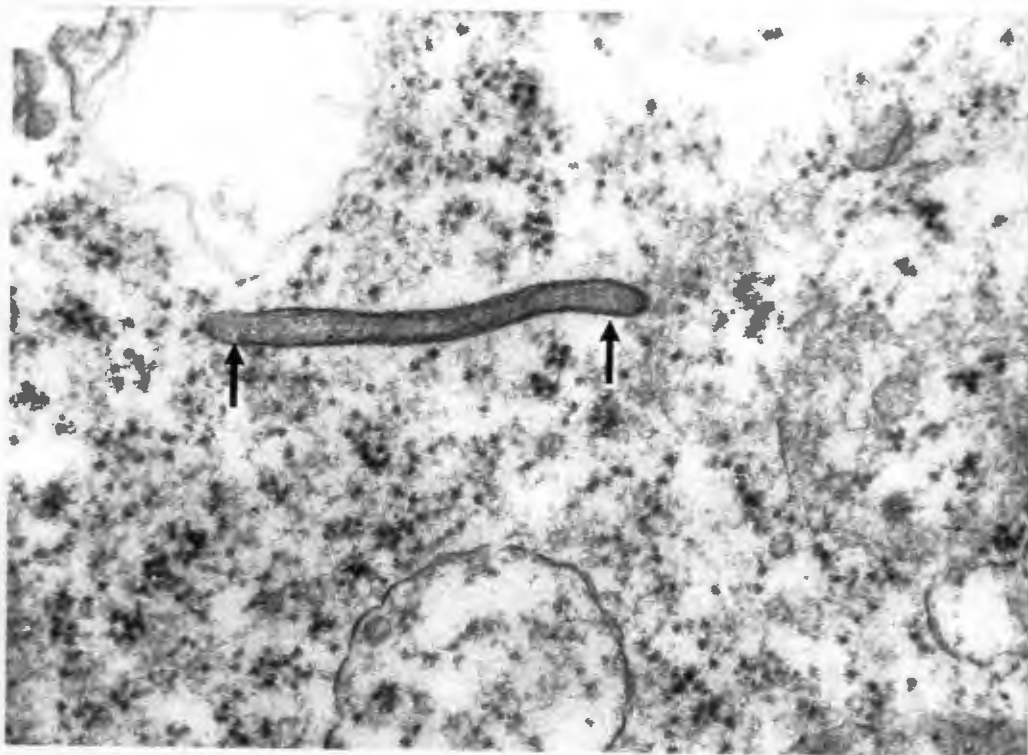


Fig.7 Case 1 MRTK. Unusual "sausage-shaped" intracytoplasmic inclusions of uncertain origin (arrow). (x 54675)

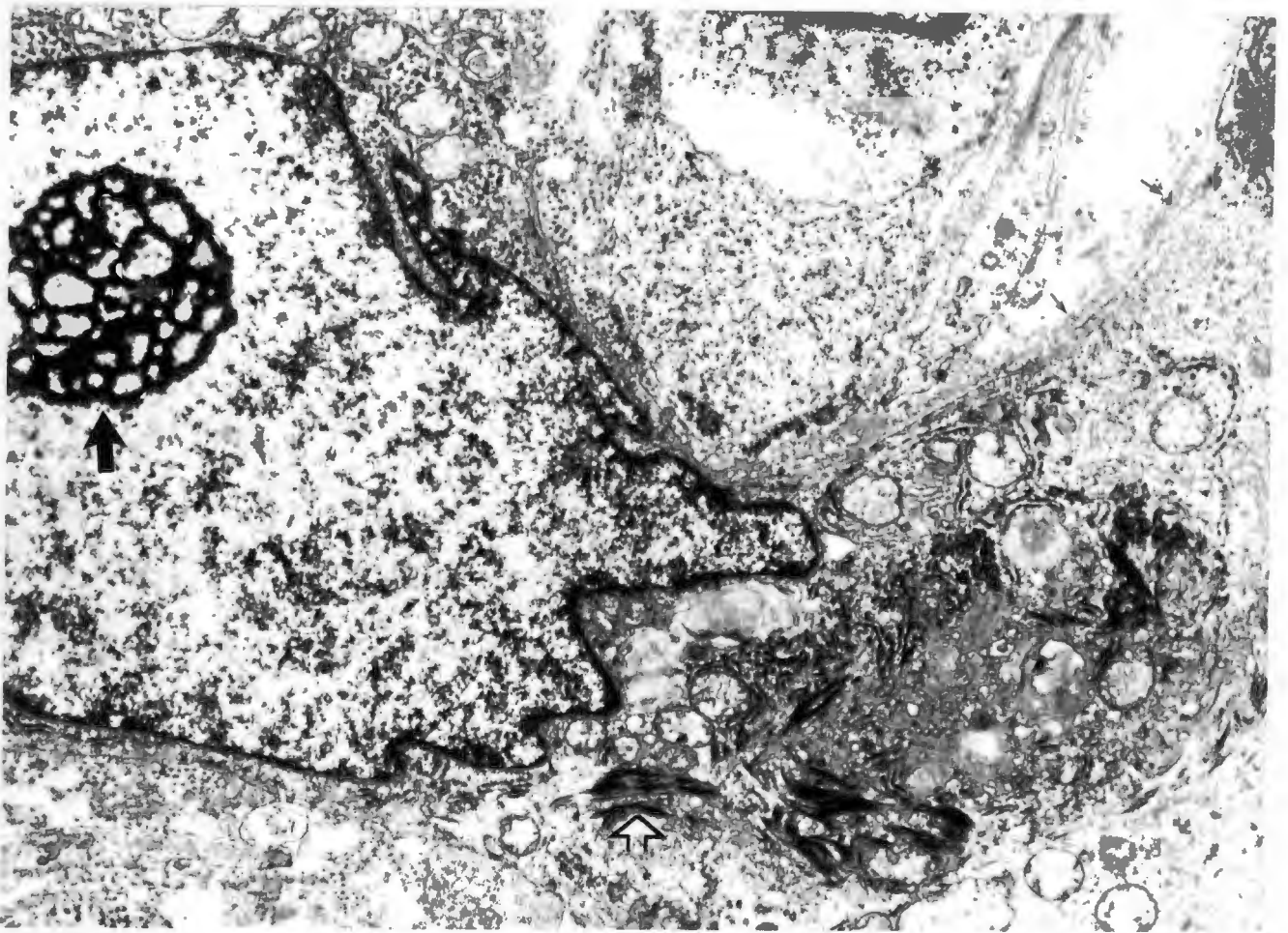


Fig.13 Case 4 MRTK. This tumour cell contains a prominent retiform nucleolus (large black arrow), tonofilaments and a continuous external lamina (small arrows) suggesting epithelial differentiation. (x 14 900)

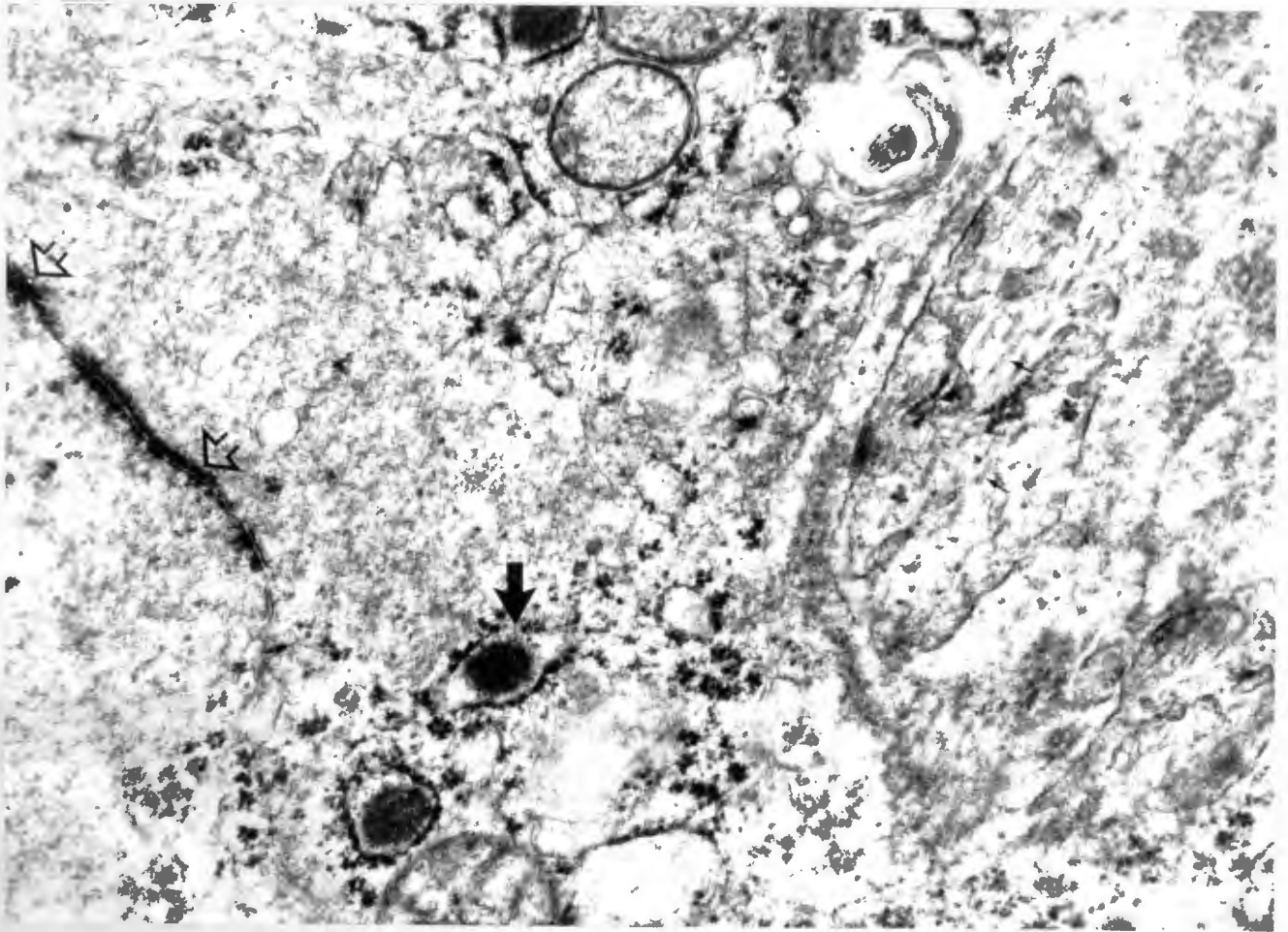


Fig.14 Case 4. A large junctional complex (large open arrows) is present. Amorphous possibly proteinaceous material is present within the distended rough endoplasmic reticulum (large dark arrow), which may correspond to the PAS positive globules seen on light microscopy. Two thin cytoplasmic processes contain numerous micro-tubules (small arrows) suggesting neural differentiation. (x 35040)

A few of the cytoplasmic processes contain moderate numbers of micro-tubules (Fig 14). No typical neuro-secretory granules are evident. Thick and thin filaments with single file ribosomes suggestive of muscular differentiation are also present within this tumour (Fig 12).

Tonofilament-like aggregates are evident within one cell that is surrounded by an external lamina (Fig 13). The cytoplasm of the cells appears to be continuous with that surrounding an adjacent large open nucleus containing a reteform macronucleolus. These epithelial features therefore appear to be present in a malignant cell although interpretation is difficult because an intimate admixture of tumour cells, histiocytes and renal epithelial cells is visible on the semi-thin toluidine blue section from which this grid was taken. No true desmosomes or desmosomes with peripherally inserted tonofilaments can be identified in this neoplasm. No fully developed basement membrane can be seen between the tumour cells. The original formalin fixed tumour tissue was retrieved and extensively sampled in the hope of finding an area of neoplasm free from the intermixed reactive epithelial cells for ultrastructural examination. Although one such area was obtained, the tissue preservation on ultrastructural examination was unfortunately too poor for meaningful interpretation.

Whilst the features on the original electron microscopic examination are highly suggestive of primitive epithelial differentiation; we cannot entirely refute the criticism that some of these cells may represent entrapped tubular epithelial cells.

No well defined features of clear-cut epithelial differentiation are present, and the site and age of presentation of this lesion suggest a malignant rhabdoid tumour. The behaviour of this lesion is also compatible with this diagnosis. The problems of diagnosis relating to this lesion are considered in the next section. (See discussion).

3.2 Extra-renal rhabdoid tumours. ERRT

3.2.1 Clinical data.

The clinical data for these cases has been summarised in table 4. Cases 1, 2 and 6 are undifferentiated lesions morphologically identical with the typical cases of MRTK. It must be pointed out, however, that only a small wedge biopsy of tissue is available from case 6. The findings in this biopsy may not necessarily be fully representative of the rest of the tumour.

Case 3 appears to represent a malignant epithelioid Schwannoma although the diagnostic criteria in the pure epithelioid variant of this entity are rather tenuous (Morgan, 1985) (Di Carlo, 1986).

The tumour from case 4 was originally diagnosed as a primitive neuro-ectodermal tumour (PNET) of the cerebral cortex.

Case 5 is possibly a poorly differentiated hepatocellular carcinoma.

Case 6 is a undifferentiated extra-renal rhabdoid tumour of the vulva. The diagnostic criteria to make these diagnoses will be discussed under the histological description of each tumour.

It is notable that the age range of these patients is wide, and varies from 36 months to 62 years. Although most of these lesions had a poor prognosis, the course was generally not as aggressive as that noted for the MRTKs. The 62 year old lady with a hepatic neoplasm is at present alive and well with no signs of recurrent tumour two years after the initial hepatectomy and clearance of the involved lymph nodes (follow-up data August 1994).

TABLE 4.

CLINICAL DATA

EXTRA-RENAL RHABDOID LESIONS:

CASE	1	2	3	4	5	6
SEX	FEMALE	FEMALE	FEMALE	FEMALE	FEMALE	FEMALE
AGE	113 MTHS	36 MTHS	10 YRS	61 MTHS	62 YRS	22 YRS
SITE	spinal canal and extradural	4 x 4 cm neck mass Horner's syndrome.	L 8 X 5 cm cervical mass. Vert. ext.	large R cerebral tumour	tumour R liver & L/N's	vaginal tumour and pelvic mass
Mx.	partial removal chemo.	Partial removal	partial removal. Laminect. Chemo. Radioth.	partial removal radioth.	R partial hepatect. L/N clearance.	Chemo. Radioth.
COURSE	29 mths died brain met.	?	alive with tumour at 36 mths.	alive at 6 mths.	Alive at 24 mths no tumour.	Died 6 mths multiple mets.

* Follow up data as at August 1994.

CASE 1, 2 and 6: Extra-renal rhabdoid tumour.

3: Primitive neuro-ectodermal tumour.

4: Malignant epithelioid Schwannoma.

5: Poorly differentiated hepatocellular carcinoma.

3.2.2 Pathology.

3.2.2a Gross morphology.

Cases 1, 2 and 3 were all ill-defined sarcomatous masses occurring adjacent to the vertebral column. Foci of necrosis were present in these lesions. Case 4, which was eventually diagnosed as a malignant epithelioid Schwannoma, appeared to arise in the brachial plexus and was inextricably intertwined with it. In case 2, the only material available for examination were scanty curettings. Several fragments of tissue were submitted at various stages from case 4 after relapses following chemotherapy. The largest of these measured 14 x 7 mm and consisted of firm whitish yellow tissue. The CT scans, however, revealed large paravertebral neoplasms in all cases.

Case 4 was a large partially necrotic primary brain tumour extending from the vertex of the skull down to the left sphenoid ridge of the left cerebral hemisphere on CT imaging.

The tumour within the fibrotic porta-hepatis of case 5 was difficult to identify macroscopically. The porta-hepatis lymph nodes did, however, appear to contain a neoplastic infiltrate.

Only a small polypoid biopsy of the large vaginal and pelvic malignant rhabdoid tumour (case 6) was submitted. No further surgery was attempted and permission for autopsy was refused.

3.2.2b Light microscopy.

Cases 1, 2 and 6 are undifferentiated malignant neoplasms with typical rhabdoid cytology. In cases 1 and 6 poorly cohesive sheets of typical polygonal rhabdoid

cells are present. In case 1 focal areas of spindle cell differentiation are visible. The majority of spindle cells still contain FCIs. Spindle cell change in some appears to be a degenerative phenomenon. In other foci it may be secondary to "crush artefact" (Fig 15). A few entrapped nerves are visible within this paravertebral tumour. Case 2 contains sheets and trabeculae of rhabdoid cells in a dense collagenous background although some more myxoid areas are apparent. A few crowded, moulded epithelioid like clusters of tumour cells are present.

Case 6 also contains a few nest-like foci of tumour cells. A Masson-Fontana stain for melanin is negative. Scanty isolated strands of loose connective tissue stroma are visible in the background.

Case 3 consists almost exclusively of sheets of monomorphic epithelioid and rhabdoid tumour cells. A few isolated foci show dense stromal collagenisation and a spindle-cell component which is presumably neoplastic. These spindle cells contain scanty wisps of cytoplasm, and thin wavy nuclei with tapered ends suggestive of a peripheral nerve sheath tumour. The nuclei in the epithelial cell areas are not as prominent as those noted in the other renal and extra-renal cases. Very scanty mitotic figures are present, with the highest count in any one area being 1 mitotic figure per 20 high-power fields. The average count is 1 mitotic figure per 30 high-power fields (200 hpf were assessed). Large nerve fascicles course through this tumour. (Fig 16). No Verocay bodies are evident, and no myxoid foci are visible.

The brain smears from case 4 show large numbers of poorly cohesive primitive small round blue neuroblastic cells. (Fig 17). A significant component of larger cells with "hard" eccentric eosinophilic cytoplasm is present, together with scattered very large reactive foamy macrophages. (Fig 18).

The larger eosinophilic cells show Homer-Wright type rosette formation in some areas of the smear. (Fig 18). Scanty thick-walled vessels are present. These are possibly of meningeal origin. No significant endothelial proliferation is visible.

The formalin fixed paraffin sections show similar features. Sheets of primitive neuroblastic cells are present. In areas of white matter adjacent to the tumour these small round blue cells form cuffs in the Virchow-Robin spaces around vessels (Fig 19). These are one of the "secondary structures of Sherer " (Sherer, 1938), and they indicate that this is a primary brain tumour.

Scattered large foamy macrophages are once again evident throughout this neoplasm. Sheets of rhabdoid tumour cells are present in other areas of the neoplasm (Fig 20). Prominent eosinophilic macronucleoli are present in these cells. The hard eosinophilic cytoplasmic inclusions in the cells of this case appear to be surrounded by halos of clear cytoplasm, but this is probably a fixation artefact. A background of neuropil appears to be present, even in these rhabdoid areas. Perivascular pseudo-rosettes are also present. Other large circular arrays of nuclei surround large central masses of neuropil.

Case 5 contains small nodules of tumour within the fibrous tissue of the porta hepatis of the liver. These nodules contain large characteristically rhabdoid cells with large open nuclei, amphophilic macronucleoli and eccentric eosinophilic cytoplasmic inclusions (Fig 23). Numerous mixed inflammatory cells are present between the malignant cells, with many lymphocytes, plasma cells and macrophages. Although a few multinucleated histiocytes are present, other giant cells with eccentric cytoplasm contain irregular nuclei, with clumping of the nuclear chromatin and large nucleoli suggestive of malignant tumour giant cells. Tumour giant cells are not an obvious feature of any of the other renal or extra-renal lesions.

The surrounding hepatic parenchyma shows no evidence of cirrhosis, and the architecture of the acini is preserved. Patchy macro-vesicular fatty change and isolated parenchymal

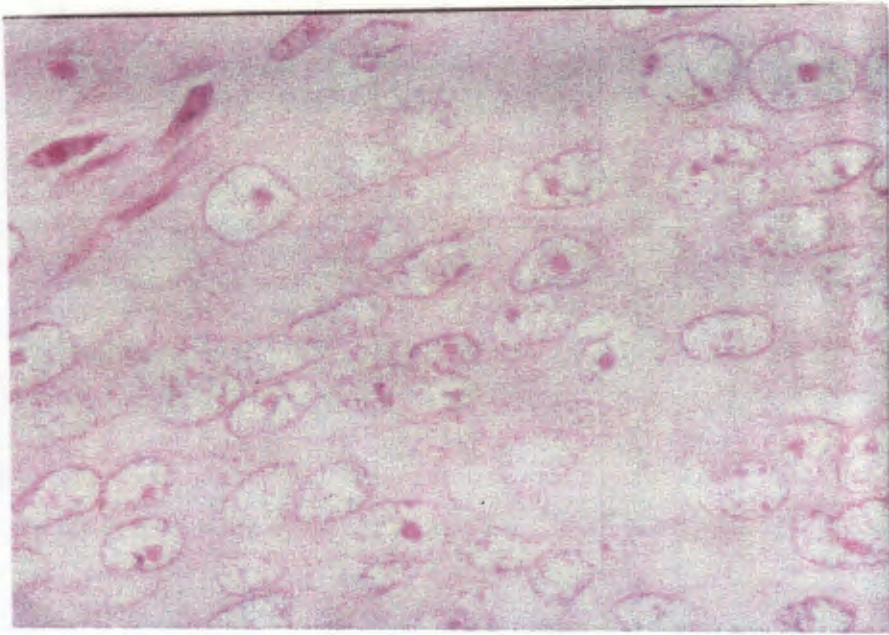


Fig.15 Case 1 ERRT. Cells with a typical rhabdoid phenotype are evident. Crush artefact possibly accounts for the spindle-cell morphology in parts of the tumour (H+E x 1242)

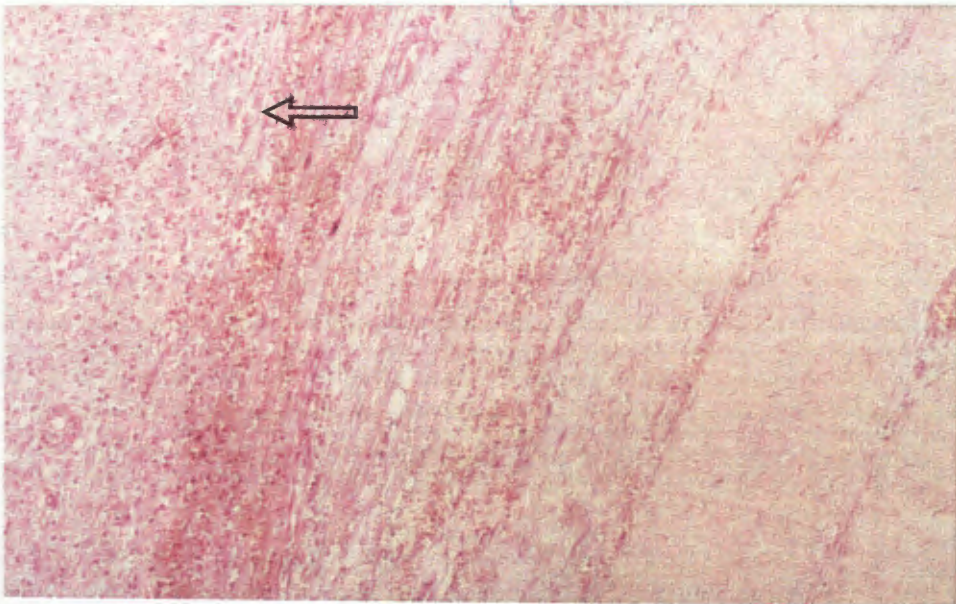


Fig.16 Case 3 ERRT. This purely epithelioid MES contains sheets of rhabdoid cells (open arrow) adjacent to a large nerve bundle (H+E x 124)

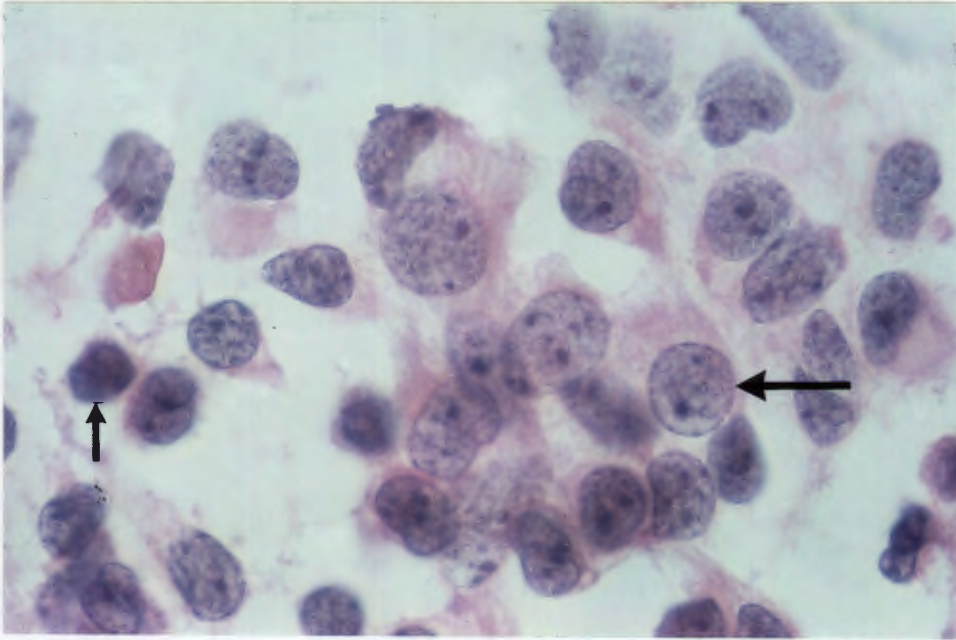


Fig.17 Case 4 ERRT. Smears from this primary malignant brain tumour (ATT) reveal numerous small, primitive neuroblast-like cells (small arrow), and occasional cells with abundant eccentric eosinophilic cytoplasm (large arrow) (H+E x 1242).

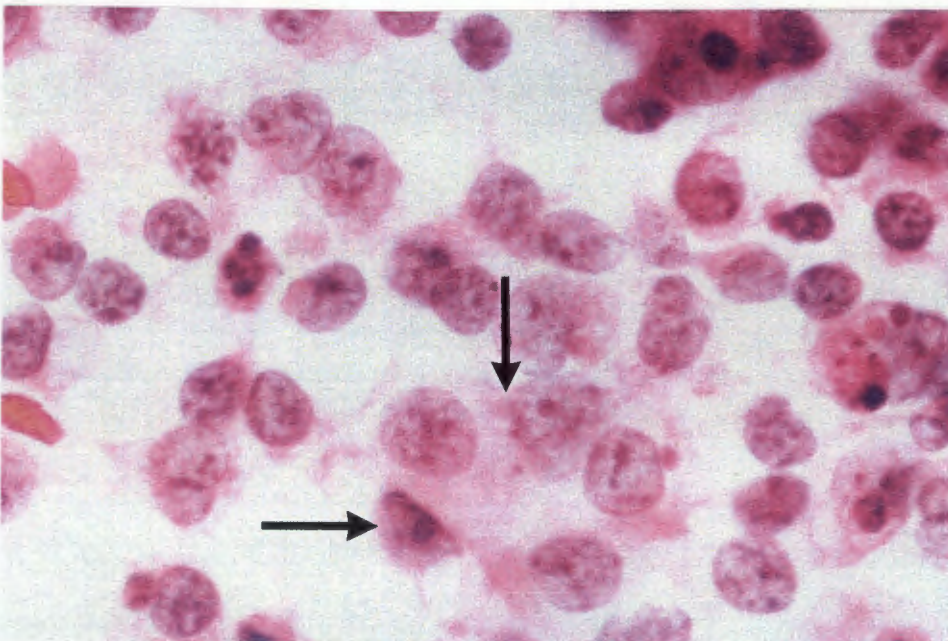


Fig.18 Case 4 ERRT. Another smear from the ATT reveals a Homer-Wright type pseudo rosette between the larger tumour cells with eosinophilic cytoplasm (H+E x 1242)

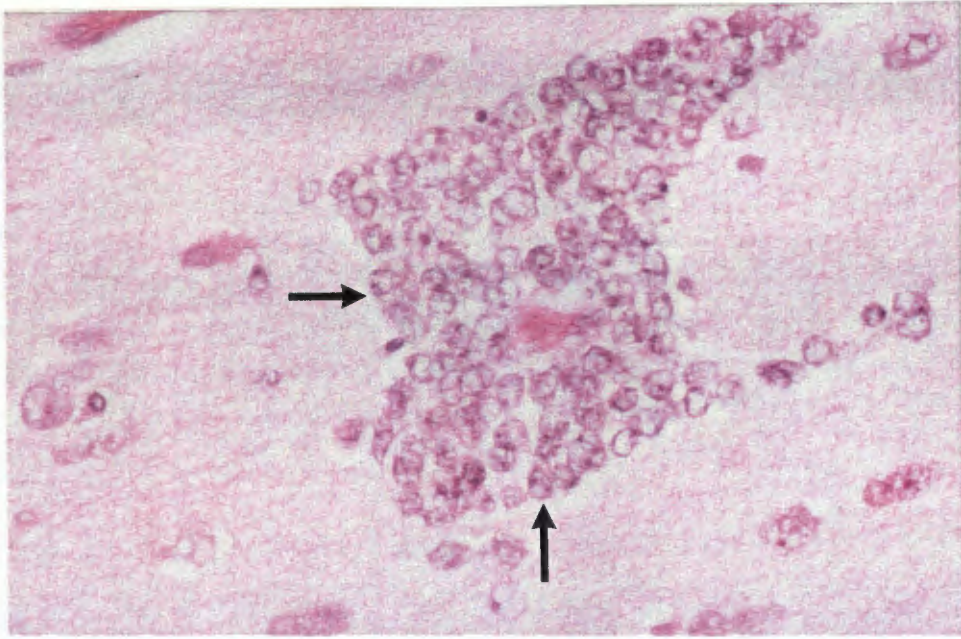


Fig.19 Case 4 ERRT. The surrounding white matter contains numerous small malignant immature neuroblastic cells within the Virchow-Robin spaces (ie secondary structures of Scherer are present)(H+E x 497).

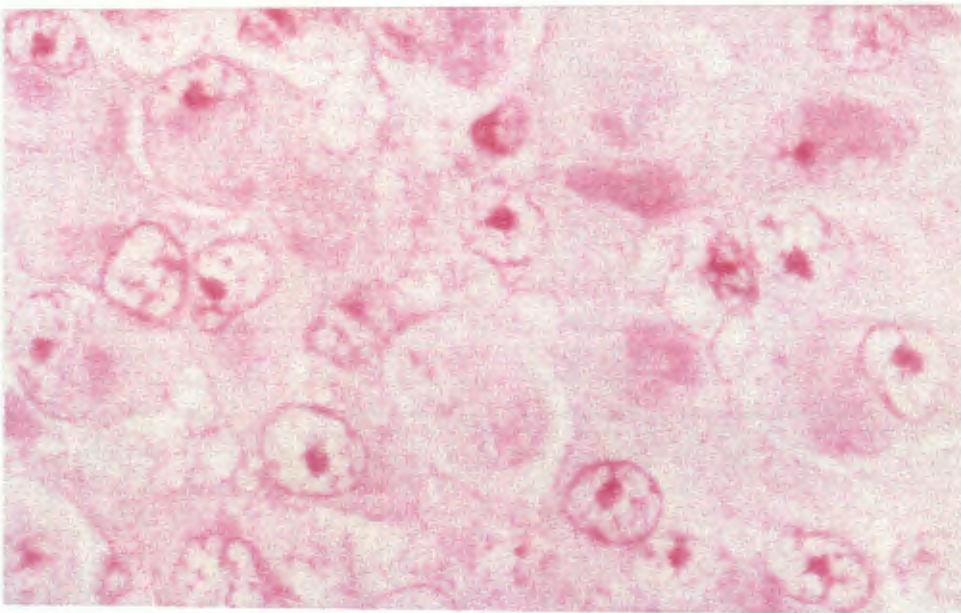


Fig.20 Case 4 ERRT. Large areas within this ATT contain sheets of rhabdoid cells (H+E x 1242).

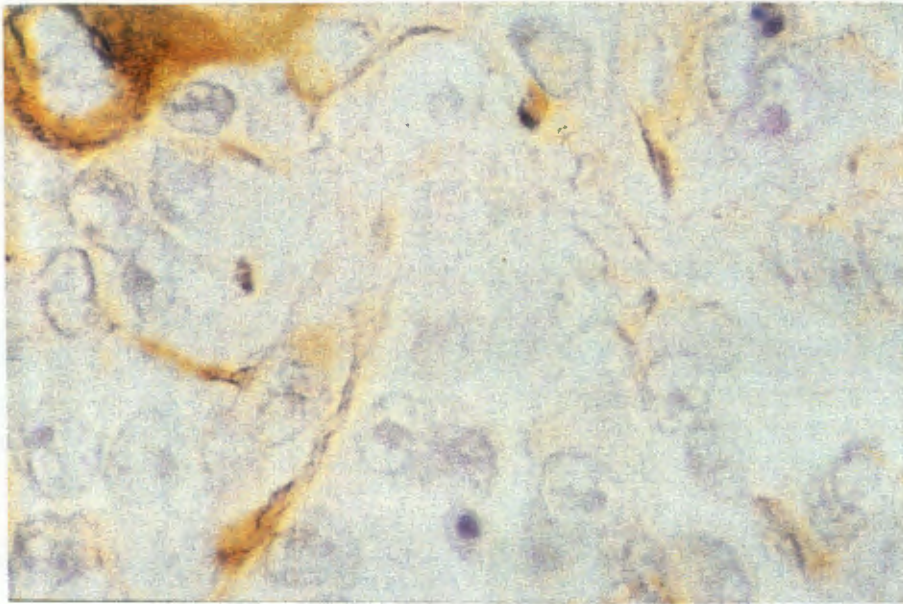


Fig.21 Case 4 ERRT. There is strong but focal immunohistochemical decoration of the neoplastic cells in this ATT for GFAP (ABC x 1242)

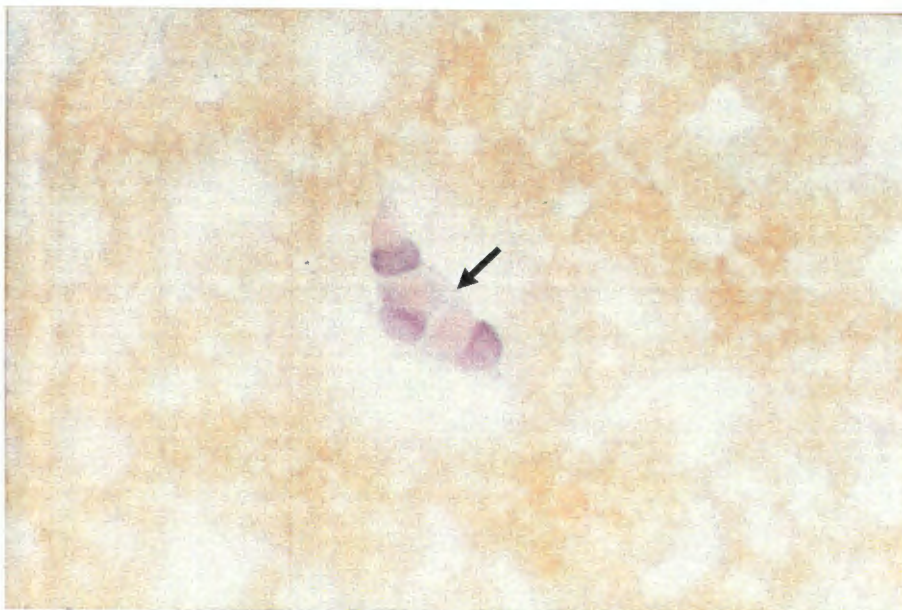


Fig.22 Case 5 ERRT. A percutaneous fine needle aspiration biopsy from this poorly differentiated liver tumour reveals malignant cells with a rhabdoid phenotype (Papanicolaou x 497)

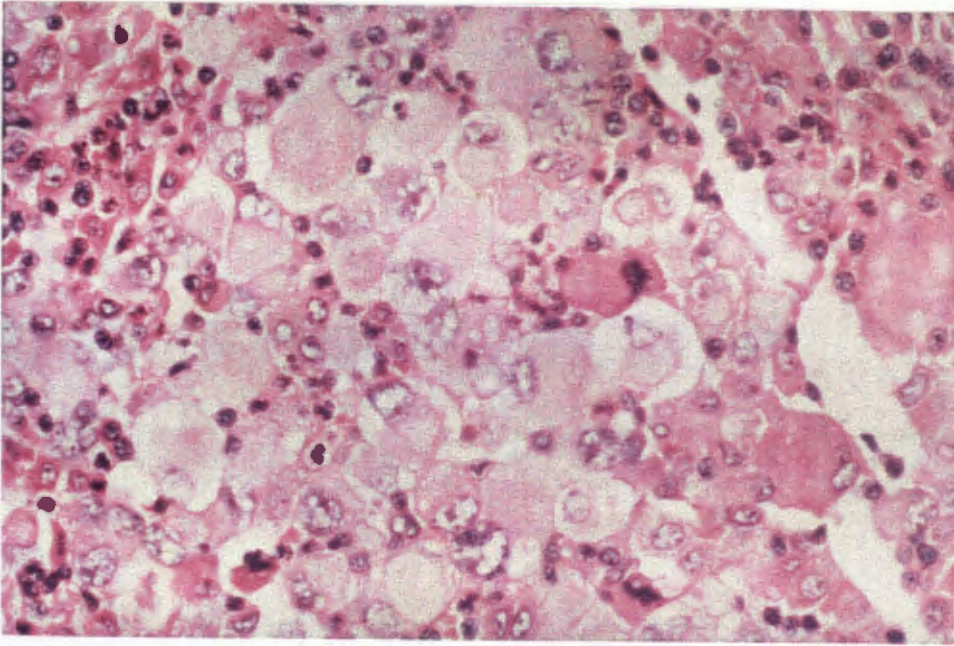


Fig.23 Case 5 ERRT. This poorly differentiated malignancy in the hilum of the liver contains sheets of rhabdoid cells. A surrounding mixed inflammatory cell infiltrate of lymphocytes and plasma cells is present. (H+E x 497).

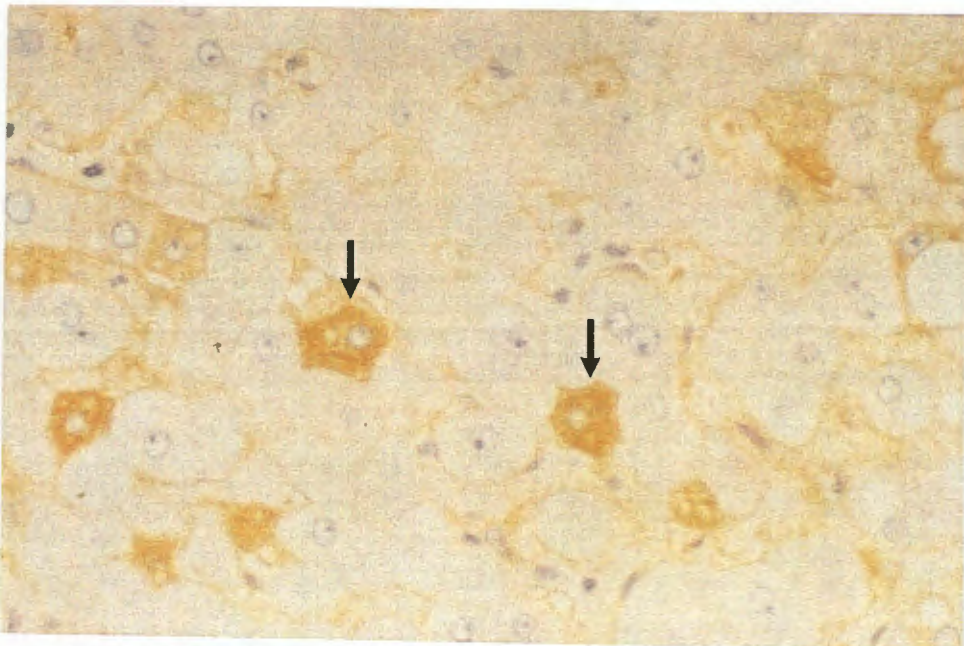


Fig.24 Case 5 ERRT. The surrounding liver contains scattered hepatocytes that show convincing diffuse intracytoplasmic positive immunohistochemical staining for hepatitis B surface antigen (ABC x 1242).

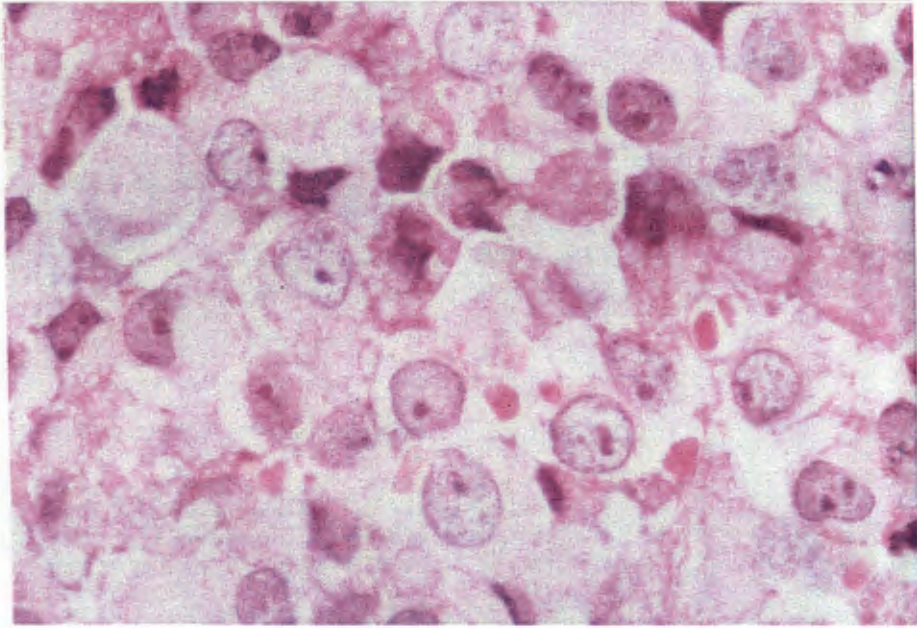


Fig.25 Case 6 ERRT. This malignant neoplasm from the vulva contains sheets of rhabdoid cells. (H+E x 1242)

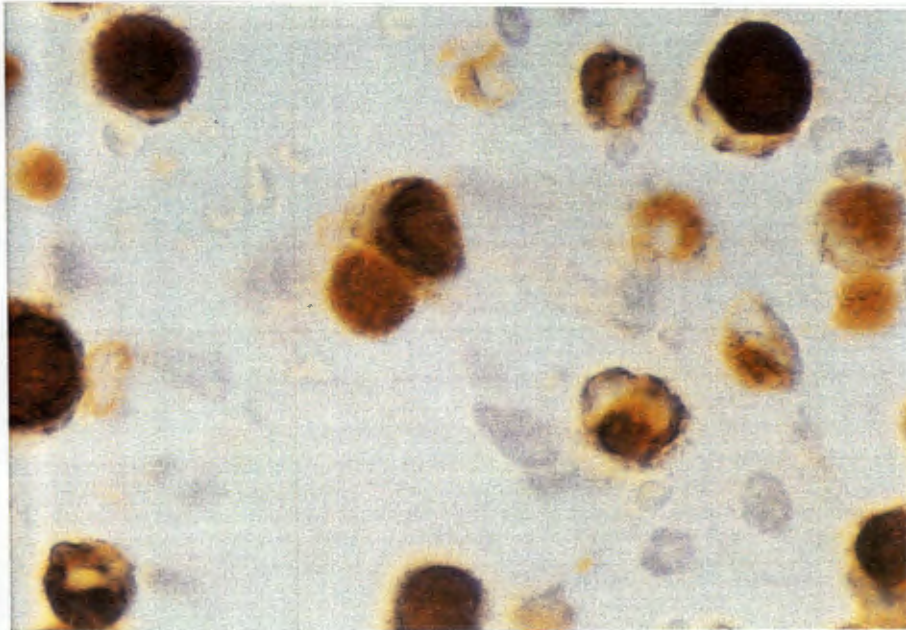


Fig.26 Case 6 ERRT. The FCIs are strongly positive for vimentin. (ABC x 1242).

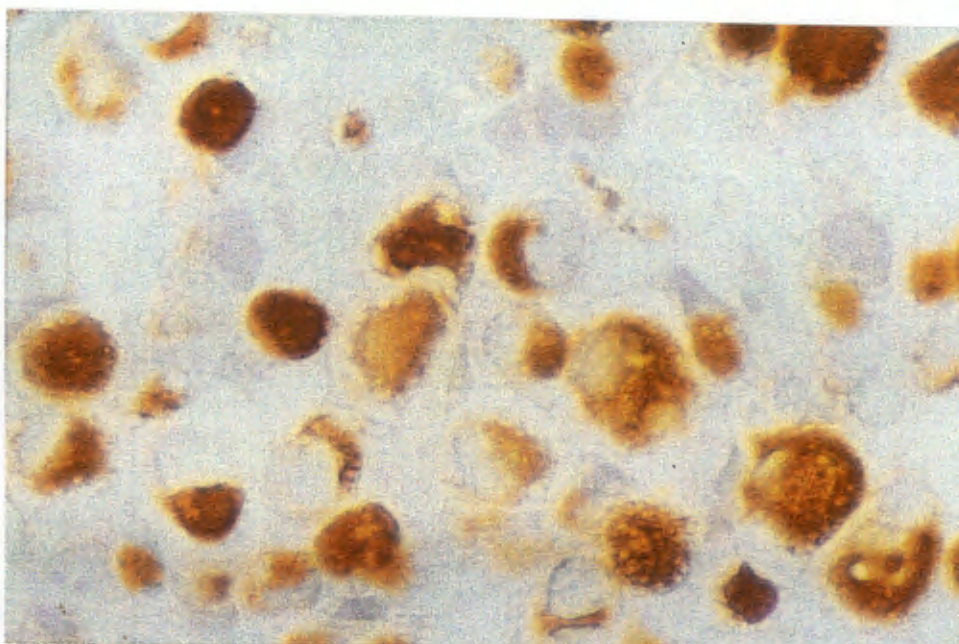


Fig.27 Case 6 ERRT. There is also intense positive staining of the FCIs within this vulval neoplasm for low molecular weight cytokeratins (CAM 5,2)(ABC x 1242).

lymphocytic infiltrates are most prominent near the tumour nodules, and may represent a reaction to the neoplasm. Hydropic degeneration and scanty intracytoplasmic pigment is evident in zone 3 of these acini. Mild cholestasis is present near the tumour. Occasional polymorphs and lymphocytes are present within the sinusoids.

No ground glass hepatocytes are visible on routine stains. The hepatocyte trabeculae are not thickened. Occasional binucleate and possibly regenerating liver cells are noted within the acini. A few foci of proliferating small bile ducts in the porta hepatis are possibly responding to the damage caused by the tumour.

3.3.3c Immunohistochemistry.

The results of the immunohistochemical investigations are summarised in table 5 & 6.

Immunohistochemical results are difficult to interpret in these cases because of non-specific mopping up of the material by the FCIs. Many of the results are therefore of dubious significance and therefore no apology is made for not applying the same complete panel of antibodies to each and every case. Convincing very strong positive staining is, however, apparent with vimentin antibodies in every case. Strongly positive staining with other antibodies can also be critical for correct interpretation and diagnosis of certain particular cases.

The diagnosis of malignant epithelioid Schwannoma in case 3 rested largely upon the confirmation of extensive positive nuclear and cytoplasmic expression of S100 within the malignant cells and the total absence of staining for EMA, CAM 5,2 and polyclonal cytokeratin antibodies in these cells. Although most malignant epithelioid Schwannomas also contain spindled cell areas with more obvious Schwannian differentiation, and also have focal areas of redundant external lamina on electron microscopy; at the same time these features are not always present and a purely epithelioid malignant Schwannoma can be a very elusive diagnosis. Occasionally the only criteria available for diagnosis is the

TABLE: 5

IMMUNOHISTOCHEMISTRY: (For intermediate filaments).**EXTRA-RENAL RHABDOID LESIONS. ERRT**

	CASE 1	2	3	4	5	6
Ab						
Vimentin	++	++	++	++	++	+++
CAM 5,2	-	++	-	-	+++	+++
CK (HMW)	-	-	-	+	+	
GFAP	-	+/-		++		
N/fil		+/-		++	-	
Desmin	- (1)	-		-		

DIAGNOSIS:

CASE 1, 2 and 6: Extra-renal rhabdoid tumour. ERRT

3: **Malignant epithelioid Schwannoma. MES**

4: **Atypical Teratoid tumour. ATT**

5: **Poorly differentiated hepatocellular carcinoma HCC.**

(1) Strong non-specific staining of the FCIs and background staining.

TABLE: 6

ERRTs: Immunohistochemistry (for antigens other than intermediate filaments.)

CASE DIAGNOSIS	1 Paraspinal ERRT	2 Paraspinal ERRT	3	4 ATT	5 HCC	6 Vulval ERRT
alpha FP					+/-	
EMA	+	+(4)	-	+/-	+	++
CEA					-	
HepBsAg					+	
S100	-	-	+++ (3)	++ (3)	-	++ (3)
GFAP	-	+/- (2)		++ (5)		
Synaptophysin	-	+ (2)		+		
NSE	-(1)			+/- (1)	+/- (1)	
Factor 8	-					
CD68				-(2)		
Muramidase			-			
Mac 387			-			
alpha-1-AT	+(2)	+(2)		-(1)		
alpha-1-ACT	+(2)	+(2)		+(2)	+(2)	

Key for Table 6.**Key to abbreviations:**

- ++ Strong positive staining.**
- + Moderate positive staining.**
- +/- Equivocal result**
- (1) Heavy non-specific background staining or non-specific mopping up of antibodies by the cytoplasmic inclusions, with a faint uniform stain and no granularity.**
- (2) Granular cytoplasmic staining away from the inclusions.**
- (3) Nuclear and cytoplasmic staining.**
- (4) Membrane staining only.**
- (5) Positive staining both in FCI and in dendritic cell processes between the tumour cells.**

clinical evidence of origin from the large nerve, and/or diffuse S100 positivity of the tumour cells in a deep seated neoplasm in the absence of epithelial markers! (Di Carlo, 1986).

Other important immunohistochemical findings in this series of extra-renal cases include:-

1. The tumour cells and dendritic process between the neoplastic cells in case 4 are both strongly positive for GFAP. (Fig 21). Focal positive staining for neurofilament proteins was also evident in the stroma of this neoplasm, and some of the neurofilament positive processes appeared to be connected to neoplastic cells. These results support the obvious diagnostic light microscopic features of a primary brain tumour.
2. Case 5 is thought to be a very poorly differentiated hepatocellular carcinoma. The FCIs in this case were very strongly positive for low-molecular weight cytokeratin markers (CAM 5,2). The ultrastructural findings in this case (to be discussed in the next section) also support a hepatocellular origin. Although the adjacent liver is not cirrhotic isolated hepatocytes in the surrounding residual liver tissue display diffuse cytoplasmic staining when tested immunohistochemically for hepatitis B surface antigen. (Fig 24). No intranuclear hepatitis B core antigen could be demonstrated. Occasional malignant cells also demonstrate this pattern of cytoplasmic staining for hepatitis B surface antigen. A radio-immuno-assay of the serum was negative for hepatitis B surface antigen. Unfortunately serology for hepatitis B was only performed on review of this case 20 months after the liver resection. The patient was brought in at this stage and blood was drawn for hepatitis B serological investigations. Certain mutant strains of hepatitis B virus may not react with the epitopes used in the radio-immuno-assay procedure. The immunohistochemical stains of the tissue sections are convincing, and indicate that this patient has/had a subclinical hepatitis B virus infection which would have predisposed to the development of a hepatocellular carcinoma. This patient's serum alpha-feto protein levels were not significantly elevated just prior to resection of

the liver tumour, however, with a level of < 1 ng/ml measured by radio-immuno-assay (Reference range: normal < 10 ng/ml).

3. Lysosomal staining with antibodies against alpha 1 antitrypsin and/or alpha 1 antichymotrypsin occurs in many of the tumours. Antigens which are more specific for macrophage differentiation such as Mac 387, CD 68 (KP1) and muramidase were not detectable on immunohistochemical evaluation of cases 2 and 3.

3.2.2d Ultrastructural examination.

All these cases have many tumour cells containing well-formed, dense whorls of FCIs within the cytoplasm. Various organelles are entrapped in these aggregates of intermediate filaments (Fig 28). Scattered very primitive cell junctions are present in all of these tumours. Fully developed desmosomes with a trilaminar structure and peripherally inserted tonofilaments were not identified in any of the cases.

The primitive cell junctions were fairly numerous in case 1, which was a paravertebral rhabdoid tumour. One oligocilium is visible in a tumour cell in case 1. Occasional microtubules are also present within the cell processes. The significance of this finding is uncertain, as entrapped nerve bundles are visible within the lesion on light microscopy. Nerves are not, however, obvious on the semi-thin toluidine blue stained sections. Numerous pinocytotic vesicles are present along the cell membranes of the this case, together with occasional "stud in button" type intercellular interdigitations. The plasma membranes lining these interesting interdigitations show some superficial resemblance to coated vesicles.

In addition to occasional well formed FCIs, case 2 which is also a paraspinal tumour also has many cells containing loose, disorganised aggregates of intermediate filaments.

(Fig 29). Aggregates of densely osmiophilic tonofilament-like bundles are evident in the centres of occasional aggregates of intermediate filaments. No external lamina is

obvious, although primitive cell junctions are present in small numbers. Thin protoplasmic cell processes are visible and small aggregates of micro-tubules are visible within a small proportion of the neoplastic cells. No neuro-secretory granules are evident. Epithelioid-like clusters of tightly apposed cells are present. Moderate numbers of free fat globules are present within the tumour cells, and phagolysosome-like structures are apparent. The malignant cells contain large skein-like reteform nucleoli, and several large bizarre mitochondria are present. Intra-mitochondrial inclusions are apparent, together with osmiophilic granular debris suggestive of calcium deposition. Rod-like deposits are present within one elongated mitochondrion. Intercellular material resembling glycosaminoglycan deposits are visible.

Many of the cells in case 3 which has been diagnosed as a malignant epithelioid Schwannoma contain well formed FCIs. (Fig 31). The presence of rhabdoid cells in this type of malignancy has been documented in the previous literature (Morgan, 1985). Huge dilated mitochondria with transversely cut cristae are present.

Moderate to large amounts of free lipid are present within the tumour cells, together with many moderate sized osmiophilic lysosomal bodies rather reminiscent of the features seen in a granular cell Schwannoma.(Fig 31). A few of the smaller dense core structures with a double limiting membrane are suggestive of neuro-secretory granules. One cannot be certain, however, that these are not in fact also small lysosomes. A nuclear fibrous lamina is present in some of the tumour cells. Complex cytoplasmic interdigitations of the tumour cell processes (Fig 32) in one area and occasional primitive junctions vaguely suggestive of Schwannian differentiation are evident, but no redundant folds of external lamina can be identified. In fact no external lamina is visible on meticulous review of the grids taken for electron microscopy. In addition, no Luse bodies are evident. The semi-thin toluidine blue section indicates that only a purely epithelioid area has been sampled for electron microscopy and no spindled cell component is present on this semi-thin section.

The primitive primary brain tumour (case 4) contains numerous thin cytoplasmic processes. No neuro-secretory granules are visible. Parallel arrays of micro-tubules are visible in several of the cytoplasmic processes between the neoplastic cells. (Fig 34). Occasional synaptic processes are also visible attached to some of these processes. Many of these processes may represent part of the background brain scaffold and are probably not part of the neoplasm itself. Straight micro-tubules are also visible, however, in some of the large tumour cells between meshes of intermediate filaments. Well developed FCIs are also present. (Figs 33 & 35). Numerous free ribosomes are present, and occasional fairly long primitive cell junctions are apparent. No external lamina is evident. The tumour cells contain large, reticulate skein-like nucleoli. Isolated tumour cells contain electron dense material on top of the arrays of intermediate filaments. These electron dense foci are not branched like tonofilaments. They are also not typical of spindly densities, and they do not appear to represent Z bands as no thin filaments or single file ribosomes are evident. Their significance is uncertain.

The reactive macrophages in the tumour contain numerous lysosomes and large amounts of free lipid.

Case 5 is a suspected poorly differentiated hepatocellular carcinoma in a 62 year old lady. This contains many cisternae of rough endoplasmic reticulum within the tumour cells. This feature is suggestive of hepatocellular differentiation when taken in this clinical context. Numerous free polyribosomes are evident. (Fig 38). Well formed FCIs are noted. (Fig 36). The tumour cells contain wavy cytoplasmic borders with many villous like interdigitations. (Figs 36 & 37). In many areas these tumour cells appear to be interacting with the histiocytes which show similarly complex cell borders, with highly folded plasma membranes. Adjacent tumour cells, however, also demonstrate complex interdigitating areas along their plasma membranes. Scanty small intercellular spaces between tumour cells are filled with primitive short villous-like cytoplasmic protrusions from the adjacent

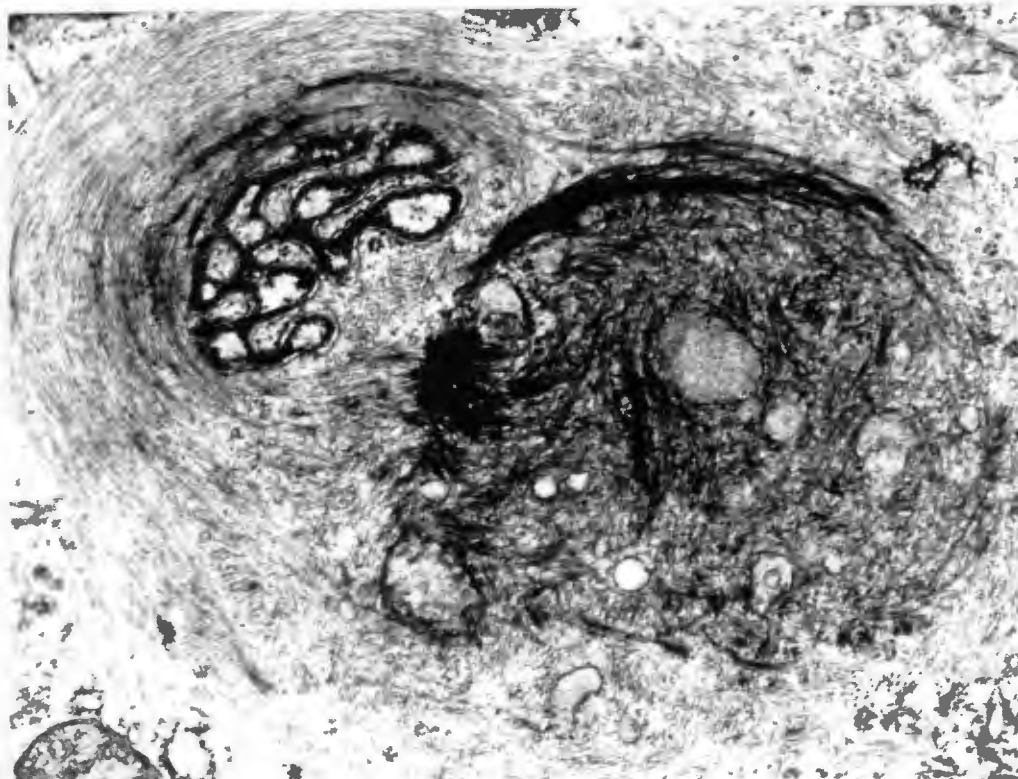


Fig.28 Case 2 ERRT. A FCI is present. This contains entrapped mitochondria and scattered tonofilaments. (x 28800)

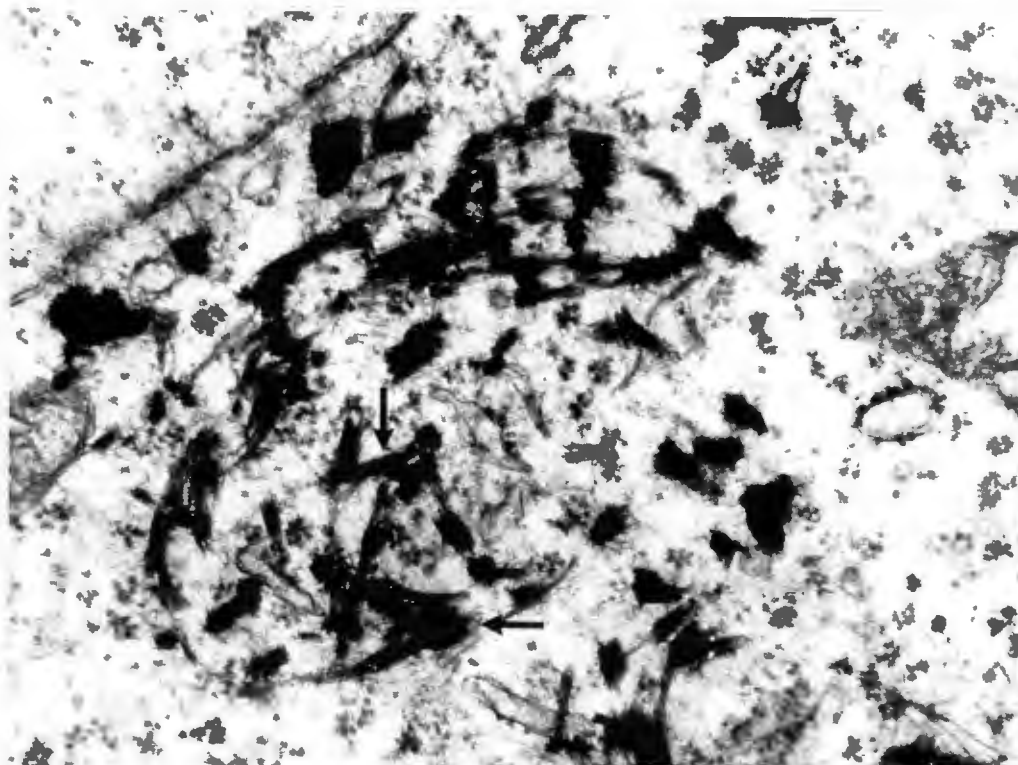


Fig.29 Case 2 ERRT. High-power view of intracytoplasmic tonofilaments (arrows). These indicate primitive epithelial differentiation. (x 54675)

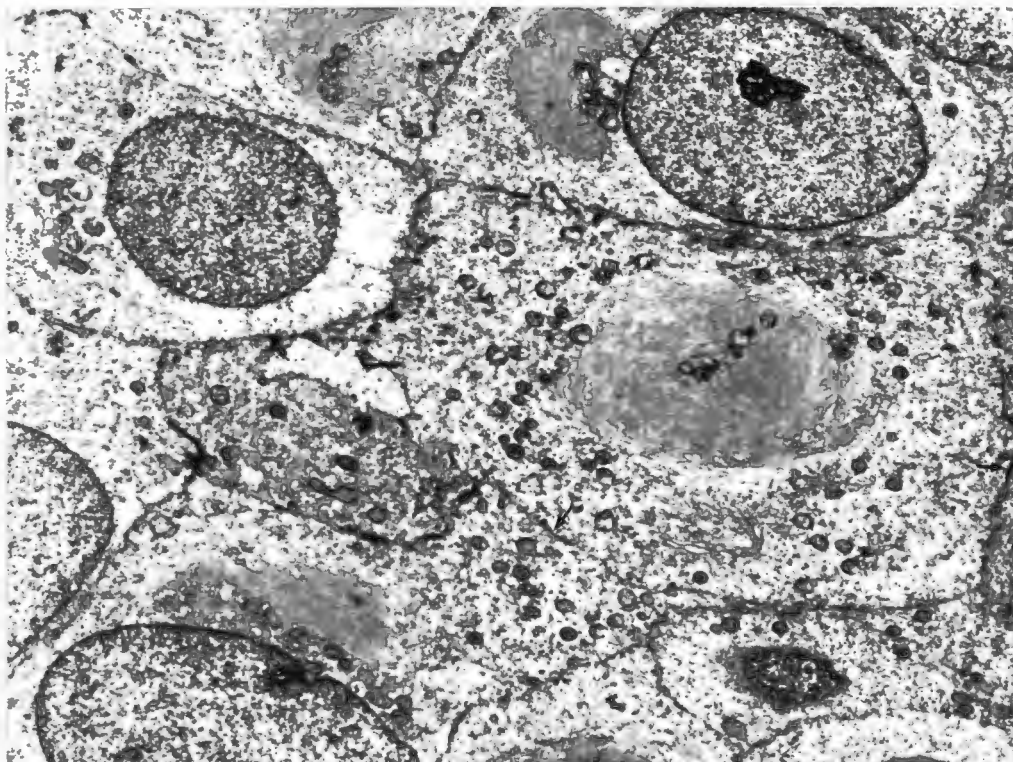


Fig.30 Case 1 ERRT. A low power electron micrograph showing typical features of malignant rhabdoid tumour, which include skein-like nucleoli, cell junctions (arrows) and large cytoplasmic whorls of intermediate filaments. (x 14 900).

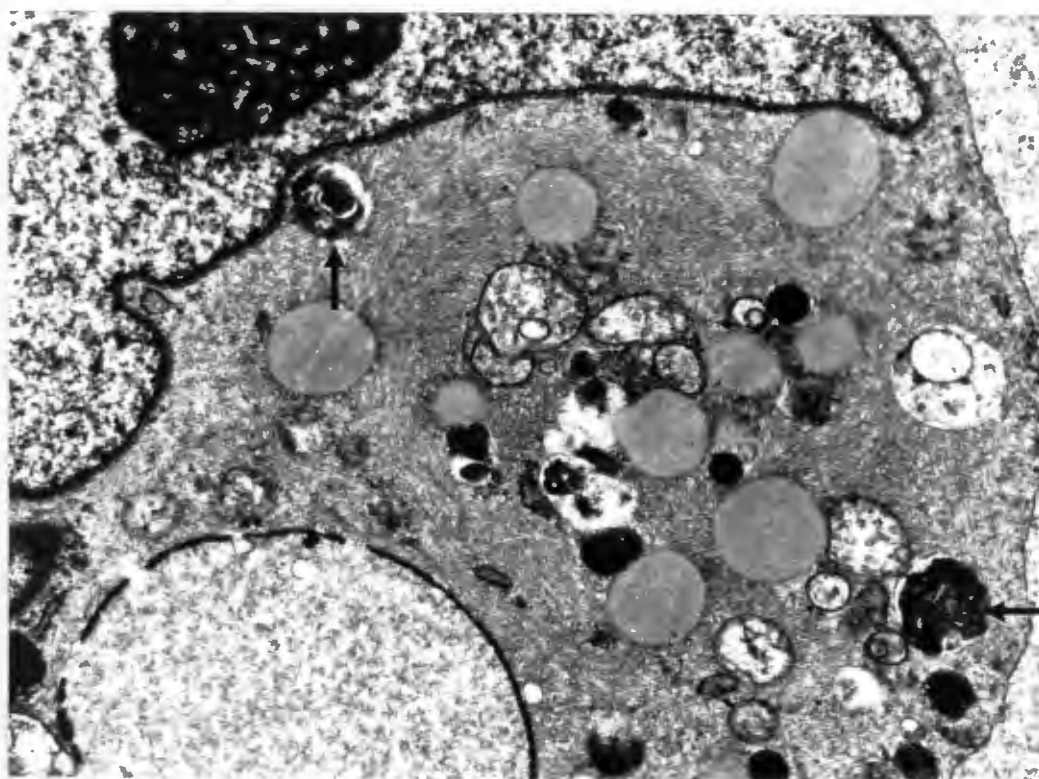


Fig.31 Case 3 ERRT. This MES contains cells with well formed FCIs and numerous lysosomes (arrows). (x 14560)

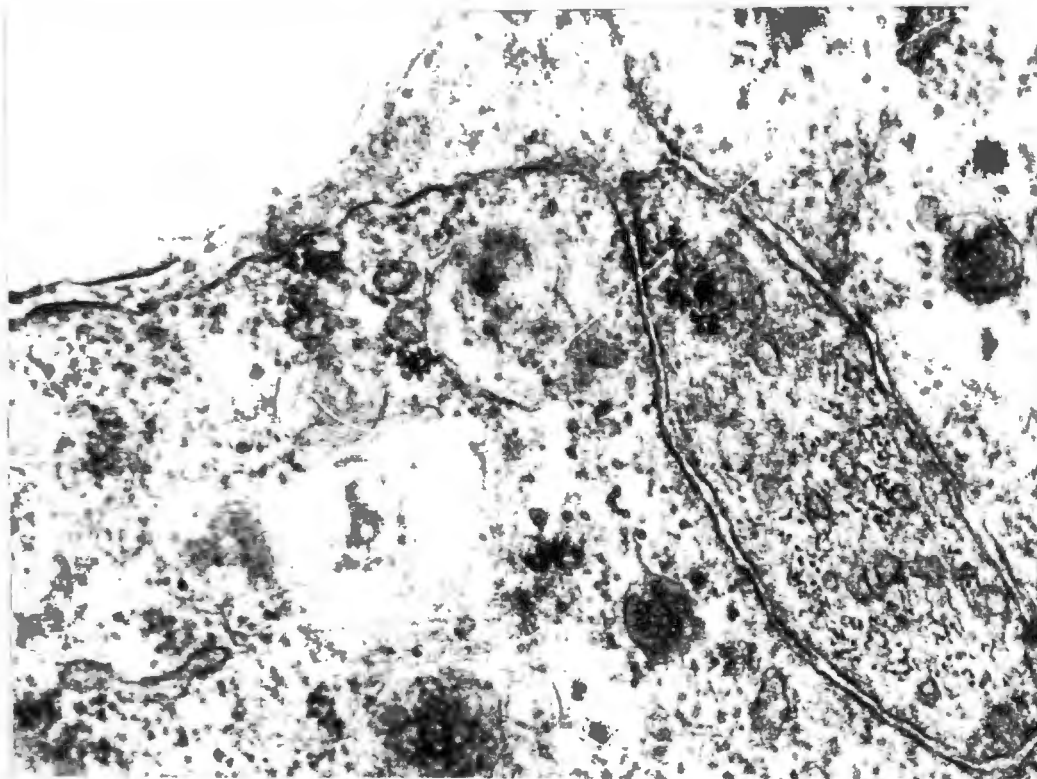


Fig.32 Case 3 ERRT. Complex cellular interdigitations vaguely suggestive of Schwannian differentiation are present in this purely epithelioid MES. No external lamina was evident. (x 54675)

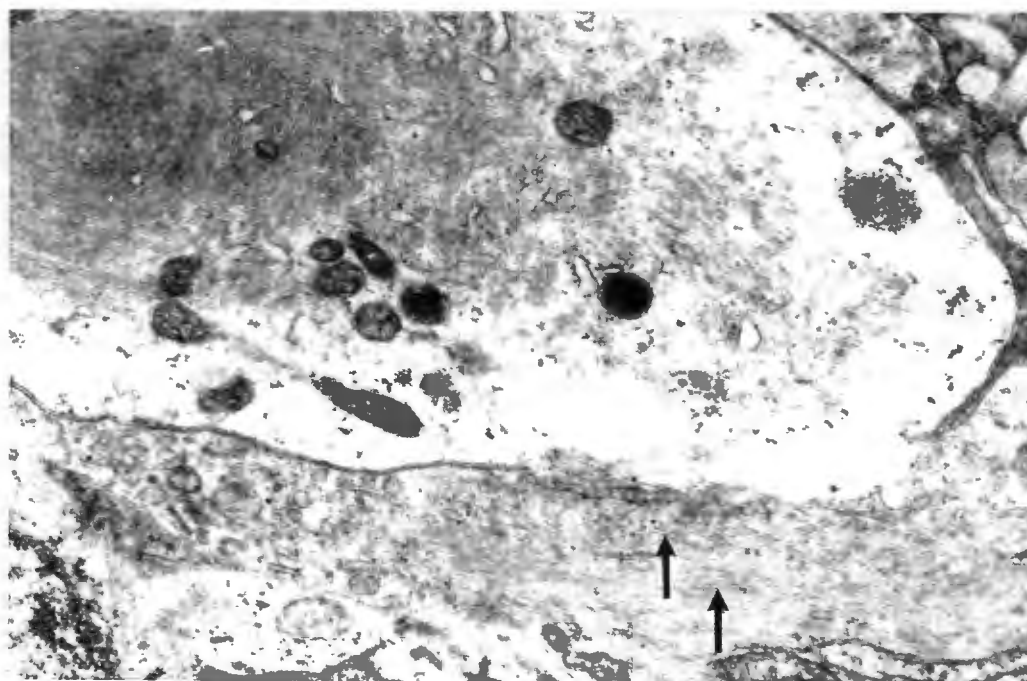


Fig.33 Case 4 ERRT. This ATT contains well-formed FCIs. Intervening cell processes of neural origin contain micro-tubules (arrows). There may also be possibly be of neoplastic origin as a fairly solid sheet of tumour was sampled for electron microscopy. (x 20800)

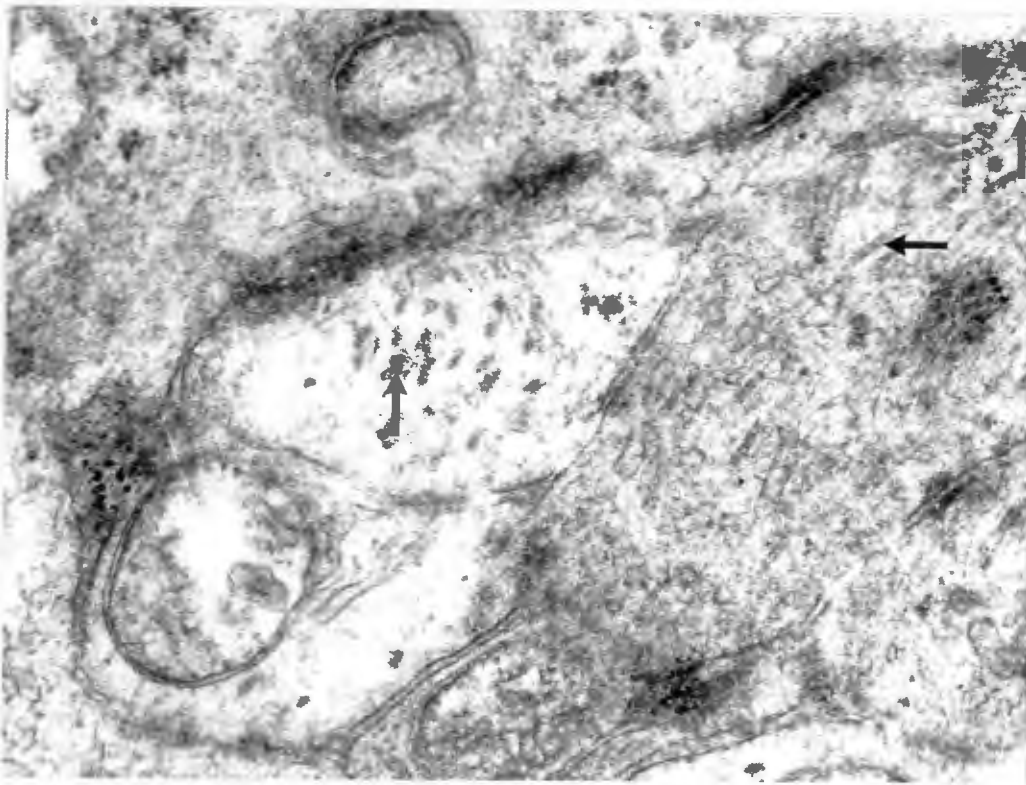

Fig.34 Case 4 ERRT. Numerous cell processes are present. These are rich in micro-tubules (arrows) (x 54675).

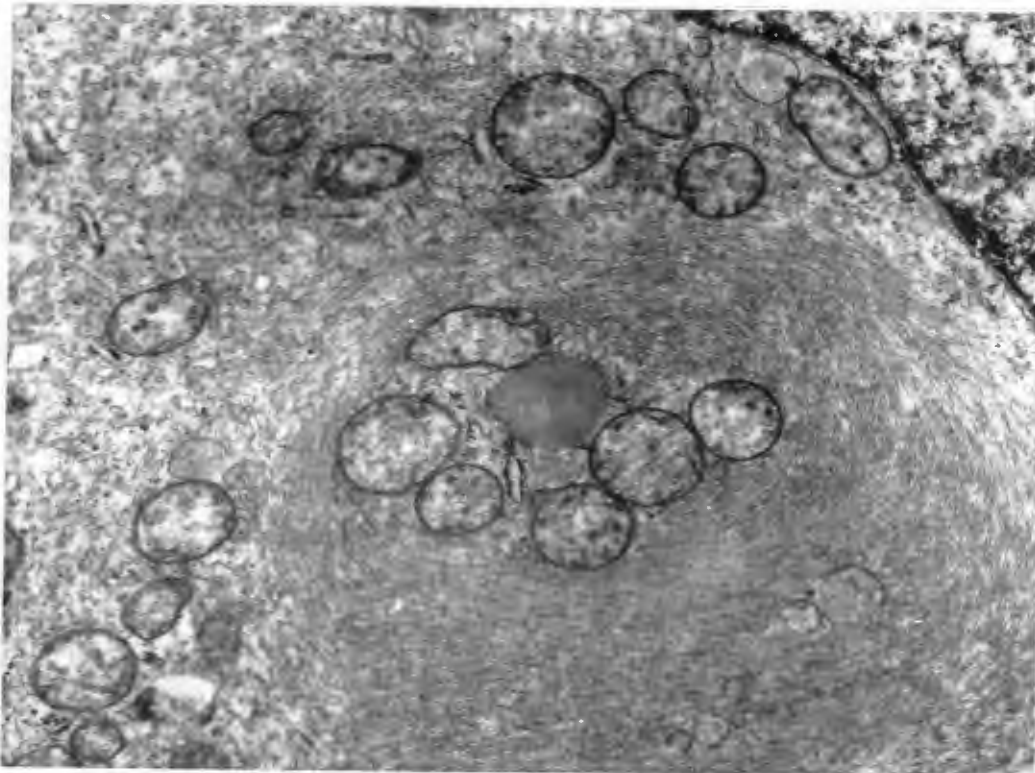


Fig.35 Case 4 ERRT. Another well-formed FCI is present in this primary brain tumour. (x 20800).

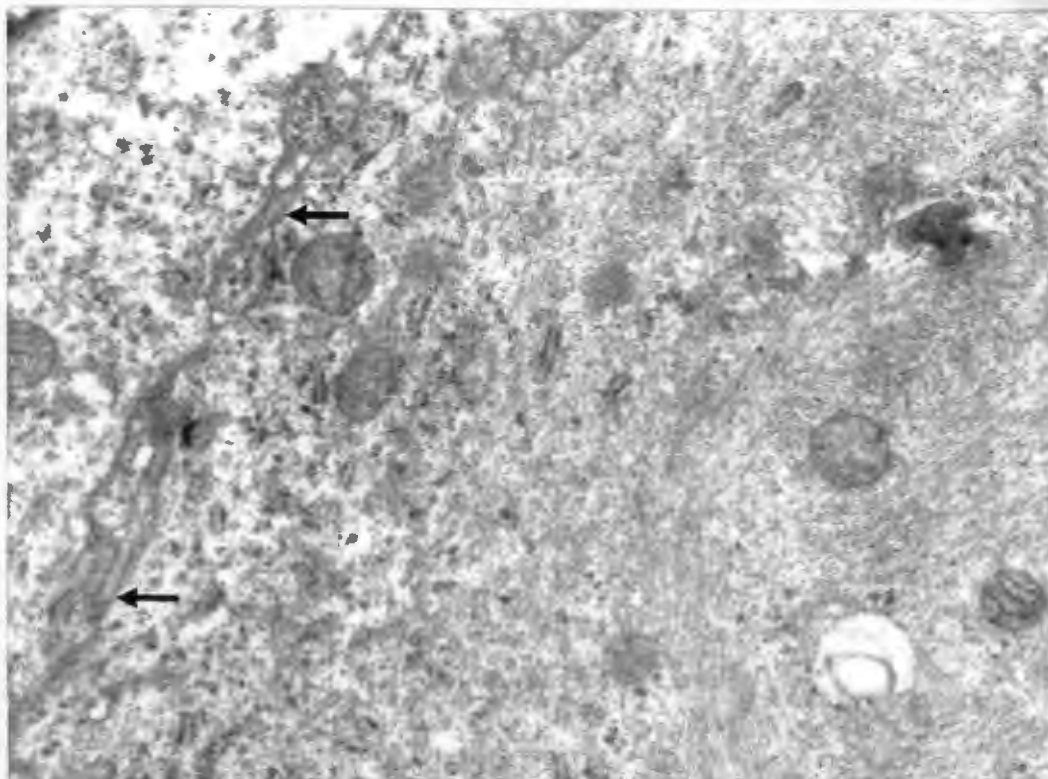


Fig.36 Case 5 ERRT. This poorly differentiated liver tumour contains well-formed FCJs and rather complex interdigitating cellular borders (arrows). (x 4000)

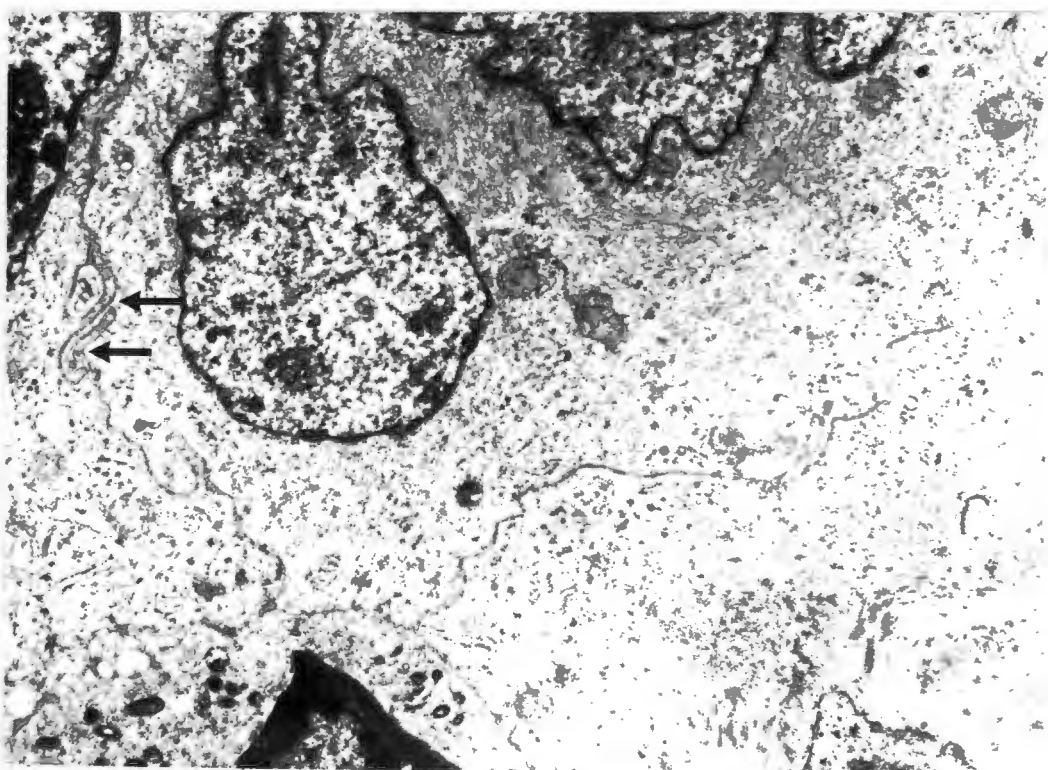


Fig.37 Case 5 ERRT. Another area of this same neoplasm highlights the complex intercellular interdigitations (arrows). (x 13410)

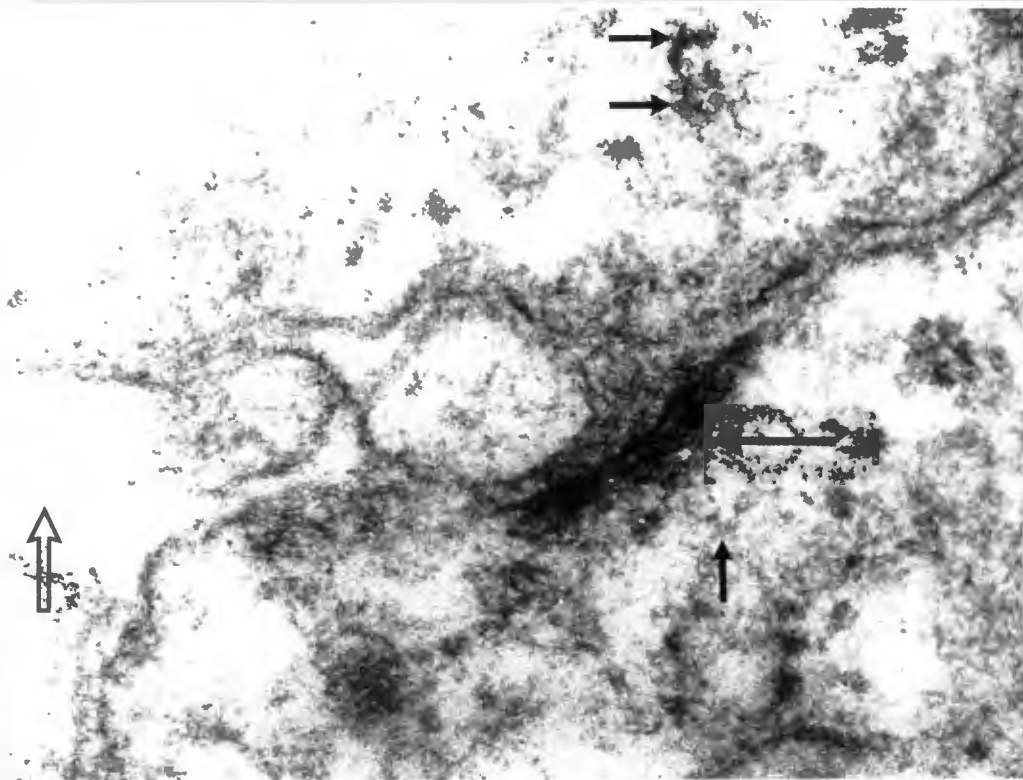


Fig.38 Case 5 ERRT. Certain spaces between the tumour cells (open arrow) and surrounding indistinct cell junctions (big arrow) are reminiscent of very primitive differentiation towards bile canaliculi. The numerous ribosomes (small arrows) are consistent with a hepatocellular carcinoma. (x 60000)

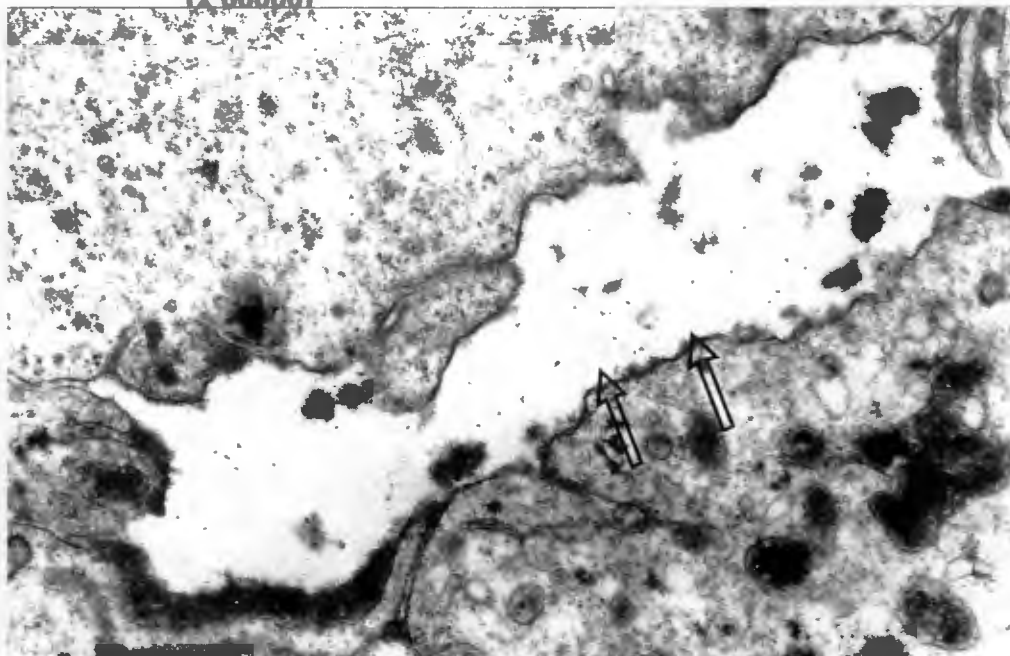


Fig.39 Case 5 ERRT. Another circumscribed intercellular space (arrow) in this poorly differentiated hepatocellular carcinoma. (Immunohistochemical detection of Hepatitis B surface antigen was evident in the surrounding liver). (x 12000)

neoplastic cells. Cell junctions are difficult to find in this tumour, but two moderately developed junctions enclose one of these spaces containing microvilli. (Fig 38). This particular structure is almost suggestive of a bile canaliculus, although it is not well enough developed to be diagnostic of this type of structure. The very scanty moderately developed desmosome-like structures present contain fuzzy material in the central spaces suggesting an early trilaminar structure. Peripheral tonofilament insertions are unfortunately not apparent in these junctions. One moderately developed hemi-desmosome like structure is also present. Small deposits of amorphous granular material are present within dilated cisternae of rough endoplasmic reticulum.

4. DISCUSSION.

4.1 Malignant rhabdoid tumour of the kidney. MRTK.

It is important to recognise the architectural diversity of MRTK, so that these lesions can be confidently separated from other histologically diverse childhood renal neoplasms. The prognosis at our institution has been so poor with MRTK that no active management is offered at present to patients who now arrive with this diagnosis. Even unfavourable histology WT and BMRTC now respond relatively well to aggressive chemotherapy. An incorrect diagnosis can therefore sometimes be lethal to the patient. FCIs have now even been described in favourable histology WT, as have macronucleoli, and these characteristics alone can not be used to identify MRTK (Weeks, 1991). The neoplasms must be adequately sampled, and the presence of other elements such as serpentine cords of WT blastema must be excluded, as must nephroblastomatous stroma or epithelial elements (Weeks, 1991).

Various growth patterns compatible with those described in the previous literature are apparent in our series of MRTKs.

4.1.1 MRTK. Cases 1 to 3.

Case 2 demonstrates the classical pattern described by Weeks (1989), with monomorphic, densely packed sheets of rhabdoid cells. Cases 1 and 3 are examples of the sclerosing pattern. In case 1, the stroma is uniformly and densely fibrotic. This reaction is also apparent in case 3, but other areas of this case conform to the chondroid and osteosarcomatous patterns noted previously (Weeks, 1989). Areas of this tumour also manifest a vascular pattern bearing a remarkable similarity to BMRTC. Cytoplasmic vacuolation in some of the tumour cells heightens this resemblance. The cytology, immunohistochemistry and ultrastructural findings in case 3 are typical of rhabdoid tumour, however, and are not compatible with BMRTC. Although this was a stage I

tumour. The patient demised three months later from a massive brain tumour filling both ventricles. This points towards an initial diagnosis of MRTK, as an association between rhabdoid tumours and CNS primaries or brain metastases has been described. (Bonnin, 1984), (Palmer, 1981). An autopsy was not obtained on this patient, so we are not certain if the brain tumour represented a second primary or a metastasis. The response of this renal neoplasm could not be evaluated as no active management was offered, but the diagnosis of MRTK in this case cannot be disputed.

4.1.2 MRTK. Case 4.

Case 4 is both architecturally and cytologically unusual, and has an epithelioid growth pattern with rarely documented features. These include prominent renal tubular invasion which has also previously been described by Weeks (1989), clear cell carcinoma-like areas (Weeks, 1989) and infrequent small PAS positive globules within some of the tumour cells. These PAS positive globules were also first described by Weeks (1989). Although this case was difficult to classify, we feel that the age of the patient, together with the renal hilar origin of the tumour, and the balance of light microscopic, immunohistochemical and ultrastructural findings support a diagnosis of MRTK. It must be pointed out, however, that the FCIs are present in only a very small minority of the tumour cells, and even these aggregates of filaments are rather loosely packed, disorganised and poorly formed. The behaviour of this neoplasm is also consistent with MRTK. The child presented with advanced disease and a short clinical history. Surgical resection was incomplete. Residual tumour failed to respond to chemotherapy, and caused the patients death within six months.

A few case reports of renal rhabdoid tumour have shown immunohistochemical evidence suggesting neural and epithelial differentiation (Fischer, 1989), (Schmidt, 1989). Non-specific uptake of immunohistochemical stains by the cytoplasmic inclusions of rhabdoid cells is a major problem and this technique is not ideal for investigating these

tumours (Berry, 1992), (Weeks, 1989). Our own observations support this contention and meaningful interpretation of a lot of the immunohistochemistry is difficult if not impossible.

Poorly preserved neuro-secretory granule-like organelles had previously been reported in one case of renal rhabdoid tumour together with foci of external lamina (Tsokos, 1989).

The neoplasm we have illustrated (Case 4) contains cytoplasmic processes with well preserved microtubules which have also been described previously on occasion in MRTK (Seo, 1988). This unfortunately by itself does not confirm neural differentiation, as fibroblasts and actively growing mesenchymal cells of the type seen in CMN may contain microtubules which presumably form part of the cytoplasmic internal transport mechanism (Favara, 1968). The possibility of neuro-epithelial differentiation in this case still exists, however, as approximately 50% of the tumour cells are positive for GFAP. The FCIs are also positive for NSE, which is unfortunately very non-specific. Scanty cells in case 4 also demonstrate nuclear staining for S100 antigen. Immunohistochemical examination did not detect neurofilament proteins, but the antibodies used here have only recently been developed, and their affinity for the neurofilament protein in formalin fixed tissue may not be that high (Osborn, 1986) (Carlei, 1984). Neurofilament proteins may also only be expressed in very small amounts. The evidence for neural differentiation in this case is not conclusive, however, and it must be borne in mind that antibodies to both S100 and GFAP bind to myo-epithelial cells in sites such as the salivary glands.

It must also be pointed out that ganglion cells have also previously been clearly demonstrated within WT (Llombart-Bosch, 1980). No one seriously believes that WT is of primary neuro-epithelial origin today. Llombart-Bosch (1980) speculates that the isolated ganglion cells possibly grow into the WT from the surrounding mesenchyme in response to trophic influences exerted by the neoplasm. This may not, however, apply to MRTK as the GFAP and S100 expression appear to be in the neoplastic cells. Overall

immunohistochemical and ultrastructural assessment does, however, provide fairly strong circumstantial evidence for a primitive neuro-epithelial component in case 4.

Bundles of tonofilaments in cytoplasm that appears to be contiguous with a tumour cell nucleus is highly suggestive of epithelial differentiation in case 4. This particular mass of cytoplasm is also surrounded by an external lamina.

Thick and thin filaments and associated single file ribosomes in the same case suggest skeletal muscle differentiation. Striated muscle differentiation, as far as we are aware, has not been noted previously in MRTKs. The diversity of ultrastructural features present in this particular case is very unusual. The loosely formed whorls of intermediate filaments may possibly represent a stage in the development of the more characteristic, tightly formed FCIs. It seems that this particular case with its unusual morphology sheds new information about the manner in which MRTK and other as yet undefined closely related tumours may manifest.

We are of the opinion that none of these scanty, immature organelles are sufficiently developed to place this neoplasm in an alternative diagnostic category. Pseudo-rhabdoid tumours have been described (Weeks, 1991) which generally have a better prognosis. These include tumours which are clearly epithelial in origin such as transitional cell, renal cell and collecting duct carcinomas (Weeks, 1991). Such tumours generally occur in much older individuals, and are not usually as aggressive as MRTK. Neuro-epithelial tumours of the kidney can also contain cells which are identical to MRTK (Weeks, 1991), but these neoplasms usually contain other areas with definite neuroblastic or ganglionic differentiation (Weeks, 1991). Small areas of these tumours can contain cells with some compartmentalisation, a "salt and pepper" nuclear chromatin pattern and rare rosettes (Weeks, 1991). There is usually far more ultrastructural evidence of neural differentiation in such tumours. Neuroblastoma of the adrenal may also involve the kidney, and also will show similar features of obvious neural differentiation.

Although this tumour (case 4) demonstrates many of the poorly differentiated features and biological aggressiveness of MRTK, it does lie in a diagnostic “grey zone” between various very poorly differentiated renal hilar tumours. Forcing it into a particular diagnostic category may be less important at this stage than carefully documenting its morphology and biological behaviour for future review. Other similar cases need to be collected and evaluated to better understand the relationship between these entities.

4.2 Extra-renal rhabdoid tumours. ERRT

4.2.1 Paravertebral tumours and malignant epithelioid Schwannomas.

Case 1 was a paravertebral tumour that manifests typical rhabdoid cytology with a spindle cell pattern in some areas. Whilst many of these spindle cells appear to be a degenerative phenomenon in this case, spindle cell growth has previously been reported in other undifferentiated paraspinal tumours with a rhabdoid phenotype (Lynch, 1983) (Biggs, 1987). This patient died from presumed brain metastases twenty-nine months after diagnosis. An autopsy was not performed. The clinical course was more protracted than that generally noted for MRTK.

Case 2 was also a poorly differentiated paraspinal tumour. Sheets of rhabdoid tumour cells are evident in the small amount of material from this case, with no special architectural patterns and no particular stromal response. This patient was offered no active management in view of the dismal prognosis of the previous MRTK, and because of the prior experience of Case 1. (He has been lost to follow-up).

Case 4 has been diagnosed as a malignant epithelioid Schwannoma on the basis of origin from large nerves, and the strong positive staining of the neoplastic cells for S100 protein in the absence of expression of cytokeratins. The anatomical location of this tumour next to the vertebral column resembles that seen in cases 1 and 2. The mode of spread through

the intervertebral foramina and subsequent course with numerous recurrences is reminiscent of the biological behaviour of the tumour in case 1.

Entrapped nerves are also present in the tumour tissue from case 1. In addition, case 1 demonstrates equivocal staining for S100 protein. Case 2 is S100 negative, but only a very small sample of the tumour had been submitted for histological examination. The suspicion that these first two cases may also represent very poorly differentiated malignant peripheral nerve sheath tumours does arise, particularly as not all previously described cases of MES have expressed S100 antigen on immunohistochemical examination (Daimaru, 1985). Only 5 out of 11 malignant epithelioid Schwannomas in this series were S100 positive. Positive immunohistochemical results for EMA and CAM 5,2 in cases 1 and 2 mitigate against a diagnosis of MES. Although epithelial acini do occasionally occur in MES (De Schryver, 1984) (Krummerman, 1978) (Foraker, 1948) (Guccion, 1979) (Michael, 1967) (Papanicolaou, 1982) (Takahara, 1979); the surrounding non-acinar elements do not express cytokeratins.

It is nevertheless difficult to exclude a nerve sheath or neuro-ectodermal origin in the tumours occurring in cases 1 and 2. Distinctions of this nature are difficult to make on the basis of a few sometimes tenuous immunohistochemical results.

The epithelial differentiation that has been described in focal acinar structures within peripheral nerve sheath tumours include ependymal (De Schryver, 1984) (Lanford, 1927) intestinal (Uri, 1984) and even respiratory components (Papanicolaou, 1982). In some cases focal cytological similarities between gland lining cells and surrounding Schwann cells have been noted on ultrastructural examination (Krummerman, 1978) (Woodruff, 1976) (Ferry, 1988), suggesting a metaplasia from Schwann cells to epithelial elements. The origin of the Schwann cell is not entirely clear. One traditional view is that melanocytes and also Schwann cells arise from the neural crest, and are therefore potentially of epithelial origin. It is not entirely clear which components of the nerve sheath are of epithelial origin,

and which parts originate in the mesenchyme. Schwann cells may actually have a mesenchymal origin. It is possible that the neural crest induces epithelial differentiation in the surrounding mesenchyme (Uri, 1984). This would be analogous to the induction of epithelial differentiation in the metanephric mesenchyme of the kidney by the ureteric cap. It is interesting that case 2 demonstrates tonofilament-like bundles within the cytoplasm of its tumour cells. This indicates epithelial differentiation. It is unfortunate that only a very small portion of this neoplasm was sampled and we have not been able to either confirm or exclude the presence of an underlying malignant peripheral nerve sheath tumour.

4.2.2 Primitive neuro-ectodermal tumours. (Atypical teratoid tumours).

Case 4 was initially diagnosed as a PNET with rhabdoid differentiation, and is obviously of neuro-epithelial origin. The possibility therefore exists that the first four cases in the series are related in entities, although cases 1 - 3 were situated in and around parts of the peripheral nervous system. The evidence for neuro-epithelial differentiation is far stronger in case 4, however, with strong cytoplasmic staining of the tumour cells for GFAP and S100 protein. Obvious immunohistochemical expression of neurofilament proteins is also present. This is a fascinating case that warrants further discussion. Some authors are of the opinion that all primitive brain parenchymal tumours showing divergent differentiation are variants of the same theme, and should all be lumped together as PNETs (Yates, 1979) (Becker, 1983). Such tumours include medulloblastoma, medullo-epithelioma, neuroblastoma, polar spongioblastoma, pineoblastoma, ependymblastoma, retinoblastoma and olfactory neuroblastoma. The histogenesis of such tumours is considered to be a primitive multipotential neuro-ectodermal cell (Markesbery, 1979). The fact that many of these tumours show a spectrum of differentiation supports this contention. The well documented association of neurofibromatosis with a wide variety of these tumours is also compatible with this concept. Waldbauer (1976) described a medulloblastoma in one of a pair of monozygous twins. The genetically identical sibling had a pineoblastoma. The common

association of pineoblastomas with bilateral retinoblastomas (Jacobiec, 1977) may or may not indicate a common stem cell.

On the other hand the presence of cerebellar haemangioblastomas and cerebral neuroblastoma (Pearl, 1981) in von Hippel Lindau disease possibly indicates two separate tumour types within one phacomatosis. Tumours of mesenchymal origin in neurofibromatosis would fit into the same category.

This case of ours contains primitive glial tissue, primitive neuronal elements and rhabdoid areas showing epithelial differentiation in the form of tonofilaments. Almost identical tumours have recently been classified under the new entity of "atypical teratoid tumour" (ATT) by Lefkowitz (1987), who described four such cases all in patients under two years of age. These tumours have poorly differentiated features of epithelial, neuro-epithelial and possibly mesenchymal differentiation at the cellular and subcellular level, without showing distinct tissue differentiation along these different germ lines as in teratomas. The term "atypical teratoid tumour" (ATT) in my opinion is possibly somewhat inappropriate for a lesion that appears to be primarily a primary brain tumour. A critical review of all malignant brain tumours in this age group at Lefkowitz's Institution reveals that 43% of these neoplasms fell into the category of ATT. The patients presented at a mean age of 9 months (range 4 - 16 months) with posterior fossa tumours. Early leptomeningeal spread occurred in all patients, and all four children deteriorated rapidly. The tumours did not appear to respond to chemotherapy or radiotherapy (three of the four patients received chemotherapy and two had cranio-spinal radiotherapy. The patient who's parents refused chemotherapy was treated later with radiotherapy). The mean survival from diagnosis was 5.5 months (range 2 - 10 months). These tumours appear to be more aggressive than typical PNETs, and it has therefore been proposed that they be classified as a separate entity. Our patient is still alive six months after diagnosis with residual disease that appears to have responded fairly well to initial radiotherapy. (Follow-up data August, 1994).

It is also interesting to know that this patient of ours had a cerebral rather than a cerebellar tumour.

A few other cases of ATT have recently been published (Biegel, 1990) (Griffin, 1988). Although Lefkowitz (1987) did not culture any of his tumours for cytogenetic analysis, recent work by Biegel (1990) has demonstrated a monosomy of chromosome 22 in the one case of ATT of the brain that they diagnosed (Biegel, 1990). The other two tumours on which cultures were obtained in this series were monomorphic rhabdoid brain tumours. Interestingly both of these lesions also demonstrated monosomy of chromosome 22, although in one of the tumours a few of the metaphases examined had a normal karyotype (Biegel, 1990). Griffin (1988) has published two examples of ATT with no detectable abnormalities in chromosome 22. Another primary rhabdoid tumour of the brain and one soft tissue rhabdoid tumour have also been shown to have abnormalities of chromosome 22 (Karnes, 1989) (Douglass, 1990). One of the three cases examined by Biegel (1990) presented initially with a MRTK and was later found to have a rhabdoid tumour of the brain (Biegel, 1990). It is unfortunate that cytogenetic analysis was only performed on the brain tumour. It is also not clear whether this brain tumour was a metastases or a second primary.

The more usual PNETs with astrocytic differentiation have been shown to contain an i(17q) chromosomal aberration in a number of cases (Biegel, 1989.2), which has not been documented in brain tumours with rhabdoid features (Biegel, 1990). The behaviour of brain tumours containing many rhabdoid cells and the above cytogenetic data indicates that they are possibly a distinct entity, different from the more usual type of PNET.

Monosomy 22 has also been documented in approximately 20% of both paediatric and adult meningiomas (Mitelman, 1988), and as a non-random change in cytogenetic studies of a limited number of acoustic neuromas. Interestingly the gene for the central form of neurofibromatosis (NF-2) has been linked to the long arm of chromosome 22 by linkage analysis in families (Rouleau, 1987). Acoustic neuromas, meningiomas and spinal

neurofibromas show tumour specific loss of alleles on chromosome 22 (Dumanski, 1987) (Seizinger, 1986), and possibly involve one or more loci on chromosome 22 (Seizinger, 1986). The locus on this chromosome has not yet been established for the genes associated with malignant rhabdoid tumours/ATTs of the brain (Biegel, 1990).

4.2.3 Rhabdoid tumours of the liver.

Case 5 is an undifferentiated neoplasm situated in the hilum of the liver. Six hepatic tumours with a rhabdoid phenotype have previously been documented in infants (Foschini, 1992) (Hunt, 1990) (Parham, 1988) (Chang, 1989) (Gonzalez-Crussi, 1982). It is interesting that case 5 occurred in a 62 year old lady. This neoplasm from the Groote Schuur Hospital Archives showed strong cytoplasmic expression of low molecular weight cytokeratins (CAM 5,2) and vimentin on immunohistochemical examination. The lesion described by Foschini (1992) was also strongly positive for vimentin, Cam 5,2 and EMA. Immunohistochemistry performed on frozen sections of the lesion described by Foschini (1992) revealed interesting results. Most of the tumour cells were positive for cytokeratins 8, 18 and 19 (CAM 5,2). This pattern is similar to that noted for very primitive liver cells during human organogenesis (Stosiek, 1990). Only 20% of these cells in this particular rhabdoid tumour of the liver were positive for cytokeratin 7 (CK7). CK7 becomes a predominant cytokeratin during bile duct differentiation (van Eyken, 1988). Focal areas of this particular lesion contain smaller cells with a more epithelial pseudo-glandular architecture. Large amounts of rough endoplasmic reticulum were visible on electron microscopy in this case, as is also evident in our ultrastructural findings on the liver tumour described in case 5. The hepatic tumour described by Foschini (1992) contained tonofilament-like bundles in the cytoplasm of the tumour cells (Foschini, 1992). Many fairly long primitive cell junctions were also present in this case, although no well developed desmosomes were described (Foschini, 1991). The evidence for epithelial differentiation in case 5 is mainly immunohistochemical, with very strong positive staining for CAM 5,2. Cell junctions are difficult to find but one or two moderately developed structures are present

with a suggestion of a trilaminar architecture, but with no peripheral insertion of tonofilaments.

It is interesting to compare this extra-renal rhabdoid lesion or poorly differentiated hepatocellular carcinoma of the adult liver with a hepatoblastoma containing rhabdoid cells. This hepatoblastoma (RxH SD 383/94) was resected from an 18 month old boy. Histological examination reveals malignant immature liver tissue containing both epithelial and mesenchymal components. The epithelial tissue contains foetal, embryonal, macro-trabecular and small cell undifferentiated components. There is also evidence of rhabdoid and neuro-ectodermal differentiation. Extra-cellular mucoid material and osteoid are also present. The neuro-epithelial differentiation is confirmed by distinct granular positive expression of both chromogranin and synaptophysin within some of the sheets of small cells on immunohistochemical evaluation. (Neuro-epithelial differentiation is well documented in hepatoblastomas.) (Ruck, 1990).

Ultrastructural examination of this particular hepatoblastoma (SD 383/94) reveals primitive hepatoblasts with abundant rough endoplasmic reticulum and well developed bile canaliculi between the tumour cells (Fig 40). Small epithelial ducts are also evident and these are surrounded by basement membrane (Fig 41). In other areas there are rhabdoid cells with FCIs. (Fig 42). The nucleoli within these particular cells were not as prominent as those noted in most cases of otherwise undifferentiated rhabdoid tumour.

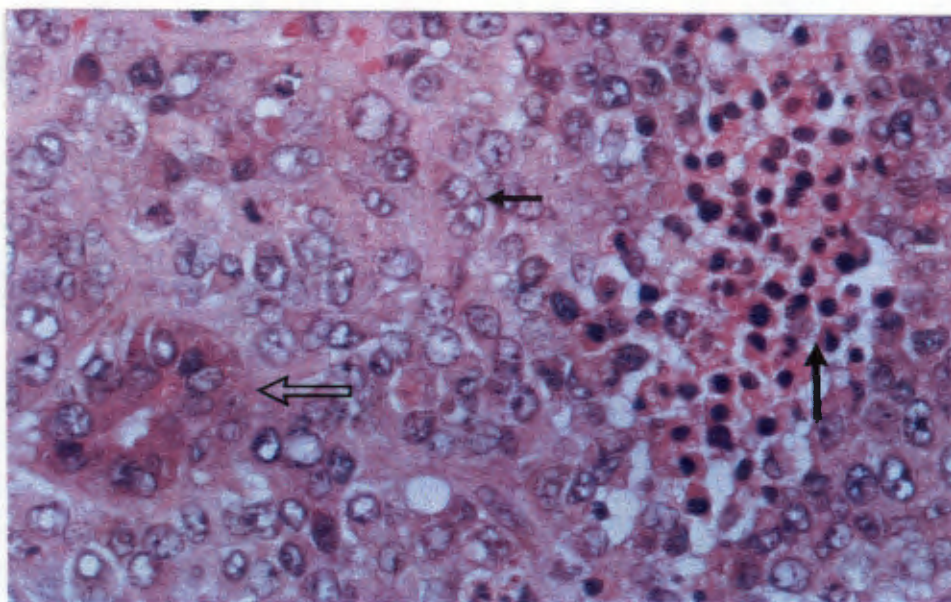


Fig.40 This hepatoblastoma (SD383/94 RxH) contains primitive bile ducts (open arrow), sheets of rhabdoid cells (small arrow) and areas of extra-medullary haematopoiesis (large arrow)(H+E x 497)

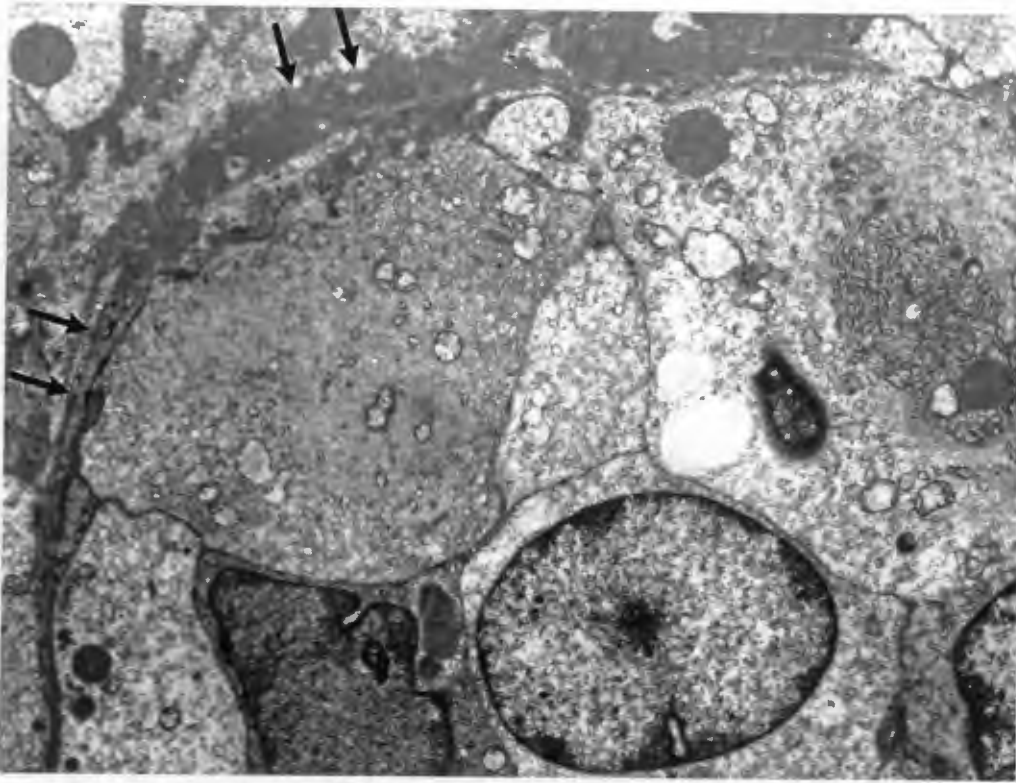


Fig.41 SD383/94 RxH. Ultrastructure of a hepatoblastoma demonstrating a primitive epithelial tubule/bile ductule surrounded by basement membrane (arrows). (x 6338)

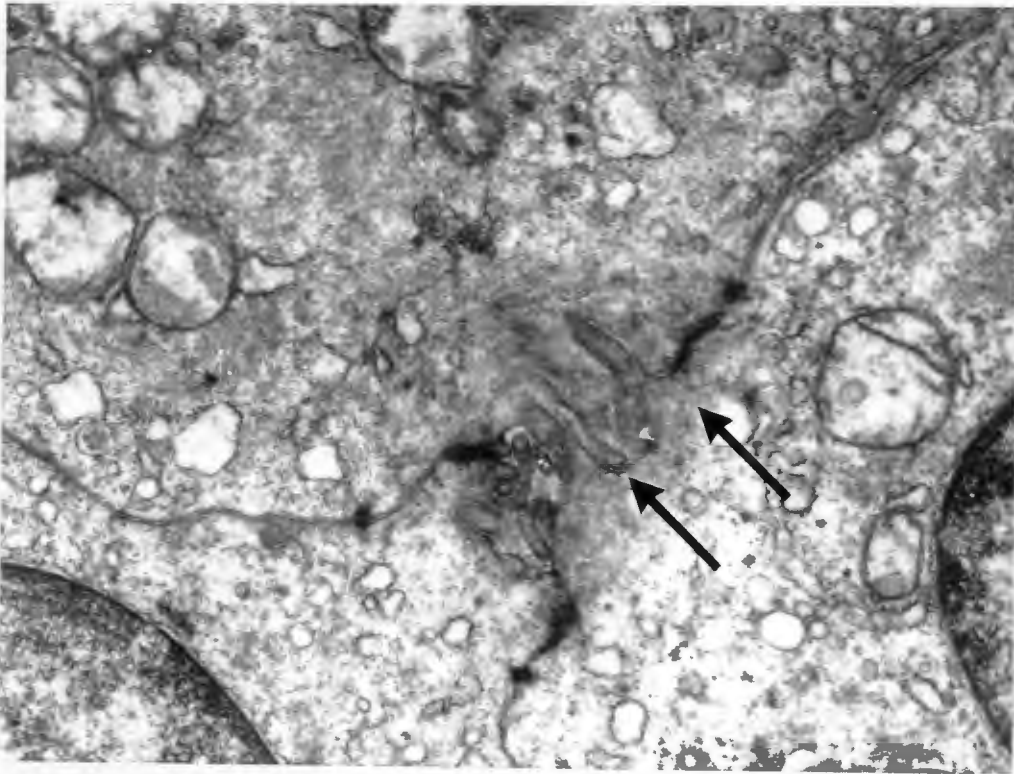


Fig.42 SD383/4 RxH. This hepatoblastoma also contains well developed FCIs (open arrow) and distinct bile canaliculi (small arrows) (x 20160)

Hepatoblastomas have recently been classified into separate histological types (Finegold, 1992):-

Classification of hepatoblastoma:

Major categories:-

EPITHELIAL

Foetal, well differentiated.

Crowded foetal with mitoses.

Embryonal.

Macrotrabecular.

Small cell undifferentiated.

MIXED:

Undifferentiated mesenchymal - blastema.

Minor components:-

Osteoid.

Keratinising squamous epithelium.

Intestinal glandular epithelium.

Neural-melanocytic (teratoid).

Rhabdomyoblastic.

Chondroid.

Exceptions:-

Rhabdoid

Ductal (Cholangioblastic)

The poorly differentiated hepatocellular carcinoma with rhabdoid features (Case 5) and this mixed hepatoblastoma from Red Cross Hospital both support the contention that primitive epithelial differentiation is present in the rhabdoid cells of liver tumours. This is supported by ultrastructural evidence in the hepatoblastoma (Figures 41 & 42).

An undifferentiated small cell hepatoblastoma described by Hansen (1992) also contained scattered rhabdoid cells on ultrastructural examination with well developed whorled FCIs. There was no evidence of neuro-endocrine differentiation in this neoplasm. A chromosomal translocation between the long arm of chromosome 22 (at q11) and the short arm of chromosome 10 (at q26) was noted in this case (Hansen, 1992). It is interesting to point out that ATTs of the brain with rhabdoid cells also show abnormalities in chromosome 22 (Biegel, 1990) (Karnes, 1989). A soft tissue rhabdoid tumour with abnormalities in chromosome 22 has also been described. (Douglas, 1990).

Could a damaged gene or mutation on this chromosome possibly lead to a disruption of the cytoskeleton of the cells so that intermediate filaments aggregate within the cytoplasm of the malignant cells? Does this aggregation of intermediate filaments and loss of cytoskeletal architecture have any bearing on the malignant potential of these cells?

One hepatocellular malignancy with a relatively good prognosis is fibro-lamellar carcinoma of the liver. Fibro-lamellar carcinomas of the liver can have identical light microscopic features to malignant rhabdoid tumours, with eccentric eosinophilic cytoplasmic inclusions, prominent nucleoli and a dense collagenous stroma surrounding nests of neoplastic cells. Ultrastructural examination of these cytoplasmic bodies has revealed very dilated cisternae of rough endoplasmic reticulum filled with proteinaceous material. This material and the presence of aggregates of abnormal mitochondria in the cytoplasm possibly account for the eosinophilic globules/inclusions in the cytoplasm (de Davila, 1987). These globules/inclusions mimic the FCIs of rhabdoid tumours on light microscopic examination. Numerous small micro-villi are also present in the folded borders of fibro-lamellar carcinoma on ultrastructural examination (de Davila, 1987).

4.2.4 Malignant rhabdoid tumours of the perineum and pelvis.

Only a small wedge biopsy was submitted from the large vulval, vaginal and pelvic tumour discovered in case 6. Only undifferentiated rhabdoid cells are apparent. Fine ultrastructural detail cannot, however, be appreciated as the material had to be dewaxed.

Immunohistochemistry shows very strong positive staining for low molecular weight cytokeratins (CAM 5,2) and vimentin, which suggests an epithelial/epithelioid origin for this tumour. FCIs with co-expression of vimentin and cytokeratin have been described in poorly differentiated endometrioid carcinoma (McNutt, 1985), and it is possible that case 6 is a very poorly differentiated carcinoma of the female genital tract. More extensive sampling of the tumour was not possible, however, as permission for autopsy was refused on religious grounds.

Immunohistochemistry also reveals strong nuclear cytoplasmic expression of S100 in this case. A faintly nested architectural pattern is also visible in some areas. Sheets of malignant rhabdoid cells had previously been described in a lymph node adjacent to an invasive malignant melanoma (Bittesini, 1992). Rare primary malignant melanomas of the cervix have been described and the possibility of this diagnosis also has to be considered in case 6. A negative Masson Fontana stain on our biopsy material mitigates against this diagnosis, but does not entirely exclude the possibility of melanoma.

Epithelioid sarcomas have also been shown to contain rhabdoid cells with macronucleoli and FCIs. (Molenaar, 1989) (Tsuneyoshi, 1987). Two of the neoplasms described by Molenaar (1989) presented in the inguinal region. Epithelioid sarcomas of the vulva appear to be extremely rare and are difficult to distinguish from malignant rhabdoid tumours occurring in the same anatomical location (Perrone, 1989). Both epithelioid sarcoma and malignant rhabdoid tumour co-express vimentin, cytokeratins and EMA in their FCIs, and both entities contain whorls of intermediate filaments in some of the tumour cells on

ultrastructural examination. On histology low power light microscopic examination often is helpful in distinguishing these two entities.

Epithelioid sarcomas are usually multinodular with an architecture reminiscent of granulomatous inflammation. Scattered tumour cells often surround central necrobiotic cores of tissue (Enzinger, 1983). The cytoplasmic inclusions are often not quite as eosinophilic as those noted in rhabdoid tumours and the nucleoli are generally not that prominent (Perrone, 1989). A deep form of epithelioid sarcoma has been described by Enzinger (1983), however, in which more solid sheets of tumour cells make distinction from malignant rhabdoid tumour difficult.

Four vulval tumours have been described in which this differential diagnosis is discussed (Perrone, 1989). One of these cases appeared to be an epithelioid sarcoma. The other three cases architecturally and cytologically appear to be totally undifferentiated extra-renal rhabdoid neoplasms. Two of these cases were originally reported in separate publications by Ulbright (1983) and Hall (1980). It is interesting to note that these cases had a vaguely nested architecture in some areas similar to that evident in case 6 of our series. The series described by Perrone (1989) were all negative for S100 protein. No melanosomes, dense core neuro-secretory granules, tonofilaments, desmosomes, microvilli, external laminae or acini were visible on ultrastructural examination of these lesions. Focal S100 staining was visible within the FCIs of two of the epithelioid sarcomas described by Molenaar (1989). One of these lesions was situated in an extremity, and the other was from the inguinal area. Epithelioid sarcomas previously described in the vulva of young women behaved in a more aggressive manner than those at other sites (Meis, 1988). It appears that the diagnosis of epithelioid sarcoma of the vulva has previously been made in certain cases that should have been reported as ERRTs (Perrone, 1989), or preferably as undifferentiated neoplasms with a rhabdoid phenotype. This could account for the unexpectedly aggressive behaviour of these neoplasms (Ulbright, 1983).

It has been established that malignant rhabdoid tumour, or a morphologically identical entity does occur in the lower genital tract and perineum of young adult females. Case 6 is most probably one of these lesions, and has demonstrated a similarly aggressive biological behaviour with the demise of the patient from widespread metastases 24 months after diagnosis.

The need for adequate sampling of these neoplasms (if possible) cannot be over-emphasised. This is highlighted by a recent publication describing an ERRT of the vulva (Kudo, 1991). Fairly strong circumstantial evidence for a diagnosis of an undifferentiated carcinoma is present in this particular case (Kudo, 1991). Accurate tumour typing is only possible if these undifferentiated lesions are extensively sampled. This will improve our understanding of malignancy in this particular anatomical location and help us to distinguish between poorly differentiated carcinomas of the female genital tract, epithelioid sarcomas and other lesions with a rhabdoid phenotype in this anatomical location.

4.3 General considerations.

4.3.1 Malignant rhabdoid tumour of kidney. MRTK

MRTK is an aggressive neoplasm that almost always arises in the hilum of the kidney in infants (Weeks, 1989). A single case of malignant rhabdoid tumour has, however, been described in an adult kidney (Lowe, 1990). Poorly differentiated transitional cell carcinomas and other poorly differentiated carcinomas can show a rhabdoid phenotype, however, as has been amply demonstrated in the preceding discussion. It is not clear, at this stage, if this renal rhabdoid tumour in an adult represents part of the same entity as MRTKs of childhood.

The MRTKs encountered in young infants do appear to be a distinct pathological entity in view of the relatively uniform age of presentation, the renal hilar origin of these neoplasms and the highly aggressive behaviour of these particular malignant neoplasms.

Cases 1, 2 and 3 in our renal series support this contention. Case 4, however, is different and may be a closely related but distinct entity.

Co-expression of vimentin and cytokeratins has been noted in many other lesions apart from rhabdoid tumour. These include poorly differentiated ovarian, thyroid, endometrioid and renal cell carcinomas (McNutt, 1985), metaplastic carcinomas of the breast (Santeusano, 1988) and adrenal cortical carcinomas (Wick, 1986).

It is difficult to draw inferences from this pattern of staining, but poorly differentiated epithelial cells may contain this combination of antigens. Neuro-endocrine tumours such as gastro-intestinal carcinoids (Sidhu, 1979) (Wilander, 1980) can also contain FCIs. Co-expression of neurofilaments and cytokeratins is evident in some examples of carcinoid tumour and in Merkel cell carcinomas (McNutt, 1985).

It is difficult to exclude a neuro-epithelial origin for MRTK, as carcinoid and primitive neuro-epithelial tumour have been described in the kidney (Weeks, 1991). Some of these tumours contain rhabdoid cells. Many carcinoids and poorly differentiated (neuro-endocrine) carcinomas of the gastro-intestinal tract are mixed with more typical areas of carcinoma, however, and probably originate from a common precursor epithelial stem cell. (Lewin, 1992). This information indicates that a distinction should not necessarily be drawn between epithelial and neuro-endocrine differentiation.

The neuro-endocrine and neuro-epithelial tumours described by Weeks demonstrate convincing ultrastructural evidence of neural and neuro-endocrine differentiation, however, and tumours showing a clear transition between such cases and MRTK have not been described.

Another point of interest is that the origin of the nerve supply to the kidney is not understood, and the possibility of origin of MRTK from neuro-epithelium/neuro-endocrine tissue deserves further investigation. Peripheral nerve sheath and Schwannian tissue in particular, in contrast to neuro-endocrine and carcinoid cells, appears to originate from

mesenchyme rather than epithelium. This distinction also has to borne in mind when considering the histogenesis of these cases, but it should also be pointed out that all renal epithelial tissue is originally of mesenchmal origin, and arises from the metanephric cap.

The ureteric and collecting ducts are also of mesenchymal origin. (Willis, 1958).

The association of MRTK with virtually synchronous brain neoplasms, however, cannot be ignored. A malignant rhabdoid tumour of the liver has also been reported with a second brain primary (Chang, 1989). Unfortunately phacomatoses such as tuberous sclerosis and von Hippel Lindau disease also show an association of brain tumours with renal neoplasms. The renal tumours are not of neuro-epithelial origin in these disorders. The renal adenomas in tuberous sclerosis clearly arise from the nephrons of the kidney, and the angioleiomyomas are mesenchymal tumours. WT has also occurred in patients with neurogenic sarcoma (Li, 1975) and various type of glioma including glioblastoma (Meadows, 1977). These particular associations occur in the absence of a common histogenesis. The presence of rhabdoid cells in both renal and brain tumours could imply a common histogenesis, or alternatively could represent non-specific damage to the cytoskeleton of cells, with the only factor in common between the two sites being an unstable genetic derangement. (Possibly with a primitive epithelioid phenotype in both types of tumour cells).

An example of such an epithelial/neuro-ectodermal derangement is the nevoid basal cell epithelioma syndrome, with the association of medulloblastomas with multiple skin and jaw tumours (Hermans, 1965). It must once again be borne in mind, however, that renal epithelium is actually of metanephric mesenchymal origin. In fact a review of the phacomatoses clearly demonstrates that no histogenetic association at all is present in some of the neoplasms that present together in a particular patient. It is interesting to note that a neuro-epithelial origin was once proposed for WT (Masson, 1938) (De Muylder, 1947) before the more widely accepted origin from metanephric blastema was proposed (Bennington, 1975). Mature ganglion cells have, in fact, been demonstrated within WT's

(Llombart-Bosch, 1980) by silver impregnation techniques. It appears that the ganglion cells in the renal WT's only occur in association with heterologous skeletal muscle, and appear to have migrated into the tumour in response to inductive influences from the skeletal muscle (Llombart-Bosch, 1980).

Tumour transplantation techniques into nude mice have shown that the rhabdoid phenotype is preserved in cells from one of these renal tumours (Gansler, 1991). The absence of the 11p chromosomal deletion in the same lesion (Gansler, 1991) suggests that MRTK is not related to the type of WT associated with ILNR's and the aniridia complex. Specific cytogenetic abnormalities have not yet been identified in MRTK, and very few of these tumours have had cytogenetic investigations performed upon them.

FCIs and macronucleoli have been described in occasional cases of both favourable and unfavourable histology WT, however, as already discussed (Weeks, 1991). These particular cases have behaved in a manner compatible with their underlying WT histology. This information could be used to suggest that the rhabdoid cells originate from the same primordial cells as WT.

Mesenchymal cells differentiating into epithelial structures should express an immunohistochemical profile similar to that noted in MRTK. The mesenchyme of the metanephric cap differentiates into epithelium as the kidney matures. I would like to propose that MRTK could represent an arrest of this differentiation from metanephric mesenchyme at a very early stage. This hypothesis is compatible with most of our data and that noted in previous publications. The ultrastructural evidence suggesting skeletal muscular differentiation in one of our cases could then be analagous to the subcellular equivalent of the differentiation of metanephric stroma in WT into heterologous elements. We have had the opportunity of examining the ultrastructural features of five renal cell carcinomas that presented in the paediatric age group at the Red Cross Children's hospital. The ultrastructure of renal cell carcinomas in children has not received much attention, and we are aware of only one previous case that has been documented in the literature

(O'Brien, 1980). We were interested to see if there was any overlap between the ultrastructural features of these tumours and MRTK. This issue was raised because of the diagnostic difficulties we encountered with case 4.

These renal cell carcinomas fell into two broad groups. Three of the cases corresponded morphologically to the common non-papillary renal cell carcinomas in the cytogenetic classification proposed by Kovacs (1993). The other two cases had scanty cytoplasm and are morphologically compatible with the papillary renal cell neoplasms identified in this cytogenetic classification. We are, unfortunately, unable to assess the cytogenetic profile of these tumours as this was a retrospective study on formalin fixed tissue.

The common mainly non-papillary clear cell tumours examined by us showed the complex cytoplasmic interdigitations so characteristic of RCC (Ghadially, 1985). These structures are also a feature of proximal convoluted renal tubular cells involved in active transport in the normal kidney. The papillary lesions with a high nuclear cytoplasmic ratio do not have these complex interdigitations. Numerous moderately developed cell junctions are visible in both groups of RCC, but fully developed desmosomes are not visible in our cases. The neoplastic cells in both groups of cases are arranged in distinct acini, and have well developed basement membranes. Zonula occludens type junctions and intra-luminal micro-villi are evident in the former groups of non-papillary clear cell tumours. The degree of epithelial differentiation contrasts markedly with the very poorly differentiated features in MRTK. RCC appears to be distinct from MRTK on the basis of these findings, and represent a derangement of almost completely differentiated renal epithelium. RCC can arise within the epithelial component of WT (Allsbrook, 1991), however, as demonstrated in one of the WTs in the Red Cross Hospital archives. (Figs 43 & 44).

4.3.2 Extra-renal rhabdoid tumours. ERRT.

Many ERRTs are extremely poorly differentiated, and have many features in common with MRTK including identical ultrastructural appearances such as the large FCIs, the open nuclear chromatin and the large, prominent single reticular nucleoli. Primitive cell junctions

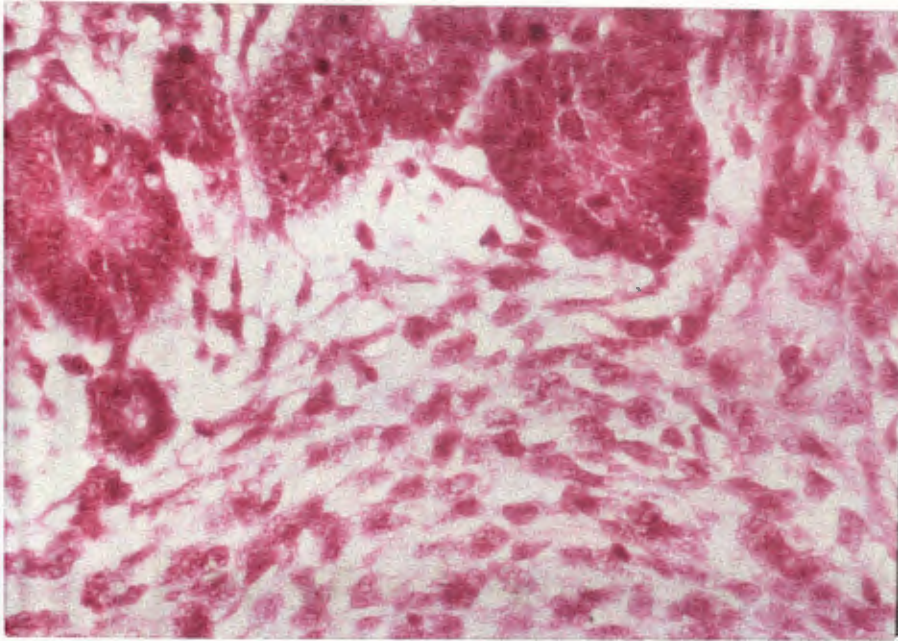


Fig.43 This WT (SD1193/92 RxH) demonstrates typical primitive tubules together with an immature mesenchymal component. (H+E x 497).

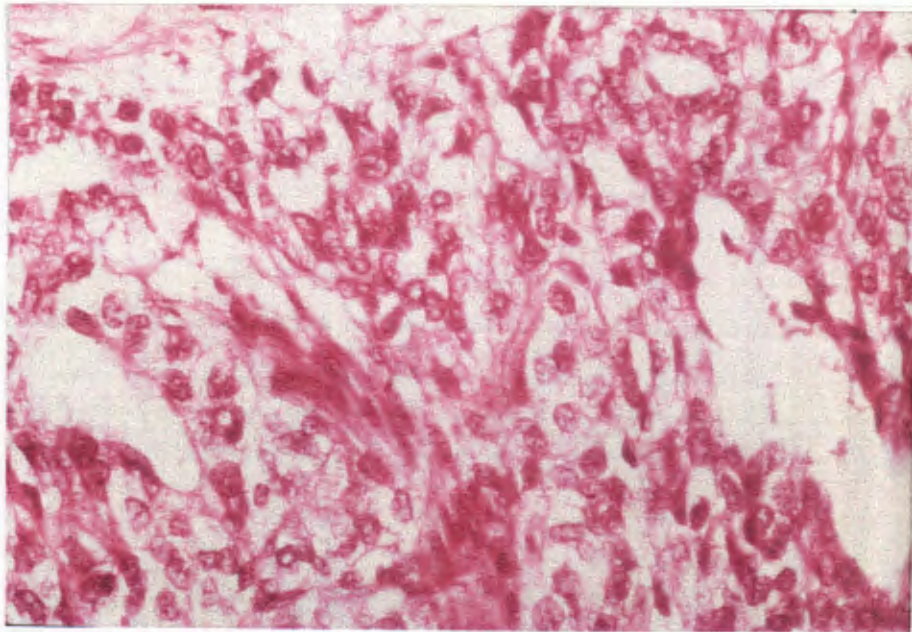


Fig.44 Other areas within this WT (SD1193/92 RxH) shows areas of transformation into a RCC with clear cell areas (illustrated) and papillary areas (not illustrated)(H+E x 497)

have been present in many extra-renal tumours and both groups of rhabdoid tumour often co-express vimentin and cytokeratin in their inclusions (Berry, 1992). The behaviour of the extra-renal tumours is also aggressive, though somewhat more variable than that of MRTK (Berry, 1992). Nearly all the cases of ERRT in this series (with the exception of the MES and PNET/ATT) express low molecular weight cytokeratins (CAM 5,2). In addition, tonofilament-like aggregates are visible in case 2 and in the liver tumour (case 6). Primitive epithelial differentiation appears to be present. In some cases this may originate in epithelial tissue such as the liver, or in neuro-epithelium as for example in the PNET/ATT.

As discussed with MRTK, however, mesenchymal cells differentiating into epithelial structures would also express this phenotype. Mesotheliomas (Jasani, 1985), synovial sarcomas (Tsuneyoshi, 1985) and epithelioid sarcomas (Perrone, 1989) (Molenaar, 1989) (Enzinger, 1983) appear to fall into this category and demonstrates both FCIs, together with co-expression of cytokeratins, EMA and vimentin. Malignant epithelioid Schwannomas (MES) also sometimes have cells displaying this rhabdoid phenotype (Morgan, 1985). It is not certain if MES is primarily of mesenchymal or of neuro-ectodermal origin. It is interesting that epithelioid and synovial sarcomas have been shown to contain high levels of epidermal growth factor receptors (Gusterson, 1985). Certain examples of rhabdoid tumour may represent undifferentiated examples of these entities. Alternatively some cases of rhabdoid tumour could represent another distinct epithelioid type of sarcoma.

Extra-renal rhabdoid tumours represent a more heterogenous group than MRTK in terms of age of presentation, anatomical location, biological behaviour and even histogenesis. Most examples of ERRT clearly arise from a number of different entities. Nearly all of these tumours share a common characteristic of primitive epithelial differentiation as suggested by immunohistochemical expression of EMA and/or cytokeratin in many cases; and by the presence of tonofilament bundles and external lamina in a few cases. The FCIs themselves are not specific, and do not appear to imply any particular form of differentiation. Some investigators have even described FCIs as a result of disruption of the cell architecture

following chemotherapy. The publication of a transitional cell carcinoma of the bladder, with metaplastic foci of spindle cell carcinoma and other adjacent areas of rhabdoid tumour provides compelling evidence for a true epithelial origin of some of these tumours (Harris, 1987).

A small proportion of otherwise undifferentiated rhabdoid tumours outside the kidney could still represent a distinct diagnostic entity, however, even if most cases are merely phenotypes in a variety of different malignant diseases. The intriguing possibility of a genuine ERRT is supported by the fact that a brain tumour developed shortly after the appearance of a malignant rhabdoid tumour of the liver in a 5 month old girl (Chang, 1989). This association is comparable to that noted for MRTK.

Two of the paraspinal lesions in our series and the vaginal lesion could also conceivably represent "genuine rhabdoid tumours". There is certainly no evidence of contrary in these particular cases although sampling in two of the examples is definitely suboptimal. Three of the vulval rhabdoid tumours presented by Perrone (1989) are also identical to MRTK, and demonstrate very aggressive biological behaviour.

Although ultrastructural examination is definitely more useful than immunohistochemistry when considering the differential diagnosis of these tumours; it is also now evident that morphology alone has its limitations.

4.4 Cytogenetic aspects.

Chromosomal studies and other more sophisticated cytogenetic investigations are clearly required. Unfortunately cell culture systems for solid tissue tumours are difficult to establish. No cell culture techniques were possible in our retrospective analysis.

Very few cytogenetic investigations have been performed on MRTK and ERRT. The only specific alteration known to date is a loss of chromosome 22 in four of the primary brain tumours with a rhabdoid morphology (Biegel, 1989). A t (18,22) reciprocal translocation has been reported in a primary extradural brain tumour (Douglass, 1990). An orbital rhabdoid tumour following a retinoblastoma and radiotherapy was reported by

Walford (1992). This tumour was hypotetraploid on 12 metaphase cultures with between 76 to 95 chromosomes. Although no non-random chromosomal alterations were detectable, low copy numbers of numerous chromosomal derangements were evident possibly indicating an unstable tumour cell genotype. This neoplasm did not appear to be a retinoblastoma that had transformed as there were no characteristic breaks on chromosome 13. Lynch (1983) has published cell culture data from two female siblings who both died from paravertebral malignant rhabdoid tumours. The non-neoplastic somatic fibroblasts from these patients could be distinguished from cultures from the parents and age-matched controls by increased *in vitro* occurrence of tetraploidy. This information may indicate a cancer-prone gene syndrome, as this feature has also been demonstrated in some kindreds with heritable colon cancer syndromes (Danes, 1976) (Danes, 1978). The mode of inheritance in these two related patients with paraspinous rhabdoid tumours may possibly be autosomal recessive, or the result of a spontaneous mutation in a dominant gene (Lynch, 1983). The few neoplasms that have been studied in other sites do not show consistent cytogenetic alterations (Molenaar, 1989) (Douglass, 1980).

Three cases of deep-seated sarcoma reported by Molenaar (1989) demonstrated predominantly diploid cell populations. These tumours occurred in patients between 10 and 20 years of age. Two were inguinal in origin, and one arose in the forearm. Their morphology and biological behaviour were more compatible with rhabdoid tumour rather than epithelioid sarcoma. One of these tumours showed over representation of chromosome 2 in the neoplastic cells, with some break points in the 2q35-37 region. Changes in this region had previously been more or less specific for alveolar rhabdomyosarcoma. This data adds to the confusion surrounding the histogenesis of these lesions.

Flow cytometry has been performed on one series of 93 paediatric renal tumours (Kumar, 1989). Sixty-seven favourable histology WTs, 12 unfavourable histology WTs, 8 BMRTCs and 6 MRTKs were included. Interestingly the only tumours that demonstrated increased

aneuploidy were the unfavourable histology WT. The BMRTCs and MRTKs were all diploid despite their unfavourable prognosis.

MRTKs do not show the 11p13 deletion seen in certain WT (Gansler, 1991), and one case studied in detail did not show the loss of heterozygosity for multiple loci on chromosome 11 (Dao, 1987). This suggests that typical cases of MRTK are not variants of WT. The MRTK described by Gansler (1991) expressed c-myc, but not N-myc, excluding the possibility of origin from an adrenal type neuroblastoma. WT also express increased quantities of N-myc (Nissen, 1986). This information mitigates against MRTK being part of the spectrum of WT, although it does not exclude its origin at some other point from the metanephric mesenchyme.

RNA from insulin growth factor-2 (IGF-2) has been increased in cultures from both MRTK (Gansler, 1991) and WT (Scott, 1985) (Haselbacher, 1987). This is interesting as damage to the 11p15 chromosome locus associated with IGF-2 is present in WT associated with the Beckwith-Weidemann complex (the WT2 gene). Unfortunately a definite association between WT and MTRK cannot be inferred, as IGF-2 expression is upregulated in many tumours including pheochromocytomas (Haselbacher, 1987), rhabdomyosarcomas (Scott, 1985), hepatoblastomas (Scott, 1985) and colonic carcinomas and liposarcomas (Tricholi, 1986).

The serum and growth factor requirements of an MRTK cell line were most consistent with those for mesenchymal cells; whilst the ingredient required to maintain WT cells were intermediate between those needed for mesenchyme and the absence of factors that suited culture of proximal tubular epithelium. (Gansler, 1991). This information suggests that MRTK may come from mesenchymal cells, although interpretation is difficult because of our still very limited understanding of the extracellular factors required for cell growth and differentiation. These culture results are not incompatible with an origin of MRTK from metanephric mesenchyme, and do not exclude early epithelial differentiation within metanephric mesenchymal cells.

4.5 Clinical considerations.

The identification of an undifferentiated tumour with a predominance of rhabdoid cells is still associated with a grave prognosis, even if it is situated outside the kidney. The malignant potential of a tumour does not necessarily correspond to its histogenesis. It is still clinically very important to identify neoplasms that will behave in an aggressive manner, and to distinguish them from other lesions that may mimic them histologically.

Sheets of eosinophilic cells in some cases of WT can mimic MRTK. The ultrastructure of WT with these features has not been illustrated in the literature, although the presence of large phagolysosomes in such cases has been well documented by Mierau (1987). We have included an example of this type of tumour from our archives to demonstrate some important distinguishing points. (SD 577/83 RxH). Sheets of eosinophilic blastemal cells are present in this case. The nuclear chromatin in the cells is rather homogenous and identical to that noted in blastemal nuclei elsewhere in the WT. Large vesicular nuclei with prominent nucleoli characteristic of rhabdoid cells are not present. The sheets of eosinophilic cells are also arranged in well defined blastemal-type nests (Fig 45). In this case the eosinophilic cytoplasmic material in the WT corresponds to multiple lysosomal bodies seen on ultrastructural examination (Fig 46). In other foci there are typical foci of nephroblastomatous blastema, as well as mesenchymal elements containing clearly defined rhabdomyoblasts.

Isolated neoplastic cells with all of the characteristic rhabdoid features have occasionally been noted in WT. (Weeks, 1991) and even in rhabdomyosarcomas (Kodet, 1991), but these cells only form a very minor component of the neoplasms. FCIs are present, but the ultrastructural features of the FCI aggregates noted in the rhabdomyosarcomas do not, in my opinion, convincingly resemble those of rhabdoid tumours. In addition, the cytoplasm of the rhabdomyosarcomatous cells express large amounts of cytoplasmic vimentin outside the inclusions. (Kodet, 1991). Nuclear morphology is also more variable than that seen in rhabdoid tumour, and the cells usually express desmin and myoglobin. There is also clear

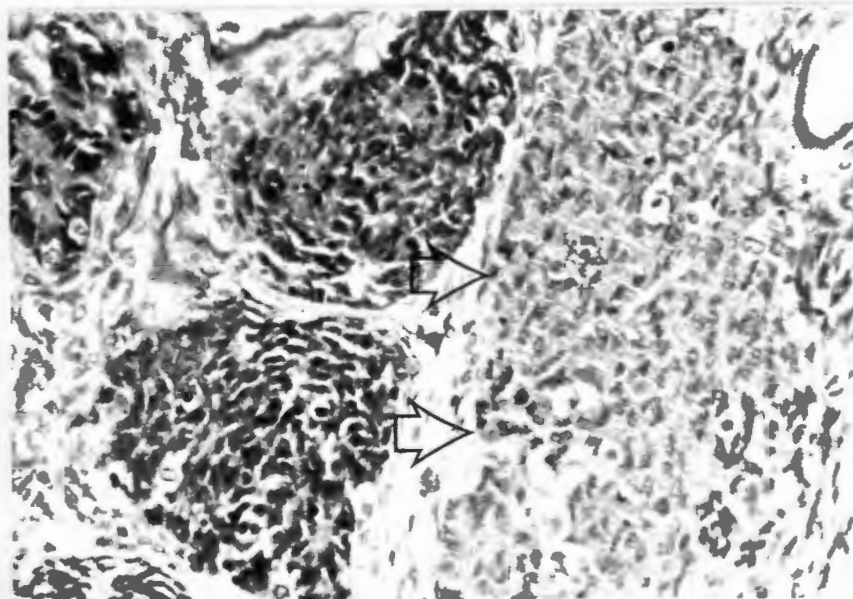


Fig.45 SD577/83. RxH. Wilms tumour showing typical blastemal foci and an additional nest of blastemal cells with pale eosinophilic cytoplasm (arrows). The large nucleoli and vesicular nuclear chromatin seen in typical rhabdoid cells are absent. (H+E x 160)

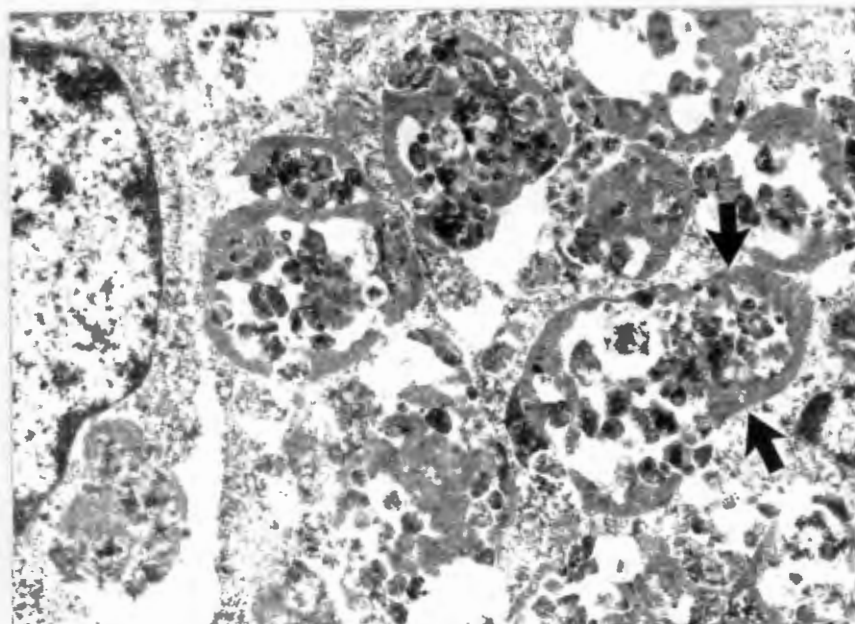


Fig.46 SD577/83. RxH Wilms tumour. Skein-like nucleoli seen in the rhabdoid tumours are absent. Large intracytoplasmic lysosomal inclusions account for the eosinophilic appearance on light microscopy. (x 16320)

cut immunohistochemical and ultrastructural evidence of rhabdomyoblastic differentiation (Kodet, 1991). Mesoblastic nephromas CMN may contain prominent nucleoli in the absence of whorled intracytoplasmic inclusions (Weeks, 1991).

5. CONCLUSION AND RECOMMENDATIONS

5.1 Conclusion:

It is obvious that FCIs alone are not specific for a particular tumour. This ultrastructural finding merely represents a derangement in the cytoskeleton of a cell rich in intermediate filaments. The material we present also indicates that they do not imply a particular histogenesis.

It is, in fact, extremely dangerous to incorrectly label a tumour that may respond favourably to therapy as a malignant rhabdoid tumour merely because of the fact that FCIs have been identified in the tumour cells. Patients with a diagnosis of rhabdoid tumour at our institution will not be offered any active management after surgical resection has been attempted.

The majority of otherwise very poorly differentiated MRTKs that arise in young infants do appear to represent a specific entity, however, with a dismal prognosis. One of the cases we present, however, indicates that not all renal tumours with this appearance are alike. Tumours that do not fit perfectly into the diagnostic framework must be reported, so that diagnostic criteria can be modified, and so that new entities can be evaluated.

Although many of the extra-renal tumours appear to have a diverse histogenesis, both the renal and extra-renal neoplasms appear to arise from tumour cells showing similar directions of differentiation.

Unfortunately no firm conclusions as to histogenesis can be made on the basis of this detailed morphological study. We would like to suggest, however, that nearly all rhabdoid tumours show evidence of primitive epithelial differentiation. This occurs despite the fact that some of the neoplasms arise in ectodermal epithelium or neuro-ectodermal epithelium,

whilst others arise in endodermal epithelium. Other rhabdoid tumours, including MRTK, appear to arise in mesenchyme that is differentiating in an epithelial direction.

Morphology alone cannot resolve this problem. Cytogenetic studies and cell culture techniques are clearly required to identify the particular genetic and biochemical abnormalities that will explain the rhabdoid phenotype. Unfortunately a rhabdoid lesion is often only identified as such several days after the tissue has been processed, and the opportunity for cell culture and cytogenetic investigation is missed.

5.1 Recommendations.

MRTKs

1. A diagnosis of MRTK should only be made on an adequately sampled tumour that contains a predominance of cells with the rhabdoid phenotype. There should be no evidence within the lesion to support an alternative diagnosis.
2. Fresh tissue from all renal tumours should be fixed in glutaraldehyde and stored for ultrastructural investigation. This is important and valuable opportunities to further our understanding of renal tumour pathology have been lost because of a lack of attention to this detail. In certain difficult cases electron microscopic examination is essential to distinguish tumours with a favourable prognosis such as cellular CMN from aggressive lesions such as BMRTC and MRTK.
3. Batteries of immunohistochemical tests are not particularly helpful in renal tumours, and the often dubious result obtained particularly with MRTK do not justify the expense of the investigation.

Directed immunohistochemical investigations may at times help to resolve difficult diagnostic problems. Appropriate tissue should ideally be taken for immuno-electron microscopy, as this may be useful for research purposes.

4. Fresh tissue should be processed for cell culture and cytogenetic studies from all renal tumours. Research into renal neoplasia cannot proceed further unless tissue is processed in this manner.

ERRTs

1. Extra-renal tumours with numerous rhabdoid cells that are otherwise undifferentiated must be adequately sampled, and preferably totally resected for diagnostic purposes. A diagnosis of malignant rhabdoid tumour must never be conveyed to a clinician on the basis of an inadequately sampled tumour. Extra-renal neoplasms of this nature should be labelled as “undifferentiated neoplasms with a rhabdoid phenotype”. An alternative diagnosis must be offered if the neoplasm contains any areas compatible with obvious differentiation towards another entity. The presence of a rhabdoid phenotype should only be mentioned after this primary diagnosis has been clearly stated. The evidence for this alternative diagnosis may only be apparent on ultrastructural examination.
2. Representative tissue sections from all undifferentiated sarcomas and all parenchymal brain tumours should be fixed in glutaraldehyde for electron microscopy. Ideally fresh tissue should also be processed for cytogenetic studies, particularly if totally undifferentiated paravertebral, vulval and hepatic tumours are encountered. All unusual cases with rhabdoid features both in the kidney and at extra-renal sites should be reported.

REFERENCES:

1. Achtstaetter T, Moll R, Moore B, Franke WW: Cytokeratin polypeptide patterns of different epithelia of the human male genital tract: Immunofluorescence and gel electrophoretic studies. *J Histochem Cytochem.* 1985. 33:415-426.
2. Allred CD, Cathey WJ, McDivitt RW: Primary renal angiosarcoma. A case report. *Hum Pathol.* 1981. 12:665-668.
3. Allsbrook WC, Boswell WC, Takahashi H, Pantazis CG, Howell CG, Martinez JE, Beck JR: Recurrent renal cell carcinoma arising in Wilms tumour. *Cancer.* 1991. 67: 690-695.
4. Batsakis JG, Manning JT: Pathology consultation. Malignant rhabdoid tumour. *Ann Otol Rhinol Laryngol* 1988. 97:690-691.
5. Becker LE, Hinton D. Primitive neuro-ectodermal tumours of the central nervous system. *Hum. Pathol.* 1983. 14(b): 538-550.
6. Beckwith JB, Palmer NF. Histopathology and prognosis of Wilms tumour. Results from the First National Wilms tumour study. *Cancer.* 1978. 41: 1937-1948.
7. Beckwith JB, Kiviat NB, Bonadio JF. Nephrogenic rests, nephroblastomosis and the pathogenesis of Wilms tumour. *Pediatr Pathol.* 1990. 10,1.
8. Bennington JL, Beckwith JB. Tumours of the kidney, renal pelvis and ureter. AFIP atlas of tumour pathology, 2nd series. Washington, D.C. 1975.
9. Berry PJ, Vujanic GM. Commentary. Malignant rhabdoid tumour. *Histopathology.* 1992. 20: 189-193.
10. Biegel JA, Rorke LB, Emmanuel BS. Monosomy 22 in rhabdoid or atypical teratoid tumours of the brain. ABSTRACT. *N Engl J Med.* 1989. 321:906.
11. Biegel JA, Rorke LB, Packer RJ, Sutton LN, Schut L, Bonner K, Emanuel BS. Isochromosome 17q in primitive neuro-ectodermal tumours of the central nervous system. *Genes, chromosomes & cancer.* 1989. 1(2): 139-147.
12. Biegel JA, Rorke LB, Packer RJ, Emmanuel BS. Monosomy 22 in rhabdoid or atypical tumours of the brain. *Journal of neurosurgery.* 1990. 73(5):710-714.
13. Biggs PJ, Garen PD, Powers JM, Garvin AJ. Malignant rhabdoid tumour of the central nervous system. *Human pathol.* 1987. 18:332-337.
14. Bittesini L, Dei Tos AP, Fletcher CDM. Metastatic malignant melanoma showing a rhabdoid phenotype. Further evidence of a non-specific histological pattern. *Histopathology.* 1992. 20:167-170.
15. Bolande RP, Brough AJ, Izant RJ. Congenital mesoblastic nephroma of infancy. *Paediatrics.* 1967. 40:272.
16. Bonnin JM, Rubinstein LJ, Palmer NF, Beckwith JB. The association of embryonal tumours originating in the kidney and in the brain. *Cancer.* 1984; 54:2137-2140.
17. Call KM, Glaser T, Ito CY et al. Isolation and characterization of a zinc finger polypeptide gene at the human chromosome 11 Wilms tumour locus. *Cell.* 1990; 60:509.
18. Carlei F, Polak JM, Ceccamea A, Marangos PJ, Dahl D, Cocchia D, Michetti F, Lezoche E, Speranza V. Neuronal and glial markers in tumours of neuroblastic origin. *Virchows Arch (Pathol Anat).* 1984; 404:313-324.
19. Carter RL, McCarthy KP, Al-Sam SZ, Monaghan P, Agrawal M, McElwain TJ. Malignant rhabdoid tumour of the bladder with immunohistochemical and ultrastructural evidence suggesting histiocytic origin. *Histopathology.* 1989;14:179-190.
20. Chatten J, Cromie WJ, Duckett JW. Ossifying tumour of infantile kidney. Report of 2 cases. *Cancer.* 1980; 45:609-612.

21. Chang CH, Ramirez N, Sakr WA. Primitive neuro-ectodermal tumour of the brain associated with malignant rhabdoid tumour of the liver. A histologic, immunohistochemical and electron microscopic study. *Paediatr. pathol.* 1989; 9:307-319.
22. Chetty R, Bhathal PS. Caecal adenocarcinoma with rhabdoid phenotype. An immunohistochemical and ultrastructural analysis. *Virchow's Arch A Pathol Anat Histopathol.* 1993; 422:179-182.
23. Cromie WJ, Davis CJ, De Ture FA. Atypical carcinoma of kidney, possibly originating from collecting duct epithelium. *Urology.* 1979; 13:315-317.
24. Daimaru Y, Hashimoto H, Enjoji M. Malignant peripheral nerve-sheath tumours (malignant schwannomas). An immunohistochemical study of 29 cases. *Am J Surg Pathol.* 1985; 9:434-444.
25. Danes BS. The Gardner syndrome: Increased tetraploidy in cultured skin fibroblasts. *J Med Genet.* 1976; 13:52-56.
26. Danes BS. Increased in vitro tetraploidy: tissue specific within the heritable colorectal cancer syndromes with polyposis coli. *Cancer.* 1978; 41:2330-2334.
27. Dao DT, Schroeder WT, Chao L-Y et al. Genetic mechanisms of tumour specific loss of 11p. DNA sequences in Wilm's tumour. *Am.J. Hum. Genet.* 1987; 41:202-217.
28. De Muylder CG. Neurogenesis observed in a mixed Grawitz-Wilms tumour. *Archives of Pathology.* 1947; 44:451-458.
29. de Davila MTG, Gonzalez-Crussi F, Mangkornkanok M. Fibro-lamellar carcinoma of the liver in a child. Ultrastructural and immunohistochemical aspects. *Paediatr pathol.* 1987; 7:319-331.
30. DeSchryver K, Santa Cruz DJ. So-called glandular schwannoma: ependymal differentiation in a case. *Ultrastruct Pathol.* 1984; 6:167-175.
31. DiCarlo, EF, Woodruff JM, Bansal M, Erlandson RA. The purely epithelioid malignant peripheral nerve sheath tumour. *Am J. Surg. Pathol.* 1986; 10(7):478-490.
32. Douglass EC, Valentine M, Rowe ST, Parham DM, Wilmas JA, Sanders JM, Houghton PJ. Malignant rhabdoid tumour: a highly malignant childhood tumour with minimal karyocytic changes. *Genes Chromosome Cancer.* 1990; 2:210-216.
33. Dumanski JP, Carlborn E, Collins VP, et al. Deletion mapping of a locus on human chromosome 22 involved in the oncogenesis of meningioma. *Proc Natl Acad Sci USA.* 1987; 84:9275-9279.
34. Eberth CJ. *Virch. Arch.* 1872; 55:518.
35. Ekfors TO, Aho HJ, Kekomaki M. Malignant rhabdoid tumour of the prostatic region. *Virchows Arch (Pathol.Anat).* 1985; 406:381-388.
36. Enzinger FM, Weiss SW. *Soft tissue tumours.* Mosby. 1983; 787-795.
37. Eve FS. *Trans.Path.Soc.Lond.* 1882; 33:312.
38. Farrow GM, Harrison EG jr, Utz DC. Sarcomas and sarcomatoid and mixed malignant tumours of the kidney in adults. *Cancer.* 1968; 22:545-563.
39. Favara BE, Johnson W, Ito J. Renal tumours in the neonatal period. *Cancer.* 1968; 22:845-855.
40. Fein RL, Hamm FC. Malignant Schwannoma of the renal pelvis: a review of the literature and a case report. *Ibid.* 1965; 94:356-361.
41. Ferrell RE, Strong LC, Riccardi VM, et al. A clinical, cytogenetic and gene marker survey of 106 patients with Wilm's tumour and/or aniridia. (Abstract) *Am J Hum Genet.* 1980; 32:104A.
42. Ferry JA, Dickersin GR. Pseudoglandular Schwannoma. *Am J. Clin Pathol.* 1988; 89:546-552.

43. Finegold M. Recent developments in diagnosis and treatment of hepatoblastoma. From: Short course - Eb-1. Advances in childhood tumour diagnosis. (Proceedings of the XIX international congress of the international academy of pathology. Madrid 18-23 Oct 1992).
44. Fischer HP, Thomsen H, Altmannsberger M. Malignant rhabdoid tumour of the kidney expressing neurofilament proteins. Immunohistochemical findings and histogenetic aspects. *Pathol Res Pract.* 1989; 184:541-547.
45. Fleming S, Lindop GBM, Gibson AAM. The distribution of epithelial membrane antigen in the kidney and its tumours. *Histopathology.* 1985; 9:729-739.
46. Fleming S, Lewi HJE. Collecting duct carcinoma of the kidney. *Histopathology.* 1986; 10:1131-1141.
47. Foraker AG. Gland-like elements in peripheral neurosarcoma. *Cancer.* 1948; 1:286-293.
48. Foschini MP, van Eyken P, Brock PR, et al. Malignant rhabdoid tumour of the liver. A case report. *Histopathology.* 1992; 20:157-165.
49. Francke U, Holmes LB, Atkins L, Riccardi VM. Aniridia Wilms tumour association. Evidence for specific deletion of 11p13. *Cytogenet Cell Genet.* 1979; 24:185-192.
50. Franquemont DW, Mills SE. Plasmacytoid monomorphic adenoma of salivary glands: absence of myogenous adenoma and comparison to spindle cell myo-epithelioma. *Am J Surg Pathol.* 1993; 17:146-153.
51. Fuhrman SA, Lasky LC, Limas C. Prognostic significance of morphologic parameters in renal cell carcinoma. *Am J Surg Pathol.* 1982; 6:655-663.
52. Gansler T, Gerald W, Anderson G, Stokes-Gramling T, Williams CH, Sens D, Garvin AJ. Characterisation of a cell line derived from rhabdoid tumour of the kidney. *Human Pathol.* 1991; 22:259-266.
53. Ghadially FN. Diagnostic electron microscopy of tumours. 2nd Ed. London. Butterworths. 1985.
54. Gonzalez-Crussi F, Sotelo-Avila C, Kidd JM. Mesenchymal renal tumours of infancy. *Human pathol.* 1981; 12:78-85.
55. Gonzalez-Crussi F, Goldschmidt RA, Hsueh W, Trujillo YP. Infantile sarcomas with intracytoplasmic filamentous inclusions. Distinctive tumour of possible histiocytic origin. *Cancer.* 1982; 49:2365-2375.
56. Griffin CA, Hawkins AL, Packer RJ, et al. Chromosomal abnormalities in paediatric brain tumours. *Cancer res.* 1988; 48:175-180.
57. Guccion JG, Enzinger FM. Malignant schwannoma associated with Von Recklinghausen's neurofibromatosis. *Virch Arch A. Path Anat Histol.* 1979; 383:43-57.
58. Gusterson B, Cowley G McIlhinney J, et al. Evidence for increased epidermal growth factor receptors in human sarcomas. *Int J Cancer.* 1985; 36:689-693.
59. Haber DA, Buckler AJ, Glaser T, et al. An internal deletion within 11p13 zinc finger gene contributes to the development of Wilms tumour. *Cell.* 1990; 61:1257.
60. Hall DJ, Grimes MM, Goplerud DR. Case report. Epithelioid sarcoma of the vulva. *Gynaecol Oncol.* 1980; 9:237-246.
61. Hai M, Diaz-Perez R. Atypical carcinoma of kidney originating from collecting duct epithelium. *Urology.* 1982; 19:89-92.
62. Hamperl H. Benign and malignant oncocyoma. *Cancer.* 1962; 15:1019-1027.
63. Hansen K, Bagtas J, Hon Fong M, Homans A, Singer DB. Undifferentiated small cell hepatoblastoma with a unique chromosomal translocation: A case report. *Paediatr Pathol.* 1992; 12:457-462.
64. Harris M, Eyden BP, Joglekar VM. Rhabdoid tumour of the bladder. A histological, ultrastructural and immunohistochemical study. *Histopathology.* 1987; 11:1083-1092.

65. Haselbacher GK, Irminger JC, Zapf J, et al. Insulin-like growth factor II in human adrenal pheochromocytomas and Wilms tumours. Expression at the mRNA and protein level. *Proc Natl Acad Sci USA*. 1987; 84:1104-1106.
66. Henmans EH, Grosfeld JCM, Spaas JAJ. The fifth phacomatosis. *Dermatologica*. 1965; 130:446-476.
67. Howat AJ, Gonzales MF, Waters KD, Campbell PE. Primitive neuro-ectodermal tumour of the central nervous system associated with malignant rhabdoid tumour of the kidney. Report of a case. *Histopathology*. 1986; 10:643-650.
68. Hunt SJ, Anderson W. Malignant rhabdoid tumour of the liver. A distinct clinicopathological entity. *Am J Clin Pathol*. 1990; 94:645-648.
69. Jasani B, Edwards RE, Thomas ND, Gibbs AR. The use of vimentin antibodies in the diagnosis of malignant mesothelioma. *Virchows Arch. (Pathol Anat.)* 1985; 406:441-448.
70. Jakobiec FA, Tso MOM, Zimmerman LE, et al. Retinoblastoma and intracranial malignancy. *Cancer*. 1977; 39:2048.
71. Joshi VV, Beckwith JB. Multilocular cyst of the kidney (cystic nephroma) and cystic partially differentiated nephroblastoma. Terminology and criteria for diagnosis. *Cancer*. 1989; 64:466-479.
72. Joshi VV, Beckwith JB. Pathological delineation of the papillonodular type of cystic partially differentiated nephroblastoma. *Cancer*. 1990; 66:1568-1577.
73. Karnes PS, Tran TN, Ho HY, et al. The establishment of a malignant rhabdoid tumour cell line with a specific chromosomal translocation t(11p;22q). *Cancer Genet Cytogenet*. 1989; 41:B17.
74. Kaschula ROC. The pathology of Wilms tumour. *Understanding Oncology*. 1996;7:4-11.
75. Kent AL, Mahoney DH, Gresik MV, Steubar CP, Fernbach DJ. Malignant rhabdoid tumour of the extremity. *Cancer*. 1987; 60:1056-1059.
76. Klein MJ, Valensi QJ. Proximal tubular adenomas of kidney with so-called oncocytic features. A clinicopathologic study of 13 cases of a rarely reported neoplasm. *Cancer*. 1976; 38:906-914.
77. Kodet R, Newton W, Hamoudi A, Asmar L. Rhabdomyosarcomas with intermediate filament inclusions and features of rhabdoid tumours. *Am J Surg Pathol*. 1991; 15:257-267.
78. Kovacs G, Soudah B, Hoene E. Binucleated cells in a human renal cell carcinoma with 34 chromosomes. *Cancer Genet. Cytogenet*. 1988; 31:211-216.
79. Kovacs G, Welter C, Wilkens L, Blin N, Deriese W. Renal oncocytoma; a phenotype and genotypic entity of renal parenchymal tumours. *Am J Pathol*. 1989; 134:967-971.
80. Kovacs A, Kovacs G. Low chromosome number in chromophobe renal cell carcinomas. *Genes Chromosomes Cancer*. 1992; 4:267-268.
81. Kovacs A, Storkel S, Thoenes W, Kovacs G. Mitochondrial and chromosomal DNA alterations in human chromophobe renal cell carcinomas. *J Pathol*. 1992; 167:273-277.
82. Kovacs G. Molecular differential pathology of renal cell tumours. (Review). *Histopathology*. 1993; 22(1):1-8.
83. Krumerman MS, Stingle W. Synchronous malignant glandular schwannomas in congenital neurofibromatosis. *Cancer*. 1978; 41:2444-2451.
84. Kumar S, Carr T, Marsden HB, Calabuig-Crespo MC. Study of childhood renal tumours using antisera to fibronectin, laminin, and epithelial membrane antigen. *J Clin Pathol*. 1986; 39:51-57.
85. Kumar S, Marsden HB, Cowan RA, Barnes JN. Prognostic relevance of DNA content in childhood renal tumours. *Br J. Cancer*. 1989; 59:291-295.
86. Kudo E, Hirose T, Fujii Y, Hasegawa T, Ino H, Hizawa K. Undifferentiated carcinoma of the vulva mimicking epithelioid sarcoma. *Am J Surg Pathol*. 1991; 15:990-1001.

87. Lack EE, Cassady JR, Sallan SE. Renal carcinoma in childhood and adolescence: a clinical and pathological study of 17 cases. *J Urol*. 1985; 133:822-828.
88. Lanford JA, Cohn I. Ependymal neoplasm of the median nerve with case report. *South Med J*. 1927; 20:273-278.
89. Lefkowitz IB, Rorke LB, Packer RJ, et al. Atypical teratoid tumour of infancy; definition of an entity. *Ann Neurol*. 1987; 22:448-449.
90. Lemos LB, Hamoudi AB. Malignant thymic tumour in an infant (malignant histiocytoma). *Arch. Pathol Lab Med*. 1978; 102:84-89.
91. Leuschner L, Harms V. Renal cell carcinoma in children. *Medical and paediatric oncology*. 1991; 19:33-41.
92. Lewin KJ, Riddell RH, Weinstein WM. Gastro-intestinal pathology and its clinical implications. *Igaku-Shoin*. 1992; 245.
93. Li FP, Cassady JR, Jaffe N. Risk of second tumours in survivors of childhood cancer. *Cancer*. 1975; 35:1230-1235.
94. Llombart-Bosch A, Peydro-Olaya AA, Cerda-Nicolas M. Presence of ganglion cells in Wilm's tumours: a review of the possible neuro-epithelial origin of nephroblastoma. *Histopathology*. 1980; 4:321-330.
95. Lowe W, Weiss RM, Todd MB, True LD. Malignant rhabdoid tumour of the kidney in an adult. *J Urol*. 1990; 143:110-112.
96. Lynch HT, Shurin SB, Dahms BB, Izant RJ, Lynch J, Danes BS. Paravertebral malignant rhabdoid tumour in infancy. *Cancer*. 1983; 52:290-296.
97. Malhotra CM, Doolittle CH, Rodil JV, Vezeridis MP. Mesenchymal chondrosarcoma of the kidney. *Cancer*. 1984; 54:2495-2499.
98. Mancilla-Jimenez R, Stanley RJ, Blath RA. Papillary renal cell carcinoma. A clinical radiologic and pathologic study of 34 cases. *Cancer*. 1976; 38:2469-2480.
99. Markesbery WR, Challa VR. Electron microscopic findings in primitive neuro-ectodermal tumours of the cerebrum. 1979; 44:141.
100. Marsden HB, Lawler W, Kumar PM. Bone metastasizing renal tumour of childhood: morphological and clinical features, and differences from Wilms tumour. *Cancer*. 1978; 42:1922-1928.
101. Marsden HB, Lawler W. Bone metastasizing renal tumour of childhood: histopathological and clinical review of 38 cases. *Virchows Arch (Pathol Anat)*. 1980; 387:341-351.
102. Masson P. The role of the neural crest in the embryonal adenosarcomas of the kidney. *American Journal of Cancer*. 1938. 33:1-31.
103. Mayes LC, Kasselberg AG, Roloff JS, Lukens JN. Hypercalcaemia associated with immunoreactive parathyroid hormone in a malignant rhabdoid tumour of the kidney. *Cancer*. 1984; 54:882-884.
104. McNutt MA, Bolen JW, Gown AM, Hammar SP, Vogel AM. Co-expression of intermediate filaments in human epithelial neoplasms. *Ultrastructural pathology*. 1985; 9:31-43.
105. Mead JH, Herrera GA, Kaufman MF, Herz JH. Case report of a primary cystic sarcoma of the kidney, demonstrating fibrohistiocytic, osteoid and cartilaginous components (malignant mesenchymoma). *Cancer*. 1982; 50:2211-2214.
106. Meadows AT, D'Angio GJ, Mike V, et al. Patterns of second malignant neoplasms in children. *Cancer*. 1977; 40:1903-1911.
107. Meis JM, Mackay B, Ordonez NG. Epithelioid sarcoma: an immunohistochemical and ultrastructural study. *Surg Pathol*. 1988; 1:13-31.
108. Michel SL. Epithelial elements in a malignant neurogenic tumour of the tibial nerve. *Am J Surg*. 1976; 113:404-408.
109. Micolonghi TS, Liang D, Schwartz S. Primary osteogenic sarcoma of the kidney. *J Urol*. 1984; 131:1164-1166.
110. Mierau GW, Beckwith JB, Weeks DA. Ultrastructure and histogenesis of the renal tumours of childhood: an overview. *Ultrastruct pathol*. 1987; 11:313-333.

111. Mierau GW, Weeks DA, Beckwith JB. Anaplastic Wilms tumour and other clinically aggressive childhood renal neoplasms. Ultrastructural and immunocytochemical features. *Ultrastruct pathol.* 1989; 13:225-248.
112. Misugi K, Okajima H, Misugi N, Newton WA. Classification of primary malignant tumours of liver in infancy and childhood. *Cancer.* 1967; 20:1760-1771.
113. Mitelman F. Catalog of chromosome aberrations in cancer, ed 3. New York: Alan R Liss. 1988; 1146 pp.
114. Molenaar WM, De Jong B, Dam-Meiring A, Postma A, De Vries J, Hoekstra HJ. Epithelioid sarcoma or malignant rhabdoid tumour of soft tissue? Epithelioid immunophenotype and rhabdoid karyotype. *Human Pathol.* 1989; 20:347-351.
115. Moll R. Intermediarfilamentmuster des Nephrons und des Urothels. *Verh Dtsch Ges Pathol.* 1989; 73:314-320.
116. Morgan KG, Gray C. Malignant epithelioid schwannoma of superficial soft tissue? A case report with immunohistochemistry and electron microscopy. *Histopathology.* 1985; 9:765-775.
117. Nativ O, Horowitz A, Lindner A, Many M. Primary chondrosarcoma of the kidney. *J Urol.* 1985; 134:120-121.
118. Ng WD, Chan KW, Chan YT. Primary leiomyosarcoma of renal capsule. *J Urol.* 1985; 133:834-835.
119. Nicholson GW. An embryonic tumour of the kidney in a foetus. *J Pathol Bacteriol.* 1931; 34:711-730.
120. Niffenegger JH, Jakobiec FA, Shore JW, Albert DM. Adult extra-renal rhabdoid tumour of the lacrimal gland. *Ophthalmology.* 1992; 99:567-574.
121. Nisen PD, Zimmerman KA, Cotter SV, et al. Enhanced expression of the N-myc in Wilm's tumours. *Cancer Res.* 1986; 46:6217-6222.
122. Osborn M, Dirk T, Kaser H, Weber K, Altmannsberger M. Immunohistochemical localisation of neurofilaments and neuron-specific enolase in 29 cases of neuroblastoma. *Am J Pathol,* 1986; 122:43-442.
123. O'Brien PK, Bedard YC. A papillary adenocarcinoma of the renal pelvis in a young girl. *Am J Clin Pathol.* 1980; 73:427-433.
124. Palmer NF, Beckwith JBI. Multiple primary tumour syndrome in children with rhabdoid tumour of the kidney (RTK), abstracted. *Proc Am Soc Clin Oncol.* 1981; 22:406.
125. Papanicolaou SJ, Eversole LR. Glandular structures in neural sheath neoplasms. *Oral Surg.Oral Med.Oral Pathol.* 1982; 53:69-72.
126. Parham DM, Peiper SC, Robicheaux G,Ribeiro RC, Douglass EC. Malignant rhabdoid tumour of the liver . Evidence of epithelial differentiation. *Arch Pathol Lab Med.* 1988; 112:61-64.
127. Patron M, Palacios J, Rodriguez-Peralto JL, Bungos E, Contreras F. Malignant rhabdoid tumour of the tongue. *Oral Surg. Oral Med. Oral Pathol.* 1988; 65:67-70.
128. Pearl GS, Takei Y, Stefanis GS, et al. Intraventricular neuroblastoma in a patient with Von Hippel-Lindau's disease: light and electron microscopic study. *Acta Neuropathol.* 1981; 53:253.
129. Perrone T, Swanson PE, Twiggs L, Ulbright TM, Dehner LP. Malignant rhabdoid tumour of the vulva; is distinction from epithelioid sarcoma possible? A pathologic and immunohistochemical study. *Am J Surg Pathol.* 1989; 13:848-858.
130. Potter EL. Pathology of the foetus and new born. Chicago. 1953;
131. Robson CJ, Churchill BM, Anderson W. The results of radical nephrectomy for renal cell carcinoma. *J Urol.* 1969; 101:297-301.
132. Rouleau GA, Wertelecki W, Haines JL, et al. Genetic linkage of bilateral acoustic neurofibromatosis to a DNA marker on chromosome 22. *Nature.* 1987; 329:246-248.
133. Ruck P, Harms D, Kaiserling E. Neuro-endocrine differentiation in hepatoblastoma, *Am J Surg Pathol.* 1990; 14:847.

134. Rumpelt HJ, Storkel S, Moll R, Scharfe T, Thoenes W. Bellini duct carcinoma; further evidence for this rare variant of renal cell carcinoma. *Histopathology*. 1991; 18:115-122.
135. Santeusanio G, Pascal RR, Bisceglia M, Constantino AM, Bosman C. Metaplastic breast carcinoma with epithelial phenotype of pseudosarcomatous components. *Arch Pathol Lab Med*. 1988; 112:82-85.
136. Scherer HJ. Structural development in gliomas. *The American Journal of Cancer*. 1938 (Nov); No 3. 333-351.
137. Schmidt D, Dickersin GR, Vawter GF, Mackay B, Harms D. Wilms tumour: review of ultrastructure and histogenesis. *Pathbiol Ann*. 1982; 12:281-300.
138. Schmidt D, Leuschner I, Harms D, Sprenger E, Schafer HJ. Malignant rhabdoid tumour. A morphological and flow cytometric study. *Pathol Res Pract*. 1989; 184:202-210.
139. Scriven RR, Thrasher TV, Smith DC, Stewart SC. Primary renal malignant fibrous histiocytoma. A case report and literature review. *J Urol*. 1984; 131:948-949.
140. Scott J, Cowell J, Robertson ME, et al. Insulin-like growth factor II gene expression in Wilm's tumour and embryonic tissues. *Nature*. 1985; 317:260-263.
141. Seo IS, Min KW, Brodecker C, Mirkin LD. Malignant renal rhabdoid tumour. Immunohistochemical and ultrastructural studies. *Histopathology*. 1988; 13:657-666.
142. Sidhu GS. The endodermal origin of digestive and respiratory tract APUD cells. *Histopathologic evidence and a review of the literature*. *Am J Pathol*. 1979; 95:5-20.
143. Small ES, Gordon GJ, Dahms BB. Malignant rhabdoid tumour of the heart in an infant. *Cancer*. 1985; 55:2850-2853.
144. Sotelo-Avila C, Gonzalez-Crussi F, deMello D, et al. Renal and extra-renal rhabdoid tumours in children: a clinicopathologic study of 14 patients. *Semin. Diag. Pathol*. 1986; 3:151-163.
145. Stosiek P, Kasper M, Karsten U. Expression of cytokeratin 19 during human liver organogenesis. *Liver*. 1990; 10:59-63.
146. Takahara O, Nakayama I, Yokoyama S, Moriuchi A, Muta H, Urchida Y. Malignant neurofibroma with glandular differentiation (glandular schwannoma). *Acta Pathol Jpn*. 1979; 29:597-606.
147. Tannenbaum M. Ultrastructural pathology of human renal cell tumours. *Pathol Ann*. 1971; 6:249-277.
148. Thoenes W, Stoerker S, Rumpelt HJ. Histopathology and classification of renal cell tumours (adenomas, oncocytomas and carcinomas). The basic cytological and histological elements and their use for diagnostics. *Pathol Res Pract*. 1986; 181:125-143.
149. Tricoli JV, Rall LB, Karakousis CP, et al. Enhanced levels of insulin-like growth factor messenger RNA in human colon carcinomas and liposarcomas. *Cancer Res*. 1986; 46:6169-6173.
150. Tsokos M, Kouraklis G, Chandra RS, Bhagavan BS, Triche TJ. Malignant rhabdoid tumour of the kidney and soft tissues. Evidence for a diverse morphological and immunocytochemical phenotype. *Arch Pathol Lab Med*. 1989; 113:115-120.
151. Tsuneyoshi M, Daimaru Y, Hashimoto H, Enjoji M. Malignant soft tissue neoplasms with the histological features of renal rhabdoid tumours. *Human Pathol*. 1985; 16:1235-1242.
152. Tsuneyoshi M, Daimaru Y, Hashimoto H, Enjoji M. The existence of rhabdoid cells in specified soft tissue sarcomas. *Virshows Archiv A*. 1987; 411:509-514.
153. Ulbright TM, Brokaw SA, Stehman FB, Roth LM. Epithelioid sarcoma of the vulva. Evidence suggesting a more aggressive behaviour than extra-genital epithelioid sarcoma. *Cancer*. 1983; 52:1462-1469.
154. Uri AK, Witzleben CL, Raney RB. Electron microscopy of glandular schwannoma. *Cancer*. 1984; 53:493-497.

155. Van Eyken P, Sciote R, Callea F, Van Der Steen K, Moerman P, Desmet VJ. The development of the intrahepatic bile ducts in man: a keratin-immunohistochemical study. *Hepatology*. 1988; 6:1586-1595.
156. Variend S, Spicer RD, Mackinnon AE. Teratoid Wilms tumour. *Cancer*. 1984; 53:1936.
157. Vogel AM, Gown AM, Caughlan J, Haas J, Beckwith JB. Rhabdoid tumours of the kidney contain mesenchymal specific and epithelial specific intermediate filament proteins. *Lab Invest*. 1984; 50:232-238.
158. Waldbaur H, Gottschaldt M, Schmidt H, et al. Medulloblastom des Kleinhirns und Pineoblastom bei eineiigen Zwillingen. *Klin Paediatr*, 1976. 188:366.
159. Walford N, Deferrari R, Slater RM, et al. Intra-orbital rhabdoid tumour following bilateral retinoblastoma. *Histopathology*. 1992; 20:170-173.
160. Weeks DA, Beckwith JB, Mierau GW, Luckey DW. Rhabdoid tumour of the kidney. A report of 111 cases from the National Wilms tumour Study Pathology Center. *Am J Surg Pathol* 1989; 13:439-458.
161. Weeks DA, Beckwith JB, Mierau GW, Zuppan CW. Renal neoplasms mimicking rhabdoid tumour of kidney. A report from the National Wilms Tumour Study Pathology Center. *Am J Surg Pathol* 1991; 15: 1042-1054.
162. Wick MR, Cherwitz DL, McGlennen RC, Dehner LP. Adreno-cortical carcinoma. An immunohistochemical comparison with renal cell carcinoma. *Am J Pathol* 1986; 122:343-352.
163. Wigger HJ. Foetal rhabdomyomatous nephroblastoma: a variant of Wilms tumour. *Hum Pathol* 1976; 7:613-623.
164. Wigger HJ. Foetal mesenchymal hamartoma of kidney. A tumour of secondary mesenchyme. *Cancer*. 1975; 36:1002-1008.
165. Wilander E, Westermark P, Grimelius L. Intracellular and extracellular fibrillar structures in gastro-duodenal endocrine tumours. *Ultrastruct Pathol*. 1980; 1:49-54.
166. Willis RA. *The borderland of embryology and pathology*. London. Butterworth and Co. 1958.
167. Woodruff JM. Peripheral nerve tumours showing glandular differentiation (glandular schwannomas). *Cancer* 1976; 37:2399-2413.
168. Yates AJ, Becker LE, Sachs LA. Brain tumours in childhood. *Childs brain*. 1979; 5:31.

Reference added proof:

Parham, DM, Weeks DA, and Beckwith JB. The clinicopathologic spectrum of putative extra-renal rhabdoid tumours. *Am J Surg Pathol*. 1994; 18(10):1010-1029.