

Bone Stress Injuries in the Lower Back of Cricket Fast Bowlers.

**A dissertation prepared by HELEN MILLSON SMTHEL007
in partial fulfillment of the requirements for the Master of
Philosophy degree in Sports Physiotherapy (MPhil Sports
Physiotherapy) from the University of Cape Town**

November 2003

The copyright of this thesis vests in the author. No quotation from it or information derived from it is to be published without full acknowledgement of the source. The thesis is to be used for private study or non-commercial research purposes only.

Published by the University of Cape Town (UCT) in terms of the non-exclusive license granted to UCT by the author.

Declaration

I, Helen Millson hereby declare that the work on which this dissertation is based is my original work (except where acknowledgements indicate otherwise) and that neither the whole work nor any part of it has been, is being, or is to be submitted for another degree in this or any other university.

No part of this dissertation may be reproduced, stored in a retrieval system, or transmitted in any form or means without prior permission in writing from the author or the University of Cape Town.

.....

(Signature)

.....

(Date)

Acknowledgements

- Professor Mike Lambert for his encouragement, kindness and patience.
- Janine Gray for her willing guidance.
- Dr. Richard de Villiers for his valuable input.
- Dr. Phil Pretorius for his input in the radiological section
- My children for their warm encouragement and support.

Table of contents

	Page
Declaration	2
Acknowledgements	3
Table of contents	4
List of Tables	5
List of Figures	6
Abbreviations	7
Abstract	8
Chapter 1: Introduction and scope of the thesis	11
Chapter 2: Bone stress injuries in the lower back of cricket fast bowlers	15
Chapter 3: Dissociation between pain and bone stress reaction as measured by CT scan in young cricket fast bowlers	52
Chapter 4: Summary and conclusion	79
References	86
Appendices	100

List of Tables

	Page
Table 1 A summary of the advantages and disadvantages of Xray, BS, SPECT, CT scan and MRI in detecting bone stress injuries... ..	31
Table 2 Summary of the 10 subjects	78
Table 3 Guidelines for radiological investigation of fast bowlers with possible bone stress injury.....	85

List of Figures

	Page
Fig 1. Subject 1: CT scan of a 17-year-old right arm bowler.....	68
Fig 2. Subject 2: CT scan of a 15-year-old right arm bowler.....	69
Fig 3. Subject 3: CT scan of a 22-year-old right arm bowler.....	70
Fig 4. Subject 4: CT scan of an 18-year-old right arm bowler.....	71
Fig 5. Subject 5: CT scan of a 21-year-old right arm bowler.....	72
Fig 6. Subject 6: CT scan of a 15-year-old right arm bowler.....	73
Fig 7. Subject 7: CT scan of a 21-year-old right arm bowler.....	74
Fig 8. Subject 8: CT scan of a 22-year-old right arm bowler.....	75
Fig 9. Subject 9: CT scan of a 19-year-old left arm bowler.....	76
Fig 10. Subject 10: CT scan of a 17-year-old right arm bowler.....	77
Fig 11. Low Back Pain in cricket fast bowlers: Radiological investigation.....	84

List of abbreviations

BS (Bone scintigraphy)

CT (Computed tomography)

PBS (Planar bone scintigraphy)

SPECT (Single photon emission computed tomography)

MRI (Magnetic resonance imaging)

VAS (Visual analogue scale)

ABSTRACT

Background: The lower back of the cricket fast bowler presents the clinician with a multitude of problems. Firstly, there is the difficulty of distinguishing the symptomatic spondylolysis or bone stress reaction from other causes of lower back pain. Of particular difficulty is establishing whether or not the symptoms of pain are associated with the bone stress reaction. Secondly, there is confusion surrounding the fast bowler's return to full participation in fast bowling following an injury of this nature. Few studies have addressed sensitivity and specificity of imaging for diagnosis, and follow-up assessment has been poorly investigated. **Objective:** The primary aim of this thesis was to evaluate the literature investigating lower back pain in fast bowlers, as well as the appropriate assessment and management strategies. The secondary aim was to determine whether there was an association between pain and bone stress reaction as measured by Computed Tomography (CT) scan in young cricket fast bowlers. **Methods:** (i) Computerized bibliographic databases (MEDLINE, CINAHL, AMED) were searched without language restrictions from the earliest date to September 2003 using a combination of keywords and MEDLINE subject headings. Communication via e-mail with authors of studies dealing with spondylolysis in the cricket bowler's lower back was also undertaken. A review of the literature regarding bone stress reaction in the cricketer bowler's lower back was discussed in chapter 2. (ii) Ten young cricket fast bowlers were included in the experimental phase of the study. Nine of these bowlers presented to a physiotherapy practice with low back pain and were later diagnosed with lumbar stress fractures. The remaining subject was an experienced bowler with no lower back pain. The provisional diagnosis was made based on the subjective and objective clinical assessment. All players had a CT scan after

presenting to the physiotherapy practice. Pain was assessed according to a subjective scale (0-10) where 10 represented the player's subjective, maximum pain score. The recovery and rehabilitation of the players was then monitored until they returned to full participation. **Results:** (i) One of the main findings of the literature review was the lack of scientific evidence supporting a specific association between spondylolysis, radiological investigation, pain and clinical symptoms. Therefore, management strategies are not clearly indicated and there are no objective, evidence-based measures regarding return to bowling. (ii) The first important finding of this study was that there was a dissociation between pain and spondylolysis or pars interarticularis (PI) defect as measured by CT scan. There was no pain or minimal pain in many of the subjects (e.g. Subject 2, 3, 5, 8, 10) even in the presence of PI defects (with or without union) in the spine. Another important finding in this study was the relevance of non-bony union (i.e. fibrous union) of the stress fracture of the posterior elements of the lumbar spine. For example, there was pseudo-joint and osteophyte formation in subject 3 which may be interpreted as the body adapting to the extreme ranges of movement required by these spinal joints during the cricket bowling action. This may be advantageous to the bowler in terms of future mechanical pressure on those structures.

Conclusion: There is dissociation between pain and bone stress reaction as measured by CT scan. Therefore, CT scan does not provide objective evidence for ongoing management or decision as to return to sport in the fast bowlers. Further studies are needed to determine objective, evidence-based criteria for return to fast bowling after sustaining a bone stress injury of the lower back.

Keywords: spondylolysis, pars interarticularis, radiography, cricket, fast bowling,
lower back pain.

Chapter 1

Introduction and scope of the thesis

Lumbar spondylolysis is a defect or fracture of the pars interarticularis in the neural arch of a vertebra. It is a common structural defect of the spine which affects approximately 4-6% of the general population (Wiltse et al., 1975; Nathan, 1977; Fredrickson et al., 1984; McCarrol et al., 1986; Hensinger and Arbor, 1989).

Younger age groups and the participation in certain sports increases the risk of this condition with the incidence reaching between 23-63% in certain groups of young sportsmen and women (Ferguson et al., 1975; Jackson et al., 1976, 1981; Rossi, 1988; Karpakka et al., 1989; Annear et al., 1992; Elliott et al., 1992; Hardcastle et al., 1992).

The demands of fast bowling in cricket requires hyperextension of the spine, combined with rapid, forceful rotation and side flexion. Back injury represents a serious threat to the fast bowler and the appearance of abnormal radiological features in the lumbar spine is common within the cricketing population (Fitch, 1987; Elliott et al., 1992; Hardcastle et al., 1992). Fast bowlers have an increased risk for the development of a pars defect or spondylolysis of the lumbar spine with the incidence of pars defects in the fast bowling population ranging from 11-58% (Wiltse et al., 1975; Nathan, 1977; Fredrickson et al., 1984; McCarrol et al., 1986; Mackay and Keech, 1988; Hensinger and Arbor, 1989; Foster et al., 1989; Elliott et al., 1992; Elliott, 2000; Hardcastle, 1991, 1993 ; Hardcastle et al., 1992; Annear et al., 1992; Walker et al., 1996).

The studies investigating the aetiology of spondylolysis and spondylolisthesis have been controversial with a number of theories being proposed. The proposed causes may be due to a congenital defect (Wiltse et al., 1957); trauma (Wiltse et al., 1975; Moe et al., 1978; Letts et al., 1986), or it may be as a result of indirect trauma (Letts et al., 1986; Hensinger and Arbor, 1989; Sherman et al., 1977). However, the general agreement is that the lesion spondylolysis is an acquired pseudoarthrosis following a fatigue fracture in patients who have an hereditary predisposition, particularly when the athlete is young and participates in high risk sport (Cyron and Hutton, 1978; Karpakka et al., 1989).

There appears to be no single cause, but rather a combination of factors that may predispose a fast bowler to lower back injury. Whilst a number of studies have attempted to determine the causes of lower back injury in fast bowlers (Payne et al., 1987; Foster et al., 1989; Hardcastle, 1991; Hardcastle et al., 1992), there are a limited number of prospective studies investigating this problem (Foster et al., 1989; Elliott, 2000). Biomechanics of fast bowling, postural considerations, physical maturation and overuse are the main predisposing factors resulting in the back pain in the fast bowler's back (Elliott and Foster, 1984; Payne et al., 1987; Mackay and Keech, 1988; Elliott et al., 1989; Foster et al., 1989; Elliott et al., 1990; Hardcastle, 1991; Annear et al., 1992; Elliott et al., 1992; Vidick, 1987; Whiting and Zernicke, 1998; Elliott, 2000; Cyron and Hutton, 1978; Hardcastle, 1991; Kippers et al., 1998).

Specific pars stress reactions have been defined from a radiological perspective in terms of spondylolisthesis and spondylolysis, pedicle hypertrophy or sclerosis.

These defects may be imaged with plain Xray, bone scintigraphy (BS), including single photo emission computed tomography (SPECT), computed tomography (CT) and magnetic resonance imaging (MRI) (Anderson et al., 1998). Every imaging method has particular strengths and weaknesses and the choice will depend on the provisional diagnosis (Anderson et al., 1998; Moeller, 2001). However, inconsistencies between radiographs and clinical observations have been noted (Jackson et al., 1981; Harvey et al., 1998; Hardcastle, 1992; Guillodo et al, 2000; Moeller, 2001) and frequent detection of structural abnormalities that are real but clinically irrelevant, occurs frequently in the instance of pars interarticularis stress fractures.

The many studies identifying spondylolysis and spondylolisthesis in the lower back of the cricket fast bowler and other sports people have reached different conclusions regarding any direct link between this bony pathology and pain. In many of the studies, symptoms are vaguely described, with no objective pain measurement recorded. The criteria of management has been based mostly on the stage of bony healing and the specific pain intensity is not mentioned. The relationship between healing, pain and management of the bone stress reaction in the pars interarticularis has not been documented (Lisbon et al., 1982; Saraste, 1986; Letts et al., 1986; Morita et al., 1995; Sys et al., 2001).

Many studies have supported different conservative treatments for a pars interarticularis stress fracture (Wiltse and Jackson, 1976; Hensinger and Arbor 1989; Morita et al., 1995; Sys et al., 2001). These include strategies from immobilization with various braces to rehabilitation and surgery (Letts et al., 1986;

Jackson, 1979; Goldberg, 1980; Steiner and Micheli, 1985; Hardcastle, 1991; Gunzburg and Fraser, 1991). However, there is limited evidence to assess the efficacy of any of these interventions in cricketers (Sys et al., 2001).

The return to sport described in the studies varied from no time off (Guillido et al., 2000) to 7.3 months (Jackson et al., 1981). In many instances, union of the bone is the main priority of management with little concern for specific clinical symptoms (Fredrickson et al., 1984).

Thus, the aim of this thesis was firstly, to review the literature on lower back pain, particularly in cricket fast bowlers with the emphasis on assessment and management strategies. The next phase of the thesis was to identify a specific radiographic investigation to demonstrate the status of the bone and to link these findings with the pain experienced by the fast bowler. The overall goal of the thesis was to attempt to provide objective, evidence-based criteria which will assist the clinician in determining when the fast bowler can return to bowling after a bone stress injury of the lower back.

Chapter 2

Bone stress injuries in the lower back of cricket fast bowlers

CONTENTS	Page
1. INTRODUCTION.....	16
2. INCIDENCE OF LUMBAR SPONDYLOLYSIS	
2.1 GENERAL POPULATION.....	17
2.2 OTHER SPORTS.....	18
2.3 CRICKET.....	19
3. AETIOLOGY OF SPONDYLOLYSIS	
3.1 DUE TO A CONGENITAL DEFECT.....	21
3.2 DIRECT TRAUMA CAUSES A STRESS FRACTURE.....	22
3.3 INDIRECT TRAUMA CAUSES A STRESS FRACTURE.....	22
4. PREDISPOSING FACTORS FOR SPONDYLOLYSIS IN CRICKET BOWLERS	
4.1 BIOMECHANICS OF BOWLING.....	24
4.2 POSTURAL CONSIDERATIONS.....	26
4.3 PHYSICAL MATURATION.....	27
4.4 OVERUSE.....	28
4.5 OTHER FACTORS.....	29
4.6 SUMMARY.....	29
5. RADIOLOGICAL ASSESSMENT.....	30
5.1 XRAY.....	32
5.2 BONE SCINTIGRAPHY (BS) WITH SINGLE PHOTO EMISSION COMPUTED TOMOGRAPHY (SPECT).....	33
5.3 COMPUTED TOMOGRAPHY (CT SCAN)	36
5.4 MAGNETIC RESONANCE IMAGING (MRI).....	38
5.5 CONCLUSION OF RADIOLOGICAL INVESTIGATION.....	40
6. PAIN	
6.1 GENERAL.....	41
6.2 CRICKET.....	42
6.3 OTHER CAUSES OF PAIN.....	43
6.4 SUMMARY OF PAIN.....	45
7. MANAGEMENT.....	45
8. CONCLUSION.....	50

1. INTRODUCTION

The objective criteria for bone stress reaction in the lumbar spine of cricket fast bowlers is poorly understood, particularly when trying to relate these criteria to clinical symptoms. Firstly, the causes of the back pain may be unrelated to the spondylolysis or bone stress reaction. The source of the pain may arise from other structures such as a facet joint. Secondly, the criteria regarding the bowlers return to full participation in fast bowling after sustaining a vertebral bone stress reaction is not clear. The studies investigating the aetiology of spondylolysis and spondylolisthesis have been controversial. The proposed theories have ranged from congenital anomalies, acquired defects, to defects in cartilaginous development. The most widely accepted theory is that of a fatigue fracture caused by recurrent mechanical stress. Other aetiological factors that have been proposed for acute fractures include osteoporosis, bone pathology or traumatic origin (Wiltse, 1962; Saha et al., 1970; Wiltse et al., 1975; Sherman et al., 1977; Cyron and Hutton, 1978; Porter and Park, 1982; Fredrickson et al., 1984; Letts et al., 1986; Rossi, 1988).

Studies investigating fast bowling, biomechanics and lower back pain were first published approximately 5 decades ago (Rowe and Roche, 1953). Further studies have attempted to explain the aetiology of this common injury in cricketers. The combination of rotation, hyperextension and side flexion during fast bowling, combined with overbowling, represents significant risk factors for stress fractures in the cricketer's lower back (Payne et al., 1987; Foster et al., 1989; Finch et al., 1999; Elliott, 2000). However, there are no studies that provide conclusive

evidence to guide the practitioner or coach on the treatment of a cricket fast bowler who has been diagnosed with a bone stress reaction of the lower back. The aim of this review is to examine the existing literature on lower back injuries associated with fast bowling, with particular reference to the relationship between the imaging of the bone stress reaction in the posterior elements of the spine and pain in the fast bowler's lower back. A further aim is to investigate the management of this injury with particular focus on the return to fast bowling following injury.

2. INCIDENCE OF LUMBAR SPONDYLOLYSIS

2.1 GENERAL POPULATION

Lumbar spondylolysis is a defect or fracture of the pars interarticularis in the neural arch of the vertebra. It is a common structural defect of the spine which affects approximately 4-6% of the general population (McCarrol et al., 1986; Nathan, 1977; Wiltse et al., 1975; Fredrickson et al., 1984; Hensinger and Arbor, 1989). Although some studies have suggested that spondylolysis is not of congenital origin, other studies have reported congenital anomalies in 5-10% of the normal population (Rowe and Roche, 1953; Wynne Davies and Scott, 1979; and Hensinger, 1983). Further longitudinal studies should be undertaken in order to clarify this issue. A varying incidence of spondylolysis in certain families and race groups has been demonstrated (Rowe and Roche, 1953; Saha et al., 1970; Wiltse et al., 1975). The incidence of spondylolysis ranges from 1% in black women (Hensinger, 1983) to 54% in Eskimo tribes (Stewart, 1953; Simper, 1986). Younger age groups and the participation in certain sports increases the risk of this condition with the incidence reaching between 23-63% in certain groups of young

sportsmen and women (Ferguson et al., 1975; Jackson et al., 1976, 1981; Rossi, 1988; Karpakka et al., 1989; Annear et al., 1992; Elliott et al., 1992; Hardcastle et al., 1992).

2.2 OTHER SPORTS.

The incidence of lumbar pain in the young athletic population is reported to range from 15% - 85% (Ferguson et al., 1975; Jackson et al., 1976; Rossi, 1988; Semen and Spengler, 1981; McCarroll et al., 1986; Commandre et al., 1988; Blackbourne, 1989; Rossi and Dragoni, 1990, 2001; Sward et al., 1990; Sward, 1992; Morita et al., 1995; Micheli and Wood, 1995). Connelly et al., (2001) bring up the issue of imaging of suspected spondylolysis in the young athletic patients and state that spondylolysis is more commonly seen in younger athletic patients than older ones. Halvorsen et al., (1996) showed that the frequency of spondylolysis is higher among sports participants who perform movements involving repeated flexion and extension of the spine. Gymnastics is a sport which involves repetitive hyperextension combined with rotation and lateral flexion movements. Gymnasts have an incidence of spondylolysis ranging from 5 – 20% (Micheli, 1985; Ciullo and Jackson, 1985; Soler and Calderon, 2000). Jackson et al., (1976) reported 5% spondylolysis and 6% spondylolisthesis in a study of 100 female gymnasts as detected by a lumbo-sacral roentgenographic series, including antero-posterior, standing lateral and oblique views. As a negative plain radiographic investigation does not completely rule out a developing pars defect, Jackson et al., (1976) advises that bone scintigraphy should be used as an additional tool for evaluating early stress reactions in the pars interarticularis. Other sports demonstrating a higher incidence of spondylolysis and low back pain compared to that in the normal population, include wrestling (59%) (Granhed and Morelli, 1988), weight lifting

(Granhed and Morelli., 1988; Soler and Calderon, 2000) and sports that involve lumbar torsion against resistance, such as rowing (Serge et al., 1989). In a study of 7 elite boardsailors complaining of low back pain, investigations were undertaken with plain Xrays and CT scans. Five of the subjects demonstrated intervertebral disc changes and two had pars interarticularis defects. The results demonstrated that the frequency of the low back pain in this group of boardsailors exceeded that of the normal population (Locke and Allen, 1992). However, this study was limited by its sample size.

2.3 CRICKET

The demands of fast bowling in cricket requires hyperextension of the spine, combined with rapid, forceful rotation and side flexion. Back injury represents a serious threat to the fast bowler and the appearance of abnormal radiological features in the lumbar spine is common within the cricketing population (Fitch, 1987; Elliott et al., 1991; Hardcastle, 1991 check these). Fast bowlers have an increased risk for the development of a pars defect or spondylolysis of the lumbar spine (Mackay and Keech, 1988; Resnick et al., 1988; Foster et al., 1989; Hardcastle et al., 1992, 1995; Elliott et al., 1992; Harvey et al., 1998; Elliott, 2000). Elliott et al., (1992) found a 55% incidence of radiological abnormalities of the lumbar spine in a group of competitive young fast bowlers (n=20). A prospective study by Hardcastle et al., (1992) of the West Australian under-19 fast bowling squad demonstrated an incidence of pars defects and spondylolisthesis of 58% and 19% respectively. In a group of A-grade fast bowlers (n=12) who were studied over a 5 year period, spondylolysis occurred in 50% of the bowlers (Payne et al., 1987). This was higher than the 45% incidence of bony abnormalities reported for

retired elite fast bowlers (Annear et al., 1992). Further studies have demonstrated an incidence of pars interarticularis defects of 11% (Foster et al., 1989), 14% (Walker et al., 1996) and 20% (Mackay and Keech, 1988) respectively. Other studies have shown that the rate of bony abnormalities in fast bowlers is approximately 10 times higher than the incidence in the male Caucasian population (Wiltse et al., 1975; McCarrol et al., 1986; Nathan, 1977; Fredrickson et al., 1984; Hensinger and Arbor, 1989; Hardcastle, 1991; Elliott et al., 1992).

In summary, the incidence of pars defects in the fast bowling population range from 11-58%. This variation may be attributed to study design, radiological interpretation and the mode of investigation. Many of the studies have been retrospective and the mode of investigation has not been consistent across the studies. The radiological investigations include Xrays, bone scintigraphy, CT scans or MRI. Due to the different sensitivities of these modalities, the reporting of incidence can be inconsistent. Some of the pars defects were reported as stress fractures only, whilst others included sclerosis of the pars interarticularis. In limited cases, records were made about the lesion being symptomatic or asymptomatic and whether the bone stress reaction was a developing lesion or healing reaction/fracture. The relatively high incidence of bone stress reaction in the cricket fast bowler's lower back, demonstrates the high risk associated with fast bowling. The interpretation of these results in terms of clinical significance remains poorly investigated. Thus, although the incidence of pars defects is elevated in the fast bowling population, information regarding an association between abnormal radiological features of the lumbar spine and fast bowling has been largely based on cross sectional prevalence surveys. Further prospective studies are required.

3. AETIOLOGY OF SPONDYLOLYSIS

The aetiology of spondylolysis has been debated and a number of theories have been proposed.

3.1 DUE TO A CONGENITAL DEFECT

Although spondylolysis and spondylolisthesis have been referred to as congenital anomalies of the spine, there is no supporting embryological or anatomical evidence for this assumption, resulting in numerous conflicting opinions. It has been theorized that the defect in the pars resulted from dissolution of continuity of the bone because of a congenital weakness at the pars interarticularis (Wiltse, 1957). Further, it was stated that this genetically determined defect was expressed differently, resulting in different pathologies being presented.

The lesion is identified at the age of seven or eight years old, after which the incidence of spondylolysis increases until the age of 20 years when it remains constant (Wiltse et al., 1976). Cyron and Hutton (1979) stated that the fundamental lesion of spondylolisthesis was familial. Further, they postulated that the defect in the pars was caused firstly, by an hereditary defect or dysplasia most likely in the cartilage model of the arch of the affected vertebra and secondly, the strain on the pars in the lower lumbar spine, consequent to the erect stance and lumbar lordosis characteristic to man. Corrigan (1984) states that spondylolysis is unlikely to be a congenital disorder because the ossification centres in the vertebral body and neural arch do not correspond to the site of the defect. Rather, an inherent weakness in the pars was a more likely explanation.

3.2 DIRECT TRAUMA CAUSES A STRESS FRACTURE

Spondylolysis and spondylolisthesis may in some cases be caused by trauma (Wiltse et al., 1975; Moe et al., 1978; Letts et al., 1986). However, although there may be a history of minor trauma that may initiate the symptoms, there is seldom a history of significant injury (Hensinger and Arbor, 1989). The strength and stiffness of the neural arch tends to preclude this in favour of mechanical fatigue as the mode of failure (Cyron and Hutton, 1978). This interpretation concurred with Sherman et al., (1977), who suggested that spondylolysis was a physiological response to the stress of repeated trauma in the presence of an unstable neural arch. Mostly, the symptoms coincide with the adolescent growth spurt and repetitive mechanical stress (Laurent and Emola, 1961; Rossi, 1988).

3.3 INDIRECT TRAUMA CAUSES A STRESS FRACTURE

Spondylolysis differs from stress fractures in other parts of the body in that pars interarticularis lesions do not show periosteal new bone formation, and there is a higher potential for fibrous union (Fredrickson et al., 1984). Wiltse et al., (1975) proposed that spondylolysis is a defect in the pars interarticularis, secondary to a chronic low grade trauma from repetitive spinal hyperextension and rotation. The existence of a unilateral spondylolysis has been presented in a study by Porter and Park (1982) in which the controversy surrounding the dilemma of whether the defects are congenital or traumatic is explored. The observations from the case studies suggest that the unilateral spondylolysis is associated with localized underdevelopment or hypoplasia of adjacent structures and it is probable that the effect occurred before skeletal maturity was complete. This questions the concept

of spondylolysis occurring as a result of a fatigue fracture only. There is growing evidence that the repetitive microtrauma and the resultant fatigue fracture at the site may be an important contributor to the aetiology of spondylolysis and isthmic spondylolisthesis (Rossi, 1988). This theory is further supported by the “unusual” occurrence of reactive sclerosis and hypertrophy of the pedicle and lamina on the contralateral side to the spondylolysis in the same vertebral segment (Letts et al., 1986; Sherman et al., 1977). This is believed to be a physiological response to the stress of repeated trauma in the presence of an unstable neural arch. Two types of lesions have been described; a spondylolytic lesion due to an acute stress fracture of the pars, and a dysplastic or elongated lesion representing a chronic stress reaction with gradual attenuation of the pars (Hensinger and Arbor, 1989). The latter pathology seems the most likely in the back of the cricket fast bowler, due to the physical demands of bowling and the resultant mechanical stress on the lower back.

There is general agreement that the lesion spondylolysis is an acquired pseudoarthrosis following a fatigue fracture in patients who have an hereditary predisposition (Karpakka et al., 1989). Thus there may be some genetic factors which predispose an individual to develop the defect, particularly when the athlete is young and participates in high risk sport (Cyron and Hutton, 1978).

4. PREDISPOSING FACTORS FOR SPONDYLOLYSIS IN CRICKET BOWLERS.

Whilst a number of studies have attempted to determine the causes of lower back injury in fast bowlers (Payne et al., 1987; Foster et al., 1989; Hardcastle, 1991; Hardcastle et al., 1992), there are a limited number of prospective studies investigating this problem (Foster et al., 1989; Elliott et al., 1992; Elliott, 2000). There appears to be no single cause, but rather a combination of factors that may predispose a fast bowler to lower back injury. These factors will be discussed under the following headings; biomechanics of bowling, postural considerations, physical maturation and overuse.

4.1 BIOMECHANICS OF BOWLING

The combination of rotation, hyperextension and side flexion during fast bowling is a risk factor for stress fractures. Hardcastle et al., (1992) stated that the unilateral defects of pars interarticularis occur on the opposite side of the lumbar spine to the bowling arm in over 80% of cases. This would suggest that the cause of the unilateral defects is not hyperextension alone, as hyperextension is maximal on the same side as the bowling arm. Hyperextension, however, may be responsible for the bilateral defects and for the presence of spondylolisthesis. Incorrect bowling technique has been identified as a risk factor for stress fractures. Three main actions of fast bowling have been described. Namely, front-on, side-on or a mixed action which is a combination of these two actions. It has been hypothesised that the mixed action causes increased counter-rotation in the lumbar spine and therefore increases the risk of stress fractures of the pars interarticularis (Elliott

and Foster, 1984; Payne et al., 1987; Mackay and Keech, 1988; Elliott et al., 1989; Foster et al., 1989; Elliott et al., 1990; Hardcastle, 1991; Annear et al., 1992; Elliott et al., 1992). The mixed action is defined as a shoulder alignment of greater than 190 degrees, any foot placement, and a counter-rotation of the shoulder of greater than 10 degrees (Elliott et al., 1992). The mixed action technique is characterized by bowlers adopting a front-on foot and shoulder orientation at back-foot impact, which is then followed by a re-alignment of the shoulders to a more side-on position during the delivery stride. This causes a counter-rotation in the lumbar spine which has been associated with an increased risk of stress fractures of the pars interarticularis and disc degeneration. As a result of this excessive movement in the lower lumbar spine, the 5th lumbar vertebra (particularly the neural arch) is more vulnerable to stress fractures because of the abrupt change in direction of movement between the spinal column and the pelvis (Cyron and Hutton, 1978; Foster et al., 1989).

Fast bowling is a high impact activity with ground reaction forces approximately 2 to 5 times the body weight occurring at rear foot and front foot impact respectively during the delivery stride (Elliott et al., 1984; Elliott et al., 1986; Mason et al., 1989; Elliott, 2000). These forces are absorbed throughout the body and may place the lower back at risk for injury. A greater height of ball release has been shown to predispose a bowler to lumbar spine bony abnormalities (Foster et al., 1989).

The evidence of the studies thus far, shows that the biomechanics of fast bowling may predispose the fast bowler to a bone stress reaction in the lower back. Elliott and Khangure (2002) have conducted an intervention study which assessed this

association. The intervention included small group coaching which resulted in significantly reduced shoulder counter-rotation. This was coupled with a decrease in the incidence and progression of lumbar disc degeneration. Additional studies are needed to further analyse the biomechanics of the fast bowling action and its association with lumbar pathology.

4.2 POSTURAL CONSIDERATIONS

Fast bowlers with a low foot arch are more likely to develop a stress fracture in the lumbar vertebrae (Elliott, 2000). A foot with a low arch is not able to dissipate force as effectively as a higher arch, with its better visco-elastic potential (Vidick, 1987; Whiting and Zernicke, 1988). A prospective study found that a low medial longitudinal arch of the foot was a variable that significantly differentiated injured (stress fractures and muscle) from injury-free fast bowlers (Foster, 1989).

Players with poor hamstring or lower back flexibility have been identified as being at greater risk for developing spondylolysis or spondylolisthesis (Hensing and Arbor, 1989; Elliott et al., 1992; Moreland, 1994). However, another study showed that there was no significant correlation between hamstring tightness, low back pain, and the radiographic evidence of pars defects (Albanse and Pizzutillo, 1982). Anecdotal reports have placed emphasis on low back pain and tight hamstring muscles. Further studies are required to verify this factor.

Troup (1976) stated that poor posture with consequential increased lumbar lordosis increases the shear forces on the vertebrae. These forces are concentrated on the pars interarticularis, which may contribute to stress fractures

of these posterior elements of the lumbar spine. An increased lumbar lordosis in fast bowlers has been associated with an increase in abnormal radiological findings in the lumbar spine (Ogilvie and Sherman, 1987). In this study, 8 out of 10 bowlers who displayed a marked level of lumbar lordosis showed abnormal radiologic features (six bony abnormalities and 2 disc abnormalities). The combination of lumbar lordosis and relatively restricted hip extension places strain on the pars interarticularis (Corrigan, 1984). Further, it was found that the lower lumbar vertebrae joints demonstrated increased hypomobility over the off-season and that stiff joints at particular interval levels may place extra stress on existing hypermobile joints at other levels and thus increase the risk of injury (Mackay and Keech, 1988). This interpretation was re-affirmed by Foster et al., (1989) who stated that decreased flexibility in the low back region could increase the risk of lower back injury. Although studies have shown an association between hamstring and lower back flexibility and an exaggerated lumbar lordosis and lower back pain, a prospective study needs to be undertaken to confirm this association and determine a cause and effect relationship.

4.3 PHYSICAL MATURATION

There is a high incidence of stress fractures in young, cricket fast bowlers. This may be in part due to an immature skeleton (Hardcastle, 1991). Ground reaction forces and the strenuous activity of bowling further predisposes the youth to this injury. Cyron and Hutton, (1978) found that young people are more likely to develop spondylolysis since they frequently engage in strenuous activities at a time when their intervertebral discs may be less resistant to shear forces and the neural arch has not reached its maximum strength. In a study of West Australian U19 fast

bowlers, it was found that the young bowlers were especially prone to overuse as their musculo-skeletal systems are still immature and the pars inter articularis is not as strong as it would be in the over 20 year age group (Hardcastle, 1991). This conclusion is based on incidence findings and a limitation of the study is that there is no measure of the skeletal maturity found in the population group. A number of studies postulate that the immature skeleton of the young fast bowler, combined with the excessive ground reaction forces at front foot strike, may predispose the young cricket bowler to bone stress reaction (Cyron and Hutton, 1978; Hardcastle, 1991; Kippers et al., 1998).

Most of the studies make conclusions based on the high incidence of bone stress reaction in young fast bowlers. However, a practical consequence of these findings might be to implement bowling programmes for young fast bowlers which minimizes the number of overs bowled per season. Many countries are currently doing this.

4.4 OVERUSE

Elliott et al., (1992) hypothesised that over-bowling may be a major factor predisposing the cricketer to low back problems. In a study by Dennis et al., (2003), the bowling workload and the risk of injury in elite cricket fast bowlers was investigated. It was concluded that there appears to be a fast bowling workload threshold beyond which the risk of injury increases. However, maintaining a workload that is too low or infrequent is an equally significant risk factor for injury.

The fast bowling action involves large repetitive forces to the lumbar spine, taking place as often as 300-500 times each week (Payne et al., 1987). A prospective study of 82 young fast bowlers showed a relationship between overbowling and an increase in lower back injuries (Foster et al., 1989). These bowlers were tested immediately prior to the season for selected kinanthropometric and physiological data. They were tested with cinematography and a force platform, as well as being advised to keep a log book over the ensuing season that detailed their training and playing programmes. All cricket related injuries sustained over this season were assessed by a sports physician who used Computed Tomography scan to assist in the diagnosis of spinal injuries. Thereafter the bowlers were grouped according to their injury status. They reported that of the 32 subjects who bowled more than the mean number of 17 games over a season, 19 sustained a stress fracture or muscle injury to the back. Of the 41 subjects who reported bowling in excess of 10 overs in a spell during the season (mean for the group = 8.5 overs), 27 reported lower back pain the following day.

In summary, the cricket season is long, with many practices and matches and consequently many overs being bowled. This may be highly significant during the adolescent growth spurt when the immature musculo skeletal system is most vulnerable. Further studies investigating the relationship between overuse and an increase in back injuries need to be undertaken.

4.5 OTHER FACTORS

Although a hard surface and hard cricket boots may further compound the problem, there is little research in this field. It may be argued that lower extremity

strength may be of benefit to counteract these factors, but no research exists to support or negate this factor. Poor physical preparation, decreased flexibility of the entire kinetic chain, decreased pelvic stabilisation and other factors such as divets in the field may further increase the risk for developing stress fractures in the spine (Foster et al., 1989; Elliott et al., 1992). Furthermore, other sports in which the fast bowler participates and the off-season physical activities have to be taken into consideration when attempting to assess the potential for the development of stress fractures in the cricketer bowler's back.

4.6 SUMMARY

Although there are many predisposing factors which could lead to a stress fracture in the cricketer's lumbar spine, it is often a combination of factors that ultimately cause the problem. The appearance of abnormal radiological features have not been linked to a single cause in any one of the studies. Many theories on the mechanism of stress fractures in cricket bowler's back have been hypothesized. However, more prospective cohort studies are required to accurately identify risk factors associated with lower back injuries.

5. RADIOLOGICAL ASSESSMENT

Specific pars stress reactions have been defined from a radiological perspective in terms of spondylolisthesis and spondylolysis, pedicle hypertrophy or sclerosis.

Based on radiographic findings, lesions have been classified as early, progressive or terminal (Morita et al., 1995). It is important to distinguish the difference between the acute bone stress reaction and the chronic lesion when diagnosing a

Table 1. A summary of the advantages and disadvantages of X-ray, BS, SPECT, CT scan and MRI in detecting bone stress injuries.

IMAGING	PRO	CON	REFERENCE
X-ray	<ul style="list-style-type: none"> • Able to observe: <ul style="list-style-type: none"> • Good basic bone reaction. • Bone degeneration. • Asymmetry. • Screen other conditions. 	<ul style="list-style-type: none"> • Stress reaction of posterior elements may be visible on an oblique only after 3 weeks. 	Prather et al., 1977; Lisbon et al., 1982; 1984; Amato et al., 1984; Hensinger, 1989; Anderson, 1998; Harvey et al., 1998; Moeller et al., 2001
Bone Scintigraphy (BS) and Single Photo Emission Computed Tomography (SPECT)	<ul style="list-style-type: none"> • BS shows recent trauma or early stress reaction in the pars interarticularis. • Extreme sensitivity in detecting abnormalities of bone blood flow or metabolic activity. • SPECT more sensitive than BS and better able to localize abnormalities. 	<ul style="list-style-type: none"> • Both techniques are relatively non-specific for identifying the exact status of the bone stress reaction. • Will remain sensitive long after patient's symptoms have subsided. 	Micheli et al., 1979; Penning et al., 1980; Jackson et al., 1981; Resnick et al., 1981; Lowe et al., 1984; Papanicolaou et al., 1985; Collier et al., 1985; Letts et al., 1986; Yochum and Rowe, 1987; Van den Oever et al., 1987; Elliott et al., 1988; Hensinger and Arbor, 1989; Raby and Matthews, 1993; Lusin et al., 1994; Itoh et al., 1996; Anderson, 1998; Harvey et al., 1998; Dutton et al., 2000; Moeller et al., 2001
Computed Tomography (CT Scan)	<ul style="list-style-type: none"> • Assess bony configuration and structure. • Shows cortical bone status. 	<ul style="list-style-type: none"> • Not sensitive to oedema / metabolic activity unless pathological. • High radiation dose 	McPhee and Yan, 1982; Rothman, 1986; Hardcastle et al., 1992; Annear et al., 1992; Congeni et al., 1997; Anderson, 1998; Harvey et al., 1998; Moeller et al., 2001
Magnetic Resonance Imaging (MRI)	<ul style="list-style-type: none"> • Identifying underlying predisposing pathological conditions. • Extremely sensitive to oedema released into medullary cavity i.e. bone bruising. • Imparts no ionizing radiation to the patient. 	<ul style="list-style-type: none"> • Costly • Less accurate definition of cortical bone (subtle lesion in posterior bony element may be missed). 	Anderson, 1998; Wirtz et al., 1999; Stabler et al., 2000; Moeller et al., 2001; Udeshi and Reeves, 1999; Saifuddin and Burnett, 1997; Hollenburg et al., 2002

spondylolysis or bone stress reaction of the pars interarticularis of the lumbar spine. This may give more accurate information on the source of pain and the time to return to activity. These defects may be imaged with plain Xray, bone scintigraphy (BS), including single photo emission computed tomography (SPECT), computed tomography (CT) and magnetic resonance imaging (MRI). Table 1 provides a summary of the advantages and disadvantages of the different radiological investigations in detecting a bone stress reaction in the lower back.

5.1 XRAY

Xrays have frequently been used to assess the status of back pain regarding any bone stress reaction (Prather et al., 1977; Lisbon et al., 1982, 1984; Amato et al., 1984; Hensinger and Arbor, 1989; Anderson, 1998; Harvey et al., 1998; Moeller, 2001). Plain radiographic projections of particular value include the coned lateral view of the lumbosacral junction, which displays the majority of defects, and the anteroposterior view with 30 degree cranial angulation (Harvey et al., 1998). The benefits of using Xrays include screening for other pathologies, to demonstrate obvious pars interarticularis abnormalities, and to assess for spondylolisthesis. However, plain radiography of the pars is difficult due to the positioning of the pars interarticularis (Anderson, 1998). Various positioning for accuracy has been described. If the defect is large, it can be seen on nearly all radiographs of the lumbar spine. If the lesion is unilateral, as it is in 20-25% of patients, it can be a very subtle finding that can be identified only by special radiographic techniques (Lisbon et al., 1982, 1984). Oblique radiographs of the lumbar spine have been proposed as the prescribed view to accurately visualize the posterior elements of the lumbar spine (Lisbon et al., 1982, 1984; Amato et al., 1984; Yochum and

Rowe, 1987). However, the value of oblique radiography has been questioned and it was proposed that a 30 degree angle is better than 45 degree angle for the detection or exclusion of a pars defect. Further, stress reactions that have not progressed to complete defects will be radiologically occult (Harvey et al., 1998). Bilateral oblique positioning was advocated for easier visualisation of the pars interarticularis (Moeller, 2001). The study of Hensinger and Arbor (1989) demonstrates that a patient with an acute injury, has a gap of the so called "Scotty sign of Lachapele" which is narrow and has irregular edges. In patients with a long-standing lesions, the edges are smooth and rounded, suggesting a pseudarthrosis. This information could be important in terms of identifying the status of the spondylolysis. Prather et al, (1977) showed that microfractures would occur with continued stress, and a true fracture line with endosteal callus formation may not be seen on the Xray until the third week of the injury. The presence of a pars lesion is not diagnostic of an active lesion (Moeller, 2001). Additional tests are required to determine the metabolic activity of the bony spine in order to confirm the diagnosis. Further, the genetic proponent of a pars defect must be considered.

In summary, the literature shows that an Xray has definite value as a first line investigation in a painful lumbar spine with suspected stress fracture. This investigation technique is most important for excluding other pathologies. However, as endosteal callus formation may only be seen on the third week, a potential stress fracture may be missed, limiting the use of Xrays for this condition. If a spondylolysis is found on Xray, further investigation is necessary to determine the exact status of the bone stress reaction.

5.2 BONE SCINTIGRAPHY (BS) WITH SINGLE PHOTO EMISSION COMPUTED TOMOGRAPHY (SPECT)

Spondylolysis that is suspected clinically but cannot be confirmed radiologically, or is in the stress reaction stage prior to fracture (pre-spondylolytic), may be detected initially by bone scintigraphy (Micheli, 1979; Penning and Blickman, 1980; Papanicolaou et al., 1985). Initial studies using technetium-99m methylene diphosphonate bone scintigraphy (BS) found discrepancies with radiography. Firstly, there may be a negative Xray and positive BS as it is too early or subtle to visualise the pars stress fracture on Xray. Secondly, there may be a negative BS and a positive Xray which would be indicative of an old lesion still representing spondylolysis but no longer causing osteoblastic activity (Jackson et al., 1981; Elliott et al., 1988; Lusins et al., 1994; Itoh et al., 1996; Dutton et al., 2000). Resnick, (1988) concluded that radiographs and scintigraphy are complimentary procedures and both are needed to diagnose stress induced injuries of the pars. BS provides a functional image of skeletal osteoblastic activity and a triple phase study should be performed with SPECT. A triple phase bone scan consists of a flow study showing blood flow to the region, blood pool images showing vascularity and static images showing osteoblastic activity. Static images need to include planar images and SPECT (Anderson et al., 1998). The clinical context will heavily influence the interpretation of isotope scans. Although a bone scan is not very specific, it is highly sensitive for detecting increased bony metabolism and may be the most sensitive tool for diagnosing pars lesions (Moeller, 2001). A scan would be undertaken to localize the exact level(s) of current active stress, to detect any injuries that are occult to Xray or CT, and to enable further imaging to be targeted to the specific area of abnormality (Anderson et al., 1998). It was suggested that lesions identified radiologically, but showing no activity on BS were chronic and

healed. Another interpretation is that it may also be due to an ununited stress fracture which no longer demonstrates accelerated osteoblastic activity (Elliott et al., 1988; Lusins et al., 1994; Itoh et al., 1996; Dutton et al., 2000). Lesions with increased activity on BS, but not seen on Xray, are classified as acute injuries that represent radiologically occult stress reactions (Lowe et al., 1984; Elliott et al., 1988; Harvey et al., 1998). Activity decreases with the chronicity of the injury, but may only normalize once remodeling / osteoblastic activity has ceased. This is shown in a study by Lusins et al, (1994), where fifty patients with back pain and radiologically diagnosed spondylolysis were evaluated by SPECT bone scanning. The data obtained from the study indicate that in acute spondylolysis, the SPECT scan is positive at the pars interarticularis. As the spondylolysis becomes chronic, the SPECT scan tends to revert toward normal even though healing of the spondylolysis has not occurred. As spondylolisthesis develops and progresses, the SPECT scan again becomes positive. The positivity, however, is more anterior and more diffuse. The authors propose that SPECT scanning in spondylolysis is not a positive or negative process, but rather varies with the time and stability of the spondylolytic spine (Lusins et al., 1994).

SPECT is an obligatory part of a bone scintigraphy examination for injuries of the pars interarticularis. SPECT is more sensitive than planar BS alone due to increased contrast which is important for the detection of subtle lesions. Its ability to localize lesions such as pars abnormalities is also valuable to confirm this type of injury (Collier et al., 1985; Raby and Matthews, 1993). Thus, bone scans can be positive when the clinical history is short and can demonstrate increased uptake in patients who have only had symptoms for 5-7 days (Micheli, 1979). Hensinger and

Arbor, (1989) speculate that with early detection of the bone stress reaction, appropriate treatment may be undertaken and therefore the recovery period would be shortened. Although bone scans have been used to assess recovery and to determine whether an athlete can return to activity, there is limited evidence to support this assumption. It has been suggested that bone scans show repairing of osseous bone which is likely to result in a positive scan even if healing or a pseudoarthrosis has been established (Letts et al., 1986). However, there is little evidence to support this. The assumption that bone scans are of little value for primary diagnosis, but are helpful to distinguish between those patients with established non-union of the defect and those in whom healing is still progressing was made by Van den Oever et al., (1987). Thus BS with SPECT is more sensitive than radiography in the detection of early stress reaction in the pars interarticularis.

In summary, the use of bone scans to follow the stress reaction as a guide for treatment is controversial. The main value of BS is the identification of an acute stress reaction of the pars before it manifests radiologically (Harvey et al., 1998). There are no studies, however, which show the time period over which the increased uptake activity will be detected by the scan, the clinical significance of pseudo-arthrosis, the significance of non union, the rationale for immobilization or how the scan can contribute to a decision about when the athlete can return to sport.

5.3 COMPUTED TOMOGRAPHY (CT SCAN)

Computed Tomography (CT) is the technique of choice when fine bone detail is required, such as the detection of occult fractures. As the CT scan visualises the

calcium of the bone very well, it is a useful tool to diagnose, grade and characterize a pars stress reaction or fracture (Anderson et al., 1998). Standard gantry angle or reformations along the plane of reverse gantry can be performed. CT scanning is the ideal imaging method whenever the cortical and trabecular architecture of bone, or the bony anatomy of complex joints need to be further assessed. CT is superior to magnetic resonance imaging for demonstrating fracture lines, small calcifications, loose bodies, subtle bone erosions and bone mineral loss or destruction (Anderson et al., 1998). This concurs with the study of Hardcastle et al (1992) where a group of young fast bowlers underwent CT scan as well as other radiological investigations in order to identify any cortical bone fracture. However, Rothman (1986) states that although CT scan may be helpful in the examination of an adult who has an established defect, it is rarely indicated as oblique radiographs and bone scans are more reliable. Further, the CT scan at the 3rd and 4th lumbar vertebrae was difficult because the plane of the scanning slice is parallel to the fracture. Harvey et al., (1998) cites the reverse gantry angle technique where the scan plane is perpendicular to the fracture, as being the method of choice. CT is superior to plain radiography and PBS for consistent and accurate demonstration of spondylolysis and identification of accompanying features of spondylolysis such as facet joint changes, spondylolisthesis, disc herniation and foraminal or lateral recess stenosis. CT gives the best indication of potential for a defect to heal, based on the demonstration of the callus formation around the fracture (Harvey et al., 1998). CT can also demonstrate wide, well-orientated margins indicating an established non union, and it is postulated that there is thus no potential for healing with conservative management (Harvey et al., 1998). Congeni et al., (1997) indicated a 15% false positive rate for nuclear

medicine studies when using CT scan for diagnosis. It was thus advocated using thin slice CT scan through the affected area. McAfee and Yuan (1982) advocated CT scanning for an established defect and postulated that it is the only preoperative diagnostic method that could directly visualize a pseudarthrosis mass at the isthmus of the defect of the pars. It was also stated that as the spondylolytic slip becomes more severe, CT scans are more difficult to interpret, due to geometric distortion of the canal that is caused by increased lordosis and the abnormal relationship with the vertebrae.

Moeller, (2001) proposed that CT scan is used to help determine the stage of injury or healing and the prognosis for complete radiological healing. Further studies are needed to verify this statement.

In summary, when a stress fracture in the posterior elements of the lumbar spine is suspected, a CT scan is the best imaging method to view the cortical bone. It will show fracture lines, small calcifications, loose bodies, subtle bone erosions and bone mineral loss or destruction (Anderson et al., 1998). However, it should be done in conjunction with a plain Xray to screen other conditions and magnetic resonance imaging to determine the exact status of the bone stress reaction.

5.4 MAGNETIC RESONANCE IMAGING (MRI)

Magnetic resonance imaging (MRI) demonstrates good anatomical definition of tissues and bone and exquisite detail of overlying soft tissues. It is very sensitive to oedema in bone, particularly cancellous bone (Ohashi et al., 1997; Anderson et al., 1998; Ruggieri, 1999). However, it has a less accurate definition of cortical bone. Although MRI resolves bone mineral poorly, it resolves cellular marrow space and

is the ideal method whenever a detailed delineation and characterization of bone marrow pathology is sought. This gives MRI an advantage in the detection of bone "bruising" and bone stress in the pars interarticularis. MRI has equivalent sensitivity to isotope bone scanning for the detection of bone stress, but provides more anatomical information (Anderson et al., 1998). Although pathology can be visualized accurately on MRI, more subtle lesions may be missed. In a clinical trial (n=50), MRI had a sensitivity of 57-86%, specificity of 81-82%, positive predictive value of 14-18% and negative predictive value of 97-99% for the diagnosis of pars interarticularis defect (Saifuddin and Burnett, 1997). MRI images the bone marrow, and the posterior elements of the spine contain relatively little bone marrow, but abundant bone cortex. Therefore, pathology of bone marrow, for example bone marrow oedema, may be missed. Stabler et al., (2000) stated that MRI imaging should be the first and only imaging modality in young patients with low back pain and advised against using bone scans and CT scans due to irradiation. However, routine MRI has a high false-positive rate for the diagnosis of pars defects and this is related to poor imaging techniques employed (Harvey et al., 1998; Campbell and Grainger, 1999). It has been shown that thinner slices sagittal T1 and T2 images used in MRI imaging procedures effectively demonstrate the pars defects and confirms the importance of the imaging technique (Udeshi and Reeves, n=100; 1999). However, this study did not examine the use of MRI in detecting or staging injuries. Harvey et al., (1998) state that there are reactive marrow changes in the pedicles adjacent to the pars defect and postulate this may assist in the diagnosis, as oedematous change correspond to painful pars defects, whereas fatty changes are associated with chronic defects. This aspect needs further investigation.

Wirtz et al., (1999) showed typical bone marrow changes in T1- and T2- weighted images, even at an early stage of injury. These locally ill-defined bone marrow changes in the pars of the 5th lumbar vertebra are interpreted as an occult stress fracture. MRI findings of stress reactions and spondylolysis of the lumbar pars interarticularis can reliably be classified into 5 grades (Hollenberg et al., 2002). However, further studies are needed to determine the role of these findings in the management of young athletic patients with low back pain.

In summary, the MRI is currently being used more frequently as an investigation of choice for identifying pars interarticularis bone stress reactions. Improved visualization of the normal pars interarticularis can be achieved with optimized MRI (Campbell and Grainger, 1999). However, there are shortcomings in diagnosing abnormalities in the posterior elements of the lumbar spine. The role of MRI in both diagnosis of pars defects and the relationship to clinical findings needs further research.

5.5 CONCLUSION OF RADIOLOGICAL INTERVENTION

It is important to note that the frequent detection of structural abnormalities that are real but clinically irrelevant, occurs frequently in the instance of pars interarticularis stress fractures (Fredrickson et al., 1984; Wiltse and Jackson, 1976; Hensinger and Arbor, 1989; Harvey et al., 1998). The radiographic criteria of a bone stress reaction often lags behind the clinical measurement of healing. Imaging does not replace the need for thorough clinical evaluation of an injury. Furthermore, the significance of an abnormal radiological finding can only be determined by the clinical context. Every imaging method has particular strengths and weaknesses and the choice will depend on the provisional diagnosis (Anderson et al., 1998; Moeller, 2001).

Many studies have shown the various imaging methods for bone stress reaction in the posterior elements of the lumbar spine (Weir and Smith, 1989). These studies are not limited to injury in cricketers. Further studies to determine the optimum imaging on cricket fast bowlers with this pathology need to be undertaken. These studies need to relate the radiological findings to the symptoms experienced to determine whether the spondylolysis is, in fact, the cause of the pain. This information would contribute to a better understanding of the aetiology of low back pain in cricket fast bowlers, and would contribute to a more evidence-based approach when clinical decisions are made about the management of the injury.

6. PAIN

6.1 GENERAL

Back pain is more common among athletes participating in sports which place high demands on the back than other athletes and non-athletes. Spondylolysis occurs in higher frequencies among athletes representing many different sports and occurs in up to 50% of athletes with back pain (Sward, 1992). A causative relationship between vigorous athletic activity, abnormal radiological features and low back pain has been investigated in a study of 142 top athletes, representing wrestling, gymnastics, soccer and tennis (age range 14-25 years). All groups of athletes reported back pain at high frequencies (50-85%) and radiological abnormalities of the posterior elements of the lumbar spine occurred in 36-55% of the athletes (Sward et al., 1990).

Some studies have however, reported that the development of spondylolysis, with or without spondylolisthesis was not associated with back pain in all patients. In a prospective longitudinal study, symptoms of pain were experienced before the age of 18 years in only 13% of children who were known to have spondylolysis (Fedrickson et al., 1984). This concurs with the study of Wiltse and Jackson, (1976) and Hensinger et al., (1989) who state that most children with spondylolysis never develop significant symptoms of back pain.

Further studies show that approximately half of patients with radiological symptoms of spondylolisthesis never develop symptoms of pain (Newman and Stone, 1963; Pease and Najat, 1967). However, Sherman et al., (1977) reported that ten of 11 patients who displayed pedicle sclerosis experienced back pain. In a further study it was reported that when symptoms of pain do develop, this usually occurs at the onset of the adolescent growth spurt (Sherman et al., 1979).

Thus, it is generally accepted that although there is a prevalence of these conditions in the general population, there is an inconsistent relationship between symptoms and the presence of spondylolysis and mild spondylolisthesis. In summary, these studies show the inconsistencies between physical activity, symptoms of lower back pain and diagnoses. The next section will focus specifically on lower back pain in fast bowlers.

6.2 CRICKET

The controversy surrounding the aetiology of spondylolysis and spondylolisthesis in fast bowlers makes the clinical approach to these injuries a challenge. Cricket

fast bowlers with pars interarticularis defects in the lumbar spine, may or may not be symptomatic. For example, Elliott et al., (1992) concluded that fast bowlers who displayed abnormal radiological features had a two in three chance of experiencing back pain. It was further proposed that fast bowlers with pars interarticularis stress fractures experience pain during the specific repetitive movement of bowling (Hardcastle, 1991; Hardcastle et al., 1992; Hardcastle, 1993). Eleven out of 20 (55%) young, fast bowlers had pars interarticularis defects. Of these 11 bowlers with this defect, 9 bowlers had pain induced by bowling and 2 were asymptomatic (Hardcastle et al., 1992). This has resulted in the assumption that pain is often associated with a radiological abnormality. Although these studies advocated having appropriate examinations to determine the exact cause of pain, none were designed to relate pain to the healing status of the stress fracture.

Another study has shown that spondylolysis is commonly asymptomatic or symptoms may be associated with low back pain from other causes (Harvey et al., 1998). The suggestion has been proposed that the appearance of abnormal radiological features alone should not prevent a fast bowler from competing (Burnett et al., 1996). However, it is presumed that in the presence of lower back pain, with associated radiological abnormalities, the fast bowler should be prevented from participating in fast bowling.

6.3 OTHER CAUSES OF PAIN

Back pain is a multidimensional syndrome and as such, it is difficult to determine an exact cause of pain or dysfunction (Paajanen et al., 1989). There have been studies showing a high incidence of disc abnormalities in the lower back of young athletes (Evans and Seibert, 1989; Boden et al., 1990; Sward et al., 1991; Annear

et al., 1992; Ong et al., 2003). Degeneration and/or bulging of the intervertebral disc may be symptomatic (Torgerson and Dotter, 1976; Bogduk, 1983; Bogduk, 1985; Biering-Sorenson et al., 1985; Paajanen et al., 1989; Terti et al., 1991; Hardcastle, 1991; Elliott et al., 1993; Campbell and Grainger, (1999) or asymptomatic (Magora and Schwartz, 1976; Witt et al., 1984). However, in most studies, the pain source has not been differentiated between bony abnormalities, disc abnormalities or pain arising from other from causes (Elliott et al., 1992). In a study to determine the progression of thoracolumbar disc degeneration in young fast bowlers in cricket, no association was found between the presence of disc degeneration and back pain in a follow up study. It was suggested that the pars defects were a more likely source of pain in fast bowlers under the age of 21 years (Burnett et al., 1996). This concurred with the studies of Hardcastle et al., (1992) and Elliott et al., (1992).

Other causes of low back pain in spondylolysis have been largely attributed to facet joint syndrome (Cyron and Hutton, 1978; Fehlandt and Micheli, 1993). Methalene blue dye was injected into 32 facet joints in 17 patients with bilateral spondylolysis (34 defects) in order to determine the source of the symptomatic back (Shiple and Beukes, 1998). The results suggest that stress fractures of the pars interarticularis may fail to heal because of the presence of synovial fluid from a nearby facet joint. However, the likelihood of pain arising from these joints was not discussed.

The role the technique of fast bowling plays with the mechanical fatigue of the articular facet joints of the lumbar vertebrae has also been described by Annear et

al., (1992). Both facet joint pathology and spondylolysis presents as pain when tested clinically on extension of the lumbar spine. The two pathologies may co-exist and be a plausible reason for the pain in chronic spondylolysis. The use of facet joint blocks may be useful to assess the relationship between facet joint and spondylolysis symptoms.

Further, musculo-skeletal strains have been hypothesised as another causative factor for pain in the lower back of the fast bowler (Foster et al., 1989; Hardcastle, 1991). Other differential diagnoses include disc space infection, osteoid osteoma, spinal cord tumour, slipped vertebral apophysis, herniated disc, thoracolumbar Scheuermann disease, early rheumatoid spondylitis, and muscular and neurological disorders (Hensinger and Arbor, 1989).

6.4 SUMMARY OF PAIN

The many studies identifying spondylolysis and spondylolisthesis in the lower back of the cricket fast bowler and other sports people have reached different conclusions regarding any direct link between this bony pathology and pain. In many of the studies symptoms are vaguely described, with no objective pain measurement recorded. Furthermore, details on return to sport have not been described in any studies. No study has used a pain scale such as the Visual Analogue Scale (VAS) and related it to the stage of the spondylolysis, the pain intensity and the return to sport. Further, this relationship of pain symptoms with the healing or management of the bone stress reaction in the pars interarticularis has not been documented (Lisbon et al., 1982; Saraste, 1986; Letts et al., 1986; Morita et al., 1995; Sys et al., 2001). The criteria have been based mostly on the

stage of healing and specific pain intensity is not mentioned. Further studies are needed to investigate the relationship between pain and the diagnostic markers of bone stress injuries.

7. MANAGEMENT

Decisions about management of a bone stress reaction should ideally be based on a clinical investigation using a radiological diagnosis and the pain that the bowler may or may not have. Different radiological procedures provide different information. For example, whereas a CT scan will identify the status of the cortical bone and therefore identify a stress fracture, a MRI can be undertaken to identify the early bone stress reaction as it manifests in the trabecullae bone (Andersen et al., 1998). This could possibly be linked to pain and a grade four bone stress fracture may be prevented, reducing the period of time away from bowling.

Inconsistency between radiographic interpretation and clinical observations does indeed occur. Spontaneous consolidation of pedicular fractures were shown to occur in a gymnast despite continued intensive practice with no symptoms (Guillodo et al., 2000). In a study where 506 college football players were tested over 8 years, it was shown that of the 27% who reported back pain, 21% were Xrayed and were diagnosed as having spondylolysis. None of these players lost

any more game time than the players who did not have spondylolysis. The conclusion from this study was that football players with a mature skeleton and with spondylolisthesis and/or spondylolysis were able to play without any problems and only those players who demonstrate biomechanical instabilities, along with persistent symptoms, warranted further consideration (Semen and Spengler, 1981).

At this stage data on radiological diagnoses in the context of management are lacking. The evaluation and management of spondylolysis remains unclear, in part because the measure of outcome is primarily subjective. Clinical evaluation of low back pain using the standing one-leg extension manouver (stork test) has been described and the treatment of the symptoms is prescribed accordingly (Jackson et al., 1981; Weir and Smith, 1989). Many studies have supported different conservative treatments for a pars interarticularis stress fracture (Wiltse and Jackson, 1976; Hensinger and Arbor, 1989; Morita et al., 1995; Sys et al., 2001). These include strategies from immobilization with various braces to rehabilitation and surgery (Letts et al., 1986; Jackson, 1979; Goldberg, 1980; Steiner and Micheli., 1985; Gunzburg and Fraser, 1991; Hardcastle, 1991).

Several authors have reported healing of a spondylolytic defect in children and young adults after treatment with a cast or a thoraco-lumbasacral orthosis (Letts et al., 1986; Micheli, 1979; Van den Oever et al., 1987; Anderson et al., 2000; d'Hemecourt et al., 2002). However, this occurred in many cases where there had been an acute onset of symptoms with the episode of injury clearly documented. The concern was raised in these studies that not all defects healed (Letts et al.,

1986; Steiner and Micheli, 1985; Andersen et al., 1998). Yet again there was no conclusive evidence that the symptoms were in fact related to the spondylolysis.

Other suggestions for the management of spondylolysis has been the restriction of vigorous activities, specific strengthening exercises to stabilise the spine, a graduated exercise programme, bed rest, non-narcotic analgesics and local cortico-steroid injections (Jackson, 1979; Goldberg, 1980; Steiner and Micheli, 1985; Hardcastle, 1991). There is limited evidence to assess the efficacy of any of these interventions in cricketer fast bowlers.

It has also been suggested that the treatment of an un-united stress fracture of the pars interarticularis should be surgical if conservative management fails and the symptoms are present for more than 6 months (Hardcastle, 1993). This is based on the supposition that the pain and clinical symptoms arise from the pars lesion site. In this study it was reported that the bowlers returned to fast bowling with no further problems. The primary concern in this study was whether the fractured pars interarticularis had healed and no mention was made of the clinical symptoms in the bowlers with these post-operative un-united fractures.

The inference of healing of the fracture and reduction of pain is highlighted in a study by O'Neill and Micheli (1989). Patients (n=148) had spinal fusions for spondylolysis and/or spondylolysthesis. Ninety percent of these fractures healed, which was believed to be due to the presence of a mechanically stable environment. The significance in the healing of the pars defects (which were not clearly defined in this study), was that surgery was based on the duration of the

pre-operative symptoms. It was believed that the pars could be expected to heal in the presence of a rigid lumbar spinal stability, provided the duration of symptoms had not been greater than 2 years. Thus, although the status of healing was shown, there was no comment from this study with regard to clinical satisfaction post-operatively. Thus it is not clear if the "healing" of the pars was at all significant regarding reduction of symptoms and in fact, if that was the cause of the initial symptoms. Further, the recommendation of posterior spinal stabilization to heal pars defects for patients with symptoms and failed conservative management is based on the assumption that the symptoms arise from the pars interarticularis defects.

In another study designed to evaluate the outcome of surgical repair of pars interarticularis defect by segmental wire fixation in young athletes with lumbar spondylolysis, the results were reported to be 80% positive. These results were based on radiographic examination (bony fusion), pre and post-operative sports activity levels and intensities and the presence of complications. The study did not define intensity of symptoms pre- or post operative, or determine if the status of the bone was the cause of the initial low back pain (Nozawa et al., 2003). Further studies involving surgical repair of lumbar spondylolysis concluded that this management of the problem is most effective and is even the gold standard of treatment to save a functional segment (Wu et al., 1999; 2003; Ivanic et al., 2003; Debnath et al., 2003). This may well be the case in a potentially unstable or an unstable spondylolisthesis. Furthermore, in these studies, the origin of the pain symptoms was not clearly demonstrated and the appropriateness of the surgery can therefore not be assessed.

The return to sport described in the studies, varied from no time off (Guillido et al., 2000) to 7.3 months (Jackson et al., 1981). In a study by Sys et al (2001), 34 highly competitive athletes were diagnosed with a fatigue fracture of the pars interarticularis using SPECT and CT investigation and were re-evaluated after a mean time of 15.9 weeks. The healing of the fracture, the subjective outcome and the return to sport were evaluated. It was shown that non-union did not seem to compromise the overall outcome. However, the relevance, cause and the intensity of the pain was not demonstrated.

In summary, when dealing with bone stress reaction in the cricket bowler's back, poor clinical and radiological assessment techniques have often resulted in inadequate management. With the exception of surgical intervention, few management strategies, particularly rehabilitation, have been assessed scientifically with regard to lower back pain in fast bowlers.

8. CONCLUSION

Suspicion of spondylolysis is raised by the patient's history, physical examination and plain radiographs. Most of the management of spondylolysis in the back of the cricket fast bowlers or in athletes has been anecdotal. There are no well-designed intervention studies assessing the diagnostic procedures, the effect of the management and its relationship to pain (Standaert and Herring, 2000). The significance of spondylolysis and stress fractures of the pars interarticularis in the cricket fast bowler and indeed, the athlete, continues to be debatable. The

association between these pathologies and back pain has been inferred and is the accepted theory in many studies. Inconsistencies between radiographs and clinical observations have been noted (Jackson et al., 1981; Harvey et al., 1998; Hardcastle et al., 1992; Guillodo et al., 2000; Moeller, 2001). In many instances, union of the bone is the main priority of management with little concern for specific clinical symptoms (Fredrickson et al., 1984; Sys et al., 2001). Other causes of back pain need to be researched and specific diagnostic studies are needed for a definitive diagnosis and appropriate management. The presence of a pars lesion on a plain radiograph is not diagnostic of an active lesion. Bone scintigraphy with SPECT can assess metabolic activity and locate lesions. Thin sliced CT may be useful for staging an injury or healing and MRI assists in the diagnosis of soft tissue pathology and shows metabolic activity in the medulla. Further research needs to be done investigating pain, the fast bowler's clinical profile and radiological assessment with the overall goal of more appropriate management and evidence-based guidelines for return to play.

Chapter 3

DISSOCIATION BETWEEN BACK PAIN AND BONE STRESS REACTION AS MEASURED BY CT SCAN IN YOUNG CRICKET FAST BOWLERS.

- (a) This chapter has been accepted for publication in the British Journal of Sports Medicine, August, 2003.
- (b) Data from this chapter were presented at the World Congress of Science and Medicine in Cricket, February 2003.
- (c) Accepted as oral presentation at the International Federation of Orthopaedic Manipulative Therapy Congress, Cape Town, March 2004.

ABSTRACT

Background: Bone stress reaction is prevalent among cricket fast bowlers. Few studies have addressed sensitivity and specificity of imaging for diagnosis, and follow-up assessment has been poorly investigated. **Objective:** To determine whether there was an association between back pain and bone stress reaction as measured by Computed Tomography (CT) scan in young cricket fast bowlers. **Methods:** Ten young cricket fast bowlers were included in the study. Nine of these bowlers presented to a physiotherapy practice with low back pain and were later diagnosed with lumbar stress fractures. The remaining subject was an experienced bowler with no lower back pain. All players had a CT scan after presenting to the physiotherapy practice. Pain was assessed according to a subjective scale (0-10) where 10 represented the player's subjective, maximum pain score. The recovery and rehabilitation of all players was monitored until they returned to full participation. **Results:** There was no consistency in the relationship between pain and CT scan results. For example, one subject had evidence of ununited stress fractures after 15 months of rest and had experienced moderate pain for only 2

weeks after the onset of symptoms. This was in contrast to another subject who had intermittent pain for 11 months even though his CT scan showed that his multiple stress fractures ranged from partially healed to fully healed status at 3 months. Conclusion: There is dissociation between back pain and bone stress reaction as measured by CT scan. Therefore, CT scan alone does not provide objective evidence for ongoing management or decision as to return to sport in cricket fast bowlers.

Keywords: spondylolysis, pars interarticularis, radiography

University of Cape Town

INTRODUCTION

Lumbar spondylolysis is a common structural defect which affects approximately 4-6% of the general population (Fredrickson et al., 1984; Mc Carrol et al., 1986, Hensinger and Arbor, 1989; Harvey et al., 1998). However, there is an increased incidence of this condition in certain groups of sportsmen and women (Ferguson et al., 1975; Hardcastle et al., 1992; Annear et al., 1992). In particular, young athletes involved in sports that require hyperextension of the spine, especially if this movement is combined with rotation and side flexion, are at high risk for spondylolysis (Elliott et al., 1993; Hardcastle, 1993). Fast bowling in cricket is an example of a sport which involves this combination of movements (Resnick, 1988; Foster et al., 1989; Hardcastle, 1991; Hardcastle et al., 1992; Harvey et al., 1998; Stretch, 1989, 1993; Elliott, 2000). Pars interarticularis abnormalities occur in 11– 60% of the cricket population (Foster et al., 1989; Payne et al., 1987; Annear et al., 1992; Elliott et al., 1992).

Fast bowlers with pars interarticularis defects do not always have associated lower back pain. Eleven out of 20 (55%) young, fast bowlers had pars interarticularis defects (Hardcastle et al., 1992). Nine of these bowlers (82%) with pars interarticularis defects had pain induced by bowling and 2 (18%) were asymptomatic (Hardcastle et al., 1992). Another study has shown that spondylolysis is commonly asymptomatic or it may be associated with low back pain from other causes (Harvey et al., 1998). Furthermore, a study in which young fast bowlers were investigated over 2.7 years showed an inconsistent relationship between disc degeneration and back pain (Burnett et al., 1996).

As a result of these phenomena fast bowlers presenting with back pain provide the clinician with several challenges. First, there is difficulty differentiating the symptomatic spondylolysis, for example the acute/subacute stress fracture, from the asymptomatic chronic spondylolysis. Secondly, the anatomical origin of the lower back pain can be difficult to determine. Thirdly, there are no well-investigated, clearly articulated objective criteria for a diagnosis of clinically relevant bone stress and the use of this criteria in the return to fast bowling. Therefore, clinicians are often in a quandary as to when the fast bowler may return to full participation in bowling, particularly as symptoms of pain may or may not be associated with the condition. Various radiological investigations are currently used in the evaluation of for bone stress status (plain radiography, computed tomography (CT), isotope bone scan, planar bone scintigraphy (PBS), single photon emission computed tomography (SPECT) and magnetic resonance imaging (MRI) (Anderson et al., 1998; Harvey et al., 1998). However, none of these diagnostic procedures have been studied prospectively with particular reference to pain in cricket fast bowlers. Therefore the aim of this study was to determine if there was an association between lower back pain and bone stress reaction as measured by Computed Tomography (CT) scan in young cricket fast bowlers.

METHODS

The design of this study is a series of case studies. The study was granted clearance by the Ethics and Research Committee of the University of Cape Town (Appendix A). Nine young cricket bowlers who presented to the physiotherapy practice with low back pain and were diagnosed with stress fractures in their lumbar vertebrae were included in this study. One experienced bowler without back pain was also included in the study. The

clinical diagnosis was made based on the subjective and objective clinical assessment. The final diagnosis was made based on a combination of radiological interventions. All subjects gave written consent to participate in the study (Appendix B).

The imaging protocol was as follows: when the patient presented with low back pain, a plain Xray of the lumbar spine was taken to determine the presence or absence of spondylolysis or chronic stress injury of the pars interarticularis in the lumbar vertebra and to screen for other pathological conditions. Anterior-posterior, lateral, flexion and extension stress views and two oblique views were taken. Next, a radionuclide scan was performed. This identified any "hot spot" (i.e. increased turnover of bony matrix) and, if one was present, allowed the CT scan to be localised to a specific level or levels of recent injury to see if there was a linear defect in the bone or simply a sclerotic reaction.

CT Scan Protocol :

Scan factors were optimised to reduce radiation levels, without compromising diagnostic quality. The following procedure was undertaken: 3 mm thick slices, spiral at 2:1 pitch, 1.5 sec cycle and 146 mA (219 mAs total), 140 V. This gives an approximate radiation dose to local tissues of 9 mGy in a "normal sized patient" as calculated for the Plus 4 Siemens Spiral CT Scanner (Erlangen, Germany). Acceptable dose limits to localised musculo-skeletal tissues in patients are accepted as 1/10 those of " radiation workers" which would be 1/10 of 300 mGy/year i.e. 30 mGy/year. With the above factor, three scans over a 12 month period at approximately 9 mGy/year would result in a radiation of 27 mGy would be within acceptable limits for 1 year (Meredith and Massey, 1977).

The scan position was modified from the “normal” axial orientation used for disc lesions. The so-called “ Reverse Gantry angle CT” was used. This attempted to scan “in – plane” to visualise the posterior elements of the bony ring of the injured vertebra. This ensured that the scan plane was perpendicular to the fracture and was able to demonstrate a pars interarticularis defect (Sandrick, 2000).

Pain experienced during activities of daily living was assessed according to a verbal analogue scale whereby 0/10 represented no pain and 10/10 was the player’s subjective maximum debilitating pain score. Players were also questioned about specific movements which were associated with pain and were scored with the same scale.

RESULTS

The case reports for each of the 10 subjects are presented.

Subject 1:

A 17-year-old right arm fast bowler had low back pain which he scored at 4/10 with hyperextension and sudden movements for 2 weeks. He had mild (1/10) pain whenever resuming bowling over the following six months. A diagnosis was performed with an Xray, isotope scan and a CT scan 6 months after the first symptoms of pain. A CT scan was undertaken again at 2 months after the first CT scan and then again 7 months later. During this time he was advised to stop bowling and experienced no pain at rest. The stress fracture of the left pars interarticularis of the 4th lumbar vertebra remained ununited 15 months after the first symptoms of pain (Figure 1a). The fractured right pedicle was partially united after 15 months (Figure 1b). During inactivity from cricket,

he participated in an intensive rehabilitation programme and returned to full participation after 15 months. He had ongoing assessments for this condition for a further 3 months and experienced no back pain while bowling.

Subject 2:

This 15-year-old right arm bowler had mild pain (3/10) for 3 weeks after presenting with his initial symptoms. Further, he had no positive subjective or objective clinical findings and had full range of movement in all planes i.e. flexion / extension, lateral flexion and rotation. These movements were applied with overpressure. An Xray and an isotope bone scan were performed when he presented with his symptoms. The Xray showed no abnormal findings, while the isotope bone scan showed an increased area of uptake over the left pars interarticularis of the 5th lumbar vertebra. This was diagnosed as a stress fracture of the left pars interarticularis of the 5th lumbar vertebra. The CT scan was undertaken at 3 months after the initial presentation of symptoms and showed partial healing of the left pars interarticularis (Figure 2). He did not bowl for 6 months after presentation of his first symptoms, during which time he underwent an intensive rehabilitation programme. Thereafter he resumed bowling with no further symptoms.

Subject 3:

This 22-year-old right arm bowler of national ranking presented with mild low back pain (3/10). He had no previous history of lower back pain or inability to play cricket at any stage during his career. The mild pain of his left lumbar spine was present for 1 week. This pain was present only when overpressure was applied in lumbar extension.

He had an Xray, an isotope bone scan and a CT scan of the injury on presentation to the physiotherapy practice with this mild back pain. The CT scan showed multiple partially healed and associated areas of ununited fractures of the right and left pars interarticularis and pedicles of the lumbar vertebrae of L3, L4, and L5 (Figures 3a, b, c). Specifically, the CT scan showed a pseudo-arthrosis of the left pars interarticularis of the 3rd lumbar vertebra, and a pseudo-arthrosis of the left pars interarticularis of the 4th lumbar vertebra. There was also a partially healed fracture line through the exostosis. There was a non-union at the right pars of L3, partial union of the right pedicle of L4, and union of the right pars of L 4. There was evidence of a healed fracture through the right pedicle with bony cortical and tubercular thickening of the 5th lumbar vertebra. The left spondylolysis showed a subtle area of cross trabeculation in the mid-third of the fracture line, with signs of non bony union superior and inferior to the area of union. There was a similar bony exostosis, namely a pseudo-arthrosis. There was a slight distortion of the spinal canal at this level. The subject had no neurological signs at this stage. After the discovery of the stress fracture he did not play cricket for 3 months, during which time he was involved in an intensive rehabilitation programme. Two months after resuming bowling, he developed a stress fracture of his 2nd metatarsal bone of his right foot. He rested for a further 2 and a half months and then returned to full participation in bowling. One year later he sustained a stress fracture of his right mid-femur.

Subject 4:

This 18-year-old right arm bowler complained of left sided lower back pain (3/10). This cricketer had experienced intermittent pain associated with bowling activity for 11 months after the first symptoms. He only resumed bowling after the 11 month period

once he was pain free. The CT scan, taken 3 months after the subject first presented with symptoms, showed a partially healed stress fracture of the right pars interarticularis, and a healed fracture of the left pars interarticularis of the 4th lumbar vertebra (Figure 4).

Subject 5:

This 21-year-old right arm bowler experienced pain during the bowling delivery. The pain (4/10) was still present 2 weeks after the initial symptoms. He was originally assessed with an Xray and isotope bone scan and diagnosed as having a left pars interarticularis stress fracture of the 5th lumbar vertebra. The CT scan taken 3 months after the original diagnosis made with the isotope bone scan, showed that he had a thickening of the left pars interarticularis and left pedicle, but no stress fracture (Figure 5). Based on the original diagnosis of a stress fracture, he did not play cricket for 3 months. His pain was 0/10 after the initial 2 weeks and remained asymptomatic when he resumed bowling.

Subject 6:

This 15-year-old right arm bowler experienced pain (5/10) for 2 weeks after the initial symptoms if he extended his lumbar spine, or stood in a sustained position for a long period. He was initially assessed with an Xray and isotope bone scan and diagnosed as having a left pedicle stress fracture of the 5th lumbar vertebra. He was advised to avoid cricket for 6 months. A CT scan taken 3 months after the diagnosis, showed a thickening of the left pars interarticularis and left pedicle, with no stress fracture (Figure 6). He was reassessed after the six month period and having no symptoms of pain, returned to bowling with no further problems.

Subject 7:

This 21-year-old right arm bowler experienced pain (5/10) for two weeks after the original symptoms. This pain was only experienced with fast bowling, or after prolonged sitting. He had an Xray followed by an isotope bone scan on first presentation of these symptoms and was diagnosed with increased uptake postero-laterally of the 3rd lumbar spine compatible with a stress fracture. He had been advised to rest from cricket activities for 3 months. The CT scan, taken 2 years after the original diagnosis, showed a thickened healed stress fracture of the left pars interarticularis and a thickened left pedicle (Figure 7). During the period following the 3 month rest from cricket activities and the subsequent CT scan, he had bowled with no further back symptoms.

Subject 8:

This 22-year-old right arm bowler of national ranking, experienced no back pain (0/10) at the time of the study, but had experienced some mild back pain during the previous 3 years. He had not had these symptoms of lower back pain investigated. Although he did not miss any matches due to back problems, he agreed to have a CT scan for the study. The scan showed an ununited left pars interarticularis stress fracture of the 5th lumbar vertebra; an ununited right pars fracture of the same vertebra and right pedicle thickening of the 5th lumbar vertebra (Figure 8).

Subject 9:

This 19-year-old left arm bowler experienced mild to moderate pain of the right lumbar spine (4.5/10) for 2 to 3 weeks after the first symptoms when sitting for sustained periods or occasionally when waking up in the morning. He had a CT scan 4 months after the first symptoms of pain in his right lumbar spine. The scan showed an old lesion

with non-bony union of the left pars interarticularis of the 5th lumbar vertebra. This had been asymptomatic, even when bowling. His symptomatic right side showed a non-bony union of the pars interarticularis of the 5th lumbar vertebra (Figure 9). He was advised to avoid playing cricket for 6 months because of the bilateral condition and the potential for a spondylolisthesis. He had an intensive rehabilitation programme during this period. After 6 months he had another CT scan which showed non-bony union. The Xray taken at the same time, showed that there was a degree of instability of this vertebra. However, he experienced no further problems when resuming bowling.

Subject 10:

This 17-year-old, right arm bowler presented with pain in the left lumbar area. The pain was rated as 3/10 and only experienced with extreme lumbar movements and when bowling. This pain lasted for 3 weeks after the initial symptoms. An isotope scan, taken 2 weeks after the original symptoms, showed an increased uptake in the posterior elements of the left L5. The CT scan taken one month later (i.e. 3 months after the appearance of the symptoms), showed a healing fracture of the left pars interarticularis (Figure 10). This cricketer did not play cricket for 3 months after the original symptoms, during which time he underwent an intensive rehabilitation programme. He experienced no further problems once resuming bowling.

These data are summarised in Table 1. The CT scans taken at various stages after injury showed varying degrees of healing of the stress fractures of the posterior elements of the lumbar spine, from non-union to partially healed or fully healed. The status of the fracture did not always correlate with the intensity or duration of pain experienced by the cricketer.

DISCUSSION

Dissociation between pain and pars defects

The first important finding of this study was that there was a dissociation between pain and spondylolysis or pars interarticularis defect as measured by CT scan. This raises the question of whether pain and/or radiological evidence from CT scan should be used as a guide for the return of the cricketer to full participation in fast bowling. Both of these factors have been the main points of reference in the clinical setting in the past. It is clear that if pain exists, then the cricketer should not participate in the game or practice. However, based on the findings of this study, there is often no pain or minimal pain, even though there are pars interarticularis defects (with or without union) in the lumbar spine. This was particularly evident in subject 3, who had multiple stress fractures without pain and subject 8 who had minimal pain with full bowling participation throughout his career. An interpretation of this observation is that the CT scan may be recording a false positive test, indicating that there is an injury when in fact, the pain is due to another cause and not the bone stress reaction. The bone stress reaction could be the body's adaptive response to the extraordinary stresses imposed by the biomechanics of fast bowling. An alternative interpretation is that it may be of genetic origin and not relevant to the current lower back pain experienced. The bone isotope scan identified the reaction to the cancellous bone injury i.e. micro fractures of the cancellous bony struts, resulting in oedema and haemorrhage into the cancellous bony spaces. This "bone bruising" would not be identified on the CT scan, unless it had progressed to cortical bone injury. The CT scan is the most sensitive imaging procedure to visualise cortical bone injuries in this area. However, it is insensitive to

acute/subacute stress reaction by the bone. Chronic stress reactions may show up as increased sclerosis and thickening of trabeculae. Therefore, the CT scan shows the cortical stress fracture (grade 4), whereas the MRI shows the reaction of the trabeculae bone fractures (grade 1-3) indicating bone bruising (Harvey et al., 1998; Moeller, 2001). An alternative interpretation could thus be that there is more pain when there is bone bruising (i.e. grade 1- 3 bone stress reaction) and less pain with the cortical stress fracture (grade 4 bone stress reaction). Perhaps if a bone stress reaction is identified at an early stage, a grade 4 stress fracture could be prevented. A clinical concern is that a grade 4 spondylolysis may render the spine unstable (Hardcastle, 1993). Further research needs to be undertaken using the MRI as the prime investigation of choice to identify the stage of bone stress reaction.

Associated bilateral pars defects

A further finding in this study was that 3 out of the 9 right-handed fast bowlers with a pars stress fracture on the left side showed a non-bony union of this side (subjects 1, 3, 8). This was associated with a fractured pedicle on the right side which did heal or partially heal or a fractured pars on the right which did not heal. There was no relationship between whether the fracture was in the pars, the pedicle or the lamina and the magnitude and duration of pain.

Clinical relevance for “return to bowling”

Another important finding in this study was the relevance of non-bony union (i.e. fibrous union) of the stress fracture of the posterior elements of the lumbar spine. This may be interpreted as the body adapting to the extreme ranges of movement required by these spinal joints during the cricket fast bowling action. For example, there was pseudo-joint

and osteophyte formation in subject 3. This represents an adaptation of the lumbar spine which may, in fact, be advantageous to the bowler in terms of future mechanical pressure on those structures. This interpretation would, however, depend on the subject observing an intensive specific trunk and pelvic stabilisation programme as excessive spinal joint movement would not be beneficial without adequate muscle control (O'Sullivan, 2000).

Subject 1 was advised to rest from bowling for 15 months based on the continual non-union shown on his CT scan. However, there was no further union after this 15-month rest period. He only experienced pain for 2 weeks after he stopped bowling. The delay in returning to bowling was based on the ununited stress fracture of the left pars interarticularis. The relevance of this clinical decision making needs to be re-evaluated. Further research needs to be undertaken to determine whether an earlier return to bowling would be detrimental to the spinal stability of the young fast bowler.

Subject 8 had bowled for a number of years relatively symptom-free, unaware of the ununited stress fracture in his lumbar spine. It is reasonable to assume that there may be other players who have been playing symptom free with this condition. This is supported by the findings of Anear et al., 1992 and Elliott et al., 1992 who showed the evidence of stress fractures in asymptomatic fast bowlers. Therefore it is proposed that in some cases, ununited stress fractures may have no significant impact on bone health, but may reflect a biological adaptation to bowling.

Genetic predisposition?

Certain studies show that spondylolysis may be familial and that there is an increased incidence in certain families and race groups (Saha et al., 1970). A number of studies show that genetic factors may predispose the individual to spondylolysis (Baker and McHollick, 1956; Wiltse, 1962; Saha et al., 1970; Wiltse et al., 1975). Thus, the genetic spondylolysis could be an additional explanation for the stress fractures seen on the CT scan in individuals who are symptom-free. It is important to recognise the age of the fast bowler, training and playing habits, bowling technique and any postural deficit when managing bone stress injuries of the lumbar spine in cricket fast bowlers. Specifically, this genetic factor may predispose an individual to develop the symptomatic defect, especially when young and playing a high risk sport such as cricket fast bowling (Cyron and Hutton, 1978). It is interesting to note that subject 3 developed stress fractures in other regions, which raises the suspicion that he may have had an underlying metabolic disorder which increased his risk of bone stress injury.

SUMMARY

This study shows that there is dissociation between pain and bone stress reaction as measured by Computerised Tomography (CT) scan. CT scans should only be interpreted in conjunction with findings from a positive isotope or MRI scan and not in isolation. CT scans will have relevance in the acute/subacute setting where there is a proved bone stress reaction on an isotope or MRI scan showing an area of increased bone turnover/metabolism or oedema respectively. A CT scan may also be used on the follow-up of a positively diagnosed injury to assess whether the "hot" area actually has a fracture, whether a fracture develops later within the reacting area and to assess the progression of healing and union of a positively diagnosed acute/subacute fracture.

Therefore, the results of a CT scan in isolation from bone isotopes and MRI as an objective method for assessing the management of a player should be used with caution. Furthermore, the results of a CT scan showing a diagnosis of a bone stress fracture does not automatically signify the cause of the pain. There is little research linking the diagnosis of spondylolysis / bone stress reaction of the pars interarticularis of the lumbar spine to pain. Moeller, (2001) state that advanced injuries have a decreased likelihood of complete radiological healing. Whether this relates to poor outcome such as eventual spondylolithesis or chronic pain is not well documented.

However the findings from this study are that there is a dissociation between pars and pain. Following from these case studies many questions arise. For example, in advising the injured fast bowler on return to fast bowling should pain be your guide? Is non-union a problem? What is the clinical relevance of radiological investigations? Further studies are needed to ascertain whether the bone stress reaction is symptomatic or whether the pain is in fact due to other causes.

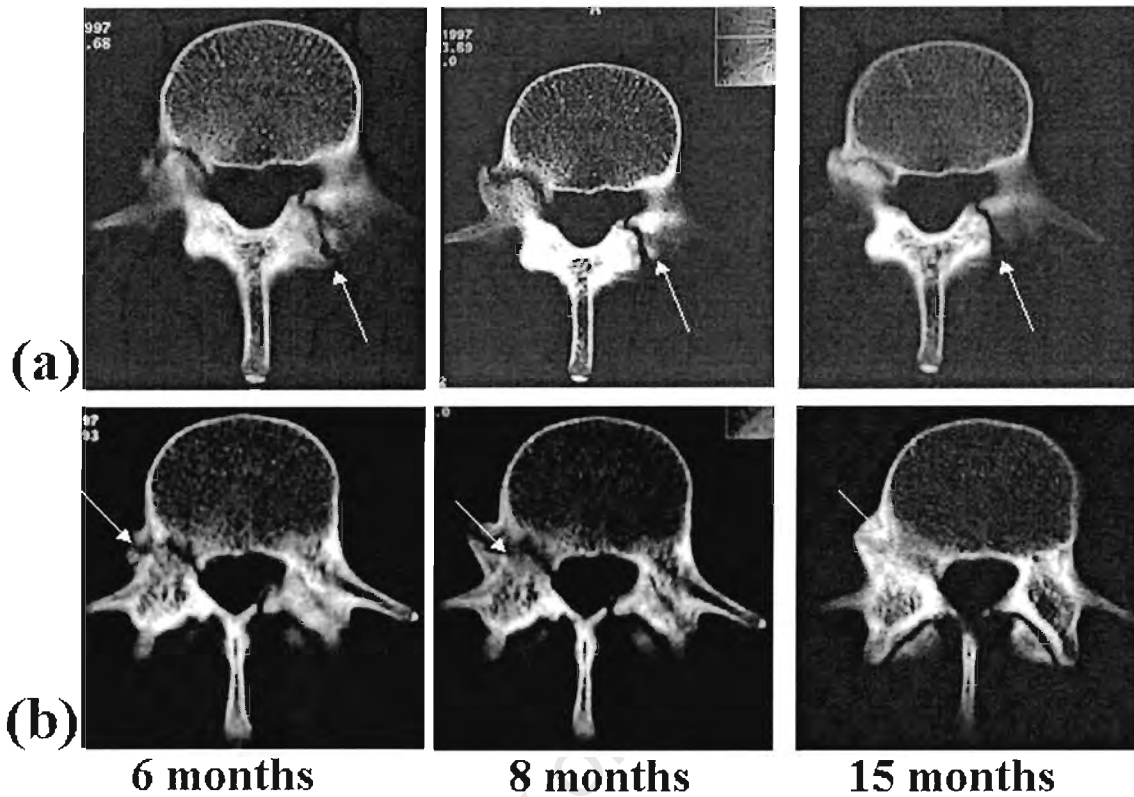


Figure 1. A CT scan in a 17-year-old right arm bowler which shows (a) non bony union of the left pars interarticularis of the 4th lumbar vertebra, 6, 8 and 15 months after the original symptoms, and (b) shows partially united fracture of the right pedicle of the 4th lumbar vertebra after 6, 8 and 15 months.

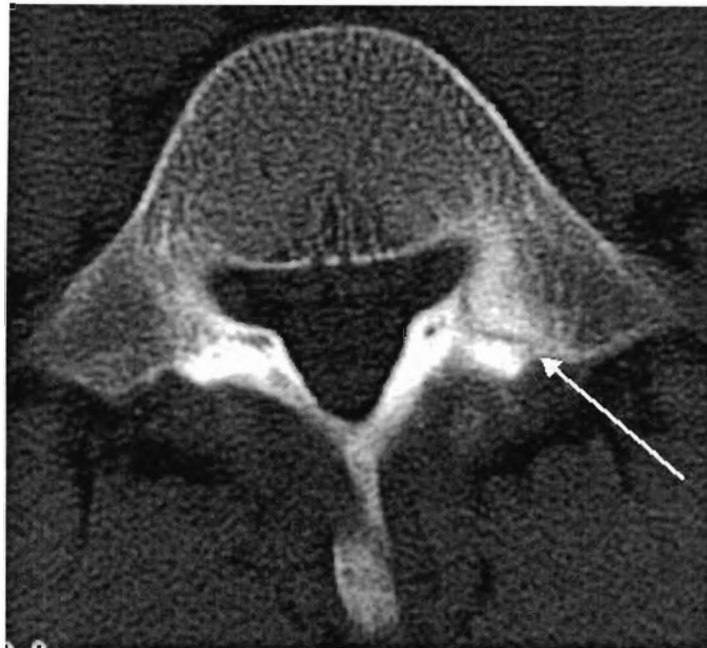


Figure 2. A CT scan of subject 2 (15-year-old right handed bowler) taken 3 months after the initial presentation of symptoms showing a partial healing of the left pars interarticularis stress fracture of lumbar 5 vertebra. The subject was free of pain 3 weeks after presentation of symptoms.

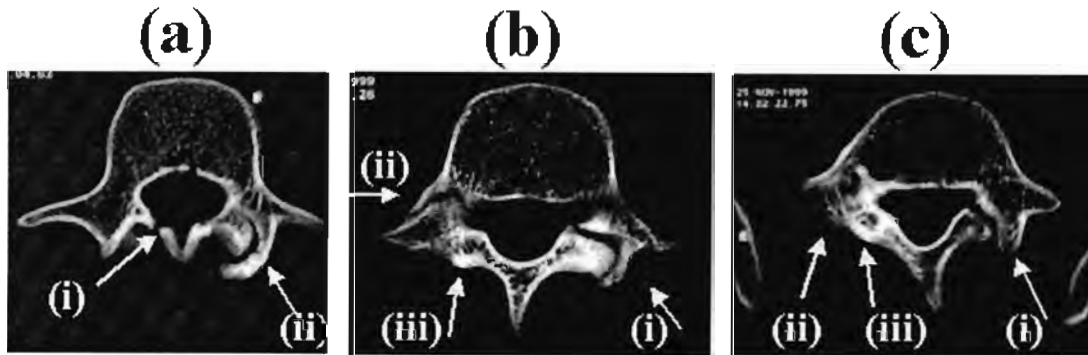


Figure 3. A CT scan of a 22-year-old right arm bowler of national ranking showing (a) (i) pseudo-arthrosis of the left pars interarticularis and (ii) ununited lamina fracture of lumbar 3, (b) (i) pseudo-arthrosis of the left pars interarticularis of the 4th lumbar vertebra with a partially ununited fracture through the exostosis; (ii) partial union of the right pedicle and (iii) union of the right pars interarticularis, and (c) (i) the left spondylolysis which showed a subtle area of cross trabeculation in the mid-third of the fracture line, with signs of non-bony union superior and inferior to the area of union. There is a similar bony exostosis, namely a pseudo-arthrosis. There is a slight distortion of the spinal canal at this level. healed fracture through the right pedicle with bony cortical and tubercular thickening of the 5th lumbar vertebra. (ii) There is thickening of the right pars interarticularis and (iii) a thickened, healed fracture of the right pedicle.

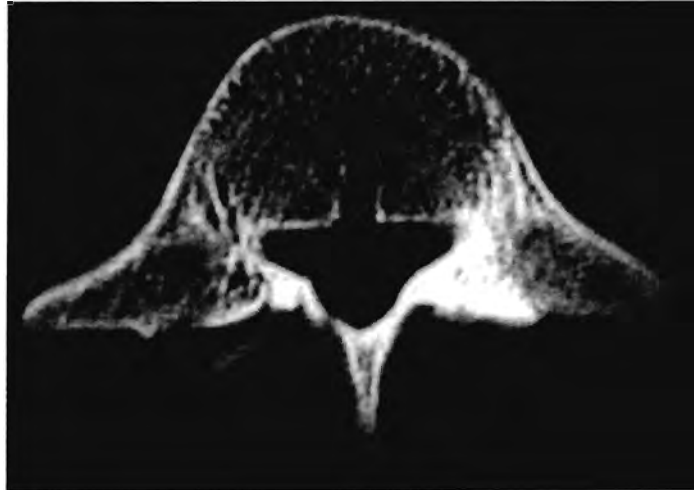


Fig. 4. A CT scan of an 18-year-old right arm bowler (subject 4) showing a healed left pars interarticularis fracture and a partially healed right interarticularis fracture of the 4th lumbar vertebra.

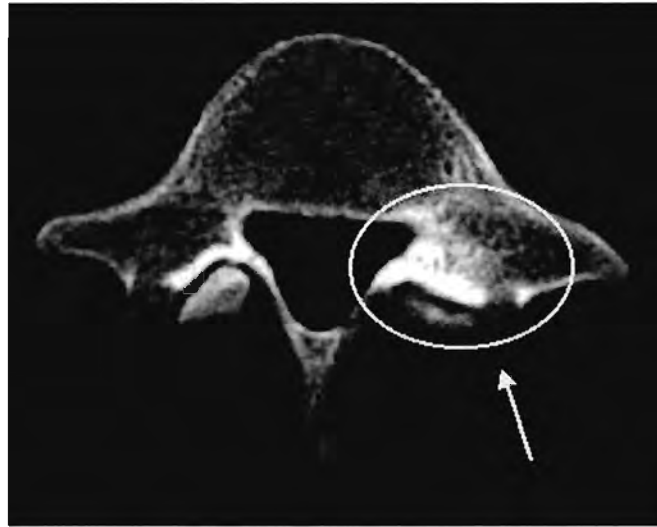


Fig.5. CT scan of a 21-year-old right arm bowler at 3 months showing a thickening of the left pars interarticularis and left pedicle with no stress fracture. The bowler was originally diagnosed with an isotope bone scan as a “left pars interarticularis fracture of 5th lumbar vertebra.”

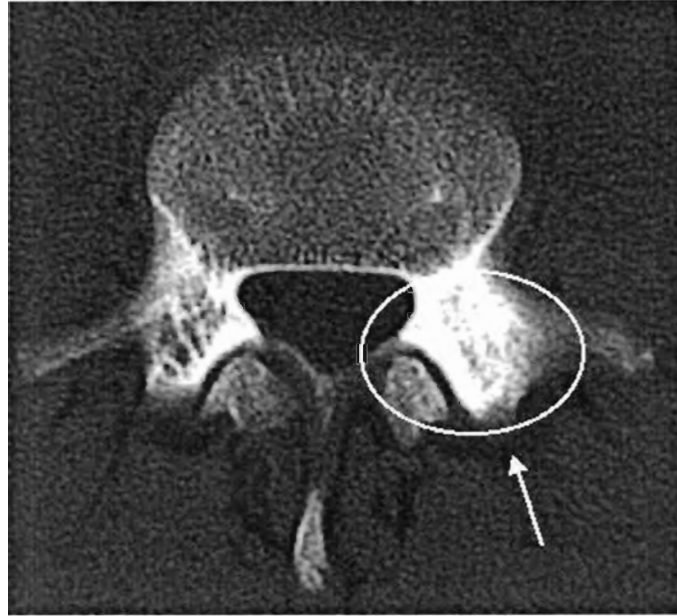


Fig. 6. A CT scan of a 15-year-old right arm bowler (subject 6) taken at 3 months after the diagnosis of a stress fracture (isotope bone scan). This showed a thickening of the left pars interarticularis and left pedicle with no stress fracture.

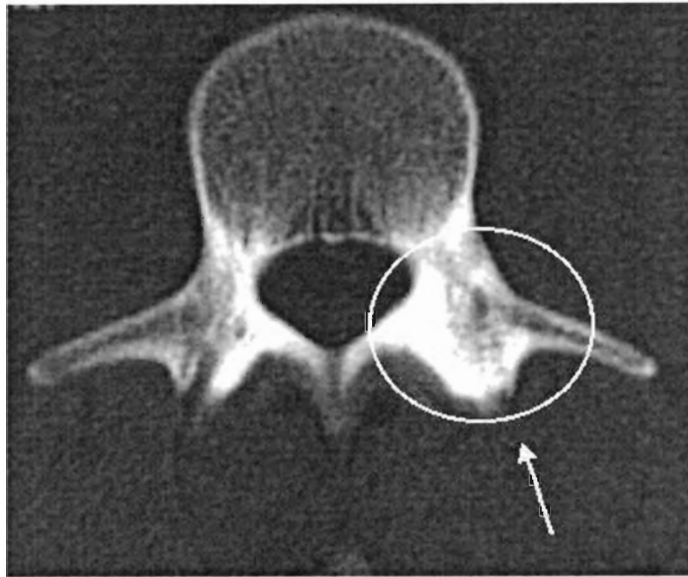


Fig.7. This 21-year-old right arm bowler (subject 7) was diagnosed with an isotope bone scan as having "increased uptake in the postero-lateral 3rd lumbar vertebra, compatible with a stress fracture". This CT scan taken 2 years after the original diagnosis and showed a thickened, healed stress fracture of the left pars interarticularis and a thickened left pedicle.

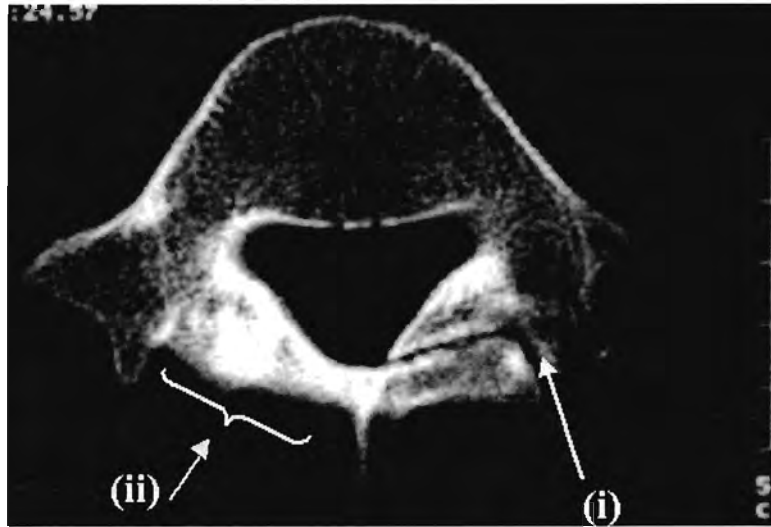


Fig. 8. A CT scan of a 22-year-old right bowler of national ranking (subject 8) showing (i) non-union of the left pars interarticularis fracture and (ii) a bony thickening of an old fracture of the right pars interarticularis of the 5th lumbar vertebra. There is also thickening of the right pedicle of the 5th lumbar vertebra. He did not miss any matches due to back pain during his national career.

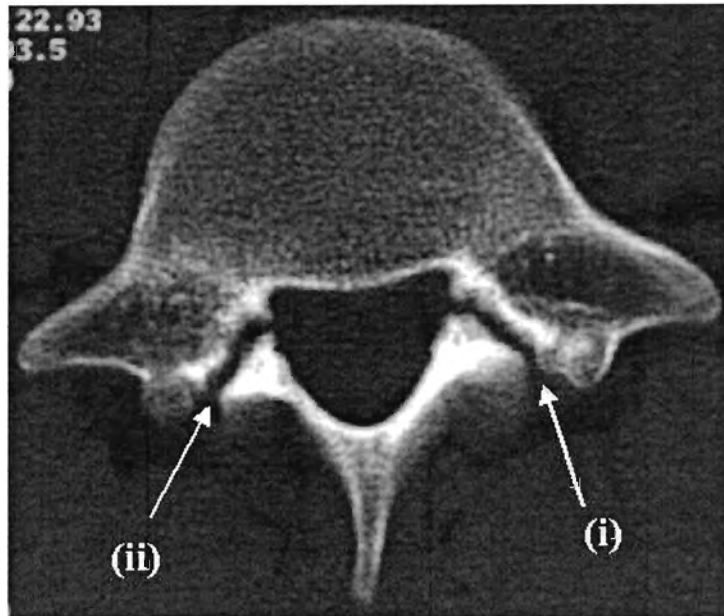


Fig.9. A CT scan of a 19-year-old left arm bowler taken 4 months after the first symptoms of pain in his lumbar spine. This showed an old lesion with non-bony union of the left pars interarticularis of the 5th lumbar vertebra. The right side shows a non-bony union of the pars interarticularis of the 5th lumbar vertebra.

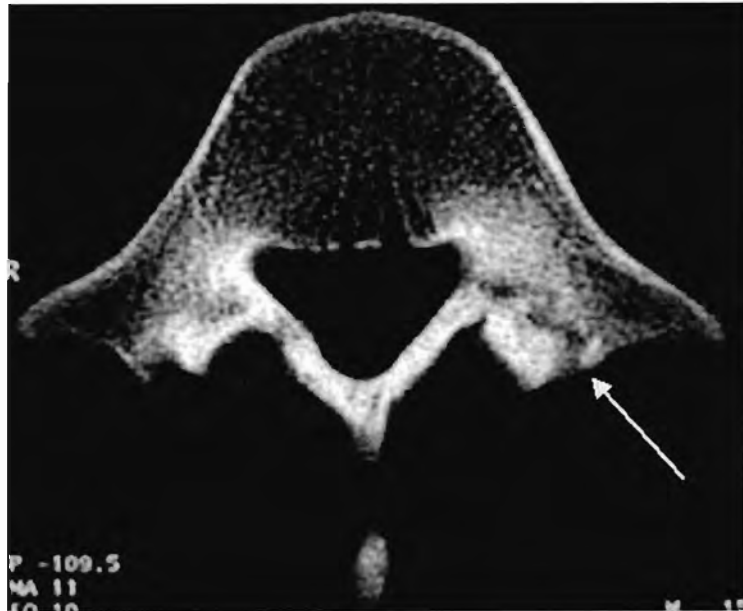


Fig. 10. A CT scan of this 17-year-old right arm bowler (subject 10) shows a healing fracture of the left pars interarticularis of the 5th lumbar vertebra.

Table 2: Summary of the 10 subjects.

Subject	Pain - severity and duration	Stage of CT scan	CT diagnosis	Time off bowling
1	4/10 for 2 weeks, 1/10 for 6 months	6 months 8 months 15 months	partially united and un-united fractures	15 months
2	3/10 for 3 weeks	3 months	partial union	6 months
3	3/10 for 1 week	immediately	multiple partial and un-united #s	3 months
4	3/10 intermittent with bowling only	3 months	partial healed and healed #	11 months
5	4/10 for 2 weeks	3 months	Thickening, but no #	3 months
6	5/10 for 2 weeks	3 months	Thickening, no #	6 months
7	5/10 for 2 weeks	2 years	healed	3 months
8	0/10	Approximately 3 years after starting at senior level	un-united #s	No time off
9	4.5/10 for 2-3 weeks	4 months	non-bony union of the left pars interarticularis of the 5 th lumbar vertebra	6 months
10	3/10 for 3 weeks	3 months	Partially healed fracture	3 months

Chapter 4

Summary and conclusion

The significance of spondylolysis of the pars interarticularis in the cricket fast bowler continues to be debatable. The association between these pathologies and back pain has been an inferred relationship in many studies as discussed in Chapter 2.

However, there are many unanswered questions for clinicians dealing with cricket fast bowlers, spondylolysis and back pain. In advising the injured fast bowler on return to fast bowling, the following questions are pertinent.

- Should pain be your guide?
- Is non-union of a pars interarticularis defect in the lumbar spine a problem?
- What is the clinical relevance of radiological investigations?

Should pain be your guide?

Many of the studies described in Chapter 2 which identified spondylolysis and spondylolisthesis in the lower back of the cricket fast bowler and other sports people have reached different conclusions regarding any direct link between this bony pathology and pain. This can be attributed to an inadequate reporting of symptoms, with no objective measurement of pain. As a result the source of the lower back pain is seldom clear.

The study described in Chapter 3 shows that there is a dissociation between pain and bone stress reaction as measured by Computerised Tomography (CT) scan. This raises the question of whether pain and/or radiological evidence from CT scan should

be used as a guide for the return of the cricketer to full participation in fast bowling. Both of these factors have been the main points of reference in the clinical setting in the past. It is clear that if pain exists, then the cricketer should not participate in the game or practice. However, based on the findings of this study, there is often no pain or minimal pain, even though there are pars interarticularis defects (with or without union) in the lumbar spine.

Thus confirmation is needed regarding the source of the pain and objective measures are needed regarding guidelines for return to bowling based on the pain.

Is non-union of a pars interarticularis defect in the lumbar spine a problem?

The aim of the study in Chapter 3 was to find an objective assessment to aid the clinician in managing a bone stress fracture in the fast bowler's back. Some fast bowlers experienced minimal or no pain but were kept out of bowling due to the ununited stress fracture of the pars interarticularis. Clinically the bowler would be allowed to play, but because of the radiological findings, participation was delayed for lengthy periods. There is often a discrepancy between radiological findings and clinical symptoms and further investigation is required to ascertain whether the non union is relevant or whether the bone stress reaction could be the body's adaptive response to the extraordinary stresses imposed by the biomechanics of fast bowling. Furthermore, it may be of genetic origin and not relevant to the current lower back pain experienced.

What is the clinical relevance of radiological investigations?

Many of the studies reported in Chapter 2, have been retrospective and the mode of investigation has not been consistent across the studies. The radiological investigations include Xrays, bone scintigraphy, CT scans or MRI. Every imaging method has particular strengths and weaknesses and the choice depends on the provisional diagnosis (Anderson et al., 1998; Moeller, 2001). Due to the different sensitivities of these modalities, the reporting of the incidence of pars interarticularis pathology can be inconsistent. Some of the pars defects were reported as stress fractures only, whilst others included sclerosis of the pars interarticularis. Few studies recorded whether the lesion was symptomatic or asymptomatic and whether the bone stress reaction was a developing lesion or healing reaction/fracture (Hollenburg et al., 2003).

A search in the literature for pain specificity and spondylolysis showed that there is a causative relationship between vigorous athletic activity, abnormal radiological features and low back pain (Fredrickson et al., 1984; Wiltse and Jackson, 1976; Sward, 1992). However, inconsistencies between radiographic interpretation and clinical observations does occur (Guillodo et al., 2000). In many of the studies described in Chapter 2, symptoms are vaguely described, with no objective pain measurement recorded (Ferguson et al., 1974; Newman and Stone, 1963; Pease, 1967; Sherman et al., 1977). Furthermore, specific details on the return to sport have not been described in any studies. No study has used a pain scale such as the Visual Analogue Scale (VAS) and related it to the stage of the spondylolysis, the pain intensity and the return to sport. Further, the relationship with the healing or

management of the bone stress reaction in the pars interarticularis has been poorly investigated (Lisbon et al., 1982; Saraste, 1986; Letts et al., 1986; Morita et al., 1995; Sys et al., 2001). The criteria have been based mostly on the stage of healing and specific pain intensity is not mentioned.

New radiological techniques are constantly being researched in order to gain a better understanding of a bone stress reaction in the posterior elements of the lumbar spine. It is most important for the clinician to investigate the technique that will give a clear understanding of the exact status of the bone stress reaction and thus have a better understanding of the management thereof.

In conclusion, a guideline for practitioners dealing with bone stress injury in the lumbar spine of fast bowlers is presented in Figure 11. A suggestion of a possible sequence of radiological investigation is proposed. Further motivation for use of these guidelines is presented in Table 3.

Thus in this thesis, only one question was investigated and many left unanswered. It is important to note that the frequent detection of structural abnormalities that are real but clinically irrelevant, occurs frequently in the instance of pars interarticularis stress fractures in the lower back of the cricket fast bowler. In many instances, union of the bone is the main priority of management with little concern for specific clinical symptoms (Fredrickson et al., 1984; Sys et al., 2001). The clinician working with cricketers need definite guidelines regarding the disability of the bowler's painful back, the source of the pain and the management thereof. Further clinically controlled prospective studies using the optimum imaging on cricket fast bowlers with this

pathology need to be undertaken. These studies need to relate the radiological findings to the symptoms experienced by the bowler, to determine whether the spondylolysis is, in fact, the cause of the pain. Future research needs to determine other causes of back pain in order to establish a working diagnosis so that appropriate management may be prescribed. This information would contribute to a better understanding of the aetiology of low back pain in cricket fast bowlers, and would contribute to a more evidence-based approach when clinical decisions are made about the management of the injury.

University of Cape Town

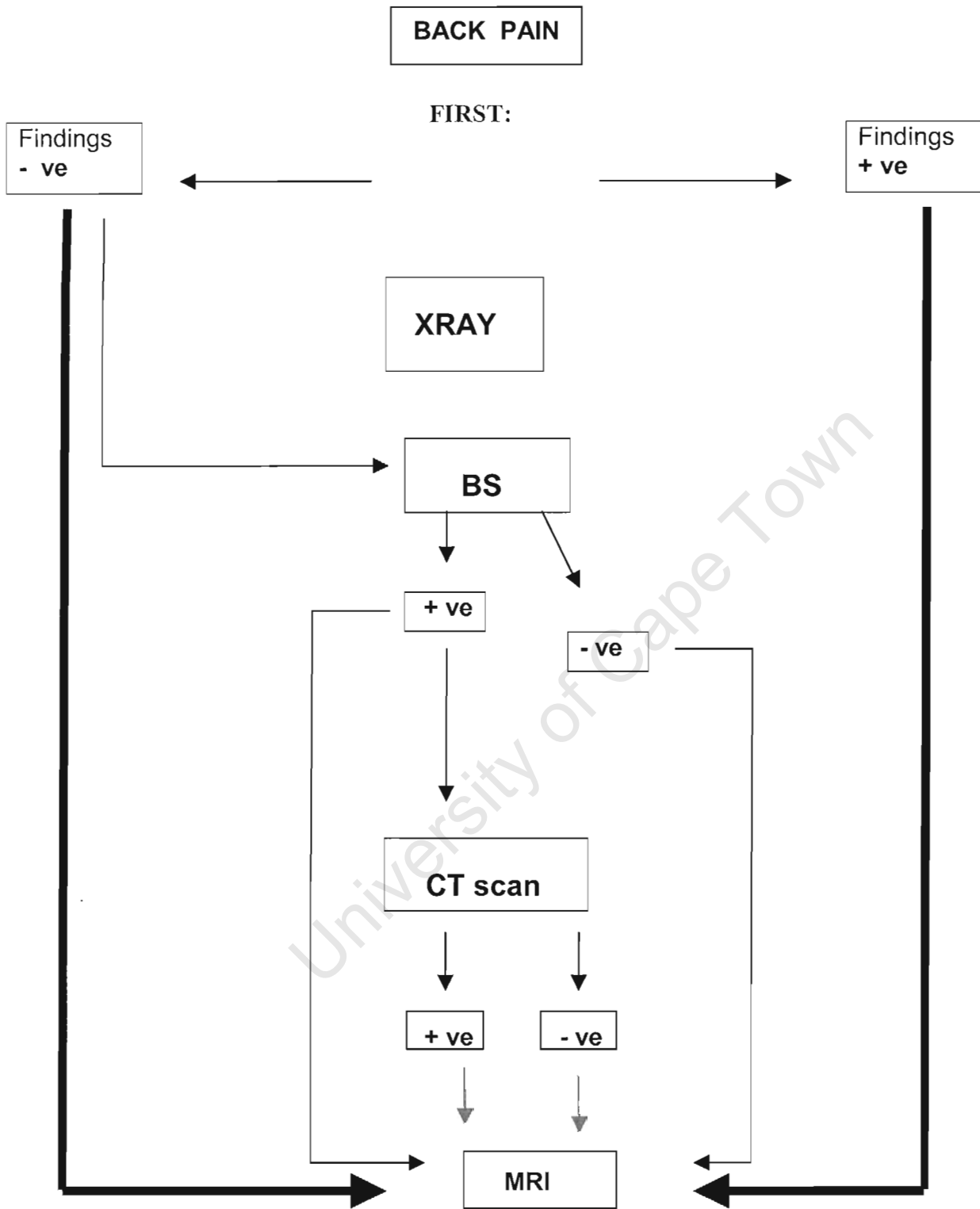


Figure 11: Low back pain in cricket fast bowlers: Radiological investigation.

Table 3: Guidelines for radiological investigation of fast bowlers with possible bone stress injury

Investigation	Reason	Result	Action	Reason
1. XRAY	Exclude other conditions e.g. TB, tumour etc Look for spondylolysis and spondylolisthesis, disc narrowing.	Positive	MRI	Bone marrow oedema
		Negative	BS	If unsure of source of pain. Shows a larger area than MRI. BS sensitive, non-specific vs MRI that is sensitive and specific.
			MRI	If sure of source of pain i.e. lumbar / thoracic spine / hip. Will see stress injury, disc protrusion, Schmorl node, infection, facet joint. Very anatomic specific diagnosis.
2. BS	Shows any bony definition metabolism	Positive	CT	Cortical bone
			MRI	Bone marrow oedema. Further bone information about abnormal area.
		Negative	MRI	Exclude other pathologies.
3. CT scan	Cortical bone definition	Positive	MRI	Bone marrow oedema. Further bone information about abnormal area
		Negative	MRI	Exclude other pathologies
4. MRI	<ul style="list-style-type: none"> - To see the present state of bone pathology. Will show fracture line, periosteal reaction, sclerosis of healing fracture etc. - To exclude other conditions 			

References

REFERENCES

Albanse M, Pizzutillo PD: Family study of spondylolysis and spondylolisthesis. *J Paediatr Orthop* 1982; 2:496-499.

Amato M, Totty WG, Gilula LA. Spondylolysis of the lumbar spine: Demonstration of defects and laminal fragmentation. *Radiology* 1984; 153: 627-9.

Anderson K, Sarwark JF, Conway JJ, et al. Quantitative assessment with SPECT imaging of stress injuries of the pars interarticularis and response to bracing. *J Pediatr Orthop* 2000; 20(1): 28-33.

Anderson I, Read J, Steinweg J. *Atlas of Imaging in Sports Medicine, Australia: McGraw-Hill*; 1998; 1- 6, 317-320, 355-358.

Annear PT, Chakera TMH, Foster DH, et al. Pars Interarticularis stress and disc degeneration in cricket's potent strike force: the fast bowler. *Aust N Z J Surg* 1992; 62 (10):768-773.

Beattie PF, Meyers SP, Stratford P, et al. Associations between patient report of symptoms and anatomic impairment visible on magnetic resonance imaging. *Spine* 2000; 25:819-828.

Biering-Sorenson F, Hansen FR, Schroll M, et al. The relation of spinal Xray to low back pain and physical activity among 60-year old men and women. *Spine* 1985; 10: 445-51.

Blackburne J. Spondylolisthesis in sportsman. *J.R. Coll. Surg. Edinb.* 34(suppl.), 1989; 12-14.

Boden SD, Davis DO, Dina TS, et al. Abnormal magnetic resonance scans of the lumbar spine in asymptomatic subjects. *J Bone Joint Surg* 1990; 72A(3): 403-408.

Bogduk N. The innervation of the lumbar spine. *Spine* 1983; 8:286-293.

Bogduk N. Low back pain. *Aust Fam Physician* 1985; 14:1168-1171.

Burnett AF, Khangure MS, Elliott BS, et al. Thoracolumbar disc degeneration in young fast bowlers in cricket: a follow-up study. *Clin Biomech* 1996; 11: 305-310.

Campbell RS, Grainger AJ. Optimization of MRI pulse sequences to visualise the normal pars interarticularis. *Clin Radiol* 1999; 54:63-68.

Ciullo JV, Jackson DW. Pars interarticularis stress reaction, spondylolysis, and spondylolisthesis in gymnasts. *Clin Sports Med* 1985;4(1):95-110.

Collier BD, Johnson RP, Carrera GF, Meyer GA, Schwab JP, Flatley TJ et al. Painful spondylolysis or spondylolisthesis studied by radiography and single photo emission computed tomography. *Radiology* 1985; 154:207-211.

Commandre FA, Taillan B, Gagnerie F, Zakarian H, Lescourgues M, Fourre JM. Spondylolysis and spondylolisthesis in young athletes: 28 cases. *J Sports Med Phys Fitness* 1988; 28:104-107.

Congeni J, McCulloch J, Swanson K. Lumbar spondylolysis. A study of natural progression in athletes. *Am J Sports Med* 1997; 25:248-253.

Connelly SA, Connelly LP, Jaramillo D: Imaging of Sports injuries in children and adolescents [review]. *Radiol Clin North Am* 2001; 39:773-790.

Corrigan A. Cricket Injuries. *Aust Fam Physician* 1984; 13:No 8.

Cyron BM, Hutton WC. The fatigue strength of the lumbar neural arch in spondylolysis. *J Bone Joint Surg Br* 1978; 60-B(2):234-238.

Cyron BM, Hutton WC. Variations in the Amount and Distribution of Cortical Bone across the Partes Interarticulares of L5. A Predisposing Factor in Spondylolysis? *Spine* 1979; 4:2:163-167.

D'Hemecourt PA, Zurakowski D, Kriemler S, et al. Spondylolysis: returning the athlete to sports participation with brace treatment. *Orthopaedics* 2002; 25(6):653-7.

Debnath UK, Freeman BJ, Gregory P, et al. Clinical outcome and return to sport after the surgical treatment of spondylolysis in young athletes. *J Bone Joint Surg Br* 2003; 85(2):244-9.

Dennis R, Farhart R, Goumas C, Orchard J. Bowling workload and the risk of injury in elite fast bowlers. *J Sci Med Sport* 2003; 6(3):359-67.

Dutton JA, Hughes SP, Peters AM. SPECT in the management of patients with back pain and spondylolysis. *Clin Nucl Med* 2000;25(2):93-6.

Elliott BC, Foster D. A biomechanical analysis of the front on and side on bowling techniques. *J Hum Mov Studies* 1984;10:83-94.

Elliott BC, Foster DH, Gray S. Biomechanical and physical factors influencing fast bowling. *Aust J Sci Med Sport* 1986; 18(1):16-21.

Elliott S, Hutson MA, Wastie ML. Bone scintigraphy in the assessment of spondylolysis in patients attending a sports injury clinic. *Clin Radiol* 1988; 39:269-272.

Elliott BC, Foster D, Blanksby BA. Send the stumps flying: the science of fast bowling. *Nedlands: University of WA Press* 1989.

Elliott BC, Foster D, John D. Side on and front on bowling in cricket. *Sports Coach* 1990; 13(2):8-11.

Elliott B, Hardcastle P, Burnett B, et al. The influence of fast bowling and physical factors on radiological features in high performance young fast bowlers. *J Sports Med Training and Rehab* 1992; 3:113-130.

Elliott B, Davis J, Khangure M, et al. Disc degeneration and the young fast bowler in cricket. *Clin Biomech* 1993; 8: No 5:227-234.

Elliott BC. Back injuries and the fast bowler in cricket. *J Sports Sci* 2000; 18: 983-991.

Elliott BC, Khangure M. Disk degeneration and fast bowling in cricket: an intervention study. *J Med Sci Sports Exerc* 2002; 24:11:1714-1718.

Evans W, Seibert C. A cross section prevalence study of lumbar disc degeneration in a working population. *Spine* 1989; 9(57):54-57.

Fehlandt AF Jr., Micheli LJ. Lumbar facet stress fracture in a ballet dancer. *Spine* 1993; 18(16):2537-2539.

Ferguson RJ, McMasters MC, Stanitski CL. Low back pain in college school linemen. *J Sports Med* 1975; 2:63-69.

Finch C., Elliott B and McGrath A. Overview of measures to prevent cricket injuries. *Sports Med* 1999; 28:263-272.

Fitch K. Spondylolysis in fast bowlers- induced by heredity or stress. *In Abstracts of the Australian Conference of Science and Medicine in Sport. Adelaide: Sport Medicine Australia* 1987; 32.

Foster D, John D, Elliott B, et al. Back injuries to fast bowlers in cricket: a prospective study. *Br J Sports Med* 1989; 23(3):150-154.

Fredrickson B, Baker D, McHolick WJ, et al. The natural history of spondylolisthesis and spondylolysis. *J Bone and Joint Surg Am* 1984; 66-(5):699-707.

Goldberg MJ. Gymnastic injuries. *Orthop Clin North America* 1980; 11:717-726.

Granhed H, Morelli B. Low back pain among retired wrestlers and heavyweight lifters. *Am J Sports Med* 1988; 16(5):530-533.

Guillodo Y, Botton E, Saraux A et al. Contralateral spondylolysis and fracture of the lumbar pedicle in an elite female gymnast. *Spine* 2000; 25:19:2541-2543.

Gunzburg R, Fraser RD. Stress fracture of the lumbar pedicle. Case reports of "pediculolysis" and review of the literature. *Spine* 1991; 16(2):185-189.

Halvorsen TM, Nilsson S, Naksted PH. Stress fractures: Spondylolysis and spondylolisthesis of the lumbar vertebrae among young athletes with back pain. *Tidsskr Nor Laegeforen* 1996; 116-117.

Hardcastle P. Lumbar pain in fast bowlers. *Aust Fam Physician* 1991; 20(7):943, 946-951.

Hardcastle P, Annear P, Foster DH, et al. Spinal abnormalities in young fast bowlers. *J Bone Joint Surg Br* 1992; 74:421-425.

Hardcastle P. Repair of spondylolysis in young fast bowlers. *J Bone Joint Surg Br* 1993; 75(3):398-402.

Harvey CJ, Richenburg JL, Saifuddin A, et al. Pictorial Review: The radiological investigation of lumbar spondylolysis. *Clin Radiol* 1998; 53(10):723-728.

Hensinger, R.N. Spondylolysis and spondylolisthesis in children. In *Instructural Course Lectures, The American Academy of Orthopaedic Surgeons* 1983; Vol. 32: 132-151. *St Louis C.V. Mosby*.

Hensinger RN, Arbor A. Spondylolysis and Spondylolisthesis in children and adolescents. *J Bone Joint Surg Am* 1989; 71(7):1098-1107.

Hollenberg GM, Beattie PF, Meyers SP, et al. Stress Reactions of the Lumbar Pars Interarticularis: the development of a new MRI classification system. *Spine* 2002; 27: 181-186.

Hollenberg GM, Beitia AO, Tan RK, Weinberg EP, Adams MJ. Imaging of the spine in sports medicine. *Curr Sports Med Rep* 2003; 2(1):33-40.

Itoh K, Hashimoto T, Shigenobu K et al. Bone SPECT of symptomatic lumbar spondylolysis. *Nucl Med Commun* 1996;17(8):732-734.

Ivanic GM, Pink TP, Achatz W, et al. Direct stabilisation of lumbar spondylolysis with a hook screw: mean 11 year follow up period for 113 patients. *Spine* 2003; 28(3):255-259.

Jackson DW, Wiltse LL, Cirincione RL. Spondylolisthesis in the female gymnast. *Clin Orthop* 1976; (117):68-73.

Jackson DW. Low Back pain in young athletes: Evaluation of Stress reaction and discogenic problems. *Am J Sports Med* 1979; 7:364-366.

Jackson DW, Wiltse LL, Dingeman RD et al. Stress reactions involving the pars interarticularis in young athletes. *Am J Sports Med* 1981;9(5):304-312.

Jinkins JR, Mathes JC, Sener RN. Spondylolysis, spondylolisthesis, and associated nerve root entrapment in the lumbosacral spine: MR evaluation. *AJR Am J Roentgenol* 1992; 159:799-803.

Karpakka J, Takala T, Orava S. The long term consequences of spondylolysis or spondylolisthesis on athletic activities. *Clin Sports Med* 1989; (1):89-93.

Kippers V, Engstrom C, Walker D, et al. Physical maturation of elite junior fast bowlers in Queensland. *In Abstracts of the Australian Conference of Science and Medicine in Sport* 1998; 106. Adelaide: Sports Medicine Australia.

Laurent L, Emola S. Spondylolisthesis in children and adolescents. *Acta Orthop Scand* 1961; 31:445.

Letts M, Smallman T, Afanasiev R et al. Fractures of the Pars in Adolescent Athletes: A Clinical Biomechanical Analysis. *J Pediatr Orthop* 1986; 6:40-46.

Lisbon E, Bloom RA, and Dinari G. Symptomatic and asymptomatic spondylolysis and spondylolisthesis in young adults. *Int Orthop* 1982; 6:259-261.

Lisbon E, Bloom RA, Dinari G and Robin GC. Oblique lumbar spine radiographs: importance in young patients. *Radiology* 1984; 151(1):89-90.

Locke S and Allen G D. Etiology of low back pain in elite boardsailors. *Med Sci Sports Exerc* 1992; 964-966.

Lowe J, Schachner E, Hirschberg E, et al. Significance of Bone scintigraphy in symptomatic spondylolysis. *Spine* 1984; 9:653-655.

Lusins JO, Elting JJ, Cicoria AD, Goldsmith SJ. SPECT evaluation of lumbar spondylolysis and spondylolisthesis. *Spine* 1994; 19(5):608-612.

Mackay G. and Keech MA. Lumbosacral screening and prevention programme for junior elite male fast bowlers. In: Torode M. (Ed.), *The Athlete Maximising Participation and Minimising Risk: Proceedings of the 25th Australian Sports Medicine Federation Conference, Sydney October 1988*; 13-18.

Magora A and Schwartz A. Relation between the low back pain syndrome and Xray findings. *Scand J Rehab Med* 1976; 8:115-125.

Mason BR, Weissensteiner JR, Spence PR. Development of a model for fast bowling in cricket. *Excel* 1989; 6:2-12.

McAfee PC, and Yuan HA. Computed tomography in spondylolisthesis. *Clin Orthop* 1982; 166:62-71.

- McCarrol JR, Miller JM, Ritter MA. Lumbar spondylolysis and spondylolisthesis in college football players. A prospective study. *Am J Sports Med* 1986; 14:404-406.
- Meredith WJ, Massey B. *Fundamental Physics of Radiology* 3rd Ed, 1977. Stonebridge Press, Bristol, UK, 1977; 629 –642.
- Micheli LJ. Low back pain in Adolescent: Differential Diagnosis. *Am J Sports Med* 1979; 7:362-364.
- Micheli LJ. Back Injuries in Gymnastics. *Clin Sports Med* 1985; 4(1):85-93.
- Micheli LJ, Wood R. Back pain in young athletes: significant differences from adults in causes and patterns. *Arch Pediatr Adolesc Med* 1995; 149:15-18.
- Moe JH, Winter RB, Bradford DS, et al. Scoliosis and Other Spinal Deformities. Philadelphia, WB Saunders 1978.
- Moeller JL. Spondylolysis in Active Adolescents. *The Physician and Sports* 2001; Vol 29:12:1-7.
- Moreland M. Special concerns of the pediatric athlete. In *Sports Injuries (edited by F. Fu and D Stone)* Sydney, NSW: Williams and Wilkins. 1994; 135-152.
- Morita T, Ikata T, Katch S, et al. Lumbar spondylosis in children and adolescents. *J Bone Joint Surg Br* 1995; 77(4):620-625.
- Nathan H. Spondylolysis. *J Bone Joint Surg Am* 1977; 59:869-874.
- Newman PH, Stone KH. The Etiology of Spondylolisthesis. *J Bone Joint Surg Br* 1963; 45:39.
- Nozawa S, Shimizu K, Miyamoto K, Tanaka M. Repair of pars interarticularis defect by segmental wire fixation in young athletes with spondylolysis. *Am J Sports Med* 2003; 31(3):359-364.

O'Neill DB, Micheli LJ. Postoperative radiographic evidence for fatigue fracture as the aetiology in spondylolysis. *Spine* 1989; 14(12):1342-1355.

Ogilvie JW, Sherman J. Spondylolysis in Scheuermann's disease. *Spine* 1987;12:251-253.

Ohashi K, Brandser EA, El-Khoury GY. Role of MR imaging in acute injuries to the appendicular skeleton. *Radiol Clin North Am* 1997; 35:591-613.

Ong A, Anderson J, Roche J. A pilot study of the prevalence of lumbar disc degeneration in elite athletes with lower back pain at the Sydney 2000 Olympic Games. *Br J Sports Med* 2003; 37(3):263-266.

O'Sullivan PB. Lumbar segmental "instability": clinical presentation and specific stabilizing exercise management. *Man Ther* 2000; 5(1):2 – 12.

Paajanen H, Erkintalo M, Kuusela T et al. Magnetic resonance study of disc degeneration in young low back pain patients. *Spine* 1989; 14:982-985.

Papanicolaou N, Wilkinson RH, Emans JB, et al. Bone scintigraphy and Radiography in Young Athletes with low back pain. *Am J Roentgenol* 1985; 145:1039-1044.

Payne WR, Joy G. and Carison JS. What research tells the cricket coach. *Sports Coach* 1987; 10(4):17-22.

Pease CN, Najat H: Spondylolisthesis in children. *Clin Orthop* 1967; 52:187-198.

Penning L, and Blickman, JR. Instability in lumbar spondylolisthesis: A radiologic study of several concepts. *Am J Roentgenol* 1980; 134:293-301.

Porter RW, and Park W. Unilateral Spondylolysis. *J Bone Joint Surg* 1982; 344-348.

Prather JL, Nusynowitz ML, Snowdy HA et al. Scintigraphic findings in stress fractures. *J Bone Joint Surg Am* 1977; 59:869-874.

Raby N, Mathews S. Symptomatic spondylolysis: Correlation of CT and SPECT with clinical outcome. *Clin Radiol* 1993; 48:97-99.

Ralston S, Weir M. Suspecting lumbar spondylolysis in adolescent low back pain. *Clin Paediat* 1998; 37:287-293.

Resnick D. *Diagnosis of Bone and Joint Disorders*. WB Saunders Co, Philadelphia 1988; 1539-1543.

Rossi F. Spondylolysis, spondylolisthesis and sports. *J Sports Med and Phys Fitness* 1988; 18:317-340.

Rossi F, Dragoni S. Lumbar spondylolysis occurrence in competitive athletes. Update achievements in a series of 390 cases. *J Sports Med* 1990; 450-452.

Rossi F, Dragoni S. The prevalence of spondylolysis and spondylolisthesis in symptomatic elite athletes: radiographic findings. *Radiography* 2001;7:37-42.

Rothman SLG, Glenn WJ Jr. Multiplanar Reconstruction in 253 cases of lumbar spondylolysis. *Am J Neuroradiol* 1984; 5:81-90.

Rothman SLG. Computed Tomography of the spine in older children and teenagers. *Clin Sports Med* 1986; 2:247-270.

Rowe GG, Roche MB. The etiology of separate neural arch. *J Bone Joint Surg* 1953; 35-A; 102-110.

Ruggieri P. Pulse sequences in lumbar spine imaging. *Magn Reson Imaging Clin North Am* 1999; 7:425-437.

Saha MM, Bhardwaj OP, Srivastava G, et al. Osteoporosis with spondylolisthesis: 4 cases in 1 family. *Br J Radiol* 1970; 43:738-740.

Saifuddin A, Burnett SJ. The value of lumbar spine MRI in the assessment of the pars interarticularis. *Clin Radiol* 1997; 52:666-671.

Sandrick K. Spinal imaging spots fractures in youth. *Sports Imaging* 2000; 17- 19.

Saraste H. Symptoms in relation to the level of spondylolysis. *Internat Orthop* 1986; 10 (3):183-185.

Semen RL, and Spengler D. Significance of lumbar spondylolysis in college football players. *Spine* 1981; 6(2):172-174.

Serge HR, De Luca CJ, Snyder-Mackler L, et al. Fatigue, recovery, and low back pain in varsity rowers. *Med Sci Sports Exerc* 1989; 463-469.

Sherman, FC, Wilkinson RH, and Hall JE. Reactive Sclerosis of a pedicle and spondylolysis in the lumbar spine. *J. Bone Joint Surg* 1977; 59-A:49-54.

Sherman, FC, Rosenthal RK, and Hall, JE. Spine Fusion for Spondylolysis and Spondylolisthesis in Children. *Spine* 1979; 4:59-67.

Shiple JA, Beukes CA. The nature of the spondylolytic defect. Demonstration of a communicating synovial pseudarthrosis in the pars interarticularis. *J Bone Joint Surg Br* 1998; 80(4):662-664.

Simper LB, Spondylolysis in Eskimo Skeletons. *Acta Orthop Scandanavica* 1986; 57: 78-80.

Soler T, Calderon C. The prevalence of spondylolysis in the Spanish Elite athlete. *Am J of Sports Med* 2000; 28(1):57-62.

Stabler A, Paulus R, Steinborn M, et al. Spondylolysis in the developmental stage: diagnostic contribution of MRI. *Rofo Fortschr Geb Röntgenstr Neuen Bildgeb Verfahr* 2000; 172(1):33-37.

Standaert CJ, Herring SA. Spondylolysis: a critical review. *Br J Sports Med* 2000; 34(6):415-422.

Steiner ME and Micheli LJ. Treatment of Symptomatic Spondylolysis and Spondylolisthesis with the modified Boston Brace. *Spine* 1985; 10:937-943.

Stewart TD. The age incidence of neural arch defects in Alaskan natives, considered from the standpoint of etiology. *J Bone Joint Surg* 1953; 35-A:937-950.

Stretch RA. Injuries to South African cricketers playing at first class level. *SA Sports Med* 1989; 4 (1):3-20.

Stretch RA. The incidence and nature of injuries in club and provincial cricketers. *S Afr Med J* 1993; 83: 339-341.

Sward L, Hellstrom M, Jacobsson B, et al. Back pain and radiological changes in the thoraco-lumbar spine in athletes. *Spine* 1990; 15(2):124-129.

Sward L, Hellstrom M, Jacobsson B, et al. Disc degeneration and associated abnormalities of the spine in elite gymnasts. A magnetic resonance imaging study. *Spine* 1991; 16(4):437-443.

Sward L. The thoracolumbar spine in young elite athletes: current concepts on the effects of physical training. *Sports Med* 1992; 13(5):357-364.

Sys J, Michielson J, Bracke P, et al. Non-operative treatment of active spondylolysis in elite athletes with normal Xray findings: literature review and results of conservative treatment. *Eur Spine J* 2001; 10(6):498-504.

Teplick JG, Laffey PA, Berman A, et al. Diagnosis and evaluation of spondylolisthesis and/or spondylolysis on axial CT. *Am J Neuroradiol* 1986; 7:479-491.

Tertti M, Paajanen H, Laato M et al. Disc degeneration in magnetic resonance imaging: a comparative biomechanical, histologic, and radiologic study in cadaver spines. *Spine* 1991A; 16:629-634.

Torgerson WR, Dotter WE. Comparative roentgenographic study of the asymptomatic and symptomatic lumbar spine. *J Bone Joint Surg* 1976; 58-A:850-853.

Troup JDG. Mechanical Factors in spondylolisthesis and spondylolysis. *Clin Orthop* 1976; 147:59-67.

Udeshi UL, Reeves D. Routine thin slice MRI effectively demonstrates the lumbar pars interarticularis. *Clin Radiol* 1999; 54(9):615-619.

Van der Oever M, Merrick MV, Scott JHS. Bone scintigraphy in symptomatic spondylolysis. *J Bone J Surg Br* 1987; 69:453-456.

Vidlik A. Properties of tendons and ligaments. In *Handbook of Bioengineering*, edited by R. Skalak and S. Chien New York: McGraw-Hill. 1987; 6.1-6.19.

Walker D., Engstrom C, Wallace R, et al. MRI of the Spine in Junior Cricket Fast Bowlers. *Consultant Radiologist Dept Radiological Sciences, The Royal Brisbane Hospital* 1996; 350-351.

Weir MR, Smith DS. Stress reaction of the pars interarticularis leading to spondylolysis. A cause of adolescent low back pain. *J Adolesc Health Care* 1989; 10 (6):573-577.

Whiting C, and Zernicke R. *Biomechanics of Musculo skeletal Injury*. Champaign, IL: Human Kinetics 1988.

Wiltse LL. The Etiology of spondylolisthesis. *Clin Orthop* 1957; Vol. 44A:No 3:10:48-53.

Wiltse LL. The etiology of spondylolisthesis. *J Bone Joint Surg* 1962; 44(3):539-560.

Wiltse LL, Widell EH, Jackson DW. Fatigue fracture: the basic lesion in isthmic spondylolisthesis. *J Bone Joint Surg Am* 1975; 57:17-22.

Wiltse LL, Newman PH, Macnab I. Classification of spondylolysis and spondylolisthesis. *Clin Orthop* 1976; 117:23-29.

Wiltse LL, Jackson DW. Treatment of Spondylolisthesis and spondylolysis in children. *Clin Orthop* 1976; 117:92-100.

Wirtz DC, Wildberger JE, Rohrig H, et al. Early diagnosis in isthmic spondylolysis with MRI. *Z Orthop Ihre Grenzgeb* 1999; 137(6):508-511.

Witt T, Vestergaard A, Rosenkilt A. A comparative analysis of Xray findings of the lumbar spine in patients with and without lumbar pain. *Spine* 1984; 9:298-300.

Wu SS, Lee CH, Chen PQ. Operative repair of symptomatic spondylolysis following a positive response to diagnostic pars injection. *J Spinal Disord* 1999; 12(1):10-16.

Wynne Davies R, Scott JHS. Inheritance and Spondylolisthesis. A radiographic family survey. *J Bone Joint Surg* 1979; 61-B(3):301-305.

Yochum TR, Rowe LJ. The Natural History of Spondylolysis and Spondylolisthesis. *Essentials of Skeletal Radiology. Williams and Wilkins, Baltimore, USA. ISBN 0-683-09329-0* 1987; Chap 5;1.

Appendices

	Page
Appendix A. Ethics letter.....	101
Appendix B. 2 x Informed consent	103

University of Cape Town

APPENDIX A

University of Cape Town



23 April 2002

REC REF: 048/2002

Ms. H. Millson
C/o Mrs.J. Gray
Human Biology

Dear. Ms Millson

STRESS FRACTURES AND LOWER BACK PAIN IN CRICKET BOWLERS

Thank you for submitting your study to the Research Ethics Committee for review.

It is a pleasure to inform you that the Committee has formally approved your study.

Please quote the above Rec. reference number in all correspondence

Yours sincerely

A handwritten signature in black ink, appearing to read 'Cr. Swanepoel'.

A/PROFESSOR. CR SWANEPOEL
CHAIRPERSON

APPENDIX B

University of Cape Town

MRC/UCT RESEARCH UNIT FOR EXERCISE SCIENCE AND SPORTS MEDICINE.
DIVISION OF PHYSIOTHERAPY, FACULTY OF HEALTH SCIENCES, UNIVERSITY
OF CAPE TOWN

INFORMED CONSENT FORM

Dear Volunteer

The MRC/UCT Research Unit for Exercise Science and Sports Medicine and Division of Physiotherapy, Faculty of Health Sciences will be conducting a clinical trial study to determine if there is an association between muscle pain and bone stress reaction as measured by Computed Tomography (CT) scan in young cricket fast bowlers. The practical application of this study is to develop objective criteria to assess the bowler's ability to return to full participation.

The clinical trial will involve the following:

On presenting at the physiotherapy practice with a suspected stress fracture of the lumbar spine, you will have the accepted investigations to determine the diagnosis:

- The conventional subjective and objective clinical examination.
- An X-ray.
- An Isotope bone scan to investigate any bone stress reaction.
- A CT Scan to measure any cortical bone damage.

I confirm that the nature, purpose, testing procedures, and the likely duration of the clinical trial study have been fully explained to me. I understand that I may ask questions at any time during the testing procedures. I realise that I am free to withdraw from the study without prejudice at any time, should I choose to do so. I have been informed that the personal information required by the Researchers will be held in strict confidentiality. In addition, I know that the information derived from the testing procedures will remain confidential and will be revealed only as a number in statistical analyses. I understand that this study has been reviewed by the Ethics and Research Committee of the University of Cape Town Medical School.

I have carefully read this form. I understand the nature, purpose and the procedure of this study. I agree to participate in this clinical trial study of the MRC/UCT Faculty of Health Sciences, Department of Physiotherapy, University of Cape Town.

Name (in full) of volunteer : _____

Signature of volunteer : _____

Name (in full) of witness : _____

Signature of witness : _____

Date : _____

IZIKO LE MRC/UCT ELIPHANDA NGENZULULWAZI YOKUZILOLONGA KWAKUNYE NAMACHIZA EZEMIDLALO. ICANDELO LE PHYSIOTHERAPY, KWIHLELO LENZULULWAZI YEZEMPILO, KWIDYUNIVESITHI YASE-CAPE TOWN (UCT).

IFOMU YOKUVUMA UKUTHATHA INXAXHEBA NGOKUZITHANDELA

Volontiya elithandekayo

Eli ziko likhankanywe ngentla liceba ukuqhuba uvavanyo oluphonononga unxulumano phakathi kweentlungu zesihlunu (muscle) nokuqobeka kwethambo elichaphazelekayo ngokomlinganiselo wobuchwephesha be-computer obaziwa njenge-Computed Tomography (CT) kubajuli ngokukhawuleza (fast bowlers) be bhola yeqakamba. Eyona njongo iphuhlileyo yolu phando kukuqulunqa amabakala omlinganeselo acacileyo okuvavanya ukulunga kwe-bowler ukubuyela emdlalweni ngokupheleleyo.

Olu phando luyakugxila koku kulandelayo:

Xa uhambela umzi we-physiotherapy ukrokrela uxinzelelo nokukrazuka komchachazo womqolo (lumbar spine), uyakuvavanywa ngezindlela zaziwayo zine ukuze baziwe ubunzulu bomonakalo:

.uvavanyo oluqhelekileyo olu banzi.

.i-x-ray

.ubuchule obubizwa 'isotope bone scan' bethambo nobuphonononga lo monakalo.

...I-CT scan yokulinganisela umonakalo wethambo i-cortic.

Ndiyavuma ukuba uhlobo, injongo, neendlela zovavanyo, kwakunye nethuba elithelekelelwayo loluphando zonke zichaziwe kum. Ndiyaqonda ukuba ndikhululelwe ukubuza ndakungaqondi nangaliphi na ithuba lophando. Ndicacelwe kukuba ndingakuphelisa nanini na ndithanda ukuthatha inxaxheba kolu phando yaye akukho sithintelo koko. Ndichazelwe ukuba ezincukacha zobume bam zithe zafunwa ngabaphandi 'researchers' azisayi kuthiwa pahaha nakubani na ongomnye. Ngaphezulu, ndiyazi ukuba ezi ncukacha zivela kolo phando ziyakuhlala ziyimfihlo yaye ziyakuvezwa kuphela njengamanani xa kucukucezwa iziphumo ngokwamanani. Ndiyaqonda ukuba esi sifundo, olu phando, lufunyaniswe lamkelekile ngabesikolo esijongene noko sale-Dyunivesithi.

Ndiyifunde ngonophelo le-fomu. Ndiyaluqonda uhlobo, injongo kunye nenkqubo yesi sifundo. Ndiyavuma ukuthatha inxaxheba kolu phando lwe MRC/UCT lwehlelo lwezenzululwazi yeZempilo, kwiSebe le-Physiotherapy, kwiDyunivesithi I-UCT.

Igama levolontiya ngokupheleleyo:

Intsayino yevolontiya:

Igama lengqina ngokuzeleyo:

Intsayino yengqina:

Date:

University of Cape Town