



**Master of Medicine (MMed) in  
Plastic and Reconstructive Surgery**

**Submitted to:**

**University of Cape Town  
Faculty of Health Sciences**

**THE ROLE OF PROPRANOLOL IN THE TREATMENT OF  
INFANTILE HAEMANGIOMA**

**Submitted by:**

**Sean Thirumalay Moodley**

**Student number: MTHTHI001**

**Supervisor:**

**Professor Donald Anthony Hudson**

**November 2013**

The copyright of this thesis vests in the author. No quotation from it or information derived from it is to be published without full acknowledgement of the source. The thesis is to be used for private study or non-commercial research purposes only.

Published by the University of Cape Town (UCT) in terms of the non-exclusive license granted to UCT by the author.

## DECLARATION

I, Dr Sean Thirumalay Moodley, hereby declare that the work, on which this dissertation/thesis is based, is my original work (except where acknowledgements indicate otherwise) and that neither the whole work nor any part of it has been, is being, or is to be submitted for another degree in this or any other university.

I empower the university to reproduce for the purpose of research either the whole or any portion of the contents in any manner whatsoever.

Signature: .....

Date:.....

## **CONTENTS OF DISSERTATION**

<b>1. Part A: Protocol</b>	<b>page 6</b>
<b>2. Part B: Structured Literature Review</b>	<b>page 12</b>
<b>3. Part C: Journal Article</b>	<b>page 27</b>
<b>4. Part D: Addendum</b>	<b>page 39</b>
<b>5. Part E : Glossary</b>	<b>page 42</b>

# THE ROLE OF PROPRANOLOL IN THE TREATMENT OF INFANTILE HAEMANGIOMA

There has been a change in the management of infantile haemangioma with the introduction of propranolol. The aim of this study is to retrospectively evaluate a simple treatment for infantile haemangioma at the Red Cross War Memorial Children's Hospital (RCWMCH) and document the results. While it is known that all haemangiomas undergo involution at some stage, some haemangiomas pose certain problems. These relate mainly to visual axis obstruction and aesthetics. Subjects are children in the first two years of life presenting with haemangiomas. All patients were treated with oral propranolol in conjunction with haemangioma size documentation, using a simple radiological modality, i.e. ultrasound imaging. Patients are followed up and clinical and radiological evaluations are undertaken to observe changes in size and appearance.

Propranolol is non-selective  $\beta$ -adrenergic antagonist that is used extensively for the treatment of a multitude of disorders, mainly cardiovascular indications. The main adverse effects include bradycardia, hypotension and bronchospasms.

For the purposes of this study, all subjects were routinely examined, especially with regard to the cardiopulmonary systems. Any perceived anomaly was referred to the cardiorespiratory physicians at RCWMCH for further evaluation, which includes all the necessary investigations such as electrocardiograms (ECG) and echocardiograms. Therefore, only fit healthy patients were selected for this study. Patients are educated and fully informed regarding the adverse effect profile of propranolol, and advised of the appropriate route of management.

The anticipated benefits:

- Decrease the proliferative phase of haemangioma growth and potentially limit its eventual size
- Accelerate the proliferative stage and therefore, rapidly decrease the size
  - improve visual axis/nasopharyngeal obstruction
  - improve the short- and long-term aesthetic outcomes thus, decreasing parental stress
  - alter the long-term sequelae of the involuted haemangioma changes
- Whilst the proliferative phase is usually over at one year, some children with large haemangiomas may still be in a growth pattern and thus still benefit from propranolol treatment

The anticipated result is whether this is indeed a simple cost-effective way of managing a relatively common disorder, while achieving the optimal functional and aesthetic outcome. It may also answer an important question: Should oral propranolol be the first-line treatment of all haemangiomas?

## 1. Part A: Protocol/Proposal

# THE ROLE OF ORAL PROPRANOLOL IN THE TREATMENT OF INFANTILE HAEMANGIOMA

### STUDY INVESTIGATOR(S):

**Principal Investigator:** Dr S.T. Moodley  
Email: dr.seanmoodley@gmail.com  
**Co-Investigator:** Professor D.A Hudson

Department of Plastic and Reconstructive Surgery  
University of Cape Town / Groote Schuur Hospital /  
Red Cross War Memorial Children's Hospital  
Observatory,  
7925

### a). INTRODUCTION

Haemangiomas are the most common childhood tumours affecting 5-10 per cent of infants. They produce both functional and cosmetic problems to those children affected. The head and neck is affected in up to 60 per cent of haemangiomas. These often prove to be problematic, causing visual axis obstruction, airway obstruction and ulceration.

### b) BACKGROUND

There are various treatment modalities available for the treatment of haemangiomas, but none that are simple, effective and predictable. The previously accepted *gold standard* was the use of systemic corticosteroids, which have limitations. The use of propranolol is increasing and is proving to be effective in reducing haemangioma growth size. However, no quantitative data exists regarding the change in dimension and clinical appearance of haemangiomas.

### **c) AIM(S) OF THE STUDY**

To retrospectively evaluate a simple treatment for infantile haemangioma.

### **d) OBJECTIVES**

The objective of this study was to determine if oral propranolol was effective in significantly decreasing the growth and size of haemangiomas during the proliferative phase.

### **e) HYPOTHESIS**

- **Primary Hypothesis**

Propranolol plays a significant role in the inhibition of haemangioma growth during the proliferative stage.

- **Secondary Hypothesis**

Propranolol influences the long-term sequelae of haemangiomas.

### **f) STUDY DESIGN**

This is a retrospective study evaluating the efficacy of oral propranolol in reducing the growth and the size of haemangiomas.

### **g) STUDY SETTING/LOCATION**

This is a single-centre study conducted at the Red Cross War Memorial Children's Hospital Plastic Surgery Outpatients Clinic.

## **h) STUDY POPULATION**

The target population was children less than 24 months of age presenting with haemangiomas at the Outpatient Plastic Surgery Department, who comply with the eligibility criteria.

## **i) ELIGIBILITY CRITERIA**

- Inclusion: All haemangiomas in fit, healthy children  
(male/female) less than 24 months of age
- Exclusion: Cardiovascular anomalies  
Lower respiratory tract infections  
Asthma  
Complicated haemangiomas requiring  
surgical/alternative medical therapy

## **j. STUDY OUTCOMES**

- **Primary Outcome**

The primary outcome was the evaluation of the change in size of the haemangioma in millimeters in response to oral propranolol administration. The size was measured via ultrasound and clinical examination.

- **Secondary Outcome(s)**

Treatment related side effects/adverse events

Poor response in some haemangiomas

Aesthetic outcome

## **k) STUDY PROCEDURES**

- A non-random selection of suitable patients was retrospectively recruited, following consultation and follow-up at the Plastic Surgery Outpatient Clinic over a two-year period.

- Patients have a confirmed haemangioma (clinical and radiological diagnosis).  
At the initial consultation, treatment regimens and alternatives are discussed with the parents, and verbal consent is acquired. (Propranolol is an accepted modality of haemangioma treatment). In addition, the adverse effects profile of propranolol is discussed with the parents.
- The expected number of subjects is approximately 30, with almost all predicted to conform to the treatment regimen.
- This was a retrospective study over a two year period.
- **Procedure:**
  - Full pre-treatment cardiovascular workup was done and suspected anomalies are referred to the cardiorespiratory physicians for further evaluation and treatment.
  - Those included in the study will have a pre-treatment ultrasonic evaluation of the haemangioma (LxTVxAP).
  - Commencement of treatment: Propranolol 1 mg/kg twice daily orally.
  - Parents are advised appropriately regarding adverse effects and the management thereof.
  - Follow up was every four weeks at the Plastic Surgery Outpatients Clinic and if oral propranolol is well tolerated, it is prescribed at a dose adjusted for weight.
  - A repeat ultrasound examination was performed at 8-12 weeks with appropriate measurements in millimeters taken.
  - Oral Propranolol treatment continues for six months if patient is older than 1 year of age. Alternative treatment modalities are utilised for problematic/residual lesions. (This is intralesional bleomycin-injection).
- **Measurement Tools Used:**
  - An ultrasound is utilised to attain the dimensions (LxTVxAP).  
This is performed before commencement of treatment and repeated at +/- eight weeks and at three months (whilst on treatment).
  - A clinical assessment is made at each visit to the Outpatients Clinic (every four weeks).
- **Safety Considerations/Patient Safety:**
  - Oral propranolol relatively low-risk medication (compared with other treatment modalities available): 2 mg/kg in two divided doses
  - Non-surgical approach
  - Hypoglycaemia risk (one to three per cent)

- Cardiorespiratory disorders are determined by history and clinical examination

## **l) STATISTICAL CONSIDERATIONS AND DATA ANALYSIS**

- Adequate patient numbers
- Only external haemangiomas considered
- Simple comparison of growth change related to ultrasonic findings

## **m) ETHICAL CONSIDERATIONS**

- Accepted alternate modality of treatment of haemangiomas with low side-effect profile reported in the literature

## **n) OUTCOMES AND SIGNIFICANCE**

- Safe, simple and effective treatment for haemangiomas with a lower side-effect profile than other modalities
- Improvement in size and appearance of tumours
- Unknown long-term aesthetic outcome/improvement
- Main modality of treatment for *all* haemangiomas

## **o) REFERENCES**

1. Leaute-Labreze C, Dumas de la Roque E, Hubiche T, Boralevi F, Thambo JB, Taïeb A et al. Propranolol for severe hemangiomas of infancy. *N Eng J Med*. 2008;358(24):2649e51
2. Holmes WJM, Mishra A, Gorst C, Liew LH. Propranolol as first-line treatment for infantile hemangiomas. *Plastic and Reconstructive Surgery* 2010 Jan1;125(1):420e1
3. Frieden IJ, Haggstrom AN, Drolet BA . Infantile hemangiomas: current knowledge, future

directions. Proceedings of a research workshop on infantile hemangiomas, April 7e9, 2005, Bethesda, Maryland, USA. *Pediatr Dermatol* 2005 SepeOct;22:383e406

4. Paltiel HJ, Burrows PE, Kozakewich HP, Zurakowski D, Mulliken JB. Soft-tissue vascular anomalies: Utility of US for diagnosis. *Radiology* 2000;214:747

## **Part B: Structured Literature Review**

### **LIST OF CONTENTS OF LITERATURE REVIEW**

- a) Objectives**
- b) Literature Search Methods**
- c) Summary /Interpretation of Literature**
  - Introduction
  - Classification of Vascular Lesions
  - Pathogenesis of Haemangioma
  - Diagnostic Imaging
  - Haemangioma Treatment Modalities
  - The Use of Propranolol in the Treatment of Haemangiomas
- d) Aims and Objectives of Current Study**
- e) References**

### **a) Objectives:**

- Acquire information regarding the incidence and distribution of infantile haemangiomas
- Classification of haemangiomas
- Understand the pathogenesis
- Explore and understand the main treatment modalities
- Examine the use of propranolol for the treatment of infantile haemangiomas including:
  - pharmacology
  - history of its use
  - current accepted dosages of propranolol
  - documentation of quantitative measurements of response to propranolol treatment
  - examine the literature as to the mechanism of action of propranolol on haemangiomas
- Evaluation of long-term sequelae of haemangiomas treated with propranolol during the proliferative stage

### **b) Literature Search Methods:**

- PubMed and Medline search engines were used to acquire the appropriate journal articles (only articles in the English language).
- Search words and phrases used:
  - Haemangiomas
  - Infantile haemangiomas
  - Propranolol
  - Beta-blockers
  - Vascular malformations
  - Capillary haemangiomas
- Related citations suggested by the search engine were used.
- References already obtained from the journal articles were used further to broaden the search.

### **c) Summary/Interpretation of Literature**

#### • Introduction

Haemangiomas are the most common benign vascular tumours of infancy, which can cause numerous cosmetic and functional deformities. They have an incidence of 1.0 to 2.6 per cent at birth in Caucasian infants, occurring in up to 12 per cent of children by the age of 1

year.(1,2,4) There is a higher incidence of up to 30 per cent reported in premature infants.(4) There are however, very sparse studies comparing the incidences across various race groups. Girls are affected two to five times as often as boys.(5)

Whilst most haemangiomas do not require treatment, due to their inherent ability to regress or involute with age, about 10 per cent will require medical or surgical intervention.(6) Haemangiomas can present with serious complications depending on: their location (obstruction of airways, visual axis and auditory canal obstruction); and size (congestive cardiac failure). They can also present with infections, painful ulcerations and haemorrhages. There are various treatment regimens available for the medical treatment of haemangiomas. In the past, the medical treatment of choice for haemangiomas was the use of systemic corticosteroid. More recently, this has been largely superseded by the use of systemic propranolol.(7) Labreze first reported the use of propranolol, when it was serendipitously discovered to have a dramatic effect in a child with a large facial haemangioma.(8) Interestingly, there appears to be no reporting of quantitative dimensional changes and a paucity of prospective data exists.

- Classification of Vascular Lesions

Mulliken and Glowacki are credited with the classification of vascular lesions in their landmark paper.(3) Prior to this, much confusion regarding diagnosis and incorrect nomenclature of these lesions resulted in inappropriate and inadequate treatment. Subsequently, terms such as strawberry haemangioma, capillary haemangioma, cavernous haemangioma have largely been consigned to history. Their system divides vascular anomalies into either tumors (mainly haemangiomas) or malformations based on clinical and histological findings. Subsequent radiographic studies have confirmed the validity of their classification.(16)

This classification, which was accepted by the International Society for the Study of Vascular Anomalies (ISSVA) in 1996, has been further amended:

<b>Malformations</b>		
<b>Tumors</b>	<b>Slow Flow</b>	<b>Fast Flow</b>
IH	Capillary (CM)	AVM
Congenital hemangioma (CH)	Venous (VM)	Combined
KHE	Lymphatic (LM)	
PG	Combined	
Angiosarcoma		

**Figure 1: (1)**

**IH:** Infantile Haemangioma

**CH:** Congenital Haemangioma – Rapidly Involuting Type

**KHE:** Kaposiform Haemangioendothelioma

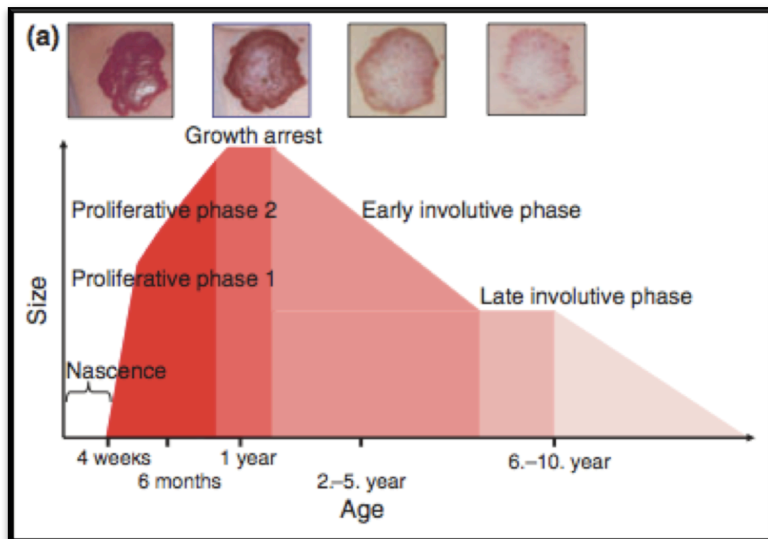
**PG :** Pyogenic Granuloma

This classification is based on Mulliken's original biological classification and findings regarding haemangiomas(3):

- endothelial hyperplasia
- multilaminated basement membrane below the endothelium
- history of rapid growth during infancy
- distinct phases of proliferation/involution

Despite an extensive search of the literature, no other classification system is available that has good clinical use.

- Pathogenesis of Haemangioma:



**Figure 2: (9)**

Mulliken's original work was the first to document the distinct phases that haemangiomas undergo (3):

- a) proliferative: There is an expansile growth pattern, which continues for six to eight months before plateauing.
- b) involutinal: The involutinal process begins at approximately 1 year of age and continues over the next five to seven years. There is decreased tumour size and turgidity of the lesion.(18)
- c) involuted: Approximately 50 per cent of haemangiomas have involuted by 5 years of age and 70 per cent by 7 years of age.(2,3) In 69 per cent of untreated haemangiomas, a residual lesion can be found. Even with complete involution, signs of the haemangioma may persist in the form of residual tumour, loose skin, telangiectasia, fibrofatty tissue, atrophic scar, skin surplus, erythema, hyperpigmentation and hypopigmentation.(19)  
Enjolras et al. reported residual lesions in only half of the haemangioma cases.(20)

In the proliferative phase of infantile haemangioma, endothelial cells exhibit an increased expression of the proliferating cell nuclear antigen, collagenase (Type 4), and other proangiogenic factors, especially vascular endothelial growth factor (VEGF).(10,11) VEGF serum levels vary in the different phases of haemangioma growth, and this may help to distinguish haemangiomas from vascular malformations.(12) VEGF levels are higher during the proliferative phase and seem to drop during the involution phase. Up-regulation of messenger RNA for fibroblast growth factor (FGF) and VEGF has also been demonstrated in

the proliferative phase of haemangiomas.(15,22) Urinary levels of fibroblastic growth factor (FGF) are elevated in infants with haemangiomas and could offer a potential means of monitoring the response to treatment.( 21,22) VEGF is also increased by hypoxaemia as well as adrenergic stimulation.(9)Transforming growth factor (TGF) is known to suppress endothelial growth. TGF is reduced during both the proliferative and involution phases.(9) Tissue inhibitors of metalloproteinase (TIMP) inhibit angiogenesis and are increased during the involution phase.(9)

Rous sarcoma oncogene cellular homologue (Src) activates the extracellular signal-related kinases(ERK)/mitogen-activated protein kinases (MAPK) cascade.



ERK and MAPK are serine/threonine kinases phosphorylating nuclear transcription factors



These are involved in the regulation of the expression of multiple genes involved in the control of cell proliferation.

VEGF itself exerts its proangiogenic effects by activating the ERK / MAPK cascade. Thus, the proliferation of endothelial cells is stimulated via beta2-adrenoceptors by two different mechanisms(14,9):

- (i) stimulation of beta2-adrenoceptors, which directly leads to an activation of ERK / MAPK
- (ii) inducement of an increased release of VEGF, which itself can activate the ERK/ MAPK cascade

Metallomatrix proteins (MMPs) are usually raised in haemangiomas. Elevated concentrations of MMP-2 and MMP-9 were found in tissue samples and in the blood of infants in the proliferative phase of haemangiomas. More specifically, MMP-9 is important for the migration of endothelial cells and tubulogenesis.(9,17)

Adrenaline causes a vasodilatory effect within the haemangioma via beta2-adrenergic receptors binding with activation of adenylate cyclase. This converts adenosine triphosphate(ATP) to cyclic adenosine monophosphate (cAMP) with stimulation of protein kinase A (PKA). Stimulated PKA leads to an activation of the endothelial nitric oxide synthase(NOS), which results in the formation and release of nitric oxide(NO). NO diffuses into the vascular smooth muscle cell resulting in smooth muscle relaxation and vasodilation.(9)

At a cellular level, haemangiomas in the involuting phase demonstrate a 30-fold to 40-fold increase in mast cells. Mast cells contain heparin and other vasoactive substances involved in neoangiogenesis.(2,3,16)

These mechanisms have important implications relating to the role of beta blockade as a means of treating haemangiomas.(8,14,15)

- Diagnostic Imaging

Previously, imaging was performed only if diagnostic doubt existed. Nowadays, it is also used to demonstrate the presence and extent of visceral involvement, to plan surgical excision and to assess response to treatment.

There is however, a paucity of literature documenting serial dimensional changes in response to treatment.

The preferred method of imaging is magnetic resonance imaging(MRI) (T1 and T2 weighted images).(23) Computerised tomography(CT scan) is a good alternative in the absence of MRI facilities, with the findings being closely correlated. Ultrasonography is another useful imaging modality. It is inexpensive, non-invasive and readily available. However, it offers less information than MRI and is very operator-dependent.(24)

- Haemangioma Treatment Modalities

There has been a significant paradigm shift in the management of infantile haemangiomas. A variety of treatment options is available for the treatment of haemangiomas. These are generally classified as conservative, medical or surgical. It has always been accepted that only a small fraction of haemangiomas require any intervention. Medical treatment modalities include corticosteroids (systemic /intralesional), interferon alpha, intralesional and more recently, propranolol. Other treatment options include surgical excision, laser therapy and embolisation.

Corticosteroids have always been regarded as the modality of choice in the treatment for haemangiomas. Edgerton et al. were first credited with its use in 1967, showing a dramatic reduction in size of a very large 'cavernous haemangioma' with prednisone therapy.(25,26) The accepted dose of systemic treatment is 2-3 mg/kg body weight.(26) Response is usually seen within 10 days, and treatment is usually discontinued before 1 year of age.(26,27) The response rate is reported to be about 90 per cent,(26,27) but there is some discrepancy in this figure due to the initial incorrect nomenclature. To the contrary, Enjolras et al. report a 'rule of thirds' finding.(6) Approximately one third of infants experienced a dramatic shrinkage

of the haemangioma (usually within seven days), a stabilization of growth without measurable change in size in another third, and little or no response in the final third of cases.(28) A 36 per cent rebound rate after cessation of therapy was noted.(36) Despite systemic corticosteroid therapy being used to treat haemangiomas for 30 years, the first study investigating the possible complications was by Boon, Mulliken et al.(28) These comprised Cushingoid facies (71 per cent), mental status changes (29 per cent), gastric upset (21 per cent), yeast infection (6 per cent) and growth retardation (35 per cent). Mulliken et al. concluded that systemic corticosteroids can be safely given to treat problematic haemangiomas in infants, at doses of 2-3 mg/kg/day. These doses are slowly tapered and stopped before the age of one year. They noted that the short-term side effects were minor and transient, and no serious long-term complications occurred.(28)

Recombinant interferon alpha has been used successfully in the treatment of life-threatening haemangiomas that have failed to respond to corticosteroid therapy. Interferon alpha-2a and alpha-2b are inhibitors of angiogenesis.(30,31) Interferon also results in a dose-dependent increase in endothelial cell apoptosis, but this is somewhat absent during the proliferative phase.(33) Interferon alpha is known to have significant side effects: neutropaenia, altered liver enzymes and more seriously, spastic diplegia (known to occur in up to 20 per cent of cases).(30,33)

Pulsed-dye laser is less effective for haemangiomas than it is in treating port-wine stains. This is due to the limited depth of penetration (approximately 1 mm). Therefore, this treatment is preferable for thin, superficial haemangiomas than for those that have both superficial and deep components. Achauer et al. used intralesional laser treatment for periorbital lesions and reported a significant improvement in lesion size, but noted ulceration of up to 25 per cent.(34) However, this treatment can improve residual telangiectasia after involution.

Surgical excision may be indicated for obstructing, ulcerating or large haemangiomas that are unresponsive to medical treatment. In the proliferative phase, there is a higher risk for blood loss, iatrogenic injury and an inferior aesthetic outcome, compared with excising residual tissue after the tumor has involuted. Mulliken recommends circular excision and purse-string closure for facial haemangiomas, in order to achieve a more aesthetic outcome in the long term.(2)

The use of intralesional bleomycin has proved to be a successful alternative method of

treating haemangiomas. Pienaar et al.(35) reported a 75 per cent reduction in haemangioma size using 0.3 to 0.6 mg/kg (per dose) intralesional bleomycin injection. More recently, in a prospective study of 75 patients, Hassan et al.(46) showed a marked improvement in 47 per cent of patients, with complete resolution in 24 per cent of patients. No haematological toxicity or pulmonary fibrosis was noted.

The exact mechanism of action in inducing regression is not completely understood. Mabeta et al.(47) demonstrated the direct anti-angiogenic effects of bleomycin. However, the direct sclerotic effects on vessel walls have been postulated by a few authors.(35) Pienaar et al.(35) demonstrated its significant value in treating very large haemangiomas of the head and neck region. However, repeated general anesthesia was required and scarring with hyperpigmentation occurred in some patients. The other potential complication of bleomycin use is pulmonary fibrosis. Pulmonary fibrosis is a major complication for oncology patients treated with systemic bleomycin. In a comparison of intralesional bleomycin to systemic bleomycin using similar doses (0.2 to 0.9 mg/kg), Ionescu et al.(48) showed that intralesional bleomycin injection resulted in plasma bleomycin levels about 100 times lower than the levels with intravenous administration. The low systemic levels with intralesional administration explain the virtual absence of systemic complications.

- The Use of Propranolol in the Treatment of Haemangiomas

In 2008, Leaute-Labreze et al. described their serendipitous observation of a dramatic antiproliferative effect of propranolol on a large facial haemangioma.(8) Propranolol has since become the first choice of therapy for complicated haemangiomas and has, to a large extent, replaced corticosteroid therapy as the first-line treatment of problematic haemangiomas. The true mechanism of its action is not completely understood, and there remains a paucity of prospective studies on its use. Three important questions require answering:

- a) What is the mechanism of action?
- b) What is the ideal dosage?
- c) What is the safety profile?

Propranolol is a non-cardio-selective beta-adrenergic antagonist, which competitively inhibits beta1- and beta2-adrenoceptors. Propranolol is a pure antagonist without partial agonistic effects. Its cardiovascular uses are well known, but these have been replaced by more modern cardioselective beta blockers.

Propranolol appears to exert its effect on haemangiomas at three levels(9):

(1) vasoconstriction:

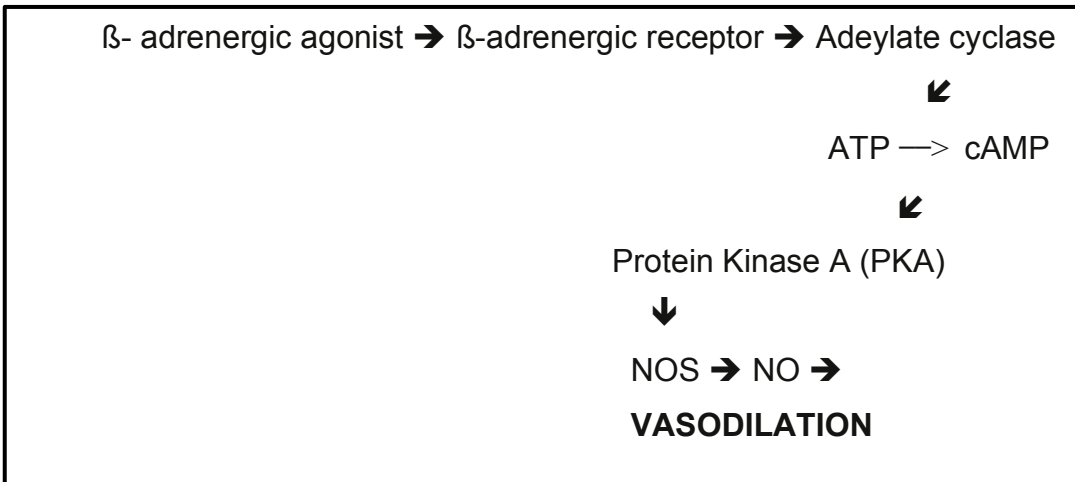


Figure 3:

Beta-adrenergic agonists, e.g.adrenaline, lead to vasodilation via the release of nitric oxide, as discussed earlier under Pathogenesis of Haemangiomas. Beta-adrenergic blockade using propranolol leads to vasoconstriction through the inhibition of NO synthesis and NO release.

(2) Inhibition of angiogenesis(37):

Beta-adrenergic agonists stimulate the synthesis of proangiogenic factors (VEGF and basic fibroblast growth factor(bFGF) ) and matrix metalloproteinases (MMP-2 and MMP-9), which activate proangiogenic cascades (ERK / MAPK cascade) thereby, promoting angiogenesis. This is discussed in Pathogenesis of Haemangioma. Propranolol beta blockade results in a downregulation of PKA and an inhibition of the ERK / MAPK cascade, leading to the inhibition of angiogenesis.

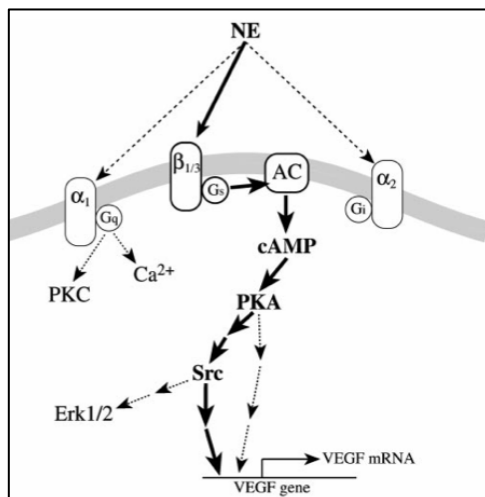


Figure 4:(37)

### (3) Apoptosis:

Sommers Smith et al.(38) demonstrated the induction of apoptosis in endothelial cells with prolonged beta blockade using propranolol.

Beta-adrenergic agonists inhibit apoptosis via src/MAPK. Propranolol beta blockade inhibit src via PKA inhibition thereby, inducing apoptosis.(9)

There is no consensus on the optimal dosage or regimen for the use of propranolol. In fact, a wide variation exists for dosage and duration of treatment. In a review of eight case studies, Zimmerman et al.(41) found a range of 2 to 3 mg/kg/day to have successful outcomes. Holmes et al. used a dose of 3 mg/kg/day, given in three divided doses (1 mg/kg/tds) for a total of 31 patients with no major side effects reported. A significant regression was observed in 87 per cent of patients.(42) The duration of treatment was usually between seven to eight months, with many authors citing the end of the proliferative phase as the reason. Only one study documents rebound growth (24 per cent) occurring on cessation of treatment, with a range of four to six months.(42)

Propranolol acts on the beta adrenergic receptors and reduces circulating catecholamines by competitively inhibiting the second messenger pathway. Propranolol reduces heart rate, blood pressure and cardiac contractility. It also produces vasoconstriction and bronchospasms. The adverse effect profile of propranolol includes bradycardia, hypotension, hypoglycemia, seizures, rashes and bronchospasms. These complications are generally rare in the paediatric population and occur with doses higher than 2 mg/kg per day, with the most concerning complications being bradycardia, hypotension and bronchospasms. Propranolol exerts its hypoglycaemic effect by the inhibition of the normal beta-2 adrenergic receptor during mediated hepatic glycogenolysis. This is in response to a decrease in blood glucose levels.(40)

The review by Love et al. of the literature over the past 40 years failed to reveal a single documented death, which was directly related to acute beta-blocker exposure in any child under 6 years old, regardless of the dose ingested.(39)

#### **d) Aims and Objectives of Current Study**

- Document the efficacy of oral propranolol for the treatment of *all* haemangiomas.
- Attain a clinical and a quantitative response to treatment.
- Ascertain a safe and effective dosage and regimen of propranolol administration.

- Observe the side-effect profile and compare it to other centres.
- Ascertain if any value is to be gained in prescribing propranolol in patients beyond the proliferative phase.
- Document the long-term cosmetic outcomes.

## e) References for Literature Review

1. Burns AJ, Navarro JA, Cooner RD. Classification of vascular anomalies and the comprehensive treatment of haemangiomas. *Plast Reconstr Surg*. 2009;124 (1 Suppl):69e–81e.
2. Mulliken JB, Young AE. *Vascular Birthmarks: Hemangiomas and Malformations*. Philadelphia:Saunders 1988:Pp.24-103.
3. Mulliken JB, Glowacki J. Hemangiomas and vascular malformations in infants and children: A classification based on endothelial characteristics. *Plast. Reconstr. Surg*. 1982;69:412
4. Drolet BA, Swanson EA, Frieden IJ. Infantile hemangiomas: an emerging health issue linked to an increased rate of low birth weight infants. *J Pediatr* 2008;153:712–15
5. Enjolras O, Gelbert F. Superficial hemangiomas: Associations and management. *Pediatr. Dermatol*. 1997;14:173
6. Enjolras O, Mulliken JB. Vascular tumors and vascular malformations. *Adv Dermatol* 1997;13:375e423 (new issue)
7. Izadpanah A, Izadpanah A, Kanevsky J, Belzile E, Schwarz K. Propranolol versus Corticosteroids in the Treatment of Infantile Hemangioma: A Systematic Review and Meta-Analysis. *Plast Reconst Surg*. 2013;131(3)
8. Leaute-Labreze C, Dumas de la Roque E, Hubiche T, Boralevi F, Thambo JB, Taïeb A. Propranolol for severe hemangiomas of infancy. *N Eng J Med*. 2008;358(24):2649e51
9. Storch CH, Hoegera PH. Propranolol for infantile haemangiomas: insights into the molecular mechanisms of action. *British Journal of Dermatology* 2010;163:269-274
10. Berard M, Sordello S, Ortega N, Carrier JL, Peyri N, Wassef M, et al. Vascular endothelial growth factor confers a growth advantage in vitro and in vivo to stromal cells cultured from neonatal hemangiomas. *Am J Pathol* 1997;150:1315-26.
11. Takahashi K, Mulliken JB, Kozakewich HPW, Rogers RA, Folkman J, Ezekowitz RA. Cellular markers that distinguish the phases of hemangioma during infancy and childhood. *J Clin Invest* 1994;93:2357-64.

12. Przewratil P, Sitkiewicz A, Andrzejwska E. Local serum levels of vascular endothelial growth factor in infantile hemangioma: intriguing mechanisms of endothelial growth. *Cytokine* 2010;49:141-7
13. Greenberger S, Boscolo E, Adini I, Mulliken JB, Bischoff J. Corticosteroid suppression of VEGF-A in infantile haemangioma-derived stem cells. *N Engl J Med* 2010;362:1005-13
14. Fredriksson JM, Lindquist JM, Bronnikov E, Nedergaard J. Norepinephrine induces vascular endothelial growth factor gene expression in brown adipocytes through a beta-adrenoceptor/cAMP/protein kinase A pathway involving src but independently of Erk1/2. *J Biol Chem* 2000;18:13802-11.
15. Chang J, Most D, Bresnick S, Mehrara B, Steinbrech DS, Reinisch J, et al. Proliferative hemangiomas: Analysis of cytokine gene expression and angiogenesis. *Plast. Reconstr. Surg.* 1999;103:1.
16. Gampper TJ, Morgan RF. Vascular Anomalies: Hemangiomas. *Plast Reconst Surg* . 2002;110(2)
17. Annabi B, Lachambre MP, Plouffe K, Moudjian R, Béliveau R. Propranolol adrenergic blockade inhibits human brain endothelial cells tubulogenesis and matrix metalloproteinase-9 secretion. *Pharmacol Res* 2009;60:438-45.
18. Boon, L M, Enjolras O, Mulliken JB. Congenital hemangioma: Evidence of accelerated involution. *J. Pediatr.* 1996;128:329
19. Bauland C.G, Lüning TH, Smit JM, Zeebregts CJ, Spauwen PH. Untreated Hemangiomas: Growth Pattern and Residual Lesions. *Plast Reconstr Surg.* 2011;127(14)
20. Enjolras O, Gelbert F. Superficial hemangiomas: Associations and management. *Pediatr Dermatol.* 1997;14:173-179
21. Drolet BA, Esterly NB, Frieden IJ. Hemangiomas in children. *N. Engl. J. Med.* 1999;341:173
22. Takahashi K, Mulliken JB, Kozakewich HPW, Rogers RA, Folkman J, Ezekowitz AB. Cellular markers that distinguish the phases of hemangioma during infancy and childhood. *J Clin Invest* 1994;93:2357-64
23. Meyer JS, Hoffer FA, Barnes PD, Mulliken JB. Biological classification of vascular soft-tissue anomalies: MR correlation. *A.J.R. Am. J. Roentgenol.* 1991;157:559
24. Paltiel HJ, Burrows PE, Kozakewich HP, Zurakowski D, Mulliken JB. Soft-tissue vascular anomalies: Utility of US for diagnosis. *Radiology* 2000;214:747
25. Zarem HA, Edgerton MT. Induced resolution of cavernous hemangiomas following prednisone therapy. *Plast. Reconstr. Surg.* 1967;39:76
26. Edgerton MT. The treatment of hemangiomas: With special reference to the role of steroid therapy. *Ann.Surg.* 1976;183:517

27. Lasser AE, and Stein AF. Steroid treatment of hemangiomas in children. *Arch. Dermatol.* 1973;108:565
28. Boon LM, MacDonald DM, Mulliken JB. Complications of systemic corticosteroid therapy for problematic hemangioma. *Plast. Reconstr. Surg.* 1999;104:1616
29. Sloan GM, Reinisch JF, Nichter LS, Saber WL, Lew K, Morwood DT. Intralesional corticosteroid therapy for infantile hemangiomas. *Plast. Reconstr. Surg.* 1989;83:459
30. Ezekowitz RA, Mulliken JB, Folkman J. Interferon alfa-2a therapy for life-threatening hemangiomas in infancy. *N. Engl. J. Med.* 1992;326:1456
31. Bauman NM, Burke DK, Smith RJ. Treatment of massive or life-threatening hemangiomas with recombinant alpha-2a interferon. *Otolaryngol. Head and Neck Surg.* 1997;117:99
32. Achauer BM, Chang CJ, Van der Kam VM. Management of hemangioma of infancy: review of 245 patients. *Plast Reconstr Surg* 1997;99:1301-8.
33. Barlow CF, Priebe C, Mulliken JB, Barnes PD, Mac Donald D, Folkman J, Ezekowitz RA. Spastic diplegia as a complication of interferon Alfa-2a treatment of hemangiomas of infancy. *J Pediatr* 1998;132:527-30
34. Achauer BM, Chang CJ, Van der Kam VM, Boyko A. Intralesional photocoagulation of periorbital hemangiomas. *Plast. Reconstr. Surg.* 1999;103:11
35. Pienaar C, Graham R, Geldenhuys S, Hudson DA. Intralesional Bleomycin for the Treatment of Haemangiomas. *Plast Reconstr Surg* 2006;117
36. Bennett ML, Fleischer Jr AB, Chamlin SL, Frieden IJ. Oral corticosteroid use is effective for cutaneous hemangiomas: an evidence-based evaluation. *Arch Dermatol* 2001 Sep;137:1208e13
37. Fredriksson JM, Lindquist JM, Bronnikov E, Nedergaard J. Norepinephrine induces vascular endothelial growth factor gene expression in brown adipocytes through a beta-adrenoceptor/cAMP/protein kinase A pathway involving src but independently of Erk1/2. *J Biol Chem* 2000;18:13802-11
38. Sommers Smith SK, Smith DM. Beta blockade induces apoptosis in cultured capillary endothelial cells. *In Vitro Cell Dev Biol Anim* 2002;38:298-304.
39. Love JN, Sikka N. Are 1-2 tablets dangerous? Beta-blocker exposure in toddlers. *J Emerg Med* 2004;26:309-14.
40. Artman M, Grayson M, Boerth RC. Propranolol in children: safety-toxicity. *Pediatrics* 1982 Jul;70:30e1.
41. Zimmerman AP, Wiegand S, Werner JA, Eivazi B. Propranolol therapy for infantile haemangiomas: review of the literature. *Int J Pediatr Otorhinolaryngol* 2010;74(4):338e4
42. Holmes WJM, Mishra A, Gorst C, Liew SH. Propranolol as first-line treatment for rapidly proliferating Infantile Haemangiomas. *JPRAS.* 2011;(64):445

43. Lawley LP, Siegfried E, Todd JL. Propranolol treatment for hemangioma of infancy: Risks and recommendations. *Pediatr Dermatol.* 2009;26:610-614
44. Romana-Souza B, Nascimento AP, Monte-Alto-Costa A. Low-dose propranolol improves cutaneous wound healing of burn-injured rats. *Plast Reconstr Surg.* 2008 Dec;122(6):1690-9.
45. Mohammadi AA, Bakhshaeekia A, Alibeigi P, Hasheminasab MJ, Tolide-ei HR, Tavakkolian AR, Mohammadi MK. Efficacy of Propranolol in Wound Healing for Hospitalized Burn Patients. *Journal of Burn Care & Research.* November/December 2009;30(6):1013-1017
46. Hassan Y, Osman AK, Altyeb A. Noninvasive management of hemangioma and vascular malformation using intralesional bleomycin injection. *Ann Plast Surg.* 2013 Jan;70(1):70-3.
47. Mabeta P, Davis PF. The mechanism of bleomycin in inducing haemangioma regression . *SAMJ* July 2008;98(7)
48. Ionescu G, et al. Bleomycin plasma spill-over levels in paediatric patients undergoing intralesional injection for the treatment of haemangiomas. *SAMJ.* July 2008;98(7)

# **THE ROLE OF PROPRANOLOL IN THE TREATMENT OF INFANTILE HAEMANGIOMA**

Sean T. Moodley<sup>1</sup>, Donald A. Hudson<sup>2</sup>

<sup>1</sup>Registrar, Department of Plastic and Reconstructive Surgery, University of Cape Town

<sup>2</sup>Professor and Head, Department of Plastic and Reconstructive Surgery, University of Cape Town

## **ABSTRACT**

**INTRODUCTION:** Infantile haemangioma is the most common childhood tumour affecting up to 12 per cent of infants. These tumours can cause significant functional and cosmetic problems. While there are many treatment modalities, propranolol is increasingly being recognised as the first-line treatment of problematic haemangiomas. This study documents the Red Cross War Memorial Children's Hospital's experience in the use of oral propranolol for the treatment of all haemangiomas.

**METHOD:** This is a retrospective study evaluating 15 children (3 boys and 12 girls) presenting at the Red Cross War Memorial Children's Hospital (RCWMCH) with infantile haemangioma during a 24-month period. The protocol consisted of pre-treatment ultrasonic evaluation of the lesion, followed by the commencement of propranolol therapy (2 mg/kg orally in two divided doses), with repeat imaging performed in order to document the dimensional changes. Adverse effects of propranolol were documented. Intralesional bleomycin was utilised as a second-line modality of treatment for large or problematic haemangiomas with inadequate regression in size after oral propranolol therapy.

**RESULT:** A total of 15 patients with a mean age of 7 months (Range: 3-12 months) presented with haemangiomas. The majority presented with lesions affecting the head and neck region (65 per cent). Three patients presented with an ulcerated haemangioma, with all healing well with propranolol and simple dressings. The average decrease in size between the ultrasonography procedures was 48.87 per cent. Only one patient showed no improvement. No

side effects were reported. Concomitant bleomycin treatment was reserved for large problematic haemangiomas and proved successful at speeding up the involution process.

**CONCLUSION:** At the RCWMH, oral propranolol has become the first-line treatment of choice for all haemangiomas. It has proven to be effective and safe for simple and complicated haemangiomas during the proliferative phase. Some benefit is to be gained for treatment after the proliferative phase.

## INTRODUCTION

Haemangiomas are the most common benign vascular tumours of infancy. They can cause numerous cosmetic and functional deformities. The condition has an incidence of 1.0-2.6 per cent at birth in Caucasian infants, occurring in up to 12 per cent of children by the age of 1 year.(1,2,4) Girls are affected two to five times as often as boys.(5) Haemangiomas undergo distinct phases of evolution, as described by Mulliken et al.(3) Most haemangiomas are usually well defined by the third month of age.(16) The rapid proliferative phase is followed by a slow, variable involution phase. However, the speed and extent of the proliferative phase remains unpredictable and ultimately influences the long-term outcome of haemangiomas.

Whilst Mulliken suggested that only about 10 per cent of all haemangiomas will require medical or surgical intervention, there has been a paradigm shift in the management of all haemangiomas. Haemangiomas can present with serious complications depending on their location (obstruction of airways, visual axis and auditory canal obstruction) and size (congestive cardiac failure). Other complications include infections, painful ulcerations and haemorrhages. Will early implementation of an effective treatment modality significantly decrease the proliferative phase and ultimately reduce the size and severity of these lesions in the long-term functional and aesthetic outcomes?

There are various treatment regimens available for the medical treatment of haemangiomas. Whilst some have shown variable results, others have displayed adverse effects that have curtailed their usage. In the past, the *gold standard* for the medical treatment of haemangiomas was the use of systemic corticosteroid. More recently, this has been largely superseded by the use of systemic propranolol.(7) However, little documentation of quantitative dimensional changes exists, and there is a paucity of prospective data relating to the treatment of haemangiomas with propranolol. Whilst the use of propranolol for only problematic haemangiomas was presented by Holmes et al.,(42) the aim of this study is to document the efficacy of propranolol for the treatment of all haemangiomas. The side-effect profile of propranolol (especially in an outpatient setting) and the justification of its use beyond the proliferative phase are also investigated.

## METHOD:

This is a retrospective study conducted over a 24-month period (May 2011-May 2013). All new patients presenting with a diagnosis of infantile haemangioma (proliferative phase) to the Red Cross War Memorial Children's Hospital Plastic Surgery Outpatients Clinic were enrolled into the study. Clinical data recording included the age and sex of the patient and anatomical location of the haemangioma. The initial size/dimensions were recorded prior to commencement of propranolol therapy using ultrasonography.

### Eligibility Criteria:

- Inclusion: All haemangiomas in fit healthy children (male/female) less than 24 months of age
- Exclusion: - Cardiovascular anomalies  
- Lower respiratory tract infections  
- Asthma  
- Complicated haemangiomas requiring surgical/ alternative medical therapy

Prior to commencement of oral propranolol treatment, a cardiovascular/respiratory history and examination was done. Routine cardiology consult and echocardiogram (ECG) were not done. Any anomaly detected was referred to the paediatricians for further investigation and treatment. These patients were not included in the study. The parents of eligible patients were counselled, regarding all the treatment modalities available and the adverse effect profile of propranolol, especially hypoglycaemia. They were asked to report to the Casualty Department of RCWMCH if there were any concerns.

Patients commenced with propranolol at a dose of 2 mg/kg in two divided doses daily. Follow-up was at one week and thereafter every four weeks, when a reassessment of the lesion was done with an enquiry regarding adverse effects, haemangioma changes and compliance with treatment.

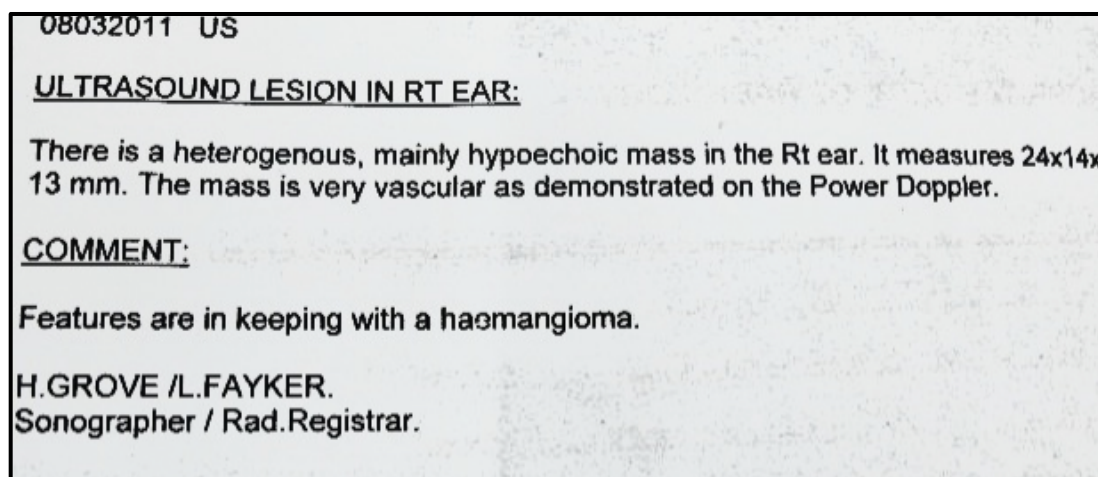
Patients were re-weighed and the dose of propranolol adjusted accordingly.

The ultrasound scan was performed by a radiology registrar assisted by a consultant, who had been involved with most of the scans (operator variability minimised). Two important pieces of information were elucidated and documented: confirmation of the diagnosis and dimensions of the lesion.

(L= length, TV = transverse width, AP = antero-posterior (depth)).

An estimate of the volume was calculated:  $L \times TV \times AP$  (cm<sup>3</sup>)

For the ulcerated lesions, AP width could not be ascertained due to technical factors. Therefore, the area of the lesion was calculated:  $L \times TV$  (cm<sup>2</sup>).



**Figure 5:** An example of an ultrasound report (Study patient RCWMCH)

Repeat ultrasound scans were performed 16-24 weeks later. This depended on availability of ultrasound bookings and patient social factors. The area and volume of the lesions were expressed as *aL*, *aTV*, *aAP*, *Vol1* and *bL*, *bTV*, *bAP*, *Vol2*. (See Addendum) The change in size was documented and expressed as a percentage of the original lesion dimensions. Other clinical changes were also documented: colour changes, ulcer healing, infection.

Treatment was stopped: if no further reduction of haemangioma size (even out of the proliferative phase) was seen, if any adverse reactions were noted, or if compliance with treatment was questionable.

Ethics approval: This study was approved by the Research Ethics Committee of the University of Cape Town.

## **RESULTS:**

A total number of 23 patients with haemangiomas was seen at the Plastic Surgery Outpatients at RCWMCH over a 24 month period. Seven patients defaulted treatment and one patient declined treatment with oral propranolol. A total number of 15 patients were enrolled into the study. The mean age at presentation was 7 months (Range: 3-14 months). Five patients who were 9 months or older presented for the first time with their lesion.

There was a marked preponderance of female patients. Females accounted for 80 per cent of the patients, with 20 per cent male. The t-test was 0.6214. However, a larger number of male patients would be required to lend greater weight to this statistical significance.

**TABLE 1**

<b>GENDER</b>	<b>Freq.</b>	<b>Percent</b>	<b>Cum.</b>
<b>F</b>	12	80	80
<b>M</b>	3	20	100
<b>Total</b>	15	100	

The majority of lesions were located in the head and neck region. This accounted for 67 per cent of cases. Twenty-six per cent of lesions were located to the trunk and one patient presented with an upper limb haemangioma. There were no lesions of the lower limbs. (See Table 2 and Addendum for distribution)

**TABLE 2**

<b>SITE</b>	<b>Freq.</b>	<b>Percent</b>	<b>Cum.</b>
<b>Trunk</b>	4	26,67	26,67
<b>Upper limb</b>	1	6,66	33,33
<b>Head &amp; neck</b>	10	66,67	100
<b>Total</b>	15	100	

The overall volume change between the initial scan at commencement of propranolol therapy and the follow-up ultrasound scan showed a mean of 48.87 per cent (SD = 33.28, SE = 8.59, 95% CI = 30.44 – 67.30).

The data was found to be statistically normally distributed (Shapiro-Wilk test value 0.376 [ $p > 0.05$ ]). However, a larger patient number would most likely lend more weight in the final analysis. Further analysis by gender revealed that females experienced a mean volume reduction of 54.12 per cent (SD = 32.43, SE = 9.939), as opposed to the male patients who had a mean volume reduction of 27.86 per cent (SD = 20.11, SE = 20.108). With regard to the haemangioma location, the largest reduction of volume was noted in the head and neck region, with a mean reduction of 58.32 per cent (SD = 33.29). Volume reduction of 26.9 per cent and 42.22 per cent was experienced in the trunk and upper limb respectively.

**TABLE 3**

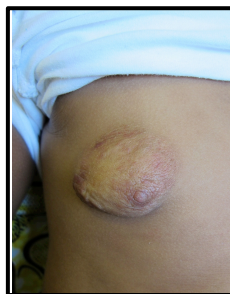Group	N	Mean	Std. Err.	Std. Dev.	[95% Conf. Interval]	
F	12	54,1202	9,938916	34,42941	32,2448	75,99561
M	3	27,86019	11,60962	20,10845	-22,09197	77,81236
<b>combined</b>	15	<b>48,8682</b>	8,592062	33,27691	30,44006	67,29634
<b>diff</b>		26,26001	21,0676		-19,25378	71,7738

Three patients had ulceration of their haemangiomas at presentation. Two were localised to the trunk region. These were completely epithelialised with a commensurate decrease in size at the second follow-up consultation. No adverse effects of propranolol therapy were reported by any of the study patients.

Four patients required adjunctive treatment with intralesional injection of bleomycin. A very good response was noted in all four patients, with rapid involution of larger lesions noted.

## DISCUSSION:

Infantile haemangiomas are the most common benign vascular tumour of infancy, affecting up to 12 per cent of infants.(6) Expectant observation is usually recommended for uncomplicated haemangiomas.(2) However, as reported by Bauland et al.,(19) almost 70 per cent of patients will have residual lesions. This usually comprises a combination of telangiectasia, fibrofatty tissue, atrophic scar, skin surplus, hyperpigmentation and hypopigmentation.



**Figure 6:** ( Study patient RCWMCH )

An 8 year old female patient, managed previously by expectant observation

In the past, systemic corticosteroid was regarded as the *gold standard* for the treatment of complicated haemangiomas.(28) Labreze first reported the use of propranolol for the treatment of a large facial haemangioma in 2008.(8) Since then, this is increasingly regarded as the first-line treatment of choice for complicated haemangiomas. These include very large haemangiomas, visual axis or nasopharyngeal obstruction and ulceration of the lesion.

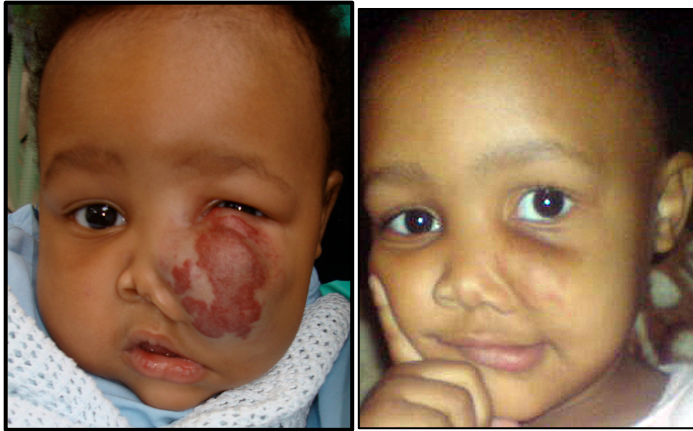However, the literature is lacking in studies examining the role of propranolol in the treatment of *all* haemangiomas, specifically of quantitative analysis/imaging in response to treatment. A quantitative analysis was undertaken using a simple diagnostic modality, albeit with its inherent shortcomings.(24) This study investigated if there was any further advantage to be gained in respect of further rapid involution by continuing propranolol in the post-proliferative phase, and whether early propranolol treatment will decrease the residual lesions that Bauland et al.(10) describes in untreated, uncomplicated haemangiomas.

This study has shown a good correlation with the demography quoted in the literature. There is a 60 per cent predilection for the female gender, with 60 percent localised to the head and neck region.(1,2,3,6) The study revealed a 4:1 female preponderance, and 67 per cent of lesions were localised to the head and neck region. No lower limb haemangiomas were presented. One possible explanation is that facial haemangiomas tend to cause more functional and cosmetic deformities. Parents tend to be more sensitive to these and seek medical attention. However, this is not supported by the literature.

Radiological imaging was usually reserved for lesions with diagnostic doubt but more frequently, it is used to demonstrate the extent of the lesion, plan surgical excision and assess response to treatment.(23) While MRI is the preferred method of imaging haemangiomas, ultrasonography is another useful imaging modality. It is inexpensive, non-invasive and readily available. However, it offers less information than MRI and is very operator-dependent.(24) For this study, ultrasonography was easily accessible with short waiting-times for appointments. Operator dependency was limited by ensuring observation by the same consultant radiologist in a single facility, and consistent reporting was available. However, some lesions were technically more difficult to image. These included lesions of the lip and periorbital region. Ulceration of the haemangiomas resulted in an inability to image these haemangiomas, and measurement with a rule was sufficient. However, the depth was not ascertained in these two haemangiomas.

There was a significant decrease in haemangioma size from the time of oral propranolol commencement to the follow-up ultrasound. This decrease was more pronounced in the female group, with a mean of 54.12 per cent. However, a larger number of patients would be more representative from a comparison point of view. It does beg the questions: Why are haemangiomas more common in females(1,2,3), and why do females seem to respond more favourably to oral propranolol? The literature supports the fact that there is a female preponderance, but no comparison is made to gender response to treatment.

Haemangiomas of the head and neck region appear to be much more responsive to propranolol therapy, with close to a 60 per cent mean reduction in haemangioma size achieved.



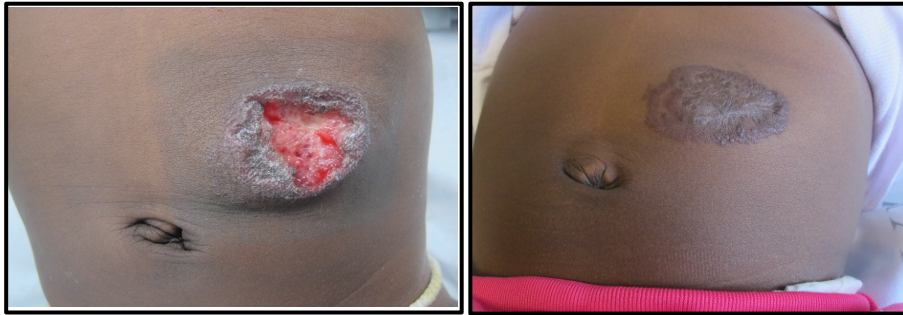**Figure 7:** ( Study patient RCWMCH )

Female patient at initial presentation at 4 months of age with visual axis obstruction. At commencement of propranolol treatment (left) and continued for an eight month period. No visual problems (amblyopia) reported. Picture on right: patient at 18 months. The residual small mass has shown even further aesthetic improvement with intralesional bleomycin injection.

The use of intralesional bleomycin for the treatment of haemangiomas is one of the preferred methods of treatment at the RCWMCH. Pienaar et al. reported favourable outcomes in halting the proliferative phase, but hyperpigmentation was the main disadvantage of its use. (35) In four patients, adjunctive treatment with bleomycin outside of the proliferative phase resulted in a significant increase of the involution process, with a favourable aesthetic outcome and fewer intralesional injections being required. Early signs are very encouraging that, in combination, they offer another tool in the effective treatment of haemangiomas.

Three patients presented with ulcerated haemangiomas. All wounds epithelialised completely within eight weeks of commencement of propranolol. In addition to halting the proliferative process, propranolol appears to expedite the epithelialisation process. Several studies have shown an improvement in skin burn wound healing. They have also reported a decreased hospital stay, decreased time to epithelialisation and a decrease in the area requiring skin grafts.(44,45) Interestingly, cellular proliferation, myofibroblast density, collagen deposition and active matrix metalloproteinase-2 levels were reduced in the control group compared with the propranolol-treated group, 63 days after sustaining the initial burn wounds.(44) This correlates closely with the process of epithelialisation in an ulcerated haemangioma. Fredriksson et al eloquently described the possible mechanism of beta blockade on the inhibition of angiogenesis.(18)Beta-adrenergic agonists stimulate the synthesis of

proangiogenic factors (VEGF and bFGF) and matrix metalloproteinases (MMP-2 and MMP-9) which activates proangiogenic cascades (ERK / MAPK cascade) thereby, promoting angiogenesis. Propranolol (beta blockade) results in a down regulation of PKA and an inhibition of the ERK / MAPK cascade, leading to inhibition of angiogenesis.(37) This plausibly explains the rapid decrease in swelling and induration surrounding the ulcerated haemangiomas.



**Figure 8:** ( Study patient RCWMCH )

This 6 month old presented with an ulcerated haemangioma of the anterior abdominal wall. Note the size and surrounding induration. After five weeks of propranolol and simple hydrofibre dressings, complete epithelialisation was achieved (right). The lesion is flat and lacks substance.

Despite reports in the literature, no adverse effects of propranolol therapy were noted in this study. In Holmes' et al. series of 31 patients (at 3 mg/kg), no significant side-effects were noted. A full cardiology assessment was performed for each patient.(42) In this study, a dose of 2 mg/kg, as described by Labreze(8) in his original article, was found to be effective and free of any unnecessary adverse effects. A simple history and clinical examination were found to be sufficient in a busy outpatient clinic setting for selecting patients suitable for propranolol treatment.

## **CONCLUSION:**

In this study, oral propranolol was found to be a simple and effective treatment modality for haemangiomas, with a significant objective regression noted. At the RCWMCH, it has become the first-line treatment of all haemangiomas with a safe adverse effect profile, as well as being very cost-effective. However, careful patient selection is important for avoiding any deleterious effects of propranolol and ensuring good compliance with treatment. Judging by the positive results relating to the adjunctive use of intralesional bleomycin, further research is required to assess the efficacy and feasibility of their combined use. Finally, the improvement of long-term aesthetic sequelae of early propranolol intervention is the ultimate goal.

## REFERENCES:

1. Burns AJ, Navarro JA, Cooner RD. Classification of vascular anomalies and the comprehensive treatment of haemangiomas. *Plast Reconstr Surg.* 2009;124(1 Suppl):69e–81e.
2. Mulliken JB, and Young AE. *Vascular Birthmarks: Hemangiomas and Malformations.* Philadelphia:Saunders 1988:Pp.24-103.
3. Drolet BA, Swanson EA, Frieden IJ, Infantile hemangiomas: an emerging health issue linked to an increased rate of low birth weight infants. *J Pediatr* 2008;153:712–15
4. Mulliken JB, Glowacki J. Hemangiomas and vascular malformations in infants and children: A classification based on endothelial characteristics. *Plast. Reconstr. Surg.* 1982;69:412
5. Enjolras O, Gelbert F. Superficial hemangiomas: Associations and management. *Pediatr. Dermatol.* 1997;14:173
6. Gampper TJ, Morgan RF. Vascular Anomalies: Hemangiomas. *Plast Reconst Surg .* 2002;110(2)
7. Enjolras O, Mulliken JB. Vascular tumors and vascular malformations. *Adv Dermatol* 1997;13:375e423(new issue)
8. Izadpanah A, Izadpanah A, Kanevsky J, Belzile E, Schwarz K. Propranolol versus Corticosteroids in the Treatment of Infantile Hemangioma: A Systematic Review and Meta-Analysis. *Plast Reconst Surg.* 2013:131(3)
9. Holmes WJM, Mishra A, Gorst C, Liew SH. Propranolol as first-line treatment for rapidly proliferating Infantile Haemangiomas. *JPRAS.* 2011;(64):445
10. Bauland C.G, Lüning TH, Smit JM, Zeebregts CJ, Spauwen PH. Untreated Hemangiomas: Growth Pattern and Residual Lesions. *Plast Reconstr Surg.* 2011;127(14)
11. Boon LM, MacDonald DM, Mulliken JB. Complications of systemic corticosteroid therapy for problematic hemangioma. *Plast. Reconstr. Surg.* 1999;104:1616
12. Leaute-Labreze C, Dumas de la Roque E, Hubiche T, Boralevi F, Thambo JB, Taïeb A. Propranolol for severe hemangiomas of infancy. *N Eng J Med.* 2008;358(24):2649e51
13. Paltiel HJ, Burrows PE, Kozakewich HP, Zurakowski D, Mulliken JB. Soft-tissue vascular anomalies: Utility of US for diagnosis. *Radiology* 2000;214:747
14. Meyer JS, Hoffer FA, Barnes PD, Mulliken JB. Biological classification of vascular soft-tissue anomalies: MR correlation. *A.J.R. Am. J. Roentgenol.* 1991;157:559
15. Pienaar C, Graham R, Geldenhuys S, Hudson DA. Intralesional Bleomycin for the Treatment of Haemangiomas. *Plast Reconstr Surg* 2006:117
16. Romana-Souza B, Nascimento AP, Monte-Alto-Costa A. Low-dose propranolol improves

cutaneous wound healing of burn-injured rats . *Plast Reconstr Surg.* 2008 Dec;122(6):1690-9.

17. Mohammadi AA, AA, Bakhshaeekia A, Alibeigi P, Hasheminasab MJ, Tolide-ei HR, Tavakkolian AR, Mohammadi MK. Efficacy of Propranolol in Wound Healing for Hospitalized Burn Patients. *Journal of Burn Care & Research.* November/December 2009;30(6):1013-1017
18. Fredriksson JM, Lindquist JM, Bronnikov E, Nedergaard J. Norepinephrine induces vascular endothelial growth factor gene expression in brown adipocytes through a beta-adrenoceptor/cAMP/protein kinase A pathway involving src but independently of Erk1/2. *J Biol Chem* 2000;18:13802–11

## Part D: Addendum

**TABLE 4: Volume 1 (Volume prior to propranolol treatment)**

	aL	aTV	aAP	vol1
1	.	.	.	.
2	2,5	2	2,5	12,5
3	4,5	4,5	1,5	30,375
4	3,1	0,5	2,5	3,875
5	4,3	4,4	2,2	41,624
6	1,2	1,1	1,4	1,848
7	.	.	.	.
8	1	0,2	0,6	0,12
9	3,5	2,7	0,6	5,67
10	1,2	0,9	0,6	0,648
11	3,9	3,4	0,4	5,304
12	2	1,2	1,5	3,6
13	0,7	0,6	0,3	0,126
14	3,6	1	2	7,2
15	2,4	1,4	1,3	4,368

**TABLE 5: Volume 2 (Volume after propranolol treatment)**

	bL	bTV	bAP	vol2
1	.	.	.	.
2	2	0,9	2,4	4,32
3	4,4	4,2	0,5	9,24
4	2,5	0,5	2,5	3,125
5	4,3	4,4	2,2	3,696
6	1,3	0,8	0,3	0,312
7	.	.	.	.
8	0,7	0,2	0,2	0,028
9	2,6	1,8	0,7	3,276
10	1	0,5	0,4	0,2
11	3,1	2,9	0,4	3,596
12	0	0	0	0
13	0,9	0,6	0,2	0,108
14	3,5	0,8	2,1	5,88
15	1,7	1,4	0,9	2,142

**L = length, TV = transverse width, AP = antero-posterior (depth).**

**An estimate of the volume was calculated thus:  $L \times TV \times AP$  (cm<sup>3</sup>)**

**a = before treatment ( aL, aTV, aAP )**

**b = after treatment ( bL, bTV , bAP )**

**Table 6: Volume Change ( Vol 1-Vol 2 )**

	Vol 1	Vol 2	change~l
1	.	.	.
2	12,5	4,32	8,18
3	30,375	9,24	21,135
4	3,875	3,125	0,75
5	41,624	3,696	37,928
6	1,848	0,312	1,536
7	.	.	.
8	0,12	0,028	0,092
9	5,67	3,276	2,394
10	0,648	0,2	0,448
11	5,304	3,596	1,708
12	3,6	0	3,6
13	0,126	0,108	0,018
14	7,2	5,88	1,32
15	4,368	2,142	2,226

**Table 7: (Ulcerated lesions) – Area 1**

	area1	amL	amTV
1	8,75	3,5	2,5
2	.	.	.
3	.	.	.
4	.	.	.
5	.	.	.
6	.	.	.
7	11,25	4,5	2,5
8	.	.	.
9	.	.	.
10	.	.	.
11	.	.	.
12	.	.	.
13	.	.	.
14	.	.	.
15	.	.	.

**Table 8: (Ulcerated lesions) – Area 2**

	area2	bmL	bmTV
1	6	3	2
2	.	.	.
3	.	.	.
4	.	.	.
5	.	.	.
6	.	.	.
7	8	4	2
8	.	.	.
9	.	.	.
10	.	.	.
11	.	.	.
12	.	.	.
13	.	.	.
14	.	.	.
15	.	.	.

**Table 9: Change in area (cm<sup>2</sup>)**

Change in area	Freq.	Percent	Cum.
2,75	1	50	50
3,25	1	50	100
Total	2	100	

## **Part E : Glossary and Abbreviations**

- Haemangioma = Infantile haemangioma = IH
- Hemangioma (USA) = Haemangioma
- VEGF : Vascular Endothelial Growth Factor
- FGF : Fibroblast Growth Factor
- PKA : Protein Kinase A
- NOS : Nitric Oxide Synthase
- NO : Nitric Oxide
- Src : Rous sarcoma oncogene cellular homologue
- MAPK : Mitogen Activated Protein Kinase
- RCWMCH : Red Cross War Memorial Children's Hospital
- ECG : Electrocardiogram
- ISSVA : International Society for the Study of Vascular Anomalies
- MRI : Magnetic Resonance Imaging