

**SPERM ABNORMALITIES IN THE DOG: A LIGHT AND ELECTRON  
MICROSCOPIC STUDY**

---

Edmund Eric Oettlé

A thesis submitted to the Faculty of Medicine, University of  
Cape Town, in fulfilment of the requirements for the degree  
of Doctor of Philosophy.

Cape Town, 1990

The University of Cape Town has been given  
the right to reproduce this thesis in whole  
or in part. Copyright is held by the author.

The copyright of this thesis vests in the author. No quotation from it or information derived from it is to be published without full acknowledgement of the source. The thesis is to be used for private study or non-commercial research purposes only.

Published by the University of Cape Town (UCT) in terms of the non-exclusive license granted to UCT by the author.

## **ABSTRACT**

OETTLÉ, Edmund Eric, Ph.D thesis (1990). Department of Anatomy and Cell Biology, Medical School, University of Cape Town.

### **SPERM ABNORMALITIES IN THE DOG: A LIGHT AND ELECTRON MICROSCOPIC STUDY**

This thesis is a systematic description of normal and abnormal dog spermatozoa by means of bright field light and transmission electron microscopy, and an investigation into the effect that abnormal sperm have on canine fertility. A total of 101 ejaculates were collected from 88 dogs, of 34 different breeds. Sperm samples were examined macroscopically for volume, colour, consistency, and pH. Microscopic evaluation of sperm motility was conducted on all samples. Morphological evaluation using light microscopy was conducted on 71 of the samples. Samples from 10 of the dogs were examined ultrastructurally. A novel classification for abnormal dog sperm is presented. Abnormal sperm were classified into one of the following groups: Acrosomal defects, head defects, midpiece defects, tail defects and other abnormalities. Abnormalities were further sub-divided into major and minor defects. The most common abnormalities

encountered were major sperm head defects. The abnormalities are compared with those described for other species, in particular the bull and man.

The association between the percentage abnormal sperm in the ejaculate and the fertility of the dog was statistically evaluated. On this basis, the dogs were divided into normal and sub-normal groups. The percentage normal morphology below which fertility was adversely affected was found to be sixty percent. The fertility of dogs with greater than or equal to 60 percent normal morphology was 61 percent, while the fertility of dogs with less than 60 percent normal morphology was 13 percent. There was no statistical difference between the ages of the dogs in the two groups; from this it was concluded that sub-fertility may affect a dog at any age. A means of evaluating dogs for reproductive potential is discussed.

## DECLARATION

I declare that this thesis is my own, unaided work. It is being submitted for the degree of Doctor of Philosophy in the University of Cape Town. It has not been submitted before for any degree or examination in any other University.

Signed by candidate

Signature Removed

Edmund Eric Oettle

24 day of July, 1990.

In Memory of my Father

Alfred George Oettle

22.6.1919 - 8.11.1967

## ACKNOWLEDGEMENTS

The encouragement and guidance offered by my supervisor, Professor B. B. Rawdon, are greatly appreciated. The study was supported by financial assistance from the Medical Research Council of South Africa. Thanks are extended to Professor M. Henneberg and Dr D. O. Chalton for advice on the statistical methods employed. I would like to thank Professor R. I. Coubrough for introducing me to the field of spermatology. The technical assistance given by Mr J. Soley in the preparation of specimens for electron microscopy is gratefully acknowledged. Colour photographs were processed by Mrs H. Smit; line drawings were prepared by Mrs E. Fuller. Thanks are extended to Sisters A. E. Botha and D. van Zyl, whose efficient running of the Genesiology small animal clinic lightened the task enormously.

## TABLE OF CONTENTS

Chapter	Page
1. INTRODUCTION.....	1
2. BACKGROUND INFORMATION ON THE ANATOMY AND PHYSIOLOGY OF CANINE REPRODUCTION.....	4
2.1. Testicular development and spermatogenesis:	4
2.2. The blood-testis barrier.....	12
2.3. The epididymis.....	13
2.4. Factors influencing spermatogenesis.....	17
2.4.1. Nutrition.....	17
2.4.2. Hormones.....	19
2.4.3. Temperature.....	20
2.4.4. Orchitis and epididymitis.....	22
2.4.5. Other factors.....	23
2.5. Semen.....	28
2.5.1. Spermatozoa.....	28
2.5.1.1. Enzyme systems.....	28
2.5.1.2. Sperm respiration and motility....	30
2.5.1.3. Sperm motility in relation to axonemal structure.....	30
2.5.2. Seminal plasma.....	35
2.5.3. Whole semen.....	37
3. MATERIALS AND METHODS.....	42
3.1. Physical examination of the dogs.....	42
3.2. Genital examination.....	43



4.3.2.3.	Detached heads.....	67
4.3.2.4.	Nuclear decondensation.....	68
4.4.	Midpiece abnormalities.....	68
4.4.1.	Major midpiece abnormalities.....	68
4.4.1.1.	Retention of cytoplasmic droplets.	68
4.4.1.2.	Ruptured midpiece.....	69
4.4.1.3.	Pseudodroplet defect.....	69
4.4.1.4.	Kinked midpiece.....	69
4.4.1.5.	Other midpiece defects.....	70
4.4.2.	Minor midpiece abnormalities.....	71
4.4.2.1.	Proximal droplets.....	71
4.4.2.2.	Distal droplets.....	71
4.5.	Tail abnormalities.....	72
4.5.1.	Major tail abnormalities.....	72
4.5.1.1.	The "Dag" defect.....	72
4.5.1.2.	Double tails.....	72
4.5.2.	Minor tail abnormalities.....	73
4.5.2.1.	Simple coiling of the tail.....	73
4.6.	Sperm agglutination.....	74
4.7.	Foreign cells.....	74
4.7.1.	Macrophages and phagocytosis of sperm.....	74
4.7.2.	Sperm precursors.....	74
4.7.3.	Leucocytes.....	75
4.7.4.	Epithelial cells.....	75
4.8.	Patient data.....	76
4.9.	Statistical evaluation.....	76

4.9.1. Significance of association between the percentage normal morphology and the pregnancy rate.....	76
4.9.2. Strength of association (Phi co- efficient) of the Chi-squared values with fertility.....	76
4.9.3. Division of the dogs into normal and sub-normal groups.....	77
5. DISCUSSION.....	151
5.1. Evaluation of methods .....	151
5.1.1. Microscopical evaluation.....	153
5.1.1.1. Motility.....	153
5.1.1.2. Morphology.....	154
a. Morphological stains.....	155
b. Morphological classification of abnormal sperm.....	163
5.2. Evaluation of results.....	173
5.2.1. Sperm morphology.....	173
5.2.1.1. Normal morphology.....	173
5.2.1.2. Acrosomal abnormalities.....	174
a. Major acrosomal defects.....	174
b. Minor acrosomal defects.....	176
5.2.1.3. Head abnormalities.....	177
a. Major head abnormalities.....	177
b. Minor head abnormalities.....	180
5.2.1.4. Midpiece abnormalities.....	182
a. Major midpiece abnormalities.....	182

b. Minor midpiece abnormalities.....	184
5.2.1.5. Tail abnormalities.....	184
a. Major tail abnormalities.....	184
b. Minor tail abnormalities.....	185
5.2.1.6. Other abnormalities.....	186
5.2.2. Semen quality and fertility.....	188
5.2.2.1. Division of the dogs into normal and sub-normal groups on the basis of fertility.....	189
a. Differences between the normal and sub- normal groups.....	190
5.3. General discussion.....	193
5.3.1. Other methods of assessment of sperm function.....	193
5.3.2. Causes of sperm defects.....	194
5.3.2.1. Physical and chemical causes.....	194
5.3.2.2. Infectious causes.....	196
5.3.2.3. Hereditary causes.....	197
5.3.2.4. Iatrogenic causes.....	198
a. Effect of processing for cryo- preservation.....	198
5.3.2.5. Idiopathic and other causes.....	198
5.3.3. Assessment of dogs for genital soundness.....	200

APPENDICES.....	202
Appendix 1. Staining methods.....	202
Appendix 2. Sample processing for electron microscopy.....	206
Appendix 3. Patient data.....	209
Appendix 4. Spermograms of patients and pregnancy data.....	221
REFERENCES.....	224

## LIST OF FIGURES

	Page
1. Schematic representation of spermatogenesis.....	7
2. Phases in the transformation of the spermatid to the spermatozoon.....	9
3. Schematic representation of a cross section through the axoneme.....	34
4. Examples of primary and secondary sperm abnormalities (after Christiansen, 1984).....	169
5. Dog sperm morphology (after Burke, 1986).....	171

## LIST OF TABLES

	Page
1. Composition of plasma in the canine cauda epididymis.....	14
2. Composition of dog semen and seminal fractions....	39
3. Morphological classification of sperm from the dogs in this study.....	52
4. Chi-squared values at various percentages of normal sperm .....	78
5. Strength of association (Phi coefficients) of the Chi-squared values for pregnancy at various percentages of normal sperm.....	79
6. Spermograms of "normal" and "sub-normal" dogs....	80
7. Blom's classification of the bull spermogram.....	164
8. Sperm defects according to Christiansen.....	165
9. Sperm abnormalities according to Seager.....	166

## LIST OF PLATES

<b>The light micrographs.....</b>	<b>81</b>
1. Normal dog sperm, acrosomal loss, major acrosomal abnormalities.....	83
2. Major acrosomal abnormalities, cont.....	85
3. Minor acrosomal abnormalities.....	87
4. Major head abnormalities.....	89
5. Major head abnormalities, cont.....	91
6. Minor head abnormalities.....	93
7. Minor head abnormalities, midpiece abnormalities..	95
8. Midpiece abnormalities, cont.....	97
9. Major tail abnormalities.....	99
10. Major and minor tail abnormalities, multiple abnormalities.....	101
11. Multiple abnormalities, cont.....	103
12. Minor tail abnormalities, cont.....	105
13. Other abnormalities.....	107
14. Sperm agglutination.....	109
<b>The electron micrographs.....</b>	<b>110</b>
1. Normal dog sperm.....	112
2. Major acrosomal abnormalities - lipping.....	114
3. Major acrosomal abnormalities - cysts.....	116
4. Other major acrosomal abnormalities.....	118

5. Minor acrosomal abnormalities - the acrosome reaction.....	120
6. Minor acrosomal abnormalities, cont.....	122
7. Major head abnormalities: the diadem defect.....	124
8. Major head abnormalities: other nuclear vacuoles..	126
9. Major head abnormalities: nuclear ridging.....	128
10. Other major head abnormalitie«.....	130
11. Other major head abnormalities, minor head abnormalities.....	132
12. Other head abnormalities: head-base defects.....	134
13. Other head abnormalities, cont.: head-base defects.....	136
14. Major midpiece abnormalities.....	138
15. Major midpiece abnormalities, cont.....	140
16. Major midpiece abnormalities, cont., minor midpiece abnormalities.....	142
17. Midpiece abnormalities, cont., major tail abnormalities.....	144
18. Major tail abnormalities, cont.: the "Dag" defect.....	146
19. Bizarre and multiple abnormalities.....	148
20. Other abnormalities.....	150

"In all the things of Nature there is something marvellous"

Aristotle, Parts of animals 645 a 16

"A million million spermatozoa

All of them alive:

Out of their cataclysm but one poor Noah

Dare hope to survive,

And among that billion minus one

Might have chanced to be

Shakespeare, another Newton, a new Donne-

But (alas) the One was Me."

Aldous Huxley, The Fifth Philosopher's Song.

## CHAPTER 1. INTRODUCTION

The dog will always hold a special place in relation to man. Throughout the ages, Canis familiaris has served man's needs faithfully, despite deplorable conditions and treatment at times. Dogs occur in all corners of the globe, and virtually all cultures have kept domesticated dogs for utility or pleasure. They are highly adaptable, being able to survive extremes of both heat and cold. In many instances, the dog was the subject of the first experiments conducted on animals, and is still used extensively as an experimental animal today.

The first description of dog spermatozoa (sperm) was published by Leeuwenhoek in 1679, some 109 years after the development of the compound light microscope (Singer, 1959). Spallanzani (1781) was the pioneer of artificial insemination (AI), and recorded the first successful AI, in a bitch. This was repeated the following year by Rissi (1782), also in a bitch. By 1897, Heape reported that 15 out of 19 bitches that he had artificially inseminated had conceived. Despite an early start, the study of dog semen went into an eclipse for over a century, and interest was revived only in the twentieth century (Amantea, 1914 a; b).

Despite advances in microscopy, including improved design of the light microscope and the use of specific differential stains, as well as the quantum leap afforded by the electron microscope, no detailed systematic description of dog sperm exists. Thus there is no comparison of light with electron microscopic findings, or comparison of sperm defects in the dog with those noted in other animals. At best, line drawings adapted from other species form the sole basis on which rests the evaluation of an enormous amount of clinical material. Thus comparison of other workers' results becomes difficult to nigh impossible, and the student that is unfamiliar with the field is faced with an array of conflicting information and ideas that have arisen over the years. The main objective of this thesis is to provide a systematic morphological description of normal and abnormal dog sperm, which will form the basis of a system of classification. This will enable more consistent and comparable data to be collected and collated, thereby clarifying the current obscurities. Dogs produce structurally abnormal sperm: the hypothesis that these have an adverse impact on fertility is also tested in this thesis.

The domestic dog is closely related to many wild canidae, and the description and definition of the parameters of fertility will have application to many of these species as well. With the interest that has recently been generated in

the field of preservation of endangered species, the results of this study could find far reaching application. Furthermore, the identification of sperm defects, and their ultimate association with fertility has economic implications for breeders. While the dog industry is at present not very large, it is felt that there is potential for growth, and the need for definition of the parameters of fertility will become increasingly important.

## CHAPTER 2. BACKGROUND INFORMATION ON THE ANATOMY AND PHYSIOLOGY OF CANINE REPRODUCTION

A brief overview of spermatogenesis is given which is pertinent to understanding the mechanisms of sperm production, and hence the understanding of the sperm abnormalities which follow.

### 2.1. Testicular development and spermatogenesis

Very little work has been done in the dog, so much of what follows has been collated from studies conducted in other species.

Spermatozoa are first produced at puberty, but they represent the culmination of a series of events that begin in the embryo. The testes develop from the urogenital ridge and are largely mesodermal in origin (Monesi, 1972). As development proceeds, testis cords grow inwards from the germinal epithelium; soon the tunica albuginea develops between the cords and the epithelium, and thereafter further development proceeds within the deeper parts of the gonad. This is in contrast to the female, where development is confined to the cortex of the developing ovary. The exact sequence of events whereby the seminiferous tubules

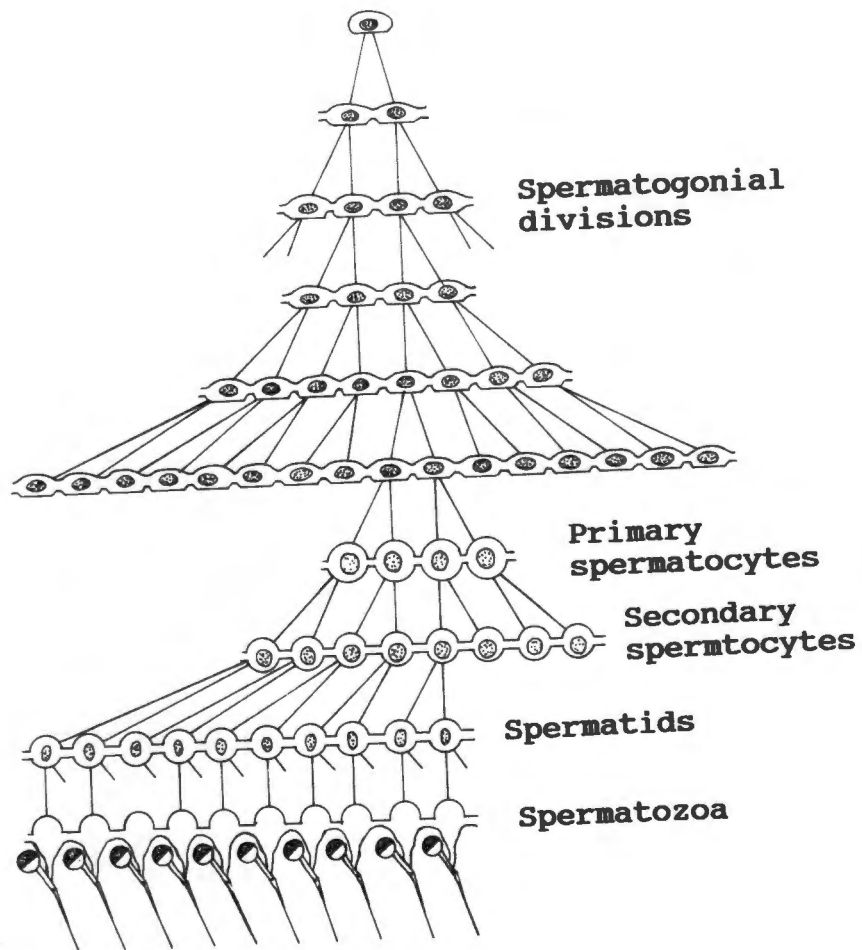
eventually contain rapidly dividing spermatogonia alongside highly specialized Sertoli cells (cellulae sustentaculares) which never divide in the mature testis, is unknown.

The interstitium, composed mainly of Leydig cells (cellulae interstitiales), is mesenchymal in origin. These Leydig cells occur in clumps around the blood vessels and produce testosterone under control of the hypophysis. Soon the developing testis joins the mesonephric (Wolffian) duct through some of the efferent ductules. The prostate, bulbo-urethral and other urethral glands develop as outgrowths from the mesonephric duct.

The testes ultimately migrate to lie extra-abdominally. The testicular tissue, surrounded by the relatively inelastic tunica albuginea, is enclosed by a double-layered peritoneal sac, the visceral and parietal layers of the tunica vaginalis, and lies within the scrotal skin. This is often pigmented in the dog, and is lined by a layer of connective tissue containing smooth muscle (tunica dartos). This muscle layer plays a part in testicular thermoregulatory mechanisms, and is highly sensitive to changes in temperature (Glover, 1974).

**Figure 1. Schematic representation of spermatogenesis**

(Redrawn with modification from Saunders, 1982).



**Figure 1: Schematic representation of spermatogenesis.**  
 (Redrawn with modification from Saunders, 1982.)

**Figure 2. Phases in the transformation of the spermatid to the spermatozoon. (A-C) Golgi phase; (D,E) cap phase; (F,G) acrosome phase; (H) maturation (Redrawn from Saunders, 1982).**

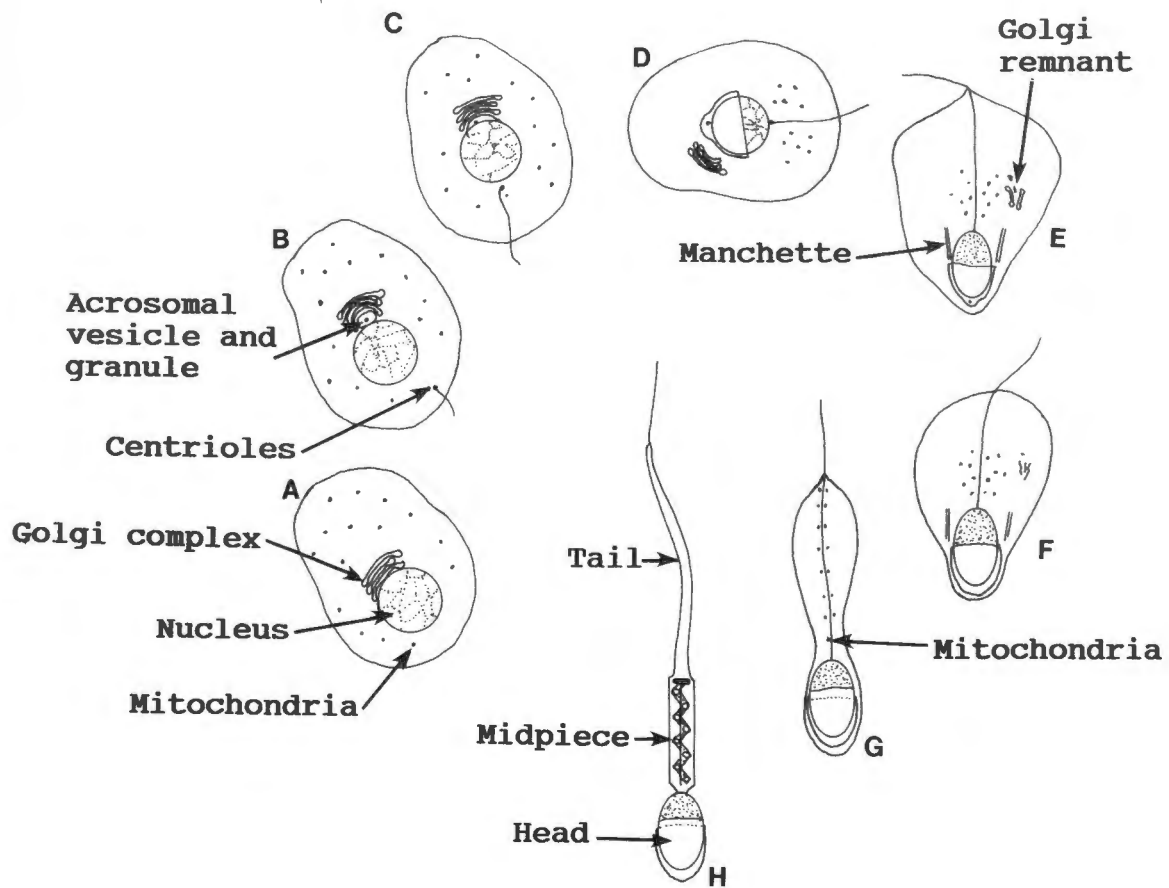


Figure 2: Phases in the transformation of the spermatid to the spermatozoon. (A-C) Golgi phase; (D, E) cap phase; (F, G) acrosome phase; (H) mature spermatozoon. (Redrawn from Saunders, 1982.)

Mammalian spermatogenesis consists of two clearly defined phases: spermatocytogenesis and spermiogenesis (Fig. 1). Spermatocytogenesis involves the mitotic division of the spermatogonial stem cells to provide successive generations of type A spermatogonia, and intermediate-type spermatogonia, which yield type B spermatogonia. Each spermatogonium B divides once, yielding two primary (preleptotene) spermatocytes. These undergo meiosis, which leads via two diploid secondary spermatocytes to the formation of four haploid spermatids.

Spermiogenesis involves the maturation of the spermatids into spermatozoa (Fig. 2). This may be divided into the following stages: a) The Golgi phase, when the pro-acrosomic granules arising from the Golgi apparatus fuse to form the pro-acrosome. b) The cap phase, when the pro-acrosomic granules separate from the Golgi apparatus and assume the form of a cap over the anterior part of the nucleus. At about this time, the centrioles begin to move: the proximal one takes up its position at the base of the nucleus, while the distal one starts to form the flagellum. c) The acrosome phase, when the pro-acrosome transforms into the acrosome proper. At the same time there is condensation of the nucleus and migration of the bulk of the cytoplasm posteriorly. Cytoplasmic microtubules associate to form a cylindrical structure, called the manchette, which extends caudally from a ringlike specialization of the cell membrane

located at the posterior margin of the acrosomal cap. The manchette encircles the initial part of the flagellum, and is associated with the organization of the midpiece and tail (flagellum); during the maturation phase, the manchette disappears. Around the tail a ring or annulus is formed from the cytoplasmic material contributed by the chromatoid body. The annulus will eventually slide along the flagellum and come to rest at the caudal end of the midpiece. The mitochondria move from the periphery of the cytoplasm towards the flagellum, in preparation for the formation of the mitochondrial helix. A fibrous sheath appears around the distal portion of the flagellum. d) The maturation phase, when the spermatid completes its transformation into a spermatozoon, and the functionally immature sperm are released into the seminiferous tubule (see Fawcett, 1986; Mann, 1964; Mann & Lutwak-Mann, 1981; Monesi, 1972).

Large batches of spermatogonia enter mitotic division simultaneously, thus large groups of germ cells, referred to as generations, develop synchronously. Spermatids at different phases of differentiation are always associated with spermatocytes and spermatogonia at specific phases of development. The particular association of cells found at any point along the length of a seminiferous tubule changes with time, passing through all the stages before the sequence is repeated. The time interval between the series of changes occurring in a given area of epithelium between

two successive appearances of the same cellular association, is called the cycle of the seminiferous epithelium. This time is constant for each animal species. New generations of germ cells are intimately related to, and synchronized with, the earlier ones (see Fawcett, 1986; Glover, 1974; Mann & Lutwak-Mann, 1981; Monesi, 1972).

The duration of the cycle has been found to be 12 days in the rat, and a spermatogonium takes about 4 cycles (i.e. 48 days) to complete its differentiation and to be released as a mature spermatozoon (Fawcett, 1986). Spermatogenesis in the dog normally takes 4-5 cycles of 13-14 days each, that is, approximately 55-70 days, till the sperm is ready to be ejaculated (Foote et al., 1972; Shille & Stabenfeldt, 1980; Christiansen, 1984).

## 2.2. The blood-testis barrier

A blood-testis barrier, similar to the blood-brain barrier, has been demonstrated in a number of mammals. It has been shown that while water, urea, ethanol and bicarbonate ions pass freely into the fluid of the rete testis, inorganic ions such as sodium, potassium and chloride enter only slowly, while permeability to albumin is very low. A major part of the barrier appears to be formed by the tight junctions between the interlamellar cells which form a myoid layer outside the basal lamina of the seminiferous tubules.

A second part of the barrier exists between the Sertoli cells, in the form of special junctional complexes between adjacent cells. If there is sufficient damage to the blood-testis barrier this can lead to the production of auto-antibodies to sperm and result in infertility (Fawcett, 1986; Glover, 1974; Mann & Lutwak-Mann, 1981).

### 2.3. The epididymis

The morphological and functional integrity of the epididymis is androgen-dependant. Changes in tubular diameter, epithelial height, and histochemical characteristics after castration, and their reversal or prevention by the administration of exogenous testosterone, have been well documented. It appears that maturation of sperm in the epididymis is also androgen-dependant, since the removal of androgen causes epididymal sperm to lose their viability and rapidly degenerate (Glover, 1974; Danzo *et al.*, 1975). The composition of epididymal plasma in the dog is shown in Table 1.

**Table 1: Composition of plasma in the canine cauda epididymis** (Adapted from Mann & Lutwak-Mann, 1981)

Constituent	Quantity		
	Mean	S.D.	
Na	22.0	2.8	mEq./l
K	37.6	0.4	"
Mg	2.2	0.2	"
Ca	1.7	0.1	"
Zn	0.1	0	"
Cl	15.5	1.6	"
Total protein	3016	335	mg/100 ml
Glycerolphosphorylcholine	924	239	"
Carnitine	485	111	"
Total sialic acid	265	12.3	"
Total nitrogen	1200	169	"
Total phosphorus	590	43	"
Total carbohydrate	1080	4.2	"
Lactic acid	98.5	9.8	"
Cholesterol	25.1	3.4	"
pH	6.8	0.1	
Freezing point depression	0.59	0.02	<sup>0</sup> C
Spermatocrit	34.6	0.7	%

The epididymis may be divided into 3 parts, according to structure and function, namely the initial, middle and terminal segments. These regions do not correspond with the head, body and tail of the epididymis, which are anatomical features that aid in orientation.

The initial and middle segments of the epididymis are responsible for sperm maturation, the terminal portion for sperm storage. The maturation events that take place in the proximal parts of this duct probably require quite different environmental conditions to those necessary for sperm storage in the distal segment. (Skinner, 1971; Glover & Nicander, 1971). Spermatozoa entering the head of the epididymis from the testis exhibit no propulsive movements and have no fertilizing ability. These two properties are acquired gradually during transit along the epididymis. Maturation of the spermatozoa involves the deposition on the sperm surface of some epididymis-specific glycoproteins, at least one of which is synthesized in the initial segment under the influence of a factor present in the testicular plasma. Motility can be induced in vitro in spermatozoa from the head of the epididymis of the bull by incubating them with diluents containing phosphodiesterase inhibitors, thereby raising the intracellular cyclic AMP levels (Mann & Lutwak-Mann, 1981). The situation in vivo appears to be associated with an increase in the levels of both cyclic AMP

and a special 'forward motility protein'. The presence of androgens is important for the acquisition of motility. Maturation of spermatozoa in the epididymis also involves the formation of disulphide bonds in the nucleus, the final removal of cytoplasmic remnants, and the maturation of the acrosome (Calvin & Bedford, 1971).

The epididymis also appears to be involved with the elimination of abnormal spermatozoa, since it has been found in the bull that the percentage of spermatozoa with abnormal heads is greater in the testes than in ejaculated semen (Mann & Lutwak-Mann, 1981). Conversely, in some types of epididymal dysfunction, increases in the incidence of certain sperm abnormalities, notably coiled tails and defective midpieces, coincides with abnormalities in the epididymal plasma, especially its ionic constituents and osmotic pressure (Mann & Lutwak-Mann, 1981). The limits of epididymal storage time has been established in the rabbit, where it was found that ejaculated sperm were functionally intact at 38 days after ligation of the vasa efferentia, which effectively prevented passage of testicular sperm into the epididymis. About 70 days after ligation, there was a loss of the motility of the ejaculated sperm (Adams, 1972). If the epididymal transit time is too long or too short, certain secondary sperm abnormalities occur. Ageing of sperm, caused by long periods of sexual rest, first induces damage to the acrosome, and then loss, and detachment of the

head from the midpiece (Eltes et al., 1982). These changes are distinct from the primary abnormalities which occur in old animals, due probably to the cumulative effects of multiple microtraumas. Sexual overuse also results in specific abnormalities, namely an increased incidence of retained cytoplasmic droplets due to a decreased epididymal transit time (Boucher et al., 1958). With rest or repeated ejaculations the spermogram usually returns to normal in over- or under-used animals respectively. Transit time through the epididymis is between 8 and 15 days (Esnault et al., 1975).

#### **2.4. Factors influencing spermatogenesis**

Many factors are known to influence spermatogenesis, and there is a vast literature pertaining to this area. Some of the more important clinical aspects are summarized below. Factors that cause sperm abnormalities will be discussed in Chapter 5.

##### **2.4.1. Nutrition.**

Nutritional deficiency has long been known to exert a deleterious effect on reproduction in the male. In general, a common early sign of underfeeding or dietary protein deficiency is the suppression of libido, the arrest of growth and secretory activity of the accessory reproductive

glands, and delayed puberty. The primary lesion in nutritionally induced androgenic insufficiency is in the hypothalamus and hypophysis, not in the testis. Certain hypovitaminoses and protein deprivation act by interfering with the neural regulation of the pituitary gland. This condition is sometimes called 'pseudohypophysectomy', to emphasize that the basic lesion underlying the testicular insufficiency is in the hypophysis (Paufler, 1967).

Folic acid seems to be an important requirement for meiosis; a deficiency results in lesions in the spermatogenic cells before lesions are evident in bone marrow cells. Testicular degeneration and sterility in rats have been associated with reduced levels of Vitamins A and E, and it has been demonstrated that deficiencies of the Vitamin B complex cause regressive changes in the accessory reproductive glands of the rat (Paufler, 1967). Spermatogenesis cannot proceed beyond the preleptotene stage in spermatocytes of Vitamin A deficient rats (Mann & Lutwak-Mann, 1981). Vitamin A deficiency also results in keratinisation and degenerative processes in the epithelia of the accessory glands, an increase in sperm abnormalities and the suppression of spermatogenesis and libido of bulls and boars (Dunn, 1980; Sadleir, 1972).

On the other hand, overfeeding leads to deposition of excessive fat around the internal organs and may lead to

endocrine disorders. This is accompanied by a loss of libido, as well as defective testicular thermoregulation due to increased scrotal insulation. (Paufler, 1967; Sadleir, 1972).

#### 2.4.2. Hormones.

The hypophyseal gonadotropins, follicle stimulating hormone (FSH) and luteinising hormone (LH), are the hormones that control spermatogenesis. It appears that LH is the more important hormone, since some degree of spermatogenesis can be maintained in hypophysectomised animals by replacement therapy with LH. Release of hypophyseal gonadotropins is under hypothalamic control, mediated by the decapeptide gonadotropin-releasing hormone (Short, 1972; Mann & Lutwak-Mann, 1981).

Spermatogenesis may be affected by steroids. Oestradiol produces a sharp reduction in the testicular weight of rats, an effect that can be partially reversed by the injection of testosterone. Progesterone has a profound suppressive effect on libido (Paufler 1967). Testosterone can maintain spermatogenesis but the dose is important: in rats, low doses reduce spermatogenesis by suppressing the hypophysis, but high doses overcome this by exerting a direct effect on spermatogenesis. Indeed, spermatogenesis can be re-initiated in hypophysectomised animals by testosterone (Glover, 1974).

### 2.4.3. Temperature

In many species testicular descent occurs during foetal life, but in the dog the testes descend postnatally. It is important that the testes should have descended by 6 months postnatally. Thermoregulation of the testes is essential in maintaining normal sperm production. Mechanisms whereby the testes regulate their temperature are through countercurrent heat exchange between the testicular artery and vein, through heat loss from the testicular artery because of its superficial course, and through the action of the cremaster muscle. The latter raises or lowers the testes according to the surrounding temperature. When these mechanisms are disturbed, as happens in cryptorchidism, or when normal blood circulation is impaired, a variety of defects are produced.

Experimentally induced cryptorchidism in dogs induces a loss of sperm motility, with eventual loss of spermatogenesis. It has been found, however, that the warming of scrotal testes to body temperature for a period of 10 days is insufficient to cause irreversible damage to the testes; it was concluded that the dog has a greater capacity to recover from thermally induced testicular degeneration than have some other species (Larsen, 1980). It has been reported that in the dog insect bites and stings on the scrotum result in

poorly motile sperm, and sperm with loose heads and bent tails, but there is a return to a normal spermiogram after 1 year (Bane, 1970). In the boar, an increased ambient temperature results in sperm abnormalities, notably an increase in the incidence of retained cytoplasmic droplets, and acrosomal damage (Cameron & Blackshaw, 1980). Vaccinations and systemic disease which induce a generalized fever also have an adverse effect on spermatogenesis. It would appear that the nature, degree and duration of the stress sustained by the testes influence the types and relative percentages of the sperm abnormalities which appear in the semen. An accurate history is thus an important aid in the identification of the cause of the condition (Paufler, 1967).

Naturally occurring cryptorchidism is inherited in most cases. It may be uni- or bilateral, and the testis may be situated inguinally or intra-abdominally. Right sided cryptorchidism is twice as common as left sided. A diagnosis should not be made before 6 months of age, since testes may descend normally up to this time. Many unilaterally cryptorchid dogs fail to produce spermatozoa in the ejaculate, and the volume of the ejaculate is generally reduced. There is a high frequency of Sertoli cell tumours and seminomas in retained testicles (Christiansen, 1984).

#### 2.4.4. Orchitis and epididymitis.

Orchitis is clinically obvious in the acute stage, but in the chronic stage where the heat and swelling is reduced, the testicles become firm and nodular. Bacterial orchitis may be caused by a variety of organisms, and is often difficult to treat due to the blood-testis barrier. Infection by Brucella canis can manifest as an orchitis and epididymitis, with the ejaculated sperm showing retained protoplasmic droplets, acrosomal defects, swollen midpieces and head to head agglutination (Harrop, 1966; Christiansen, 1984, Serikawa et al., 1984).

Viral orchitis has been reported in the bull (Paufler, 1967; Foster et al., 1980), and viruses may be excreted in the semen (Parsonson & Snowdon, 1974). There have been unconfirmed reports of infertility in male dogs thought to have been caused by vaccination with certain live strains of Parvo virus. Most of these were reported shortly after the first introduction of Parvo virus vaccines: if the vaccines were indeed responsible, it is possible that the degree of attenuation was insufficient.

Epididymitis may occur alone, or with a concurrent orchitis, and unless the blockage of the duct is complete, usually results in a marked leucospermia. Epididymitis can cause retention of sperm, and consequent azoospermia when

bilateral. Epididymal rupture with sperm leakage and spermatocele formation is a possible sequel. The prognosis is usually hopeless in the latter cases (Christiansen, 1984).

#### **2.4.5. Other factors**

Compared with the adult dog, the first ejaculations around puberty are noted for their smaller volume, lower concentration of sperm, and higher percentage of abnormal sperm. These parameters normalize as the animal matures. Puberty is reached at about 9 months, although some dogs may be fertile at 6 months. Testicular biopsies have been used to determine the stage at which mature sperm may be found: in collies, spermatogonial activity has been noted at 5-6 months, and the first spermatozoa reported at 9-10 months (Christiansen, 1984).

Physical trauma, usually as a result of kicks or bites to the scrotum, can, if severe enough, lead to permanent sterility (Rosenthal, 1983). The maintenance of the blood-testis barrier is essential, as its damage exposes the "foreign" haploid cells to the body's immune system, with the subsequent production of auto-antibodies. Autoimmunity manifests in two distinct ways, either as destruction of testicular cells and immature sperm, leading to a condition

known as autoimmune aspermiogenesis, or as an agglutination or lysis of the ejaculated sperm.

Autoimmune aspermatogenesis may be induced by experimental immunization. When males are immunized with pieces of their own testis or with testicular tissue from another male of the same species, there is a very violent immunological reaction. Many germinal cells are destroyed and spermatids, spermatocytes and spermatozoa are lysed in particular regions of the testis; the condition may extend to involve the whole testis. Initially, fertility is reduced, but spermatogenesis may recover over a period of months, and full fertility may be restored. Libido is not affected, indicating that the endocrine system is not unduly disturbed, and that the Leydig cells generally escape destruction. The antigens that have been isolated are proteins or glycoproteins, derived mostly from the acrosome.

The second type of autoimmunity, namely agglutination or immobilization of spermatozoa post-ejaculation, has been found mostly in man. The agglutinated sperm are functionally incompetent, in that they cannot ascend the female tract. This condition is thought to be caused by temporary or partial blockage of the vas deferens or by inflammation of the male tract, and once established, is difficult to reverse. The antibodies are evident both in blood and seminal plasma (Edwards, 1972). There are a variety of tests

available to demonstrate such antibodies. Some of these tests are routinely used in clinics investigating human infertility, but none are commercially available for use in dogs. Simple tests such as the Kremer test or the sperm-cervical mucus contact test (SCMC) (Franken *et al.*, 1986) should be relatively easy to adapt for use in the dog.

Spermatogenesis is highly sensitive to radiation, and even relatively small doses of X-rays bring about extensive damage to the seminiferous epithelium, the action being principally due to destruction of type A spermatogonia (Mann & Lutwak-Mann, 1981).

Seasonal variation in spermatogenesis, as noted specifically in some ungulates (Skinner, 1971), does not appear to occur in the dog. Since the oestrus interval in bitches is between 5 and 10 months (Christie & Bell, 1971), it is an adaptive advantage to the males being fertile throughout the year.

Drug effects are diverse, and are dose dependant. Cytostatic anti-cancer drugs have a profound effect on all rapidly dividing cells, and as such are potent inhibitors of spermatogenesis. "Win. 13,099" (N,N,-bis(dichloroacetyl)-N,N-dimethyl-1,4-xylenediamine) is a potent (but reversible) inhibitor of spermatogenesis in dogs and other animals. It was abandoned as an antifertility drug in humans because of undesirable side-effects when taken concurrently with

alcohol. Some of the organochlorines, especially those used as defoliants, have mutagenic and oestrogenic properties. They are easily absorbed through the skin, but are only slowly excreted, and are therefore extremely hazardous. Dibromochloropropane, a soil fumigant for nematodes, has marked antispermatogenic properties. This has been reported both in experimental animals, and in factory workers where the product was being produced. Organophosphates, another major group of insecticides, cause a reduction of sperm motility, although this is usually mild and transitory (Mann & Lutwak-Mann, 1981).

Testicular tumours occur fairly commonly in dogs over 7 years of age: The incidence is increased in cryptorchid dogs. Interstitial cell tumours are the most common type, but Sertoli cell tumours cause more severe clinical signs, namely feminization, loss of libido, gynaecomastia, atrophy of the unaffected testis, and bilateral ventral hair loss. Metastases occur, and thus timeous removal of the affected testis is advocated. Seminomas are usually benign, and cause no functional disturbance in the dog (Paufler, 1967; Christiansen, 1984).

Certain sperm defects have been shown to be heritable in the bull (Bertschinger, 1975; Blom, 1972; Ross et al., 1973). None have yet been shown to be so in the dog, but the possibility should always be borne in mind when advising a

client on the use of certain dogs for stud. Recently there has been a report where three related miniature Schnauzer dogs all showed similar sperm abnormalities, although they were bred and reared by different breeders (Petty & van Niekerk, 1987). While this does not prove that the abnormalities were genetically transmitted, it is likely that genetic factors are operative, since the gene pool of miniature Schnauzers is relatively small, and the chances of inbreeding is high. On the other hand, genetically transmitted defects in bulls tend to manifest as a single predominant abnormality (Bertschinger, 1975), but in these dogs, there was a wide range of abnormalities.

Hypogonadism has been found to be heritable in bulls (Paufler, 1967) and it may well prove to be so in the dog. It may be primary, such as when the testicles remain small after puberty, or secondary, as in dogs with Cushing's syndrome. Thus, caution should be exercised when advising a dog breeder who presents an animal with this condition; if possible, alternative stud animals should be used.

## **2.5. Semen**

Semen is made up of two components, namely spermatozoa and seminal plasma. These differ in origin, composition and function, and the ratio between them is determined to a large extent by the size, storage capacity and output of the testes and accessory glands respectively.

### **2.5.1. Spermatozoa**

#### **2.5.1.1. Enzyme systems.**

Spermatozoa possess a multitude of enzyme systems. These may be divided into two main categories: those involved with sperm metabolism (associated with the midpiece) and those involved with fertilization (associated mainly with the head, in particular the acrosome). Acrosomal enzymes are similar to those present in lysosomes, and are organized by the Golgi complex during the process of spermatogenesis. These enzymes play important roles during fertilization (Zaneveld, 1975).

The high concentration of enzymes makes the acrosome, like the lysosomes of other cells, an extremely sensitive, labile organelle. The distribution of these enzymes in relation to the different acrosomal membranes endows each of these membranes with its own individual characteristics. The outer

membrane is fragile, and is easily displaced or disrupted. Non-specific degenerative changes induced in spermatozoa by ageing, cold shock, freezing and thawing, osmotic effects, dilution or centrifugation are associated with swelling and vacuolation of the acrosome; under specific conditions vesiculation of the outer acrosomal membrane may occur. As a consequence there is increased permeability and leakage of the acrosomal contents (Mann & Lutwak-Mann, 1981), which results in differential "live-dead" staining with the Eosin-Nigrosin technique. Acrosomal integrity may be assessed with Spermac stain, since this technique can be used to achieve differential staining of the acrosome (Oettlé, 1986a; b; c). The staining characteristics of sperm will be discussed in detail below.

There are enzyme inhibitors in seminal plasma of certain species. It seems that their function is to deactivate free enzymes which may have been exuded from dying spermatozoa. This would otherwise damage the remaining sperm, to the detriment of fertility. During passage through the female genital tract the sperm are separated from the seminal plasma, which thereby also removes these inhibiting substances. However, some inhibitors are firmly bound to the plasma membrane of the sperm, and are only removed on capacitation of sperm. This is the period of maturation of the sperm that normally takes place in the female genital

tract, before fertilization can occur. Artificial substances which prevent these changes from taking place have potential for use as contraceptives (Mann & Lutwak-Mann, 1981).

#### 2.5.1.2. Sperm respiration and motility.

Glycolysis and respiration are the two main processes whereby sperm produce their energy. Fructose is the main sugar in semen, and under anaerobic conditions sperm are able to metabolize it to lactic acid. This results in the drop in pH noted when ejaculated semen is held over a period of time. Lactic acid is not metabolized further unless air is admitted, when it undergoes oxidation to pyruvic acid, and thereby provides the substrate for respiration. Glycolysis, followed by the Krebs citric acid cycle, represents the main pathway for the breakdown of exogenous carbohydrate by spermatozoa. In the female genital tract, the oxygen tension in the blood and the transfer of the oxygen to the tissue fluids is adequate to maintain aerobic respiration by the sperm (Mann & Lutwak-Mann, 1981).

#### 2.5.1.3. Sperm motility in relation to axonemal structure.

Flagellar motion is the major source of energy expenditure by spermatozoa. Adenosine triphosphate (ATP) represents the primary donor of this energy. This energy is generated along the length of the flagellum by a mechano-chemical process

coupled to the enzymatic dephosphorylation of ATP. Transduction of energy within the sperm tail is made possible by the diffusion of mitochondrial ATP along the flagellum. In respect to the efficiency of energy usage, the axonemal structure is important. The core of the flagellum is formed by the axial filament complex (axoneme), consisting of a central pair of single fibrils and nine double peripheral fibrils, from which extend the dynein side arms. In addition to this, there is also a set of nine outer dense fibres creating the familiar 9+9+2 pattern. The principal piece also has an outer fibrous sheath, composed of a series of circumferentially arranged ribs terminating in two longitudinal columns (Fig. 3). Two important proteins located in the microtubules are involved in the initiation and maintenance of flagellar motion, and are known as tubulin and dynein. Tubulin is the principal structural protein of the cylindrical wall of the microtubules. Dynein is the principal protein in the arms of the axonemal fibrils, and has ATPase activity associated with it.

The progressive movement of a spermatozoon is caused by an undulating, helically bending wave propagated backwards along the flagellum, resulting in a forward thrust which propels the sperm. It was thought that this bending results from a localized shortening of the axonemal fibrils on one side of the flagellum, but it appears now that it is not an alteration of the length of the fibrils, but a sliding of

the fibrils past each other, by interaction of the dynein arms with ATP. Interaction with tubulin also appears to be involved, and the process may be likened to the actin-myosin sliding filament mechanism seen in muscle fibres. Apart from temperature, which has a profound effect on flagellar motion, capacitation and the acrosome reaction also affect motion, sperm being vigorous in their movements after both these reactions. Conversely, certain conditions in which dynein is absent result in abnormal or loss of motility; Kartagener's syndrome is a good example of such a condition (Coetzee et al., 1985).

Motility of sperm may be improved or prolonged in vitro by treatment with methylxanthines, notably caffeine and theophylline, which act by providing the sperm with more cyclic AMP. This is probably achieved by the specific inhibitory effect of these substances on phosphodiesterase. (Barkay et al., 1984; Mann & Lutwak-Mann, 1981).

**Figure 3. Schematic representation of a cross section through the axoneme (Redrawn from Mann & Lutwak-Mann, 1981).**

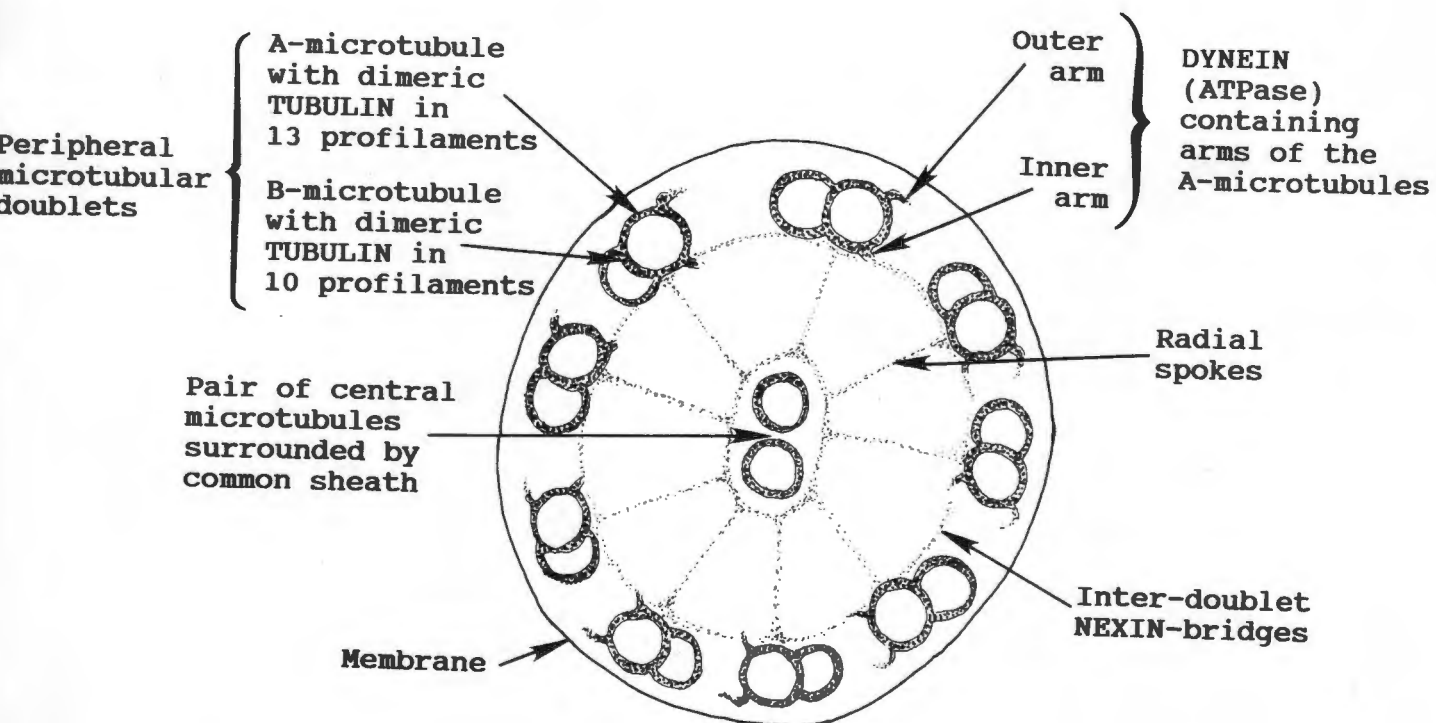


Figure 3: Schematic representation of a cross section through the axoneme of a spermatozoon. (Redrawn from Mann & Lutwak-Mann, 1981.)

As sperm pass from the caput to the cauda epididymis, they show a gradual rise in cyclic AMP concurrent with initiation of motility. Cold shock, which markedly reduces motility, has been shown to induce loss through leakage of intracellular cyclic AMP. If the sperm are cooled slowly, leakage does not occur, or is at least reduced, so that on warming of the sperm, motility is regained fully. In cold shocked samples, motility is not regained to the same degree, presumably due to the loss of cyclic AMP as well as to the membrane damage that accompanied such loss (Mann & Lutwak-Mann, 1981).

#### 2.5.2. Seminal plasma

The dog does not possess seminal vesicles, and the bulk of the seminal plasma is made up of secretions from the prostate gland. Smaller amounts of fluid are secreted from the urethral glands, and minute amounts from the epididymis and vas deferens. Seminal plasma contains certain characteristic substances, among them citric acid, fructose, a prostatic phosphatase, phosphorylcholine, ergothioneine, inositol and glycerylphosphorylcholine. Cellular debris is often present, and represents cellular elements shed from the accessory glands. Macrophages may also occur; these apparently phagocytose dead spermatozoa in the epididymis. They are not found in large numbers in the normal ejaculate.

The prostate gland is normally situated in the middle of the pelvis, resting on the symphysis pelvis, about 1 cm posterior to the neck of the bladder. It surrounds the neck of the bladder at its junction with the urethra, and contains numerous excretory ducts which open into the urethra. The prostate gland is globular in shape, and has a median dorsal furrow which divides it into two equal parts. On rectal palpation it should be firm yet elastic, and has an average diameter of about 2 cm (Christiansen, 1984). The output of secretion by the prostate is under the influence of testosterone and the cessation of prostatic secretion induced by castration is to a large degree reversible following the injection of testosterone. Prostatic fluid is colourless, generally slightly acid (pH 6.5), and contains many powerful proteolytic enzymes. The citric acid concentration is lower in the dog than in man. Hyaluronidase levels are relatively low in the dog, but glycosidases occur in about the same concentrations as in human semen. Acid phosphatase activity is much lower than in human seminal plasma. High levels of copper and zinc are characteristic of canine prostatic secretions (Mann, 1964).

### 2.5.3. Whole semen

Dog semen is very variable in composition, the major cause of this variability being differences in breed. Apart from this, there are significant daily variations in the semen composition in the same individual; both the spermatogenic activity of the testes and the secretory function of the accessory glands are subject to considerable fluctuation and may be influenced by light, temperature, season, nutrition, and other environmental factors. Because of this variation it is essential to perform a series of semen analyses on an individual before making a diagnosis. Furthermore, the method and frequency of collection will influence semen quality (Mann, 1964).

The average specific gravity of whole semen in the dog is 1.011, as compared to 1.028 in man and 1.035 in the bull. The differences are largely due to the ratios of sperm to seminal plasma in these species. (Mann, 1964).

Dog semen is ejaculated in 3 fractions, namely pre-sperm, sperm rich, and post-sperm fractions. The first fraction is small in volume (generally about 0.5 ml) and clear; it arises from the urethral glands. It is often emitted before complete erection has been attained, and is accompanied by the 'searching' motions of the dog. The second fraction is emitted after full erection has been attained, and contains

the bulk of the spermatozoa. It is usually greyish-white in colour, and has a volume of about 1 to 2 ml. The third fraction is clear and large in volume (about 10 ml), the bulk of the ejaculate being contributed by this fraction; it arises from the prostate gland. Table 2 shows the biochemical composition of dog semen.

Dog sperm are very sensitive to extraneous factors such as altered pH, tonicity, or washing in buffered solutions, and appear to be especially sensitive to diluents containing 0.02 M carbonate-bicarbonate buffer, which causes a depression in their motility (Mann, 1964).

Coitus in the dog is prolonged, and lasts up to 20 min, due to the familiar coital lock. This is due to the large swelling of the bulbus glandis at the base of the penis, that is held in position in the vagina by the caudal contraction of the constrictor vulvae et vestibulae by the bitch. These muscular contractions stimulate the ejaculatory muscles in the male, whose movements in turn stimulate the female to contract. This see-saw-like effect continues until the bitch tires, or the male can no longer ejaculate, and so the erection subsides, and the lock loosens. This mechanism of stimulation of the male by the female has practical application in the collection of semen, and will be discussed further in chapter 3.

**Table 2: Composition of dog semen and seminal fractions in the order of their appearance at ejaculation.**

(Adapted from Mann, 1964).

Constituent	Whole semen	1st Fr	2nd Fr	3rd Fr
(mEq./l)				
Na	56-124	146-195	180	136
K	8.0-8.3	4.8-6.9	13.0	7.7
Ca	0.4-0.9	0.3-2.2	0.4	0.2-0.6
Mg	0.3-0.7	1.3-1.7	0.8	0.1-0.6
Cl	151.4	151-171	192	160
Bicarbonate	1.1-6.4	1.7-2.5	2.3-5.4	1.7-2.7
(mg/100ml)				
Phosphate	12.7-13.2			
Cu	0.64-0.67	0.16-0.43	0.91-1.33	0.35
Zn	7.6-9.0	1.71-2.81	14.06-19.7	6.26-8
Fe	0.02-0.09	0.01-0.04	0.04-0.1	0.015
Fructose	0.5-0.6	0.4-0.6	1.2-3.0	0.2-0.6
Lactic acid	11-30	5.8-10.7	20.6-41.2	7.9-21
Protein (%)	1.71-2.61	1.46-2	3.99	2.38

The penis has two distinct corpora cavernosa. The posterior part of the penis is divided by the median septum penis; anteriorly the os penis reaches from the bulbus glandis almost to the penis tip, into which it projects by a conical projection of fibrocartilage. The glans penis comprises two parts: the bulbus glandis, consisting of erectile tissue completely surrounding the os penis and urethra, and the pars longa penis, composed of erectile tissue dorsally and laterally. The prepuce forms a complete sheath around the anterior part of the penis (Christiansen, 1984).

There is thus a more or less continuous pulsatile emission of semen, which is thought to be deposited almost directly through the short cervical canal into the body of the uterus. Distribution of the fluid throughout the uterine horns is rapid, being promoted by myometrial contractions, so that semen is able to reach the ovarian end of the horns shortly after the beginning of coitus. Spermatozoa may thus be transported to the base of the uterine tubes within about a minute of coitus, and by means of the uterine fistula technique, have been detected at that point within 25 sec of ejaculation. Passage through the utero-tubal junction and along the uterine tubes may also be accomplished with considerable speed, for spermatozoa have been detected in the isthmus 2 minutes after coitus. Prior to ovulation sperm appear to be stored in the uterine glands of the bitch, but

this has not been conclusively proven, and is in contrast with the findings in the ewe and sow, where the main site of sperm storage in the female post ejaculation is the uterine tube (Hunter, 1975).

Much work has been done on the anatomy and physiology of the reproductive organs in the dog. There is, however, a need for further investigation in the field of sperm abnormalities; their identification, classification, and especially their influence on fertility. The present study is an attempt to clarify these areas.

## CHAPTER 3. MATERIALS AND METHODS

### 3.1. Physical examination of the dogs

It is generally accepted that a fertility investigation must include a comprehensive history and a thorough clinical examination before carefully and systematically examining the genital system (Christiansen, 1984). Information concerning feeding, management, previous health problems, previous breeding history, number of bitches served, conception rate, and litter size was obtained. Where possible, vaccination history was also obtained and included the types of vaccines used (dead or alive).

Since normal reproduction depends not only on functional sperm, but also on the ability to deposit the semen in the correct place, a normal nervous, muscular, and skeletal system are essential prerequisites. These systems were therefore examined clinically and any abnormalities noted. Attention was focused in particular on the muscles, joints and bones of the hind limbs, since these are under the most stress during coitus.

### 3.2. Genital examination

#### 3.2.1. Palpation.

The internal and external genital organs were palpated for dimensions and consistency. The normal average size of the dog testis is 3 x 2 x 1.5 cm (Christiansen, 1984), but there is enormous variation between the different breeds of dogs. A firm yet elastic testicular consistency was considered normal. Normal scrotal skin was thin, supple and elastic, and was usually pigmented. The testes should be freely moveable within the scrotum.

#### 3.2.2. Semen collection

Before attempting to collect semen from the dog, all the equipment was pre-warmed to 35 °C. The collection room was quiet and free from sudden interruptions by unfamiliar personnel, and the surface covered with a non-slip rubber mat. If a bitch was due to be inseminated, she was allowed to be present to act as an added stimulant for the male.

A total of 101 ejaculates were collected by digital manipulation from 88 dogs, of 34 different breeds. The collection method was as follows: a partial erection was induced by stimulating the penis through the prepuce. The sheath was then drawn back, and pressure applied by

oscillation on and behind the bulbus glandis, causing the dog to ejaculate. The rate of pulsation and the amount of pressure needed was varied to suit the individual dog. As a general rule, the pulsations were about one per second, and pressure applied so as to mimic the natural coital lock, which is enough to hold the penis in the vagina for the duration of coitus. Some dogs resented the sliding back of the sheath over the bulbus glandis. These patients were stimulated through the prepuce; the erection was always adequate to ensure that the tip of the penis protruded out of the prepuce, ensuring collection of an uncontaminated sample. Samples were collected in sterile glass funnels inserted into sterile plastic graduated collection tubes (15 ml Falcon tubes, # 2099, Becton Dickson Co., New Jersey).

After use, the funnels were cleaned in distilled water and sterilized by dry heat.

#### **3.2.2.1. Semen examination**

After collection, the semen samples were examined as soon as possible, in all cases within 30 minutes. During this time, the samples were protected from cold shock by maintaining them in a water bath at 32  $\frac{1}{2}$ C.

The semen was assessed according to the following parameters:

**a. Macroscopic examination**

i) The volume in ml, accurate to 0.1 ml, was read off the graduations on the collection tube.

ii) The colour was judged on a subjective scale ranging from clear through greyish to white.

iii) The consistency was estimated by gently inverting the sample and allowing it to run back down the inner side of the tube. This characteristic of the sample was subjectively compared with that of water, thin milk, milk, thin cream, cream or thick cream. Whole dog semen was usually watery, but when the second (sperm-rich) fraction was collected separately, it was found to be milky to thin creamy. This method, although subjective, was found to be adequate to assess consistency; objective fully quantitative methods, for example photometric measurements, do not render significant advantages over the simple method described above, and hence were not employed in the present study. Sperm concentration was not measured in this study.

iv) The pH was assessed by placing a drop of semen on pH strips (Merck, Darmstadt, range 6.4-7.2, accuracy 0.1).

## **b. Microscopic examination**

### **i) Motility**

Since sedimentation of dead sperm occurs reasonably rapidly, the sample was well mixed by gently inverting it a few times before drawing the aliquot for motility assessment. A wet preparation was made by placing a drop of well mixed semen on a warm slide, and covering this with a warm coverslip. The use of Pasteur pipettes to transfer the semen ensured that the drops were all of approximately the same volume, which was estimated to be about 0.06 ml. Examination was by means of phase contrast optics under 100 X and 400 X magnification. The microscope was fitted with a Leitz warm stage to maintain the temperature at 32 °C. Motility was assessed subjectively on the basis of the percentage of sperm that were moving progressively, the percentage that were moving locally (small circles, or backwards, or movement on one spot only), and the percentage that were non-motile.

### **ii) Viability**

Where the motility was poor, or it was suspected that there had been some shock to the sperm that might have depressed the motility (for example cold shock during winter morning collections), an objective assessment of viability was

performed by means of the eosin-nigrosin technique (Appendix 1). This technique exploits the principle that viable cells are able to prevent penetration of the eosin stain; these remain unstained against a black (nigrosin) background, whereas the dead cells stain pink. An objective assessment of the percentage of viable sperm is thereby obtained (Hackett & Macpherson, 1965).

### **iii) Light microscopical morphology**

#### **Development of Spermac stain for sperm morphology.**

Due to inadequacies of existing morphological stains, particularly with regard to the visualization of the acrosome, and unsatisfactory results on extended semen, a new acrosome-specific stain was developed. All reagents were obtained from Merck (Darmstadt, West Germany); Analytical grade chemicals and Certistain grade stains were used. Fixation was considered essential to preserve the acrosome, a particularly labile organelle, intact. Practicality played a major role in the choice of fixative; formaldehyde was chosen for its stability, relatively rapid action, and ready availability. A four percent solution of paraformaldehyde was made up in 0.05 M sodium phosphate buffer (pH 6.8). In order to adjust the osmolarity to that of seminal plasma, sodium citrate was added to a concentration of 2 percent. The osmolarity before the addition of paraformaldehyde was

approximately 300 mOsm. The paraformaldehyde did not dissolve easily; the solution had to be agitated on a magnetic stirrer for about 4 hours to dissolve the paraformaldehyde. A photographic wetting agent (Cascade, May & Baker, Dagenham, England) was added at the standard dilution of 1 part per 4000 to the fixative. Better results were obtained when this was included in the fixative. The reason for this is unclear.

Before experimentation with the definitive staining procedure, it was necessary to establish a difference in affinity for stain between the acrosome and the nucleus. The Wells-Awa procedure achieved this, although poorly (Wells & Awa, 1969). With this procedure, it is possible to stain the acrosome of dog sperm green while staining the nucleus red. The problem with this staining procedure is that the green stain recommended (Fast green FCF) is water soluble, so that washing of the smear after staining is not possible. This gave unacceptably high levels of background staining, making the thickness of the smear critical in order to ensure visualization of the sperm. Furthermore, semen that had been diluted for cryopreservation could not be stained, due to excessive background staining. Therefore a stain that would not be removed from the sperm by washing is a prerequisite for visualization of well-stained sperm against a clear background.

A large number of stains, including eosin B & Y, erythrosin, neutral red, rose Bengal, brilliant green, malachite green, crystal violet, pyronin Y, orange G, naphthol yellow and haematoxylin, was tested; brilliant green was found to provide the required degree of differentiation. Optimal results, namely well stained organelles against a clear background, were obtained with a one percent solution in 5 percent dextrose. Eosin B gave satisfactory nuclear staining which was retained after the preparations were washed to clear the background. This stain was made up as a 2 percent solution in 25 percent ethyl alcohol and 2 percent sodium citrate.

Separate application of the two stains was essential as they precipitate when mixed. Furthermore, addition of a 'stain excluder' was necessary to prevent green staining of the nucleus. The 'stain excluders', phosphotungstic and phosphomolybdenic acids, in the modified Shorr's stain (Oetttlé & Weldhagen, 1982) gave acceptable results. Optimal results were obtained with a mixture of 0.25 percent phosphotungstic acid, 0.25 percent phosphomolybdenic acid and 5 percent glucose in 25 percent ethyl alcohol.

### **Sample preparation**

Evenly spread thin smears were made by placing a drop of semen on a slide, and by means of another slide held at  $30^{\circ}$  to the horizontal, drawing (not pushing) the sample across the slide. The smear was air dried, and fixed and stained with the stain as described in Appendix 1. Smears were examined unmounted under oil immersion Plan 100 X objective. At least 100 sperm were evaluated per slide, to ensure a representative assessment of the sample. The microscope used was an Olympus Vanox Universal Research microscope, fitted with an Olympus C35 AD camera and PM 10 AD photomicrographic system, incorporating neutral density and tungsten filters over the light source. Colour plates were prepared from Ektachrome 50 tungsten diapositives. Light microscopic evaluation of morphology was performed on 71 of the 101 ejaculates collected; the remaining 30 were assessed for motility but not morphology.

#### **iv) Electron microscopic morphology.**

Once the above procedures had been carried out, the remainder of the semen samples from 10 dogs was taken for transmission electron microscopy. Samples were processed following standard procedures. Details of the processing are given in Appendix 2.

### **Morphological assessment**

When examining the morphological smears, sperm and other cells were allocated to one of the groups shown in Table 3.

References to the description of specific abnormalities are scarce for the dog. Much comparison was of necessity made with other species, predominantly the bull and man. It is felt that these parallels are not unjustified, as many seemingly identical defects have been described in a variety of species, and it has been suggested that these defects might share a common mechanism of development (Hancock, 1971). There are, of course, some notable differences between species, and these will be discussed under the appropriate sections.

#### **v) "Foreign" cells**

Leucocytes, precursors of mature spermatozoa, and preputial epithelial cells were visualized by means of the Diff-Quik<sup>R</sup> stain (Diff-Quik AHS del Caribe, Inc., Aguada, PR00602 USA) following Kruger et al., (1988) (see Appendix 1 for details). Since these "foreign" cells usually occur at low frequency, a thick smear was made to increase their number. In order to make a thick smear, a drop of semen was drawn

**Table 3. Morphological classification of dog sperm used in this study.**

1. Normal morphology

2. Acrosome abnormalities

- Major - lipped, cysts, abnormal distribution  
 Minor - acrosome reaction, swelling, severe damage, loss

3. Head abnormalities

- Major - macrocephalic, microcephalic, pyriform, diadem defects, other nuclear vacuoles, ridged sperm, double forms, severe pleiomorphism or bizarre forms  
 Minor - narrow heads, head-base defects, detached heads, nuclear decondensation.

4. Midpiece defects

- Major - retained cytoplasmic droplets, ruptured midpiece, pseudodroplet defect, kinked midpiece  
 Minor - distal droplets

5. Tail defects

- Major - the "Dag" defect, double tails  
 Minor - simple bent or coiled tail, terminally coiled tail

6. Sperm agglutination

- Head to head, head to tail, tail to tail, or attachment to other cells.

out over a slide in much the same way as described for a thin smear, except that the "smearing" slide was held at an angle of about  $60^{\circ}$ , and drawn rapidly across the slide, leaving a thick trail behind it. Diff-Quik<sup>R</sup> stain has only a slight affinity for sperm, and thus the "foreign" cells stand out clearly in spite of a relatively thick bed of sperm.

### 3.2.3. Libido.

A subjective assessment of libido was made when collecting semen, and if this was abnormal it was noted.

### 3.2.4. Fertility data.

Sixty nine of the 88 dogs studied were used for natural breeding or for artificial insemination. It was possible to obtain the breeding results of these in 45 cases. From previous breeding histories, a bitch was termed fertile if she had produced at least one litter of pups.

### Statistical analysis:

At present, no statistically valid association between the percentage of sperm showing normal morphology (% normal morphology) and the fertility of a sire has been established. It is well known that fertility is reduced as

the percentage abnormal sperm increases, but the point below which fertility shows a statistically significant reduction is not known. Various suggestions, based on clinical experience, which attempt to define normality in the dog, have been proposed (Burke, 1986; Christiansen, 1984), but none of these has been subjected to critical statistical evaluation, i.e. to assess the effect of the percentage normal morphology on the probability of achieving a litter of pups. In an attempt to define this, and to relate sperm morphology to fertility, the Chi-squared test was used to establish the association between the percentage normal morphology and the pregnancy rate at less than, and at greater than or equal to 50, 55, 60, 65, and 70 percent morphologically normal sperm, using 2 X 2 contingency tables and the following formula:

$$\text{Chi-squared} = \frac{(cb - ad)^2}{(a+c)(b+d)(c+d)(a+b)} \times (a+b+c+d)$$

calculated for each percentage group above. For example at the 50 percent level,

a=number of pregnancies from < 50 % normal sperm

b=number of pregnancies from ≥ 50 % normal sperm

c=number of non-pregnancies from < 50 % normal sperm

d=number of non-pregnancies from ≥ 50 % normal sperm

When Chi-squared >3.8, p < 0.05

A measure of the strength of the association (Phi coefficient,  $\psi$ ) was then calculated for the Chi-squared values at 50, 55, 60, 65, and 70 percent morphologically normal sperm, by means of the following formula:

$$\psi = \sqrt{\frac{\text{Chi-squared}}{a+b+c+d}}$$

The percent normal morphology below which fertility starts to be adversely affected was established on the basis of the greatest  $\psi$  value, and the dogs thus divided into normal and subnormal groups.

Students' t-test was used to compare the motilities, morphologies and ages of the normal and subnormal groups. Statistical procedures were carried out following Snedecor & Cochran (1967).

## CHAPTER 4. RESULTS

### 4.1. Normal morphology of dog sperm.

Under the light microscope, dog sperm stained with Spermac stain show the following characteristics. The nucleus stains red, and the acrosome, midpiece and tail green. The green component of the stain provides a semi-quantitative measure of stained material, hence the paler staining of the acrosome at the equatorial region where it is thinner. The equatorial region is a distinctive feature of dog sperm, visible even under low magnification. The mitochondrial sheath of the midpiece in the dog is approximately 1.5 times the length of the head. That part of the midpiece which does not possess mitochondria is seen as a paler staining area immediately below the base of the head. Where the mitochondria end distally, the principal piece of the tail continues as a thinner green axoneme (LM Plate 1 a).

Under the electron microscope, the nucleus of the mature dog spermatozoon stains very deeply with uranyl acetate and lead citrate and appears dense and homogeneous (EM Plate 1 A; B).

The acrosome of dog sperm is a cap-like structure covering slightly more than the anterior half of the head (EM Plate 1 A; B). A very slight apical thickening is sometimes noted on

sagittal section. The remainder of the anterior segment of the acrosome is of uniform thickness. The equatorial segment, which is thinner, has the shape of an ellipse. The elliptical shape of the equatorial region is most easily seen when viewed under the light microscope (LM Plate 1 a). The equatorial region of the acrosome may comprise up to 18 percent of the total length of the head.

Between the acrosome and the nucleus at the anterior margin of the head is the area that corresponds to the perforatorium described in rat sperm (Fawcett, 1975). This region is much smaller in the dog, and the opaque material contained in it is restricted to the anterior margin of the acrosome. As no evidence exists that this subacrosomal substance performs any perforating function in the dog, the use of the term perforatorium is avoided here.

Below the acrosome, the post acrosomal sheath covers the remainder of the head.

The principal component of the neck is the connecting piece, which is a complex of cross-striated columns that terminate anteriorly in a dense, articular structure joined to the basal plate. The latter lines the implantation fossa of the nucleus. The implantation fossa is not bilaterally symmetrical, due to the position of the proximal centriole. Lodged in the interior of the connecting piece is the

proximal centriole, whose long axis is aligned with the flattened plane of the head, and approximately perpendicular to the axis of the flagellum. This centriole has a structure that does not differ from centrioles in other mammalian cells (EM Plate 1 B). A distal centriole is not seen in mature dog sperm.

The mitochondria are helically arranged (EM Plate 1 C); distally the mitochondria end at the annulus, which is composed of circumferentially orientated finely fibrillar material.

The flagellum possesses the same basic pattern of microtubules and matrix components that have been observed throughout most of the animal kingdom; nine evenly spaced pairs of microtubules around a central pair of single microtubules (EM Plate 1 C; D). The doublets consist of a complete microtubule seen as circular in cross section (known as subfibre A), and a fibre which is C-shaped in cross section (known as subfibre B), the latter attached at its edges to a portion of the wall of subfibre A. Radial spokes extend from the central pair of tubules to subfibre A of each doublet. The nine doublets are connected to one another by nexin links. Two diverging dynein arms extend

from each subfibre A toward the next doublet. Surrounding the doublets are nine coarse fibres, which fuse distally to form the fibrous sheath.

The cell membrane of the mature spermatozoon has the usual trilaminar unit membrane structure throughout.

## **4.2. Acrosome abnormalities**

### **4.2.1. Major acrosomal abnormalities**

Major acrosomal abnormalities occur in the form of acrosomal lipping, ridging, cysts, and an irregular distribution of acrosomal material.

Acrosomal lipping is seen under the light microscope as a distinct increase in acrosomal density, and typically occurs apically. The acrosome folds back on itself, resulting in extra acrosomal material in the region of the lip (LM Plate 1 d). Under the electron microscope, the folding back of the acrosome is clearly visible. A common feature of lipped acrosomes is the occurrence of a raised plasma membrane adjacent to the lip (EM Plates 2 A - D). Variations in the length of the lip occur, and various cytoplasmic components may be found beneath the lip. Sometimes the lipping is so severe as to include all the non-equatorial part of the acrosome (EM Plate 2 D). Where the lipping is narrow and is

limited to the perimeter of the sperm, it is termed acrosomal ridging (LM Plate 2a; EM Plates 2C; 4C).

Most commonly acrosomal cysts occur apically, where they are sometimes referred to as "nipple acrosomes". They are usually filled with cytoplasmic material (LM Plate 1 e; EM Plates 3 A,B). The contents of the cyst is granular or vesicular, and sometimes contains acrosomal material (EM Plate 4 A). Under the light microscope, the cysts show varying degrees of staining with brilliant green, depending on the amount of acrosomal material present, and the degree to which the non-acrosomal material displaces the acrosomal material. Acrosomal cysts may be folded back on themselves, in which case they are termed lipped cysts (EM Plates 2 D; 3 C, D; 4 A, B). The cyst may displace nuclear material (EM Plate 3 B). Occasionally the cyst appears to be empty in that it contains no electron dense material (EM Plate 3 D).

An irregular distribution of acrosomal material is seen on using light microscopy as variations in the outline and/or staining density of the acrosome (LM Plates 1 f; 2 g). Under the electron microscope, the abnormal extent of the acrosome is readily observed (EM Plates 4 A - D). The equatorial region may be abnormal in size. An example of an abnormally large equatorial region is shown in LM Plates 2 d and e and EM Plate 4 C. The irregular distribution of the acrosomal material may occur over a small, well circumscribed part of

the acrosome, with the rest of the acrosome appearing normal (LM Plate 2 f). The equatorial region is sometimes not visible under the light microscope (LM Plate 2 f).

In addition to the above examples there is a wide range of other abnormalities, some bizarre, that may be observed in the acrosome. Some examples of these are shown in EM Plates 4 A - D. All of them, however, are various combinations of lips, cysts, and irregular distribution.

#### **4.2.2. Minor acrosomal abnormalities**

These are secondary acrosomal changes, and are known to arise after the sperm have left the testis (Blom, 1972; Bedford, 1970). They may be divided into damage to the acrosome (pathological) and the acrosome reaction (physiological). Since membrane detail is not visible under the light microscope, the two conditions were impossible to differentiate accurately, especially in cases of mild damage. However, where severe damage was sustained, it was possible to identify the defect as a pathological change.

##### **4.2.2.1. Acrosomal damage.**

In its early stages the damage is seen under the light microscope as a decrease in acrosomal staining; this indicates a loss of acrosomal contents. As the damage

progresses, the acrosome takes on a ruffled appearance; the acrosome then swells, and thereafter ruptures and the contents are lost. In the final stage there is a total loss of the acrosome, including the equatorial region (LM Plates 1 b, c; 3 a - f)

Under the electron microscope, the acrosome appears swollen and irregularly stained. The loss of acrosomal contents is seen as a loss of electron-dense acrosomal material from between the outer and inner acrosomal membranes. Damage to the acrosome may include the equatorial region.

#### **4.2.2.2. The acrosome reaction.**

This is a physiological change in the acrosome which leads eventually to loss of both the contents and the outer acrosomal membrane. It normally only occurs on contact with the zona pellucida. Occasionally a semen sample may contain sperm that have undergone the reaction precociously. The reaction can also be experimentally induced by exposing sperm to media containing a large amount of calcium or the Ionophore A23187 (Aitken et al., 1984). The reaction starts as a slight irregularity of staining of the acrosome (LM Plate 3 a). This extends, and the irregularity becomes obvious over most of the acrosome, but excludes the equatorial region.

Under the electron microscope, the first indication of the acrosome reaction is seen as a few areas of reduced electron density in the acrosome (EM Plate 5 A). There is vesiculation of the outer acrosomal membrane, with loss of acrosomal contents (EM Plate 5 B). These areas gradually extend, and portions of the reacting acrosome may be seen interspersed with swollen, non-vesiculated acrosomal material. The reaction does not affect the equatorial region at this stage (EM Plate 5 B). The process of vesiculation extends over the whole of the non-equatorial region (EM Plate 5 C). Thereafter, the vesiculated acrosome detaches, and the plasma membrane fuses with the outer acrosomal membrane at the equatorial region, leaving an exposed inner acrosomal membrane attached to the nucleus (EM Plates 5 D, E). Finally, the equatorial region is also lost (EM Plate 5 F).

#### **4.3. Head abnormalities**

##### **4.3.1. Major head abnormalities**

###### **4.3.1.1. Macrocephalic.**

In this abnormality, the whole head is enlarged. The proportions of acrosome and nucleus may be normal (LM Plate 4 a) or abnormal (EM Plate 10 C). Macrocephalic sperm were often seen to possess double tails.

#### **4.3.1.2. Microcephalic.**

There is a reduction in head size. Under the light microscope it is usually accompanied by an increased intensity of pink staining of the nucleus (LM Plate 4 b), probably as a result of hypercondensation of the chromatin.

#### **4.3.1.3. Pyriform head.**

This abnormality is commonly known as "pear shaped head". There is a greater intensity of pink staining in the narrowed portion of the head, due to the increased nuclear condensation in this area (LM Plate 4 c; EM Plate 7 C).

#### **4.3.1.4. Diadem defect.**

The diadem, or crater defect, is the term given to single or multiple nuclear vacuoles which typically occur in the equatorial region of the head. Due to the depth of field of the light microscope being less than the depth of the sperm head, it is not possible to visualize the complete defect in one focal plane. For example, in one focal plane, the defect appears as a row of white dots, while on a lower focal plane, these dots appear black (LM Plates 4 d; e). The vacuoles may occur anywhere in the nucleus, but are most common in the equatorial region. Occasionally the vacuoles

coalesce to form a solid band across the sperm head (LM Plate 4 f). Under the electron microscope, the defect is characterized by pouch-like invaginations into the nucleus, generally connected to the sub-acrosomal region by means of a small stalk or pedicle. The latter may or may not be visible, depending on the plane of sectioning. The vacuoles are lined by nuclear membrane and may appear empty or be filled with various cytoplasmic constituents including membranous, granular or vesicular material (EM Plate 7). An abnormal accumulation of cytoplasmic material is commonly found between the equatorial region and the nucleus (EM Plate 7 B).

Large nuclear vacuoles, not associated with the diadem defect, were noted occasionally. They were always associated with another abnormality, usually acrosome cysts or bizarre ridged sperm (EM Plate 8).

#### **4.3.1.5. Ridged sperm.**

These sperm are usually binucleate (see Bertschinger, 1975), the "extra" nucleus which forms the ridge being positioned at right angles to the other nucleus. Varying degrees of this abnormality occur, depending on the orientation and the degree of separation of the two nuclei. The ridge may be partial or complete, and aligned laterally, centrally or horizontally. Photographic reproduction of this defect

encounters similar problems to that of the diadem defect, and so it is difficult to get both head and ridge in focus. (LM Plates 5 a - d; EM Plates 9 A - C)

#### **4.3.1.6. Double forms.**

In this abnormality the separation of the spermatids is incomplete. Double heads were always seen to possess double tails, although the reverse did not hold true. The degree of separation of the two components varied, from almost none to complete separation of the heads and the midpieces, with only the tails still joined. The sperm usually shared a common plasma membrane over the area of fusion, and could thus be differentiated under the electron microscope from cases of sperm agglutination (EM Plates 10 E; 11 A, B; 20 A, B).

#### **4.3.1.7. Bizarre forms.**

Severe multiple head abnormalities that did not allow classification into any other category were classified as bizarre forms. A variety is shown in LM Plates 10 e - g and 11 a - f.

#### **4.3.2. Minor head abnormalities.**

##### **4.3.2.1. Narrow heads and small, normal heads.**

Narrow heads show a mild degree of uniform narrowing of the head, while showing normal staining characteristics (LM Plate 6 a). This defect is difficult to show on electron micrographs because variations in the orientation of the sections of the heads complicate comparative interpretation of the relative head size. Small, normal heads were occasionally encountered.

##### **4.3.2.2. Head-base defects.**

These included mildly narrowed head-bases, abaxial implantation of the midpiece, skew head-bases, broad and concave head-bases (LM Plates 6 b - f). Under the electron microscope, a range of abnormalities is noted, including curving of the base plate, small nuclear vacuoles beneath the base plate, and defective implantation of the midpiece (EM Plates 12 A - D; 13 A - D; 15 A).

##### **4.3.2.3. Detached heads.**

These were obvious under the light microscope. If the detached head was also abnormal, then it was classified under the appropriate major head defect.

#### **4.3.2.4. Nuclear decondensation.**

Nuclear decondensation was never noted in otherwise normal sperm, but was always associated with other abnormalities. It appeared as irregular areas of less electron dense nuclear material (EM Plate 11 C). Ageing and death of sperm were associated with nuclear degeneration, as may be seen in EM Plate 11 D.

#### **4.4. Midpiece abnormalities**

##### **4.4.1. Major midpiece abnormalities**

###### **4.4.1.1. Retention of cytoplasmic droplets**

This defect was usually associated with failure of sperm to mature fully, but was also associated with epididymal malfunction. Under the light microscope, a normal midpiece was usually discernable running through the droplet (LM Plate 7 e). Under the electron microscope, the droplet was seen to contain a variety of cytoplasmic components, commonly membranous and granular material (EM Plate 16 B). Sometimes the midpiece was also abnormal in such sperm (EM Plates 15 D; 16 C, D).

#### 4.4.1.2. Ruptured midpiece

In this defect there was mitochondrial damage and disorganization, as well as axonemal damage, which usually occurred with concomitant retention of cytoplasmic material (LM Plates 8 a, b; EM Plates 16 C, D). An abnormality that was only seen in one instance was an unwinding of one of the mitochondrial spirals (LM Plate 8 c).

#### 4.4.1.3. Pseudodroplet defect

The pseudodroplet defect is due to disruption of the mitochondrial helix. The mitochondria are aggregated proximally or proximally and distally, leaving part of the axoneme denuded (LM Plates 8 d, e). Under the light microscope the presence of a denuded axoneme differentiates this defect from that with retained cytoplasmic droplets. The defect is difficult to demonstrate in its entirety under the electron microscope. A section through the proximal part of a pseudodroplet is illustrated in EM Plate 17 A.

#### 4.4.1.4. Kinked midpiece

This defect was associated with infertility in a Maltese poodle. Various degrees of the kinking were found. Under the electron microscope, a relatively normal midpiece was seen distally, but proximally at the point of attachment to the

segmented columns there was rupture of fibres and kinking of the midpiece; the presence of loose disorientated fibrils was also noted (LM Plate 7 g; EM Plate 14 D).

#### **4.4.1.5. Other midpiece defects**

Occasionally other defects were identified under the electron microscope. Vacuoles in the segmented columns were either well demarcated within otherwise normal columns, or had poorly defined boundaries within abnormal columns (EM Plates 15 B, C). Aplasia of mitochondria in the neck region could be identified under both the light and electron microscopes. The defect appeared as excessively long segmented columns, without the surrounding mitochondria (LM Plate 8 f; EM Plate 15 D). Mitochondrial degeneration was seen in sperm presumed to be aged. The cristae were poorly defined and the core of the mitochondria appeared empty (EM Plates 17 B, C). Folding back of the midpiece upon itself within an intact plasma membrane, as shown in LM Plate 9 a and EM Plate 17 D, is most likely the mildest form of "Dag" defect that occurs (see section 3.5.1.1).

#### **4.4.2. Minor midpiece abnormalities**

##### **4.4.2.1. Proximal droplets**

For a description see section 3.4.1.1. Where the retained cytoplasmic droplets were caused by sperm immaturity from excessive sexual activity, the droplets were classified as minor defects. Differentiation between this minor defect and the major defect described in section 3.4.1.1, which appeared morphologically identical, was based on retesting the dog after a period of sexual rest. If the percentage of droplets was significantly reduced, the defect was classified as a minor defect.

##### **4.4.2.2. Distal droplets**

These have the same structure as the proximal droplets, but occur at the junction between the midpiece and the principle piece of the tail (LM Plate 7 f). These probably represent a milder degree of sperm immaturity, and were only occasionally noted.

#### **4.5. Tail abnormalities**

##### **4.5.1. Major tail abnormalities**

###### **4.5.1.1. The "Dag" defect**

The "Dag" defect is associated with various degrees of coiling of the tail within an intact plasma membrane. The coiling varies from quite loosely to extremely tightly coiled, the latter often virtually obliterating the head. The tail may or may not be coiled around the head (LM Plates 9 a - f; 10 a - c). Under the electron microscope, a variety of longitudinal and transverse sections of the tail are seen. Abnormal axonemes are typical of the defect; they are recognized by the loss of fibrils from the axoneme and the occurrence of loose fibrils within the cytoplasmic material (EM Plates 18 A - D).

###### **4.5.1.2. Double tails**

Double tails were seen on sperm with normal and abnormal heads, the abnormal heads usually being macrocephalic or ridged. Sometimes double-tailed sperm shared common central mitochondria (LM Plate 11 D; EM Plates 10 C, D; 11 A, B); two base plates were always associated with the defect. The section through the multiple tails shown in EM Plate 11 B is most likely that of spermatids showing incomplete

separation. This is not a section through an example of the "Dag" defect, where the tail is coiled a number of times within a single plasma membrane, because the sections of the tail would then be at different angles and of different sizes depending on the plane and position of section. In this instance the tail sections are very uniform and are taken transversely from approximately the same level in the tail.

#### **4.5.2. Minor tail abnormalities**

##### **4.5.2.1. Simple coiling of the tail.**

This sperm defect, shown in LM Plate 10 d, was experimentally induced by incubating sperm for 24 hours in canine capacitation medium (Mahi & Yanagimachi, 1978). This defect was differentiated from the "Dag" defect, by the loose coiling and movement of the tail that could be observed in the wet preparation. Under the electron microscope, the tail coils were not contained within a common plasma membrane, and the axonemes were normal. Terminal coiling of the tail was seen occasionally, usually as an incidental finding (LM Plate 12 a).

#### **4.6. Sperm agglutination**

This may occur as tail to tail, tail to head, or head to head agglutination. Under the light microscope it was differentiated from incomplete separation of spermatids by the large numbers of sperm involved and by the random alignment of the sperm. (LM Plates 13 a, c, 14; EM Plates 20 A, B). Under the electron microscope, the closely opposed plasma membranes were clearly visible.

#### **4.7. Foreign cells**

##### **4.7.1. Macrophages and phagocytosis of sperm.**

Both normal and abnormal sperm were seen to be phagocytosed by macrophages (EM Plates 20 C, D). The normal sperm that were phagocytosed usually had damaged acrosomes; it is not known whether this damage occurred before or after phagocytosis.

##### **4.7.2. Sperm precursors**

Sperm precursors did not stain differentially with Spermac stain. The intense green staining of the cytoplasm obscured nuclear detail, except in spermatids, where a degree of nuclear differentiation was obtained. In Diff-Quik<sup>R</sup> stained

samples however, cytological detail was sufficient to identify the cell stage seen.

#### **4.7.3. Leucocytes**

Leucocytes did not stain differentially with Spermac stain. In Diff-Quik<sup>R</sup>-stained preparations leucocytes could be differentiated from sperm precursors. Leucocytes were noted in cases of epididymitis, orchitis, and contamination of semen by preputial secretions. In cases of preputial contamination, the semen often contained a large number of epithelial cells as well. A preputial wash with physiological saline was performed prior to collecting semen the following day; in cases of preputial contamination a dramatic reduction in the number of contaminating cells was noted on the subsequent evaluation.

#### **4.7.4. Epithelial cells**

These were found in cases of contamination of the semen with preputial secretions. The same washing and repeat collections were performed in these instances as in 3.7.3., in order to obtain an uncontaminated sample for evaluation.

#### **4.8. Patient data**

The details of the dogs' histories, clinical and genital examinations are given in Appendix 3. The majority of cases were presented for routine genital evaluation, usually just prior to breeding naturally or being used for artificial insemination. Some of the dogs were presented with specific histories of infertility or subfertility. The spermograms and the pregnancy data are given in Appendix 4.

#### **4.9. Statistical evaluation**

##### **4.9.1. Significance of association between the percentage normal morphology and the pregnancy rate**

The Chi-squared values for those dogs which did or did not produce pups from semen which had equal or more versus less than 50, 55, 60, 65, or 70 percent normal sperm are shown in Table 4. Known cases of female infertility are also shown.

##### **4.9.2. Strength of association (Phi coefficients) of the Chi-squared values with fertility.**

The strength of association (Phi coefficients) of the Chi-squared values with the pregnancy rates are shown in Table 5.

#### 4.9.3. Division of the dogs into normal and sub-normal groups.

From the figures in Table 5, the dogs were divided into normal and sub-normal groups using the maximum  $\Psi$  figure as the lower limit of normality. This was 60 percent normal sperm, whether or not known cases of female infertility were included in the calculations.

Table 6 shows the means and standard deviations of the abnormalities in the two categories. The distributions of the abnormalities are skewed, and therefore prior to applying the t-test, the data were transformed logarithmically so as to obtain normal distributions, and the test statistics were calculated on these figures.

**Table 4.** Chi-squared values at various percentages of normal sperm. Cases of known female infertility are excluded in the first column, and the total of all cases is given in the second column.

**Chi-squared values**

<b>Percent normal sperm</b>	<b>Excluding infertile females (n=38)</b>	<b>Total (Incl. infertile females) (n=42)</b>
50	4.09	2.97
55	4.24	2.84
60	6.58	4.54
65	4.11	2.29
70	6.27	3.36

**Table 5. Strength of association (Phi coefficients) of the Chi-squared values for pregnancy at various percentages of normal sperm. Those cases where a female factor was identified as the cause of the infertility were not included in the lower tier figures. All cases were included in the upper tier figures.**

	50	55	60	65	70
$\Phi$ (total, n=42)	0.266	0.260	0.329*	0.234	0.283
$\Phi$ (excluding infertile females, n=38)	0.328*	0.334*	0.416*	0.329*	0.406*

\*  $p < 0.05$

**Table 6. Spermograms of "normal" and "sub-normal" dogs.**

The mean and standard deviation for motility, sperm morphology, age of dog, and fertility are given. Azoospermic specimens were not included. The fertility data exclude the cases where the female was known to be infertile. Four of the 71 ejaculates examined morphologically were excluded from the statistical evaluation due to incomplete data (see Appendix 4).

	Normal		Sub-normal	
	n=45		n=22	
	mean	S.D.	mean	S.D.
Progressive motility (%)	75.6	15.2	57.2	24.3*
Sperm morphology (%)				
Normal	79.3	11.4	33.4	21.0***
Head abnormalities	4.6	5.1	22.2	23.0***
Acrosome abnormalities	3.2	5.9	3.6	5.2
Tail abnormalities	4.1	4.3	12.6	14.2*
Proximal protoplasmic droplets	3.6	5.4	16.2	22.0**
Abaxial attachment	1.6	3.0	4.3	7.4*
Separated heads	2.7	3.5	4.9	6.0
Midpiece abnormalities	1.2	2.1	3.1	3.6*
Age (years)	4.65	2.53	4.85	2.61
Fertility (%)	60.87	(n=23)	13.33	(n=15)

\*\*\* p<0.001    \*\* p<0.01    \* p<0.05

### THE LIGHT MICROGRAPHS

The EM Plate numbers in parentheses after the LM Plate descriptions refer to the corresponding EM Plate depicting the ultrastructure of the defect. Likewise in the electron micrograph section that follows, the corresponding LM Plates are given in parentheses after the EM description. Both the light and electron micrograph series of plates appeared in Oettle & Soley, 1988.

**Plate 1. Normal dog sperm, acrosomal loss, major acrosomal abnormalities**

(a) Normal dog sperm. Note colour and intensity of staining of the acrosome (ac), equatorial region of the acrosome (eq), and post acrosomal region of the head (p). The midpiece (m,m) connects to the base of the head at the neck (n). The latter does not possess mitochondria, and may be seen under the light microscope as a paler staining area immediately below the head-base. Where the mitochondria end distally, the principal piece of the tail (t) continues as a thinner green axoneme. (EM Plate 1 A,B)

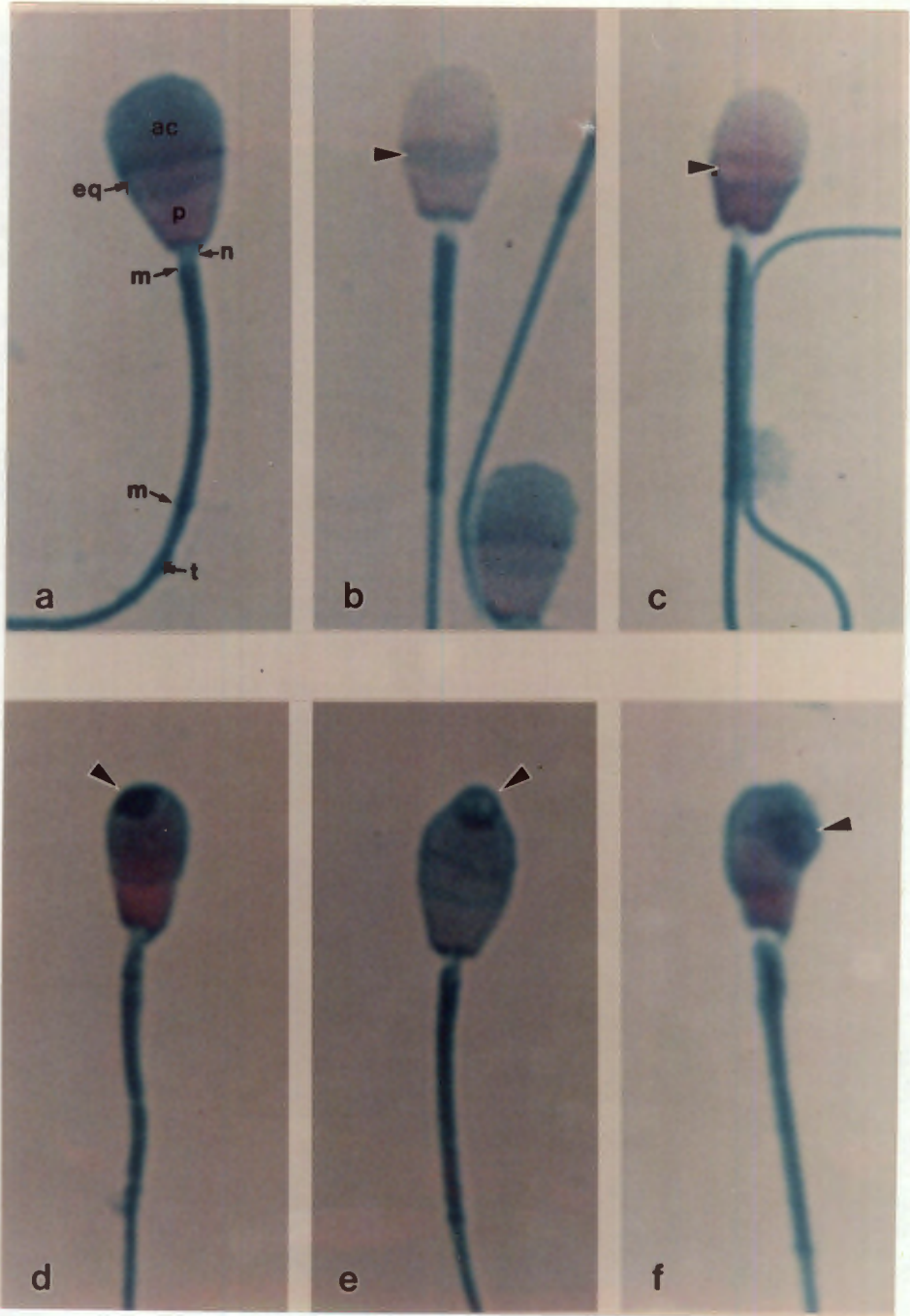
(b) Acrosome loss, not involving the equatorial region. Note pale pink staining of the area which used to be covered by the acrosome, while the equatorial region (arrow head) still stains green. (EM Plate 5 E)

(c) Acrosome loss, including the equatorial region. Note that the equatorial region also stains pink in this micrograph. The green outline is possibly acrosomal remnants attached to the remains of the acrosomal membranes. (EM Plate 5 F)

(d) Acrosome lipping. The acrosome has folded back on itself, resulting in extra acrosomal material in the region of the lip (arrow head). The head is also narrow. (EM Plates 2 A-D)

(e) Acrosome cyst, apical and partially filled with acrosomal material. Note the round appearance of the cyst, and more intense staining circumferentially. (EM Plates 3 A,B).

(f) Irregular acrosome. Under the light microscope the fine structure is not discernable, but it is probably similar to EM Plate 4 A.



**Plate 2. Major acrosomal abnormalities, cont.**

(a) Ridged acrosome. Note thickenings at the edges of the acrosome (arrow heads). This abnormality is a variation of the simple lipping, shown in LM Plate 1 d, and is also caused by folding over of excess acrosome onto itself. (EM Plates 2 C, 4 C)

(b) Loose head, with acrosome cyst in equatorial region. (EM Plate 4 D)

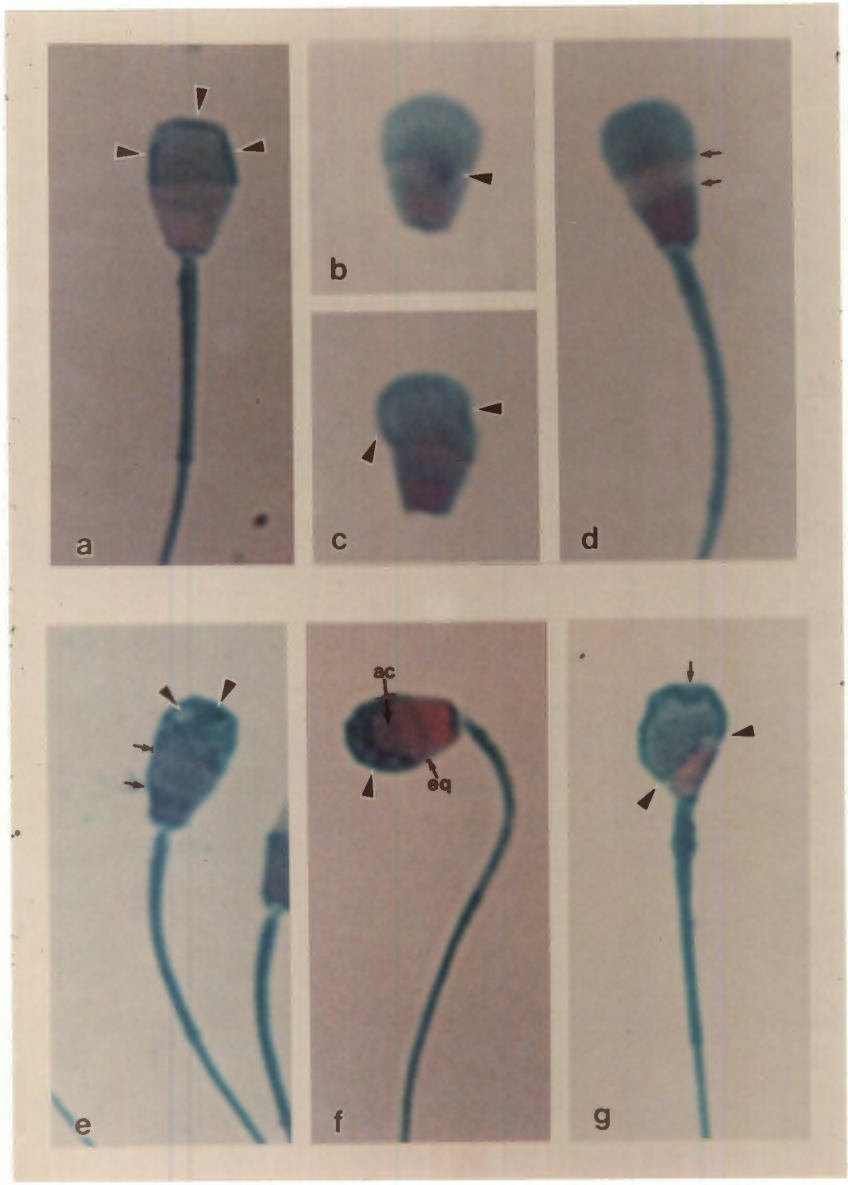
(c) Loose head, with acrosome irregularly situated on the head. It seems as if the acrosome has been pulled to the left (arrow heads).

(d) Abnormally large equatorial region. Compare the extent of the equatorial region (arrows) with that on LM Plate 1 (a). (EM Plate 4 C)

(e) Abnormally large equatorial region. This is a more severe example than that in the previous figure. The extent of the equatorial region is shown with the arrows. Note also the irregular distribution of the acrosomal contents (arrow heads), which is probably a secondary change (Compare with LM Plate 3 (b)).

(f) Irregular distribution of the acrosome, with normal equatorial region (eq) and a portion of normal acrosome (ac-arrow). The irregular portion (arrow head) is probably a severe form of lipped cysts.

(g) Irregular acrosome. Note the extent of the acrosome on either side (arrow heads), the lack of a distinct equatorial region, and ridging (arrow). (EM Plate 7 A).



**Plate 3 Minor acrosomal abnormalities**

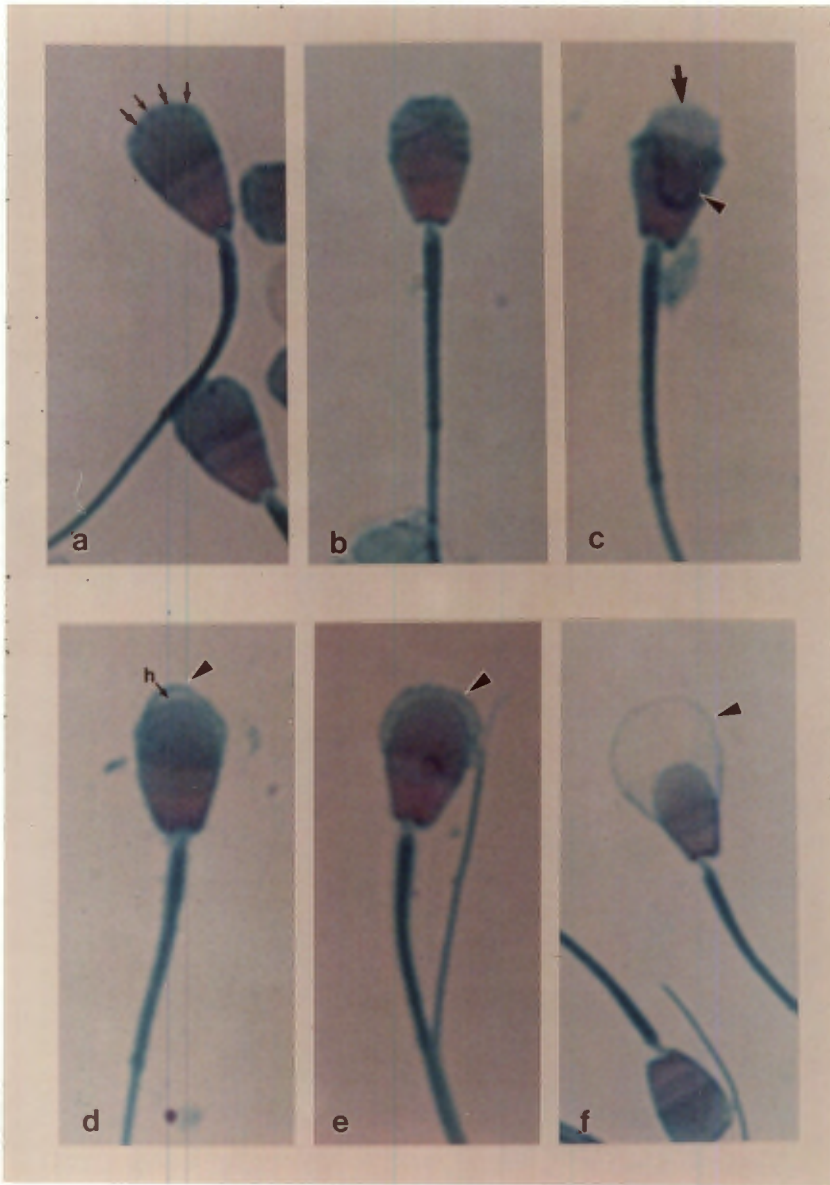
(a) Start of the acrosome reaction. At this stage, all that is visible under the light microscope is irregular staining of the acrosome (arrows). (EM Plate 5 A). This extends, as may be seen in (b), where the irregular staining is obvious over the acrosome excluding the equatorial region. Compare with the EM Plate 5 B, where the vesiculation causing this irregular staining is clearly seen.

(c) Rupture of the acrosome. The damaged acrosome may be seen torn off and folded back onto the head (arrow head), leaving the denuded head apically (arrow).

(d) Acrosomal swelling. Note the outline of the head (h) and the swollen acrosome with decreased staining intensity (arrow head), indicating loss of acrosomal contents. (EM Plate 6 A)

(e) Moderately severe acrosomal swelling (arrow head). More acrosomal contents have been lost than in LM Plate 3 d, with consequent further loss of staining affinity. (EM Plate 6 B)

(f) Severe acrosomal swelling. The ballooned membrane (arrow head) is clearly visible as a pale halo around the head. There is almost no green staining in the acrosome, indicating that most of the acrosomal contents have been lost. (EM Plate 6 C)



**Plate 4. Major head abnormalities**

(a) Macrocephalic. The large head with the coiled tail may be compared with the normal head alongside.

(b) Microcephalic. This small head also shows an abnormal acrosomal arrangement. Note the increased intensity of the pink staining at the head-base (arrow head), possibly due to the condensation of chromosomal material.

(c) Pyriform head. The severely narrowed head-base typical of these pear shaped sperm heads is clearly visible (arrow head). There is also a greater intensity of pink staining, but not to the degree seen in microcephalic heads. This is a fairly constant finding for pyriform heads, and is immediately seen by comparison with normal sperm. (EM Plate 7 C)

(d) Diadem defect. This is also known as the crater defect, and is caused by nuclear vacuoles (arrows). Due to the limited depth of field of the light microscope, it is not possible to show the complete defect in one picture. In one focal plane, the defect appears as a row of light dots, at a lower focal plane, these dots become dark, as may be seen in (e). The vacuoles may be single or multiple, and may occur anywhere in the nucleus, (EM Plate 7) but are most common in the equatorial region.

(e) Vacuoles (arrows) at a lower focal plane (compare with LM Plate 4 d).

(f) Severe form of the diadem defect. The vacuoles have coalesced and appear as a solid band (arrow head).

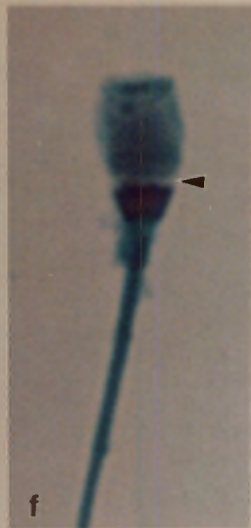
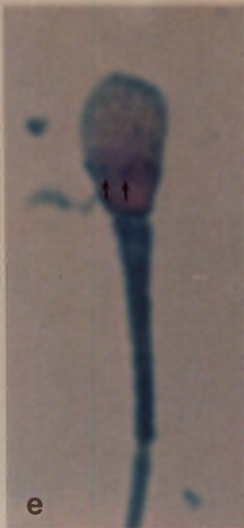
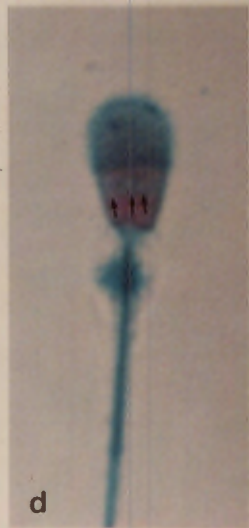

Plate 5. Major head abnormalities, cont.

(a) Ridged sperm. These are usually diploid sperm and the "extra" nucleus is positioned at right angles to the other nucleus (arrow head). Varying degrees of this abnormality occur: the ridge may be partial or complete, and aligned laterally, centrally or horizontally. This sperm shows a lateral ridge. Photographic reproduction of this defect encounters similar problems to that seen with the diadem defect, and so it is difficult to get both head and ridge in focus at the same time. (EM Plates 9 A,B,C)

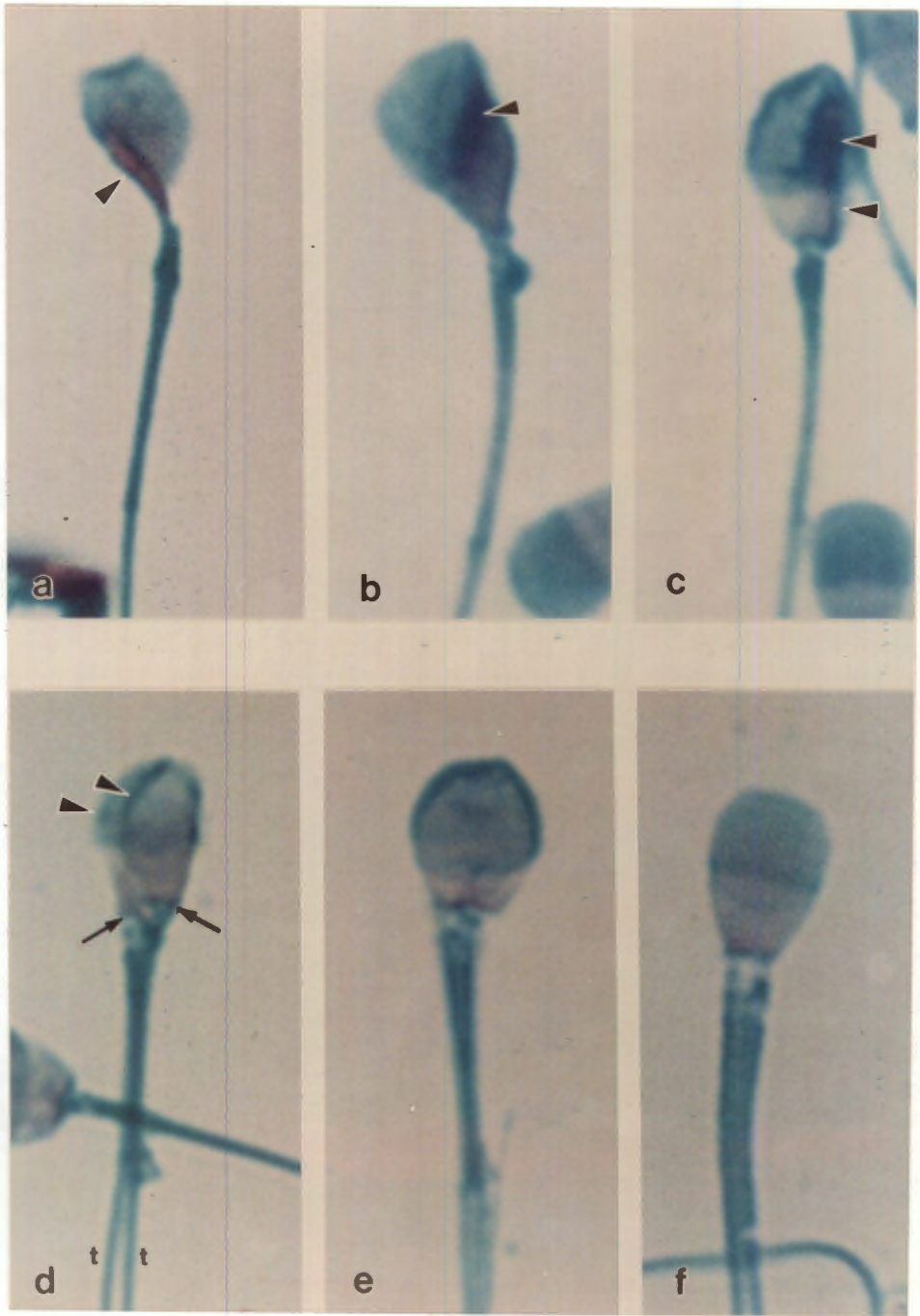
(b) Here the ridge is centrally situated and runs obliquely (arrow head).

(c) In this sperm the ridged portion is seen to run centrally and has an acrosomal region (upper arrow head) as well as a post acrosomal region (lower arrow head).

(d) Double head. Here the two nuclei (arrow heads) appear partially fused, giving the impression of a longitudinal ridge, but there are two midpieces, head-bases (arrows) and tails (t,t). (EM Plate 10 B)

(e) Macrocephalic, with a double midpiece and tail (EM Plate 10 C).

(f) Relatively normal heads with double tails were also encountered, as is shown in this Plate. (EM Plate 11 A)



**Plate 6. Minor head abnormalities**

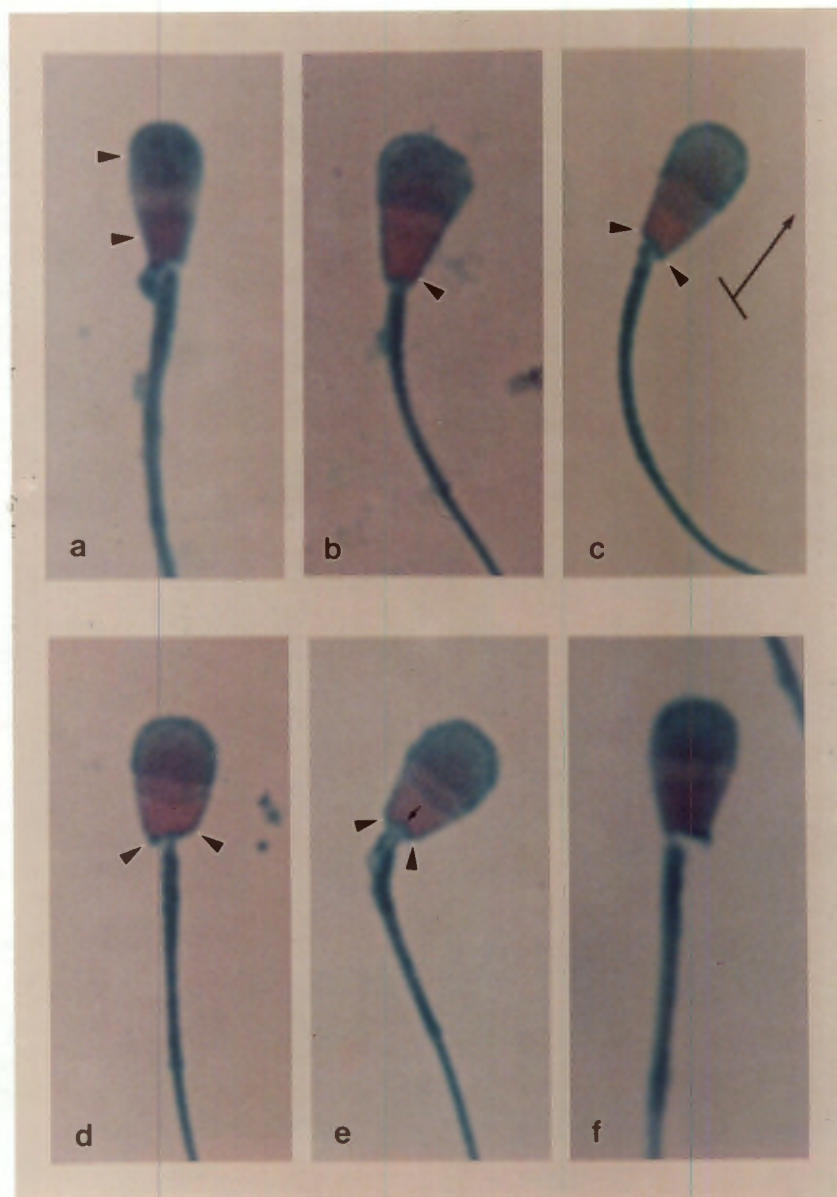
(a) Narrow head. Note that the narrowing affects both the acrosomal and post acrosomal regions (arrow heads), while in (b), Narrow based head, the head is narrowed at the base only (arrow head).

(c) Skew head-base. Note that the extremities of the head-base (arrow heads) do not make a right angle with the midpiece. These axes are reconstructed at the right of the sperm head. In addition to the skew head-base, the head-base is narrowed. (EM Plate 13 A)

(d) Skew head-base, of normal width (arrow heads). (EM Plate 13 B)

(e) Concave head-base. The implantation fossa (arrow) is more concave than in normal sperm, but the head-base is normal in width (arrow heads). (EM Plate 12 D)

(f) Abaxial implantation of the midpiece. The midpiece is attached to the left lateral portion of the head-base. (EM Plates 3 B, 13 B)



**Plate 7. Minor head abnormalities, midpiece abnormalities.**

(a) Broken neck, with the head folded back on itself.

(b, c, d) Loose heads, associated with a variety of defects. In (b) there is a diadem defect present (arrows), and the acrosome is missing (arrow head). In (c) there is a concave head-base (lower arrow head), and the acrosome is damaged but still present (upper arrow head). In (d), the upper sperm has a pyriform head (arrow head), the middle one a flattened acrosome (arrow head), and the lower shows a grossly distorted acrosome (upper arrow head), and the remnants of a tail (lower arrow head). The latter example is somewhat reminiscent of the stump-tailed defect in the bull.

(e) Proximal protoplasmic droplet (arrow head). (EM Plates 16 A, B)

(f) Distal protoplasmic droplet (arrow head).

(g) Kinked neck (arrow head). This defect was associated with infertility in a Maltese poodle; various degrees of kinking were found. (EM Plate 14 D).

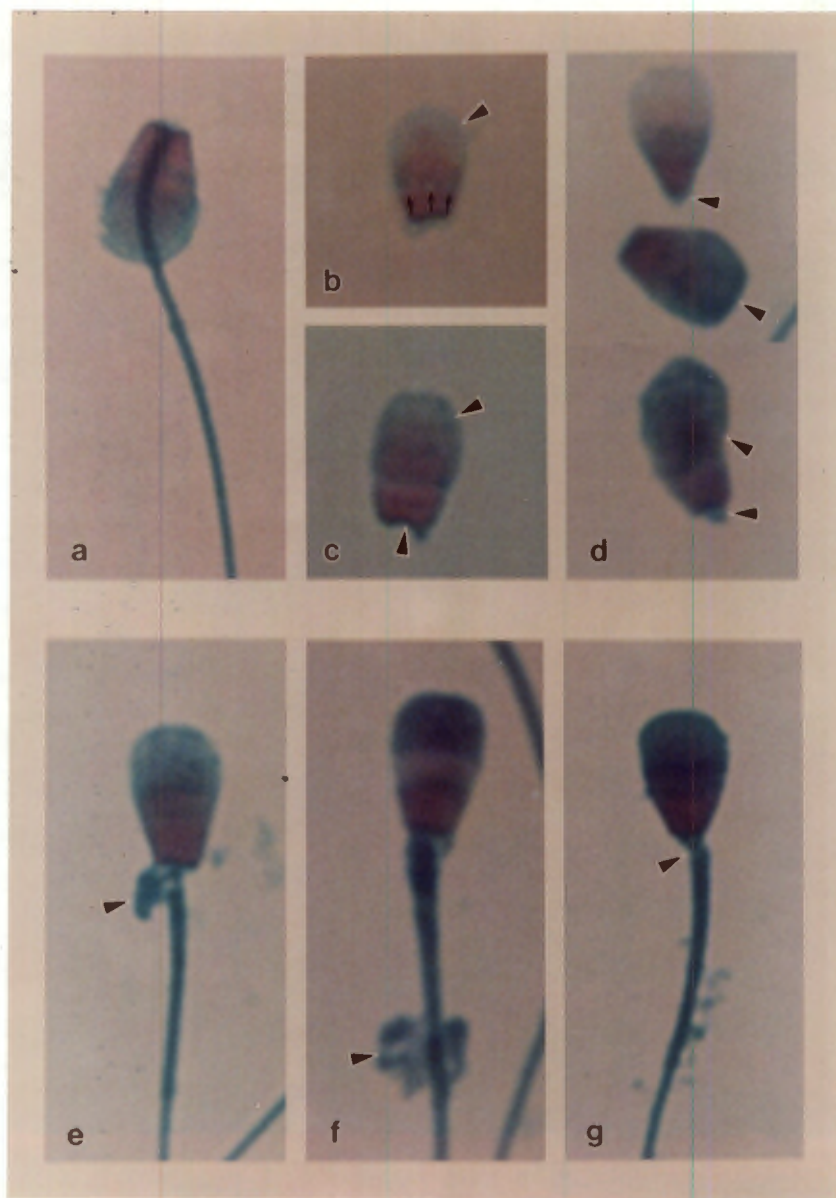


Plate 8. Midpiece abnormalities, cont.

(a) Swollen midpiece (arrow head). There is also abaxial implantation.

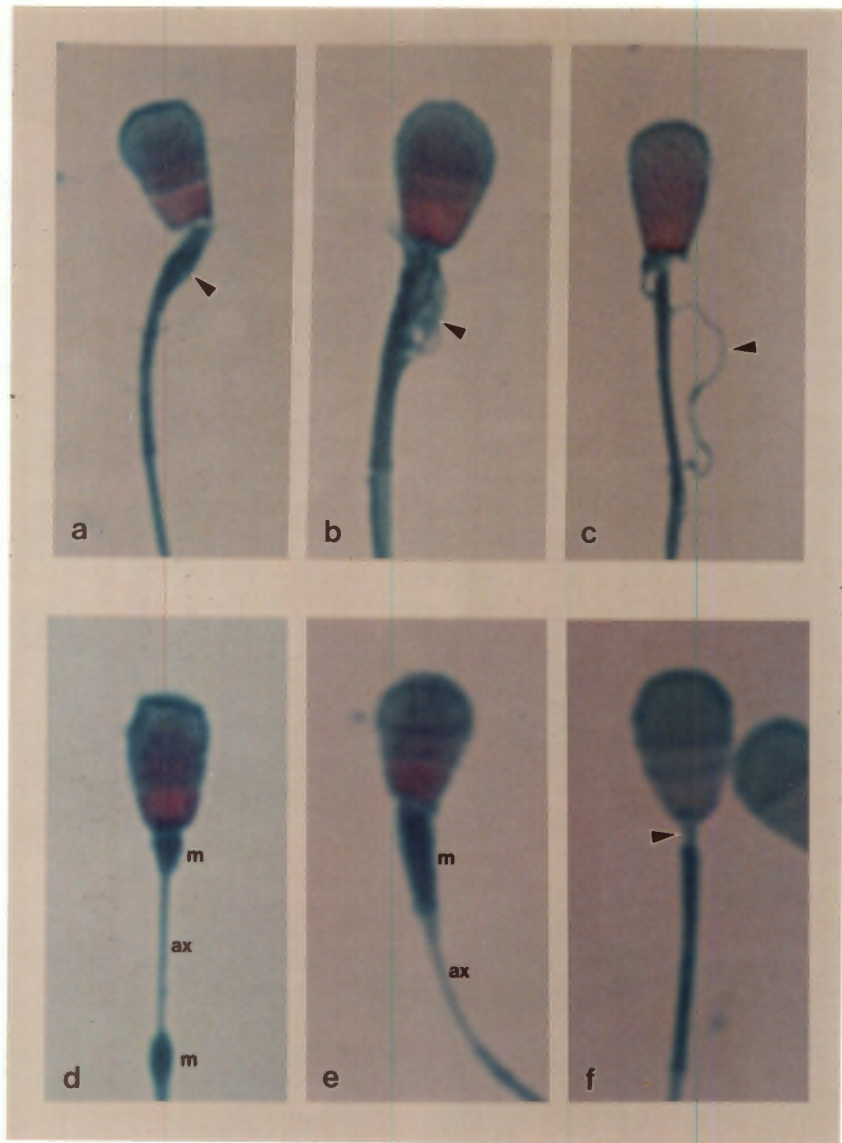
(b) Ruptured midpiece. Note that the rupture is located proximal (arrow head), and that the double midpiece seems relatively normal distally. This defect should not be confused with a protoplasmic droplet, where the normal midpiece can usually be distinguished running through the droplet (see LM Plate 7 e). (EM Plates 16 C, D)

(c) Ruptured midpiece. The arrow head shows what is most likely a mitochondrial spiral that has become unravelled (an axonemal fibre would be shorter and not tortuous).

(d) Pseudodroplet defect. Here the mitochondrial spiral has ruptured, and has been drawn proximally and distally into two pseudodroplets, each containing an aggregation of mitochondria (m,m); the denuded axoneme (ax) may be seen between the pseudodroplets. (EM Plate 17 A)

(e) Pseudodroplet defect (m, m, ax), where the mitochondria are confined to the proximal region only. (EM Plate 17 A)

(f) Dysplasia of the midpiece. Here the mitochondria are missing proximally, leaving a neck that is longer than normal (arrow head). (EM Plate 15 D)



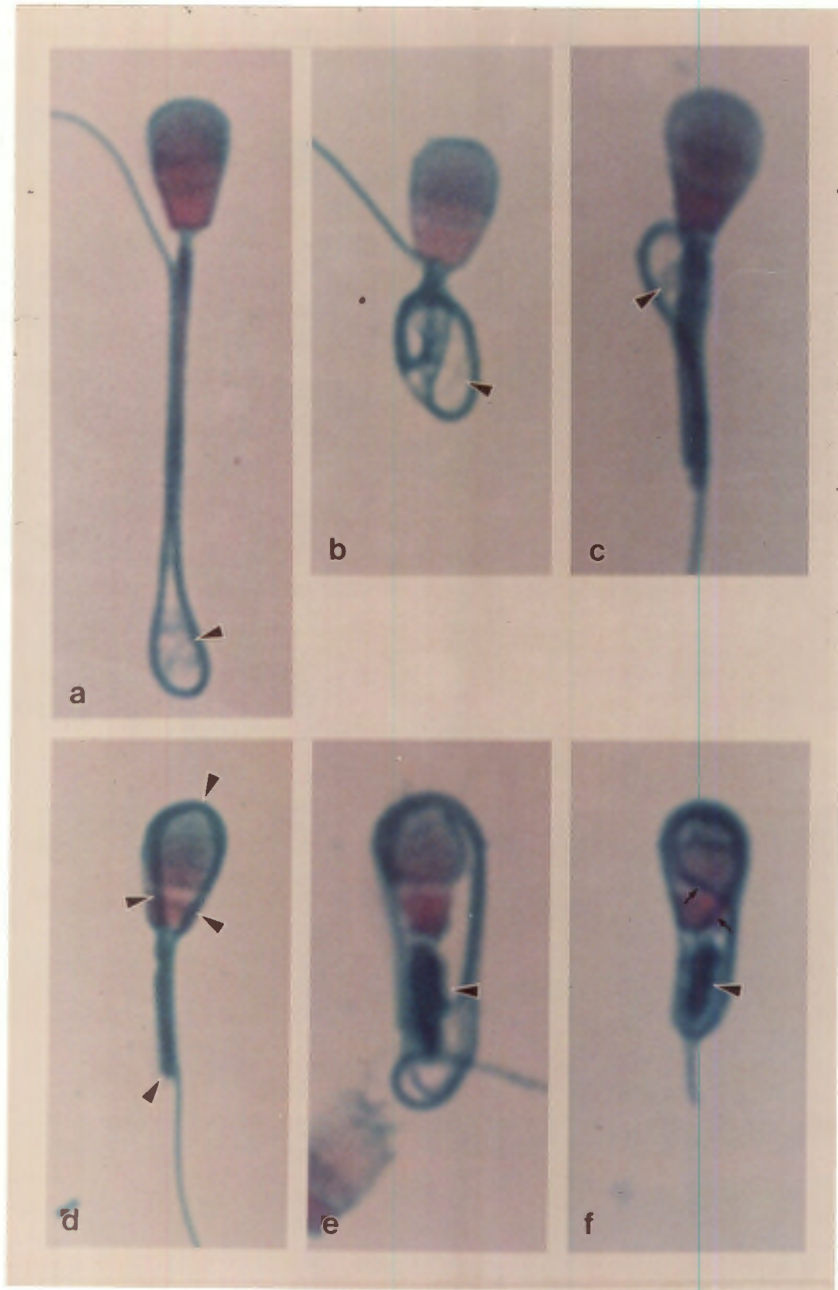
**Plate 9. Major tail abnormalities**

(a) Tail folded back on itself, around a distal droplet (arrow head). This may be the simplest form of the "Dag" defect, shown in (b) to (f). Note that the recurved portion of the tail is situated next to the midpiece.

(b,c,d,e,f) "Dag" defect of the tail. This defect is associated with various degrees of coiling of the tail within an intact plasma membrane. In (b), the tail is coiled fairly loosely, tighter in (c): the arrow heads show cytoplasmic material within the defect that appears fibrillar in b, and diffuse in c. In (d), the tail coils around the head (follow the coil around with the arrow heads). (EM Plate 18)

(e) The "Dag" defect may be associated with other defects, in this instance a thickened midpiece (arrow head) with an abnormal head-base and equatorial region. (EM Plate 19 A)

(f) Here the tail is very tightly coiled, and the coils of the tail may be followed over the head (arrows). There is also a damaged midpiece (arrow head).



**Plate 10. Major and minor tail abnormalities, multiple abnormalities**

(a) "Dag" defect. The tail is even more tightly coiled than in LM Plate 9 f.

(b, c) Total coiling of the tail. The head is only just visible beneath the coils (arrow heads). The head of the sperm shown in b is abnormal, as may be seen from the intense pink staining. This is probably due to hypercondensation of the chromatin in this microcephalic head. (EM Plate 18 D)

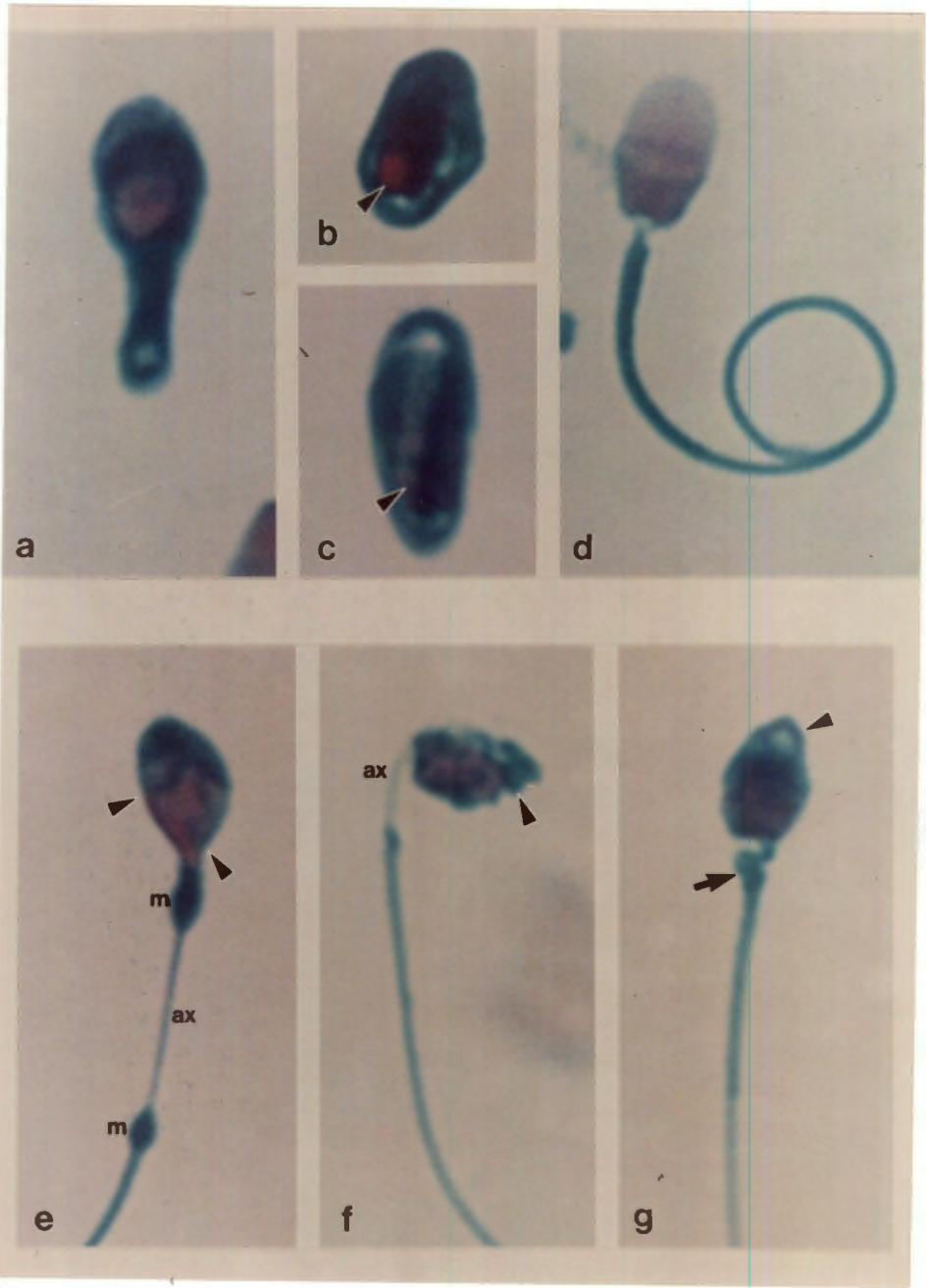
(d) Simple coiling of the tail. This is not an example of the "Dag" defect, but was environmentally induced, by incubating the sperm for 24 hours in canine capacitation medium.

**Multiple abnormalities**

(e) Note the irregular distribution of the acrosome (arrow heads), that extends on the right side into the pyriform head-base. There is also a pseudodroplet defect, as seen by the proximal and distal accumulations of mitochondria (m,m) and the denuded axoneme (ax).

(f) This sperm is microcephalic; it exhibits degeneration of the acrosome (arrow head), a denuded axoneme (ax), a midpiece that appears too short and a broken neck.

(g) This sperm is microcephalic with an abnormal acrosome (arrow head), a swollen midpiece (arrow) and abaxial attachment of the midpiece.



**Plate 11. Multiple abnormalities cont.**

(a) Double head, with common acrosome (bold arrow) visible as a rift between the two nuclei (the right nucleus is shown with the long fine arrow). The midpiece is attached to the left nucleus (arrow head).

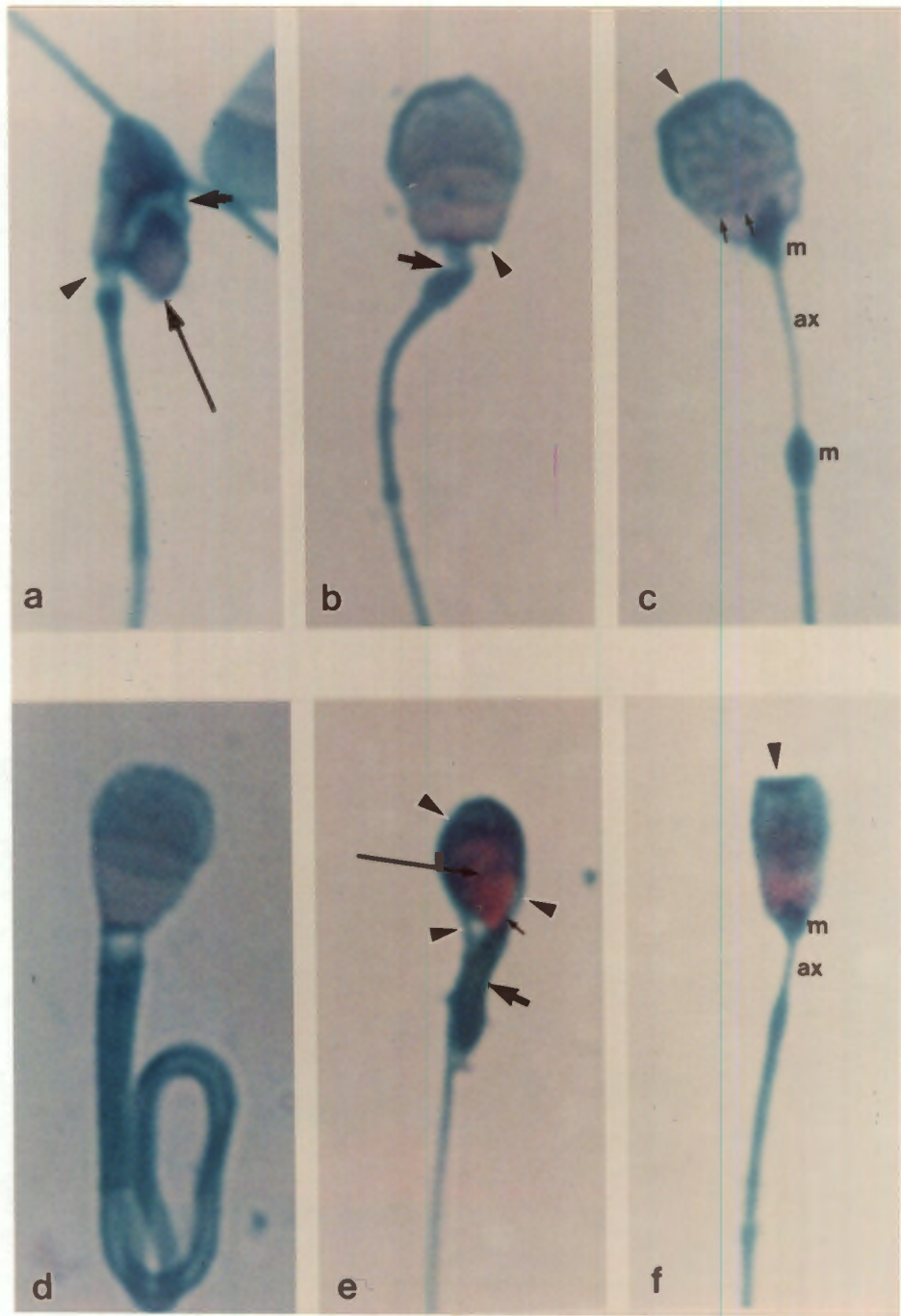
(b) Macrocephalic, broad head-base (arrow head) and swollen, kinked midpiece (bold arrow).

(c) Macrocephalic, with acrosomal ridging (arrow head), diadem defect (fine arrows), and pseudodroplet defect (m, m, ax).

(d) Double tail: both tails are coiled in the "Dag" defect.

(e) Microcephalic sperm (note intense pink staining of the nucleus), abnormal acrosome (long arrow), "Dag" defect (the coils of which may be followed with the arrow heads), pyriform head-base (fine arrow) and thickened short midpiece (bold arrow).

(f) Microcephalic sperm, lipped acrosome (arrow head) and a mild form of pseudodroplet defect (m, ax).

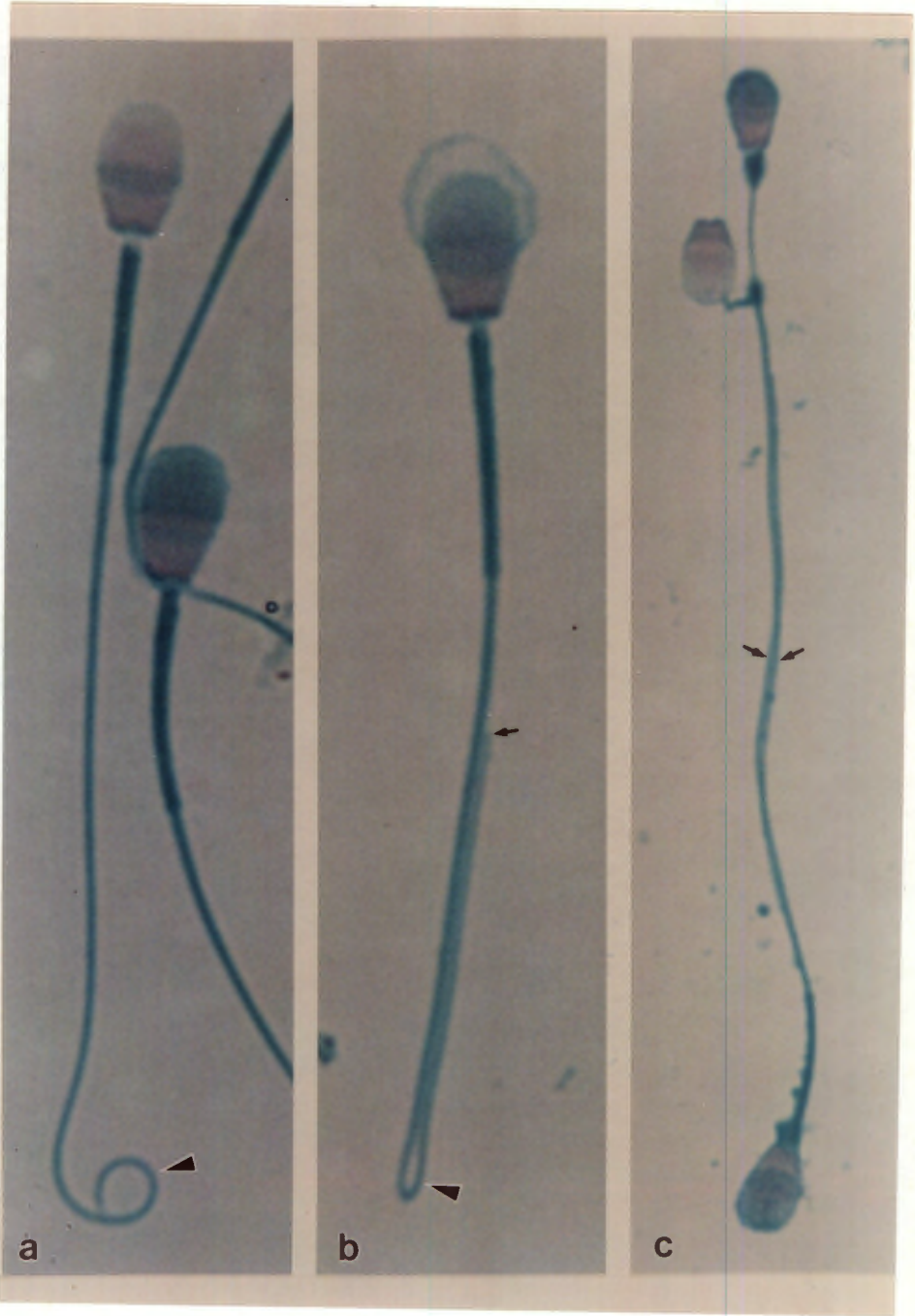


**Plate 12. Minor tail abnormalities, cont.**

(a) Terminal coiling of the tail (arrow head). This is a minor defect, and should not be confused with the "Dag" defect.

(b) Folding back of the tail onto itself (arrow head), possibly associated with rupture of fibrils. The tail may be followed to its end (arrow).

(c) Tail to tail agglutination. The tails (arrows) are in close apposition for their whole length. The upper sperm also has a pseudodroplet defect. The adjacent sperm head has lost its tail, and shows secondary acrosomal loss.



**Plate 13. Other abnormalities**

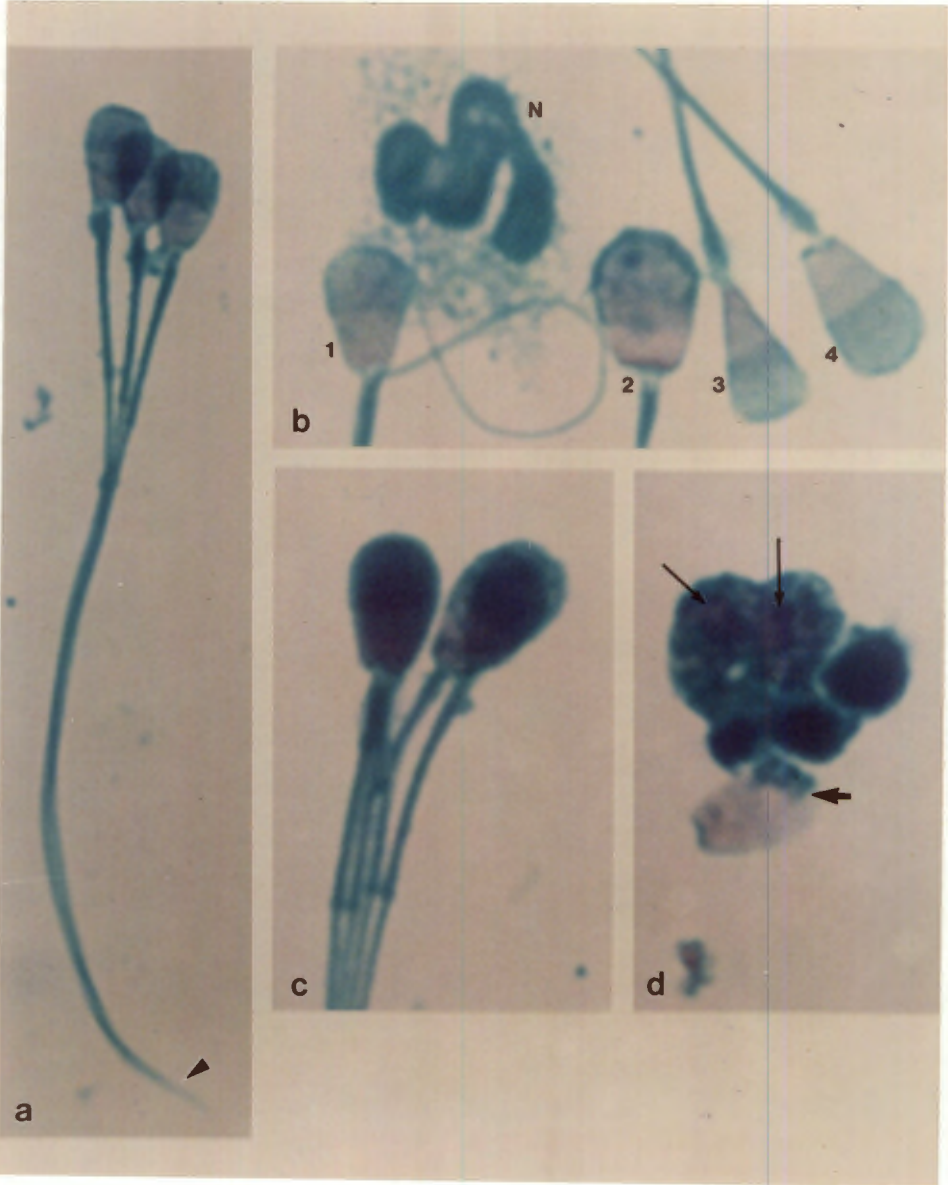
(a) Three headed sperm. This is unlikely to be agglutination, as the sperm heads are aligned, and the fusion of the tails continues to the end (arrow head).

(b) Various abnormalities.

1. Skew head-base
  2. Broad head-base
  3. Narrow head-base, with a small retained proximal protoplasmic droplet
  4. Proximal protoplasmic droplet on a slightly elongated head
- N. Neutrophil

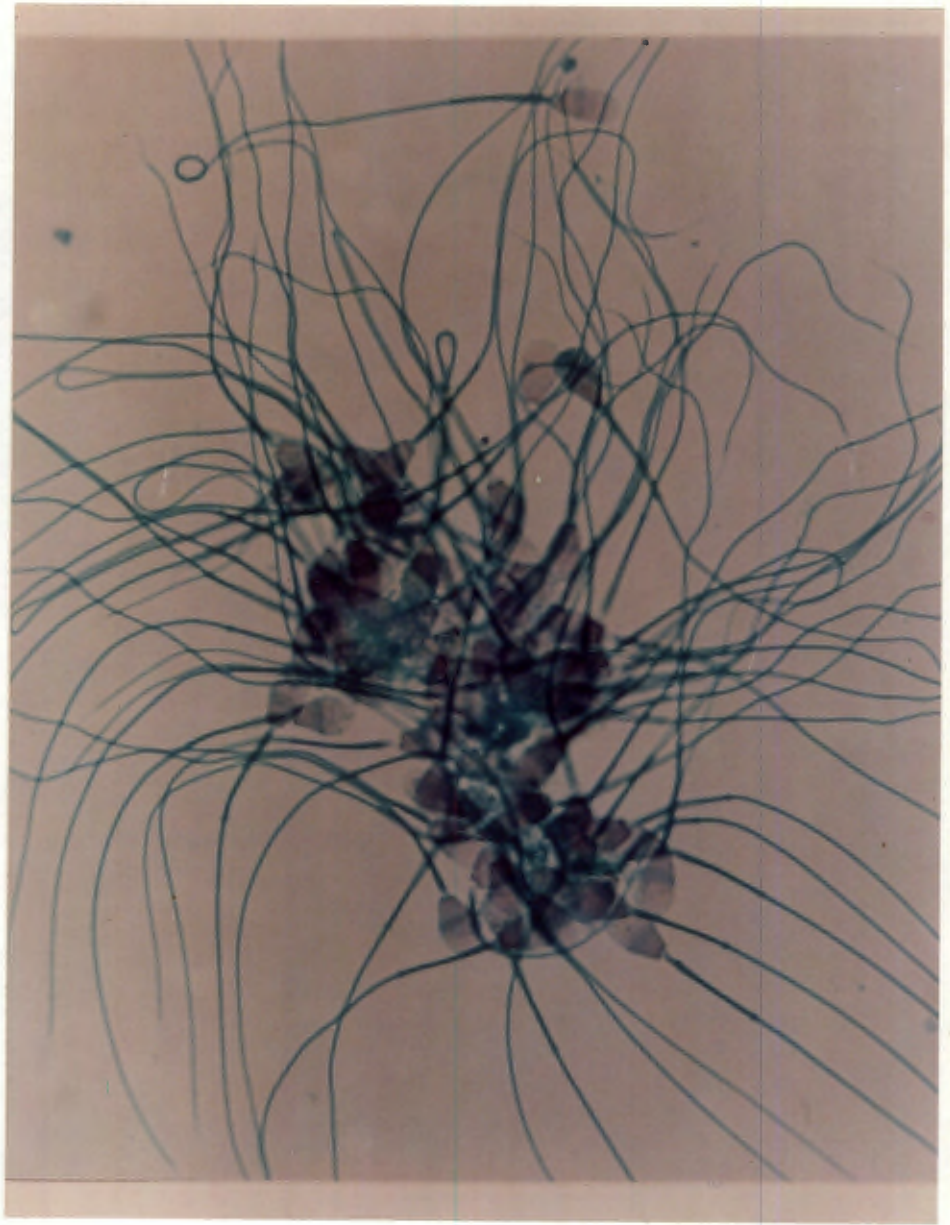
(c) Multiple sperm. This is unlikely to be due to agglutination, because of the ordered arrangement of the sperm. The ends of the four midpieces may be clearly seen.

(d) Phagocytosis of sperm. Two sperm nuclei (fine arrows) may be distinguished within the macrophage, while a third (bold arrow) is about to be phagocytosed. Note that the latter sperm is aged (loose head, no acrosome). (EM Plates 20 C, D).



**Plate 14. Sperm agglutination**

Sperm agglutination, head to head. Note that most of the sperm have secondary damage to their acrosomes.



**THE ELECTRON MICROGRAPHS****GENERAL LEGEND**

Nu - Nucleus

Ac - Acrosome

Eq - Equatorial region of the acrosome

oam - Outer acrosomal membrane

iam - Inner acrosomal membrane

pm - Plasma membrane

T - Tail

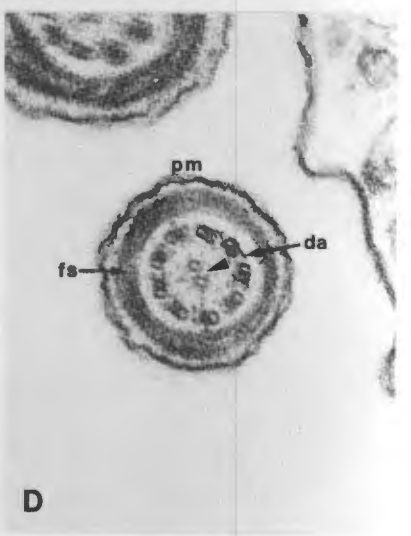
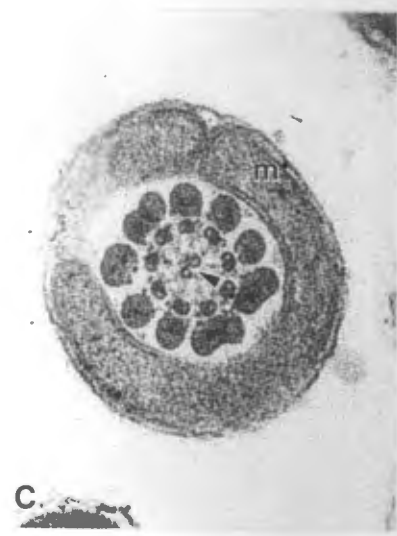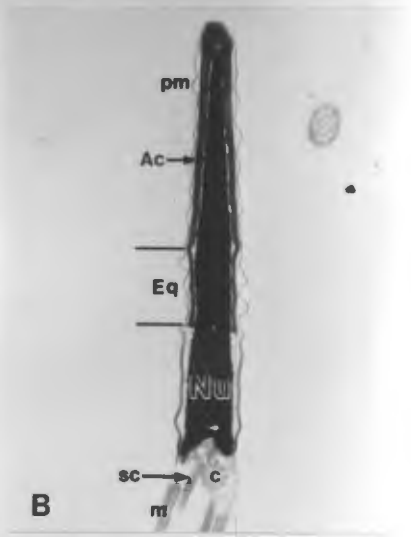
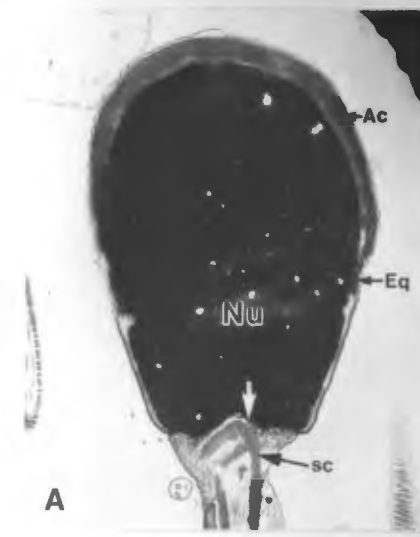
**Plate 1 - Normal dog sperm**

A. Planar section. The acrosome cap enclosing the apical portion of the nucleus may clearly be seen at the perimeter, but the thinning of the acrosome at the equatorial region is better seen in the following sagittal section (B). Note the base plate (white arrow) and the segmented columns (sc) of the midpiece. (14 400 X)

B. Sagittal section. Note the thinning of the acrosome at the equatorial region, the centriole (c), segmented columns (sc) and the mitochondria (m) of the midpiece. (15 800 X)

C. Transverse section through a midpiece. Note the spirally arranged mitochondria (m) surrounding the 9 coarse fibrils, the 9 fine fibrils, and the 2 central fibrils (arrow head) of the axoneme. (42 500 X)

D. Transverse section through a tail. Note that the coarse fibrils have coalesced into the fibrous sheath (fs). The dynein arms (da) may be seen on the 9 fine fibrils, and the central two fibrils are designated by the arrow head. (48 500X)



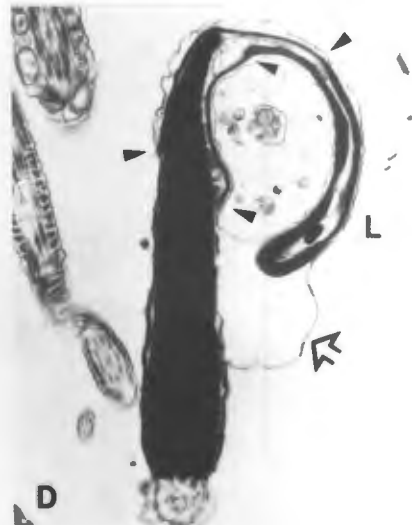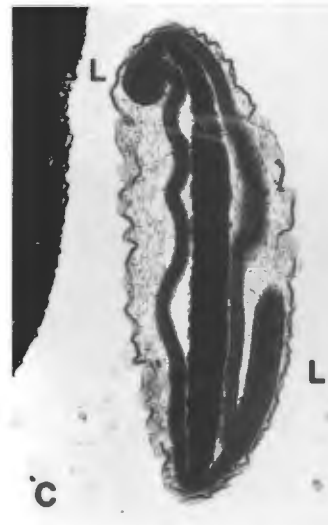
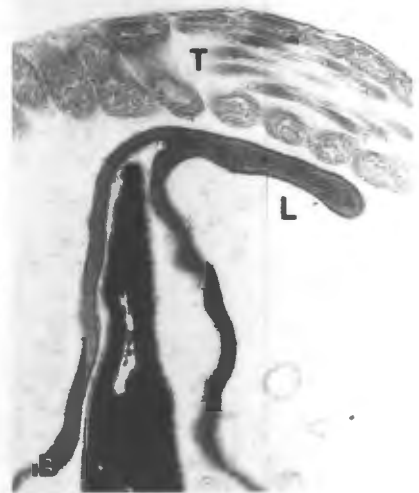
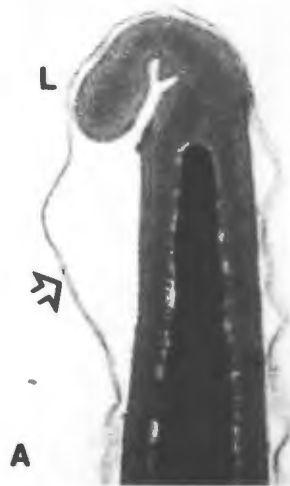
**Plate 2. Major acrosome abnormalities - lipping**

A. Acrosome lipping. The lipped dorsal extremity of the acrosome is designated by L. A common feature of lipped acrosomes is the occurrence of a lifted plasma membrane adjacent to the lip (arrow) (compare with LM Plate 1 d). (36 500 X)

B. More severe lipping. Here the lip (L) is longer and thinner, and there is also a "Dag" defect present, as shown by the longitudinal section profiles through the tail (T) in the same field. (25 000 X)

C. Bilateral lipping. This is a transverse section through the head. Note that the acrosome completely surrounds the nucleus; the two lips (L, L) are thus lateral (compare with LM Plate 2 a). (22 000 X)

D. Very severe lipping. Here the lip (L) has incorporated all of the non-equatorial region of the acrosome, as well as part of the equatorial region of the acrosome. The equatorial region is abnormally long; its limits are shown by the four arrow heads, two on each side. The lip itself contains abnormal material between the two halves of the acrosome that comprise the lip; this is probably subacrosomal substance. The whole lip encloses a membranous type of cyst on the right of the head. Note that the plasma membrane is lifted (arrow). (18 000 X)



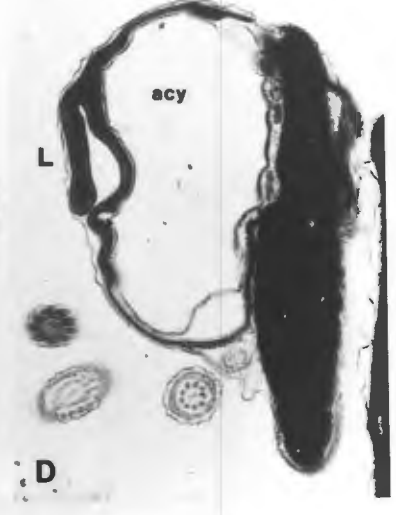
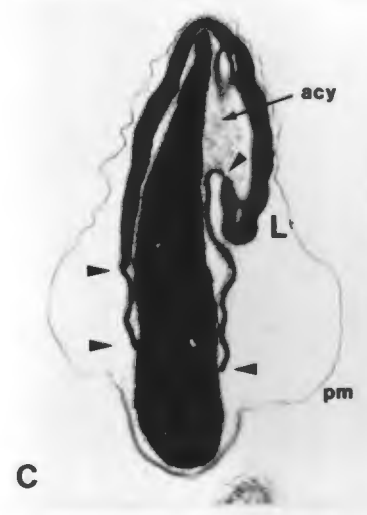
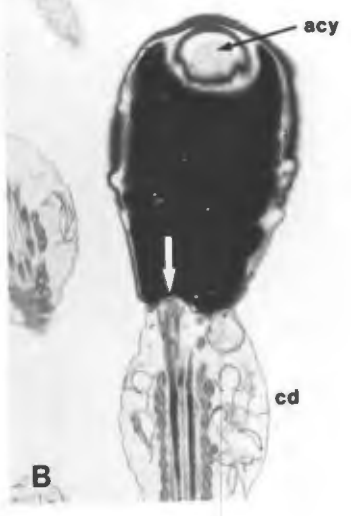
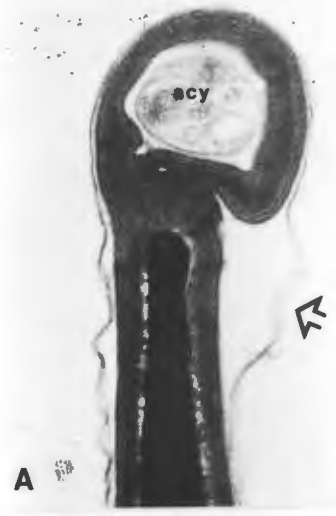
**Plate 3. Major acrosome abnormalities - cysts.**

A. Apical cyst. Here the cyst (acy) is granular in appearance, and the plasma membrane is lifted in the region where the cyst connects to the head (arrow). Under the light microscope, such cysts show varying degrees of green staining, depending on the amount of acrosomal material present, and the degree to which the non-acrosomal material displaces the acrosomal material (compare with LM Plate 1 e). (35 000 X)

B. Planar section through an apical cyst. Here the cyst (acy) has displaced part of the nuclear material. The contents are granular in appearance, and the perimeter of the cyst is comprised of acrosomal material which seems to be separated from the rest of the acrosome. There is also abaxial attachment of the midpiece (white arrow), and a proximal cytoplasmic droplet (cd). (11 000 X)

C. Bizarre acrosomal cyst (acy), which is also lipped (L), containing granular material. The equatorial region extends up to the cyst on the right, but not on the left. (The extremities of the equatorial regions on either side are shown by the four arrow heads). (14 500 X)

D. Severe form of acrosomal cyst (acy), which appears empty; a lip (L) is also present. (18 000 X)



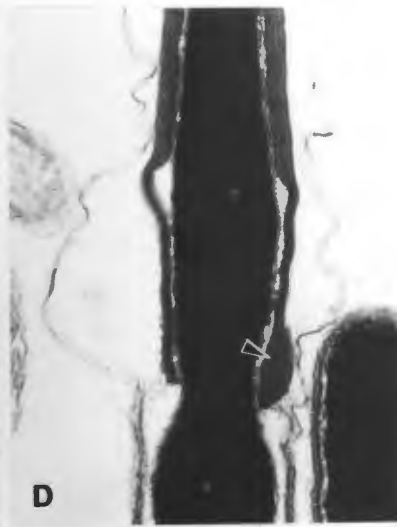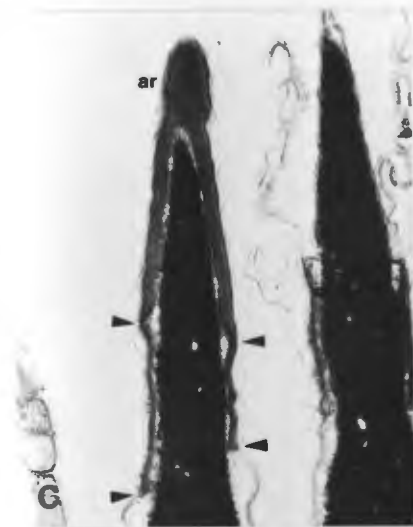
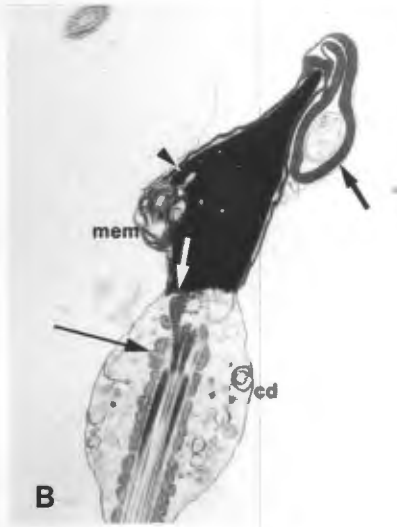
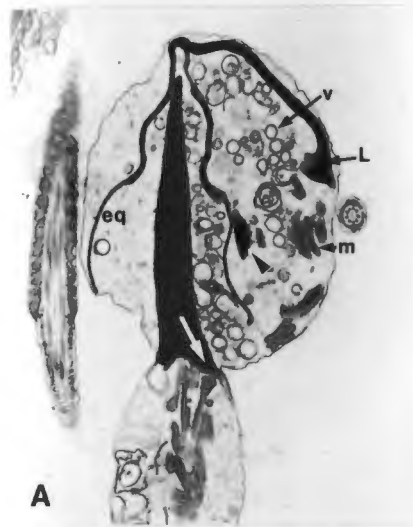
**Plate 4. Other major acrosomal abnormalities.**

A. Severe lipping (L), enclosing vesicular material (v), a portion of normal acrosome seemingly unattached to the rest of the acrosome (arrow head), and scattered mitochondria (m). The equatorial region (eq) is elongated, and there is abaxial attachment of the midpiece (white arrow). (8 800 X)

B. There is a lipped cyst apically (heavy black arrow), and an accumulation of membranous material (mem) on the left in the post acrosomal region of the head. Adjacent to this is a nuclear protuberance (ridging) (arrow head). The apex of the head is tapered, and the midpiece is abaxially attached (white arrow). There is a cytoplasmic droplet present (cd), and the midpiece contains irregularly arranged mitochondria (fine black arrow). (8 600 X)

C. Irregular equatorial region. Note the different lengths of the equatorial region on either side (four arrow heads). There is also an acrosomal ridge present apically (ar). (22 500 X)

D. Equatorial swelling. Note that the distal portion of the equatorial region is enlarged, and contains acrosomal material (arrow head) (compare with LM Plate 2 b). (36 800 X)



**Plate 5. Minor acrosomal abnormalities - the acrosome reaction.**

A. The first indication of the acrosome reaction may be seen as a few areas of low electron density (arrow heads) in the acrosome. This is caused by invaginations of the outer acrosomal membrane forming vesicles and consequent loss of acrosomal contents. These areas of low electron density gradually extend, as may be seen in B. (12 000 X)

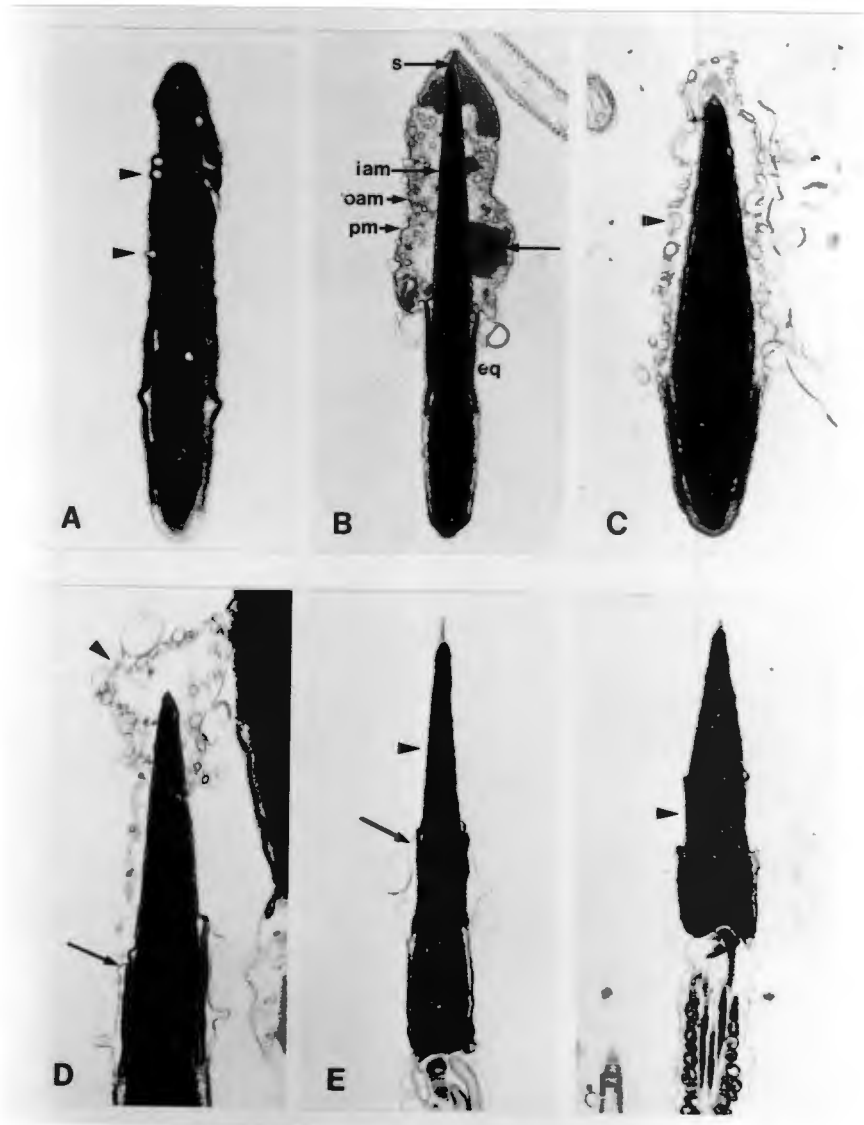
B. Here portions of reacting acrosome may be seen interspersed with swollen acrosomal material (fine black arrow). The membrane systems (plasma, outer and inner acrosomal membranes) may be seen. Note that the inner acrosomal membrane is tightly adherent to the nucleus, and does not vesiculate. The reaction does not affect the equatorial region at this stage. The sub-acrosomal substance (s) may be clearly seen where it forms the apical body. (12 200 X)

C. Vesiculation has extended over the whole of the non-equatorial region of the acrosome (arrow head). (14 000 X)

D. The vesiculated acrosome is partially detached (arrow head) and the fusion of the plasma membrane with the outer acrosomal membrane at the equatorial region is indicated (fine black arrow). (22 600 X)

E. The acrosome has detached, leaving an exposed inner acrosomal membrane (arrow head) covering the nucleus. The fused plasma and outer acrosomal membranes may be seen at the equatorial region (fine black arrow). The apical body is also visible. At this stage the sperm has fully reacted, and is capable of fertilization. If the sperm does not fertilize an oocyte, the reaction continues, as shown in F. (11 500 X)

F. Here the sperm has "over reacted", and the equatorial region has also been lost (arrow head). (8 600 X)



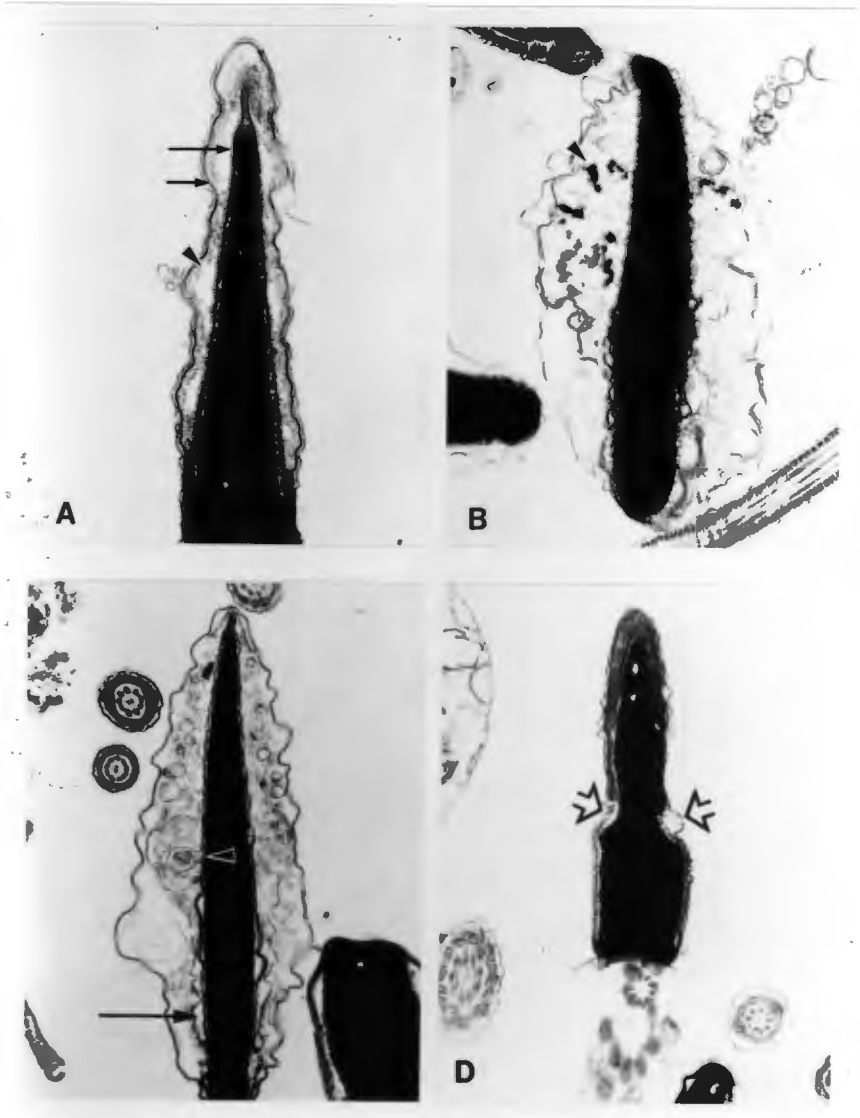
**Plate 6. Minor acrosomal abnormalities, cont.**

A. Swollen acrosome. Note the overall swollen and fuzzy appearance of the acrosome, and the loss of acrosomal contents, as may be seen by the loss of electron dense acrosomal material (arrow head) between the outer and inner acrosomal membranes (arrows). In the equatorial region the acrosome is still reasonably intact (compare with LM Plate 3 d). (25 000 X)

B. Extreme swelling of the acrosome. Here the damaged acrosome is seen showing loss of contents, and swelling between the membranes. Portions of undispersed acrosome are still visible as electron dense material (arrow head). (LM Plate 3 e). (18 000 X)

C. Acrosome damage that includes the equatorial region. Note the loss of acrosomal material in the equatorial region (black arrow) and the swelling with some vesiculation over the rest of the acrosome (LM Plate 3 f). Note also that there is vesiculation of the inner acrosomal membrane which contains a membranous mass (arrow head). This was the only sperm seen with a defect of the inner acrosomal membrane. This is probably a primary abnormality, not associated with the acrosomal damage. (18 000 X)

D. Tapered head over the acrosomal region. Here the head is narrowed in the region of the acrosome (arrows). It seems as if the head has been "pinched" during formation of the acrosome. Below the equatorial region the head is more normal in size. (8 600 X)



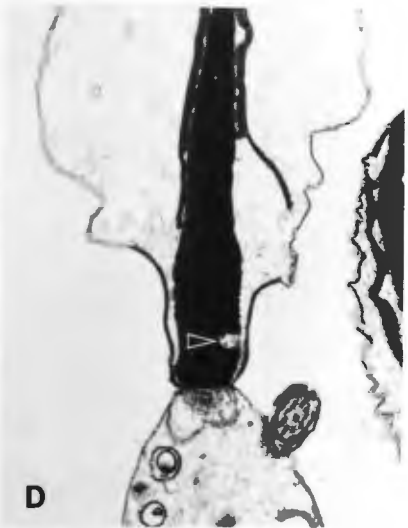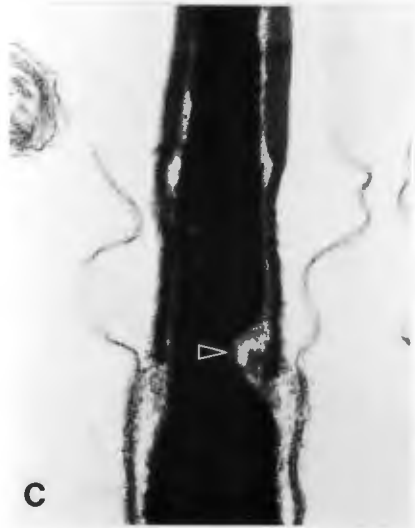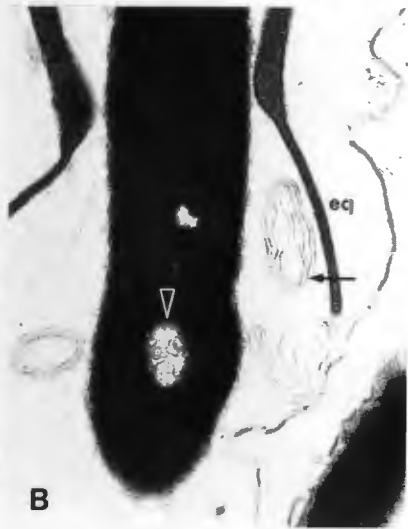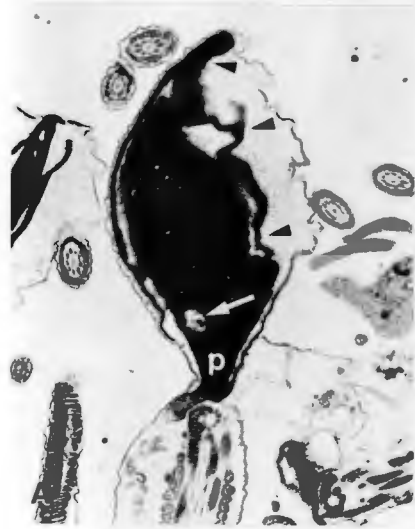**Plate 7: Major head abnormalities: the diadem defect.**

A. The diadem or crater defect is characterized by pouch-like invaginations into the nucleus, usually situated equatorially and generally connected to the sub-acrosomal region by means of a small stalk or pedicle. The latter may or may not be visible, depending on the plane of section. The vacuoles are lined by nuclear membrane and may appear empty, or may be filled with various cytoplasmic constituents in the form of membranous, granular or vesicular material. In this micrograph the vacuole (white arrow) has a granular content. The nucleus is pyriform (P), and it has an irregularly shaped acrosome (arrow heads).  
(9 900 X)

B. An enlargement of EM Plate 18 A, showing the diadem defect. Note that the defect is membrane lined (arrow head), filled with membranous material and is situated equatorially (eq). Membranous material (arrow) may also be seen between the nucleus and the equatorial region.  
(40 000 X)

C. This vacuole has a large opening into the sub-acrosomal region, and the sub-acrosomal substance may be seen to penetrate into this vacuole (arrow head). (36 800 X)

D. Nuclear vacuole that is not in the equatorial region, but is located near to the base plate. Nuclear vacuoles were only occasionally noted in this region in the dogs examined.  
(14 500 X)



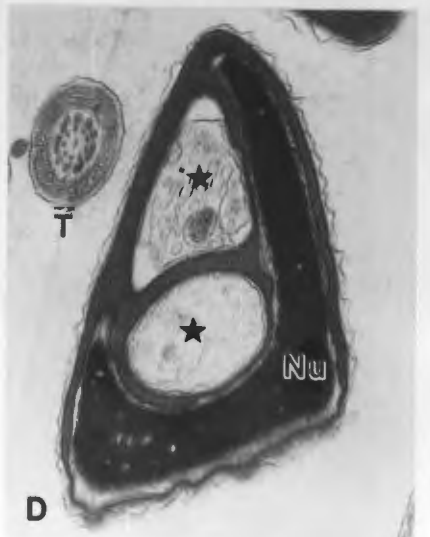
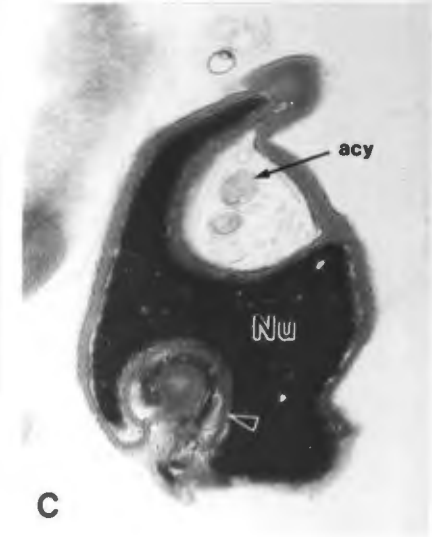
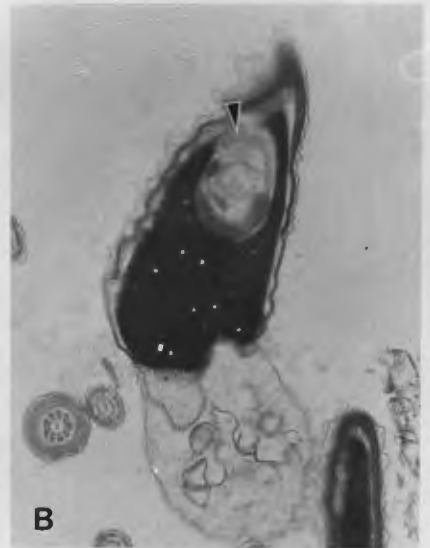**Plate 8: Major head abnormalities: other nuclear vacuoles not associated with the diadem defect.**

A. Here the vacuole seems to extend from the base of the head into the equatorial region (arrow head). It may however be an accentuated form of nuclear ridging (see EM Plate 9). (25 000 X)

B. Large nuclear vacuole seen in the apical region of the head filled with membranous and acrosomal material (arrow head). In general, the acrosome conforms to the contour of the nucleus, and thus nuclear abnormalities tend to impose abnormal features on the acrosome. There is also a curved base plate present. (16 000 X)

C. Double nuclear vacuole. The vacuole located apically seems to be an acrosomal cyst (acy) with vesicular material surrounded by acrosomal material that has invaginated into the nucleus. The vacuole located caudally (arrow head) also seems to be due to an invagination of acrosomal material, as suggested by the small amount of equatorial region that is included in the vacuole. It is possible that the two vacuoles are sections through the same cyst. This sperm may also be a type of bizarre nuclear ridging. (See EM Plate 9). (18 000 X)

D. Here a double acrosomal cyst (\*) has invaginated into the nucleus. The apical cyst contains membranous material, and the caudal cyst contains granular material; both are surrounded by common acrosomal material. (18 000 X)



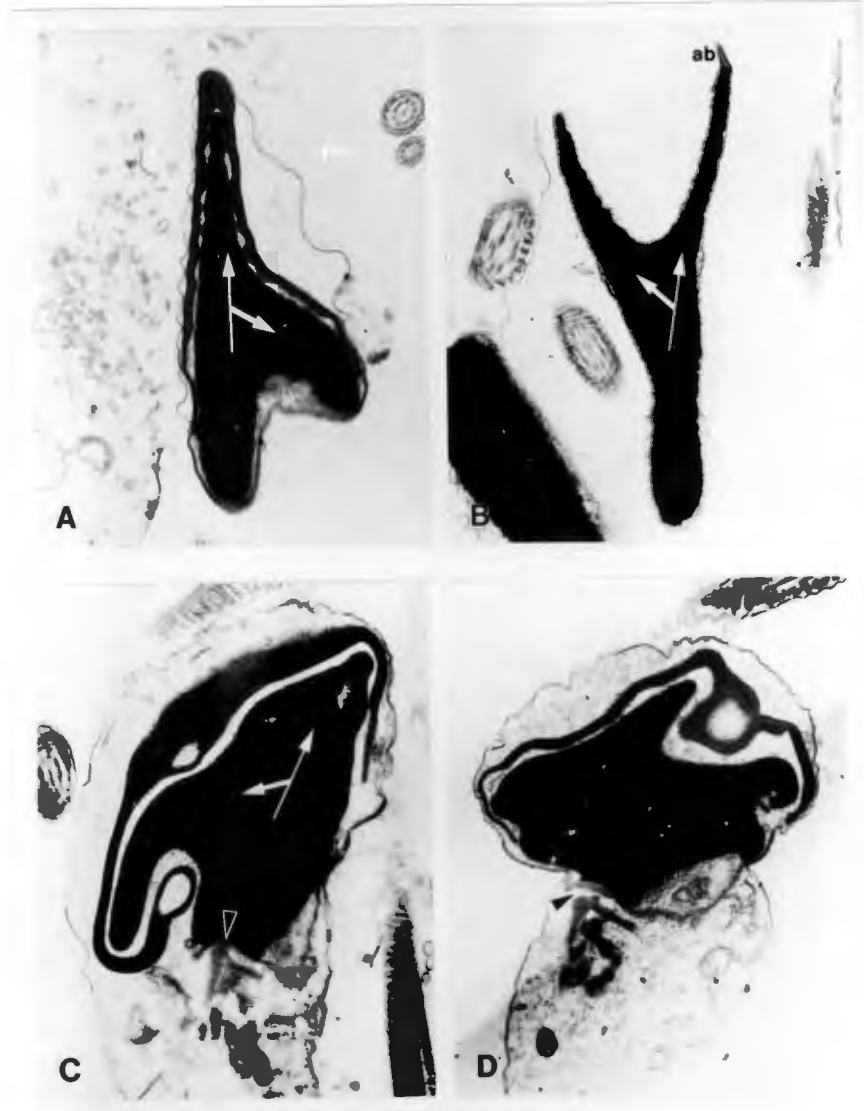
**Plate 9: Major head abnormalities: nuclear ridging**

A. The two axes of the nuclei are shown with the white arrows. This sperm has a lateral ridge which is partially covered by the acrosome. (15 000 X)

B. More marked ridging. On the left is a lateral ridge that has bent apically. The apical body (ab) may be seen on the right. The acrosome has been lost but the apical body helps to define the axes of the nuclei (white arrows). (17 000 X)

C. Macrocephalic head with a lateral ridge which has curved caudally. There is also an acrosomal cyst that appears to have pushed into the space created by the ridge. (Alternatively, the invagination of the acrosome may have induced the ridge) (see EM Plate 8). The head-base may be identified by the base plate (arrow head). The axes of the nuclei are shown with white arrows. (16 000 X)

D. Multiple ridging: Here the various ridges of the nucleus radiate from the macrocephalic head. The base plate is misaligned (arrow head) and the acrosome is malformed and contains a cyst. The midpiece appears disordered, and there is a protoplasmic droplet present. (14 000 X)



**Plate 10: Other major head abnormalities.**

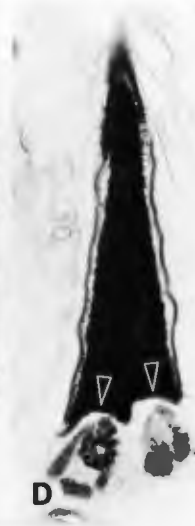
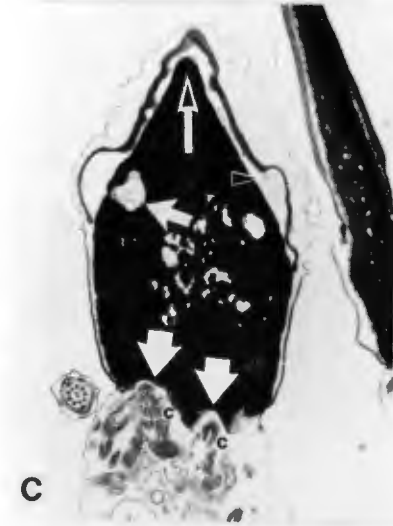
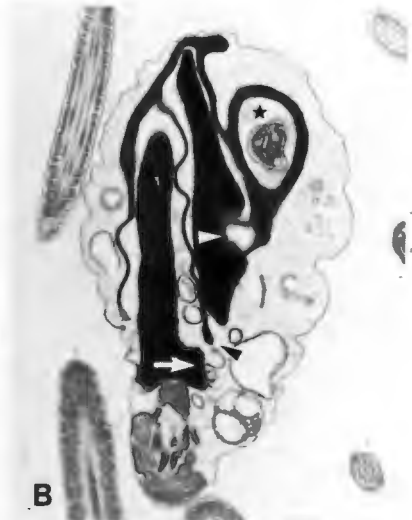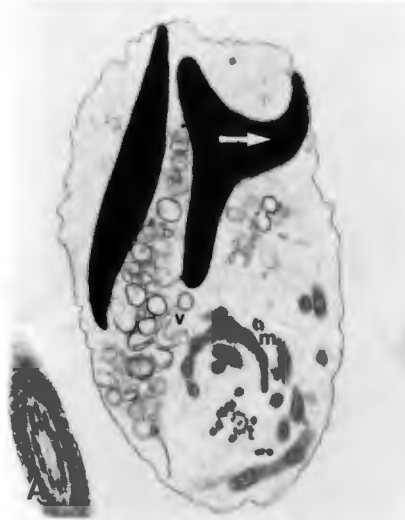A. Double head, one of which is ridged (note the axis of the ridge - white arrow). Cytoplasmic remnants comprising vesicular components (v), mitochondria (m) and tail sections (t) enclose the two nuclei. (8 000 X)

B. A sperm with a double head sharing a common equatorial region (black arrow head). One part of the acrosome has a cyst (\*) and another part is invaginated into the nucleus on the right (white arrowhead). The other nucleus has a basal ridge (white arrow). The mitochondria of the midpiece are arranged in a disorderly way within the retained cytoplasmic droplet. (8 500 X)

C. Macrocephalic head with double base plates (large white arrows) and double centrioles (c,c). There are diadem defects present (narrow white arrow), and the apex of the head is pointed instead of rounded (black on white arrow). Membranous components are visible beneath the acrosome (arrow head). (11 000 X)

D. Head with double base plates (arrow heads). The head, while abnormal, does not seem to be macrocephalic. (14 000 X)

E. Double head with two tails that are intertwined and share a common plasma membrane. There is also a transverse section through the tail (t) near the head-base on the left. This tail section is enclosed within the plasma membrane of the sperm, and thus can be assumed to originate from these sperm. The mitochondria of the sperm on the left are arranged in a disorderly way proximally, but seem to become more ordered as the tails spiral around each other distally (arrow heads). At this level, there is another transverse section through the tail (t). (4 500 X)



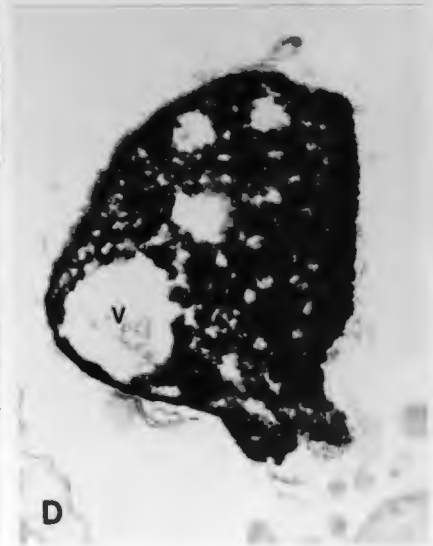
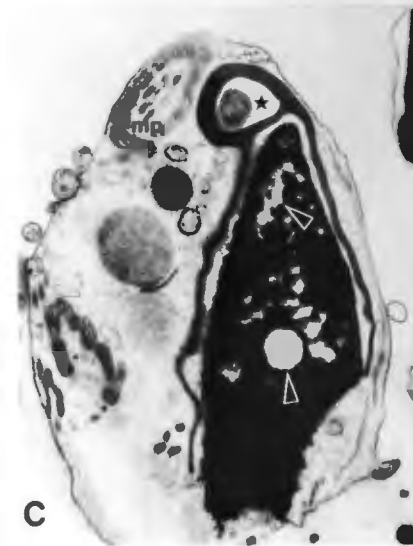
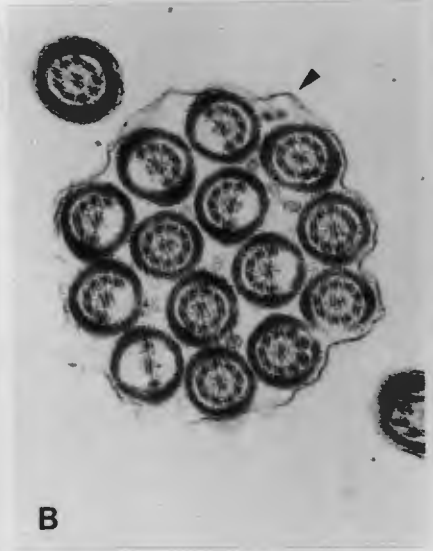
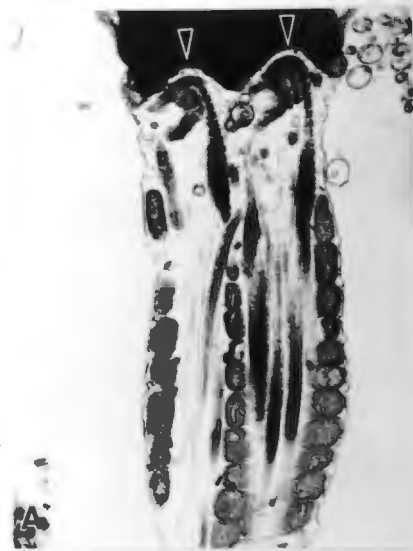
**Plate 11 Other major head abnormalities, cont; minor head abnormalities.**

A. Double tail with common central mitochondria. The two base plates are identified by the arrow heads. The coarse fibrils are arranged in a disorderly way; one fibril seems to originate in the midpiece on the right, and crosses over to the left. Some of the mitochondria appear to be missing from the midpiece on the left. (17 200 X)

B. Section through multiple tails surrounded by a common plasma membrane (arrow head); fourteen sections of tail are visible. Note various degrees of loss of fibrils within each tail, some having the complete set (9 + 2) while others have fewer fibrils. One tail has only two outer and two central fibrils. This is not a section through a "Dag" defect, where the tail is coiled around a number of times within the plasma membrane, because the sections of the tail would then be at different angles and levels depending on the plane of section. Note that these tail sections are very uniform and have all been taken transversely from approximately the same position on the tail. (18 000 X)

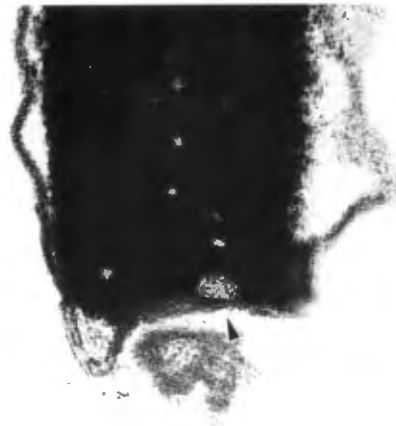C. Nuclear decondensation. This is seen as irregular areas of nuclear material showing reduced electron density (upper arrow head). The round area in the equatorial region may be a diadem defect (lower arrow head). There is also an acrosomal cyst present (\*) and a "Dag" defect (as indicated by the section through the midpiece (mp), the loose arrangement of fibrils and irregular mitochondria contained within the plasma membrane) (see EM Plate 18). (16 000 X)

D. Nuclear degeneration. Note the irregularity of electron density in this pyriform head. There is a large non-membrane bound vacuole (v) present, and the acrosome has been lost. (15 000 X)

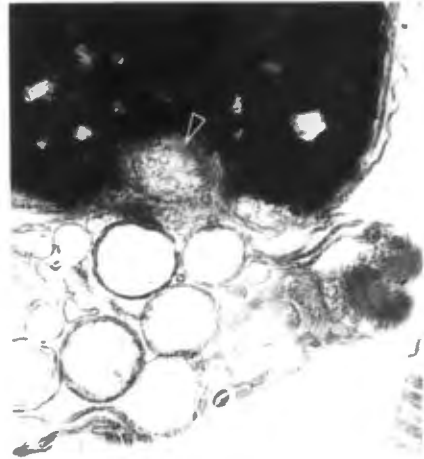


**Plate 12: Other head abnormalities: head-base defects**

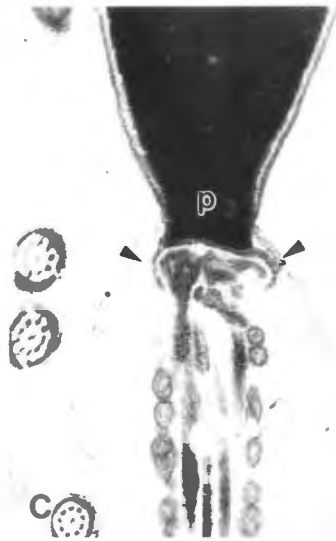
- A. Head-base vacuole. The small vacuole is covered by the base plate (arrow head). (35 000 X)
- B. Head-base vacuole, where the base plate does not bridge over the vacuole. The vacuole contains vesicular material (arrow head) similar to that seen below the head. (48 000 X)
- C. Pyriform head (p) with curved base plate (arrow heads). (28 500 X)
- D. Curved base plate (arrow heads). This accentuates the normal slight concavity of the implantation fossa. (30 000X)



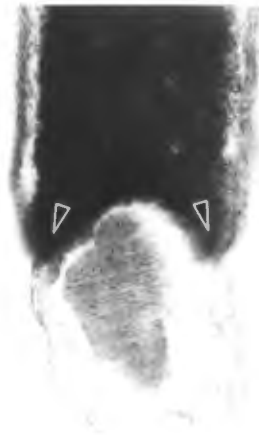
A



B



C



D

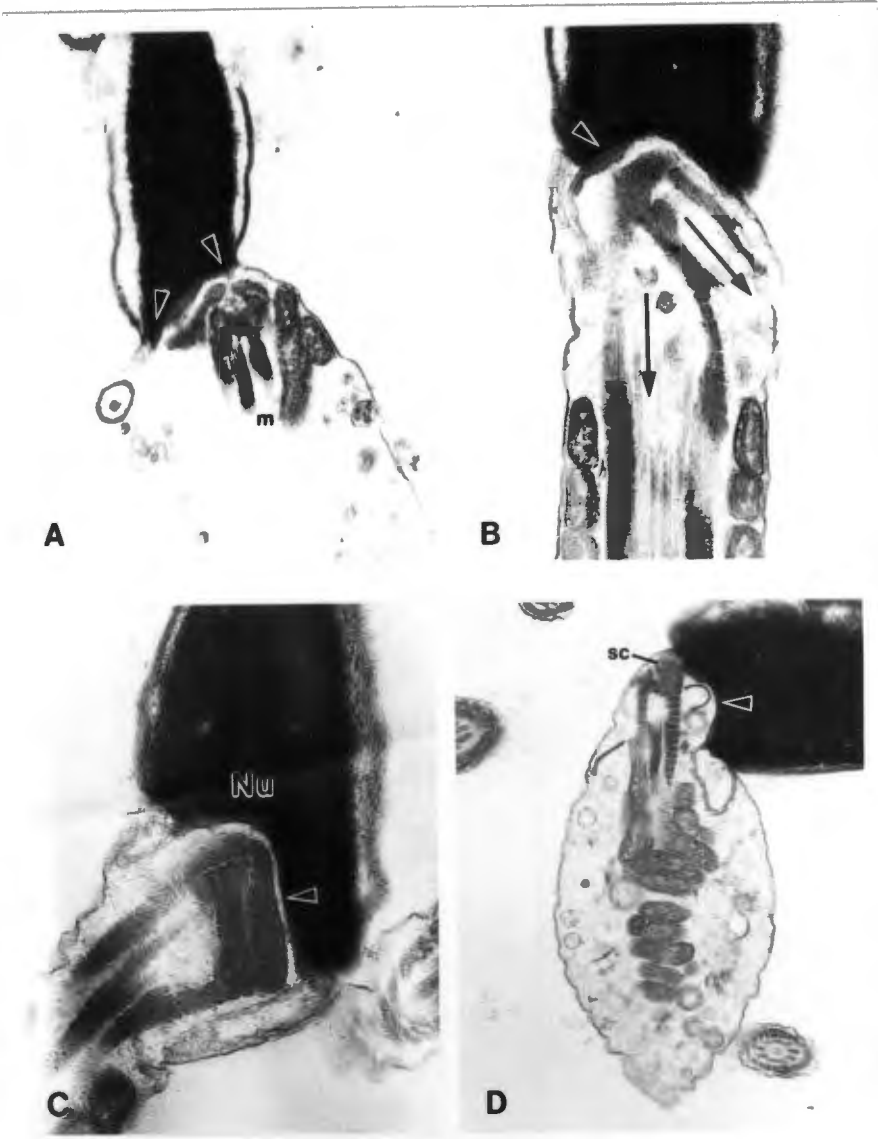
**Plate 13: Other head abnormalities, cont.: head-base defects**

A. Skew head-base. Note that the head-base (arrow heads) is skew, and attached to an abnormal midpiece containing irregular, disorderly arranged mitochondria (m). (25 000 X)

B. Skew head and misaligned segmented columns. Note the two axes of the segmented columns (black arrows) and the head-base axis (arrow head). It appears as if the midpiece was rotated relative to the head, rupturing the fibrils and misaligning the axes. (30 000 X)

C. Severe implantation abnormality. Note that the segmented columns are attached at right angles to the nucleus. (35 000 X)

D. Defective implantation of the segmented columns on the head. Note the concave head-base and base plate (arrow head), and the completely misaligned segmented columns (sc). The correct implantation of the segmented columns is essential to ensure normal motility of sperm. (28 000 X)



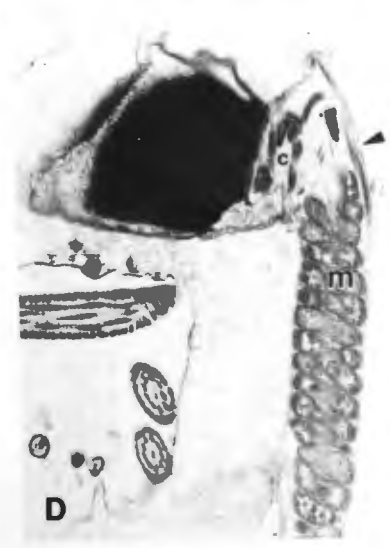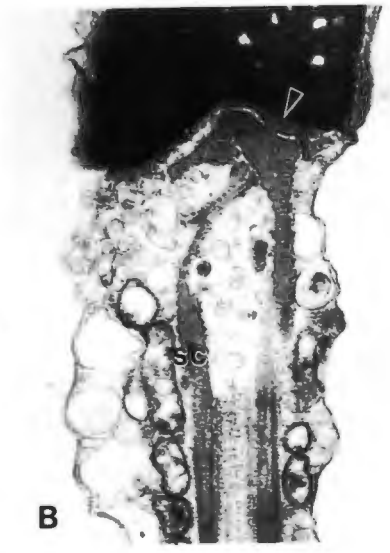
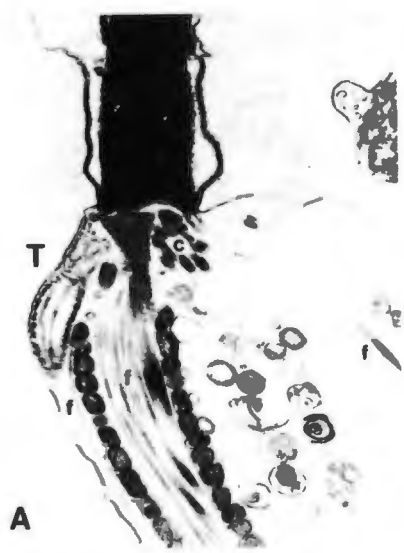**Plate 14: Major midpiece abnormalities**

A. Misalignment of the segmented columns. Note the centriole (c) and the longitudinal section of tail (T) next to the midpiece. There are also fine fibrils (f,f,f) lying misaligned in the midpiece and loose in the cytoplasmic droplet. (25 000 X)

B. Concave head-base (arrow head) with misaligned segmented columns. Note the curved segmented columns (sc). The mitochondria are abnormal, and appear swollen with indistinct cristae. (30 000 X)

C. Curved base plate on reasonably flat head-base. Note that the base plate is not correctly aligned on the head-base but has been bent (arrow head) so as to join the nuclear scroll (black arrow). The centriole (c) is also visible. (28 000 X)

D. Kinked midpiece. Note the relatively normal midpiece (m) distally, but proximally at the attachment to the segmented columns there is rupture of fibrils and kinking of the midpiece. Disorientated loose fibrils are also present (arrow head). (26 000 X)



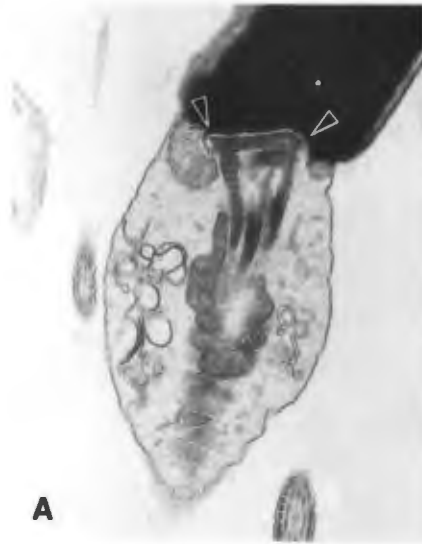**Plate 15: Major midpiece abnormalities, cont.**

A. Broad head-base. Note the increased width of the head-base as indicated by the arrow heads. Compare with the normal head-base in EM Plate 1 A and B. (29 000 X)

B. Vacuole in the segmented column (arrow head). (35 000 X)

C. Large vacuole (v) in the segmented column. Note coalescence of the segmented columns with loss of normal cross banding (arrow head) in this abnormal midpiece. (26 000 X)

D. Mitochondrial aplasia. In this sperm there is a large section of midpiece where there are no mitochondria present (arrow head), and the segmented columns are abnormally long (compare with LM Plate 8f). (25 000 X)



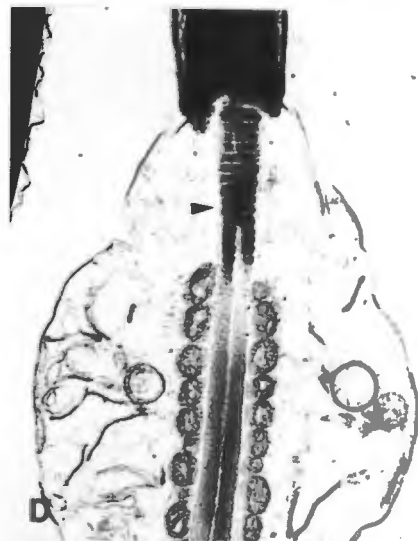**A**



**B**



**C**



**D**

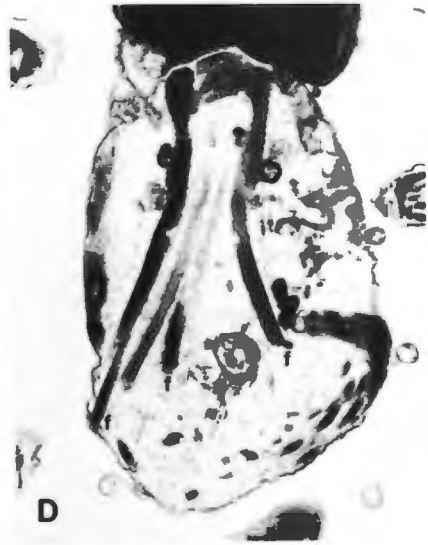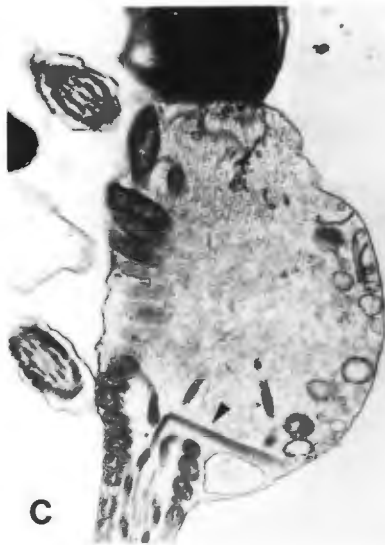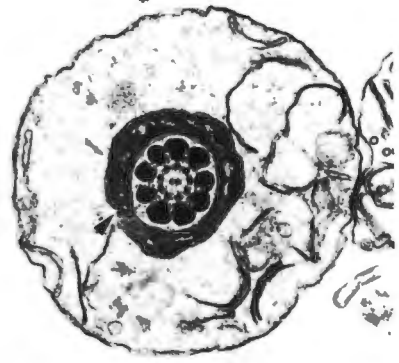
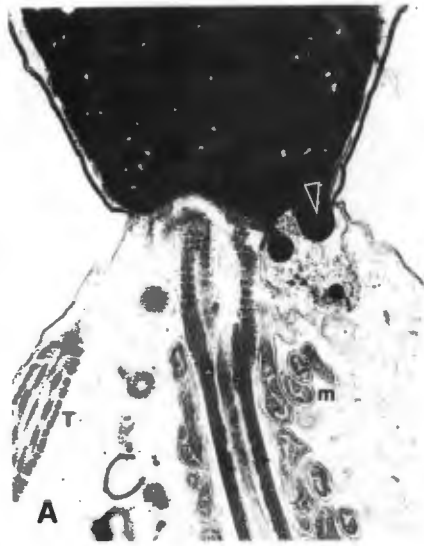**Plate 16: Major midpiece abnormalities, cont.; minor midpiece abnormalities**

A. Abaxial attachment. Note that the attachment of the midpiece is not central in this planar section. Note also that there is a nuclear evagination into the cytoplasmic droplet in the nuclear scroll region (arrow head). The mitochondria (m) show a disorderly arrangement, and there are sections through the tail (T) indicating a "Dag" defect. (25 000 X)

B. Cytoplasmic droplet. This is a transverse section through the droplet, and the mitochondria (arrow head) may clearly be seen surrounding the coarse and fine fibrils of the axoneme. The droplet contains granular and membranous components. (19 500 X)

C. Longitudinal section through a proximal cytoplasmic droplet. The axoneme has ruptured, as seen by the misaligned fibrils (arrow head). The mitochondrial helix is disorderly arranged between the arrow head and the head-base. The motility of such sperm will be seriously affected. (23 000 X)

D. Rupture of the midpiece. Here the fibrils are seen to splay (f,f,f) and the mitochondria show a disordered arrangement and are poorly developed. There is also a cytoplasmic droplet present. (28 000 X)



**Plate 17: Midpiece abnormalities, cont.; major tail abnormalities**

A. Swollen midpiece. There is an accumulation of irregularly arranged mitochondria (arrow head) near the head-base, around coarse fibrils which show a disordered arrangement (fine black arrow). This may be a "pseudodroplet" defect, and should be compared with LM Plates 8 d and e. (28 000 X)

B. Mitochondrial degeneration. Note the reasonably normal mitochondria (m) in the sperm on the left but in the sperm on the right mitochondrial degeneration is evident. The cristae are poorly defined and the centers of the mitochondria appear empty (arrow head). (28 000 X)

C. Severe degeneration of the mitochondria. These membranous bodies (arrow head) contained within the cytoplasmic droplet (cd) are only vaguely reminiscent of mitochondria. They are arranged in a disorderly way, and appear to displace the tail to the left. The head-base is concave. (26 000 X)

D. Midpiece folded back on itself. The degree of folding has induced kinking and rupturing of the fibrils (black arrows) and also loss of mitochondria in the area of the fold (arrow heads). (25 000 X)

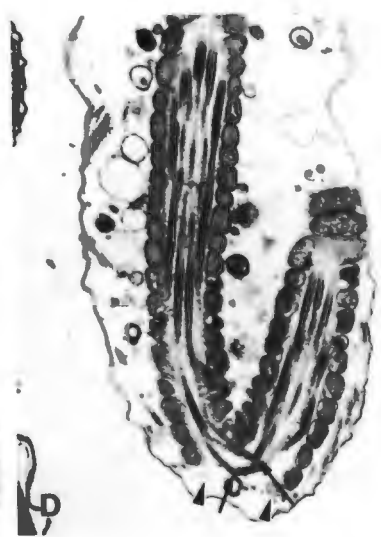
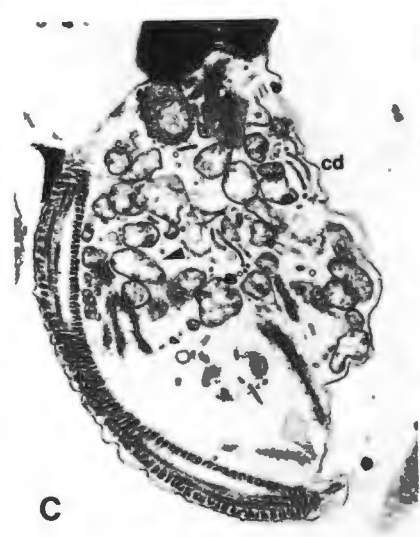
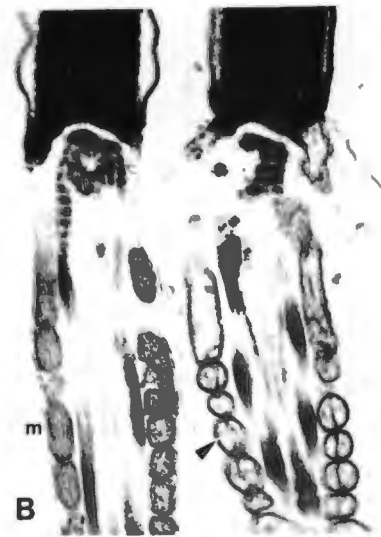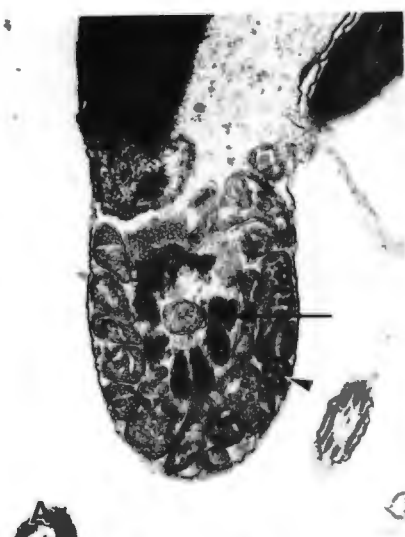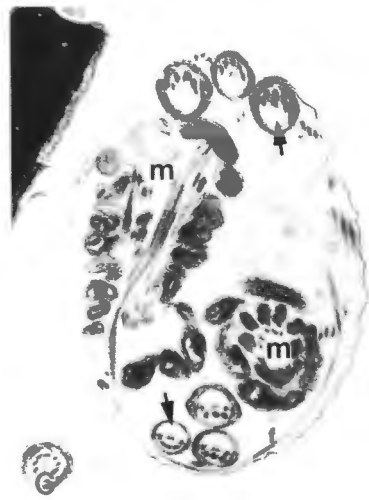
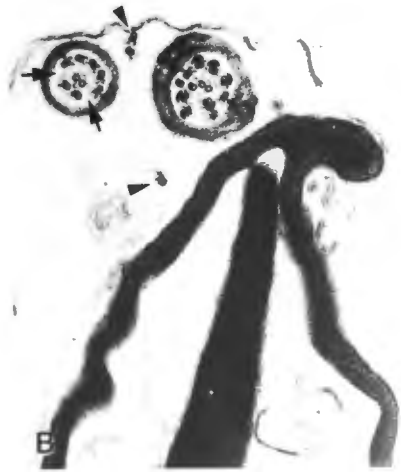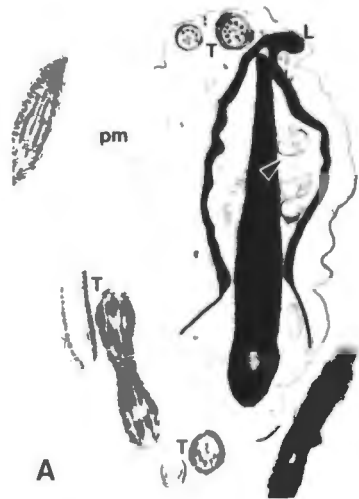
Plate 18: Major tail abnormalities, cont.: the "Dag" defect

A. The "Dag" defect is characterized by coiling of the tail within an intact plasma membrane. The tail may or may not be coiled around the head. (Compare with LM Plates 9 and 10). In this sperm there are many longitudinal and transverse sections through the tail (T,T,T). There is also a lipped acrosome (L), a diadem defect, and membranous material has pushed up beneath the acrosome. (8 800 X)

B. An enlargement of A, showing loss of fibrils within the tail (black arrows) and loose fibrils within the cytoplasmic material (arrow heads). Both of these features are regularly found in sperm with the "Dag" defect. (22 000 X)

C. "Dag" defect involving the midpiece. Note the longitudinal and transverse sections through the midpiece (m,m). The sections through the tail show loss of fibrils (arrows) and there are loose fibrils (f) in the cytoplasmic material. (15 000 X)

D. "Dag" defect. The coils of the tail (arrow heads) completely enclose the head. The mitochondria (m) are arranged in a disorderly way. There is an abnormal acrosome present and areas of nuclear decondensation. (11 500 X)



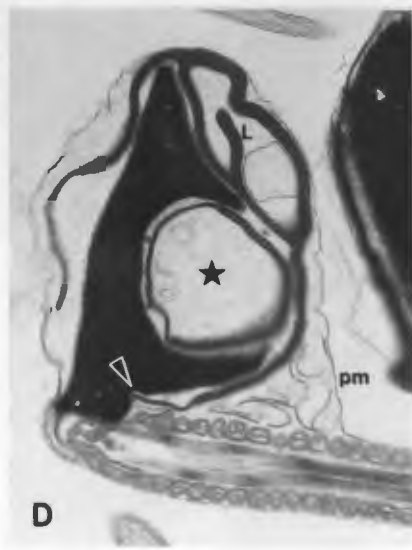
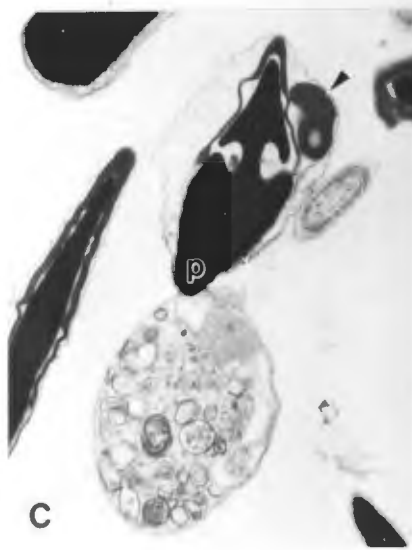
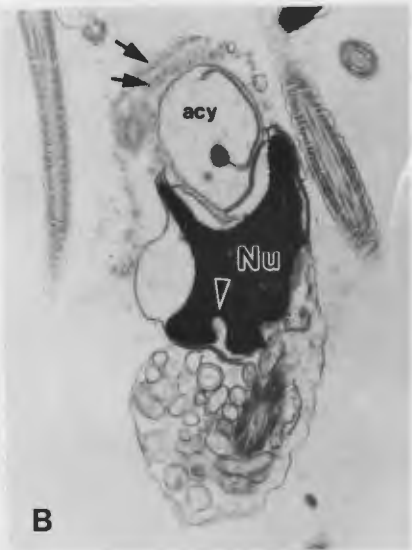
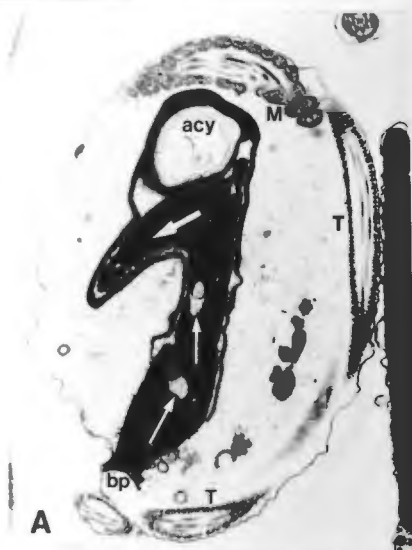**Plate 19: Bizarre and multiple abnormalities.**

A. This sperm has an irregularly shaped nucleus which is ridged (heavy white arrow) and has two vacuoles due to a diadem defect (fine white arrows). An acrosomal cyst (acy), a curved base plate (bp) and a "Dag" defect are also present. The latter is seen by the sections through the midpiece (M) and tail (T) (10 000 X)

B. Multiple ridged nucleus with basal vacuole (arrow head) and acrosomal cyst (acy). There is a double row of acrosomal vesicles (arrows), indicating an abnormal form of acrosome reaction (compare with EM Plate 5 C). (8 600 X)

C. Pyriform head (p) with large vacuoles due to a double diadem defect. The acrosome is abnormal; there is a large piece of acrosomal material (arrow head) to the right of the main portion of the acrosome. Note the cytoplasmic droplet filled with vesicular material, which may represent degenerated mitochondria. (6 500 X)

D. Nuclear ridging and acrosomal cysts with an inverted lip (L). Note also that the equatorial region has pushed into the nucleus distally (arrow head). Note how the plasma membrane (pm) is lifted away from the mitochondria of the midpiece by the membranous material which has formed a small cytoplasmic droplet in the area between the acrosome and midpiece. The attachment of the midpiece to the head is skew. (16 000 X)



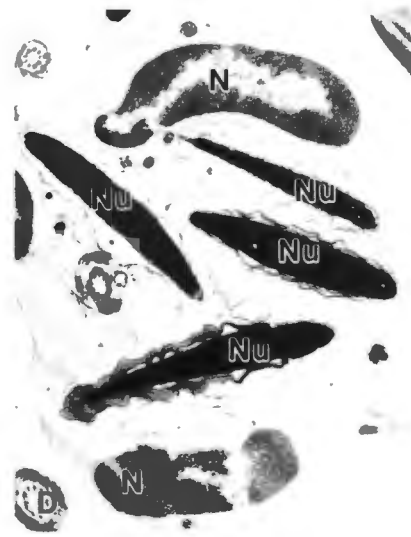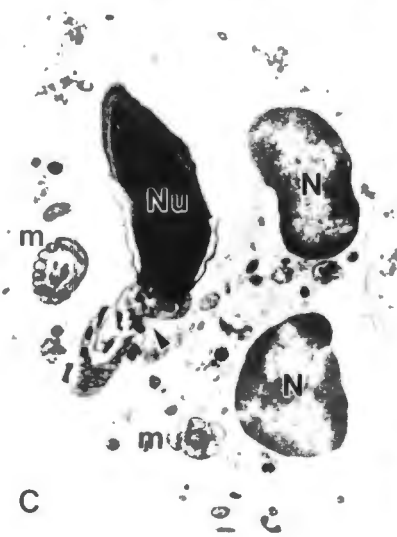
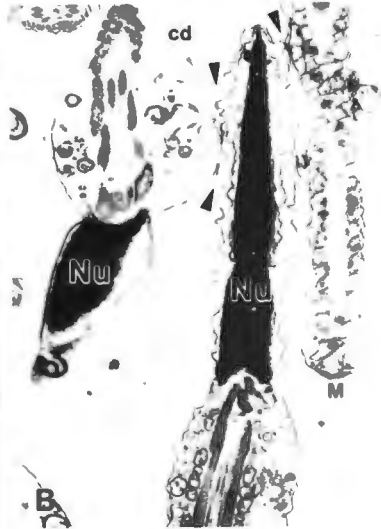
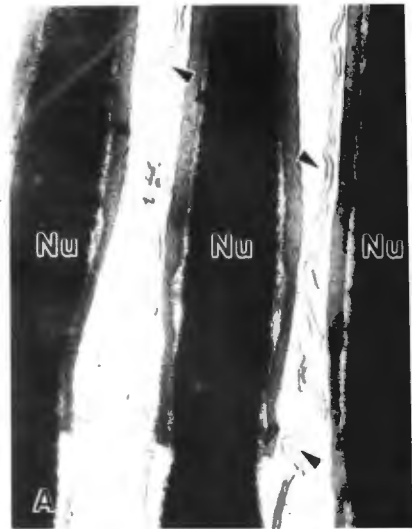
**Plate 20: Other abnormalities**

A. Head to head agglutination. Note the closely opposed plasma membranes (arrow heads) of these normal heads which possess normal acrosomes. (36 000 X)

B. Head to tail agglutination. In this example the acrosome has undergone secondary changes and is in close apposition to the cytoplasmic droplet (cd) on the left and the midpiece (M) on the right. Note the close apposition of the plasma membranes (arrow heads). (10 000 X)

C. Phagocytosis of abnormal sperm. Note nuclei of the macrophage (N) and sperm (Nu). There is kinking of the midpiece (arrow head), which shows a high degree of disorganization. Other normal sections through midpieces (m, m) are also present within the cytoplasm of the macrophage. The sperm nucleus has an abnormal shape. (8 500 X)

D. Phagocytosis of normal sperm. Here the sperm heads seem normal, apart from secondary acrosomal changes. It is not known whether these changes occurred before or after phagocytosis. The lower sperm may have been phagocytosed last, as its acrosome is only mildly swollen in comparison with the other three sperm. (6 500 X)



## CHAPTER 5. DISCUSSION

### 5.1. Evaluation of methods

Semen may be collected by artificial vagina, electro-ejaculation, or digital manipulation (Harrop, 1954; Christensen & Dougherty, 1955; Burke, 1986). The latter method, used in this study, was found to give consistently better results than when an artificial vagina was used. This is most likely due to the inherent problems associated with the use of the artificial vagina (Boucher et al., 1958). Since inaccurate evaluations might be obtained for semen collected with an artificial vagina, none of the samples collected in this manner were included in this study. Electro-ejaculation was attempted in one instance, but without success. Compared with the ease with which semen could be collected by digital manipulation, electro-ejaculation did not appear to be a practical method of semen collection in the dog.

The presence of a bitch in oestrus always increased the libido of the dogs. However, semen could always be obtained from dogs showing poor libido, even without the aid of an oestrous bitch, although the first and third fractions tended to be lower in volume than expected.

The volume of dog semen was found to be dependant on the size of the dog, and varied between 0.5 and 10 ml. This is in agreement with Christiansen (1984), although he also recorded volumes of up to 15 ml occasionally. The volumes and origins of the fractions of the ejaculate have been discussed in detail by Christiansen (1984).

Most of the ejaculates were greyish-white in colour, this being conferred by dilution of the second fraction by the first and third fractions. On occasion a clear sample was obtained, usually as a result of oligo- or azoo-spermia, an incomplete ejaculation, or an accidental loss of the second fraction. The latter was sometimes found to occur when the dog ejaculated with violent thrusting movements, making collection awkward. In these instances the collection was repeated the following day. An abnormal pink colour was found to be caused by the presence of blood. This was usually caused by rupture of the small superficial penile blood vessels, possibly caused by the large increase in blood pressure that occurs with erection. The haemorrhage was usually minor and ceased when the erection subsided. Cotton wool moistened with cold water was found to be a useful compress in such cases.

### 5.1.1. Microscopical evaluation of the semen samples

#### 5.1.1.1. Motility

The value for normal motility of dog sperm has been the subject of considerable contention. This is probably due to inherent problems associated with the use of the artificial vagina as discussed above, resulting in a consequent artifactual loss of motility in fertile dogs. Christiansen (1984) reports that less than 60 percent motile sperm should be considered abnormal, while Freshman et al. (1988) consider that more than 70 percent motility is normal. Rosenthal (1983) found that for the normal dog more than 80 percent motile sperm is expected; he found that only rarely did a dog with less than 70 percent motile sperm have good fertility. In the present study, the average motility ( $\pm$ S.D.) in the group of dogs with normal morphology was 76 ( $\pm$ 15) percent while that in the group of dogs with subnormal morphology was 57 ( $\pm$ 24) percent .

There are more sophisticated methods than those employed in the present study for the assessment of sperm motility, but for practical reasons these have not yet been applied to routine investigations in the dog. They include frame-lapse videography, time-lapse photomicrography, and computerized motility assessments; their chief disadvantage is the expense of the equipment.

Spermatozoa are motile cells, a characteristic that has intrigued workers ever since sperm were seen under the light microscope by Leeuwenhoek in 1679 (see Singer, 1959). Early experiments involved studies on the effect of various treatments on the motility. It was not long before the postulate that motility and fertility might possibly be interrelated was tested. In many species, however, this was found not to be the case, and the search began for other parameters within the sperm cell that might be related to fertility. The aim was to predict semen quality (i.e. fertilizing potential) without actually performing fertilization experiments. While no single parameter has yet proved to be the ultimate in fertility assessment, over the years it has become apparent that sperm morphology bears the best correlation with fertility (Saacke, 1970).

#### **5.1.1.2. Morphology**

The assessment of sperm morphology provides an enormous amount of valuable information about the reproductive status of an individual. Unfortunately, it is an approach that is often neglected by practicing veterinarians. A certain amount of practice is required to ensure that high quality preparations are consistently produced, and experience is

needed for their interpretation. Morphological evaluation can be carried out on unstained, wet preparations by phase contrast microscopy, but it is usual to examine stained preparations under conventional bright field light microscopy.

**a. Morphological stains.**

There are a number of stains available for the study of sperm morphology. The ideal combination of fixative and stain should have the following characteristics:

- i) They should give good definition and contrast to the spermatozoa, without changing the morphology by distortion.
- ii) The procedure should be quick and easy to apply, and not require specialized, expensive equipment.
- iii) Reagents should be stable and should not need to be prepared fresh each time. Ideally, reliable results should be obtained even with old stains.
- iv) The stain should differentiate between the major organelles, preferably quantitatively, so that an idea of cellular content may be inferred by variations in staining intensity.

v) The stain should be applicable to a wide variety of species, and to diluted (extended) semen, in particular where the common extenders which contain egg yolk or milk are employed.

Simple monochromatic one step stains, like Rose Bengal or eosin, were initially used to stain spermatozoa for light microscopy (Hackett & Macpherson, 1965). These monochromatic stains were modified so as to enhance contrast, by the addition of a background stain such as nigrosin. Such differential stains have since become popular because they distinguish between different portions of the cell, and also give reliable structural detail.

Seminal fluid, mucus or other unidentified coatings of the spermatozoa present problems with the use of some stains, since many dyes do not satisfactorily penetrate these constituents (Casarett, 1953). A balance thus had to be struck between the affinity of the stain for the spermatozoa and for background constituents. Methods whereby the spermatozoa were stripped from the plasma were advocated as a means of enhancing spermatozoal visibility, but alteration of morphological features by the extra handling required is a potential drawback (Casarett, 1953). Subsequently, other methods of reducing background interference and of increasing the affinity of stains for spermatozoa were introduced (Dott & Foster, 1972; Harasymowycz, Ball &

Seidel, 1976; Watson, 1975). Newer methods, which concentrate on the differences in composition between acrosome and nucleus, led to the development of the Wells-Awa and Bryan stains (Wells & Awa, 1968; Bryan 1970). Unfortunately, these stains can only be applied to a limited number of species, and background staining is intense when diluted (extended) semen is stained. Furthermore, the thickness of the preparation is critical when the Wells-Awa stain is used.

Rose Bengal does allow some degree of assessment of acrosomal integrity (Calderon Yubi et al., 1987); buffered Giemsa has also been used for this purpose, but the reagents must be warmed to 37 °C, and the fixing and staining times are long (Watson, 1975). Papanicolou stain is widely used for staining human sperm (W.H.O., 1987), but the technique is involved and gives poor results when applied to dog semen, especially extended semen (Oettlé, unpublished observations). However, reasonable acrosomal differentiation of human sperm is obtained when Papanicolou-stained preparations are visualized by phase contrast microscopy. This stain has the added advantage that it allows some degree of differentiation between immature sperm cells and leucocytes. However, for this purpose the combination of Bryan's sperm stain and Leishmann's stain for leucocytes gives better results (W.H.O., 1987).

Another complicated staining procedure is the triple stain technique of Talbot & Chacon (1981); this method combines a stain which indicates viability with an acrosome-specific stain. The aim is to differentiate between sperm which are alive but have lost their acrosomes (acrosome reacted), from those which are dead and without acrosomes (secondary acrosome damage). The stain was devised for use in humans, and has been tested in other species with some success. It is, however, a difficult staining procedure to execute correctly and has as yet found application only in research. The concensus of a number of delegates at the 5th International Symposium of Spermatology in Japan, 1986, was that when this stain works, it is very good, but its unpredictability makes it unreliable and thus impractical. When the reasons for this become known and remedied, it will surely be an excellent stain.

Spermac stain was developed to circumvent some of the problems outlined above (Oettlé, 1986c). The sperm nucleus stains red, and the acrosome, midpiece and tail are stained green. The equatorial region of the acrosome stains a paler green than the rest of the acrosome. Background staining is very faint. A semi-quantitative assessment of staining of cell organelles is obtained with the stain, which makes it particularly useful for the identification of sperm defects. Many defects are the result of hyper- or hypoplasia of a particular cellular component; for instance, in lipped

acrosomes, the acrosomal material is increased in the area of the lip, and thus the lipped portion stains deeper green than the rest of the acrosome. Changes in nuclear composition also are reflected as variations in staining intensity. Pyriform heads, micro- or macro-cephalic sperm, and nuclear vacuoles are good examples in this regard. Decondensation of the sperm nucleus results in a decrease in red staining of the nucleus. These and other staining variations will be discussed in more detail in the description of the individual defects.

Spermac stain was originally developed for use in the dog, and has since been shown to be effective in all mammalian species tested to date; these include man, the bull, ram, goat, horse, boar, cheetah, a variety of wild ungulates, rodents, bats, and also certain lower vertebrates including avian and reptilian (tortoise, snake, lizard and gecko) species, but not teleosts, which interestingly do not have acrosomes (Van der Horst, pers. comm.). The highest degree of differential staining is obtained in the dog and the poorest in the horse (Oettlé, unpublished data).

This stain in no way adversely affects sperm morphology, and good correlation was obtained between smears stained with this stain and electron microscopic preparations (Oettlé & Soley, 1986b). The procedure is simple; staining takes about

4 minutes, following a 5 minute period of fixation. The stain does not deteriorate with age, as long as evaporation is prevented.

Spermac stain may be used on diluted (extended) semen, since constituents such as egg yolk, serum or milk commonly included in diluents do not interfere with the staining. Unfavourable processing conditions or techniques may damage the acrosome, which is a labile organelle (Aalseth & Saacke, 1985; Oettlé, 1986b; Zalewski & Andersen-Berg, 1983). Such damage is related to the integrity of the acrosome, a parameter which is in turn correlated to fertility (Foote, 1975). This staining technique thus provides a useful method for the assessment and monitoring of acrosome integrity (Oettlé, 1986a). This has specific application in the field of cryopreservation; further applications are to be found in in vitro fertilization, methods for the concentration of motile sperms, and techniques used to separate X and Y bearing sperm.

#### **Mechanism of action of Spermac stain.**

The permeability of the various cell and tissue constituents and the speed of diffusion of the dye play important roles in determining the differential action of many stains. Eosin is a rapidly diffusing dye, and tends to get trapped by closer meshed constituents (for example alpha granules in

eosinophils), and is therefore often used as a cytoplasmic stain (Baker, 1958). In Spermac stain, however, the eosin is used as a nuclear stain. This is due to the unique hypercondensed structure of sperm chromatin as compared with that of most other nuclei. Initially the cytoplasmic portions also stain pink, but this effect is masked by the more vigorous brilliant green dye. A similar effect has been demonstrated in the experiments by Collin (see Baker, 1958) who used eosin and methyl blue to stain different concentrations of gelatin. He showed that eosin was able to penetrate the denser gelatin, but in the less concentrated gelatin methyl blue was able to enter, and competed with and masked the eosin. The conclusion that he drew was that the blue dye was more vigorous in action, but penetrated with more difficulty than the red. Spermac stain utilizes an intermediate step of phosphomolybdic and phosphotungstic acids. These high molecular weight substances act to exclude the background dye, and prevent staining of the nuclei with the brilliant green. When this step is omitted, the whole sperm stains green. This is similar to the effect seen with phosphomolybdic acid in the Mallory technique. Here the phosphomolybdic acid opposes the action of the aniline blue; if the phosphomolybdic acid is omitted, the aniline blue colours everywhere more strongly (Baker, 1958). Leucocytes and epithelial cells do not stain differentially with Spermac stain, since they do not possess hypercondensed nuclei. Thus the eosin is unable to act as a nuclear stain,

and is masked by the brilliant green. However, spermatid nuclei show a gradually increasing eosinophilia as they mature and condense. Initially this effect was thought to be related to the content of the disulphide bonds in the nuclei of these cells. However, this is not so, since lysis of disulphide bonds with dithiothreitol does not affect nuclear staining of the sperm. Moreover, when these dithiothreitol-treated sperm decondense following disruption of the nuclear and plasma membranes (for example drying on a glass slide) there is a concomitant decrease in staining affinity that appears proportional to the degree of decondensation. Counterstaining with Diff-Quik<sup>R</sup> confirmed that this loss of staining affinity was not an artifactual loss of nuclear material during specimen preparation (Oettlé & Clarke, 1989).

Another unrelated characteristic of the stain that has not been adequately explained is the effect of the degree of drying of the smear on the quality of the staining result. The best quality staining is achieved when the smear is fixed shortly after it has air-dried, preferably within 5 minutes of making the smear. When the smear is left too long before fixing the quality of staining deteriorates, and unsatisfactory results are obtained. A possible explanation is that the drying process takes place in two steps: initially extracellular drying, followed by intracellular dehydration. Fixation should take place between these steps;

since the staining appears to be adversely affected by intracellular dehydration, the cells must be fixed before this occurs. The mechanism by which the degree of dehydration affects the staining is unknown.

Electron microscopic examination is to date the most sophisticated technique for the examination of sperm morphology. Certain abnormalities are not visible with light microscopy, and are only revealed by transmission electron microscopy (Coetzee et al., 1985). Unfortunately, time and expense preclude the use of the electron microscope for routine examination. As a research tool it is unsurpassed, and has revealed in many instances not only the detailed ultrastructure of the defects, but also indicated their mechanism of formation.

#### **b. Morphological classification of abnormal sperm**

Much of the earlier work on the morphological assessment of sperm was performed on bull semen. In 1972, Blom proposed a classification for the bull spermogram which is shown in Table 7. This has been taken as the prototype on which many subsequent classifications have been modelled. The classification is based on the effect the abnormality has on fertility, as well as on morphological criteria.

**Table 7: Blom's classification of the bull spermogram  
(1972).**

**Major sperm defects**

Underdeveloped  
Double forms  
Knobbed sperm defect (acrosome defects)  
Decapitated sperm defect  
Diadem defect  
Pear shaped head  
Narrow at the base  
Abnormal contour  
Small abnormal heads  
Free abnormal heads  
Corkscrew defect  
Other middle piece defects  
Proximal droplets  
Pseudodroplet defect  
"Dag" defect

**Minor sperm defects**

Narrow heads  
Small abnormal heads  
Giant and short, broad heads  
Free heads (normal)  
Detached acrosomal caps  
Abaxial implantation  
Distal droplets  
Simple bent or coiled tail  
Terminally coiled tail

**Table 8: Sperm defects according to Christiansen (1984)**

<b>Location</b>	<b>Primary</b>	<b>Secondary</b>
<b>Head</b>	Macrocephalus Microcephalus Double heads Pointed heads Indented heads Opaque heads	Free heads Bent heads Detached heads Swollen acrosomes Detaching acrosomes
<b>Neck</b>	Thickened neck  Abaxial insertion Cytoplasmic droplets	Disintegration of neck region
<b>Midpiece</b>	Irregularly thickened midpiece Irregularly thinned midpiece Coiled midpiece Kinked midpiece Proximal cytoplasmic droplets Double midpiece Mid-cytoplasmic droplets Distal cytoplasmic droplets Extraneous material around midpiece	Bent midpiece
<b>Tail</b>	Thin tail Double tail Triple tail	Coiled tail Looped tail Kinked tail Folded tail Detached tail Cytoplasmic droplets

**Table 9: Sperm abnormalities according to Seager (1986).****Primary abnormalities****Head abnormalities**

Giant heads (Megalosperm)  
 Slender and small heads (Microsperm)  
 Tapered heads  
 Abnormal acrosome  
 Bicephalic

**Midpiece abnormalities**

Abaxially attached midpiece  
 Double midpiece  
 Coiled midpiece  
 Bent midpiece

**Tail abnormalities**

Tightly coiled tails  
 Double tails

**Secondary abnormalities**

Separation of the acrosomes  
 Presence of protoplasmic droplets:  
     Proximal: in neck region  
     Distal: at junction of midpiece and principal  
     piece of the tail, often accompanied by a bent  
     tail  
 Detached head and galea capitis  
 Bent tails and bent midpieces: present in sperm cells  
 with and without distal droplets.

**Miscellaneous abnormalities:** Unusual numbers of spermatids  
 and spermatocytes.

Classification of human spermatozoal abnormalities has been attempted by David et al. (1988), who classed all abnormalities into 13 categories. Seven related to the head, two to the midpiece, and four to the tail. The categories are as follows: irregular head, microcephalic, macrocephalic, elongated head, thin head, duplicate head, lysis, cytoplasmic remnants, no tail, short tail, bent tail, coiled tail and duplicate tail.

Various classifications have been proposed for the spermiogram in the dog, the first being by Bartlett (1962). Christiansen (1984) conducted a survey of the principal primary and secondary abnormalities of dog sperm (Table 8). Line drawings depicting these abnormalities are shown in Figure 4. Figure 5 depicts the abnormalities according to Burke (1986).

Seager (1986) also divided the defects of dog sperm into primary and secondary categories, and his classification is shown in Table 9.

The classification used in the present study (Oettlé & Soley, 1988) is based on Blom's classification for the bull spermiogram (1972) and is slightly different from previous classifications for dog sperm. It provides a systematic morphological description of the abnormality based on

Figure 4. Examples of primary and secondary sperm abnormalities. (a) Macrocephalus; (b) microcephalus; (c) double heads; (d) pointed heads; (e) eccentric insertion; (f) double midpiece; (g) double tail; (h) free heads; (i) swollen acrosomes; (j) detaching acrosomes; (k) mid-cytoplasmic droplets; (l) distal cytoplasmic droplets; (m) coiled tail; (n) looped tail. (Redrawn from Christiansen, 1984).

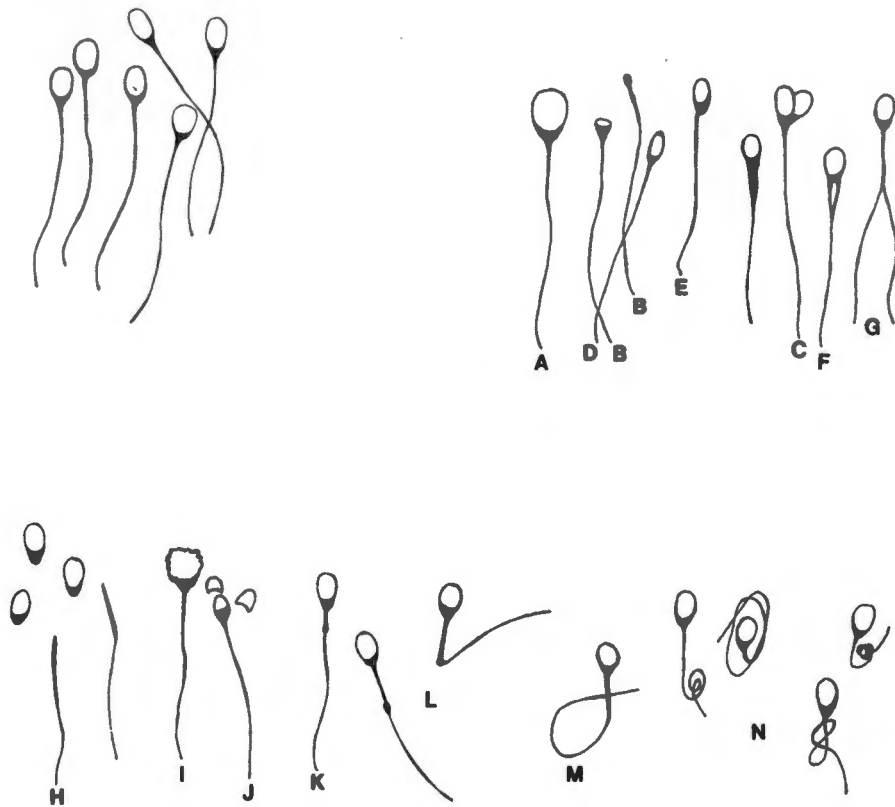


Figure 4: Examples of primary and secondary sperm abnormalities. (a) Macrocephalus; (b) microcephalus; (c) double heads; (d) pointed head; (e) eccentric insertion; (f) double midpiece; (g) double tail; (h) free heads; (i) swollen acrosomes; (j) detaching acrosome; (k) mid-cytoplasmic droplet; (l) distal cytoplasmic droplets; (m) coiled tail; (n) looped tails. (Redrawn from Christiansen, 1984.)

Figure 5. Dog sperm morphology according to Burke (1986)



Normal Sperm

Primary Abnormalities



Pyriform Head



Tapered Head



Slender Head



Midget Head



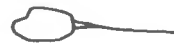Giant Head



Round Head



Flame Head



Deformed Head



Double Head



Double Tail  
Midpiece



Double  
Midpiece



Double Tail



Abaxial  
Midpiece



Swollen  
Midpiece



Rudimentary  
Midpiece



Proximal  
Droplet

Secondary Abnormalities



Distal Droplet



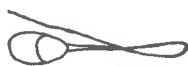Detached Head



Bent Tail



Detached Galea  
Capitis



Reverse Tail



Distal Coiled  
Tail

Figure 5: Dog sperm morphology according to Burke (1986).

comparison of light and electron microscopical findings, with the defect categories being further divided into major and minor defects. One drawback to this system, like the others mentioned above, is the inability to identify multiple defects. However, as noted by Blom (1972), the predominance of one major defect is always of greater significance than an even spread of a variety of abnormalities. Thus, in order to ensure correct interpretation, when a sperm was seen to possess more than one abnormality, it was lodged under the most important abnormality, or the more predominant abnormality if the abnormalities were of equal significance. This tends to mask certain abnormalities, and, for example, may account for the finding of a lack of difference between the frequency of acrosomal abnormalities in the normal and abnormal categories (see section 3.9.3).

## 5.2. Evaluation of results.

### 5.2.1. Sperm morphology

#### 5.2.1.1. Normal morphology

The morphology of the normal sperm in the dogs studied is essentially in agreement with the findings of Nicander & Bane (1966). Spermac stain highlights the acrosome, and the semi-quantitative nature of this stain allows easy identification of the equatorial segment of the acrosome. This segment is a distinctive feature of dog sperm stained with this stain, and is visible quite clearly even under medium power light microscopy. The equatorial segment has the shape of an ellipse, and is much reduced at the lateral edges of the sperm. This is in contrast to the findings of Nicander and Bane (1966) who state that the height of the equatorial segment is nearly the same across the width of the sperm head, and that the anterior margin is not markedly arched.

The acrosome conforms to the contour of the nucleus, and thus nuclear abnormalities tend to impose abnormal features on the acrosome (Hancock, 1971). In the rabbit, however, it has been suggested that the acrosome governs the shape of the nucleus (Ploen, 1973). Due to the intimacy of contact between the two organelles, the author suspects that

abnormalities of either may induce abnormal features in the other. In some instances it appears as if the acrosome has pushed into the nucleus, forming cysts; in other instances grossly deformed nuclear morphology is accompanied by distorted acrosomes.

The mitochondrial sheath of the midpiece varies in length between species; in man it is short, and in rodents long (Pedersen, 1974). In the dogs studied it was found to be of intermediate length, approximately 1.5 times the length of the head.

#### **5.2.1.2. Acrosomal abnormalities**

##### **a. Major acrosomal defects**

Acrosome lipping and cysts have been well documented as causes of sterility in the bull (Blom, 1972; Coubrough & Soley, 1977) and ram (Savage, 1984). In the dogs studied, acrosome lipping and cysts were commonly encountered, but were often associated with other head abnormalities. They occurred alone in much lower frequency. The thickness of the acrosome is approximately doubled in the region of the lip: Since Spermac stain gives a semi-quantitative estimation of acrosomal content, this explains why the defect is visible under the light microscope as an area of increased staining intensity. The lifting of the plasma membrane that was a

consistent feature below the region of the lip in the dogs studied has also been reported in the bull (Coubrough & Soley, 1977). In man acrosomal abnormalities have been recorded (Oettlé & Wiswedel, 1989a), but their influence on fertility is uncertain. This might be due to their passing unnoticed as a result of poor acrosomal differentiation afforded by the commonly employed Papanicolou stain (Bartoov et al., 1980). Acrosome lipping has also been noted in the boar, and the defect was associated with subfertility (53 % conception rate) when present in 40 % of the sperm (Andersen, 1974).

The structure of the apical acrosomal cysts described in this study of the dog appears to be similar to the "knobbed sperm" defect in bulls, where it has been known to occur in 95-100 percent of sperm; in the latter instance it acts as a "sterilizing defect" (Blom, 1972). In the ram it has been found in up to 78 percent of sperm, and it likewise has a sterilizing effect (Savage, 1984). In none of the dogs studied did the defect reach the high proportions noted above. In man, both primary and secondary acrosomal defects have been shown to escape selection due to the filtering imposed by the "swim-up" technique, and thus these abnormal sperm are in a position to compete with normal sperm for fertilization (Oettlé & Wiswedel, 1989a). Sperm with acrosomal abnormalities might well be able to penetrate the

zona pellucida and thereby induce the zona reaction preventing polyspermy, but unable themselves to fertilize the ovum (Oettlé & Wiswedel, 1989a, b).

#### **b. Minor acrosomal defects**

Ageing of dog sperm, either as a result of extended epididymal transit time or from prolonged post-ejaculation incubation of semen, was noted initially to induce a swelling and then loss of the apical portion of the acrosome. Ultimately this was followed by loss of the equatorial region. The equatorial region appeared to be relatively resistant to damage, and severely damaged acrosomes were often noted with normal, intact equatorial regions. This could be seen quite clearly under both light and electron microscopes. Demembration with complete loss of the acrosome has been described in man as a result of epididymal malfunction. In these patients normal sperm were shown to enter the epididymis, but severely aged and dead sperm were ejaculated. In such cases an increase in the frequency of ejaculation resulted in a shortened epididymal transit time with an associated three- to sevenfold increase in motile sperm (Wilton et al., 1988).

The acrosome reaction is a physiological alteration in the acrosome, whereas techniques for processing semen (for example cryopreservation) induce pathological changes in

this structure. It was not always possible by means of light microscopy to differentiate between physiological and pathological reactions in the dogs studied. However, since the acrosome reaction normally takes place only on contact with the zona pellucida (Bedford, 1970), unless the reaction had been intentionally induced in vitro, such changes were regarded as minor abnormalities. The acrosome reaction of the dogs studied appears to follow the same basic pattern as that of rodents, farm animals and man (Bedford, 1970; Nagae et al., 1986). In the dog and fox, the changes induced by dilution, cooling, freezing and thawing have been described (Oettlé, 1986 b; Zalewski & Andersen-Berg, 1983). These are similar to the changes induced by processing bull, ram, boar and human sperm (Aalseth & Saacke, 1985; Watson, 1975; Boender, 1968; Oettlé & Soley, 1986b).

#### **5.2.1.3. Head abnormalities**

##### **a. Major head defects**

In the dogs studied, macrocephalic sperm were most often associated with other defects, usually with double tails and abnormal acrosomes. Bizarre forms of macrocephalic sperm were among the severe multiple sperm abnormalities found in a bulldog that had suffered from a derangement of testicular thermoregulation (Oettlé & Soley, 1986a). Despite the grossly abnormal appearance of a high percentage of the

sperm, the dog recovered over a period of 5 months, and regained full fertility. In the bull, macrocephalic sperm are usually diploid (Bertschinger, 1975). In the bull and ram, ridged sperm are also often diploid and are formed as a result of defective and incomplete separation of spermatids during spermatogenesis. Their ultrastructure (Bertschinger, 1975; Blom, 1980; Wild et al., 1978) is essentially the same as the ridged sperm described in the dogs studied here. As might be expected from Bertschinger's study of diploid sperm, double tails were often encountered in the diploid sperm seen in this study. These double tails were sometimes seen to share common central mitochondria, but on other occasions the two tails had separate mitochondrial sheaths. Multiple ridges with corresponding bizarre shapes were occasionally noted.

Almost without exception, the microcephalic sperm encountered in the dogs' semen were grossly abnormal, and intensely pink stained with Spermac stain. In man, a severe form of microcephalic sperm, called "pin-head" sperm, occurs; these are often highly motile (Chemes et al. 1987).

The diadem defect has been described in the bull (Coulter, 1976; Heath & Ott, 1982), boar, cheetah, (Soley & Coubrough, 1981), dog (Oettlé & Soley, 1985; 1986 a) and rabbit (Ploen, 1973). In the diadem defect the vacuoles are usually found in the equatorial region of the head, where they often form

a ring, hence the name diadem, or crown. It is an unusual defect in that it is a major defect which is usually transient in nature, and thus carries a good prognosis (Heath & Ott, 1982; Oettlé & Soley, 1985; 1986 a). Many causes have been implicated in its production, notably frostbite, increased testicular temperature, stress, and the administration of corticosteroids (Coulter, 1976). There also has been one unconfirmed report of virus-like particles associated with this defect (Foster et al., 1980). The presence of the defect indicates that the animal has undergone some form of transient testicular degeneration, and recovery should occur within a few months (Heath & Ott, 1982; Oettlé & Soley, 1986a; Ploen, 1973).

Gross nuclear invaginations by acrosomal material was noted in semen of a small percentage of the dogs studied. These were clearly visible under the light microscope as large green-stained areas displacing the normal pink nuclear material, and were typically irregular in appearance and distribution. Ultrastructurally, these nuclear cysts did not correspond to the SME-defect as typically described in the boar. In the SME-defect, the cyst consists of acrosomal material invaginated into the nucleus, and is visible under the light microscope as a relatively uniform central circular cyst (Blom & Birch-Andersen, 1975). In man, nuclear cysts are commonly found in the ejaculate (Holstein, 1975).

The tapered head defect typical of human sperm (Anniballo, 1979) was not noted in the dogs studied. This defect appears to be unique to man, the closest approximation to it in the dog being the pyriform head defect. The latter has been described in the bull (Blom, 1972), and the defect in the dog appears to be similar.

#### **b. Minor head defects**

Loose heads are associated with ageing of sperm, and it is thus not surprising that loose heads often showed degenerating or lost acrosomes. In these instances, repeat collections of semen at short time intervals caused a reduction in the number of loose heads and an improvement in acrosomal integrity. However, in the bull and in man a major defect associated with loose heads has been reported (Blom, 1972; Hancock, 1971; Aughey & Orr, 1978; Chemes et al., 1987). In the latter instances, there was no reduction in the number of loose heads on repeated semen collections, and the tails were often motile. The defect may be caused by a failure of implantation of the flagellum as a whole or the dissociation of the centrioles during spermiogenesis (Holstein et al., 1986). On very rare occasions separated motile tails were noted in the dogs studied.

Nuclear decondensation and nuclear degeneration were noted in the semen of dogs with defective testicular thermoregulation and in dogs suffering from heat stress to the scrotal contents; it also occurred in aged sperm. This combination has been noted in the rabbit (Ploen, 1973) and man (Pedersen, 1969; Bartoov et al., 1980). Nuclear decondensation is also one of the features of the abnormal sperm found in men suffering from inflammatory bowel disease (Hrudka & Singh, 1984). "Granular chromatin", a form of defective nuclear condensation, caused sterility in bulls when found in 70 % of sperm ejaculated (McCosker, 1969).

A "pouch-like" defect has been described in the basal plate region of cheetah sperm. The defect consisted of an invagination of homogeneous material seemingly derived from the neck region of the sperm. The defect is thought to form as a result of abnormal behaviour of the nuclear envelope during spermiogenesis, but it was not reported whether the nuclear pouching resulted from external pressure or from factors within the nucleus (Soley & Coubrough, 1981). In the dogs studied, the invagination into the basal plate region was filled with membranous material which seemed to be derived from the neck region. The vesicular material seen below the head-base (see EM Plate 12 B) is similar to that described by Bartoov et al. (1980) in man as being "empty" mitochondria. However, similar structures seen next to normal mitochondria are described in the same article by

these authors as remnants of spermatid cytoplasm. Their irregular shape and large size is indicative of cytoplasmic remnants rather than mitochondria. In the dog, such cytoplasmic remnants were occasionally visible next to normal mitochondria.

The significance of the curved base plates noted in the dogs' semen is not known. It was only sporadically seen, and is thus probably an incidental finding. Curved base plates are a normal feature of guinea-pig sperm (Nicander & Bane, 1966).

#### **5.2.1.4. Midpiece abnormalities**

##### **a. Major midpiece defects**

Retained cytoplasmic droplets were associated with immature sperm, produced either as a result of sexual hyperactivity or in semen from immature animals. Mature dogs which showed high percentages of retained cytoplasmic droplets were rested adequately before retesting. In these instances the semen showed a dramatic reduction in the number of sperm with retained cytoplasmic droplets.

The latter is in contrast to dogs which showed increased cytoplasmic droplets in their sperm as a result of epididymal malfunction; in such cases sexual abstinence did

not produce a reduction in the frequency of the defect. In this respect, the dog appears to be similar to the bull and sheep, but different from man, where retained cytoplasmic droplets of less than half the size of the head are considered normal (Bartoov et al., 1980; Hancock, 1971; Takeishi et al., 1975).

Midpiece abnormalities often involved defects of the axoneme, which partially reduced or entirely eliminated motility. Midpiece kinking was found to be the predominant abnormality in sperm from a sterile Maltese poodle; in this case only 8 percent of sperm in the ejaculate were normal (Oettlé & Soley, 1985a). This defect has not been described in other species.

In most species midpiece abnormalities are frequently associated with infertility (Blom & Birch-Andersen, 1966; Oettlé & Soley, 1985a; Ross et al., 1971; Williamson et al., 1984). Breakage or interruption of the mitochondrial sheath has been reported in the bull (Blom, 1959) and stallion (Bielanski et al., 1982). In the dogs studied, abnormalities of the midpiece were often associated with retained cytoplasmic droplets. This also has been noted by Plummer et al. (1987) and Oettlé & Soley (1985a). In man, a total absence of the mitochondrial sheath has been described (Holstein, 1975). This was never encountered in the dogs studied.

The psuedo-droplet defect was first reported in the dog in a greyhound by Aughey & Renton (1971). In the dogs studied, sperm showing the pseudodroplet defect were occasionally noted, but never occurred as the predominant defect. The ultrastructure of defect was essentially the same as that described in the bull (Blom, 1972).

#### **b. Minor midpiece defects**

Distal cytoplasmic droplets, associated with a milder degree of sperm immaturity, were occasionally noted. Their frequency was markedly reduced in subsequent ejaculates after the dog was sexually rested.

#### **5.2.1.5. Tail abnormalities**

##### **a. Major tail defects**

Sperm with double tails have been reported in a subfertile greyhound (Aughey & Renton, 1971). In the dogs studied here, they occurred regularly at low frequency in many samples, but never at a sufficient level to exert a noticeable influence on fertility. By far the most common tail abnormality was the "Dag" defect, which often was overall the predominant defect in the semen. The "Dag" defect was first described in a bull of that name, where it was associated with epididymal malfunction. Sperm entering the

epididymis were found to have straight tails, while those in the cauda epididymis and vas deferens had their tails bent and coiled around the protoplasmic droplet (Swanson & Boyd, 1962). A number of factors have been implicated as causes of the "Dag" defect in the bull, notably high dietary zinc levels, experimental cryptorchidism, or, in the case of Danish Jersey bulls, an autosomal recessive factor (Koefoed-Johnson et al., 1980). Subsequent studies have cast doubt on the accuracy of the hereditary hypothesis, and epididymal malfunction is now the generally accepted cause of the "Dag" defect (Coubrough & Soley, 1982). The defect has been described in the bull, cheetah, dog, horse, man, monkey, rabbit and ram. In all of these species, as well as in the dogs in this study, the ultrastructure of the defect is similar (Coubrough & Soley, 1981). In a bulldog which had suffered from deranged testicular thermoregulation, numerous sperm with "Dag" defects were noted. These abnormalities gradually reduced as the dog returned to normal over a period of 5 months (Oettlé & Soley, 1986a). Thus, in this case, when the cause of the epididymal derangement had been removed, the sperm morphology returned to normal.

#### **b. Minor tail defects**

When dogs are kept under tropical conditions, minor tail defects such as looped and bent tails, as well as bent midpieces and detached heads were reported to comprise the

majority of abnormalities encountered in their semen (Wong & Dhaliwal, 1985). Despite the fact that summer temperatures at Onderstepoort where this study was conducted are high (usually between 30 and 40 °C, occasionally over 40 °C), it was not possible to demonstrate a seasonal variation in sperm abnormalities in the dogs studied.

#### 5.2.1.6. Other abnormalities

Sperm agglutination was occasionally seen in the dogs studied, and was normally associated with a leucospermia. This condition has been reported in the United States of America in dogs with Brucella canis infection; in these cases, there is production of antibodies to sperm with a high affinity for the acrosome (Christiansen, 1984; George et al., 1979; Serikawa et al., 1984). As yet, this disease has not been reported in South Africa. Immunological causes of infertility in man are associated with sperm agglutination. The "Sperm-cervical mucus-contact test" (see W. H. O., 1987) is one of the tests used to demonstrate immunological infertility in man. No such tests are currently available for the dog but it is reasonable to assume that immunological infertility could occur in the dog and that similar tests might be of benefit in their identification. According to Burke (1986), immunological infertility has not yet been clearly identified as a clinical entity in dogs. In the dogs studied, sperm

agglutination was noted when sperm were incubated in media designed to induce the acrosome reaction (Mahi & Yanagimachi, 1978). After about 10 hours the heads appeared to become sticky and numerous groups of agglutinated sperm were noted. At this stage most of the sperm had undergone the acrosome reaction.

The presence of epithelial cells was taken as an indication of contamination of the sample by preputial secretions. In these cases, although leucocytes were usually present, they generally did not indicate a genital infection. When contamination of the semen by preputial secretions was suspected, the prepuce was rinsed with physiological saline prior to collection of semen. This resulted in a dramatic reduction in both the leucocyte and epithelial cell counts.

Literature describing specific sperm abnormalities are scarce for the dog, and thus much comparison has of necessity been made with other species, predominantly the bull and man. These parallels are not unjustified, since many seemingly identical defects have been described in a variety of species, and it has been suggested by Hancock (1971) that they might share a common mechanism of development. However, there are certain defects that appear to be typical of a species; these may occur in other species only in low frequencies or not at all.

The abnormalities that have been reported in other species but were not observed in the dogs studied are as follows. Round headed sperm, round headed sperm without acrosomes, and dysplasia of the fibrous sheath have been recorded as causes of infertility in man (Anton-Lamprecht et al., 1976; Chemes et al., 1987; Lalonde et al., 1988) . The absence of dynein arms in human patients suffering from Kartagener's syndrome results in reduction of or lack of sperm motility (Coetzee et al., 1985). Nuclear vacuoles are regarded as a normal feature of human sperm (Bartoov et al., 1980). The "corkscrew" defect appears to be unique to the bull, and the SME-defect to the boar (Blom, 1972; Blom & Birch-Andersen, 1975).

#### **5.2.2. Semen quality and fertility.**

The ultimate test for the quality of semen is the evaluation of fertility data from controlled breeding trials, but this is a lengthy and involved process. The long cycle interval of the bitch (5 to 9 months) (Christie & Bell, 1971) makes the collection of sufficient results from fertility trials for significant statistical analysis an even more protracted and costly affair than in man and in the other domestic species.

Freshman et al. (1988) noted that there were no reports on the statistical analysis of the relationship between fertility and the percentage of abnormal spermatozoa in canine semen. The present study appears to be the first of its kind in this regard. However, various suggestions regarding the influence of sperm abnormalities on fertility have from time to time been offered in the literature; Rosenthal (1983) suggested that total head and midpiece abnormalities in excess of 40 percent of sperm in an ejaculate is associated with infertility, while 20 percent head, acrosome and retained cytoplasmic droplets may be associated with decreased conception rates. According to Seager (1986), the fertile dog should not have more than 20 to 30 % abnormal forms present in the ejaculate. Krause (1965) reported on the fertility of 7 dogs with abnormal spermograms. A total of 33 bitches were served with these males; only occasional litters were produced when the percentage of sperm showing normal morphology was less than 57 percent.

#### **5.2.2.1. Division of the dogs into normal and subnormal groups on the basis of fertility.**

Controlled breeding trials incorporating large numbers of dogs and bitches would be ideal to define the effect of sperm morphology on fertility. However, the retrospective data that has been collected in this study can provide a

provisional answer to this question until such time as trials can be undertaken. By using of the strength of association (Phi coefficients) of the Chi-squared values, the dogs were divided into normal and subnormal groups taking 60 percent normal morphology as the cut-off point between the two groups. As might be expected, where cases of suspected female infertility were excluded, the strength of association was greater. This method of relating morphology to fertility is a novel approach.

**a. Differences between the normal and subnormal groups.**

Although the number of bitches tested was low ( $n=38$ ), there was a marked difference in fertility between the two groups (61 versus 13 percent fertility for the normal and subnormal groups respectively). Thus the separation of the normal and subnormal groups at the level of 60 percent normal morphology appears to be realistic. Interestingly, Aughey & Renton (1971) described a greyhound which had 59 percent normal sperm; the dog achieved one pregnancy in three fertile bitches that were mated.

It is evident from the marked differences in the standard deviations between the normal and subnormal groups, that normal dogs display relatively uniform spermograms, but that when there is a disturbance to spermatogenic homeostasis, there is a large increase in variation in sperm

morphology. This indicates that trauma to spermatogenesis produces quite a range in sperm abnormalities in an ejaculate, but that conditions that induce pathognomonically unique abnormalities in sperm are uncommon.

There was no significant difference between the ages of the normal and subnormal groups. This indicates that subfertility can affect dogs of any age from puberty to reproductive senescence. From a practical point of view, the best means of ensuring subsequent fertility of valuable sires would thus be the cryopreservation and storage of sufficient quantities of semen early in the sire's career, as soon as he is proved fertile.

Abnormalities most commonly encountered were head, tail and retained cytoplasmic droplets. Less commonly encountered abnormalities were abaxial attachment of the midpiece, and other primary midpiece abnormalities. No statistically significant difference was noted between the normal and subnormal groups for acrosomal abnormalities. This abnormality is a major defect, and the reason for this apparent lack of difference between the two groups is obscure. It is possibly as a result of acrosomal defects commonly occurring with other head defects. A false low figure for acrosomal defects would thus be obtained, since due to the method of analysis these multiple defects would have been lodged under the "head defect" category.

The probability of conception per given mating has been discussed by Freshman et al. (1988). They calculate the probability of conception from a given mating as the product of the inherent fertility of both male and female, i.e. 0.9 (fertile male) X 0.9 (fertile female) = 0.81. However, if the male has a low fertility (e.g. 0.25), the probability drops dramatically to 0.23 (0.25 X 0.9 = 0.23). In practice, however, they found better conception rates were obtained; a 95 percent pregnancy rate was reported in 211 fertile bitches bred once only to fertile males.

Occasional reports of variation in semen quality in dogs have been noted. Heywood & Sortwell (1971) reported monthly variations in sperm characteristics in 6 dogs over a period of 7 months. They found motility to range from 51 to 90 percent, and the percentage of abnormal sperm from 6 to 30 percent. They attributed the large range in motility to the use of the artificial vagina for the collection of semen (see Boucher et al. 1958). A similar degree of variation was not encountered in the dogs studied here, possibly due to more rigorously controlled collection and examination techniques. In any event, this highlights the need to repeat examinations when samples of poor quality are obtained.

There has been a single report of wide variation in sperm abnormalities in 4 fertile dogs sampled 14 times during a seven week period. However, some of the defects contributing to the variability were thought to arise as artifacts during collection of the semen or preparation of the smears (Freshman et al., 1988).

### 5.3. General discussion

#### 5.3.1. Other methods of assessment of sperm function.

Biochemical lesions may render sperm incapable of fertilization without the sperm necessarily showing any concurrent structural defects (Aitken et al., 1982). Methods to assess sperm function that are not directly related to sperm morphology have been developed in man and may in the future find application in the dog. Examples of these methods are the hamster egg penetration test (see W.H.O., 1987), the response of sperm to calcium ionophores (Aitken et al., 1984), and the measurement of the production of reactive oxygen species (Aitken and Clarkson, 1987).

### 5.3.2. Causes of sperm defects.

#### 5.3.2.1. Physical and chemical causes of sperm defects

High ambient temperatures may reduce semen quality in dogs (Larsen, 1980), but dogs adapted to a tropical environment do not show an increase in sperm abnormalities when compared to dogs in temperate regions (Wong & Dhaliwal, 1985). This is in line with the present findings where the dogs had been bred in the Onderstepoort area, and were thus adapted to hot summer temperatures. No seasonal variation in sperm morphology was noted.

Thermoregulation of the testes is important in maintaining normal sperm production, and when this is disturbed, a variety of aberrations may occur, depending on the degree and duration of the thermal stress (Mann & Lutwak-Mann, 1981). In the rabbit, defective testicular thermoregulation induced by experimental cryptorchidism results in the production of a variety of sperm abnormalities. The most pronounced changes were nuclear decondensation, invaginations of the acrosome into the nucleus, acrosomal asymmetry and discontinuity, local dilatations of the sub-acrosomal region, and irregular, swollen and disintegrating fibrous sheaths in the tail (Ploen, 1973). Many of the sperm abnormalities described by Ploen (1973) were seen in a dog with defective testicular thermoregulation induced by a

severe scrotal oedema (Oettlé & Soley, 1986a). In this case, the spermiogram returned to normal after about five months, and the dog successfully sired litters thereafter. However, testicular degeneration that may be caused by insect bites and stings to the scrotum may require up to a year before recovery is evident (Bane, 1970). Experimental cryptorchidism in dogs resulted in a loss of sperm motility and eventual loss of sperm production but the warming of scrotal testes to body temperature for only 10 days was insufficient to cause irreversible damage to the testes (Larsen, 1980).

Collection of semen from dogs more than once every second day caused a reduction in sperm output, and an increase in retained cytoplasmic droplets (Boucher *et al.*, 1958). Total azoospermia resulted in one dog from which semen was collected four times weekly for four months; the dog made a subsequent recovery after three months of sexual rest (Evans & Renton, 1973). In no instances were the dogs in this trial subjected to this kind of spermatogenic stress. For purposes of artificial insemination it was occasionally necessary to collect semen daily for a few days, but epididymal reserves were always sufficient to cope with the required short term increase in sperm output. In cases where the presence of a high percentage of retained cytoplasmic droplets suggested possible sexual hyperactivity, the dog was retested after a period of sexual rest, usually about one month later.

The nuclear crest defect (ridged sperm) in the ram has been experimentally induced by ethylene dibromide toxicity (Eljack & Hrudka, 1979). In 1978, a high degree of atmospheric pollution from nuclear fallout was implicated in the production of the corkscrew defect in Danish bulls (Blom, 1978). No chemical causes of sperm defects were noted in the dogs in the present study.

#### **5.3.2.2. Infection as a cause of sperm defects**

An orchitis usually results in a severe disturbance of spermatogenesis, and relapses are common in spite of intensive treatment (Burke, 1986). A schnauzer in this trial had a unilateral orchitis and epididymitis in the left testis. The dog recovered although the affected testis underwent progressive atrophy. Despite this, the right testis was normal on palpation, and the semen collected from the dog gave a normal spermiogram. A dachshund that had a unilateral testicular abscess had a severely abnormal spermiogram, with only 17 percent normal sperm present. The prostatitis that was found in a Scottish terrier did not influence the sperm morphology.

#### 5.3.2.3. Hereditary causes of sperm defects

Hereditary causes have been implicated in a number of sperm defects. These include the "Dag" defect, the pseudodroplet defect, the "decapitated sperm" defect in bulls, and the knobbed acrosome defect in bulls and boars (Ross et al., 1973). Most of the evidence for hereditary involvement stems from related animals being similarly affected. Before it can be conclusively shown that a defect does indeed have a hereditary origin, extensive breeding trials are necessary. This has been done in mice, where clear evidence has been presented that certain defects are hereditary (Ross et al., 1973). In dogs, inbreeding causes detrimental effects on reproductive parameters, including a reduction in the quality of the ejaculate and in testicular volume (Wildt et al., 1982). The "decapitated sperm" defect seen in Guernsey bulls has been shown to have a genetic origin. The defect is caused by a recessive gene, and is associated with abnormal migration of the cytoplasmic droplet; sperm in the proximal part of the epididymis are affected (Blom & Birch-Andersen, 1966).

#### **5.3.2.4. Iatrogenic causes of sperm defects**

##### **a. Effect of processing for cryopreservation on sperm morphology.**

In all species studied to date, the organelle most sensitive to damage by cryopreservation is the acrosome. Secondary acrosomal damage as described for the dogs in this trial may be induced by dilution, cooling and cryopreservation of semen. The degree of damage may be quantified by the assessment of acrosomal integrity. In the bull and man, the percentage of sperm that survive cryopreservation with normal, intact acrosomes has been found to correlate well with the fertilizing ability of that sample (Foote, 1975; Mahadevan & Trounson, 1984). However, the percentage of normal acrosomes has a poor correlation with motility in the ram (Watson, 1975), fox (Zalewski & Andersen Berg, 1983) and dog (Oettlé, 1986 b). Acrosome damage induced by freezing fox semen (Zalewski & Andersen-Berg, 1983) is essentially the same as that seen in the dog (Oettlé, 1986 b).

#### **5.3.2.5. Idiopathic and other causes of sperm defects**

Human semen is characterized by the high percentage of abnormal sperm that occur in normal patients. Moreover, in man, sperm samples with a high proportion of a single abnormality are extremely uncommon (Aughey & Orr, 1978;

Eltes et al., 1982). The cut-off point between normal and abnormal human semen as measured by the percentage of normal sperm varies between laboratories. The standard set by the World Health Organization is 50 percent (W.H.O., 1987). Lack of uniformity of analysis between workers in different laboratories has led to reports on an unfavourable relationship between sperm morphology and fertilizing ability (Zaini et al., 1985; Sokol & Sparkes, 1987; Hunter & Kretzer, 1986; Dadoune, 1988). However, when strict criteria are applied, sperm morphology does appear to correlate well with fertilizing ability (Kruger et al., 1988). The latter workers found that greater than 14 percent normal sperm in the semen was compatible with fertility, and was thus considered by them to be normal.

Bulls that were kept under stressful conditions showed a significant drop in semen quality, including reduced sperm motility, a rise in the number of dead sperm, an increase in retained cytoplasmic droplets and in acrosomal damage. The nature of these changes indicated that damage was occurring in the epididymis; libido was also adversely affected (Coubrough, 1985). Testicular atrophy and a reduction in sperm output was found in 30 percent of dogs suffering from Cushings disease, while a reduced libido and decreased sperm output was noted in hypothyroid dogs (Christiansen, 1984).

### 5.3.3. Assessment of dogs for genital soundness

Fertility data is often not available, and the evaluation of a dog is thus usually based on an assessment of his genital soundness; this concept encompasses the ability of the animal to produce a normal semen sample, and to perform normal copulatory behaviour. In assessing an animal, the concept of optimum fertility as opposed to the ability to fertilize should always be borne in mind. While a single offspring may well be sufficient to satisfy an owner, one should nevertheless aim for optimum fertility. Bearing in mind the possible heritability of some defects, progeny from a particular sire might even be undesirable.

A prognosis is often difficult to give on a single consultation, since the examination gives only the current status of the animal. As has been shown in this study, the spermograms of a dog may vary quite markedly over a period of time. Sperm in an ejaculate may be at varying stages of their life histories (Cohen, 1971), and this should be taken into account when assessing the potential fertility of a sire. As shown earlier, this is particularly important when confronted with a spermogram indicating sperm immaturity, aging, or induced morphological changes. The potential of the dog testis to recover should not be underestimated (Evans & Renton, 1973; Oettlé & Soley, 1986a), and retesting subnormal dogs at suitable intervals is essential. The

frequency of subsequent examinations will vary, depending on the spermiogram and the type, cause and duration of the condition that caused the disturbance to spermatogenesis. A general observation that emerges from the assessment of the dogs in this study is that if after 3 months there is still a poor spermiogram, the prognosis is guarded. If there is no improvement after 6 months, the prognosis may be regarded as poor. If there is still no improvement after 12 months, the prognosis is virtually hopeless. The final assessment of genital soundness is thus a synthesis of the information obtained from all the tests performed into a comprehensive picture of the potential fertility of the dog.

**APPENDIX 1****Staining methods****a. Procedure for staining with Spermac stain:**

A thin smear is needed in order to ensure adequate visualization of each sperm.

1. Place a drop of semen (about 0.06 ml) on a clean glass slide. Draw out the smear by means of another slide held at approximately 30° to the first slide. Slides with a polished glass edge aid in the production of uniform smears.
2. Air dry the smear for a maximum of 5 minutes. Do not allow the smear to dry excessively.
3. As soon as the smear is sufficiently dry, fix it for 5 minutes or longer. Longer fixation is not detrimental to staining and for practical reasons a number of smears may be accumulated in the fixative and stained in a batch. Overnight fixation should be regarded as the maximum for smears.
4. Wash the smear by dipping gently 5 to 6 times in tap water.
5. Stain for 1 minute in Stain A.
6. Wash as above in tap water.
7. Treat for 1 minute with Solution B.

8. Wash as above in tap water.
9. Stain for 1 minute in Stain C.
10. Wash as above in tap water, and allow the smear to drip dry.

Examine unmounted under oil immersion.

Staining characteristics: Acrosome green, equatorial region of the acrosome pale green, nuclear material red, midpiece and tail green. Other cells stain uniformly dark green.

**b. Procedure for staining with Diff-Quik<sup>R</sup> stain (Kruger et al, 1988) :**

A thick smear is required, in order to increase the concentration the leucocytes and other cells present.

1. This is achieved by holding the "smearing" slide at an angle of 60° to the first slide, and by drawing out the smear rapidly, leaving behind a thick smear.
2. Air dry the smear.
3. Fix for 10 seconds in the triarylmethane methanol fixative supplied.
4. Drain off the excess stain onto tissue paper, and place directly in the next stain.
5. Stain for 10 seconds by dipping 10 times in Solution 1 (buffered 0.1 % xanthene containing sodium azide). The dipping is important to ensure uniform staining when moving from the methanol-based fixative to the aqueous stain.

6. Drain off the excess stain as above.
7. Stain for 10 seconds by dipping 10 times in Solution 2 (a buffered aqueous mixture of 0.0625 % azure A and 0.0625 % methylene blue)
8. Rinse the smear in tap water.
9. Allow to air dry.

Examine mounted in DPX or Canada Balsam, or unmounted, under oil immersion.

Staining characteristics: Nuclei of leucocytes, epithelial cells and germ cells stain dark purple; cytoplasm stains pale pink/purple. Sperm stain very faintly purple.

Discard the stains when cross contamination of Solution 2 by Solution 1 prevents adequate differentiation, usually after staining about 100 slides.

c. The eosin/nigrosin technique (Hackett & Macpherson, 1965)

1. Mix a drop of semen with a drop of warmed stain (2 % eosin and 10 % nigrosin in 3 % sodium citrate) on a warm glass slide. Keep all reagents and glassware at about 32 °C.
2. Transfer a drop of the mixture to a second slide, and make a thin smear with a third slide.
3. Dry the smear over a flame.

Examine mounted in DPX or Canada Balsam under 400 X magnification.

Staining characteristics: Sperm that were alive at the time of preparation do not take up the stain, and stand out as transparent against the black background. Dead sperm take up stain and stain pink.

**APPENDIX 2: Processing of sperm for electron microscopy**

Samples were fixed in 4 % glutaraldehyde (Sigma G5882, specially pure electron microscopic grade) in 0.2 M phosphate buffer (pH 6.8), and held overnight at 4 °C. Gentle centrifugation at 500 g for 5 minutes followed by resuspension was employed for the following steps.

The sperm were washed once with 0.1 M sodium cacodylate buffer (pH 7.2), post fixed in similarly buffered 1 % osmium tetroxide for one hour at room temperature, and given two final buffer washes. After the last centrifugation, most of the supernatant was carefully withdrawn, leaving about 0.5 ml containing the sediment and some supernatant. These were mixed, and the concentrated sperm suspension drawn by capillary action into microhaematocrit tubes. The tubes were sealed and centrifuged to form a firm pellet. The pellets were removed from the tubes using a glass ampoule saw, and dehydrated through a graded ethanol series (25, 50, 75, 96, 100, 100, 100 %) for 10 minutes in each solution. Thereafter they were cleared by two 10 minute exposures to propylene oxide and embedded in Polarbed 812 epoxy resin which had been mixed 1:1 with propylene oxide to aid penetration of the resin into the tissue. The samples were left overnight in open jars and the following morning placed in freshly

prepared resin and mounted in blocks. Blocks were cured at 60 °C for 48 hours (Coubrough & Soley, 1979). All reagents were analytical grade, from BDH or Sigma.

Gold sections were cut on a Reichert OmU3 ultramicrotome with glass or diamond knives, and collected onto 300 mesh copper grids. Sections were stained for 5 minutes with a saturated aqueous solution of uranyl acetate, and washed by careful flooding with double distilled, deionized water; they were then stained for 5 minutes in Reynolds lead citrate, and washed again (Glauert, 1982; Weakley, 1972). The sections were viewed in a Philips 301 transmission electron microscope operated at 80 kV.

#### **Solutions:**

All water used was double distilled and deionized.

#### **0.1 M Cacodylate buffer.**

Dissolve 10.7 g sodium cacodylate in 125 ml water, giving a concentration of 0.2 M. Adjust the pH of the solution to 7.2 with 0.2 M sodium hydroxide. Add water up to 250 ml, giving a final concentration of 0.1 M.

**Reynolds lead citrate**

1,33 g Lead nitrate  
1,76 g Sodium citrate  $\cdot 2\text{H}_2\text{O}$   
30 ml water.

Shake in 50 ml volumetric flask and let stand for 30 minutes, with intermittent shaking to ensure complete conversion of lead nitrate to lead citrate. Then add 8 ml of 1 M sodium hydroxide and dilute to 50 ml with water. Mix by inversion.

**Polarbed 812 resin**

50 ml Polarbed 812 resin  
80 ml Dodecyl succinic acid  
10 ml methyl madic anhydride

Mix thoroughly and store at  $-20\text{ }^{\circ}\text{C}$ .

Prior to use, warm to room temperature, and add the accelerator (benzyl dimethyl amine) at a rate of 0.2 ml per 10 ml resin.

**APPENDIX 3: Patient data**

Unless otherwise stated, the subjects were clinically healthy, and genital palpation revealed nothing abnormal. The details of the semen analyses are given in Appendix 4.

1. Schnauzer, aged 15 months. This dog had achieved a pregnancy previously, and thereafter developed an orchitis. The left testis had atrophied and the epididymis was hard. The right testis and epididymis were normal on palpation. Two semen samples were analyzed; both gave normal spermiograms.

2. Bull mastiff, aged 9 years. Because of his age, the owner wanted to store his semen by cryopreservation.

3. Miniature wire-haired dachshund, aged 5 years. This dog had previously been fertile, but 6 months before had developed a testicular abscess. This was treated by hemiorchidectomy. The remaining testis was normal. Subsequently he served a bitch, but this did not result in a litter being born. After the first semen analysis, the owner was requested to bring the dog back for a repeat test, but did not oblige.

4. Bulldog, aged 6 years. The owner complained of a generally reduced fertility in his colony of bulldogs. In

the previous year, 15 bitches had been mated with this dog, but none had produced litters.

5. Bulldog, aged 5 years. This dog had suffered from a scrotal oedema and posthitis which extended to involve the scrotum. This was treated locally, with a good response. (For details see Oettle & Soley, 1986a.)

6. Bulldog, aged 3 years. This dog was presented because an infertility problem was suspected.

7. German shepherd dog, aged 17 months. This dog was presented for a routine examination for genital soundness prior to being used at stud. Despite the initial spermiogram being poor, the dog made a complete recovery, and was successfully used many times at stud.

8. Collie, aged 2.5 years. This dog had served 3 bitches, all of which did not fall pregnant. Genital examination revealed a small penis and bulb. The semen analyses were of reasonable quality, and it was felt that a mechanical problem probably contributed to the infertility.

9. Bulldog, aged 3 years. This dog was presented for a routine examination for genital soundness. He had achieved one previous litter, which was still-born. According to the owner, when he was subsequently mated with other bitches, the dog apparently gave "acceptable" results. The owner was not prepared to divulge further details on numbers of bitches used nor conception rates.

10. Pointer, aged 5 years. This dog was presented for cryo-preservation of semen.

11. Saint Bernard, aged 2 years. The owners requested an artificial insemination (AI). This resulted in a litter of seventeen pups.

12. Great Dane, aged 3 years. This dog was presented for cryo-preservation of semen.

13. Bull terrier, aged 17 months. This dog was presented for a routine examination for genital soundness.

14. Old English sheepdog, aged 6 years. The owners requested an AI. The male had an unknown breeding history. The bitch did not fall pregnant. The owners did not make further attempts to get the bitch pregnant on subsequent oestrus cycles.

15. Pyrenean mountain dog, aged 4 years. This dog was presented for a routine examination for genital soundness.

16. Springer spaniel, aged 7 years. This dog was presented for cryo-preservation of semen. The dog had sired "numerous" litters, but due to his advancing age the owner wanted some semen stored for future use. Genital examination revealed a mildly enlarged prostate.

17. Bulldog, aged 2 years. The dog was presented because an infertility problem was suspected.

18. Irish wolfhound, aged 8 years. This dog was presented for cryo-preservation of semen.

19. Pointer, aged 9 years. This dog was presented for cryo-preservation of semen.

20. Bulldog, aged 2 years. The owner requested an AI. The bitch did not fall pregnant. Subsequently the owners did not try to get the bitch pregnant again.
21. Pekingese, of unknown age. This dog was presented for an AI.
22. Borzoi, aged 2.5 years. This dog was presented for a routine examination for genital soundness and AI. The bitch did not fall pregnant.
23. Newfoundland, of unknown age. This dog was presented for AI.
24. Chow-chow, aged 7 years. This dog was presented for a routine examination for genital soundness and AI. The dog had never served a bitch before. Genital examination revealed a marginally reduced testicular elasticity. The AI did not result in a litter of pups. Due to the aggressive nature of the male which initially necessitated the AI, the owners did not try to use him again for breeding.
25. Boxer, aged 3 years. This dog was presented for AI. The dog had not been used previously at stud. The bitch became pregnant, and produced 8 pups.
26. German shepherd dog, aged 3 years. The dog was presented for an AI.
27. Pekingese, of unknown age. This dog was presented for an AI.
28. Borzoi, aged 4 years. This dog was presented for an AI.
29. Rough collie, aged 2 years. This dog was presented for an AI.

30. Boxer, aged 8 years. This dog was presented for a routine examination for genital soundness.
31. Pekingese, aged 3 years. This dog was presented for an AI.
32. Staffordshire bull terrier, aged 6 years. This dog was presented for an AI.
33. Bull terrier, aged 16 months. This dog was presented for a routine examination for genital soundness.
34. Maltese poodle, aged 1.5 years. This dog had two previous fertile matings. The bitch was unreceptive, and so the owner requested an AI. The bitch became pregnant, and produced two pups.
35. Great Dane, aged 7 years. This dog was presented for a routine examination for genital soundness and AI. The bitch did not fall pregnant. According to the owner, the bitch was suspected of being infertile, as the male had previously and subsequently produced litters of pups.
36. Borzoi, aged 6.5 years. This dog was presented for an AI due to the nervous disposition of the bitch.
37. Maltese poodle, aged 2.5 years. This dog had been used three times on three different bitches, none of which resulted in pups being born (for details see Oettlé & Soley, 1985a).
38. Pointer, aged 2 years. This was an imported dog, presented for cryo-preservation of semen. Artificial insemination of the frozen-thawed semen resulted in a litter of 4 pups.

39. Scottish terrier, aged 6 years. This dog was presented for AI. Clinically the dog had an enlarged prostate. Urinalysis revealed a proteinuria, with numerous prostatic cells. He was treated with 15 mg delmadinone ("Tardak", Coopers, Isando) and Co-trimoxazole ("Bactrim", Roche). There was a good response clinically. Furthermore the bitch became pregnant, and at the same time he successfully sired 4 other litters.

40. Bull terrier, aged 7 years. The dog had previously sired a few litters of pups. The owner had him vaccinated with a live parvovirus vaccine, after which the dog had numerous infertile matings. The owner suspected that the vaccination had induced the infertility. However, the circumstantial evidence that the infertility was associated with the vaccine is tenuous, and the cause of infertility could not be conclusively ascertained.

41. Pomeranian, aged 6 years. This dog was presented for an AI, but the bitch did not fall pregnant. The male was mated to the same bitch on her following oestrus, and 3 pups were born.

42. Dachshund, aged 3.5 years. The owner requested an AI because the male was too large for the female. The bitch had previously produced a litter of pups. The AI did not result in a litter of pups. Following this, the same male was used with natural matings on two other bitches, and both were likewise unsuccessful.

43. German shepherd dog, aged 8 years. This dog was presented for an AI The bitch did not fall pregnant. The male had many times previously had fertile matings.

44. The same dog, 1 month later: The dog was used for another AI This was successful, and the bitch produced 3 pups.

45. The same dog, 2 weeks later: The dog was used for a further AI, but the bitch did not fall pregnant.

46. Bulldog, of unknown age. This dog was presented for AI.

47. Bull terrier, aged 6 years. A history of a gradually increasing subfertility over the previous 18 months, which worsened to a complete infertility, induced the owner to present the dog for investigation. On genital examination the left testis was found to be small and soft, and the right testis of normal size but reduced consistency and elasticity. Histopathology revealed a testicular atrophy.

48. Bulldog, aged 5 years. This dog was presented for a routine examination for genital soundness. On clinical examination the dog was found to have a deep facial pyoderma.

49. Bull terrier, aged 4 years. The owner requested an AI, but the bitch did not produce a litter. Subsequent to this, the dog was used on other bitches, and all became pregnant and produced normal litters. Another fertile male was used on the original bitch's subsequent oestrus, but this also did not result in a litter of pups. The infertility was thus thought to be due to a problem with the female.

50. Old English sheepdog, aged 4 years. This dog was presented for a routine examination for genital soundness and AI. The bitch did not produce a litter of pups. The male was used for many subsequent services, but none of them resulted in any pups being born.

51. Chow-chow, aged 7.5 years. This dog was presented for a routine examination for genital soundness.

52. Chow-chow, aged 9 months. This dog was presented for a routine examination for genital soundness. The dog was prepubertal.

53. Chow-chow, aged 2.5 years. The owner requested an AI. The bitch did not produce a litter of pups, although the previous and subsequent attempts both produced litters.

54. Bullmastiff, aged 9 years. This dog was presented for an AI. The bitch became pregnant, and produced one pup.

55. Pack hound, aged 11 years. The dog was presented for cryo-preservation of semen. On clinical examination a Grade 4 heart murmur was audible over the mitral area. There was a large cutaneous neoplasm on the left thigh. The left popliteal lymph node was also enlarged.

56. Bulldog, of unknown age. This dog was presented for AI due to a vaginal hyperplasia in the bitch. No pups were born. The male was then used on other bitches, all of which became pregnant and produced litters. Another male was used on the original bitch, but this also did not result in any pups being born.

57. Staffordshire bull terrier, aged 5 years. This dog was presented for a routine examination for genital soundness.

58. Bull terrier, aged 7 years. This dog was presented for a routine examination for genital soundness and AI. The bitch did not produce any pups.

59. Bull terrier, of unknown age. The owner requested an AI. The bitch became pregnant and produced a litter. According to the owner, this male has subsequently successfully impregnated many other bitches.

60. Doberman pinscher, aged 3 years. This dog was presented for an AI.

61. Bulldog, aged 1.5 years. This dog was presented for an AI.

62. Pyrenean mountain dog, of unknown age. This dog was presented for an AI.

63. Pekingese, aged 3 years. Previously the dog had successfully sired litters. The owner requested an AI. The bitch did not produce pups.

64. Rottweiler, aged 4 years. This dog was presented for an AI. The previous 3 bitches served naturally by this dog all fell pregnant.

65. Bulldog, aged 3.5 years. The dog had not previously served a bitch. The owner requested a routine examination for genital soundness and AI.

66. Samoyed, aged 1 year. This dog was presented for an AI.

67. Bull terrier, aged 4 years. This dog was presented for an AI.

68. Bouvier de Flandre, aged 3 years. This dog was presented for an AI.

69. Golden retriever, aged 4 years. This dog was presented for a routine examination for genital soundness and AI. The owner suspected that the bitch was infertile; on previous cycles the bitch was served by different males but never produced a litter of pups.

70. Bull terrier, aged 2.5 years. This dog was presented for a routine examination for genital soundness.

71. Chow-chow, aged 3 years. This dog was presented for an AI.

72. Pekingese, aged 3 years. The owner requested an AI as difficulty was experienced in achieving a normal mating.

73. Rottweiler, aged 1 year. This dog was presented for an AI.

74. Chow-chow, aged 3 years. This dog was presented for a routine examination for genital soundness. Subsequently the dog was not used at stud, because of his over-aggressive temperament.

75. Cairn terrier, aged 4 years. This dog was presented for an AI. The bitch became pregnant, and produced one pup.

76. German shepherd dog, aged 10 years. This dog was presented for an AI. The bitch became pregnant, and produced 3 pups.

77. Bulldog, aged 3 years. This dog was presented for an AI.

78. Pomeranian, of unknown age. This dog was presented for an AI. The bitch became pregnant, and produced 3 pups.

79. Saint Bernard, aged 3 years. The dog had never served a bitch before. The owner requested a routine examination for genital soundness and an AI. The bitch became pregnant, and produced 17 pups.

80. Staffordshire bull terrier, aged 6.5 years. This dog was presented for an AI.

81. Chow-chow, aged 5 years. This dog was presented for an AI.

82. Airedale terrier, aged 1 year. This dog was presented for a routine examination for genital soundness because the owners had noticed an asymmetry in the testes. The left testis was found to be atrophied and fibrotic, but the right testis appeared normal. He was treated with 20 mg/kg amoxicillin and clavulanic acid (Synulox, Beechams) and 15 mg prednisolone (Prednisolone, Millvet, Benrose). The dog also developed babesiosis, which was successfully treated with 6 mg/kg imidocarb (Forray 65, Coopers, Isando). The dog was re-examined one month later. A distinct improvement was noted on the second semen analysis.

83. Boxer, aged 2.5 years. This dog was presented for an AI. Clinically a few small abrasions were noted at the preputial opening. The bitch became pregnant and produced a litter of pups.

84. Bulldog, of unknown age. This dog was presented for an AI.

85. Bouvier de Flandre, aged 4.5 years. This dog was presented for an AI. The bitch became pregnant, and produced 10 pups.

86. Bulldog, aged 1.25 years. This dog was presented for an AI. The bitch became pregnant, and produced 2 pups.

87. Bulldog, aged 2 years. This dog was presented for an AI. The bitch did not produce a litter of pups.

88. Miniature poodle, of unknown age. This dog was presented for an AI.

**Appendix 4: Spermograms of the patients, and pregnancy data**  
 (Abbreviations: Pr = percentage progressively motile sperm, L = percentage locally motile sperm, N = percentage non-motile sperm, a = acrosome, h = head, s = separated head, m = midpiece, p = proximal protoplasmic droplet, ab = abaxial implantation of the midpiece, t = tail. P = pregnant, NP = not pregnant, WBC = white blood cells, nd = no data)

No.	Volume (ml)	Motility (Pr:L:N)	Morphology % Normal (% abnormal)	P/NP
1.	3	85:10:5	96 (1a, 2s, 1t)	(nd)
	4	80:10:10	95 (nd)	(nd)
2.	8	90:5:5	66 (20a, 4h, 4s, 2p, 4t)	(nd)
3.	1.5	30:25:45	17 (5a, 7h, 3s, 15p, 2m, 51t)	NP.
4.	1	50:40:10	24 (56h, 6ab, 10p, 4t)	NP.
	8 months later:			
	1.5	50:10:40	49 (1a 13h 1sh 10ab 18p 1m 7t)	NP.
	1 month later:			
	1	30:30:40	50 (4a 19h 1s 4ab 11p 11t)	NP
5.	1	30:10:60	30 (50h 4s 4p 6m 6t)	NP
	1 month later:			
	2	60:10:30	8 (2a 38h 12s 2ab 26p 2m 10t)	NP.
	4 months later:			
	1.5	90:5:5	76 (10h 8ab 4p 2t)	P.
	4 months later:			
	2.5	80:10:10	72 (16h 4s 2m 6t)	P.
6.	2.5	80:10:10	44 (12h 18s 8p 2m 16t)	NP.
7.	10	85:10:5	0 (all sperm with diadem defects.)	(nd)
8.	1.5	80:10:10	65 (5a 17h 4 s 4ab 5p)	NP.
9.	1	60:35:5	60 (2a 1h 1s 14ab 3p 5m 14t)	P.
10.	2.5	85:10:5	95 (nd)	(nd)
11.	5	90:5:5	85 (8h 2ab 5t)	P.
12.	10	60:10:30	68 (7a 1h 13s 3m 8t)	(nd)
13.	1	no sperm present in ejaculate (greyish, pH 6.8)		(nd)
14.	4	65:30:5	90 (1a 4h 2ab 1p 1m 1t)	NP.
15.	2	30:50:20	46 (3a 4h 5s 22p 20t)	(nd)
16.	3.5	90:5:5	80 (6a 8h 4p 2m)	P.
17.	3	70:20:10	56 (14h 4s 4ab 14p 2m 6t)	NP.
18.	1.6	40:10:50	57 (5a 26h 2s 9p 1t)	(nd)
19.	4	75:10:15	10 (90 p)	(nd)
20.	3	80:10:10	86 (4a 8h 2t)	NP.
21.	2	70:20:10	80 (4a 6h 2s 6p 2t)	(nd)
22.	5	60:20:20	92 (2a 2h 1s 1ab, 1m 1t)	NP.
23.	5	85:5:10	98 (1h 1t)	(nd)

## Appendix 4. cont.

No.	Vol.	Motility	Morphology	P/NP
24	7.5	50:30:20	83 (2a 1h 8m 6t) ++ WBC, occasional epithelial cells.	NP.
	3 days later:			
	8	50:20:30	79 (7h 8m 6t) No WBC or epithelial cells were present.	(nd)
25	5	85:5:10	90 (2a 2h 4ab 2p)	P.
26	0.75	85:10:5	(nd)	(nd)
27	0.4	30:50:20	(nd)	(nd)
28	6	90:5:5	(nd)	(nd)
29	4	90:5:5	(nd)	(nd)
30	3	95:3:2	(nd)	(nd)
31	4	30:10:60	(nd)	(nd)
32	2	90:5:5	(nd)	(nd)
33	4.5	50:30:20	(nd)	(nd)
34	0.5	90:5:5	(nd)	P
35	5	60:20:20	53 (7a 2h 6s 3ab 1lp 4m 14t)	NP
36	2	10:10:80	(nd; contaminated with urine)	(nd)
37	1	40:35:25	20 (8a 32h 32ab, 8m)	NP
38	2	70:20:10	(nd)	P
39	4	70:20:10	77 (4h 6s 2a 1p 1m 9t)	P
	2	80:15:5	74 (5h 7s 5p 1m 8t)	(P).
40	2.5	75:15:10	6 (28h 48p 4ab 14m)	NP
	1.5	75:10:15	7 (20h 2s 11ab 55p 6m)	(nd)
41	2	40:25:35	67 (1a 13s 3ab 10p 6t)	NP
42	3	85:10:5	64 (8a 10h 10ab 4m 4t)	NP
	10 months later:			
	1.5	90:5:5	57 (21a 3h 4s 7m 8t)	NP
43	7	80:15:5	80 (2a 2h 10s 2p 4t) (female infertile).	NP
44	4	80:10:10		P
45	8	75:10:15	87 (3s 7p 3t) (female infertile)	NP
46	2	70:10:20	49 (4a 1lh 3s 14ab 5p 1m 13t)	(nd)
47	3	No sperm present		NP
48	5	70:20:10	64 (24h 4s 4p 4t)	
49	5	70:15:5	87 (8h 1ab 2p 2t) (female infert.)	NP
	5	90:5:5	78 (1a 12h 3s 4p 2t)	
50	5	No sperm present. Three collections were made and all were clear and watery.		
				NP
51.	5	No sperm present		(nd)
52	5	No sperm present (prepubertal animal)		(nd)
53	5	90:5:5	96 (1s 1p 1m 1t)	NP
54	5	85:10:5	70 (6a 7h 2s 8p 1m 6t)	P
55	2	60:30:10	70 (3a 1h 4s 3p 2m 17t)	(nd)
56	2	75:20:5	98 (1s, 1p) (female infertile).	NP
57	7	90:5:5	87 (5a 3h 1s 2p 1m 1t)	(nd)
58	5	0:0:100	2 (10a 16h 10s 4ab 10p 4m 44t)	NP
59	1	90:5:5	67 (6a, 5h, 2ab, 20p)	P
60	9	0:0:100	(nd)	(nd)

## Appendix 4. cont.

No.	Vol.	Motility	Morphology	P/NP
61	6	90:5:5	(nd)	(nd)
62	6	30:20:50	(nd)	(nd)
63	4	7:3:90	(nd)	NP
64	7	85:5:10	(nd)	P
65	5	90:5:5	(nd)	(nd)
66	2	60:10:30	(nd)	(nd)
67	3	50:45:5	(nd)	(nd)
68	10	90:5:5	(nd)	(nd)
69	5	90:5:5	(nd)	(nd)
70	4	75:10:15	(nd)	(nd)
71	5	90:5:5	89 (1s 10p)	(nd)
	7	80:15:5	95 (2s 1p 2t)	(nd)
72	5.5	65:15:20	(nd)	(nd)
73	8	80:10:10	(nd)	(nd)
74	1	90:5:5	94 (2h 2s 2m)	(nd)
75	1.5	80:10:10	91 (1h 8t)	P
76	5	60:30:10	42 (12h 22s, 24t)	P
77	2	90:10:10	81 (1a 1h 5s 6ab 5p 1t)	(nd)
78	3	70:20:10	82 (3h 2p 13t)	P
79	2	80:15:5	79 (3a 1h 8s 5a 1m 3t)	P
80	2	60:0:40	90 (nd)	(nd)
81	3.5	99:1:0	57 (5h 6m 33t)	(nd)
82	3	40:20:40	52 (nd)	(nd)
	3 weeks later:			
	6	70:5:25	85 (8h 2p 1m 4t)	(nd)
83		70:10:20	61 (18a 3h 11s 3a 2p 3t)	P
84	2.5	20:20:60	60 (30a 4h 2ab 1p 1m 2t)	(nd)
85	6	60:25:15	50 (10a 20h 10s 10t)	P
86	4.5	90:5:5	89 (1h 3s 7m)	P
87	7	80:10:10	68 (2a 2h 2ab 16p 10t)	NP
88	3	70:20:10	64 (4h 2s 26p 14t)	(nd)

## REFERENCES

- Aalseth, E.P. & Saacke, R.G. (1985): Morphological changes of the acrosome on motile bovine spermatozoa due to storage at 4 °C. *J. Reprod. Fertil.* 74, 473-478.
- Adams, C.E. (1972): Ageing and reproduction. In: *Reproduction in mammals, Vol 4.* Eds. Austin, C.R. & Short, R.V., Cambridge University Press, pp 128-156.
- Aitken, J.R., Best, F.S.M., Richardson, D.W., Djahanbakhch, O., Mortimer, D., Templeton, A.A. & Lees, M. M. (1982): An analysis of sperm function in cases of unexplained infertility: conventional criteria, movement characteristics, and fertilizing capacity. *Fertil. Steril.*, 38, 212-221.
- Aitken, R.J. & Clarkson, J.S. (1987): Cellular basis of defective sperm function and its association with the genesis of reactive oxygen species by human spermatozoa. *J. Reprod. Fertil.*, 81, 459-469.
- Aitken, R.J., Ross, A., Hargreave, T., Richardson, D. & Best, F. (1984): Analysis of human sperm function following exposure to the Ionophore A23187. *J. Androl.*, 5, 321-329.

- Amantea, G. (1914a): *Richerche sulla secrezione spermatica. La raccolta dello sperma nel cane. R.C. Accad. Lincei, Ser. 5A, 23, 369.*
- Amantea, G. (1914b): *Richerche sulla secrezione spermatica. Prime osservazioni sulla secrezione spermatica normale del cane. R.C. Accad. Lincei, Ser. 5A, 23, 457.*
- Andersen, K. (1974): *Morphological abnormalities in the acrosome and nucleus of boar sperm. Nord. Vet. Med. 26, 215-218.*
- Anniballo, R. (1979): *An excessive ratio of tapering forms of spermatozoa as a distinctive feature in the presence of varicocoele. Fertil. Steril., 32, 704-705.*
- Anton-Lamprecht, I., Kotzur, B. & Schopf, E. (1976): *Round-headed human spermatozoa. Fertil. Steril., 27, 685-693.*
- Aughey, E. & Orr, P.S. (1978): *An unusual abnormality of human spermatozoa. J. Reprod. Fertil., 53, 341-342.*
- Aughey, E. & Renton, J.P. (1971): *The ultrastructure of abnormal spermatozoa in a stud dog. J. Reprod. Fertil., 25, 303-304.*

- Baker, (1958): Principles of biological microtechnique: a study of fixation and dyeing. Methuen, London, pp 234-242.
- Bane, A. (1970): Sterility in male dogs. Nord. Vet. Med.. 22, 561-566.
- Barkay, J., Bartoov, B., Ben-Ezra, S., Langsam, J., Feldman, E., Gordon, S. & Zuckerman, H. (1984): The influence of in vitro caffeine treatment on human sperm morphology and fertilizing capacity. Fertil. Steril., 41, 913-918
- Bartlett, D.J. (1962): Studies on dog semen. 1. Morphological characteristics. J. Reprod. Fertil. 3, 173-189.
- Bartoov, B., Eltes, F., Weissenberg, R. & Lunenfeld, B. (1980): Morphological characterization of abnormal human spermatozoa using transmission electron microscopy. Arch. Androl., 5, 305-322.
- Bedford, J.M. (1970): Sperm capacitation and fertilization in mammals. Biol. Reprod. Suppl. 2, 128-158.
- Bertschinger, H.J. (1975): The hereditary occurrence of diploid spermatozoa in the semen of brown Swiss bulls. Dr. Vet. Med. Thesis, University of Zurich: 1-47.

- Bielanski, W., Dudek, E., Bittmar, A. & Kosiniak, K. (1982):  
Some characteristics of common abnormal forms of  
spermatozoa in highly fertile stallions. *J. Reprod.*  
*Fertil., Suppl.* 32, 21-26.
- Blom, E. (1972): The ultrastructure of some characteristic  
sperm defects and a proposal for a new classification  
of the bull spermogram. In: *Atti del VII Simposio*  
*Internazionale de Zootechia, Milano.* pp 125-129.
- Blom, E. (1978): The corkscrew sperm defect in Danish bulls-  
a possible indicator of nuclear fallout? *Nord. Vet.*  
*Med.,* 30, 1-8.
- Blom, E. (1980): Rolled-head and nuclear-crest sperm defects  
in a rare case of presumed diploidy in the bull. *Nord.*  
*Vet. Med.,* 32, 109-116.
- Blom, E. & Birch-Andersen, A. (1966): Ultrastructure of the  
"decapitated sperm defect" in Guernsey bulls. *J.*  
*Reprod. Fertil.,* 23, 67-72.
- Blom, E. & Birch-Andersen, A. (1975): The ultrastructure of  
a characteristic spermhead defect in the boar: the SME-  
defect. *Andrologia,* 7, 199-209.

Boender, J. (1968): Morphological changes of the acrosome of boar spermatozoa during ageing and cold shock. VIth International Congress on Animal Reproduction and Artificial Insemination. Ed. Thibault, C., Paris, pp 1217-1221.

Boucher, J.H., Foote R.H. & Kirk, R.W. (1958): The evaluation of semen quality in the dog and the effects of frequency of ejaculation upon semen quality, libido and depletion of sperm reserves. Cornell Vet. 48, 67-86.

Bryan, J.H.D. (1970): An eosin-fast green-naphthol yellow mixture for differential staining of cytological components in mammalian spermatozoa. Stain Technol., 45: 231.

Burke, T.J. (1986): Small animal reproduction and infertility: A clinical approach to diagnosis and treatment. Lea & Febiger, Philadelphia, pp 207-217.

Byrd, W. & Wolf, D.W. (1986): Acrosomal status in fresh and capacitated human ejaculated sperm. Biol. Reprod., 34, 859-869.

Calderon Yubi, A., Ferguson, J.M., Renton, J.P., Harker, S., Harvey, M.J.A., Bagyenji, B. & Douglas, T.A. (1987): Some observations on the dilution, cooling and freezing of canine semen. *J. small Anim. Pract.*, 28, 753-761.

Calvin, H.I. & Bedford, J.M. (1971): Formation of disulphide bonds in the nucleus and accessory structures of mammalian spermatozoa during maturation in the epididymis. *J. Reprod. Fertil., Suppl.* 13, 65-75

Cameron, R.D.A. & Blackshaw, A.W. (1980): The effect of elevated ambient temperature on spermatogenesis in the boar. *J. Reprod. Fertil.* 59, 173-179.

Casarett, G.W. (1953): A one-solution stain for spermatozoa. *Stain Technol.*, 28, 125-127.

Chemes, H.E., Brugo, S., Zanchetti, F., Carrere, C. & Lavieri, J.C. (1987a): Dysplasia of the fibrous sheath: an ultrastructural defect of human spermatozoa associated with sperm immotility and primary sterility. *Fertil. Steril.*, 48, 664-669.

- Chemes, H.E., Carizza, C., Scarinci, F., Brugo, S., Neuspiller, N., & Schwarsztein, L. (1987b): Lack of a head in human spermatozoa from sterile patients: a syndrome associated with impaired fertilization. *Fertil. Steril.*, 47, 310-316.
- Christensen, G.C. & Dougherty, R.W. (1955): A simplified apparatus for obtaining semen from dogs by electrical stimulation. *J. Am. vet. med. Assoc.*, 127, 50-53.
- Christiansen Ib.J. (1984): *Reproduction in the dog and cat.* Bailliere Tindall, London, pp 80-109.
- Christie, D.W. & Bell, E.T. (1971): Some observations on the seasonal incidence and frequency of oestrus in breeding bitches in Britain. *J. small Anim. Pract.*, 12, 159-167
- Coetzee, W.J.C., Bornmann, M.S., Du Plessis, D.J. & Van Der Merwe, C.F. (1985): Deurstraal-elektronmikroskopie as hulpmiddel in die hantering van die infertile man. *S. Afr. Med. J.*, 68, 25-29.
- Cohen, J. (1971): The comparative physiology of male gametes. In: *Advances in comparative physiology and biochemistry.* Ed. Lowenstein, O., Academic Press, London, pp 267-380.

- Coubrough, R.I. & Soley, J.T. (1977): An acrosome defect in a subfertile bull. Proc. Electron Microsc. Soc. South. Afr. 7, 117-118.
- Coubrough, R.I. & Soley, J.T. (1982): The "Dag defect" in mammalian spermatozoa. Proc. Electron Microsc. Soc. South. Afr. 12, 75-76.
- Coubrough, R.I. (1985): Stress and fertility. A review. Onderstepoort J. Vet. Res., 52, 153-156.
- Coulter, G.H. (1976): Effect of Dexamethasone on the incidence of the "crater" defect of bovine sperm. VII International Congress on Animal Reproduction and Artificial Insemination. Cracow, pp 694-697.
- Dadoune, J.P. (1988): Ultrastructural abnormalities of human spermatozoa. Human Reprod., 3, 311-318.
- Danzo, B.J., Orgebin-Crist, M-C. & Eller, B.C. (1975): Androgen regulation of epididymal function. In: The biology of spermatozoa. Eds Hafez, E.S.E. & Thibault, C.G. INSERM International Symposium, Nouzilly. Karger, Basle. pp 17-27

- David, G., Bisson, J.P., Cyzglik, F., Jouannet, P. & Gernigon, C. (1975): Anomalies morphologiques du spermatozoide humain. 1. Propositions pour un system de classification. *J. Gynaecol. Obstet. Biol. Reprod.*, 4, 17-36.
- Dott, H.M. & Foster, G.C. (1972): A technique for studying the morphology of mammalian spermatozoa which are eosinophilic in a differential 'live/dead' stain. *J. Reprod. Fertil.*, 29: 443-445.
- Dunn, T.G. (1980): Nutrition and reproduction processes in beef cattle. In: *Current therapy in Theriogenology*. Ed. Morrow D.A., W.B. Saunders Co., Philadelphia pp 456-474.
- Edwards, R.G. (1972): Immunological influences. In: *Reproduction in mammals, Vol 4*. Eds. Austin, C.R. & Short, R.V., Cambridge University Press, pp 94-127
- Eljack, A.H. & Hrudka, F. (1979): Pattern and dynamics of teratospermia induced in rams by parenteral treatment with ethylene dibromide. *J. Ultrastr. Res.*, 67, 124-134.

- Eltes, F., Fisher, J. & Bartoov, B. (1982): Transmission electron microscope morphogram of progressive motile sperm cell fraction separated from teratozoospermic human semen. *Arch. Androl.*, 8, 129-134.
- Esnault, C., Courot, M. & Ortavant, R. (1975): Transport and maturation of epididymal spermatozoa in domestic animals. In: *The biology of spermatozoa*. Eds Hafez, E.S.E. & Thibault, C.G. INSERM International Symposium, Nouzilly. Karger, Basle, pp 28-35
- Evans, J. & Renton, J.P. (1973): A case of azoospermia in a previously fertile dog with subsequent recovery. *Vet. Rec.* 92, 198-199.
- Fawcett, D.W. (1975): The mammalian spermatozoon. *Dev. Biol.*, 44, 394-436.
- Fawcett, D.W. (1986): *A textbook of histology*. 11th Edn., W.B. Saunders Co., Philadelphia. pp 796-850.
- Foote, R.H. (1975): Semen quality from the bull to the freezer: an assessment. *Theriogenology*, 3, 219-234.
- Foote, R.H., Swierstra E.E. & Hunt W.C. (1972): Spermatogenesis in the dog. *Anat. Rec.* 173, 341-351.

Foster, N.M., Alders, M.A., Luedke, A.J. & Walton, T.E.

(1980): Abnormalities and virus-like particles in spermatozoa from bulls latently infected with Bluetongue virus. *Am. J. Vet. Res.*, 41, 1045-1048.

Franken, D.R., Grobler, S. & Pretorius, E. (1986):

Sperm/Cervical mucus contact test for sperm antibodies. *Arch. Androl.* 17, 133-137.

Freshman, J.L., Amann, R.P., Soderberg, S.F. & Olson, P.N.

(1988): Clinical evaluation of infertility in dogs. *The Compendium on Continuing Education for the Practising Veterinarian.* 10, 443-460.

George, C.W., Duncan, J.R. & Charmichael, L.E. (1979):

Semen examination in dogs with canine brucellosis. *Am. J. Vet. Res.* 40: 1589-1595.

Glauert, A. (1982): Practical methods in electron

microscopy. Elsevier, Amsterdam, pp 40-53.

Glover, T.D. (1974): Recent progress in the study of male reproductive physiology: testis stimulation; sperm formation, transport and maturation (epididymal physiology); semen analysis, storage and artificial insemination. In: Reproductive physiology, Series 1 Vol 8, Eds. Guyton, A.C. & Horobin, D., Butterworths University Park Press, London, pp 221-277

Glover, T.D. & Nicander, L. (1971): Some aspects of structure and function in the mammalian epididymus. J. Reprod. Fertil., Suppl. 13, 39-50

Hackett, A.J. & Macpherson, J.W. (1965): Some staining procedures for spermatozoa. A review. Canadian Vet. J., 6, 55-62.

Hancock, J.L. (1971): Spermatogenesis and sperm defects. In: The genetics of the spermatozoon. Eds. Beatty, R.A., Gluecksohn-Waelsch, S. University of Edinburgh and the Albert Einstein College of Medicine, New York, pp 121-130.

Harasymowycz, J., Ball, L. & Seidel, G.E. (1976): Evaluation of bovine spermatozoal morphologic features after staining or fixation. Am. J. Vet. Res., 37, 1053-1057.

- Harrop, A.E. (1954): A new type of canine artificial vagina. *British Vet. J.*, 110, 194.
- Harrop, A.E. (1966): The infertile male dog. *J. small Anim. Pract.*, 7, 723-725.
- Heape, W. (1897): The artificial insemination of mammals and subsequent possible fertilization or impregnation of their ova. *Proc. R. Soc.*, 61, 52.
- Heath, E. & Ott, R.S. (1982): Diadem/crater defect in spermatozoa of a bull. *Vet. Rec.*, 110, 5-6.
- Heywood, R. & Sortwell, R.J. (1971): Semen evaluation in the beagle dog. *J. small Anim. Pract.*, 12, 343-346.
- Holstein, A.F. (1975): Morphologicische Studien an abnormen Spermatiden und Spermatozoen des Menschen. *Virchows Arch. A. Path. Anat. Histol.*, 367, 93-112.
- Holstein, A.F., Schill, W.B. & Breucker, H. (1986): Dissociated centriole development as a cause of spermatid malformation in man. *J. Reprod. Fertil.*, 78, 719-725.

- Hrudka, F. & Singh, A. (1984): Sperm nucleomalacia in men with inflammatory bowel disease. *Arch. Androl.*, 13, 37-57.
- Hunter, R.H.F. (1975): Transport, migration and survival of spermatozoa in the female genital tract: Species with intrauterine deposition of semen. In: *The biology of spermatozoa*, Eds. Hafez E.S.E. & Thibault, C.G., INSERM International Symposium. Karger, Basle, pp 145-155
- Hunter, D.G. & Kretzer, F.L. (1986): Abnormal axonemes in sperm of fertile men. *Arch. Androl.*, 16, 1-12.
- Koefoed-Johnson, H.H., Andersen, J.B., Andersen, E., Blom, E. & Philipsen, H. (1980): The "Dag" defect of the tail of the bull sperm. *Studies on the inheritance and pathogenesis. Theriogenology*, 14, 471-475.
- Krause II, D. (1965): Zur Fertilitätsuntersuchung beim Hund. *Deutsche Tierärztlichen Wochenschrift* 72, 3-10.
- Kruger, T.F., Acosta, A.A., Simmons, K.F., Swanson, R.J., Matta, J.F. & Oehninger, S. (1988): Predictive value of abnormal sperm morphology in in vitro fertilization. *Fertil. Steril.*, 49, 112-117.

- Lalonde, L., Langlais, J., Antaki, P., Chapdelaine, A., Roberts, K.D. & Bleau, G. (1988): Male infertility associated with round-headed acrosomeless spermatozoa. *Fertil. Steril.*, 49, 316-321.
- Larsen, R.E. (1980): Infertility in the male dog. In: *Current Therapy in Theriogenology*. Ed. Morrow, D.A., W.B. Saunders Co., Philadelphia. pp 646-654.
- Mahadevan, M.A. & Trounson, A.O. (1984): Relationship of fine structure of sperm head to fertility of frozen human semen. *Fertil. Steril.*, 41, 287-293.
- Mahi, C.A. & Yanagimachi, R. (1978): Capacitation, acrosome reaction and egg penetration by canine spermatozoa in a simple defined medium. *Gamete Research* 1, 101-109.
- Mann, T. (1964): *The biochemistry of semen and of the male reproductive tract*. Methuen & Co., London. pp 493.
- Mann, T. & Lutwak-Mann, C. (1981): *Male reproductive function and semen*. Springer Verlag, Berlin. pp 495.
- McCosker, P.J. (1969): Abnormal spermatozoan chromatin in infertile bulls. *J. Reprod. Fertil.* 18, 363-365.

- Monesi, V. (1972): Spermatogenesis and the spermatozoa. In: *Reproduction in mammals, Vol 1*. Eds. Austin, C.R. & Short, R.V., Cambridge University Press, pp 46-84
- Nagae, T., Yanagimachi, R., Srivastava, P.N. & Yanagimachi, H. (1986): Acrosome reaction in human spermatozoa. *Fertil. Steril.*, 45, 701-707.
- Nicander, L. & Bane, A. (1966): Fine structure of the sperm head in some mammals, with particular reference to the acrosome and the subacrosomal substance. *Z. Zellforsch.*, 72, 496-515.
- Oettlé, E.E. (1986a): An improved sperm staining technique which facilitates sequential monitoring of the acrosome state. *Develop. Growth & Different.*, 28 (Suppl), 96.
- Oettlé, E.E. (1986b): Changes in acrosome morphology during cooling and freezing of dog semen. *Anim. Reprod. Sc.* 12, 145-150.
- Oettlé, E.E. (1986c): Using a new acrosome stain to evaluate sperm morphology. *Vet. Med.* 81, 263-266.

- Oettlé, E.E. & Clarke, U.A. (1989): Light and electron microscopic observations on human sperm decondensation in vitro. Proc. VI World Congress on In Vitro Fertilization and Alternate Assisted Reproduction. Jerusalem, in press.
- Oettlé, E.E. & Soley, J.T. (1985a): Infertility in a Maltese poodle as a result of a sperm midpiece defect. J. S. Afr. Vet. Assn. 56, 103-106.
- Oettlé, E.E. & Soley, J.T. (1985b): The diadem defect in dog spermatozoa. Proc. Electron Microsc. Soc. South. Afr., 15, 159-160.
- Oettlé, E.E. & Soley, J.T. (1986a): Severe sperm abnormalities with subsequent recovery following on scrotal oedema and posthitis in a Bulldog. J. small Anim. Pract. 27, 477-484.
- Oettlé, E.E. & Soley, J.T. (1986b): Ultrastructural changes in the acrosome of human sperm during freezing and thawing: a pilot trial. Arch. Androl., 17, 145-150.
- Oettlé, E.E. & Soley, J.T. (1988): Sperm abnormalities in the dog: A light and electron microscopic study. Vet. Med. Review, 59, 28-70.

- Oettlé, E.E. & Weldhagen, A.A. (1982): A modified Shorr's stain: A practical rapid stain for canine vaginal cytology. *J. S. Afr. Vet. Assn.*, 53, 267-268.
- Oettlé, E.E. & Wiswedel, K. (1989a): Changes in sperm motility, morphology and concentration induced by the swim-up procedure. *S. Afr. Med. J.*, 75, 22-23.
- Oettlé, E.E. & Wiswedel, K. (1989b): Influence of the swim-up procedure on acrosome damage induced by freezing human semen. *S. Afr. Med. J.*, 75, 23-24.
- Parsonson R.F. & Snowdon, W.A. (1974): Ephemeral fever virus: excretion in the semen of infected bulls. *Austr. Vet. J.*, 50, 329.
- Paufler, S. (1967): Disorders of spermatogenesis in domestic animals. Hoffman-La Roche Ltd., Montreal pp 1-34.
- Pedersen, H. (1969): Ultrastructure of the ejaculated human sperm. *Z. Zellforsch.*, 94, 542-554.
- Pedersen, H. (1974): The human spermatozoon. *Danish Med. Bull.*, 21, Suppl 1, 1-36

Pettey, K.P. & van Niekerk, J.P. (1987): Sperm abnormalities in three imported miniature Schnauzer dogs. Proceedings of the Reproductive Biology Workshop, University of Pretoria, 27-28.

Ploen, L. (1973): An electron microscope study of the delayed effects on rabbit spermatogenesis following experimental cryptorchidism for twenty four hours. Virchows Arch. Abt. B. Zellpath. 14, 159-184.

Plummer, J.M., Watson, P.F. & Allen, W.E. (1987): A spermatozoal midpiece abnormality associated with infertility in a Lhasa Apso dog. J. small Anim. Pract., 28, 743-751.

Rissi, P. (1782): Fecundazione artificiale ottenuta in una cagna. Opusc. scelti di Milan. 5 (Part II), 96.

Rosenthal, R.C. (1983): Infertility in the male dog. The Compendium of Continuing Education for the Practicing Veterinarian. 5, 983-990.

Ross, A., Christie, S. & Edmond, P. (1973): Ultrastructural tail defects in the spermatozoa from two men attending a subfertility clinic. J. Reprod. Fertil., 32, 243-251.

- Ross, A., Christie, S. & Kerr, M.G. (1971): An electron microscope study of a tail abnormality in spermatozoa from a sub-fertile man. *J. Reprod. Fertil.*, 24, 99-103.
- Saacke, R.G. (1970): Morphology of sperm and its relationship to fertility. Proceedings of the National Association of Animal Breeders Third Technical Conference on Artificial Insemination and Reproduction, 22-27.
- Sadleir, R.M.F.S. (1972): Environmental effects. In: *Reproduction in mammals*, Vol. 4. Eds. Austin, C.R. & Short, R.V., Cambridge University Press, pp 69-93
- Saunders, J.W. (1982): Gametogenesis in animals. In: *Developmental Biology: patterns, problems, principles*. Macmillan, New York, pp 58-94
- Savage, N.C. (1984): Infertility in a ram associated with a knobbed acrosome abnormality of the spermatozoa. *Canadian Vet. J.* 25, 126-127.
- Seager, S.W.J. (1986): Artificial insemination in dogs. In: *Small animal reproduction and infertility: A clinical approach to diagnosis and treatment*. Ed. Burke, T.J., Lea & Febiger, Philadelphia, pp 207-217.

Serikawa, T., Kondo, Y., Takada, H. & Yamada, J. (1984):

Head-to-head type auto-spermagglutination with IgA antibody to acrosome induced by Brucella canis infection. Jap. J. Vet. Sc. 46, 41-48.

Shille, V.M. & Stabenfeldt, G.H. (1980): Clinical

Reproductive Physiology in Dogs. In: Current therapy in Theriogenology. Ed. Morrow, D.A., W.B. Saunders Co., Philadelphia, pp 571-574.

Short, R.V. (1972): Role of hormones in sex cycles. In:

Reproduction in mammals, Vol. 3, Eds. Austin, C.R. & Short, R.V., Cambridge University Press, pp 42-72

Singer, C. (1959): A history of biology. Abelard-Schuman,

London. pp 580.

Skinner, J.D. (1971): The effect of season on

spermatogenesis in some ungulates. J. Reprod Fertil., Suppl. 13, 29-37

Snedecor, G.W. & Cochran, W.G. (1967): Statistical methods.

Iowa State University Press, Ames, Iowa, Sixth Edn, pp 593.

- Soley, J.T. & Coubrough, R.I. (1981): A "pouch-like" defect in the basal plate region of cheetah spermatozoa. Proc. Electron Microsc. Soc. South. Afr. 11, 121-122.
- Sokol, R. Z. & Sparkes, R. (1987): Demonstrated paternity in spite of severe idiopathic oligospermia. Fertil. Steril., 47, 356-358.
- Swanson, E.W. & Boyd, L.J. (1962): Factors affecting coiled-tail spermatozoa in the bull. Am. J. Vet. Res., 300-309.
- Spallanzani, L. (1781): Fecondazione artificiale d'una cagna. Opusc. scelti di Milan. 4 (Part IV): 279.
- Takeishi, M., Toyoshima, T., Ryo, T., Takematsu, S., Miki, H. & Tsunekane, T. (1975): Studies on the reproduction of the dog. VI: Sexual maturity of male beagles. Bull. Coll. Agric. Vet. Med., Nikon University, 32, 213-223.
- Talbot, P. & Chacon, R.S. (1981): A triple-stain technique for evaluating normal acrosome reactions of human sperm. J. Exp. Zool., 215, 201-208.

- Watson, P.F. (1975): Use of a Giemsa stain to detect changes in acrosomes of frozen ram spermatozoa. *Vet. Rec.*, 97, 12-15.
- Weakley, B.S. (1972): A beginners handbook in biological electron microscopy. Churchill Livingstone, London, pp 228.
- Wells, M.E. & Awa, O.A. (1969): New technique for assessing acrosomal characteristics of spermatozoa. *J. Dairy Sc.*, 53, 227-232
- Wild, P., Bertschinger, H.J. & Zerobin, K. (1978): Raster- und transmissionselektronenmikroskopische Untersuchung von diploiden bovinen Spermien. *Zuchthyg.*, 13, 107-112.
- Wildt, D.E., Baas, E.J., Chakraborty, P.K., Wolfle, T.L. & Stewart, A.P. (1982): Influence of inbreeding on reproductive performance, ejaculate quality and testicular volume in the dog. *Theriogenology*, 17, 445-452.
- Williamson, R.A., Koehler, J.K., Smith, W.D. & Stenchever, M.A. (1984): Ultrastructural sperm tail defects associated with sperm immotility. *Fertil. Steril.*, 41, 103-107.

- Wilton, L.J., Temple-Smith, P.D., Baker, H.W.G. & de Kretser, D.M. (1988): Human male infertility caused by degeneration and death of sperm in the epididymis. *Fertil. Steril.*, 49, 1052-1058.
- Wong, W.T. & Dhaliwal, G.K. (1985): Observations on semen quality of dogs in the tropics. *Vet. Rec.* 116, 313-314.
- World Health Organization (1987): Laboratory manual for the examination of human semen and semen-cervical mucus interaction. 2nd Edn., pp 67.
- Zaini, A., Jennings, M.G. & Baker, H.W.G. (1985): Are conventional sperm morphology and motility assessments of predictive value in subfertile men? *Int. J. Androl.*, 8, 427-435.
- Zalewski, W. & Andersen-Berg, K. (1983): Acrosomal damage caused by processing frozen semen from the silver fox (*Vulpes argenteus*) and the blue fox (*Alopex lagopus*). *Zuchthyg.*, 18, 22-26.
- Zaneveld, L.J.D. (1975): The acrosomal enzymes of mammalian spermatozoa. In: *The biology of spermatozoa*. Eds. Hafez, E.S.E. & Thibault, C.G. INSERM International Symposium. Karger, Basle, pp 192-200