


kispaces.com%2Fhome)


# Upper Limb Anatomy

 Wiki Home

## home (/home)

 Projects

 Edit (/page/edit/home?goto=http%3A%2F%2Fupperlimbanatomy.wikispaces.com%2Fhome)

 Recent Changes

 Pages (and Files)

 19 (/page/history/home)

 ... (/page/menu/home)

 Members

The Upper Limb Wiki was created in 2010 as part of an Anatomy & Physiology class project for 1st year Physiotherapy and Occupational Therapy students at the University of Cape Town. Each student wrote a wiki page.

Editors 2011-2012:

Dr Roisin Kelly-Laubscher- Lecturer in Anatomy & Physiology,  
University of Cape Town

Editors 2012-2013

Dr Roisin Kelly-Laubscher- Lecturer in Anatomy & Physiology,  
University of Cape Town

Ms. Zeenath Higgins- Physiotherapy student

Mr. Jonty Brooks- Physiotherapy student

### Upper limb dictionary:

We have now added an [upperlimbdictionary](#) where you can add and look up words that you may come across in this wiki.

### Muscles

[Biceps Brachii](#)

[Brachialis](#)

[Coracobrachialis](#)

[Deltoid](#)

[infraspinatus](#)

[Latissimus dorsi](#)

[levator scapulae](#)

[Palmaris Longus](#)

[Pectoralis Major](#)

[Pectoralis Minor](#)

[Pronator Quadratus](#)

[Pronator teres](#)

## Muscles of the Upper Limb

Biceps Brachii

Brachialis

Coracobrachialis

Deltoid

infraspinatus

Latissimus dorsi

levator scapulae

Palmaris Longus

Pectoralis Major

Pectoralis Minor

Pronator Quadratus

Pronator teres

Rhomboid major

Rhomboid minor

Subclavius

subscapularis

Teres minor

Trapezius

Triceps

## Nerves of the Upper Limb

Brachial Plexus

Dorsal Scapular nerve

Medial cutaneous nerve of the

arm  
 Medial cutaneous nerve of the forearm  
 Medial Pectoral Nerve  
 Median nerve  
 Musculocutaneous nerve  
 Nerve to subclavius  
 Radial Nerve  
 Suprascapular nerve  
 Thoracodorsal nerve  
 Ulnar nerve  
 Upper subscapular nerve

[Rhomboid major](#)  
[Rhomboid minor](#)  
[Subclavius](#)  
[subscapularis](#)  
[Teres minor](#)  
[Trapezius](#)  
[Triceps](#)

## Shoulder joint

## Axilla

## Lowerlimbanatomy

## wiki


## Feedback

**Like** Be the first of your friends to like this.

**g+1** +3 Recommend this on Google

**Tweet** 0

**15,554 Visitors**  
 15 Nov 2012 - 21 Sep 2014

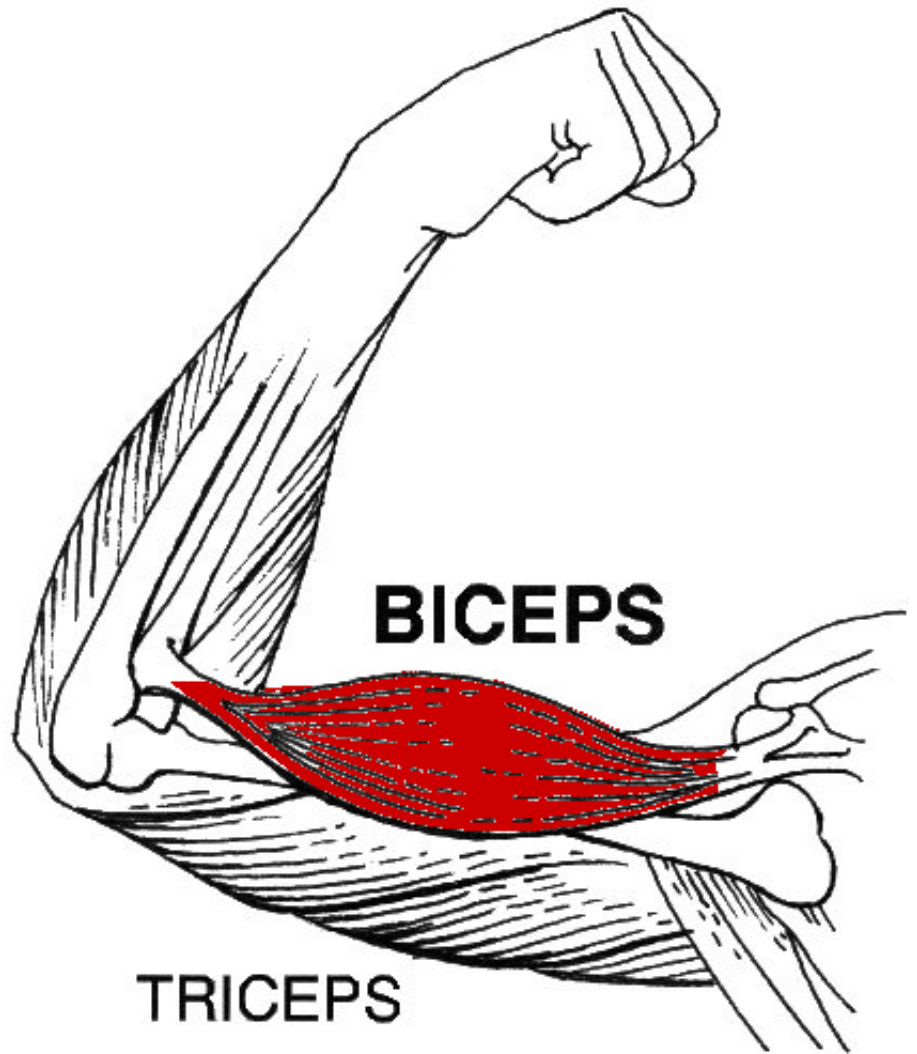


Click to see


## Nerves

[Brachial Plexus](#)  
[Dorsal Scapular nerve](#)  
[Medial cutaneous nerve of the arm](#)  
[Medial cutaneous nerve of the forearm](#)  
[Medial Pectoral Nerve](#)  
[Median nerve](#)  
[Musculocutaneous nerve](#)  
[Nerve to subclavius](#)  
[Radial Nerve](#)  
[Suprascapular nerve](#)  
[Thoracodorsal nerve](#)  
[Ulnar nerve](#)  
[Upper subscapular nerve](#)

**Like** Be the first of your friends to like this.



[Help](#) · [About](#) · [Blog](#) · [Pricing](#) · [Privacy](#) · [Terms](#) · [Support](#) · [Upgrade](#)

Contributions to <http://upperlimbanatomy.wikispaces.com/> are licensed under a Creative Commons Attribution Share-Alike Non-Commercial 3.0 License. 

Portions not contributed by visitors are Copyright 2014 Tangient LLC