

**Normal variations of coeliac and hepatic artery
blood supply to the liver
as identified on multidetector computed
tomography (MDCT) studies
at
Groote Schuur Hospital,
Western Cape Province, South Africa
between 2018 and 2019.**

Student Name: Dr Vengesai Muzenda

Student Number: mznven003

Supervisor: Dr Nazir Ahmed



A research report submitted to the
Faculty of Health Sciences, University of Cape Town,
in partial fulfilment of the requirements for the degree
of
Master of Medicine in Radiodiagnosis.

The copyright of this thesis vests in the author. No quotation from it or information derived from it is to be published without full acknowledgement of the source. The thesis is to be used for private study or non-commercial research purposes only.

Published by the University of Cape Town (UCT) in terms of the non-exclusive license granted to UCT by the author.

Table of contents

Declaration Page.....	1
I. Literature Review	2
1. Introduction	2
2. Role of MDCT	2
2.1 Embryological development of the coeliac axis and branches.....	3
2.2 Normal anatomy of the coelic axis and hepatic artery.	4
2.3 Coeliac axis variant anatomy.	7
2.4 Hepatic arterial system anatomical variations.....	9
3. Relevance in South Africa	12
4. Conclusion.....	13
5. References	14
II. Full Text Journal Article For Submission	17
1. Cover Letter	17
1.1 Acknowledgements:.....	18
1.2 Word Count:	18
1.3 List of Tables:	19
1.4 List of Figures:	20
2. Abstract	21
3. Introduction	22
4. Research Methods and Study Design	23
4.1.1 Study design.....	23
4.1.2 Sampling / Inclusion criteria	23
4.1.3 Data collection	24
4.1.4 Data analysis.....	24
4.1.5 Ethical considerations.....	25
5. Results	25
6. Discussion	31

6.1	Strengths and limitations:	38
6.2	Recommendations	39
7.	Conclusion	39
8.	References	40
III	Appendix	45
(a)	Original Ethics Approval	45
(b)	Hospital Research Board Permission	46
(C)	SAJR Instructions to Authors	47

Declaration Page

I, Dr. Vengesai Muzenda, hereby declare that the work on which this dissertation is based is my original work (except where acknowledgements indicate otherwise) and that neither the whole work nor any part of it has been, is being, or is to be submitted for another degree at this or any other university.

I empower the university to reproduce for research purposes either the whole or any portion of the contents of this dissertation in any manner whatsoever.

Signature:

Signed by candidate

Date: 24/06/2020

I. Literature Review

1. Introduction

Anatomical variations of the coeliac artery/axis (CA) and hepatic arteries (HA) are not uncommon. Previously, unsubtracted and then digital subtraction catheter angiography were the primary imaging modalities in arterial studies. The technological evolution of the multidetector computed tomography (MDCT) has led to an exponential increase in its clinical use. In addition to depicting the morphology of the intra-abdominal solid organs, MDCT is now the first imaging modality in angiographic studies for primary and secondary liver tumours and hepatic trauma. MDCT angiography has by and large replaced invasive digital subtraction angiography (DSA) for diagnostic workup of the vascular anatomy (1, 2). MDCT is readily available, has high spatial resolution, is faster and less invasive when compared with DSA (3). DSA is predominantly reserved for inconclusive CTA findings in patients with a high suspicion of vascular injury and for therapeutic purposes.

2. Role of MDCT

Technological advances in medical imaging specifically driven by the invention of the MDCT, have led to the introduction and growth of minimally invasive surgical and interventional procedures in the treatment of many intra-abdominal pathologies. Advanced primary and metastatic hepatic tumours can be treated by means of surgery, minimally invasive procedures such as trans-arterial chemoembolisation (TACE), and radio-embolization (1, 4, 5). Transarterial chemotherapy delivery and/or embolisation is a safe and effective treatment method that can achieve some local tumour control, improved quality of life and survival (4, 6). In the same vein, sufficient evidence exists to support the safety and effectiveness of the Y90 microspheres therapy, though stricter methodical angiographic technique is required to prevent non-target organ injury (7). Due to its size and a relatively fixed intra-abdominal position, the liver is one of the most frequently injured solid abdominal organs following blunt and penetrating trauma and it is the leading cause of mortality (8-10). Improvement in MDCT and

development of less invasive interventional procedures has led to a shift from operative to non-operative management of patients with liver injury following blunt and penetrating abdominal trauma (10). Massive arterial hepatic post-traumatic haemorrhage can be managed by transcatheter superselective arteriography and coil or particle embolisation of the injured hepatic artery (9, 11, 12). Therapeutic embolisation is associated with decreased morbidity, shorter hospital stays, and fewer surgery related complications such as infections. The success of hepatic artery embolisation depends on early detection of active contrast medium extravasation or false aneurysms on MDCT angiography, together with clinician awareness of its utility and the availability of rapid mobilisation of the angiographic personnel (12). The accurate depiction of the vascular anatomy is of utmost significance to both the surgeon and interventional radiologists. Furthermore, newer interventional procedures require that the interventional radiologist has a perfect understanding of the normal and variant anatomy of the arteries in order to plan and obtain the best approach possible and minimise complications (13). With the increase in the number of patients benefiting from liver transplants, trauma embolisation, TACE and/or radio-embolisation, understanding of the anatomical variations of the CA and hepatic artery is of utmost significance to minimise procedure complications and procedure duration. If the surgeon or interventional radiologist is not aware of the presence of variant anatomy, iatrogenic injury to the vessels or suboptimal treatment may occur, resulting in high morbidity and mortality.

2.1 Embryological development of the coeliac axis and branches

Angiogenesis originates from the mesoderm, initially from blood islands (haemangioblasts) situated in the lining of the yolk sac. The heart, alongside the blood vessels, start to develop towards the end of the third week when the trilaminar disc can no longer solely be supplied with nutrients via simple diffusion. Initially, there are two dorsal aortae and their respective multiple ventral and lateral segmental arteries (14). The vascular supply develops concomitantly together with

the gut system. The gut is attached to the dorsal body wall by the dorsal mesentery. The ventral segmental (vitelline) arteries traverse the dorsal mesentery to perfuse the gastro-intestinal system that stretches from the distal oesophagus to the anus. As a result of craniocaudal and lateral body folding, the two dorsal aortae combine to form a single aorta situated in the midline, anterior to the developing vertebral column. Concurrently, the paired segmental ventral arteries combine in the midline in a craniocaudal direction, resulting in the formation of the CA, superior mesenteric artery (SMA) and inferior mesenteric artery (IMA) (3). Simultaneously, the future renal arteries develop from fusion of the lateral branches supplying the mesonephros.

The fusion of the ventral arteries is a complex developmental process as regression of certain segments also occurs. During the process of angiogenesis, failure of fusion or regression of certain pre-determined components result in different anatomical variations in the branching patterns of the CA and hepatic arterial system (HAS) (2, 3).

The coeliac axis is the artery that supplies the foregut-derived organs such as the distal oesophagus, stomach, liver, first and second parts of the duodenum, gallbladder, and pancreas. The pancreas receives additional blood supply from the superior mesenteric artery (SMA) via the inferior pancreaticoduodenal artery. The SMA perfuses the midgut derivatives and inferior mesenteric artery the hindgut derivatives.

2.2 Normal anatomy of the coelic axis and hepatic artery.

The descending thoracic aorta emerges into the abdomen at T12 through the aortic hiatus of the diaphragm (15). It is bound anteriorly by the median arcuate ligament, a fibrous band or arch that unites the right and left diaphragmatic crura on either side of the aortic hiatus (16). Figure 1 depicts the branches of CA (3).

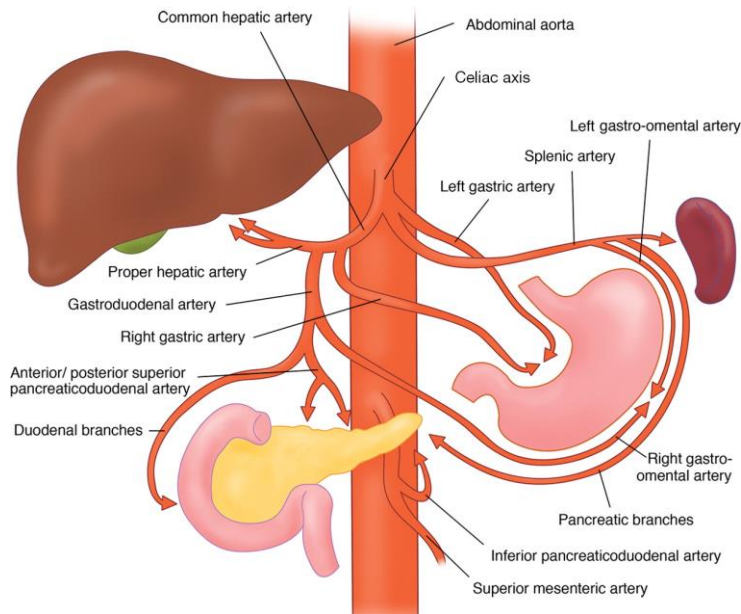


Figure 1: Normal coeliac axis and branches.

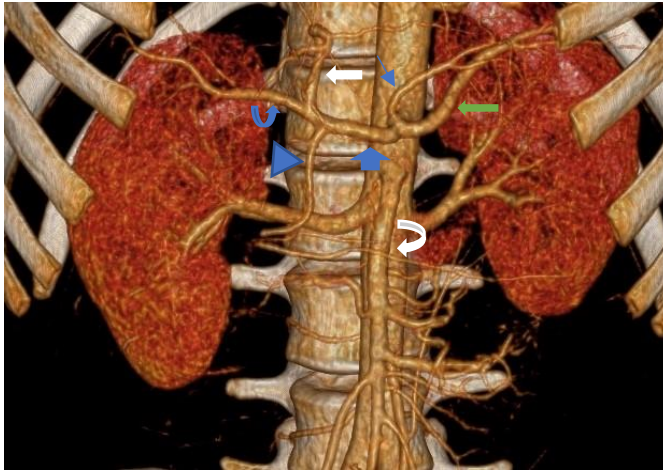
Reproduced from White R. et al. (3)

There are three unpaired anterior major branches of the abdominal aorta. The first branch is the coeliac axis (CA) that originates at the T12/ L1 level, as the aorta emerges from the aortic hiatus. This artery perfuses the foregut derivative solid and hollow organs. (See Fig 1 above)

After the CA emerges from the aorta at the T12/L1 level, it runs anteriorly for a short distance, before it first gives the left gastric artery (LGA) and then eventually splits into the splenic artery (SA) and common hepatic artery (CHA)(17). (see Figures 2(a) and (b) below)

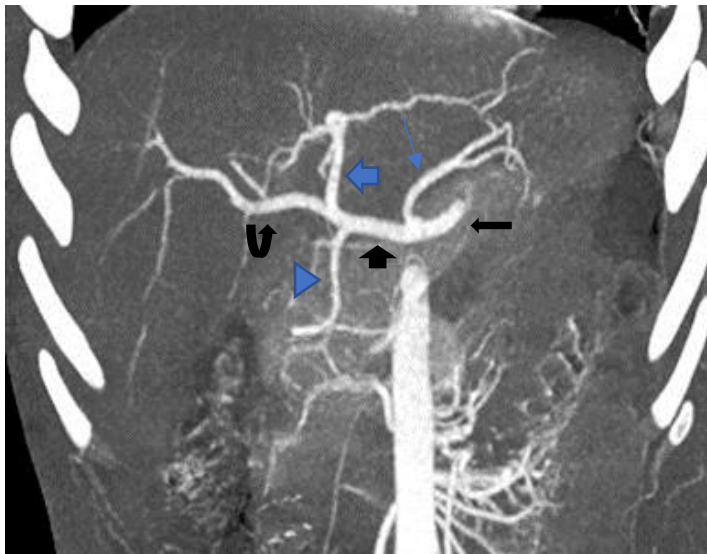
The LGA forms an inferior concave configuration as it first runs towards and approaches the oesophagus. It gives off a branch that supplies the distal esophagus. The LGA then continues along the lesser curvature of the stomach, eventually divides into the anterior and posterior branches. The posterior branch anastomosis with the corresponding branch from the right gastric artery to form an arterial arcade along the lesser curvature (13).

Figure 2: Normal coeliac axis and hepatic artery.



(a) Volume Rendered Images

Fig 2(a) Common hepatic artery (wide blue arrow), splenic artery (long green arrow), superior mesenteric artery (white curved arrow), gastroduodenal artery (blue triangle arrow), right hepatic artery (curved blue arrow), left hepatic artery (thick white arrow), left gastric artery (thin blue arrow).



(b) MIP coronal

Fig 2 (b) Splenic artery (long black arrow), left gastric artery (long thin blue arrow), common hepatic artery (short black arrow), gastroduodenal artery (blue triangle arrow). Left hepatic artery (thick blue arrow) and right hepatic artery (curved black arrow).

The second branch of the CA, the splenic artery tortuously courses to the spleen either along the superior border of or posterior to the pancreas. Along its course,

the splenic artery gives off several branches, which includes the dorsal pancreatic artery, transverse pancreatic artery, greater pancreatic artery, left gastro-omental artery (also called gastro-epiploic artery) and short gastric arteries. The left gastro-omental artery courses along the greater curvature of the stomach within the greater omentum, to anastomose with the corresponding right gastro-omental artery, arising from the gastroduodenal artery (13, 15).

The CHA takes an oblique course and passes over the head of the pancreas and gives origin to the right gastric artery, followed by the gastroduodenal artery (GDA) at the epiploic foramen (foramen of Winslow) to become the proper hepatic artery (PHA) (13, 15, 18). The PHA ascends in the hepatoduodenal ligament to the left of the common bile duct and anterior to the main portal vein (15, 19). It eventually splits into the right and left hepatic arteries. The right hepatic artery also supplies gallbladder via the cystic artery. The GDA passes behind the first part of the duodenum. It first gives branches to the duodenum and finally divides into the superior pancreaticoduodenal and right gastro-omental arteries. The superior pancreaticoduodenal artery splits into anterior and posterior branches. Together with the corresponding inferior pancreaticoduodenal from the SMA, they form a pancreatic arterial arcade/anastomosis. The right gastro-omental artery anastomoses with the left gastro-epiploic artery, a branch arising from the splenic artery(13).

2.3 Coeliac axis variant anatomy.

The reported frequency of the normal CA configuration in the literature ranges from 51% to 90.5% (1, 2, 18, 20-27) (*see Table 1*).

Ugurel et al. (2010, n=100) concluded that the frequency of normal CA anatomy in their study population was 89% (2). This correlated with the study performed by Song et al. (2010; 89.1%) (1), as well as that from South India performed by Thangarajah et al (2016) (24) with a prevalence of 89.5%.

Author	Country of study	Year	Study population (N)	Modality used	Normal anatomy (%)	Variant anatomy (%)
Araujo et al(18)	Brazil	2015	60	MDCT	90	10
Egorov et al(20)	Russia	2010	197	MDCT	56.3	45.7
Ugurel et al (2)	Turkey	2010	100	MDCT	89	11
Song et al(1)	South Korea	2010	5002	MDCT/DSA	89.1	10.9
Lezzi R et al(21)	Italy	2007	555	MDCT	72.1	27.9
Prakash et al(22)	India	2012	50	DISSECTION	86	14
Mburu et al(23)	Kenya	2010	123	MDCT	61.7	38.3
Thangarajah et al(24)	India	2016	200	MDCT	89.5	10.5
Winston et al (25)	USA	2005	394	CTA	51	49
Osman et al(26)	Egypt	2016	1000	CTA	90.5	9.5
Vandamme et al(27)	Belgium	1985	156	DISSECTION	85.9	14.1
Purushothama et al(28)	India	2018	200	MDCT	90.5	9.5

N = sample size.

Table 1: Normal and variant anatomy of the coeliac axis.

The study conducted by Mburu et al. (2008; n=123) in Kenya concluded that only 61.7% of their study population had a normal CA branching pattern. Prakash et al. (2012) in India found that 76% had normal coeliac axis anatomy.

Uflacker's classification (29) divides the different variations in CA branching pattern into eight subtypes. (See Table 2)

Coeliac trunk variations	Type
Normal coeliac trunk	I
Hepatosplenic trunk	II
Hepatogastric trunk	III
Hepatosplenomesenteric trunk	IV
Gastrosplenic trunk	V
Coeliac-mesenteric trunk	VI
Coeliac colic trunk	VII
No coeliac trunk	VIII

Table 2 : Uflacker’s classification of the coeliac trunk anatomical variations.

2.4 Hepatic arterial system anatomical variations.

The CHA is commonly referred to in textbooks as that segment of the hepatic artery originating from the coeliac artery and which terminates where the gastroduodenal artery arises (30). The CHA can have an anomalous origin or course (31, 32). Besides CHA variants, several anomalous origins and courses of the right and left hepatic arteries are also well documented in the literature (See Table 3). Egorov et al. (20) and Ugurel et al. (2) found normal common hepatic artery anatomy in 56.7 % and 52 % respectively. This correlates with a study by Thangarajah A. et al. (2016) (24) from India, with a normal hepatic artery frequency of 57 %. However, Ahmed M. Osman et al. from Egypt (26) reported normal CHA anatomy in 74.3 %.

Hepatic artery variants include a replaced right hepatic artery arising from the SMA and replaced left hepatic artery originating from the LGA (15, 25).

Additional variants include accessory right and accessory left hepatic arteries (13, 15).

Author	Study year	Country	Study Sample size (N)	Normal anatomy %	Variations %
Ugurel et al (2)	2009	Turkey	100	52	48
Araujo et al(18)	2015	Brazil	60	78.3	21.7
Song et al (1)	2010	South Korea	5002	96.3	3.71
Thangarajah et al (24)	2016	India	200	57	43
Osman et al(26)	2016	Egypt	1000	74.3	25.7
Brasil et al (33)	2018	Brazil	100	82	18
Hiatt et al (34)	1993	USA	1000	75.7	24.3
Purushothama et al (28)	2018	India	200	76.5	23.5
Covey et al (32)	2001	USA	600	61.3	38.7

Table 3: Normal patterns and variations of the hepatic arterial system.

The Michels classification is the most commonly used classification system for hepatic arterial variations (35). (See Table 4)

This classification system divides variations into 10 subtypes. However, Hiatt et al modified Michels classification to reflect the presence of vessels that were either accessory or replaced, so that the original ten groups were reduced to five major subtypes and the most rare, sixth variant (34). The difference in frequency of the hepatic artery variations amongst these studies could be dependent on the varying classifications of what constitutes a common hepatic artery (3).

In order to accommodate the variant origin of the common hepatic artery from sites other than the coeliac axis, Song et al. redefined the CHA as an arterial trunk containing at least one segmental hepatic artery plus the gastroduodenal artery, irrespective of the trunk's origin and its anatomic course (1).

Type	Description
I.	Normal anatomy
II.	Replaced left hepatic artery arising from the LGA.
III.	Replaced right hepatic artery arising from the SMA.
IV.	Replaced right and left hepatic arteries (co-existence of II and III).
V.	Accessory left hepatic artery arising from the LGA.
VI.	Accessory right hepatic artery arising from SMA
VII.	Accessory left hepatic artery off the LGA and accessory right hepatic artery off the SMA.
VIII.	Accessory left hepatic artery off the LGA and replaced right hepatic artery off the SMA.
IX.	Common hepatic artery arising from the SMA.
X.	Right and left hepatic arteries arising from the LGA.

Table 4: Modified Michels classification of the hepatic arterial system variations.

Illustrated below is a schematic representation of the hepatic artery variations as per Michels classification (13).




Figure 3: Schematic representation of hepatic arterial variation according to modified Michels classification system. *Note:* Reproduced from Favelier et al. (13).

3. Relevance in South Africa

South Africa has a high prevalence of trauma due to road traffic accidents, gunshots and interpersonal violence. The liver is one of the most commonly injured intra-abdominal solid organs after the spleen, following blunt and penetrating abdominal trauma (9, 10). South Africa has the highest rate of injury-related deaths (157.8 per 100 000) on the African continent and almost twice the global average (86.7 per 100 000) (36, 37). In addition, there are a number of patients presenting to Groote Schuur Hospital, South Africa with primary liver tumours or colorectal metastases to the liver who may benefit from surgery, liver transplantation or interventional procedures such as trans-arterial chemotherapy, chemo-embolisation or radio-embolisation (38, 39). Currently, no radio-embolisation procedure has been performed at GSH, but is a well-known standard of care procedure for inoperable hepatic tumours at other centres within South Africa (40).

These sophisticated and minimally invasive interventional procedures necessitate that the surgeon or radiologist has a good knowledge of the normal and variations in the branching patterns of the coeliac axis and hepatic arterial systems. The frequency of the normal anatomical configuration varies between 51 % and 90 % globally. However, to our knowledge, there are currently no studies of the anatomical variations of the coeliac axis and hepatic arterial system in the South African population.

It was felt relevant to investigate and document the prevalence and gender variation of the normal and variant anatomy of the coeliac and hepatic arterial systems in the Groote Schuur Hospital population located in Cape Town in the Western Cape of South Africa.

4. Conclusion

The interventional radiologist and surgeon should be aware of the full range of variant anatomy of the coeliac axis and hepatic arterial system. It is imperative to recognize this on MDCT angiography to plan the hepatic procedure by surgical or endovascular route accordingly to optimise treatment, reduce procedure time, optimise contrast utilisation and prevent iatrogenic liver injury.

5. References

1. Song S-Y, Chung JW, Yin YH, Jae HJ, Kim H-C, Jeon UB, et al. Celiac axis and common hepatic artery variations in 5002 patients: systematic analysis with spiral CT and DSA. *Radiology*. 2010;255(1):278-88.
2. Ugurel MS, Battal B, Bozlar U, Nural MS, Tasar M, Ors F, et al. Anatomical variations of hepatic arterial system, coeliac trunk and renal arteries: an analysis with multidetector CT angiography. *The British Journal of Radiology*. 2010;83(992):661-7.
3. White RD, Weir-McCall JR, Sullivan CM, Mustafa SAR, Yeap PM, Budak MJ, et al. The celiac axis revisited: anatomic variants, pathologic features, and implications for modern endovascular management. *RadioGraphics*. 2015;35(3):879-98.
4. Vogl TJ, Zangos S, Eichler K, Yakoub D, Nabil M. Colorectal liver metastases: regional chemotherapy via transarterial chemoembolization (TACE) and hepatic chemoperfusion: an update. *European radiology*. 2007;17(4):1025-34.
5. Varela M, Real MI, Burrel M, Forner A, Sala M, Brunet M, et al. Chemoembolization of hepatocellular carcinoma with drug eluting beads: efficacy and doxorubicin pharmacokinetics. *Journal of hepatology*. 2007;46(3):474-81.
6. Allison D, Jordan H, Hennessy O. Therapeutic embolisation of the hepatic artery: a review of 75 procedures. *The Lancet*. 1985;325(8429):595-9.
7. Kennedy A, Nag S, Salem R, Murthy R, McEwan AJ, Nutting C, et al. Recommendations for radioembolization of hepatic malignancies using yttrium-90 microsphere brachytherapy: a consensus panel report from the radioembolization brachytherapy oncology consortium. *International Journal of Radiation Oncology* Biology* Physics*. 2007;68(1):13-23.

8. Yoon W, Jeong YY, Kim JK, Seo JJ, Lim HS, Shin SS, et al. CT in blunt liver trauma. *Radiographics*. 2005;25(1):87-104.
9. Kokabi N, Shuaib W, Xing M, Harmouche E, Wilson K, Johnson J-O, et al. Intra-abdominal solid organ injuries: an enhanced management algorithm. *Canadian Association of Radiologists Journal*. 2014;65(4):301-9.
10. Ahmed N, Vernick JJ. Management of liver trauma in adults. *Journal of Emergencies, Trauma and Shock*. 2011;4(1):114.
11. Forlee M, Krige J, Welman C, Beningfield S. Haemobilia after penetrating and blunt liver injury: treatment with selective hepatic artery embolisation. *Injury*. 2004;35(1):23-8.
12. Rubin BE, Katzen BT. Selective hepatic artery embolization to control massive hepatic hemorrhage after trauma. *American Journal of Roentgenology*. 1977;129(2):253-6.
13. Favelier S, Germain T, Genson PY, Cercueil JP, Denys A, Krausé D, et al. Anatomy of liver arteries for interventional radiology. *Diagnostic and Interventional Imaging*. 2015;96(6):537-46.
14. Sadler TW, Langman J. *Langman's Medical Embryology* (13th ed). Philadelphia, Pa London: Lippincott Williams & Wilkins/Wolters Kluwer Health; 2015.
15. Butler P, Mitchell AWC, Healy CJ. *Applied Radiological Anatomy*. Cambridge: Cambridge University Press; 2012.
16. Horton KM, Talamini MA, Fishman EK. Median arcuate ligament syndrome: evaluation with CT angiography. *Radiographics*. 2005;25(5):1177-82.
17. Wang Y, Cheng C, Wang L, Li R, Chen J-h, Gong S-g. Anatomical variations in the origins of the celiac axis and the superior mesenteric artery: MDCT angiographic

findings and their probable embryological mechanisms. *European radiology*. 2014;24(8):1777-84.

18. Araujo Neto SA, Franca HA, de Mello Júnior CF, Silva Neto EJ, Negromonte GRP, Duarte CMA, et al. Anatomical variations of the celiac trunk and hepatic arterial system: an analysis using multidetector computed tomography angiography. *Radiologia Brasileira*. 2015;48(6):358-62.

19. Lee K-H, Sung K-B, Lee D-Y, Park SJ, Kim KW, Yu J-S. Transcatheter arterial chemoembolization for hepatocellular carcinoma: anatomic and hemodynamic considerations in the hepatic artery and portal vein. *Radiographics*. 2002;22(5):1077-91.

20. Egorov VI, Yashina NI, Fedorov AV, Karmazanovsky GG, Vishnevsky VA, Shevchenko TV. Celiaco-mesenterial arterial aberrations in patients undergoing extended pancreatic resections: correlation of CT angiography with findings at surgery. *Jop*. 2010;11(4):348-57.

21. Iezzi R, Cotroneo AR, Giancristofaro D, Santoro M, Storto ML. Multidetector-row CT angiographic imaging of the celiac trunk: anatomy and normal variants. *Surg Radiol Anat*. 2008;30(4):303-10.

22. Prakash, Rajini T, Mokhasi V, Geethanjali BS, Sivacharan PV, Shashirekha M. Coeliac trunk and its branches: anatomical variations and clinical implications. *Singapore Med J*. 2012;53(5):329-31.

23. Mburu KS, Alexander OoJ, Hassan S, Bernard Nu. Variations in the branching pattern of the celiac trunk in a Kenyan population. *Int J Morphol*. 2010;28(1):199-204.

24. Thangarajah A, Parthasarathy R. Celiac axis, common hepatic and hepatic artery variants as evidenced on MDCT angiography in South Indian population. *J Clin Diagn Res.* 2016;10(1):Tc01-5.
25. Winston CB, Lee NA, Jarnagin WR, Teitcher J, DeMatteo RP, Fong Y, et al. CT angiography for delineation of celiac and superior mesenteric artery variants in patients undergoing hepatobiliary and pancreatic surgery. *AJR Am J Roentgenol.* 2007;189(1):W13-9.
26. Osman AM, Abdrabou A. Celiac trunk and hepatic artery variants: A retrospective preliminary MSCT report among Egyptian patients. *The Egyptian Journal of Radiology and Nuclear Medicine.* 2016;47(4):1451-8.
27. Vandamme J, Bonte J. The branches of the celiac trunk. *Cells Tissues Organs.* 1985;122(2):110-4.
28. Purushothama Raju N. Variants of coeliac trunk, hepatic artery and renal arteries in Puducherry Population Yash Kumar Achantani, Purushothama Raju N, Ramesh Kumar R. 2018.
29. Uflacker R. Atlas of vascular anatomy. An angiographic approach: Philadelphia. PA: Lippincott Williams; 1997.
30. CD C. Gray's Anatomy of the Human Body, 30th American ed. Philadelphia, PA: Lea & Febiger. 1984.
31. Yang SH, Yin YH, Jang J-Y, Lee SE, Chung JW, Suh K-S, et al. Assessment of hepatic arterial anatomy in keeping with preservation of the vasculature while performing pancreatoduodenectomy: an opinion. *World journal of surgery.* 2007;31(12):2384-91.

32. Covey AM, Brody LA, Maluccio MA, Getrajdman GI, Brown KT. Variant hepatic arterial anatomy revisited: digital subtraction angiography performed in 600 patients. *Radiology*. 2002;224(2):542-7.
33. Brasil IRC, de Araujo IF, Lima A, Melo ELA, Esmeraldo RM. Computed tomography angiography study of variations of the celiac trunk and hepatic artery in 100 patients. *Radiol Bras*. 2018;51(1):32-6.
34. Hiatt JR, Gabbay J, Busuttil RW. Surgical anatomy of the hepatic arteries in 1000 cases. *Annals of Surgery*. 1994;220(1):50-2.
35. Michels NA. Newer anatomy of the liver and its variant blood supply and collateral circulation. *The American Journal of Surgery*. 1966;112(3):337-47.
36. Seedat M, Van Niekerk A, Jewkes R, Suffla S, Ratele K. Violence and injuries in South Africa: prioritising an agenda for prevention. *The Lancet*. 2009;374(9694):1011-22.
37. Norman R, Matzopoulos R, Groenewald P, Bradshaw D. The high burden of injuries in South Africa. *Bulletin of the World Health Organization*. 2007;85:695-702.
38. Botha J, Spearman C, Millar A, Mitchell L, Gordon P, Lopez T, et al. Ten years of liver transplantation at Groote Schuur Hospital. *S Afr Med J*. 2000;90(9):880-3.
39. Krige J, Bernon M, Beningeld S. Modern management of colorectal liver metastases-e liver is the most frequent site of metastases from colorectal cancer. *Continuing Medical Education*. 2013;31(6):197-200.
40. Chacko A, Nyakale N, Ahmad S, Sathekge M, editors. Radioembolisation of hepatic metastases with yttrium90 microspheres: first reported series in South Africa2013: European Congress of Radiology 2013.

II. Full Text Journal Article For Submission

1. Cover Letter

Full Title:

Normal variations of coeliac and hepatic artery blood supply to the liver as identified on multidetector computed tomography (MDCT) studies at Groote Schuur Hospital, Western Cape Province, South Africa between 2018 and 2019.

Student Name: Dr Vengesai Muzenda
Student Number: mznven003
E-mail address: ***drvmuzenda@gmail.com***
Cell phone No.: +264813313181
Postal Address: P.O. Box 26752, Windhoek, Namibia
Supervisor: Dr Nazir Ahmed
Position: Consultant Radiologist
E-mail address: redhot007_za@yahoo.com
Cell phone No.: +27827758655
Postal Address: C16 Radiology Department
New Building GSH

Corresponding author: Kindly forward all correspondences to Dr Vengesai Muzenda at the above e-mail address.

Authors' contributions:

Dr V. Muzenda:

- Concept and design of the study and literature review.
- Protocol write-up and submission.
- CT images review and data collection.
- Drafting of manuscript.

Dr N. Ahmed:

- Approval of study proposal.
- Provision of literature review.
- Revising the literature review, protocol and final study for important intellectual content.

1.1 Acknowledgements:

Firstly, we would like to express our sincere gratitude to Professor Stephen Beningfield for editing this manuscript. We are also thankful to Dr Temba Christopher Sikwila for his invaluable contributions, expertise and assistance with this research. He could burn the midnight oil to critique my manuscript.

We are indebted to Dr Mike Chisha and Dr Innocent Vusimuzi Ncube who helped with image analysis.

We would like to express our appreciation to Michelle Henry for her contribution with statistical data analysis, Dr Napo Kasyire for her encouragement and assistance towards the study proposal. Lastly, I would like to thank my family, Sharon Muna and Anashe Shalom Muzenda for their support and encouragement.

Disclaimer: All views expressed in this article are our own and not an official position of the institution or funder.

Source(s) of support: No grants, equipment, drugs, and/or other support that facilitated conduct of the work described in the article or the writing of this article.

1.2 Word Count:

Literature review – 2232

Abstract – 248

Article – 3000

Number of Pages: 46

1.3 List of Tables:

Table 1: Normal and variant anatomy of the coeliac axis.	8
Table 2 : Uflacker’s classification of the coeliac trunk anatomical variations.	9
Table 3: Normal patterns and variations of the hepatic arterial system.....	10
Table 4: Modified Michels classification of the hepatic arterial system variations. .	11
Table 5:Frequency of coeliac axis variation subtypes according to Uflacker’s classification.	27
Table 6: Hepatic arterial anatomical variations.	28
Table 7: Frequency of coeliac axis, hepatic artery, coeliac axis and hepatic arterial variant anatomy by gender.	30
Table 8: Frequency of normal and variant anatomy of the coeliac axis, hepatic artery and coeliac axis and hepatic arterial system.	31
Table 9: Frequency of normal coeliac axis anatomy.....	32

1.4 List of Figures:

Figure 1: Normal coeliac axis and branches.....	5
Figure 2: Normal coeliac axis and hepatic artery.....	6
Figure 3: Schematic representation of hepatic arterial variation according to modified Michels classification.	11
Figure 4: Age distribution of sample	25
Figure 5: Frequency of normal coeliac axis, hepatic artery and coeliac axis and.....	26
Figure 6: Absent coeliac axis.	33
Figure 7: Volume Rendering Images.	34
Figure 8 (a) and (b): Quadrifurcation of the coeliac axis.	34
Figure 9: (a) Porto-caval space.....	35
Figure 10: Gastroduodenal artery arises off the splenic artery.....	36
Figure 11: Pancreaticoduodenal arcade with a single channel connection between the CHA and SMA.	37

Title: Normal variations of coeliac and hepatic artery blood supply to the liver as identified on multidetector computed tomography (MDCT) studies at Groote Schuur Hospital, Western Cape Province, South Africa between 2018 and 2019.

2. Abstract

Background:

Variant anatomy of the coeliac axis and hepatic arterial system is not uncommon. With the evolution of new minimally invasive surgical techniques and endovascular hepatic therapies, the interventional radiologist and surgeon should have a good knowledge of the normal and variant anatomy to optimize treatment and minimise iatrogenic vascular liver injuries.

Objectives:

To analyse and describe the prevalence of normal and variant anatomy of the coeliac axis (CA) and hepatic arterial (HA) system.

Methods:

A total of 300 MDCT angiography studies performed during a two-year period at Groote Schuur Hospital, Western Cape Province, South Africa were retrospectively reviewed.

Results:

The CA and HA variations were analysed according to Uflacker's and Michels classifications respectively. A normal CA was seen in 88.3% (n=265) of patients. The most common variant anatomy was the hepatosplenic trunk, seen in 2% (n=6). 3% (n=9) of patients could not be classified according to Uflacker's classification. A normal HA was seen in 55% (n=165). The most common variant hepatic anatomy was the accessory LHA seen in 12.7% (n=38). 30.7% (n=92) of HA variant anatomy could be classified and the remaining 14.3% (n=43) could not. Double hepatic artery (2.7%; n=8) and CHA trifurcations (5.3%; n=16) were the most common variants of the unclassified variants.

Conclusion:

Variant CA and HA anatomy is very common. We demonstrated a greater prevalence of an accessory LHA than that reported in the literature. Although the prevalence of the rest of the variant anatomy was comparable to other studies, a few previously undescribed variants were also identified.

Keywords:

Variant anatomy; coeliac axis; hepatic arterial system; prevalence; MDCT angiography.

3. Introduction

Variant anatomy of the coeliac axis and hepatic arterial system is not uncommon. Reported normal anatomy of the coeliac axis and hepatic artery is between 51 and 90% (1-6). Multidetector computed tomography (MDCT) angiography has an anatomical accuracy rate of 97-98 % (7, 8). MDCT angiography is readily available, is fast, has high spatial resolution and is non-invasive when compared with DSA. Additional advantages of MDCT angiography over DSA are a significantly reduced amount of contrast medium and the ability to assess the relationship between solid organs and the vasculature (2, 9). Hence, MDCT angiography has by and large replaced digital subtraction angiography as the first line of investigation in determining vascular anatomy of the hepatic artery prior to interventional procedures or surgery of the liver.

The success of liver transplantation surgery depends on preservation of the hepatic arterial blood flow. Furthermore, treatment of advanced primary and metastatic liver tumours has evolved, with some patients benefitting from interventional procedures such as intra-arterial chemotherapy, chemo-embolisation and/or radio-embolisation (1, 10-13). South Africa is ranked the highest on the African continent in terms of trauma and violence-related injuries (14, 15). Hepatic artery embolisation is a well-recognised invaluable procedure in trauma patients with hepatic arterial injury (16). The coeliac axis is initially cannulated and super-

selective catheterisation of the hepatic artery is critical in treating traumatic hepatic arterial injury. Its advantages include shorter hospital stay, reduced risks of infections and it is a less invasive procedure.

For optimal treatment of the aforementioned hepatic conditions and prevention of iatrogenic liver injury, interventional radiologists and surgeons should have a good knowledge of the different CA and hepatic artery variant anatomy. There are currently no documented studies of the South African population pertaining to the anatomical variations of the coeliac axis and hepatic arterial system. It was therefore felt to be relevant to investigate the prevalence of the normal and variant anatomy of the coeliac axis and hepatic arterial system in the Groote Schuur Hospital population located in Cape Town in the Western Cape Province of South Africa.

4. Research Methods and Study Design

4.1.1 Study design

The study involved a retrospective review with both quantitative and qualitative components.

4.1.2 Sampling / Inclusion criteria

All patients who underwent a CT angiogram of the abdomen, the thoracic and abdominal aorta and routine contrast CT of the abdomen between January 2018 and December 2019 at Groote Schuur Hospital, a tertiary academic hospital in the Western Cape Province of South Africa were included in the study.

Exclusion criteria:

1. Patients known with or newly diagnosed with an abdominal aortic aneurysm and aortic dissection which may distort coeliac axis anatomic details.

2. Previous major abdominal surgery such as Whipple's procedure or gastrectomy.
3. Extensive abdominal aortic atherosclerosis.
4. Major abdominal trauma with retained metallic foreign bodies.
5. Suboptimal studies with poor arterial system opacification.

4.1.3 Data collection

Patients were identified by searching for specific phrases in radiology reports on the Groote Schuur Philips Picture Archiving and Communicating System, (PACS) which were: "CTA abdomen", "CTA thoracic and abdominal aorta" and "contrasted CT abdomen."

Data were recorded in Microsoft Excel where a study number cypher system was used to protect patient confidentiality.

Three radiology registrars with 4-6 years' experience in analysing CT images and vascular studies independently interpreted the CT images with respect to the anatomy of the coeliac axis and hepatic arterial system. The primary investigator initially performed double reading of the images and the other two registrars performed a single read. In the event of discrepancy, the CT images were carefully reviewed again to attain consensus.

4.1.4 Data analysis

The study population included male and female patients who had undergone an MDCT abdominal aorta angiogram or contrasted CT abdomen at Groote Schuur Hospital, Western Cape Province in South Africa between January 2018 and December 2019.

2316 studies met the search criteria and the first 300 studies were selected, evaluated and analysed.

Trauma was the indication in approximately 54 % (n=162) of the selected studies.

The collected data were classified according to Uflacker's (*Table 2*) and Michels (*Table 4*) classifications.

The data was then entered on an Excel spreadsheet, with variations of the coeliac axis and hepatic artery noted as being either present or absent. The frequency of

each variant branching pattern was calculated (as a summation of all the subjects with that variation) and converted into percentages.

4.1.5 Ethical considerations

Ethical approval was granted by the Human Research Ethics Committee of the University of Cape Town. HREC Ref 181/2020 (Appendix 1).

Hospital Research Board permission was sought and granted (Appendix 2).

5. Results

Of the 300 patients, 74% (n=222) were male and 26% (n=78) were female. The mean age was 36.8 years (SD = 14.3, Range = 13-79 years). The majority of the sample fell between 20-49 years of age (n=221; 74%). See Figure 4 below.

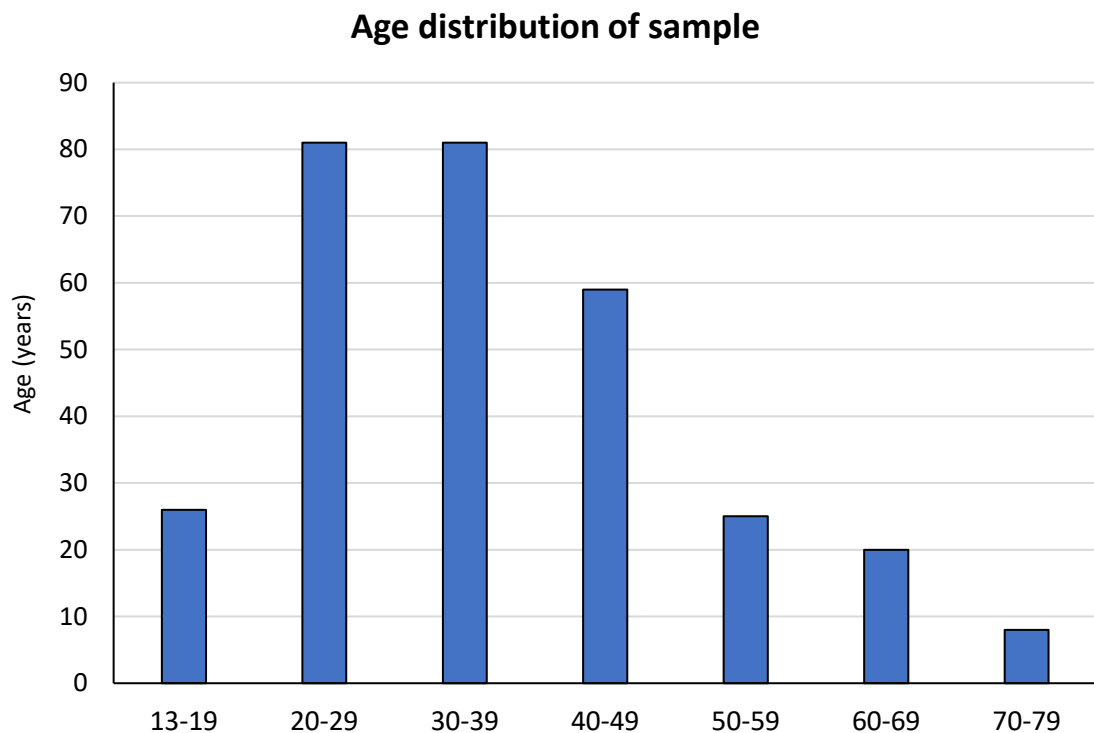


Figure 4: Age distribution of sample

88.3 % (n=265) of the subjects had a normal coeliac axis (type 1) configuration, according to Uflacker's classification and 55% (n=165) had a normal hepatic arterial

system (type 1) morphology in terms of Michels classification. 52.7% (n=158) had both a normal coeliac axis and hepatic arterial system (see figure 5 below).

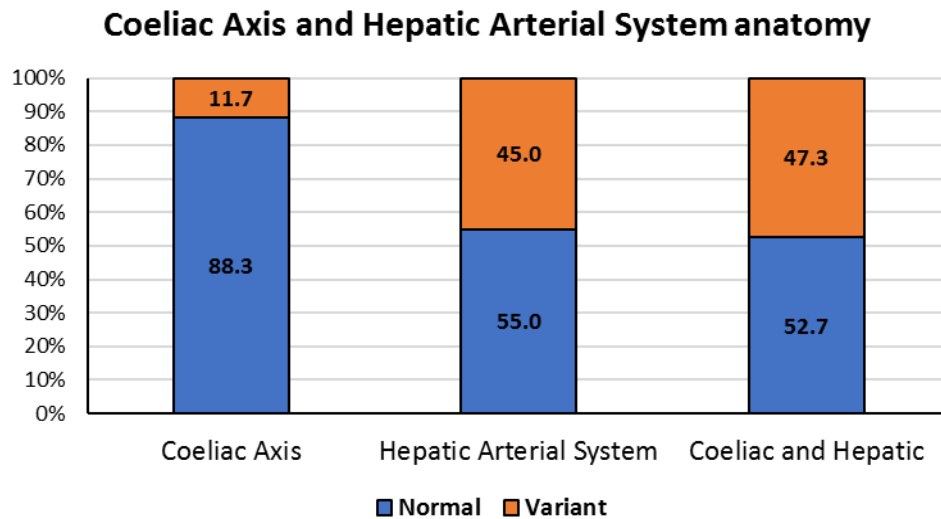


Figure 5: Frequency of normal coeliac axis, hepatic artery and coeliac axis and hepatic arterial system.

8.7% (n=26) of patients demonstrated a variation of the coeliac axis according to the Uflacker's classification (type II to type VII) with type V (3%; n=9) being the most frequent and types IV and VII the least frequent (0%; n=0). (Table 5)

An absent coeliac axis was seen in 1% (n=3) of the patients in our study population. 3% (n=9) of the patients had quadrifurcation of the coeliac axis, which is not classified as a subtype in Uflacker's classification.

Coeliac axis variation	Subtypes	% of patients (n)
Normal	I	88.3% (265)
Hepatosplenic trunk	II	2% (6)
Hepatogastric trunk	III	1% (3)
Hepatosplenomesenteric trunk	IV	0% (0)
Gastrosplenic trunk	V	3% (9)
Coeliac-mesenteric trunk	VI	1.7% (5)
Coeliac-colic trunk	VII	0% (0)
No coeliac trunk	VIII	1% (3)
NOS		3% (9)
Total		100% (300)

Table 5: Frequency of coeliac axis variation subtypes according to Uflacker's classification. (NOS Not otherwise specified)

Hepatic artery variation	Subtype	% of patients (n)
Normal anatomy	I	55 (165)
Replaced LHA originating from the LGA	II	3.7 (11)
Replaced RHA originating from the SMA	III	6.3 (19)
Co-existence of Type I and Type II	IV	0 (0)
Accessory LHA originating from the LGA	V	12.7 (38)
Accessory RHA originating from the SMA	VI	1.3 (4)
Co-existence of the accessory LHA and accessory RHA	VII	0.7 (2)
Accessory LHA from the LGA and replaced RHA from SMA	VIII	3.3 (10)
CHA from the SMA	IX	2.7 (8)
RHA and LHA from the LGA	X	0 (0)
UNCLASSIFIED:		
CHA off the SMA and Accessory LHA		0.7 (2)
PHA off the SMA, GDA off the Splenic artery		0.7(2)
Trifurcation of CHA		5.3(16)
Trifurcation of CHA and Accessory RHA		0.3(1)
Distal or “late” take-off of the GDA		3 (9)
Replaced LHA and Accessory RHA		0.7 (2)
Double hepatic artery		2.7 (8)
Double hepatic artery and accessory LHA		0.3 (1)
Accessory LGA off the PHA		0.3 (1)
Direct communication between SMA and GDA		0.3 (1)

Table 6: Hepatic arterial anatomical variations.

30.7% (n=92) of patients demonstrated a variation of the hepatic artery according to Michels classification (type II to IX), with type V being the most common (12.7%; n=38) and types IV and X being the least frequent (0%; n=0). (See Table 6)

14.3% (n=43) patients did not conform with Michels classification and were documented as unclassified.

Within this category, the trifurcation of the CHA was the most frequent (5.3%; n=16), followed by the distal or “late” take-off of the GDA (3%; n=9) and the double hepatic artery (2.7%; n=8). In distal or “late” take-off of the GDA, the common hepatic artery divides into left and right hepatic artery with the GDA originating from either the RHA or LHA. The proper hepatic artery is absent in this branching pattern. This is differentiated from the double hepatic artery, where both right and left hepatic arteries originate directly from the coeliac axis with the GDA emerging as a branch from either the LHA or RHA (17). The CHA is absent.

The percentage with trifurcations of the CHA into GDA, LHA and RHA was 5.3% (n=16), which is not considered a variant by most authors but could have serious implications in endovascular procedures and open surgery. This variant anatomy was reported in 8.3% by Covey et al(17) in their series, while Vandamme et al found it in only 2%.

Double hepatic artery is defined as separate origins of the RHA and LHA either from the CA or directly from the aorta. The GDA then arises from either the LHA or the RHA. In our series, 3% (n=9) of the patients had a double hepatic artery arising from the coeliac axis and the GDA was always a branch of the LHA. In one patient with a double hepatic artery, there was also an additional accessory LHA variant.

Distal or late take-off of the GDA can be differentiated from the double hepatic artery by the presence of the CHA, with the GDA emerging distally from either the RHA or the LHA. 3% (n=9) patients had late take-off of the GDA. In 1.5% (n=5) of patients, the GDA originated from the RHA and in the remaining 1.2% (n=4), from the LHA.

Other uncommon variant anatomy that has not been described elsewhere include a combined CHA originating from SMA with an accessory LHA off the LGA, which was seen in 0.7% (n=2) patients.

In 0.7% (n=2) patients, the PHA arose from the SMA with the GDA originating from either the gastrosplenic common trunk or the splenic artery in a second patient.

0.7% (n=2) of patients also demonstrated a replaced LHA and an accessory RHA.

There was no significant association between gender and variation in the hepatic arterial system ($p= 0.412$) or the coeliac axis and hepatic arterial system combined ($p=0.301$). However, a significantly higher proportion of males had a variant anatomy of the coeliac axis compared to females ($p=0.037$) (*Table 7*).

	Gender		Statistics		
	Male n = 222	Female n = 78	χ^2	<i>P</i>	<i>V</i>
Coeliac Axis Anatomy			4.37	0.037	0.12
Normal	191 (86%)	74 (94.9%)			
Variant	31 (14%)	4 (5.1%)			
Hepatic Arterial System			0.67	0.412	0.05
Normal	119 (53.6%)	46 (59%)			
Variant	103 (46.4%)	32 (41%)			
Coeliac and Hepatic			1.07	0.301	0.06
Normal	113 (50.9%)	45 (57.7%)			
Variant	109 (49.1%)	33 (42.3%)			

Note: Data presented are actual numbers with proportions in parentheses. *V* = Cramer's *V* (effect size for a chi-square test).

Table 7: Frequency of coeliac axis, hepatic artery, coeliac axis and hepatic arterial variant anatomy by gender.

There was no significant statistical difference in age between those with normal and variant coeliac axis, hepatic artery anatomy, or coeliac axis and hepatic artery anatomy combined (*see Table 8*).

	Variation				Statistics		
	Normal		Abnormal		<i>t</i>	<i>p</i>	<i>d</i>
	n	M (SD)	n	M (SD)			
Coeliac Axis Anatomy	265	36.8 (14.4)	35	36.7 (14.3)	-0.04	0.969	0.01
Hepatic Arterial System	165	36.4 (13.3)	135	37.3 (15.5)	0.55	0.585	0.04
Coeliac and Hepatic	158	36.3 (13.4)	142	37.4 (15.3)	0.66	0.510	0.05

Note. *d* = Cohen's *d* (effect size for an independent sample t-test).

Table 8: Frequency of normal and variant anatomy of the coeliac axis, hepatic artery and coeliac axis and hepatic arterial system.

6. Discussion

CT is performed in many patients with colorectal, hepatic and pancreatic tumours to confirm and stage the disease, as well as to formulate an appropriate management plan. Additionally, patients in acute settings such as following trauma and who are deemed haemodynamically stable or otherwise at risk, also undergo MDCT angiography studies. The latter constituted 54% of our study population. DSA was regarded as the gold standard for angiographic studies in prior work, but MDCT has almost completely replaced DSA as the first line of investigation in hepatic vascular studies because of its non-invasive nature, speed and easy accessibility. Images are acquired in a single breath-hold as thin-slice high-resolution axial images and multiplanar reconstruction (MPR), maximal intensity projection (MIP) and volume rendered 3D images are reconstructed (4). These images are used as a roadmap in hepatobiliary surgery, liver transplants and hepatic endovascular procedures such as intra-arterial chemotherapy and coil embolisation (2).

The coeliac axis is the first visceral branch of the abdominal aorta and it emerges at T12/L1 level. After a short distance, it typically divides into the LGA, splenic artery and CHA. The CHA takes an oblique course with a gentle superiorly concave curve,

coursing to the right at the superior margins of the pancreatic head until it reaches the foramen of Winslow. It then splits into the GDA and PHA (18).

The PHA ascends within the hepatoduodenal ligament on the left of the common bile duct and anterior to the portal vein (19). It eventually splits into the left hepatic and right hepatic artery at the hepatic hilum or some distance away from the hilum. The middle hepatic artery perfumes segment IV of the liver. It arises from either the right or the left hepatic artery (20, 21). However, the presence or absence of the middle hepatic artery was regarded as normal by other authors (17).

Uflacker described eight different variations in the coeliac axis (22).

We identified a normal branching pattern of the coeliac axis in 88.3% (n= 265) of our study population. This frequency correlates with that found in studies performed by Song et al. (89.1%) as well as many other studies (1, 2, 21, 23-30). (Table 9.)

Author	n	Frequency (%)
Muzenda et al (2020)	300	88.3
Song et al (2010)(1)	5002	89.1
Ugurel et al (2010)(21)	100	89
Thangarajah et al (2016)(23)	200	89.5
Araujo et al (2015)(24)	60	90
Panagouli et al (2013)(25)	12196	89.42
Michels textbook (1966)(26)	200	89
Chen et al (2009)(27)	974	89.8
Arifuzzaman et al (2017)(28)	110	88.2
Vandamme and Bonte (1985)(29)	156	85.9
Selvaraj et al (2015)(30)	75	90.6
Lezzi et al (2008)(2)	524	87.6

Table 9: Frequency of normal coeliac axis anatomy.

In his meta-analysis of “no coeliac axis reports”, Bergman et al. (31) found that the absence of the coeliac axis is a very rare variant with a frequency of 0.4%. However, our study found a higher prevalence of 1% (n=3) (*Figure 6*), which was in agreement with the 1% (n=1) reported by Ugurel et al. (21).

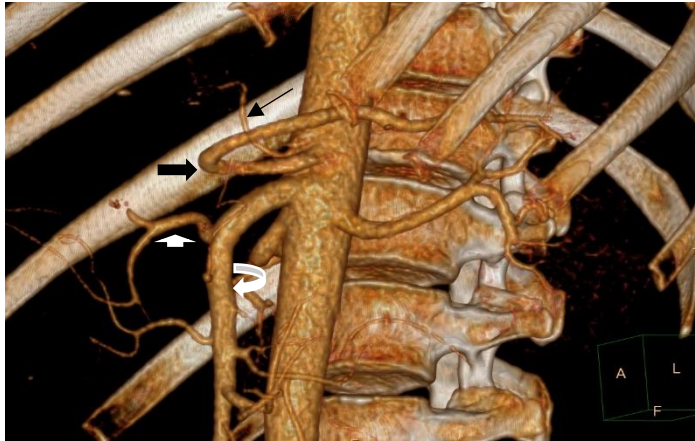


Figure 6: Absent coeliac axis.

Left gastric artery (long thin black arrow); Splenic artery (black arrow); Replaced CHA (short thick white arrow) and SMA (curved white arrow).

The three most common coeliac axis variant anatomies in our study are gastrosplenic trunk (3%; n=9), hepatosplenic trunk (2%; n=6) and coeliac-mesenteric trunk (1.7%; n=5). Oran et al. (32) reported a rare variant where the splenic artery formed a common trunk with the superior mesenteric artery (splenomesenteric trunk) and the common hepatic artery and left gastric artery formed the hepatogastric trunk. In our study population, 1% (n=3) of patients demonstrated hepatogastric trunk; 0.7% (n=2) of patients had a splenomesenteric trunk and in 0.3% (n=1) of patients (*Figure 7*), the splenic artery emerged directly from the aorta.

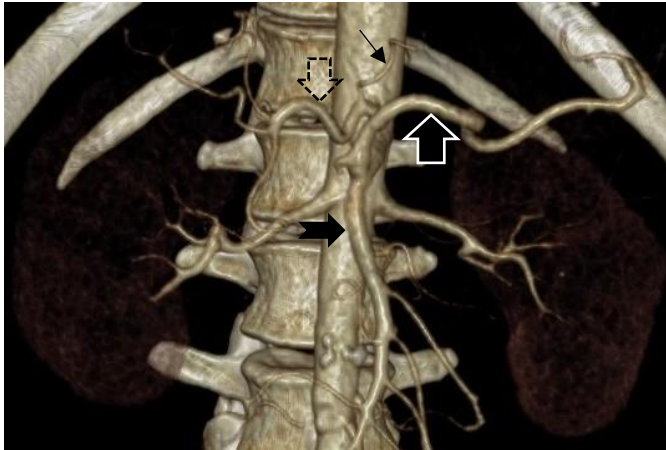
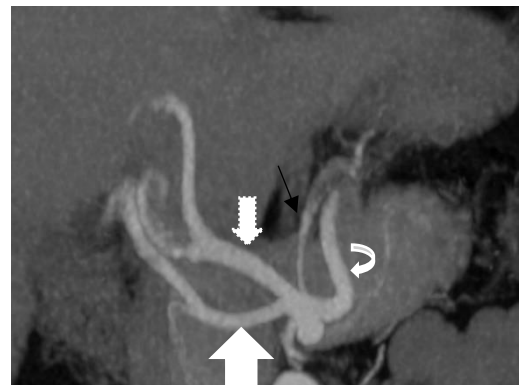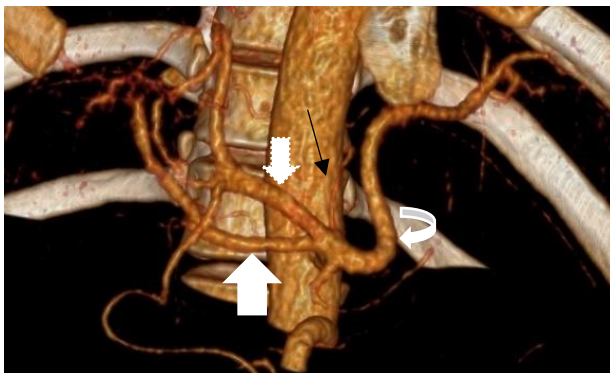


Figure 7: Volume Rendering Images.

Splenic artery (thick white outline black arrow) originating from the SMA (short black arrow). LGA (thin black arrow) and CHA (broken black arrow)

White et al. (9) reported that quadrifurcation of the CA due to separate origins of the RHA and LHA, is seen in 9.7% of the population. In our population sample, 3% (n=9) patients demonstrated quadrifurcation of the coeliac axis with the GDA originating from the LHA. (Fig 8a and 8b)



(a)

(b)

Figure 8 (a) and (b): Quadrifurcation of the coeliac axis.

Splenic artery (curved arrow); LGA (thin long arrow); LHA (dotted white arrow) and RHA (wide white arrow).

Both the coeliac axis and hepatic artery had a normal branching pattern in 52.7% (n=158) in our series. Ugurel et al. (21) in their series, found 50% of patients demonstrating normal branching pattern of the coeliac axis and hepatic artery.

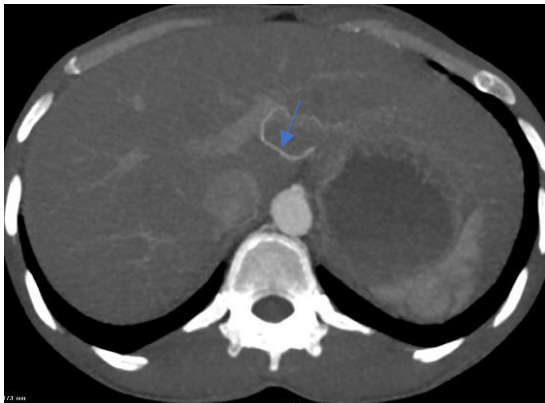
Michels classification described 10 variant subtypes of the branching pattern of the hepatic arteries (26). Normal hepatic artery configuration is reported in 51-80% (4, 5, 17, 21, 27, 28) In our study, 55% (n=165) patients demonstrated normal hepatic

artery morphology, thus lying on the lower end of this prevalence range. This correlates more closely with studies performed by Ugurel; et al. (52%), Thangarajah et al. (57%) and Covey et al. (61.3%) (17, 21, 23). Studies by Winston et al.(4), Ugurel et al. (21) and Kamel et al. (33) found the type III variant (replaced RHA originating from the SMA) as described in Michels classification to be the most common. In our series, the type V variant (accessory LHA originating from the LGA) was the most common variant with 12.7%(n=38). The replaced right hepatic artery originating from the SMA (type III) was the second most common variant identified in 6.3% (n=19) patients. The replaced or accessory RHA almost always traverses the portocaval space (*Fig. 9a*) while the replaced or accessory LHA traverses the fissure of ligamentum venosum (*Fig. 9b*) (34).

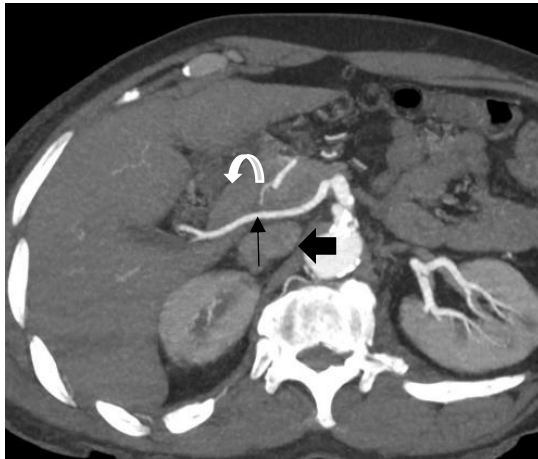

Figure 9: (a) Porto-caval space.

Replaced RHA within the portocaval space (long thin black arrow). IVC (short thick black arrow). Portal vein (curved white arrow).



9(b) fissure of ligamentum venosum.
 Accessory LHA traversing the fissure of ligamentum venosum (thin long blue arrow).

The third most common variant in our study was the unclassified trifurcation of the CHA at 5.3% (n=16). This variant was not included in Michels classification system. Another unclassified variant was a combination of the CHA arising from the SMA and an accessory LHA, seen in two cases (0.7%; n=2). To our knowledge, this variant anatomy identified in our study has not been described.

Covey et al. (17) described another rare variant, viz the PHA (0.3%; n=2) originating from the SMA, with a separate origin of the GDA directly from the aorta. A similar prevalence was noted in our study (0.7%; n=2). In one patient, the GDA originated as a branch from the splenic artery and in another from the gastrosplenic trunk, instead of from the aorta. (*Figure 10*)

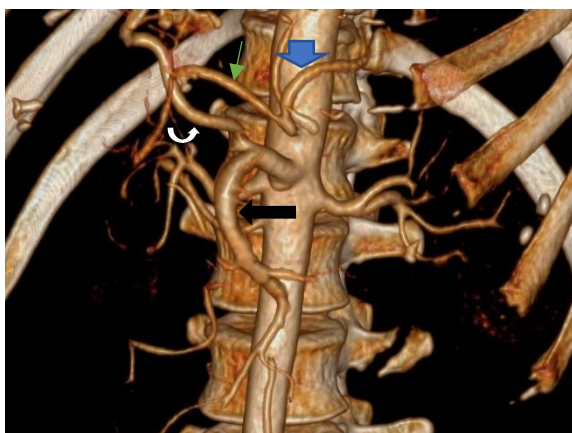


Figure 10: Gastroduodenal artery (GDA-thin green arrow) arises off the splenic artery (short blue arrow). Long black arrow -SMA, white curved arrow- PHA originating from the SMA.

Another uncommon but important variant is the double hepatic artery which was describe by Frasel et al., Covey et al., Kapoor et al. and Winston et al. (4, 17, 35, 36). Double hepatic artery is present when one or both hepatic arteries arise from the either the coeliac axis directly or the aorta. The CHA is absent in this branching pattern.

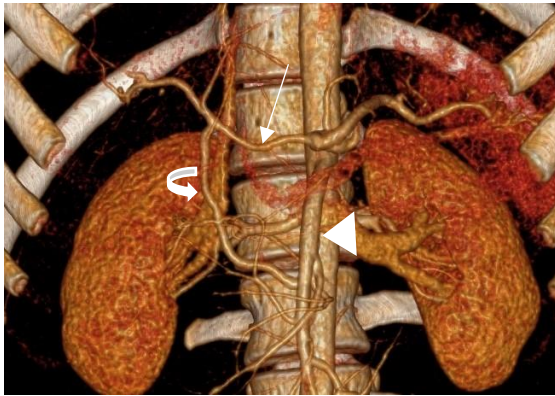
The double hepatic artery variant is distinguished from the distal or “late” take-off of the GDA by the presence of the CHA. In our series, 2.7% (n=8) and 3% (n=9) of patients had a double hepatic artery and distal origin of the GDA respectively. The frequency of the double hepatic artery and distal GDA origin were 3.7% and 4.2% respectively in Covey et al. series (17) which correlates fairly closely with our findings.

Other very rare variants were a pancreaticoduodenal arcade that developed as a single channel between the SMA and GDA (n=1) (*Figure 11*); and an accessory LGA arising from the PHA (n=1). To our knowledge the latter variant has not been reported.

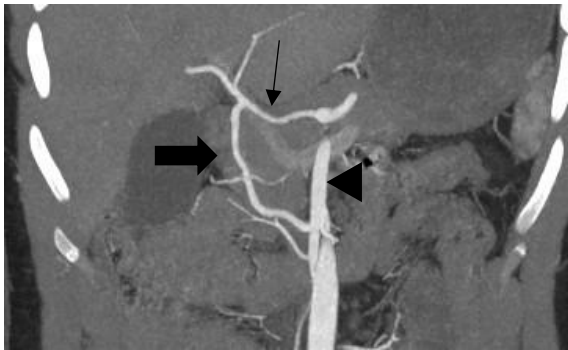

Figure 11: Pancreaticoduodenal arcade with a single channel connection between the CHA and SMA.

(a) Common hepatic artery (thin black arrow), gastroduodenal artery (thick black arrow) and superior mesenteric artery (black arrowhead).



(c) Common hepatic artery (thin white arrow), gastroduodenal artery (curved white arrow) and superior mesenteric artery (white arrowhead).

It should be noted that in the original article by Michels (26), from which the Michel's classification of hepatic artery variations originates, a middle hepatic artery is described for seven of the 10 anatomic variations. The middle hepatic artery is seldom mentioned in the literature or in radiological reports, though a variant blood supply to segment IV of the liver is very important for the donor rather than the recipient in liver transplant surgeries (20, 21).

6.1 Strengths and limitations:

The major strength of our study was the large population sample.

Limitations to our study design was the unavailability of DSA angiographic confirmation of the CTA findings.

This was a retrospective study.

6.2 Recommendations

1. Knowledge of the coeliac axis and hepatic arterial system anatomy and its variations cannot be overemphasized. Thus, information should be included in all radiological reports where necessary.
2. Similar studies in other South African populations need to be performed to determine the prevalence of the novel variants identified in this study.

7. Conclusion

Our study has demonstrated that the variant anatomy of the coeliac axis and hepatic artery separately and in combination is common (11.7%, 45% and 47.3% respectively). Most of our findings correlate with the various studies cited, although novel unclassified variants were identified specifically pertaining to the hepatic arterial system.

Ten variants identified during this study, representing 14.3% of the hepatic artery variants, could not be classified using Michels classification system. Similar studies within the South African population are recommended to establish whether the frequency of these findings is significant enough to warrant a modification of Michels classification.

8. References

1. Song S-Y, Chung JW, Yin YH, Jae HJ, Kim H-C, Jeon UB, et al. Celiac axis and common hepatic artery variations in 5002 patients: systematic analysis with spiral CT and DSA. *Radiology*. 2010;255(1):278-88.
2. Iezzi R, Cotroneo AR, Giancristofaro D, Santoro M, Storto ML. Multidetector-row CT angiographic imaging of the celiac trunk: anatomy and normal variants. *Surg Radiol Anat*. 2008;30(4):303-10.
3. Prakash, Rajini T, Mokhasi V, Geethanjali BS, Sivacharan PV, Shashirekha M. Coeliac trunk and its branches: anatomical variations and clinical implications. *Singapore Med J*. 2012;53(5):329-31.
4. Winston CB, Lee NA, Jarnagin WR, Teitcher J, DeMatteo RP, Fong Y, et al. CT angiography for delineation of celiac and superior mesenteric artery variants in patients undergoing hepatobiliary and pancreatic surgery. *AJR Am J Roentgenol*. 2007;189(1):W13-9.
5. Egorov VI, Yashina NI, Fedorov AV, Karmazanovsky GG, Vishnevsky VA, Shevchenko TV. Celiaco-mesenterial arterial aberrations in patients undergoing extended pancreatic resections: correlation of CT angiography with findings at surgery. *Jop*. 2010;11(4):348-57.
6. Hiatt JR, Gabbay J, Busuttil RW. Surgical anatomy of the hepatic arteries in 1000 cases. *Annals of Surgery*. 1994;220(1):50-2.
7. Sahani D, Saini S, Pena C, Nichols S, Prasad SR, Hahn PF, et al. Using multidetector CT for preoperative vascular evaluation of liver neoplasms: technique and results. *American Journal of Roentgenology*. 2002;179(1):53-9.

8. Takahashi S, Murakami T, Takamura M, Kim T, Hori M, Narumi Y, et al. Multi-detector row helical CT angiography of hepatic vessels: Depiction with dual-arterial phase acquisition during single breath hold. *Radiology*. 2002;222(1):81-8.
9. White RD, Weir-McCall JR, Sullivan CM, Mustafa SAR, Yeap PM, Budak MJ, et al. The celiac axis revisited: anatomic variants, pathologic features, and implications for modern endovascular management. *RadioGraphics*. 2015;35(3):879-98.
10. Vogl TJ, Zangos S, Eichler K, Yakoub D, Nabil M. Colorectal liver metastases: regional chemotherapy via transarterial chemoembolization (TACE) and hepatic chemoperfusion: an update. *European radiology*. 2007;17(4):1025-34.
11. Varela M, Real MI, Burrel M, Forner A, Sala M, Brunet M, et al. Chemoembolization of hepatocellular carcinoma with drug eluting beads: efficacy and doxorubicin pharmacokinetics. *Journal of hepatology*. 2007;46(3):474-81.
12. Allison D, Jordan H, Hennessy O. Therapeutic embolisation of the hepatic artery: a review of 75 procedures. *The Lancet*. 1985;325(8429):595-9.
13. Kennedy A, Nag S, Salem R, Murthy R, McEwan AJ, Nutting C, et al. Recommendations for radioembolization of hepatic malignancies using yttrium-90 microsphere brachytherapy: a consensus panel report from the radioembolization brachytherapy oncology consortium. *International Journal of Radiation Oncology* Biology* Physics*. 2007;68(1):13-23.
14. Seedat M, Van Niekerk A, Jewkes R, Suffla S, Ratele K. Violence and injuries in South Africa: prioritising an agenda for prevention. *The Lancet*. 2009;374(9694):1011-22.
15. Norman R, Matzopoulos R, Groenewald P, Bradshaw D. The high burden of injuries in South Africa. *Bulletin of the World Health Organization*. 2007;85:695-702.

16. Forlee M, Krige J, Welman C, Beningfield S. Haemobilia after penetrating and blunt liver injury: treatment with selective hepatic artery embolisation. *Injury*. 2004;35(1):23-8.
17. Covey AM, Brody LA, Maluccio MA, Getrajdman GI, Brown KT. Variant hepatic arterial anatomy revisited: digital subtraction angiography performed in 600 patients. *Radiology*. 2002;224(2):542-7.
18. Favelier S, Germain T, Genson P-Y, Cercueil J-P, Denys A, Krausé D, et al. Anatomy of liver arteries for interventional radiology. *Diagnostic and interventional imaging*. 2015;96(6):537-46.
19. Butler P, Mitchell AWC, Healy CJ. *Applied Radiological Anatomy*. Cambridge: Cambridge University Press; 2012.
20. Catalano OA, Singh AH, Uppot RN, Hahn PF, Ferrone CR, Sahani DV. Vascular and biliary variants in the liver: implications for liver surgery. *Radiographics*. 2008;28(2):359-78.
21. Ugurel MS, Battal B, Bozlar U, Nural MS, Tasar M, Ors F, et al. Anatomical variations of hepatic arterial system, coeliac trunk and renal arteries: an analysis with multidetector CT angiography. *The British Journal of Radiology*. 2010;83(992):661-7.
22. Uflacker R. *Atlas of vascular anatomy. An angiographic approach*: Philadelphia. PA: Lippincott Williams; 1997.
23. Thangarajah A, Parthasarathy R. Celiac axis, common hepatic and hepatic artery variants as evidenced on MDCT angiography in South Indian Population. *J Clin Diagn Res*. 2016;10(1):Tc01-5.
24. Araujo Neto SA, Franca HA, de Mello Júnior CF, Silva Neto EJ, Negromonte GRP, Duarte CMA, et al. Anatomical variations of the celiac trunk and hepatic arterial

system: an analysis using multidetector computed tomography angiography. *Radiologia Brasileira*. 2015;48(6):358-62.

25. Panagouli E, Venieratos D, Lolis E, Skandalakis P. Variations in the anatomy of the celiac trunk: a systematic review and clinical implications. *Annals of Anatomy-Anatomischer Anzeiger*. 2013;195(6):501-11.

26. Michels NA. Newer anatomy of the liver and its variant blood supply and collateral circulation. *The American Journal of Surgery*. 1966;112(3):337-47.

27. Chen H, Yano R, Emura S, Shoumura S. Anatomic variation of the celiac trunk with special reference to hepatic artery patterns. *Annals of Anatomy-Anatomischer Anzeiger*. 2009;191(4):399-407.

28. Arifuzzaman M, Nasim Naqvi SS, Adel H, Adil SO, Rasool M, Hussain M. Anatomical variants of celiac trunk, hepatic and renal arteries in a population of developing country using multidetector computed tomography angiography. *J Ayub Med Coll Abbottabad*. 2017;29(3):450-4.

29. Vandamme J, Bonte J. The branches of the celiac trunk. *Cells Tissues Organs*. 1985;122(2):110-4.

30. Selvaraj L, Sundaramurthi I. Study of normal branching pattern of the coeliac trunk and its variations using CT angiography. *Journal of clinical and diagnostic research : JCDR*. 2015;9(9):AC01-AC4.

31. Bergman RA. Illustrated encyclopedia of human anatomic variation. <http://www.anatomyatlases.org/AnatomicVariants/MuscularSystem/Text/P/08Pectoralis.shtml>. 2007.

32. Oran I, Yesildag A, Memis A. Aortic origin of right hepatic artery and superior mesenteric origin of splenic artery two rare variations demonstrated angiographically. *Surgical and Radiologic Anatomy*. 2001;23(5):349-52.
33. Kamel IR, Kruskal JB, Pomfret EA, Keogan MT, Warmbrand G, Raptopoulos V. Impact of multidetector CT on donor selection and surgical planning before living adult right lobe liver transplantation. *American Journal of Roentgenology*. 2001;176(1):193-200.
34. Lee JY, Chung JW, Kim TK, Cho SW, Cho JY, Park JH. Diagnosis of Normal Variation of Hepatic Artery on Axial Image of Spiral CT: Importance of a vascular structure in a portocaval space and fissure of ligamentum venosum. *Journal of the Korean Radiological Society*. 1997;37(3):473-8.
35. Kapoor V, Brancatelli G, Federle MP, Katyal S, Marsh JW, Geller DA. Multidetector CT arteriography with volumetric three-dimensional rendering to evaluate patients with metastatic colorectal disease for placement of a floxuridine infusion pump. *American Journal of Roentgenology*. 2003;181(2):455-63.
36. Fasel JH, Muster M, Gailloud P, Mentha G, Terrier F. Duplicated hepatic artery: radiologic and surgical implications. *Cells Tissues Organs*. 1996;157(2):164-8.

III Appendix

(a) Original Ethics Approval



UNIVERSITY OF CAPE TOWN
Faculty of Health Sciences
Human Research Ethics Committee



Room G50- Old Main Building
Groote Schuur Hospital
Observatory 7925
Telephone (021) 406 6492
Email: hrec-enquiries@uct.ac.za

Website: www.health.uct.ac.za/fhs/research/humanethics/forms

Yours sincerely

Signature Removed

PROFESSOR M BLOCKMAN
CHAIRPERSON, FHS HUMAN RESEARCH ETHICS COMMITTEE

Federal Wide Assurance Number: FWA00001637.
Institutional Review Board (IRB) number: IRB00001938
NHREC-registration number: REC-210208-007

This serves to confirm that the University of Cape Town Human Research Ethics Committee complies to the Ethics Standards for Clinical Research with a new drug in patients, based on the Medical Research Council (MRC-SA), Food and Drug Administration (FDA-USA), International Council for Harmonisation of Technical Requirements for Pharmaceuticals for Human Use; Good Clinical Practice (ICH GCP), South African Good Clinical Practice Guidelines (DoH 2006), based on the Association of the British Pharmaceutical Industry Guidelines (ABPI), and Declaration of Helsinki (2013) guidelines. The Human Research Ethics Committee granting this approval is in compliance with the ICH Harmonised Tripartite Guidelines E6: Note for Guidance on Good Clinical Practice (CPMP/ICH/135/95) and FDA Code Federal Regulation Part 312, 314.12 and 312.61.

2nd April 2020

HREC REF: 181/2020

Dr N Ahmed
Radiology
c/o Prof Benningfield's Office
C16, NGSH
Email: radh007_za@yahoo.com
Copy to student researcher: dymuzenda@gmail.com

Dear Dr Ahmed

PROJECT TITLE: NORMAL AND VARIANT ANATOMY OF THE COELIC AXIS AND HEPATIC ARTERY AS IDENTIFIED ON MULTIDETECTOR COMPUTED TOMOGRAPHY (MDCT) STUDIES AT GROOTE SCHUUR HOSPITAL, WESTERN CAPE PROVINCE, SOUTH AFRICA BETWEEN 2018 2019 (MASTERS CANDIDATE - DR V MUZENDA)

Thank you for submitting your study to the Faculty of Health Sciences Human Research Ethics Committee (HREC) for review.

It is a pleasure to inform you that the HREC has formally approved the above-mentioned study.

This approval is subject to strict adherence to the HREC recommendations regarding research involving human participants during COVID -19, dated 17 March 2020.

Approval is granted for one year until the 30 April 2021.

Please submit a progress form, using the standardised Annual Report Form if the study continues beyond the approval period. Please submit a Standard Closure form if the study is completed within the approval period.
(Forms can be found on our website: www.health.uct.ac.za/fhs/research/humanethics/forms)

We acknowledge that the student: Dr Vengesai Muzenda will also be involved in this study.

Please quote the HREC REF in all your correspondence.

Please note that the ongoing ethical conduct of the study remains the responsibility of the principal investigator.

Please note that for all studies approved by the HREC, the principal investigator **must** obtain appropriate institutional approval, where necessary, before the research may occur.

HREC REF: 181/2020 sa

HREC REF: 181/2020 sa

(b) Hospital Research Board Permission



GROOTE SCHUUR HOSPITAL
Enquiries: Dr Bernadette Eick
e-mail: Bernadette.Eick@westerncape.gov.za

Dr Nazier Ahmed
RADIOLOGY

E-mail: redhat007@yahoo.com / dr/muzenda@gmail.com

Dear Dr Ahmed,

RESEARCH PROJECT: Normal And Variant Anatomy Of The Coeliac Axis And Hepatic Artery As Identified On Multi-Detector Computed Tomography (MDCT) Studies At Groote Schuur Hospital, Western Cape Province, South Africa between 2018 and 2019 (Masters Candidate Dr Vengesai Muzenda)

Your recent letter to the hospital refers.

You are granted permission to proceed with your research, which is valid until **30 April 2020**.

Please note the following:

- a) Your research may not interfere with normal patient care.
- b) Hospital staff may not be asked to assist with the research.
- c) No additional costs to the hospital should be incurred i.e. Lab, consumables or stationary. **If access to TRACK Care/NHLS is required, kindly attach our letter of approval to the application form.**
- d) **No patient folders may be removed from the premises or be inaccessible.**
- e) Please provide the research assistant/field worker with a copy of this letter as verification of approval.
- f) Confidentiality must always be maintained.
- g) **Should you at any time require photographs of your subjects, please obtain the necessary indemnity forms from our Public Relations Office (E45 OMB or ext. 2187/2188).**
- h) Should you require additional research time beyond the stipulated expiry date, please apply for an extension.
- i) Please discuss the study with the HOD before commencing.
- ji) Please introduce yourself to the person in charge of an area before commencing.
- k) On completion of your research, please forward any recommendations/Findings that can be beneficial to use to take further action that may inform redevelopment of future policy / review guidelines.
- l) Please contact Michelle Riley (Patient Fees) at ext. 2276 to ascertain if there will be charges for conducting the Research and to obtain a quote or to discuss charges.
- m) **Kindly submit a copy of the publication or report to this office on completion of the research.**
- n) **At no time should any posters encouraging patients to partake in research, be displayed within a clinical area.**

I would like to wish you every success with the project.

Yours sincerely

Signature Removed

DR BERNADETE EICK
CHIEF OPERATIONAL OFFICER
Date: 17 April 2020

C.C. Mr. L. Naidoo,
Dr H. Aziz
Dr S. Moosa

G46 Management Suite, Old Main Building,
Observatory 7925
Tel: +27 21 404 6288 fax: +27 21 404 6125

Private Bag X,
Observatory, 7935
www.westerncape.gov.za/health

(C) SAJR Instructions to Authors

0
SA JOURNAL OF RADIOLOGY

<ul style="list-style-type: none"> HOME ARTICLES EDITORIAL TEAM AUTHORS ABOUT CPD CONNECT TWITTER LOGIN REGISTER <div style="margin-top: 10px;"> <input type="text" value="Search this journal"/> </div>	<p>INPAGE MENU</p> <p>Abridged structure</p> <ul style="list-style-type: none"> Editorials Case Reports Opinion Papers Clinical Perspectives Technical Innovation Original Research Articles Review Articles Pictorial Essays Cover Letter <p>Full structure</p> <ul style="list-style-type: none"> Original Research Article Review Article Case Report 	<p>Original Research Article full structure</p> <p>Title: The article's full title should contain a maximum of 95 characters (including spaces).</p> <p>Abstract: The abstract, written in English, should be no longer than 250 words and must be written in the past tense. The abstract should give a succinct account of the objectives, methods, results and significance of the matter. The structured abstract for an Original Research article should consist of five paragraphs labelled Background, Objectives, Method, Results and Conclusion.</p> <ul style="list-style-type: none"> • Background: <i>Why do we care about the problem?</i> State the context and purpose of the study. (What practical, scientific or theoretical gap is your research filling?) • Objectives: <i>What problem are you trying to solve?</i> What is the scope of your work (e.g. is it a generalised approach or for a specific situation)? Be careful not to use too much jargon. • Method: <i>How did you go about solving or making progress on the problem?</i> State how the study was performed and which statistical tests were used. (What did you actually do to get the results?) Clearly express the basic design of the study; name or briefly describe the basic methodology used without going into excessive detail. Be sure to indicate the key techniques used. • Results: <i>What is the answer?</i> Present the main findings (that is, as a result of completing the procedure or study, state what you have learnt, invented or created). Identify trends, relative change or differences on answers to questions. • Conclusion: <i>What are the implications of your answer?</i> Briefly summarise any potential implications. (What are the larger implications of your findings, especially for the problem or gap identified in your motivation?) <p>Do not cite references and do not use abbreviations excessively in the abstract.</p> <p>Introduction: The introduction must contain your argument for the social and scientific value of the study, as well as the aim and objectives:</p>
--	---	--

0
SA JOURNAL OF RADIOLOGY

<ul style="list-style-type: none"> HOME ARTICLES EDITORIAL TEAM AUTHORS ABOUT CPD CONNECT TWITTER LOGIN REGISTER <div style="margin-top: 10px;"> <input type="text" value="Search this journal"/> </div>	<p>INPAGE MENU</p> <p>Abridged structure</p> <ul style="list-style-type: none"> Editorials Case Reports Opinion Papers Clinical Perspectives Technical Innovation Original Research Articles Review Articles Pictorial Essays Cover Letter <p>Full structure</p> <ul style="list-style-type: none"> Original Research Article Review Article Case Report 	<p>Completing the procedure of study, state what you have learnt, invented or created. Identify trends, relative change or differences on answers to questions.</p> <ul style="list-style-type: none"> • Conclusion: <i>What are the implications of your answer?</i> Briefly summarise any potential implications. (What are the larger implications of your findings, especially for the problem or gap identified in your motivation?) <p>Do not cite references and do not use abbreviations excessively in the abstract.</p> <p>Introduction: The introduction must contain your argument for the social and scientific value of the study, as well as the aim and objectives:</p> <ul style="list-style-type: none"> • Social value: The first part of the introduction should make a clear and logical argument for the importance or relevance of the study. Your argument should be supported by use of evidence from the literature. • Scientific value: The second part of the introduction should make a clear and logical argument for the originality of the study. This should include a summary of what is already known about the research question or specific topic, and should clarify the knowledge gap that this study will address. Your argument should be supported by use of evidence from the literature. • Conceptual framework: In some research articles it will also be important to describe the underlying theoretical basis for the research and how these theories are linked together in a conceptual framework. The theoretical evidence used to construct the conceptual framework should be referenced from the literature. • Aim and objectives: The introduction should conclude with a clear summary of the aim and objectives of this study. <p>Research methods and design: This must address the following:</p> <ul style="list-style-type: none"> • Study design: An outline of the type of study design. • Setting: A description of the setting for the study; for example, the type of community from which the participants came or the nature of the health system and services in which the study is conducted. • Study population and sampling strategy: Describe the study population and any
--	---	---

<ul style="list-style-type: none"> EDITORIAL TEAM AUTHORS ABOUT CPD CONNECT TWITTER LOGIN REGISTER <div style="margin-top: 10px;"> <input type="text" value="Search this journal"/> </div> <div style="margin-top: 10px; background-color: #003366; color: white; padding: 2px;"> Cookie settings </div>	<ul style="list-style-type: none"> Opinion Papers Clinical Perspectives Technical Innovation Original Research Articles Review Articles Pictorial Essays Cover Letter <p>Full structure</p> <ul style="list-style-type: none"> Original Research Article Review Article Case Report 	<ul style="list-style-type: none"> • Scientific value: The second part of the introduction should make a clear and logical argument for the originality of the study. This should include a summary of what is already known about the research question or specific topic, and should clarify the knowledge gap that this study will address. Your argument should be supported by use of evidence from the literature. • Conceptual framework: In some research articles it will also be important to describe the underlying theoretical basis for the research and how these theories are linked together in a conceptual framework. The theoretical evidence used to construct the conceptual framework should be referenced from the literature. • Aim and objectives: The introduction should conclude with a clear summary of the aim and objectives of this study. <p>Research methods and design: This must address the following:</p> <ul style="list-style-type: none"> • Study design: An outline of the type of study design. • Setting: A description of the setting for the study; for example, the type of community from which the participants came or the nature of the health system and services in which the study is conducted. • Study population and sampling strategy: Describe the study population and any inclusion or exclusion criteria. Describe the intended sample size and your sample size calculation or justification. Describe the sampling strategy used. Describe in practical terms how this was implemented. • Intervention (if appropriate): If there were intervention and comparison groups, describe the intervention in detail and what happened to the comparison groups. • Data collection: Define the data collection tools that were used and their validity. Describe in practical terms how data were collected and any key issues involved, e.g. language barriers.
--	--	--

HOME		INPAGE MENU
ARTICLES		BY AUTHOR
EDITORIAL TEAM		BY ISSUES
AUTHORS		BY SECTION
ABOUT		Original Research Articles
CPD		Review Articles
CONNECT		Pictorial Essays
TWITTER		Cover Letter
LOGIN		Full structure
REGISTER		Original Research Article
		Review Article
		Case Report

Search this journal

<https://cair.nm.uh.edu/ehp/cair/search/authors>

- **Data collection:** Define the data collection tools that were used and their validity. Describe in practical terms how data were collected and any key issues involved, e.g. language barriers.
- **Data analysis:** Describe how data were captured, checked and cleaned. Describe the analysis process, for example, the statistical tests used or steps followed in qualitative data analysis.
- **Ethical considerations:** Approval must have been obtained for all studies from the author's institution or other relevant ethics committee and the institution's name and permit numbers should be stated here.

Results: Present the results of your study in a logical sequence that addresses the aim and objectives of your study. Use tables and figures as required to present your findings. Use quotations as required to establish your interpretation of qualitative data. All units should conform to the **SI convention** and be abbreviated accordingly. Metric units and their international symbols are used throughout, as is the decimal point (not the decimal comma).

Discussion: The discussion section should address the following four elements:

- **Key findings:** Summarise the key findings without reiterating details of the results.
- **Discussion of key findings:** Explain how the key findings relate to previous research or to existing knowledge, practice or policy.
- **Strengths and limitations:** Describe the strengths and limitations of your methods and what the reader should take into account when interpreting your results.
- **Implications or recommendations:** State the implications of your study or recommendations for future research (questions that remain unanswered), policy or practice. Make sure that the recommendations flow directly from your findings.

Conclusion: Provide a brief conclusion that summarises the results and their meaning or significance in relation to each objective of the study.

Acknowledgements: Those who contributed to the work but do not meet our authorship criteria should be listed in the Acknowledgments with a description of the contribution. Authors are responsible for ensuring that anyone named in the Acknowledgments agrees to

EDITORIAL TEAM		Opinion Papers
AUTHORS		Clinical Perspectives
ABOUT		Technical Innovation
CPD		Original Research Articles
CONNECT		Review Articles
TWITTER		Pictorial Essays
LOGIN		Cover Letter
REGISTER		Full structure
		Original Research Article
		Review Article
		Case Report

Search this journal

Acknowledgements: Those who contributed to the work but do not meet our authorship criteria should be listed in the Acknowledgments with a description of the contribution. Authors are responsible for ensuring that anyone named in the Acknowledgments agrees to be named. Refer to the acknowledgement structure guide on our [Formatting Requirements](#) page.

Also provide the following, each under their own heading:

- **Competing interests:** This section should list specific competing interests associated with any of the authors. If authors declare that no competing interests exist, the article will include a statement to this effect: *The authors declare that they have no financial or personal relationship(s) that may have inappropriately influenced them in writing this article.* Read our **policy on competing interests**.
- **Author contributions:** All authors must meet the criteria for authorship as outlined in the **authorship** policy and **author contribution** statement policies.
- **Funding:** Provide information on funding if relevant
- **Data availability:** All research articles are encouraged to have a data availability statement.
- **Disclaimer:** A statement that the views expressed in the submitted article are his or her own and not an official position of the institution or funder.

References: Authors should provide direct references to original research sources whenever possible. References should not be used by authors, editors, or peer reviewers to promote self-interests. Refer to the journal referencing style downloadable on our [Formatting Requirements](#) page.

