THESIS

on

THE PLACE OF SURGERY

IN

THE MANAGEMENT OF BRONCHIECTASIS

by

B. T. le ROUX

M.B., Ch.B., F.R.C.S. (Ed.)

Submitted for the degree of

MASTER OF SURGERY

UNIVERSITY OF CAPE TOWN

August, 1964.

The copyright of this thesis vests in the author. No quotation from it or information derived from it is to be published without full acknowledgement of the source. The thesis is to be used for private study or non-commercial research purposes only.

Published by the University of Cape Town (UCT) in terms of the non-exclusive license granted to UCT by the author.

University of Cape Town

CONTENTS

Chapter		Page
	Introduction	1
I	Historical Survey	9
	Pathogenesis	21
	Natural History	31
II	The Anatomy of the Bronchi	42
	The Anatomical Limits of Pulmonary Resection	71
	The Anatomical Distribution of Bronchiectasis	80
III	Bronchographic Contrast Media	86
	Bronchographic Technique	90
IV	Management of Bronchiectasis in 1038 Patients	100
	Total Unilateral Bronchiectasis Managed by Pneumonectomy	106
	Total Unilateral Bronchiectasis Managed Conservatively	121
	Unilateral Lobar Bronchiectasis Managed by Resection	129
	Unilateral Lobar Bronchiectasis Managed Conservatively	147
	Lobar and Segmental Bronchiectasis Managed by Resection	151
	Lobar and Segmental Bronchiectasis Managed Conservatively	159
	Unilateral Segmental Bronchiectasis Managed by Resection	162
	Unilateral Segmental Bronchiectasis Managed Conservatively	175
	Bilateral Bronchiectasis Managed Surgically	179
	Bilateral Bronchiectasis Managed Conservatively	199
	Bronchiectasis Too Extensive for Resection	206
	Scattered or Doubtful Bronchiectasis	209
V	The Original Plan and Its Modifications	218
	Results of Surgical Management of Bronchiectasis	221
	The Cause of Bronchiectasis in Those Managed Surgically	228
	Complications	230
	Mortality Amongst Those Managed Conservatively	235
	Reasons for Not Undertaking Resection	235
	Conclusions	237
	Summary	244
	References	

INTRODUCTION

The purpose of this thesis is to attempt to define the place of pulmonary resection in the management of bronchiectasis the cause of which does not demand separate therapeutic consideration - as, for example, when bronchiectasis develops distal to a carcinoma. The conclusions reached are based on a scrutiny of the literature which relates to bronchiectasis and on a retrospective assessment of the results of surgical management between 1947 and 1963 in some 400 patients with bronchiectasis. Some of the literature which is of historical interest and some which is critical of the surgical management of bronchiectasis is reviewed. Knowledge of the pathogenesis and of the natural and medically and surgically modified history of the disease is imprecise; an explanation is offered to account for some of the confusion (Chapter 1). Apart from the exercise of precise surgical technique successful surgery for bronchiectasis depends absolutely upon an accurate knowledge of the anatomical distribution of the disease in the individual patient. For comprehension and communication of anatomical facts a common language in the identification of bronchi is necessary. A description of the usual anatomy of the bronchi and of anatomical variations, particularly in the left upper lobe, which may influence selection of patients with bronchiectasis for surgery is therefore /

therefore unavoidable (Chapter 2). For the pre- and post-operative assessment of patients complete bronchograms are essential. A technique of bronchography which has been shown to give bronchograms of a consistent and acceptable standard is therefore described (Chapter 3). The group of patients with bronchiectasis managed by resection is reviewed in detail and the disease in these patients is compared with bronchiectasis in a group of some 600 other patients investigated during the same period and managed other than by resection, because these patients either were judged unsuitable for surgical treatment or declined operation (Chapter 4). Photographic reproductions of chest radiographs, particularly those in which bronchi had been outlined with radio-opaque material for contrast, have been used extensively as illustrations because such radiographs can be well reproduced and reference to them obviates much tedious description.

The need for improvement in the management of pleuro-pulmonary suppuration, commonly in the form of empyema thoracis with or without bronchiectasis, and increasing awareness of pulmonary carcinoma as a disease entity, were the stimuli to the development of thoracic surgery in the decade before the outbreak of war in 1939. This development was, however, in the hands of only a very small number of surgeons whose services were available to a proportionately small number of patients, techniques employed in investigation and in operative management not only were /

were not standardised but also had barely extended beyond experimental stages, and operative mortality was prohibitively high. During the war years thoracic surgery as a specialty became established and its scope widened; all branches of surgery have always advanced most rapidly when surgeons have been faced with the need to manage battle casualties. At the end of the war a generation of surgeons returned from military service eager to exploit techniques of pulmonary resection learned and developed in the management of thoracic trauma and its suppurative complications and in the management of service personnel found to have pleuro-pulmonary suppurative disease, and to exploit more refined techniques developed by their senior or disabled colleagues who had been retained in civilian practice where experimental facilities were available to them.

In the five years which followed surgical techniques improved further; the number of trained surgeons increased and their services became generally available; anaesthesia with controlled respiration in the pharmacologically paralysed patient became established - advances in anaesthetic technique in this half decade were more impressive than in any other aspect of pulmonary surgery; and chemotherapy based on rational bacteriological investigation became a recognised part of pre- and post-operative care. By 1949 or 1950 pulmonary resection was almost as safe as it it today; the only important advance in the last ten years has been in the pre-operative recognition of the patient likely to develop respiratory /

respiratory insufficiency and the post-operative management of this complication. By this time there had developed an attitude towards bronchiectasis amongst thoracic surgeons and respiratory physicians which was a balance between surgical enthusiasm for resection on the one hand and, on the other, recognition that in carefully selected patients bronchiectasis was not only suitable for management by resection but also probably best managed in this way, despite an eagerness to widen the scope of the chemotherapeutic management of the disease - a balance which in recent years has almost been lost. The anatomical limits of resection were generally accepted, and within these limits it was established that, in patients with symptoms, bronchiectasis which was confine to dependent, shrunken airless lobes and segments which had been seen to remain shrunken and airless for a prolonged period, was suitable for management by resection provided the patient was of an age and in a physical state, which, on general grounds, made him an acceptable candidate for a thoracic surgical procedure. Age limits for resection were not precisely defined, but children were regarded as the most suitable subjects. Co-existent bronchitis, with or without asthma, was acknowledged to diminish the likelihood of relief of symptoms by resection of localised bronchiectasis. There was some hesitation in recommending resection for bilateral bronchiectasis and even more hesitation in recommending resection of some and not all demonstrable bronchiectasis - resection of /

of a bronchographically gross "sump". An enthusiasm for the resection of widely scattered bronchiectatic segments had waned and quickly waned.

The Regional Thoracic Unit in Edinburgh became established shortly after the end of the war and patients with bronchiectasis began to accumulate in large numbers on a waiting list. From 1947 onwards resections for bronchiectasis were undertaken in increasing numbers. Management of bronchiectasis by resection was recommended to patients whose symptoms could be attributed only to bronchiectasis, in whom the disease was unilateral or, if bilateral, limited to shrunken lobes and segments devoid of respiratory function. Detailed preliminary investigation included, in all patients, an exclusion by sputum examination of pulmonary tuberculosis, examination for and, where necessary, treatment of upper respiratory tract infection, bronchoscopy and bronchography. A standard of bronchography was demanded which it was thought would make unlikely failure to recognise bronchiectasis outwith lobes and segments planned for resection; very young children were, as a consequence, rarely managed surgically because in them bronchography was rarely entirely satisfactory. It was believed that all demonstrable bronchiectasis should be amenable to resection and that partial resections should not be undertaken. The elderly with symptoms from surgically manageable bronchiectasis were submitted to unilateral resection without hesitation but in them bilateral resections were thought unwise. All patients /

patients in whom bronchiectasis was thought amenable to resection and who accepted thoracotomy were managed surgically; this group of patients does not, therefore, constitute a controlled clinical trial such as one in which half the patients regarded as suitable for surgical management are, by random selection, managed in this way and the other half are not. Enough of the natural history of the disease was already known for it to be accepted that resection of bronchiectasis in properly selected patients would not only relieve symptoms, protect from metastatic and general sequelae of chronic infection and obviate the need for continued medical care by posture and chemotherapy, but also that management by resection could be followed by normal mental and physical development in children, by a normal reproductive life in young women and by continued ability and increased capacity for work and earning in adults.

It was recognised that the need might arise for modification of the bases of acceptance of patients with bronchiectasis for surgical management and that the need for these modifications would be recognised by repeated re-assessment of both patients in whom resection had been undertaken and those in whom it had not. To facilitate the estimate of post-operative improvement resection was undertaken in very few patients who had not been observed pre-operatively for several months. Since it was believed that the planned surgical approach was rational it was accepted that it would be necessary to pursue the plan unmodified until /

until a sufficiently large number of patients had been treated for it to be possible to assess and group failures which could be attributed to errors in selection as distinct from errors in technique.

Limitations of a trial of this nature are obvious. Once a surgical procedure has been undertaken it is impossible in the individual patient to state categorically that that patient is better than he would have been without an operation, especially if there is available an alternative form of management. The assessment over many years of patients relieved of respiratory symptoms is also difficult, for many reasons. These patients are not protected by pulmonary resection from respiratory infections common to the population at large and they commonly relate the symptoms of such infection to those which they had experienced before an operation. When pulmonary resection for bronchiectasis is undertaken in young people they cease to have, as they grow older, clear memory of pre-operative symptoms, and records, however well kept, seem in retrospect curiously deficient. There is, in older patients, a variable index of gratitude to and faith in their surgical advisers which, in many, induces them to believe that, because an operation has been undertaken, their physical state is inevitably better. There is amongst surgeons a deeply ingrained conviction that, because a reasonable operation has been properly undertaken, the patient cannot be other than improved. There is a group of patients in whom an operation with its inevitable scar is an insurance against ever working again and the ground for a continued and contented state /

state of financially subsidised chronic ill-health. The final assessment of the value of surgery for any disease in any group of patients cannot be made until all patients in the series have died - it is not yet known, for example, if pneumonectomy or an extensive bilateral resection for bronchiectasis is compatible with a normal life span. All these limitations were recognised and with this knowledge the series was begun, the plan was pursued, some modifications were made, and from this review the present attitude towards surgical management of bronchiectasis in Edinburgh emerges (Chapter 5).

CHAPTER I

HISTORY AND PATHOGENESIS

Historical Survey

The first published account of the clinical and morbid anatomical features of the disease later called bronchiectasis appeared in brief in 1819 in the first, and *in extenso* in later editions of Laennec's monograph on "Mediate Auscultation". In this, bronchial dilatation was attributed to pressure from the accumulation and stagnation of endobronchial secretions. The title page and the beginning of the chapter which relates to bronchiectasis are reproduced from the English translation by Forbes of this monograph (Figs. 1 and 2).

A relationship between bronchiectasis and whooping cough was recognised by Andral (1831). The destructive effects of inflammation of the bronchial wall, with loss of muscle and elastic tissue and of ciliary action were recognised by Stokes (1837) who attributed dilatation to paralysis of circular muscle; bronchitis and bronchiectasis were differentiated and associated. A year earlier Corrigan (1836) had contended that the changes in pulmonary parenchyma subtended by dilated bronchi were primary and the cause, by traction, of the dilatation; the parenchymal lesions he called pulmonary cirrhosis. Hasse (1841), to whom the term bronchiectasis is ascribed, and Rokitansky (1842) observed a relationship /

relationship which they maintained was causal between, on the one hand, bronchiectasis, and, on the other, bronchitis, tuberculosis and emphysema. Black (1853) acknowledged the aetiological importance of infection and suggested that bronchial obstruction was a necessary concomitant of infection for the development of bronchial dilatation. Saccular dilatations he ascribed to local destruction of the bronchial wall and fusiform dilatation to more diffuse and less destructive inflammation.

In the second half of the 19th century knowledge of the pathogenesis of bronchiectasis was little modified. At the turn of the century surgical management of the disease was slowly advancing, but accurate localisation of bronchiectasis, upon which surgical management was heavily dependent, became possible only after the introduction of lipiodol by Sicard and Forestier (1922). Before bronchographic techniques and contrast media were satisfactory localisation of bronchiectasis by direct clinical and simple radiographic techniques was accurate in fewer than 30% of cases (Hedblom, 1931). An unequivocal relationship between bronchiectasis and bronchial obstruction with distal infection became established and, in the decade before the outbreak of war in 1939, special contributions to the accumulated literature on pathogenesis were made with the recognition of an association between bronchiectasis, situs inversus and sinusitis (Kartagener, 1933; Adams & Churchill, 1937), and between bronchiectasis and mucoviscidosis or fibrocystic disease of the pancreas (Anderson, 1938). More recently the development of bronchiectasis in patients with agammaglobulinaemia /

globulinaemia has been demonstrated (Bruton, 1952; Baar, 1955; Hutchison, 1955).

Progress in pulmonary surgery lagged behind advances in knowledge of the pathogenesis of bronchiectasis. Purposeful pulmonary ablation through an intentional thoracotomy was undertaken in 1823 by Milton Antony in a boy of 17 years with a history of pulmonary and pleural suppuration consequent upon trauma and possibly related to rupture of a main bronchus. Earlier pulmonary amputations had been made for lung which had herniated through a traumatic thoracotomy - in Stephen Paget's "Surgery of the Chest" published in 1896 by John Wright of Bristol there is an account of such an amputation successfully undertaken by Rolandus in 1499. A peripheral pulmonary tumour was resected in 1861 by Péan; the technique used was similar to that employed in pulmonary biopsy today and the episode apparently made so little impression on the surgeon that he confessed to it only 34 years later. In 1876 Hewett explained the need for and described a technique of closed drainage of the pleural space - a technique little modified at the present time. In 1881 Block, Schmid, Marcus and Gluck, all working independently, reported their initial experience of experimental pulmonary surgery; the importance of separate control of vessels and bronchi at the pulmonary and lobar hila was, even at this early date, clearly recognised, although practical application of this knowledge did not become technically possible, except in unusual circumstances and in occasional hands, for nearly sixty years. There is always in surgery long delay before that which is occasionally achieved by the surgical master is routinely undertaken by the apprentice, /

apprentice, and the surgical management of any disease can be regarded as established only when such management is generally available.

Gluck (1881) wrote that there was a particular place for pulmonary resection in the management of bronchiectasis. In 1886 Demons undertook successfully "lobectomy" and then nephrectomy in a patient with stab wounds - this is apparently the first recorded example of visceral resection with survival following a thorace-abdominal wound. In the last decade of the 19th century there were isolated reports of partial pulmonary resections, usually with resection of part of the chest wall, and usually for tumours primarily of rib or breast. In 1891 Tuffier resected part of a pulmonary apex for tuberculosis. The approach was extrapleural and the apex of the lung was amputated beyond a clamp; the chest wall was closed in layers with catgut and the skin with Florentine horse-hair. In 1893 Lawson, a surgeon on the staff of Hull Royal Infirmary, and in 1895 Doyen and Macewen resected lungs destroyed by tuberculosis in patients whose pleural space was obliterated. (Macewen's patient was alive 45 years later). Thoracotomy with a free pleura was still unacceptably hazardous, and much time and energy were devoted to the promotion of pleural adhesions; bird-lime, glue and sealing wax were some of the more bizarre substances used, unsuccessfully, for this purpose, (Meade, 1961). In 1898 Murphy, aware of the reports of successful pulmonary resection after traumatic lung herniation, was prompted deliberately to exteriorise a lobe before resecting it, a technique later adopted by Whittemore (1927). Krause, also in 1898, resected part of a lobe for bronchiectasis, and this was apparently the first /

first pulmonary resection undertaken for this specific purpose. Gross in 1899, in the management of an empyema resected this with part of the lung, and the pulmonary lesion was presumed to be bronchiectasis. Over the next 20 years, in Europe, Great Britain and in the United States, partial lobectomies and partial pneumonectomies were undertaken by a few surgeons, but operative and post-operative mortality was everywhere in excess of 50%, and post-operative empyema almost invariable in the survivors.

In 1912 Morrison Davies undertook lobectomy by dissection, for carcinoma, and advocated exploratory thoracotomy in the management of undiagnosed persisting peripheral pulmonary shadows - thirty years before these were accepted practices. In the next 15 years memorable contributions to the development of pulmonary surgery were made by men such as Lilienthal, Sauerbruch, Robinson, Mayer, Graham + Hitzrot. In 1925 Lilienthal recorded the mortality for lobectomy as 47%; five years later Cerylles collected the reports of 87 cases operated on by 11 different surgeons and the mortality was 53%. Despite the contributions of Morrison Davies, Robinson (1917) continued to advocate lobectomy as a staged procedure with mass ligation of the lobar pedicle. Hitzrot (1920) recorded a successful one-stage lobectomy with primary closure of the chest wall and closed drainage of the pleural space. The surgical principles which he calculated to underlie one-stage lobectomy were clearly stated by Brunn in 1929. A successful dissection lobectomy by Churchill in 1931 passed unnoticed at the time and the tourniquet techniq of Shenston and Janes (1932) and Janes (1933), modified by Roberts and Nelson (1933) was /

was widely adopted. In one of the cases reported by Roberts and Nelson carcinoma was recognised in the resected lobe to have complicated bronchiectasis in a girl of 23, a relationship between carcinoma and bronchiectasis which had been recognised in 1922 by Siegmund. In 1931 Nissen successfully completed pneumonectomy by mass ligation; this resection was undertaken for bronchiectasis which, at that time, was still managed surgically almost exclusively by collapse therapy - by the induction of a pneumothorax, by phrenic section or by thoracoplasty by cautery pneumotomy to drain large intrapulmonary collections of pus, by pulmonary artery ligation or by cautery "pneumonectomy". In 1933 dissection pneumonectomies were individually and successfully completed by Churchill and Rienhoff, followed shortly by Alexander and Overholt; of these only Rienhoff published his experience at the time.

The first volume of the Journal of Thoracic Surgery was published in 1932 and in this Ballon, Singer and Evarts Graham summarised in four papers the history and their attitude towards the place of surgery in the management of bronchiectasis. Details relating to 212 lobectomies for bronchiectasis by different surgeons were known; the mortality varied from 10% to 80% and the overall mortality was 38%. Crafoord's monograph on the technique of pneumonectomy, published in 1938 summarised the history of this operation and described the surgical techniques in use at that time. He emphasised the need for dissection techniques and the value of controlled endo-tracheal anaesthesia and bronchial tamponade, which had been introduced by Guedal and Waters and improved by Crafoord's close associate, Frenckner. The papers of Churchill and Belsey (1939) and /

and of Kent and Blades (1942) made generally available knowledge of the detailed anatomy of the lobar and segmental hila and, with the introduction of curare at the end of the war pulmonary surgery advanced so rapidly that, in 1946, Pilcher was able to report the successful removal of isolated bronchiectatic segments and sub-segments from all five lobes. Ten to 15 years later large series of patients whose bronchiectasis had been managed by resection could be reviewed at a distance (Ginsberg, Cooley, Olsen and Kirklin, 1955; Lindskog and Hubbell, 1955; Bradshaw, Myers and Cordell, 1957; Helm and Thomsen, 1958; Streete and Salyer, 1960; and Hewlett and Ziperman, 1960) and it could be demonstrated that in 80% of patients selected for surgical management resection had provided symptomatic relief and protection from the metastatic and general consequences of chronic infection with an operative mortality of less than 3%.

Notwithstanding these results which were, it must be emphasised, in selected patients and not the results of the management of the disease as a whole, there was in the minds of many physicians grave doubt regarding not only the place of surgery in the management of bronchiectasis, but also regarding the need for surgery anywhere in the management of the disease. In 1955 an editorial appeared in the Lancet extensive quotation from which serves to illustrate the growing disenchantment with resection as management for bronchiectasis: -

> "In the first account of bronchiectasis Laennec (1819) included among his cases that of a 62 year-old woman who had had repeated haemoptyses and had coughed up purulent sputum for almost fifty years. But this case was exceptional, and until recently it was generally believed that the prognosis of bronchiectasis treated medically was extremely bad. Thus Perry and King (1940) found that almost half of a series of medically treated patients died within five years of the onset of symptoms, while Bradshaw et al. (1941) showed that /

that the average duration of life after diagnosis was less than two years. Such figures, collected in the early days of bronchography with iodised oil when only the grosser cases were likely to be recognised, led to the belief that surgical resection should be undertaken in every case of bronchiectasis where it was technically feasible, not only for the relief of present disability but also as an insurance for the future. Since then improvements in surgical and anaesthetic techniques, better physiotherapy, and the control of infection by antibiotics have greatly reduced the risks of operation ..... Despite the low mortality and brilliant results in individual cases, operations should not, however, be undertaken lightly; for even in the best hands complications must be reckoned with ..... The rather high incidence of early post-operative complications would matter less if the late results were always good; but even the most enthusiastic reports ... do not record great improvement in more than two-thirds of those operated upon, (and) when the results are assessed by a third party the picture is sometimes rather different. Paterson (1952) investigated the results of resection for bronchiectasis in a group of Canadian ex-Servicemen, and found that only half of them were satisfied with the results of their operation ..... and several were subject to recurrent attacks of bronchitis although their bronchograms were normal .....There is no virtue in producing a normal bronchographic appearance if the patient continues to have cough, sputum, and bronchospasm.

At present surgery (preserving the equivalent of a whole lung) is probably the treatment of choice for those with reasonably localised disease, much cough and sputum, and repeated attacks of pneumonia or haemoptysis. The most suitable patients are older children and young adults; it is usually unwise to operate on patients under 10 or over 40 years of age. It is always difficult to select the right patients from those whose disease is either insufficient or too extensive to make operation worth while. But patients for whom operation needs to be considered are in a minority..... Evidence is accumulating that in the great majority of cases modern medical treatment, with its emphasis on postural drainage and the use of antibiotics, greatly limits the disability from this disease. The cases most in need of surgery are usually the least likely to benefit from it, on account of the extent of the disease or poor general condition. Despite the excellent results of many operations, there are good grounds for a conservative approach to the treatment of bronchiectasis."

In 1958 a second editorial on bronchiectasis in the same journal was devoted to an analysis of the results from the surgical treatment of bronchiectasis reported by Gudbjerg (1957). A sombre picture emerged - of bad results with a high /

high early and late death rate in older people, poor functional results, and post-operative bronchographic evidence of extension of the disease. The unimpressive results of surgery in this series were attributed to distortion of the bronchial tree by resection of part of the lung, with interference with drainage from the remaining bronchi and a constitutional susceptibility to bronchial infection in patients with bronchiectasis. Later in 1958 a third annotation on surgery for bronchiectasis appeared in the Lancet.

> " The prestige of surgical treatment for bronchiectasis reached its zenith in the period immediately after the last war. Not only did it seem to offer the only hope of escape from a wretched, if not too protracted, progress to the grave, but recent spectacular advances in technique had greatly enlarged its scope ..... Gradually, however, as the potentialities of chemotherapy became apparent the desirability of surgical intervention began to be reconsidered. Reappraisal of the role of surgery became necessary also as increasing use of bronchography brought to light more and more instances of bronchiectasis associated with only trifling symptoms or with no symptoms at all (McKim, 1952; Wynn-Williams, 1953). Since then, despite favourable reports of the results of resection, surgical stock has been falling steadily, and there is no indication that the bottom has yet been reached. It is difficult to get enough information to estimate the value of surgery, because it is uncertain how far the results of surgical and medical treatment in different series of cases can be compared, and controlled trials have proved impracticable, but ..... where it seems probable that surgery can offer a cure, the difficult problem arises of deciding whether it is worth accepting the risk entailed. ..... Until more information is forthcoming about the long-term results of conservative therapy in different categories of bronchiectasis, it is clearly impossible to define the scope of surgery. But it seems safe to forecast that the need for surgery will continue to decline (and) by the time it has been finally settled when best to employ resection for bronchiectasis there will be few opportunities to act on this knowledge."

While these annotations and editorials were written relatively recently it is fitting that they should conclude a historical survey of the disease because they were /

were important statements of policy which represented not only the considered opinion of eminent editors and experts who had available to them details of world-wide medical and surgical experience, but also because they were published in a journal widely read by general practitioners and physicians relatively inexperienced in the assessment of the disease but yet to whom patients shown ultimately to have bronchiectasis would first present and on whom referral for detailed investigation depended. Writings such as these did much to upset the properly balanced attitude towards the management of bronchiectasis earlier referred to. With much of the emphasis in these articles physicians such as Clark (1963) were in disagreement and many surgeons found that their experience was at variance with the conclusions drawn. Nevertheless, at least in Great Britain, there developed what amounted almost to hostility amongst some respiratory physicians in their attitude towards the referral of patients with bronchiectasis for surgical management, and for many the prestige of the surgical management of bronchiectasis had indeed swung from its zenith to its nadir. But if surgical enthusiasm had earlier allowed of the incautious selection of patients for management of bronchiectasis by resection, whether because of inadequate bronchography, failure to recognise co-existent bronchitis or other deficiencies, it was clearly ill-judged to deny surgery any place in the management of the disease and light-heartedly to condemn patients with resectable bronchiectasis to life-long surveillance and the interrupted or continued need for postural coughing and chemotherapy without assurance against metastatic infection.

A

TREATISE

ON THE

DISEASES OF THE CHEST

AND ON

MEDIATE AUSCULTATION.

BY R. T. H. LAENNEC, M.D.

REGIUS PROFESSOR OF MEDICINE IN THE COLLEGE OF FRANCE, CLINICAL PROFESSOR TO THE FACULTY OF MEDICINE OF PARIS, PHYSICIAN TO HER ROYAL HIGHNESS THE DUCHESS OF BERRI, &c. &c. &c.

TRANSLATED FROM THE LATEST FRENCH EDITION,

WITH

NOTES AND A SKETCH OF THE AUTHOR'S LIFE,

BY JOHN FORBES, M.D.

The quotation from Hippocrates may be translated to read "I think that a great part of art is to be able to observe." Much depends upon the interpretation of the word "techne", which means art and pertains especially to the useful arts. Although many of the words which stem from it have, in their present sense, a scientific rather than an artistic connotation, in the context in which it is used it probably refers specifically to the art of medicine and what is meant is that successful practice of medicine depends on accurate observation.

THIRD EDITION REVISED, WITH ADDITIONAL NOTES.

LONDON:

PRINTED FOR THOMAS & GEORGE UNDERWOOD,

FLEET-STREET.

MDCCCXXIX.

Fig. 1

CHAPTER II.

OF DILATATION OF THE BRONCHIA.

THE organic lesion which I am now to notice, seems to have been hitherto entirely overlooked, both by the anatomist and the practitioner. This oversight is easily accounted for, from the circumstance of its generally occurring in a small portion of a bronchial tube, and of its being mistaken, when observed, for a larger branch. It can only be detected by tracing the individual bronchial tubes to their ultimate ramifications,—a thing which is rarely done in our examination of the lungs.

Anatomical characters. This disease presents itself in various forms. Sometimes it exists in one or in several branches, or even over almost the whole extent of one lung, without any other change in the appearance of the affected bronchia, than increase of volume: thus, ramifications which in the natural state would scarely admit a fine probe, acquire a diameter equal to that of a crow-quill, or goose-quill, or even of the finger. These dilated branches frequently spring from a trunk of a much smaller diameter than their own. Occasionally we find the dilated branch resuming all at once its natural size; more commonly it appears to terminate in an irregularly shaped cul-de-sac, into which several small branches of a natural size are found to open. I have never observed a dilatation which seemed to exist in the ultimate division of the bronchia, and which could throw any light upon the manner in which these terminate. At other times, the dilated bronchia lose their natural shape, and present themselves under the form of a cavity, capable of containing a hempseed, a cherry-stone, an almond, or even a walnut. Several successive enlargements of this kind may exist in the course of the same tube. Sometimes the dilatation is confined to one or two branches in the upper lobe, and looks like a tuberculous excavation transformed into a fistula; frequently also, several continuous or contiguous branches, unequally dilated and forming by their inter-communication a sort of burrow filled with puriform mucus, present, at first

Fig. 2

A photographic reproduction of the English translation of the first page of Laennec's original description of the disease bronchiectasis.

Pathogenesis

What is the disease called bronchiectasis; in what circumstances does it develop and demand management in its own rights; how does it present and how is it diagnosed; what effect may it have on the patient? Most standard textbooks on respiratory diseases offer a partial answer to these questions and it is not intended to give a detailed account of the accepted facts of pathogenesis. To establish a common ground, however, some observations regarding pathogenesis will be made, principally with the object of raising doubt regarding some current views.

Permanently dilated bronchi are called bronchiectatic. The essential histological feature of the disease is destruction of the muscle and elastic tissues of the bronchial wall which become replaced with fibrous tissue. The anatomical distribution of the disease is demonstrable radiographically, and the radiographic demonstration of dilated bronchi outlined with a contrast medium is the only indisputable method of establishing a diagnosis in vivo. While the clinical features of the disease are the local, general and metastatic consequences of persisting infection in dilated and usually dependent bronchi, bronchial dilatation is itself the result of infection the inflammatory response to which has progressed to one of the more destructive terminations. Bronchial obstruction is a common but perhaps not essential concomitant of inflammation when infected bronchi become dilated, whether such obstruction is from the local products of inflammation or whether it precedes infection.

The /

The type of patient most frequently treated for bronchiectasis has a history which suggests that the lesion has been acquired in childhood (Perry and King, 1940; Clark, 1963), and in children, whose bronchi are soft and of small calibre, bronchi are most commonly obstructed by abnormally tenacious mucus, by inflammation and oedema of bronchial mucosa, by external compression from enlarged glands, or, and probably most commonly, by a combination of all three mechanisms. Bronchial obstruction of any variety (intra-luminal, mural, extra-mural or by distortion) and from any cause (retained foreign body or mucus, acute or chronic inflammatory lesions of the bronchial wall, bronchial tumours, mediastinal space occupying lesions, and so on) may be responsible for the development of bronchiectasis if the obstructed bronchi are infected and obstruction is of sufficient duration. The duration of obstruction necessary for the development of permanent dilatation of subtended bronchi must obviously depend on the virulence and destructiveness of the associated inflammation and must therefore be very variable. Middle lobar bronchiectasis has been demonstrated after the retention of a vegetable foreign body for only eight days in a patient in whom there was no reason to suspect the presence of bronchiectasis before inhalation of the foreign body (le Roux, 1964a). (Fig. 3)

It is generally taught that infected and proximally obstructed bronchi dilate because their softened walls are more directly exposed to negative intrathoracic tension through the airless pulmonary tissue subtended by these bronchi (Davidson and Lee Lander, 1938). Other tube systems - in the salivary glands, prostate, pancreas or breast, for example - dilate when infected and obstructed, and here dilatation is related to destruction of the wall of the tube /

tube system and to increase in intra-luminal tension distal to the obstruction. There seems little need to offer two explanations for similar pathological features. It is inevitable, in the absence of gas-forming organisms, that lung subtended by completely obstructed bronchi will sooner or later become airless and radiographically opaque but the tacit assumption that such airless lung is collapsed (Perry and Holmes Sellors, 1963) is unjustifiable. Airless lung distal to an obstructed bronchus often occupies a volume of the hemithorax smaller than normal, but it is not uncommon for the lung distal to a bronchial obstruction to be solid with the products of inflammation and either to occupy a normal volume of the hemithorax or to be distended and displace adjacent aerated lung. In all these circumstances bronchi distal to an obstruction will be bronchiectatic. Bronchial carcinoma of the central type is a common bronchus obstructing lesion and in older patients probably the commonest cause of bronchiectasis, and, although it is the carcinoma towards which treatment is primarily directed, it is often the clinical features of infection in the dilated bronchi distal to the carcinoma which precipitate investigation. Bronchiectasis is routinely demonstrated in lobes distal to bronchial carcinoma, whether these lobes are shrunken, distended or of normal size. And even when pulmonary shrinkage from bronchial obstruction is unilaterally total, any increase in negative intra-thoracic tension consequent upon pulmonary shrinkage is quickly and completely compensated for by mediastinal shift and increase in volume of the contralateral lung. Whitwell (1952) offers supporting evidence for discarding negative pleural tension as contributory in the pathogenesis of bronchial dilatation. /

dilatation.

Although the existence of bronchiectasis may be suspected from abnormalities on plain chest radiographs - translucencies or small cystic spaces (honeycombing), or wide, air-containing bronchi which do not taper within an opacity of lobar type - the final demonstration of bronchiectasis is by bronchography. An unequivocally normal chest radiograph is said to be found, however, in only 7% of patients with bronchiectasis (Gudbjerg, 1955). Bronchi within a shrunken airless lobe are usually wider than when the lobe is aerated, so that the demonstration on plain film of wide, tubular bronchi in such circumstances is not necessarily significant. Such a demonstration of bronchi is called an "air bronchogram".

The classification of bronchiectasis into post-pneumonic, follicular, saccular, atelectatic or congenital (Spencer, 1962) has little bearing on surgical management. In mucoviscidosis bronchiectasis is related to bronchial obstruction by abnormal mucus and bronchial dilatation is clearly acquired, although consequent upon a congenital abnormality of mucus-secreting glands (Baylin, 1944; Lowe, May and Reed, 1949; Sant 'Agnese, 1956). Bronchiectasis which is part of Kartagener's syndrome is not different from other varieties of bronchiectasis and is probably predisposed to either by the mechanical effects of visceral transposition or by sinusitis, itself probably common in these patients because of the abnormal size of the sinuses. Many patients with bronchiectasis have a history of respiratory symptoms which dates from childhood. Mediastinal glandular /

glandular enlargement related to the exanthemata, whooping cough and tuberculosis are generally regarded as common causes of bronchial obstruction in childhood and it is assumed, with control of these infections, that the incidence of bronchiectasis will fall; there is yet no statistical evidence to substantiate this belief, and the bronchi of children will always remain vulnerable to obstruction and compression because of their size and softness. Management of bronchial and pulmonary inflammatory lesions and prevention and management of the bacterial respiratory complications of the exanthemata and other virus diseases, are, however, generally more successful because of the ready availability of anti-biotics, and it seems reasonable to expect that, in a population properly housed and nourished and well served by respiratory physicians the incidence of bronchiectasis will fall. If the opportunity is still to be taken to conduct a properly controlled trial to compare the surgical and medical managements of bronchiectasis suitable for resection, such a trial will probably have to be undertaken amongst a relatively necessitous population medically ill-served. And if the claim to have demonstrated a specific causative virus in bronchiectasis is substantiated, (Cruikshank, 1948), the belief that the disease will decline may need to be modified. The existence of such a virus seems, on general principles, unlikely, since much evidence points to a mechanical and non-specific inflammatory pathogenesis, but acute bronchiolitis, from which some examples of diffusely scattered bronchiectasis may stem, is unequivocally of specific viral aetiology, (Clarke, Corner, Gambier, Macrae and Peacock, 1964).

The common sites of bronchiectasis are said to be determined by the anatomical vulnerability of bronchi; the longer and more slender bronchi, such as those serving the middle lobe (Brück,1950a) and the lingular segment of the left upper lobe, /

lobe, and the left stem bronchus as opposed to the right, are more easily obstructed. A preponderance of left-sided bronchiectasis is reported in many series (Graham, Singer and Ballem, 1935; Ogilvie, 1941; Whitwell, 1952). Upper lobe bronchiectasis is generally assumed to have developed on the basis of pulmonary tuberculosis. Post-tuberculous bronchiectasis, while common, is often symptomless and those examples of upper lobar bronchiectasis which demand surgical management usually do so because of the symptom of haemoptysis rather than because of cough with the production of purulent sputum. Massive, lethal haemoptysis from bronchiectasis is very rare.

Infection of para-nasal and frontal sinuses in patients with bronchiectasis is common and the symptoms of sinusitis often persist despite surgical or conservative management undertaken before or after the surgical treatment of bronchiectasis. A causal relationship between upper and lower respiratory tract infection in the individual patient can rarely be established, and it has been substantiated (Brock, 1950b) that either may be primary.

The complications of bronchiectasis most frequently encountered are pulmonary, pleural or metastatic (particularly cerebral) suppuration; amyloidosis, as with any other chronic suppurative disease; and cor pulmonale, consequent upon obliteration by fibrosis of large areas of the pulmonary vascular bed. Intracranial suppuration in the form of an isolated cerebral abscess is often amenable to surgical management (Pennybaker and Holmes Sellors, 1948) but metastatic cerebral suppuration is more often in the form of a ventriculitis, and this, while /

while not uniformly fatal, is only occasionally associated with survival, usually with grossly impaired mentality. Acute pyogenic lung abscess in patients who do not have bronchiectasis is said most commonly to be an aspiration phenomenon, with obstruction of small, peripheral bronchi and infection with virulent anaerobic organisms. An intense inflammatory reaction easily obstructs the pulmonary circulation, which is at low tension, so that lung abscess is commonly associated with greater or lesser degrees of mular destruction - pulmonary sphacelation. Despite this, it is common not to be able to demonstrate by bronchography bronchial dilatation in an area in which previously there had been a radiographically obvious lung abscess which has responded to conservative management - perhaps because the lesion in lung abscess is predominantly parenchymal, with obstruction only of very peripheral bronchi, while those demonstrable with standard bronchographic techniques are spared because their circulation is at systemic level. Even when most of a lobe becomes gangrenous recognisable bronchi of relatively normal calibre may be seen traversing the slough. When lung abscess complicates bronchiectasis the flora in the dilated bronchi normal for that patient are presumed to have been altered by the addition of virulent anaerobic organisms, but bacteriological investigation in these circumstances is rarely successful in the demonstration of such a change. In patients with bronchiectasis a complicating lung abscess develops as often in an area of lung subtended by normal bronchi as in an area subtended by bronchiectatic bronchi - lung abscess of the former variety is presumably the consequence of bronchial embolism or spill, of infected material from dilated bronchi. (Fig.4 and 5)

Just /

Just as the radiographic appearances on plain films may be normal in patients with bronchiectasis, so the bronchoscopic appearances, apart from the presence of pus in the bronchi, are often normal. Bronchoscopy is an essential part of the investigation of a patient who may have bronchiectasis, and must precede bronchography both for diagnostic and therapeutic reasons. But the bronchial obstructive element in the pathogenesis of most examples of bronchiectasis is clearly evanescent, because it is relatively rare to find even incomplete obstruction at bronchoscopy proximal to bronchi later shown bronchographically to be dilated. The commonest obstructing lesions found in patients, treatment of whom is directed primarily to the management of bronchiectasi rather than to that of a bronchial obstructing lesion, is a long-retained foreign body or an incomplete bronchial stricture, fibrous on histological examination and presumably the site of what was originally either an acute necrotising bronchitis or a tuberculous lesion. In patients found to have a long-retained bronchial foreign body and shown to have bronchiectasis distal to the site of foreign body impaction after the removal at endoscopy of the obstruction, symptoms of bronchiectasis are surprisingly uncommon - one reason why it is important not to resect lung at thoracotomy for removal at bronchotomy of a foreign body which has resisted removal at endoscopy (le Roux, 1964a). (Fig.6, 7 and 8)

The likelihood of spread and the possibility of resolution of bronchiectasis have exercised clinicians for many years. The question of resolution does not arise if the definition of bronchiectatic bronchi as those permanently dilated is accepted. /

accepted. Fusiform dilatation of bronchi may be demonstrated, either as an "air bronchogram" or by bronchography with radio-opaque material, after a non-specific pneumonic illness associated with a radiographic opacity, or after pulmonary "collapse" or atelectasis, but if such dilatation is not permanent it is not bronchiectatic. To avoid the error of labelling such evanescent bronchial dilatation as permanent it is wise not to undertake bronchography for the purpose of making the diagnosis of bronchiectasis until many months have elapsed after clearing of a radiographic abnormality associated with an inflammatory respiratory illness or following the removal of a bronchial foreign body. Bronchography has a place in the diagnosis of some pulmonary diseases associated with a radiographic opacity - for example, in the diagnosis of intra-lobar pulmonary sequestration (le Roux, 1962) - but in these circumstances the object of bronchography is to demonstrate an abnormality of bronchial anatomy or distribution and not bronchiectasis.

As a rule bronchiectasis has achieved its definitive extent by the time the patient first presents for investigation. For the demonstration of spread of bronchiectasis two bronchograms of a quality good enough for diagnostic purposes are pre-requisite, And it is difficult to imagine circumstances in which a patient would be subjected to a second bronchogram if the first were satisfactory unless an episode, such as a further acute respiratory illness with bronchial obstruction or an operation, had intervened. An unsatisfactory initial bronchogram used to be commonplace and on a second bronchogram of better quality bronchiectasis of an extent not appreciated from the first set of films was often revealed./

revealed. This is not evidence of spread of bronchiectasis. When an operation for bronchiectasis has been complicated by pulmonary shrinkage and bronchial obstruction of long duration, usually by mucus retention, there are reports of the demonstration at subsequent bronchography of bronchi, unequivocally normal on pre-operative films, now abnormal (Chesterman, 1957; Gudbjerg, 1957). This is new bronchiectasis, but the consequence of further bronchial obstruction and infection; it may be acceptable loosely to say, in these circumstances, that bronchiectasis has spread but it is more appropriate to recognise and state clearly that new bronchiectasis has been produced lest the use of the word spread be interpreted to imply dissemination of the original disease. And while it is true that, in clinical practice, bronchiectasis has achieved its definitive extent by the time the patient first presents for investigation, a single episode of bronchial obstruction with infection cannot account for all bronchiectasis in the individual patient with, for example, total bilateral bronchiectasis, since bronchial obstruction implied by bronchiectasis of this extent would be incompatible with survival if it occurred as a single episode. More than one illness must be admitted in these patients or, alternatively, necretising bronchitis with destruction of bronchial walls without complete obstruction - circumstances in which dilatation of weakened bronchi may be consequent upon increase in pressure distal to a closed glottis in coughing, as suggested by Laennec. Post-tubercular bronchiectasis, of which upper lobar bronchiectasis is probably the common example, may often be consequent upon bronchial /

bronchial destruction without obstruction because the progress of a tuberculous lesion has often been followed radiographically and segmental shrinkage and opacities of lobar or segmental distribution are not common while dilated bronchi can be demonstrated within a healed tuberculous focus almost routinely.

Natural History

As with most chronic diseases the clinical features of which depend on bacterial contamination the extent and specificity of which changes, the natural history of bronchiectasis is difficult to define, variable over a wide range, and greatly modified over the last two decades by the ready availability of anti-biotics. Assessment of the natural history is further complicated by laxity in labelling a patient as bronchiectatic without bronchographic evidence or because of the bronchographic changes - small sacculations which protrude from bronchi of normal calibre - in patients with suppurative bronchitis (Reid, 1955). Field (1949), Strang (1956) and Clark (1963) have attempted to outline the natural history of bronchiectasis in children, and Wynn-Williams (1957) in adults. In children symptoms have usually been present for at least five years before detailed investigation is undertaken and the diagnosis established. A clear history of an initial illness is rare; a common history is one of vague ill-health with recurring respiratory illnesses following measles. Recurrent acute respiratory infections with relative freedom from respiratory symptoms between /

between acute exacerbations are more common than are symptoms of cough and sputum which persist without appreciable remission. Haemoptysis is unusual; in children, wheeze is not unusual, and this symptom tends to disappear at puberty. The incidence of finger clubbing varies with the criteria on which this diagnosis is accepted, but an increase in nail bed fluctuation is found in about 50% of patients. Hypertrophic pulmonary osteo-arthropathy has been said to occur in 30% of adult patients with bronchiectasis (Fried, 1943), but in the present series (see Chapter 4) this concomitant of bronchiectasis was found in only two of nearly 1100 patients. While some children with bronchiectasis are thin and underweight, many are of normal physique. In children particularly, chronic upper respiratory tract infection is an almost constant accompaniment of bronchiectasis. The disease will be the cause of death before puberty in about 5% of patients; most, but not all, of those who die would, in any event, not have been suitable for surgical management. Metastatic infection, empyema or lung abscess will complicate known bronchiectasis or be the presenting lesion in a patient later found to have bronchiectasis in a further 5%. In this assessment of bronchiectasis children with the cystic pulmonary complications of staphylococcal pneumonia or with congenital cystic disease of the lungs are not included, since these are believed to be diseases entirely distinct from bronchiectasis.

At puberty all symptoms, not only wheeze, often become less obtrusive (Field, 1961), and in late adolescence, perhaps with diminishing parental supervision, symptoms tend to be ignored unless they constitute a bar to normal social /

social activities or unless either exacerbations are unusually acute or complications supervene. Wynn-Williams (1957) observed for a five year period some 200 patients with bronchiectasis, nearly all of them adults, in whom the disease was managed other than by resection, although in some the extent of bronchiectasis was within anatomical limits of resectability. Fewer than 4% of this group of patients were unable to work and in few did the disease constitute a source of social or marital embarrassment - a picture of bronchiectasis very different from that drawn by Churchill (1938) some 20 years earlier, and by Perry and King (1940) and Bradshaw et al. (1941), who found children mentally and physically stunted, and adults, amongst whom the suicide rate was higher than in the population at large, beset with marital, social and employment problems because of cough, foetid sputum and chronic ill-health with frequent acute respiratory illnesses of incapacitating severity.

In this context of a greatly changed natural history the influence of surgery in further modifying this natural history is almost impossible to assess. That in many patients established bronchiectasis can be managed medically so as to make life not only tolerable but profitable is unquestionable, but the very factors which have so altered the natural history of the disease - anti-biotics and improvements in social and medical services which have brought all patients with bronchiectasis and not only those with the grossest examples of the disease to the notice of physicians - have also influenced the rate of surgical success in its management. And it is at least very likely if not certain that what was earlier called the natural history of the disease was in fact only the natural /

natural history of the greater examples of bronchiectasis, and that the overall picture of the disease has been modified as much by the accurate diagnosis of many cases of bronchiectasis with minimal symptoms which, in earlier years, escaped recognition, so widening the field from which to select typical examples of the disease as illustrating the natural history, as by treatment, whether medical or surgical.

In summary, bronchiectasis is a morbid anatomical diagnosis. The demonstration by bronchography of dilated bronchi to one, many, or even to all broncho-pulmonary segments, while diagnostic of the morbid anatomical state, has in itself no bearing on the extent to which the individual untreated patient is disturbed by the pathology. The clinical disease called bronchiectasis implies an anatomical abnormality of bronchi in a patient with symptoms, usually of infection, either local, general or metastatic, and sometimes of pulmonary vascular obstruction, which can be clearly related to bronchial dilatation. This clinical disease has a varied and variable natural history. Dilated bronchi may serve a segment, lobe or lung of normal volume with measurable although diminished respiratory function or one shrunken and airless and devoid of function. Dilated bronchi may be found in a patient whose life is not at any time recognisably disturbed and may, at the other extreme, be associated with a disease state which, because of infection, terminates life in early childhood. Between these extremes dilated bronchi may be found in patients who have a single, isolated or occasionally repeated small haemoptysis, or in patients with haemoptysis of such severity as to frighten even the most phlegmatic; dilated bronchi may be found in patients who /

who experience in a life-time only a single episode of acute pulmonary or pleural infection or in patients with recurrent minor or major respiratory illnesses; and in patients with chronic non-specific ill-health, with persistent respiratory symptoms which disturb normal life little or greatly, or which make life intolerable, and with respiratory symptoms of many intermediate grades of severity. And symptoms of measurable severity will disturb insignificantly one patient and modify importantly the way of life of the next, while in the individual patient symptoms which vary little will at some periods in a life-time embarrass greatly and at other times not recognisably disturb.

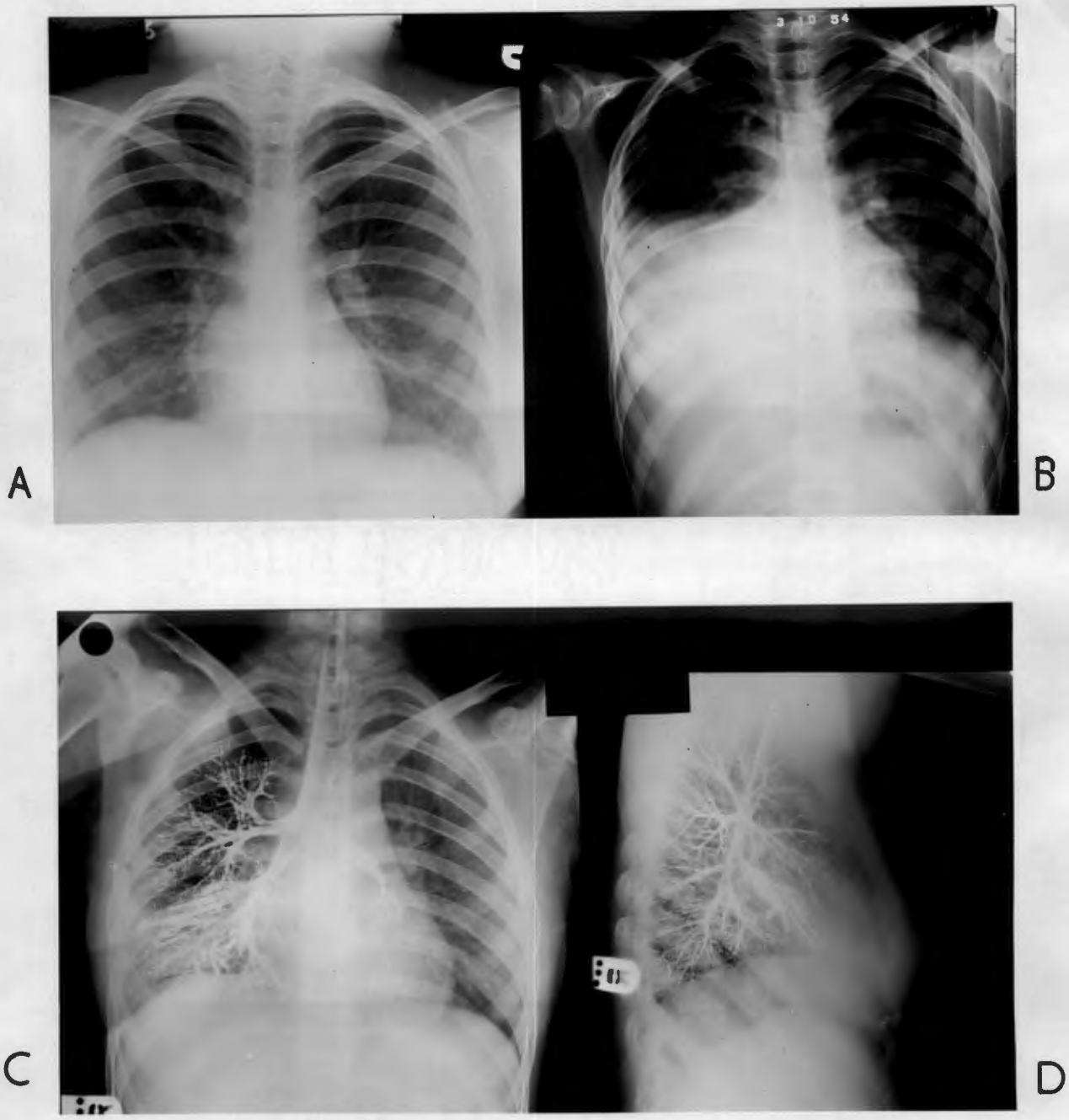

Fig. 3

Bronchiectasis of the middle lobe (C & D) demonstrated six months after the removal at bronchoscopy of a blade of grass which had been retained for eight days when the PA chest radiograph (B) was made. In this the middle and lower lobes are opaque and a little shrunken. The radiograph (A) was made a week after removal of the foreign body.

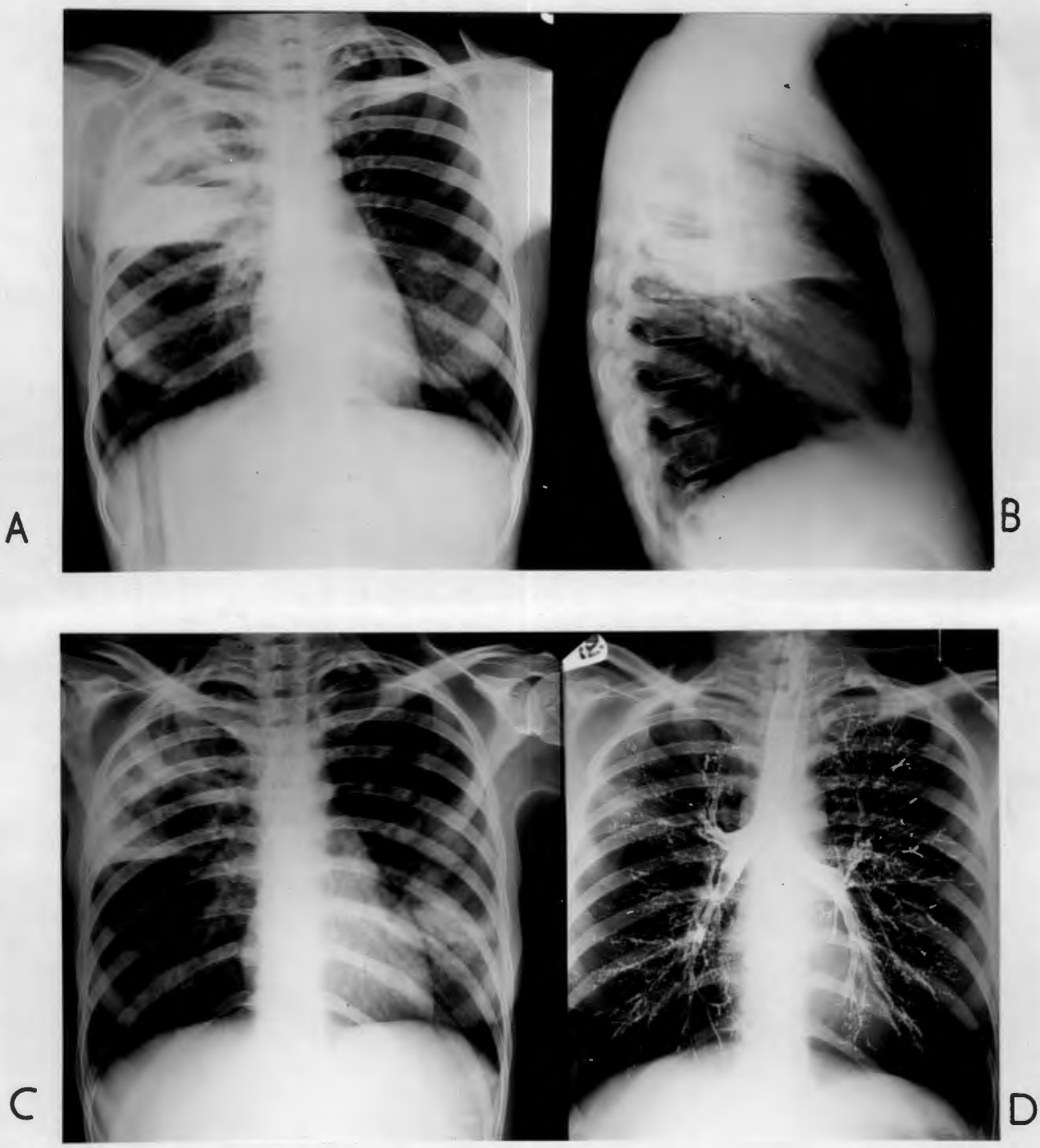

Fig. 4

Clinical and radiographic recovery from acute right upper lobe lung abscess (A & B), by posture and chemotherapy, was prompt, despite the development of an aspiration pneumonia in the lingular segment of the left upper lobe (C). The bronchogram (D) was made six months later and there is not a recognisable abnormality in the right upper lobe - a usual bronchographic sequel to acute pyogenic lung abscess.

A B

C D

Fig. 5

An acute lung abscess so diminished respiratory reserve in the patient whose films are shown (A & B) that management included tracheostomy and intermittent positive pressure respiration. In convalescence a fragment of lung slough was coughed up. The abscess was in the middle lobe and the bronchi in this are not normal, in so far as they are shown bronchographically in (C) & (D) - a bronchogram made late in convalescence. The right upper lobe is shrunken and the bronchi in it grossly abnormal. There is no way of deciding if the lung abscess in this patient developed in an area of bronchiectasis or was the consequence of spread of infection by bronchial embolism from the upper lobe and the bronchial abnormality in the middle lobe is the consequence of the abscess.

Fig. 6

A foreign body had been retaind in the left main bronchus for a month when the PA radiograph (A) was made. The foreign body resisted disimpaction at endoscopy and was removed by bronchotomy at formal lateral thorecotomy; radiographic normality was quickly restored (B). At bronchography a year later the left basal bronchi were shown to be abnormal but not grossly bronchiectatic (C & D) and the boy was symptomless. No further surgical action has been taken.

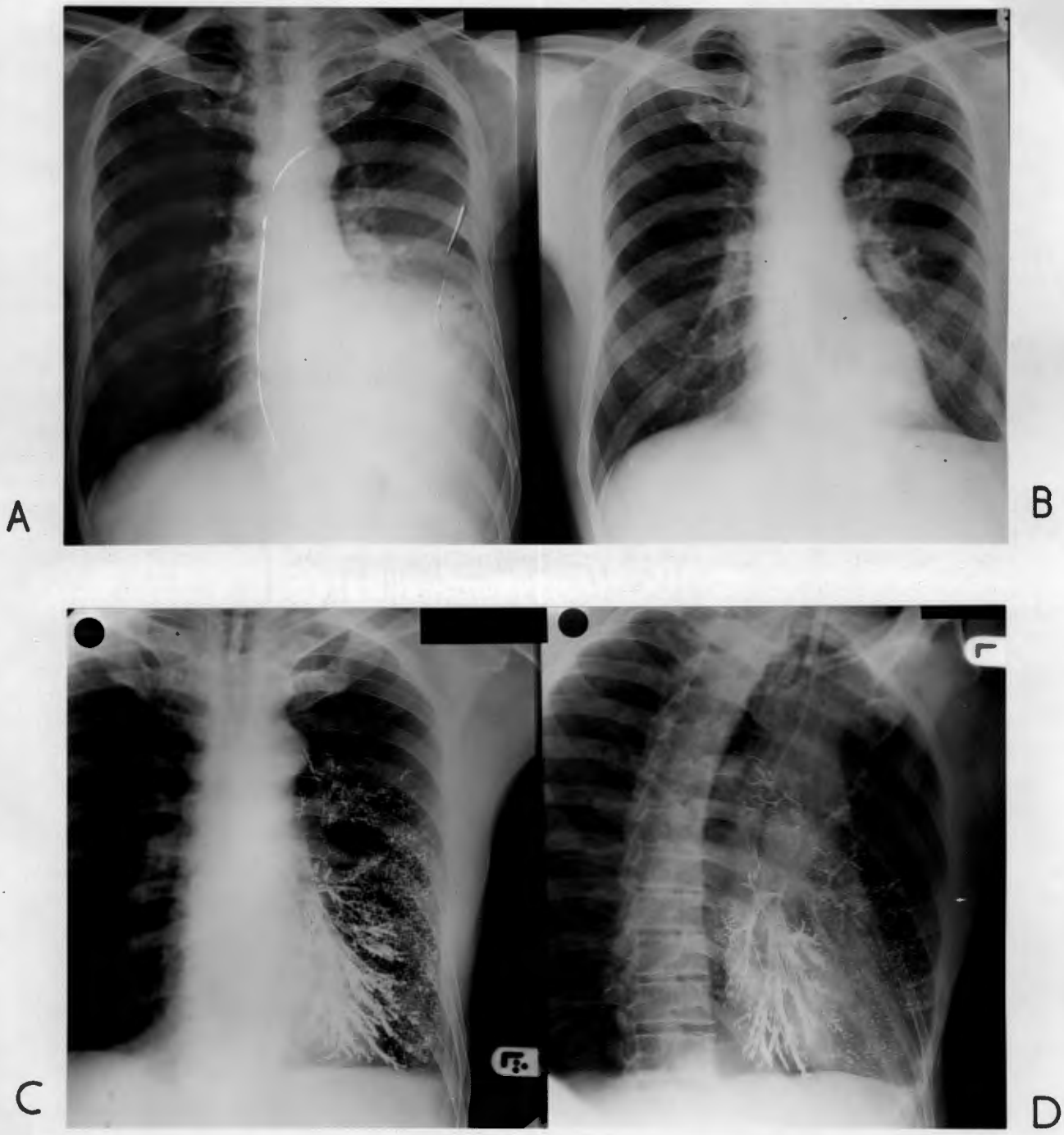

Fig. 7

Left basal bronchiectasis (C & D) was demonstrated a year after removal at bronchoscopy of a fragment of bone from the left lower bronchus. The foreign body had probably been retained for many years. Following bronchoscopy radiographic clearing from the state shown in (A) to that in (B) took several weeks. Symptoms of cough and sputum of many years duration disappeared quickly after removal of the foreign body and no surgical action has been taken in respect of the bronchiectasis.

Fig. 8

Respiratory symptoms of many years duration in the patient whose films are shown above were related to retention in the intermediate bronchus of a large fragment of bone. Shrinkage of the middle and lower lobes and severe symptoms persisted after the removal at endoscopy of the foreign body, and gross bronchiectasis of these lobes was shown bronchographically (B). Because of the severity of symptoms and despite the patient's advanced years middle and lower lobectomy were undertaken with relief not only of cough and sputum but also of dyspnoea. Shrinkage of the middle and lower lobes is clear in the pre-operative PA chest radiograph (A).

CHAPTER II

THE ANATOMY OF THE BRONCHI

In the management of bronchiectasis the accurate interpretation of bronchographic abnormalities is essential for the selection of patients for surgical treatment and for the precise planning of the extent of resection. There follows a brief account of the anatomy of the bronchi in order to establish a common anatomical nomenclature in the identification of bronchi, and to relate anatomical vulnerability with common distributions of bronchiectasis. Internationally accepted nomenclature ascribes names as well as numbers to the segmental bronchi and these numbers have been attached to two of the illustrations of normal bronchial anatomy (Figs. 10 & 16). The arrangement of bronchi on the right is most clearly seen in a right lateral bronchogram (Fig. 11), in which all the bronchi are well contrasted against the mediastinal shadow except the right upper bronchus, which passes directly laterally and is therefore seen as a well-defined radio-translucent circle, and the medial basal bronchus, which is often obscured by the other right basal bronchi. The arrangement of left bronchi is most clearly shown radiographically in an oblique view, in which the remarkably graceful sweep of the left bronchi is well shown (Figs. 17 - 23).

The/

The Right Bronchi

At its caudal end the trachea divides into a right and left main bronchus. The right main bronchus is shorter, a little wider, and a more direct continuation of the trachea than the left. The sharp cartilaginous ridge between the origin of the two main bronchi is called the main carina. There are carinae at the origins of all the more distal bronchi but there is only one main carina.

About one centimetre distal to the origin of the right main bronchus a large bronchus arises from its right lateral wall: this is the right upper bronchus, the bronchus which used to be called eparterial. The right upper bronchus is short and after about one centimetre divides, as a trifurcation or as two closely spaced bifurcations, into three segmental bronchi - anterior, apical and posterior - which serve the three segments of the upper lobe. Anatomical variations are found in 3 per cent. of right upper bronchograms, (le Roux, 1962b)

The continuation of the right main bronchus distal to the origin of right upper is called the lower part of the right main bronchus; this is the bronchus which used to be called hyparterial, and an alternative name commonly used is intermediate. The lower part of the right main bronchus terminates after 2 or 3 cm. with the origin of the bronchus to the middle lobe which passes anteriorly and a little caudally from the anterior wall of the parent bronchus. The middle bronchus divides into two segmental branches called medial and lateral.

The /

The right parent bronchus - main and lower part of main - continues after the origin of the middle bronchus as the lower bronchus and is a straight tube of diminishing calibre to the whole length of which the term right stem bronchus is sometimes applied. The right lower bronchus serves the lower lobe. Its first segmental branch, to the apical segment of the lower lobe - the apical lower bronchus - arises from the posterior wall of the lower bronchus only a short distance caudal to the origin of the middle bronchus. The apical lower bronchus may arise directly opposite the origin of the middle bronchus and occasionally at an even more cephalad level, and it is in these circumstances that the term stem bronchus is particularly valuable, since it becomes difficult to decide whether there is no lower bronchus or whether the middle lobe bronchus arises from the lower lobe bronchus.

From the medial wall of the lower bronchus, usually about one centimetre distal to the origin of the apical lower bronchus, the medial basal bronchus originates; this bronchus is often called cardiac. Beyond the origin of the medial basal bronchus three other basal bronchi - anterior, lateral and posterior - arise, usually as two bifurcations in rapid succession, occasionally as a trifurcation. A common arrangement is for the first bifurcation to represent that between anterior basal on the one hand and, on the other hand, a bronchus which continues as posterior basal after lateral basal has arisen from it. A not infrequent alteration in the pattern described is for an additional bronchus to arise from the posterior wall of the right lower bronchus distal to the origin of apical lower and proximal to that of /

of medial basal. This additional bronchus is called sub-apical and is commonly associated with an apical lower bronchus which arises from a more cephalad level. The arrangement of bronchi on the right is illustrated in Figs. 9 - 15.

Fig. 9

In the antero-posterior bronchogram shown above the anatomical arrangement of bronchi is clear, the bronchi are normal, and radiographic and bronchographic technique is of a high order.

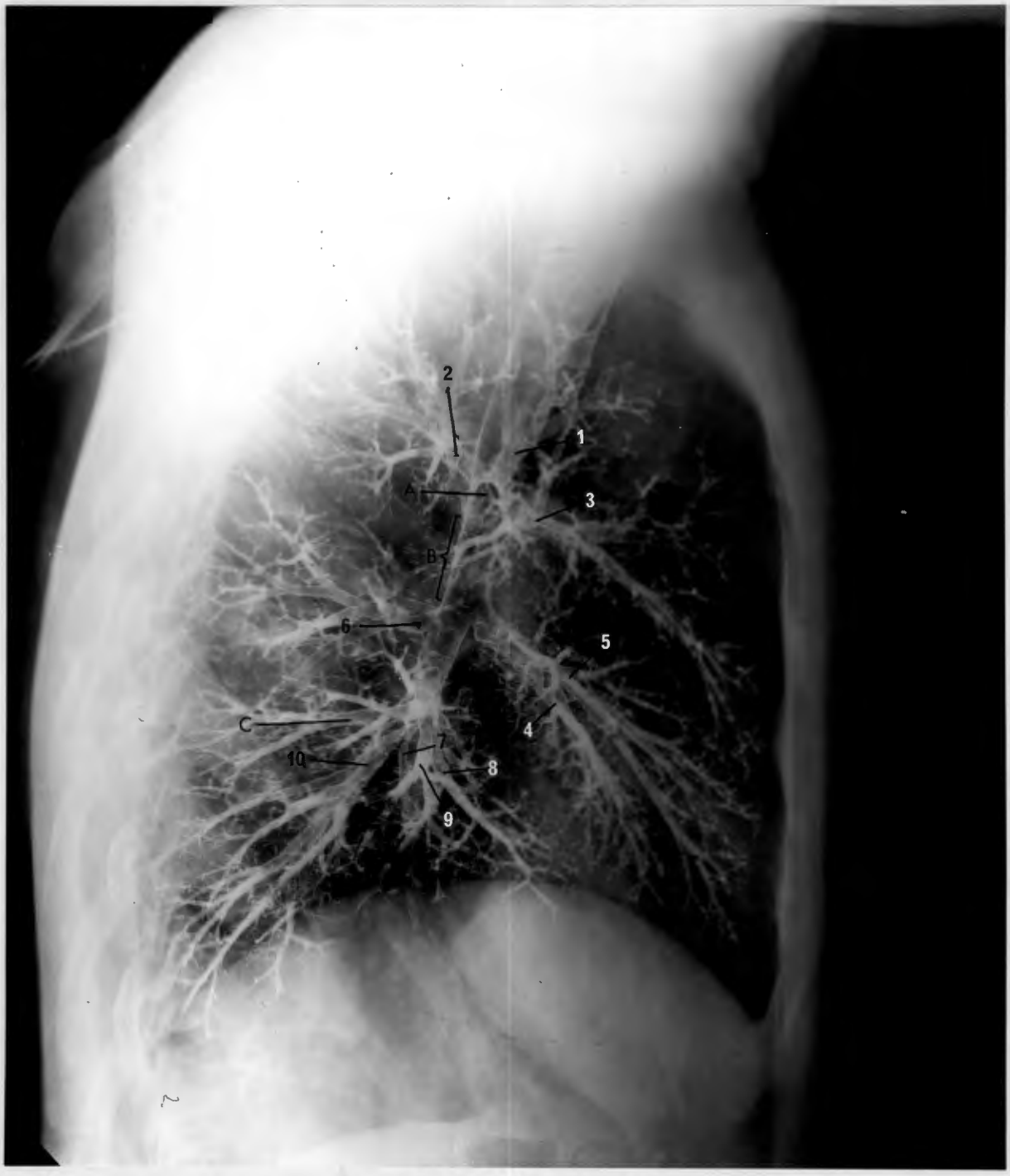

Fig. 10

In this right lateral bronchogram the right bronchi are well-outlined and are normal. The right upper bronchus (A) is seen end-on. The lower part of the right main bronchus is bracketed (B). There is a bronchus posteriorly directed and subapical in position (C) which arises distal to the medial basal bronchus. The posterior basal bronchus is large in comparison with the other basal bronchi. The lateral segment of the middle lobe is usually the smaller and lower.

Right Upper Lobe	Middle Lobe	Right Lower Lobe
1. Apical bronchus	4. Lateral bronchus	6. Apical bronchus
2. Posterior bronchus	5. Medial bronchus	7. Medial basal bronchus
3. Anterior bronchus		8. Anterior basal bronchus
		9. Lateral basal bronchus
		10. Posterior basal bronchus

Fig. 11

Right lateral bronchograms from four different subjects serve to illustrate minor variations in the normal anatomical arrangement. In (D) the medial basal (cardiac) bronchus is particularly clear - this is the bronchus which arises immediately caudal to the apical bronchus of the lower lobe and which passes downwards and forwards at an angle slightly more acute than that made by the middle bronchus with the right stem bronchus, from which the middle bronchus arises anteriorly and immediately rostral to medial basal. The position of the oblique and transverse fissures has been indicated in (D).

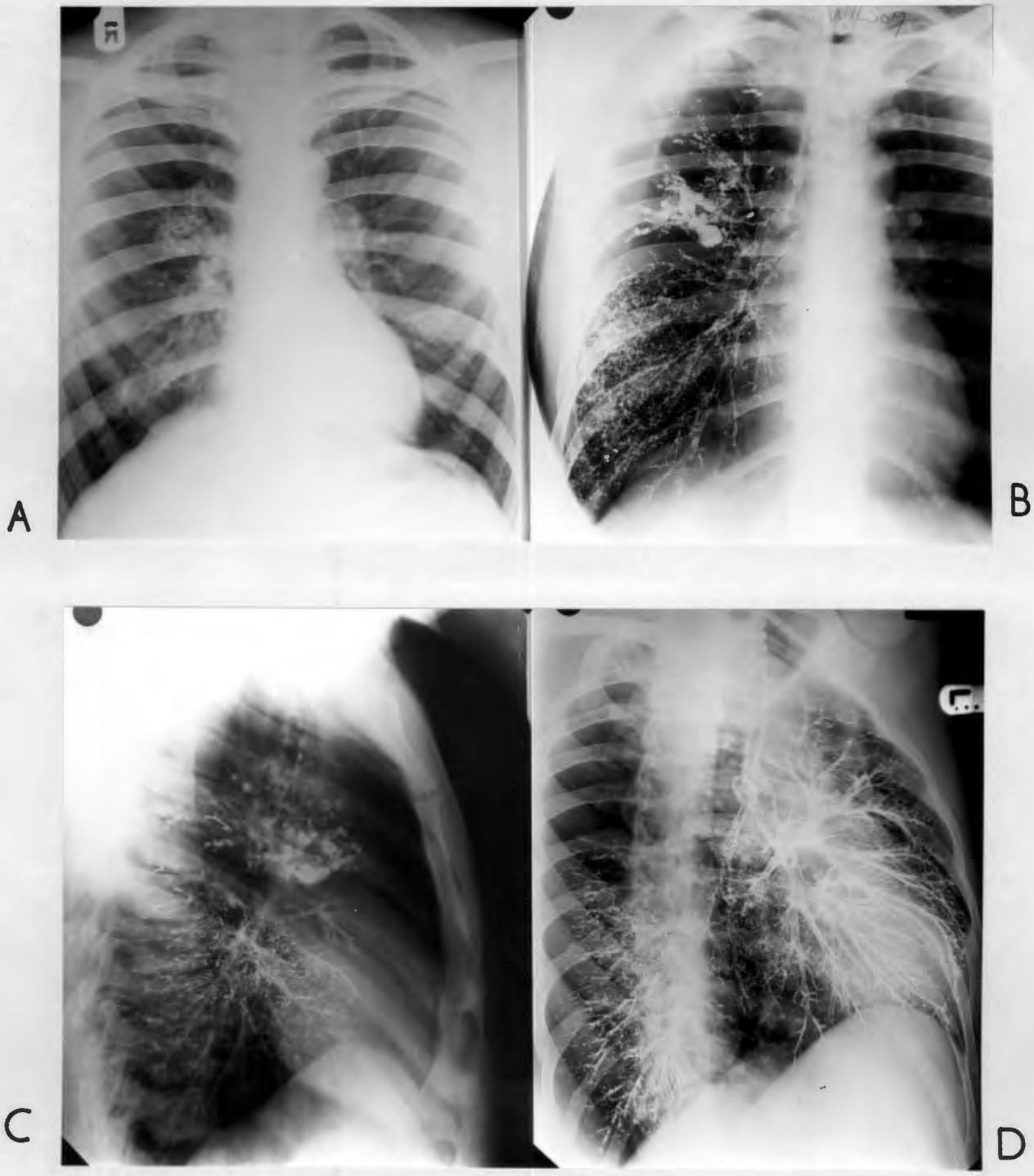

Fig. 12

Bronchiectasis of the right upper lobe, here shrunken, serves to identify this in the AP and right lateral bronchograms (B) & (C). The right anterior segment is largely replaced by cystic spaces visible in the PA film (A). The medial (upper) division of the middle bronchus is, in (C), drawn upwards and incompletely filled. The left oblique bronchogram (D) is the companion of the other films and shows clearly the common dichotomous arrangement of left upper bronchi, an arrangement here continued into the basal bronchi.

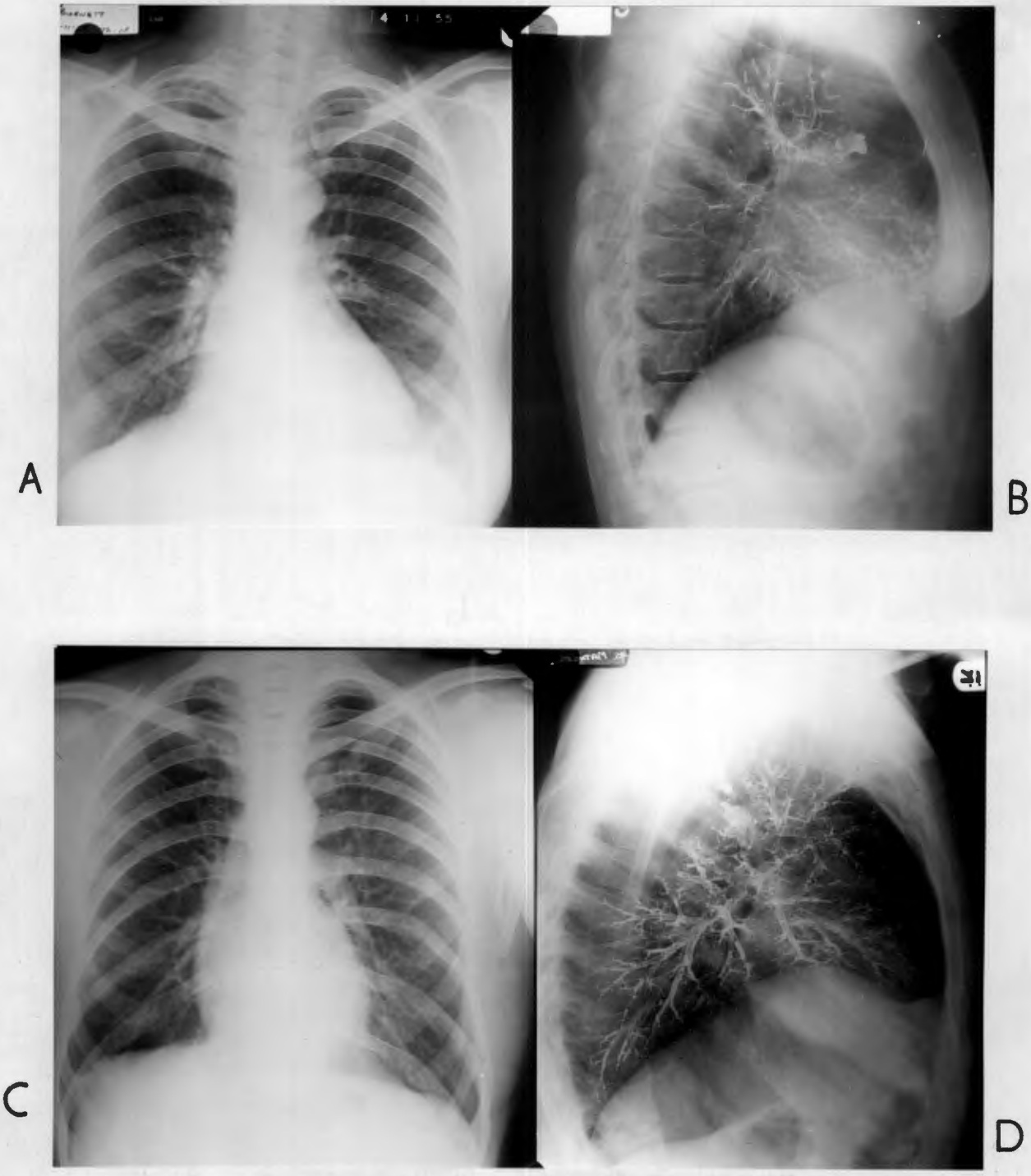

Fig. 13

Bronchiectasis of the right anterior segment in (B) is illustrated for comparison with bronchiectasis of the right posterior segment in (D). The plain films (A) & (C) relate respectively with these right lateral bronchograms and serve each no more than to draw attention to the right upper lobe in the patients whose films these are; they do not allow of the diagnosis of bronchiectasis. Both patients presented with haemoptysis.

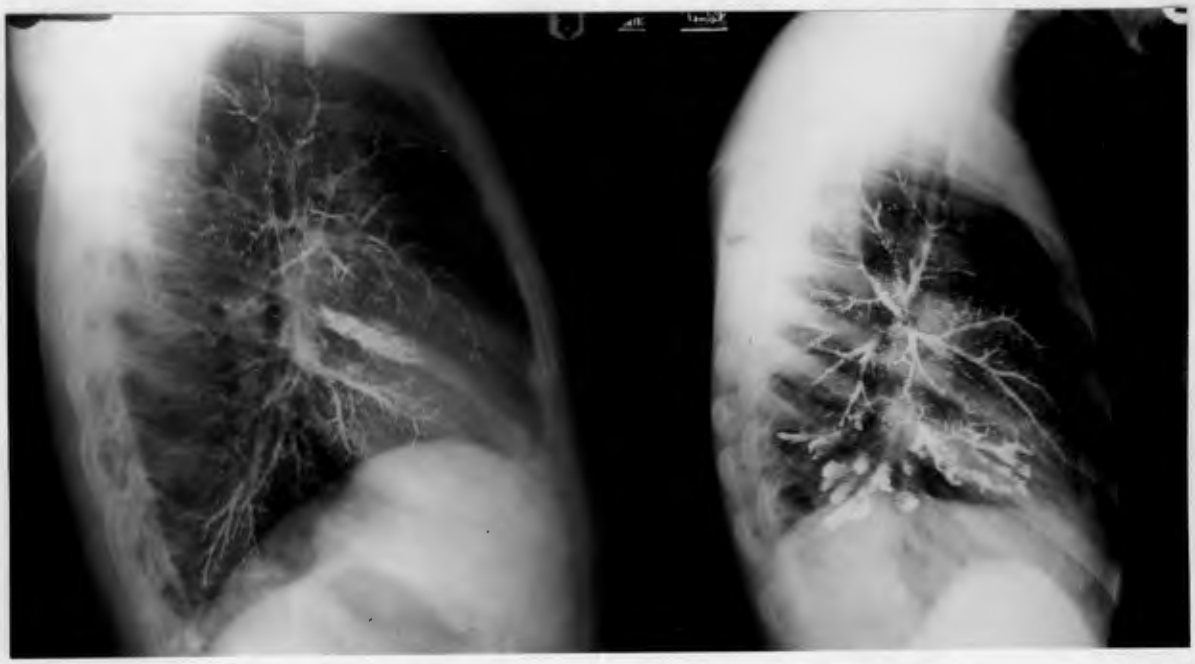

A B

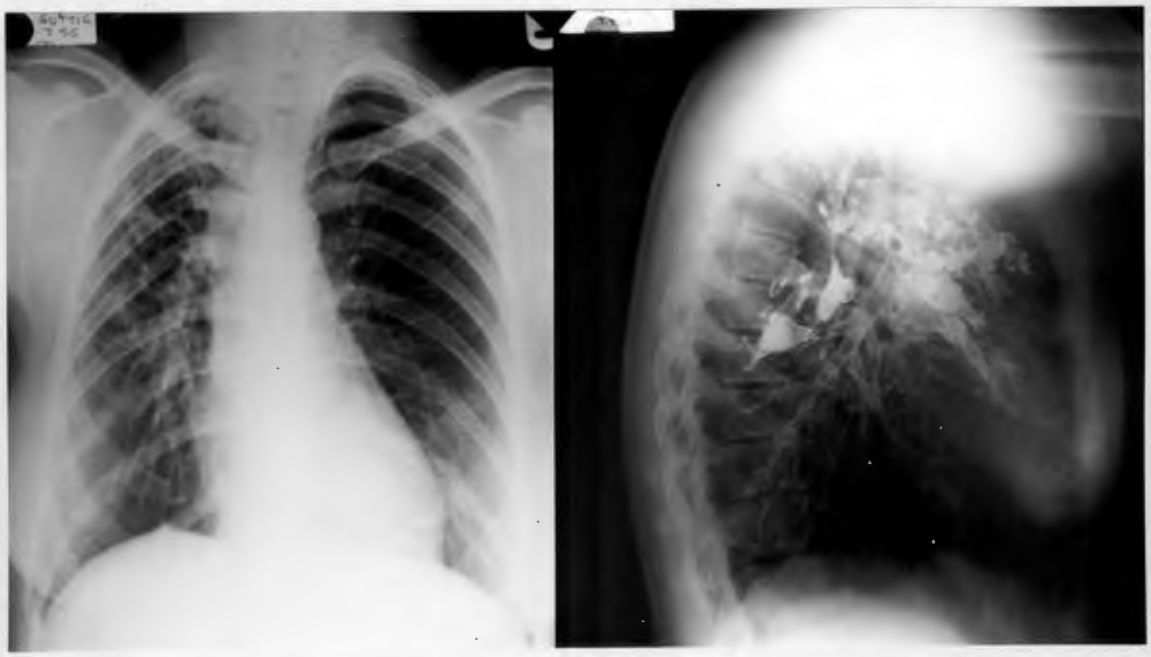

C D

Fig. 14

In the right lateral bronchogram (A) the middle lobe is bronchiectatic; in (B) the middle and lower lobes are bronchiectatic. These bronchograms are illustrated with the purpose of facilitating identification of the middle bronchus in (A), in which the bronchus to the apical segment of the right lower lobe arises from the stem bronchus rostral to the origin of the middle bronchus, and to show more clearly the segmental bronchi in the right upper lobe because they are splayed in (B). The posterior segmental bronchus on the right is often smaller than its apical and anterior companions.

In (D) bronchiectasis of the right upper lobe and of the apical and sub-apical segments of the right lower lobe is related to pulmonary shrinkage which so disposes the bronchi that identification of the sub-apical bronchus, which originates in the same sagittal plane as the medial basal bronchus, is facilitated. The PA film (C) is of the patient whose bronchogram is (D); cystic spaces in the right upper zone and shrinkage of the right hemithorax are clear.

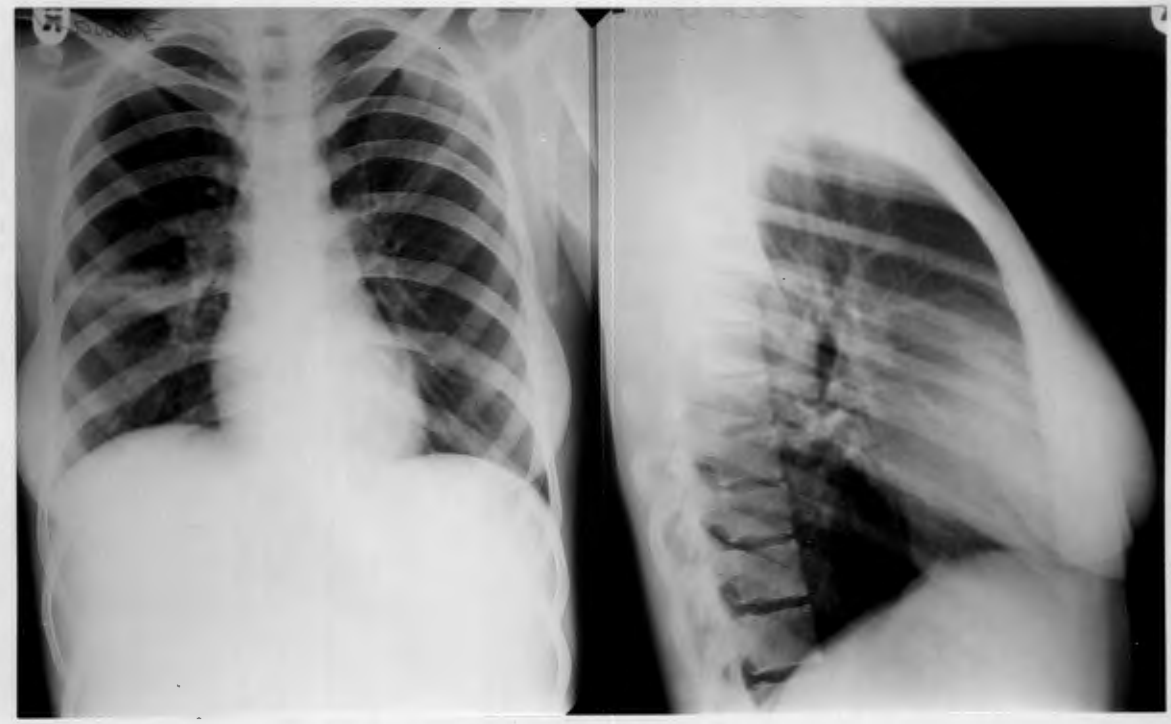

A B

C D

Fig. 15

A right sub-apical bronchus is seen with particular clarity in the bronchograms (C) & (D) because this bronchus is bronchiectatic. The corresponding pulmonary opacity visible in the PA and lateral radiographs (A) & (B) had persisted for more than a year

The Left Bronchi

The left main bronchus terminates after 4 or 6 cm. by dividing into two bronchi of nearly equal size called the left upper and the left lower bronchi. The left main and lower bronchi together are a virtually continuous tube of diminishing calibre and to them together the term left stem bronchus is sometimes applied. The left upper bronchus deviates abruptly to the left, laterally and anteriorly from the left stem bronchus.

The anatomy of the left lower bronchus is similar to that of the right lower bronchus except that there is usually no medial basal bronchus on the left. One is occasionally found and a left sub-apical bronchus may also be present.

The distribution of bronchi in the left upper lobe is variable (Scammell, (1947); Boyden, (1949a & b); Brock, (1954); and le Roux, (1962c)), especially that of the segmental bronchus or group of bronchi which, according to the international nomenclature accepted by the Thoracic Society in 1950, is known as the anterior segmental bronchus. In an analysis of the behaviour of this segmental bronchus in 50 lungs, Boyden and Hartmann (1946) were able to illustrate no fewer than 12 variations.

After scrutiny of 1,223 consecutive left oblique bronchograms made in the Regional Thoracic Unit in Edinburgh, 1,000 were accepted as demonstrating with sufficient accuracy the distribution of bronchi within the left upper lobe. The bronchograms were all made with the patients in the recumbent position; in each instance, the left bronchi were shown on right anterior oblique and anteroposterior views.

In /

In 830 bronchograms (83 per cent), the left upper bronchus divided into two branches of equal or nearly equal diameter (Figs. 17, 18 and 19). The accepted naming of these two divisions is upper and lingular (lower). In 58 of these 830 bronchograms, the upper division was unusually small or the lower division unusually large. In all 830 bronchograms, the behaviour of the upper and lower divisions of the left upper bronchus was similar. The lower division, the lingular bronchus of international nomenclature, divided into two - an upper division running forward (anterolaterally) and, in some instances, slightly downward, and a lower division, the first branch from which ran forward and, always, downward. After a variable but usually considerable length, the continuation of the lower division of the lingular bronchus then divided into two slender branches which pursued a nearly parallel course and from which significant branches rarely arose. The bronchi of the third order are, however, not sufficiently constant in their behaviour to enable names to be confidently applied to them. The upper division is also divided into two - one branch ascending to the apex of the upper lobe to supply this and the posterior part of the lobe, and called the apicoposterior bronchus; the other passing upward and slightly forward (this is the anterior segmental bronchus of international nomenclature). The common anatomical arrangement of the proximal bronchi in the left upper lobe is, therefore, dichotomous; a single bronchus dividing into two and each of these two divisions again dividing into two. The lower division of the left upper bronchus is held to be the homologue of the middle bronchus on the/

the right, and the upper division the homologue of the upper bronchus on the right.

In 147 bronchograms (14.7 per cent), the left upper bronchus divided into three branches of equal or nearly equal diameter (Figs. 21, 22 and 23). In 27 of these 147 bronchograms, the middle division of the left upper trifurcation appeared to favour a little in its origin the lower division, and, in 23, the upper division. Where the left upper bronchus divided into three branches, the architecture of the lowest division was, in 75 per cent, the same as in the lower division of those bronchograms illustrated earlier as examples of a bifurcating left upper bronchus; in 25 per cent, one of the proximal anteriorly directed branches of this lowest division was small or absent. The arrangement of the branches of the lowest division was always the same as in the lower division of a bifurcating left upper bronchus when the middle division of a trifurcation appeared to favour the highest division, and was not always deficient of one branch when the middle division appeared to favour the lowest division. The highest division of a trifurcating left upper bronchus was distributed in the same way as the upper division in the common arrangement of a bifurcating left upper bronchus, but served a smaller area of lung.

In 3 of the 147 bronchograms in which the left upper bronchus divided into three, the highest division divided again so rapidly into two that the left upper bronchus appeared almost to divide into four.

In /

In 20 bronchograms (2 per cent), the upper division of a bifurcating left upper bronchus was considerably larger than the lower division (Fig. 24). In this 2 per cent, the bronchogram of the lower division was unchanged from that in the 83 per cent described earlier, and the appearance of the upper division suggested that a middle division, such as that described in the 14.7 per cent of trifurcating left upper bronchi, had migrated to favour even further a normal upper division, rather than that the upper division was itself abnormally large, since the arrangement of bronchi usually present in the upper division could be identified, and there was, in addition to these, a large anterolaterally directed bronchus. It is only in this 2 per cent of bronchograms that the internationally accepted nomenclature appears to suit the arrangement of the bronchi in the left upper lobe.

In 3 bronchograms out of 1,000, a bronchus with the distribution of an upper division originated from the left main bronchus, and the left upper bronchus had an appearance which suggested the combination of a middle and lower division.

The arrangements of bronchi described above follow closely those recognised by Boyden,(1949 b) who interpreted the differences as the consequence of variable behaviour, migration and splitting of the anterior segmental bronchus. But in nearly all the examples of a trifurcating left upper bronchus, the arrangement of bronchi in the highest and lowest divisions is the same as in the upper and lower divisions of a bifurcating left upper bronchus - as if the middle component of the trifurcation were a new bronchus. The arrangement, in /

in which an additional bronchus is found, occurs often enough (14.7 per cent of 1,000 bronchograms) to justify identifying this middle division by a name; and to give this middle division a name which is not used in the common arrangement of bronchi, in which the left upper bronchus bifurcates, would serve immediately to identify the patient with such a trifurcation.

When a bronchus-obstructing lesion blocks one or other of the divisions of a bifurcating left upper bronchus, the areas of atelectasis demonstrable radiographically illustrate the division into two of the left upper lobe (Fig.20). In a small number of bronchial casts available for scrutiny, the volume of the lower half of the lobe is a little less than that of the upper half in most instances. During the relatively short period in which these observations have been made from bronchograms taken over 13 years and deposited in the archives of this Unit, no patient has been submitted to resection for a bronchus-obstructing lesion confined to the middle division of a trifurcating left upper bronchus, so that the segmental opacity produced by such a lesion cannot be reproduced for comparison with the previous radiographs.

A nomenclature suitable for the bronchi in the left upper lobe must identify the left upper bronchus and its common division into two, and the further division of these two branches each into two. There is no surgical need to name bronchi further than the second division of a lobar bronchus. When the left upper bronchus trifurcates, the middle division should be given a name not used when the upper bronchus bifurcates. As a start in naming the left upper segmental bronchi, the designation "lingula" is hallowed by antiquity and, when /

when applied to the familiar and constant tongue-like process at the antero-inferior extremity of the left upper lobe, has a distinct morphological significance. The "tongue" of the left upper lobe is, however, small and, although names are applied to many anatomical structures so that they may be recognised by their appearance, it would seem reasonable not to confine the term lingula entirely to the "tongue" but rather to use it for a larger part of the upper lobe to which the "tongue" is attached. The left apicoposterior segmental bronchus of international nomenclature is small, its division into apical and posterior divisions often unrecognisable bronchographically, and names are given (apical and posterior) to third divisions of a lobar bronchus.

All the branches of the lower division of the left upper bronchus, the lingular bronchus of international nomenclature, pass in an anterior and lateral direction. In his original description of these bronchi Brock (1943) used the term "pectoral" to designate some anterior and laterally directed bronchi. It is suggested, therefore, that the euphonic term "lingulo-pectoral stem" be applied to the lower division of the left upper bronchus, and that the anterolaterally directed branch numbered 4 in Fig. 16 be called the pectoral bronchus, rather than the superior division of the lingular bronchus in some instances and part of a split anterior segmental bronchus in others. The more caudally directed bronchus numbered 5 in Fig. 16 is the lingular bronchus. Its subdivisions are of the third order, but if they are to be named then the superior division passes forward and downward, and the inferior division labelled D in Fig. 16 is identifiable by the remarkably constant "cleft-stick" appearance. Using this connotation, the lower division of the lingular bronchus supplies the "tongue"./

"tongue". It is suggested further that the upper division of a bifurcating left upper bronchus be called the "apico-posterior stem," from which arise an apical bronchus (3 in Fig. 16), some branches of which certainly pass anteriorly, and a posterior bronchus, some branches of which certainly supply the apex of the lobe. The term "anterior" is deliberately omitted from this nomenclature, because in the common arrangement of the left upper bronchi no single bronchus is directed anteriorly, the anterior "segment" being supplied by bronchi from both the upper and lower divisions. International nomenclature omits the "lateral" from anterolaterally directed bronchi.

When the left upper bronchus trifurcates, it is suggested that the middle division be called the anterior segmental bronchus. This designation would have the advantage of indicating immediately that a patient has a trifurcating left upper bronchus. Since the architecture of the highest and lowest divisions in a trifurcating left upper bronchus is the same as that of the upper and lower divisions in a bifurcating left upper bronchus, the names given to these branches is suitable to either arrangement of bronchi. Thus, in the rare instances (2 per cent of 1,000 bronchograms) in which a middle division appears to arise from the apicoposterior stem, such a patient would be described as having an anterior bronchus arising from the apicoposterior stem.

The objections to this suggested nomenclature are that it introduces a previously discarded designation - pectoral, that it disturbs an international classification, and that it dissociates the nomenclature of the right and left bronchi. The surgeon's knowledge of the bronchi in the individual patient is gained from examination through a bronchoscope and from the scrutiny of bronchograms /

bronchograms made with the patient in standard positions. There is in fact very little bronchoscopic or bronchographic similarity between the bronchi in the right and left upper lobes, and the nomenclature suggested enables the surgeon to designate all the major divisions in the standard left upper bronchogram without becoming involved in rarely recognizable divisions of the third order and, also, to indicate the one common variation, the one in which the left upper bronchus divides not into two but into three. International nomenclature seems applicable to only 2 per cent of left upper bronchograms and, if "lingular" is acceptable as a variation on the left, there is no valid reason for not accepting "pectoral". The anterior segmental bronchus on the right is directed antero-laterally, and the homologue of this single segmental bronchus is encountered on the left in only 14.7 per cent of bronchograms. Much confusion which attaches to the meaning of the surgical resection designated "lingulectomy" would also be avoided.

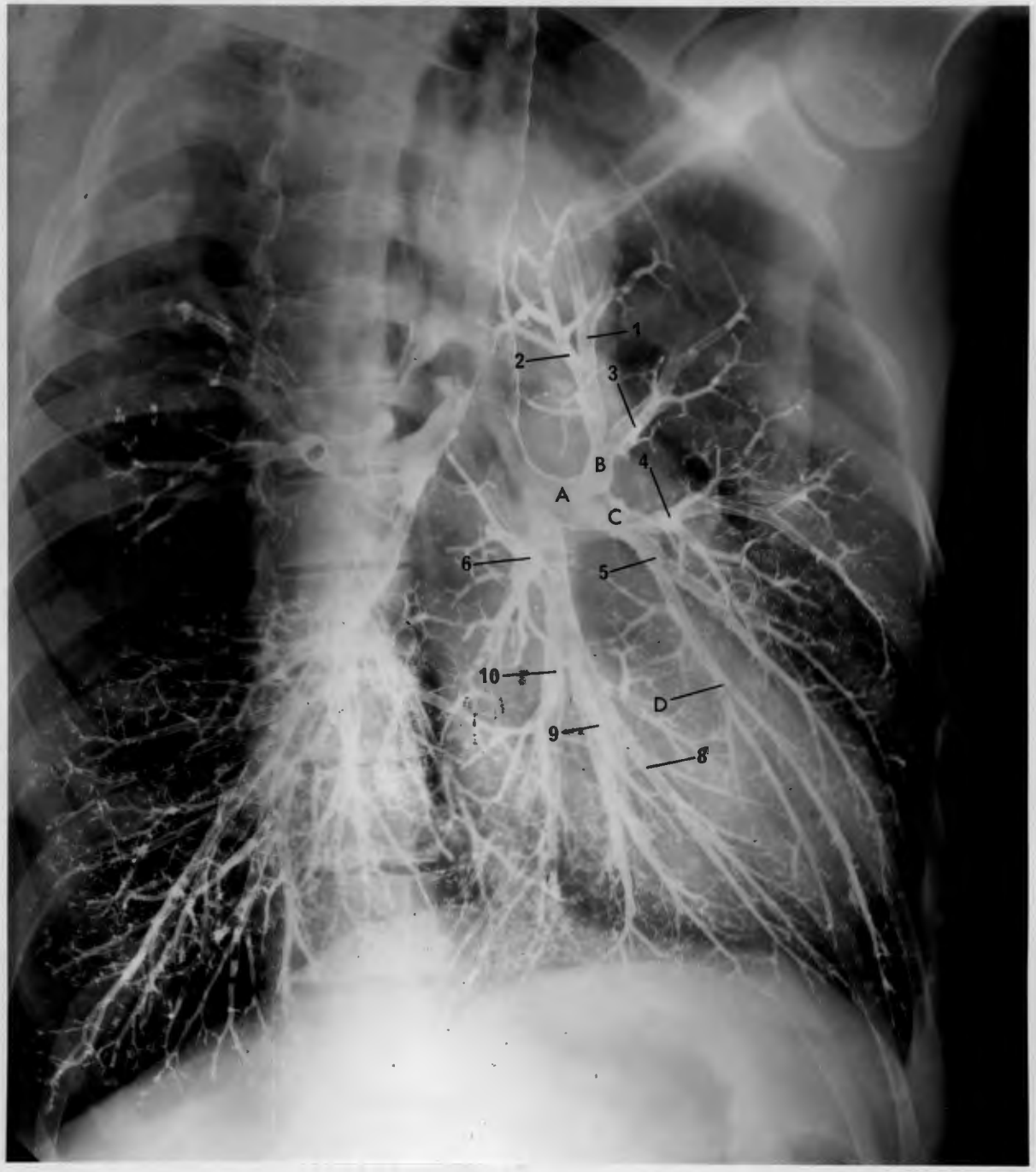

Fig. 16

In this left oblique bronchogram the dichotomous arrangement of the left upper bronchi is shown. The left upper bronchus (A) divides into an upper division (B) and a lingular (lower) division (C). The cleft stick of the lingular is marked (D) at its site of cleavage. The superior division of the lingular segmental bronchus appears in this, as in many other left bronchograms, far more to justify the name anterior than does the anterior segmental bronchus.

Left Upper Lobe		Left Lower Lobe
1. Apical bronchus		6. Apical bronchus
2. Posterior bronchus		8. Anterior basal bronchus
3. Anterior bronchus		9. Lateral basal bronchus
4. Superior bronchus	Lingular	10. Posterior basal bronchus
5. Inferior bronchus	Lingular	

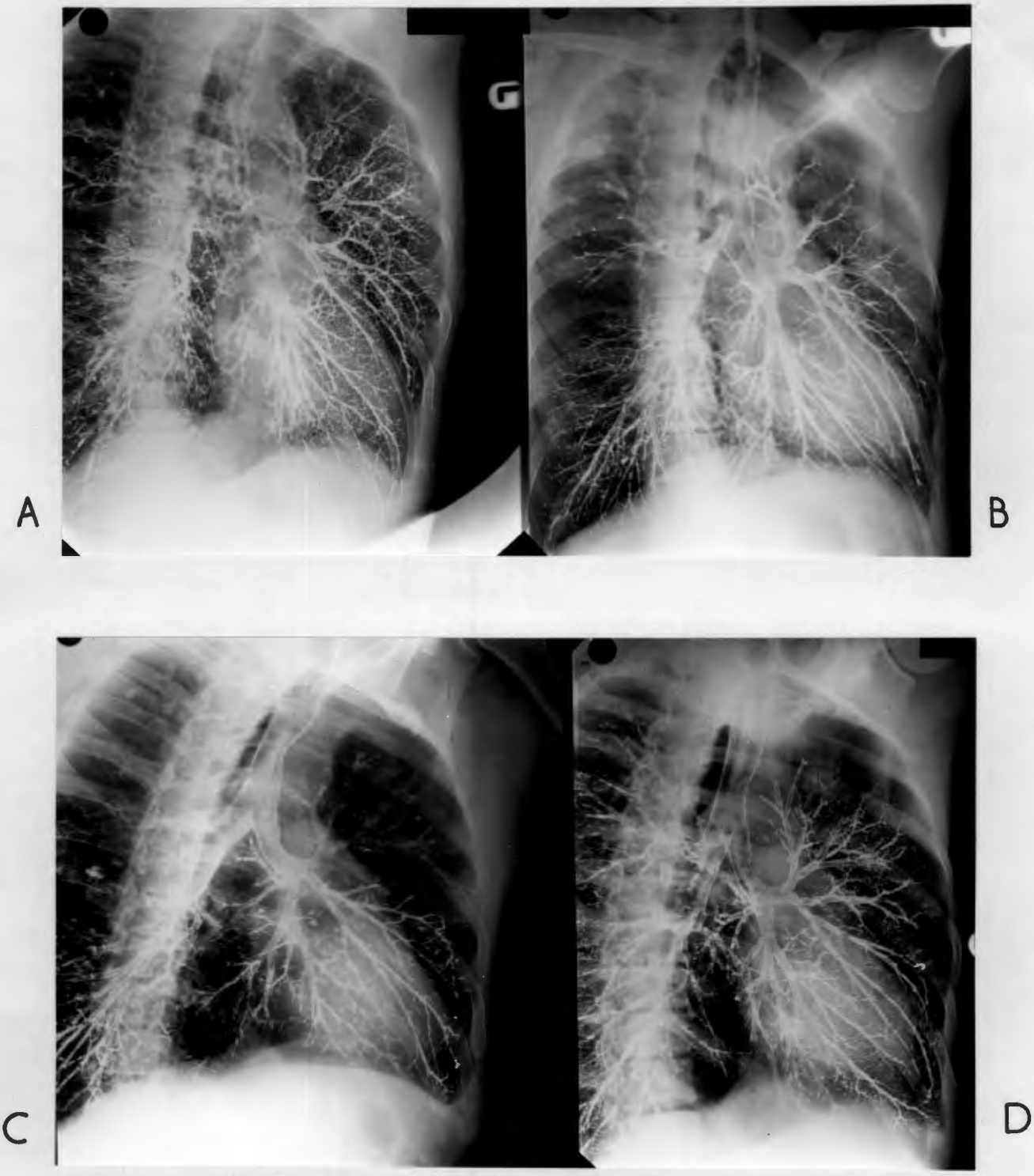

Fig. 17

These four examples of left oblique bronchograms serve to illustrate the essential similarity and the minor differences and variations in the bifurcating arrangement of left upper bronchi. Observe particularly the differences in size and shape of the "pectoral" division of the "lingulo-pectoral" stem, and the variable shape of the "cleft stick" of the lingular bronchus.

A B

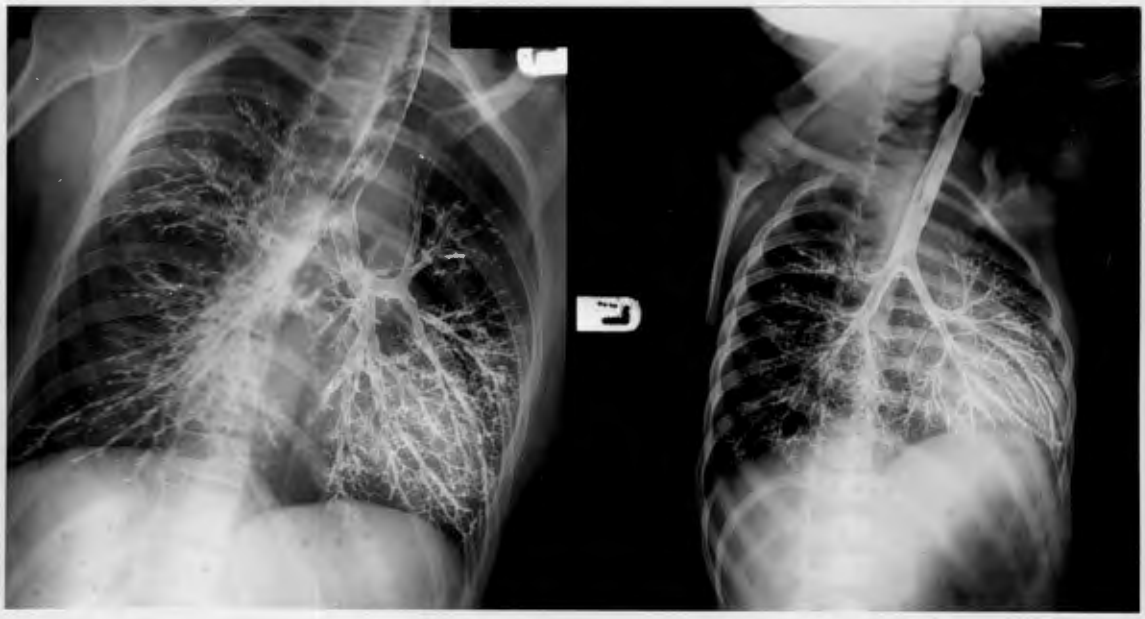

C D

Fig. 18

Examples of bifurcating left upper bronchi in four different subjects. The views (A), (C) & (D) are obliques - (B) is an antero-posterior view. The "cleft stick" of the lingular bronchus is particularly clear in (A), and extends into the left costo-phrenic angle.

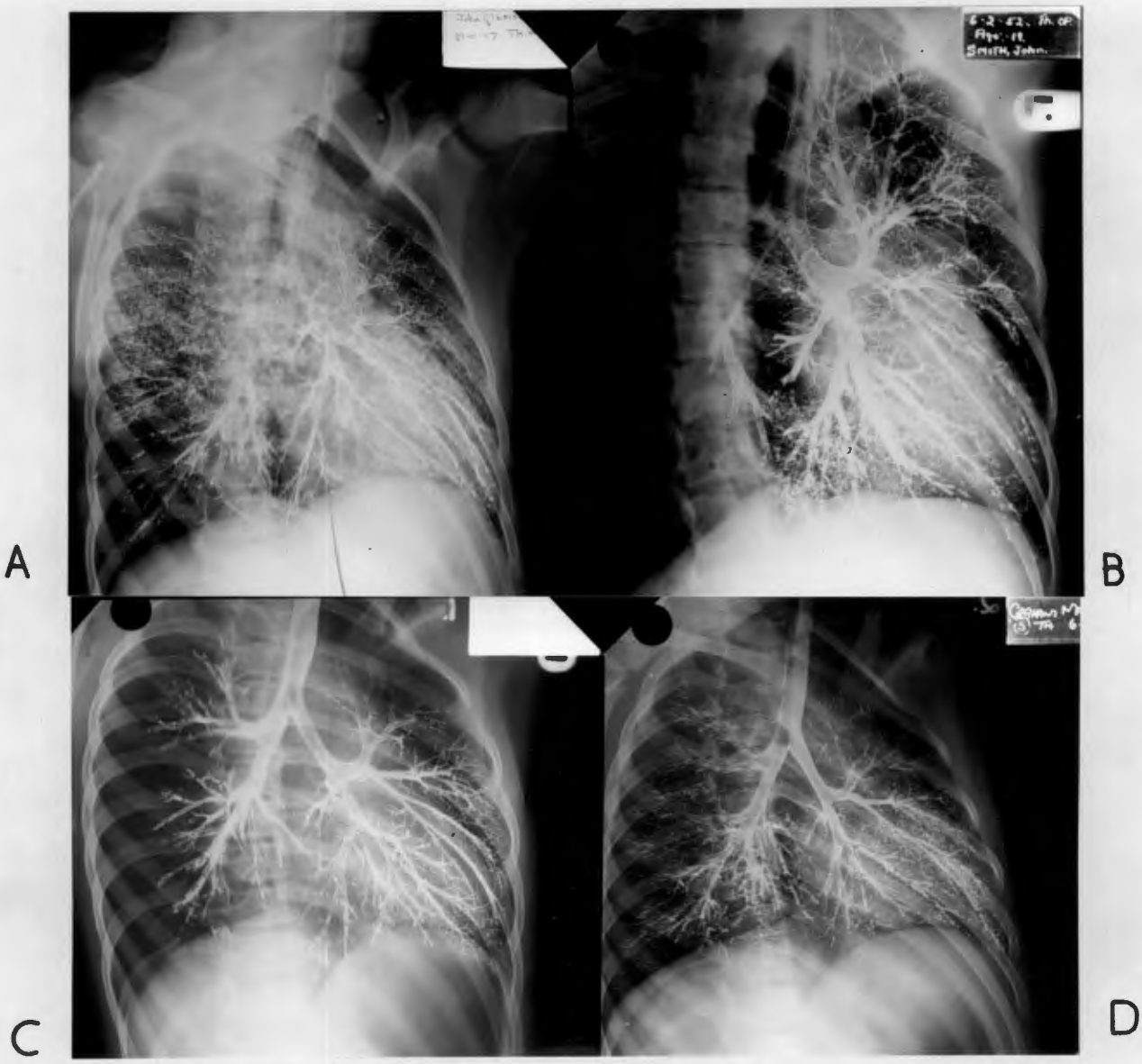

Fig. 19

In these examples of bifurcating left upper bronchi variations in the appearance of lingular bronchi the essential anatomy of which is similar, are apparent. In (B) the apical segment of the lower lobe is unusually large.

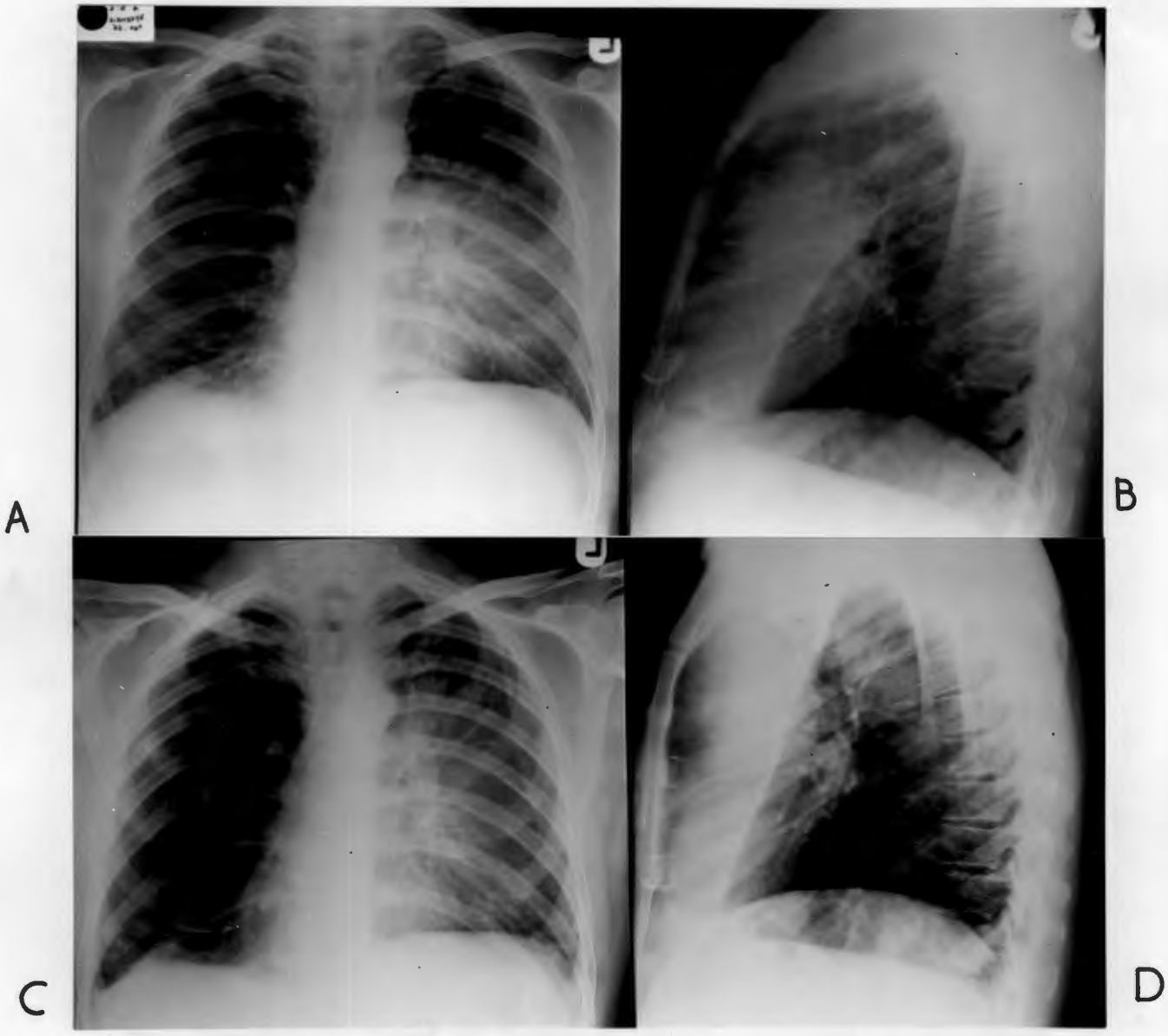

Fig. 20

The PA and left lateral radiographs (A) & (B) show a pulmonary opacity confined to the lower half of the left upper lobe. A carcinoma was seen at bronchoscopy to obstruct the lower division of a bifurcating left upper bronchus. The PA and left lateral films (C) & (D) are of the same patient and were made a fortnight later. The left upper lobe is now shrunken and opaque. At bronchoscopy the upper division of the left upper bronchus was filled with mucus. Having previously declined thoracotomy the patient was now submitted to left pneumonectomy and the anatomy of the left upper bronchi in the resected specimen was similar to that illustrated earlier as typical of a bifurcating arrangement of left upper bronchi. The division of the left upper lobe into two is clear from a comparison of the lateral films (B) & (D).

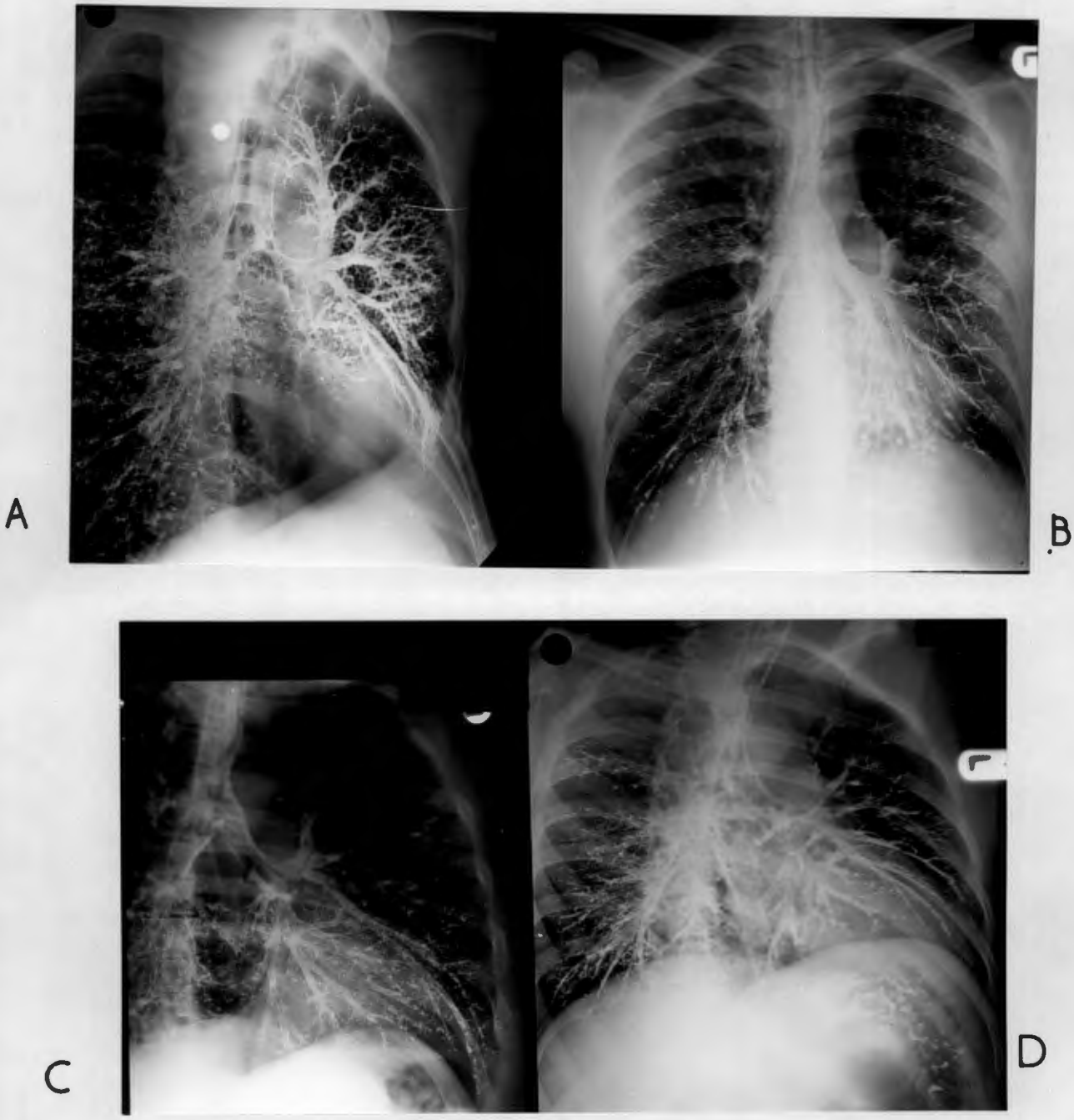

Fig. 21

Left oblique bronchograms from four different patients which illustrate minor variations in the trifurcating arrangement of left upper bronchi. In (A) & (B) the three divisions of the left upper lobe are splayed because of shrinkage of a bronchiectatic left lower lobe

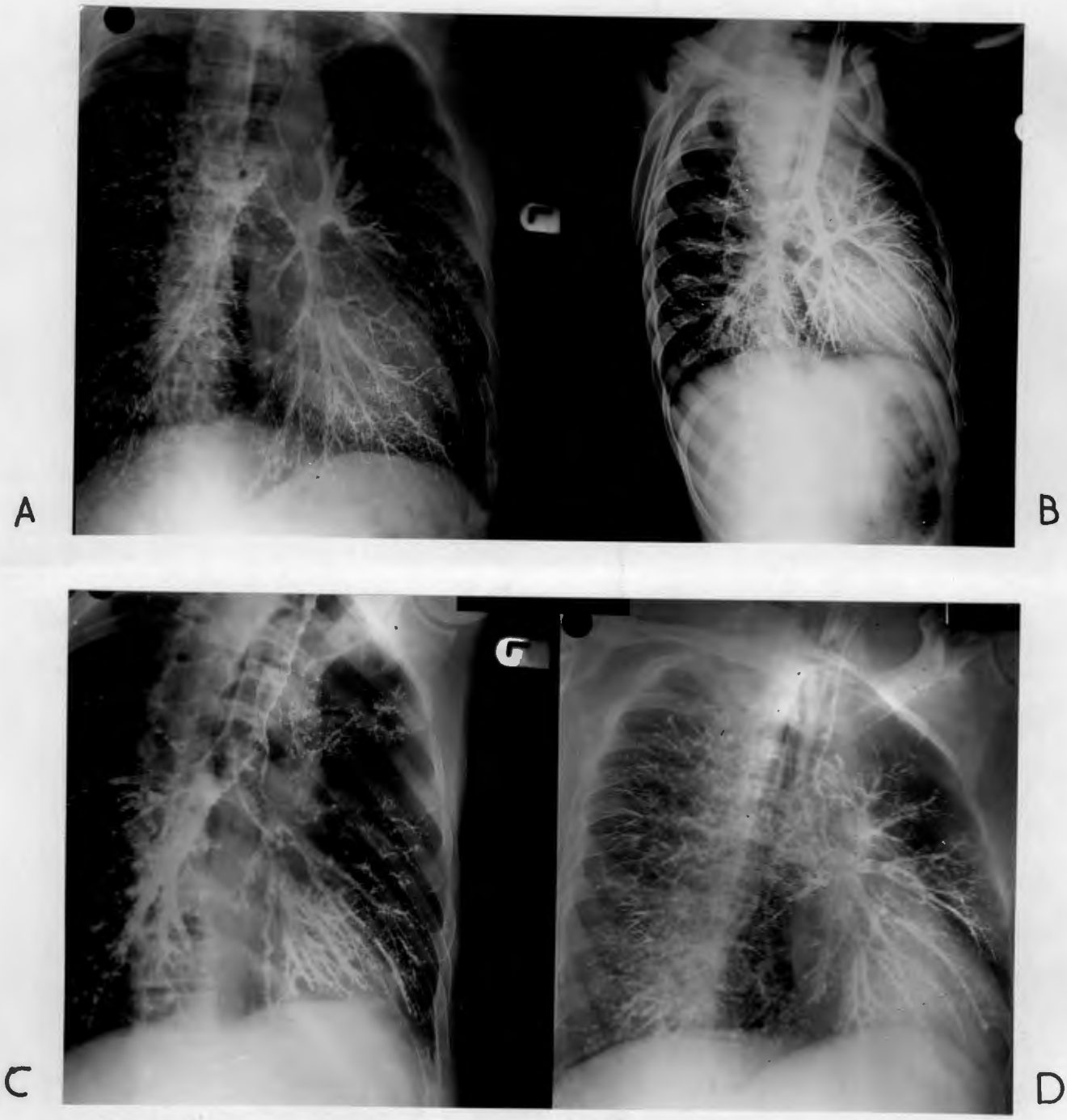

Fig. 22

Further variations in the trifurcating arrangement of bronchi in the left upper lobe in four left oblique bronchograms from four different patients are shown. In (A) the highest division divides again so quickly that the left upper bronchus appears almost to divide into four. In (D) the left upper bronchus, before its division into three, is unusually short. The basal bronchi in (A) & (C) arise as a trifurcation - in (B) & (D) as a series of bifurcations.

A B

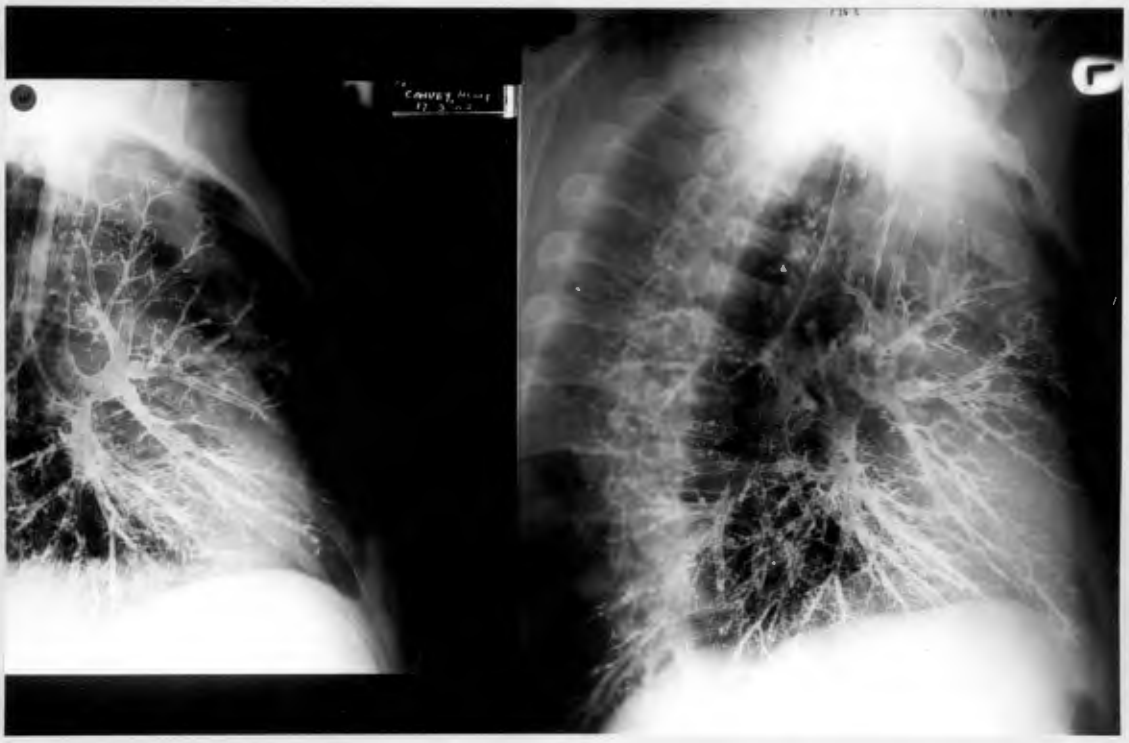

C D

Fig. 23

In these four examples of trifurcating left upper bronchi the middle division in (A) appears to favour a little in its origin the lowest division and in (B) and (C) the highest division. In (D) the trifurcation is precise. The basal bronchi in (B) arise as a series of bifurcations.

A B

C

Fig. 24

In the arrangement of left upper bronchi illustrated by these bronchograms from three different subjects there is a large anteriorly directed bronchus arising from the upper division of a bifurcating left upper bronchus - an upper division much larger than the lower division. It is only in this arrangement of left upper bronchi that internationally accepted nomenclature appears applicable.

A B

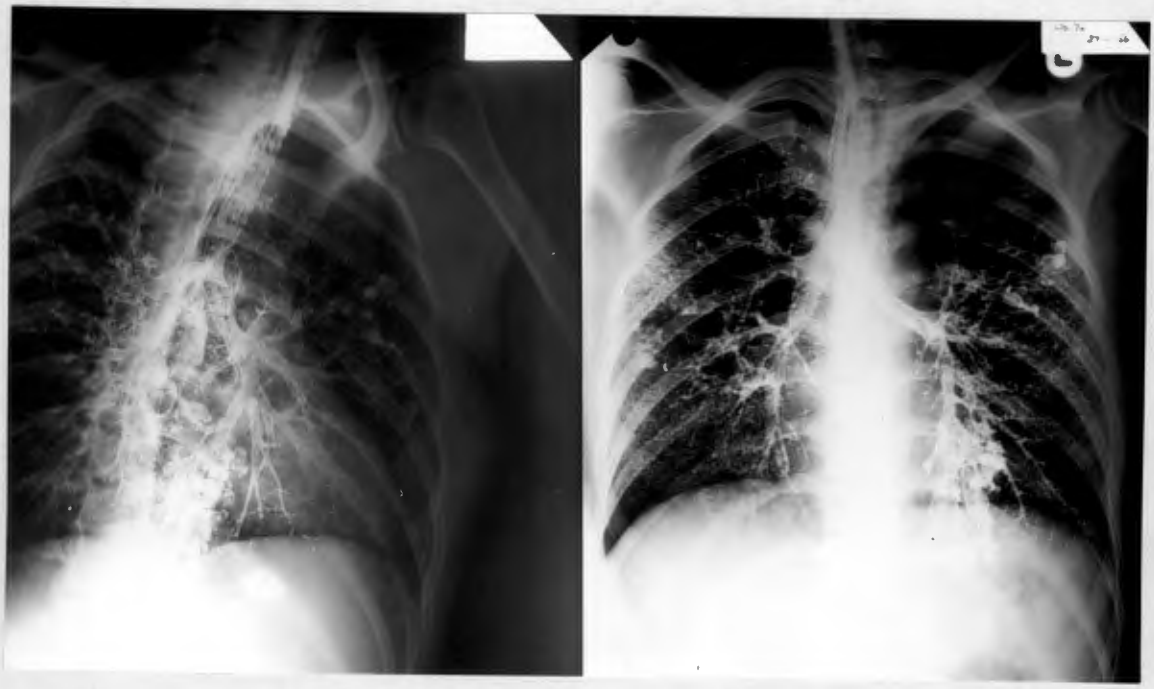

C D

Fig. 25

Brenchiectasis of the right anterior segment (A & B), of the left anterior segment of international nomenclature and of the left posterior basal segment (C & D) serves to identify these bronchi in the four radiographs illustrated above.

The Anatomical Limits of Pulmonary Resection

Provided that the equivalent of one lung is normal it is possible to resect pat or all of the equivalent of the other and yet leave a patient with a respiratory reserve adequate for normal activity. With regard to unilateral resection of less than the whole of one lung, it is unwise to leave so few segments that these do not fill completely the pleural space when all the mechanisms which compensate for reduction in lung volume are fully exercised - mediastinal shift, ascent of the dome of the diaphragm, compensatory emphysema and shrinkage of the rib cage preferably without thoracoplasty; the "thoracoplastic" effect of phrenic crush may justifiably be employed . A pleural space incompletely occupied by lung invites infection and lung suspended in and incompletely filling a pleural space functions ineffectively. With pulmonary resection short of pneumonectomy it is, therefore, usually wise to leave at least an upper or a lower lobe on the right; the middle lobe is small and will only occasionally fill the hemithorax; the right basal segments alone may adequately fill the hemithorax and in occasional circumstances the right upper lobe can be deprived of a shrunken anterior segment and yet fill the hemithorax after middle and lower lobectomy. The success of extensive unilateral pulmonary resection short of pneumonectomy is determined largely by the state of the resected lobes and segments; if these have long been shrunken and airless they occupy little of the hemithorax and their resection strains minimally the lung which remains (Fig. 26 and 27); moreover, if these lobes and segments have been shrunken and airless since infancy the remaining lung is larger probably not only because of compensatory emphysema but also because of /

of growth. On the left the extent of partial resection of the upper lobe permissible with lower lobectomy is determined largely by the distribution of bronchi within the lobe. Failure to distinguish between left upper bronchi which bifurcate and those which trifurcate makes it impossible from the literature on bronchiectasis to interpret the extent of pulmonary resection designated "linguleotomy". In the common bifurcating arrangement of left upper bronchi linguleotomy should imply resection of half the upper lobe but in many instances probably implies resection of only the lower half of the lingular segment. The apical and posterior segments of a left upper lobe the bronchi to which are arranged dichotomously may be strained to the limit in filling the left hemithorax after lower lobectomy and resection of the lower half of the upper lobe (Figs. 28 and 33) and strained very much less when "linguleotomy" implies resection of the lowest third of a trifurcating left upper bronchus or the lower half of the lingular segment of international nomenclature, sparing the "pectoral" or upper lingular segment. As on the right, so on the left the success of extensive pulmonary resection short of pneumonectomy is determined largely by the state of the resected lung, and the more completely this is shrunken and the earlier in the patient's life shrinkage occurred, the more complete will compensation be for shrinkage at the time of thoracotomy and the less likely is it that complications will follow resection. After extensive or total left pulmonary resection the mediastinum quickly deviates to the left and the heart comes to occupy much of the left hemithorax; this fact alone makes it possible to leave successfully only half the left upper lobe in many patients. After left pneumonectomy, in young people particularly/

particularly and more commonly than after right pneumonectomy, the contralateral lung frequently herniates anteriorly across the mediastinum and it may be difficult to believe from radiographs that pneumonectomy has in fact been undertaken (Figs. 29-31).

The permissible extent of bilateral resection is determined entirely by the state of the resected lung. The most extensive bilateral resection likely to be contemplated is of the middle and lower lobes on the right and the lower lobe and the lingular segment of the upper lobe on the left. Bilateral resection of this extent is successful only when the lobes and segment removed are shrunken and airless and the space in each hemithorax provided by their shrinkage long and fully occupied by normal lung now of large volume and no longer under stress. Bilateral resections of lesser extent - which involve, for example, less than two lobes on the right and one or less than one on the left - put less strain on the remaining pulmonary tissue, but are again most successful when the resected lung is long shrunken and airless.

While it is technically possible to resect together many segments scattered through all five lobes, surgical management for bronchiectasis of this distribution is not now undertaken because of the high incidence of technical failure and because the bronchi of segments not resected in patients with bronchiectasis of such widely scattered distribution are rarely completely normal.

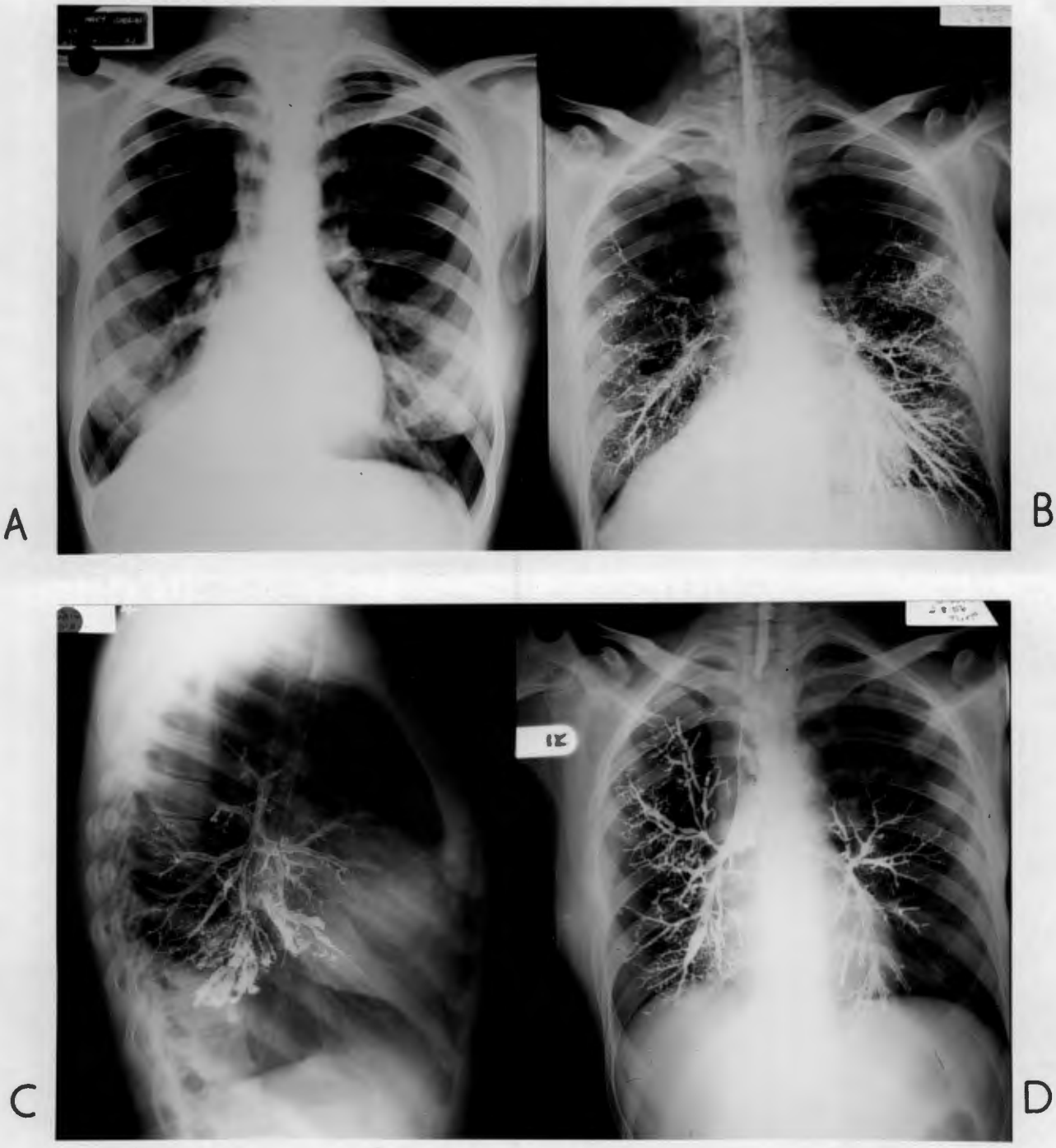

Fig. 26

The post-operative bronchogram (D) shows how completely the upper lobe can fill the right hemithorax after middle and lower lobectomy and how little the disposition of the right upper bronchi is altered when a resection of this extent is made for a patient in whom the middle and lower lobes have long been shrunken and airless (A,B & C).

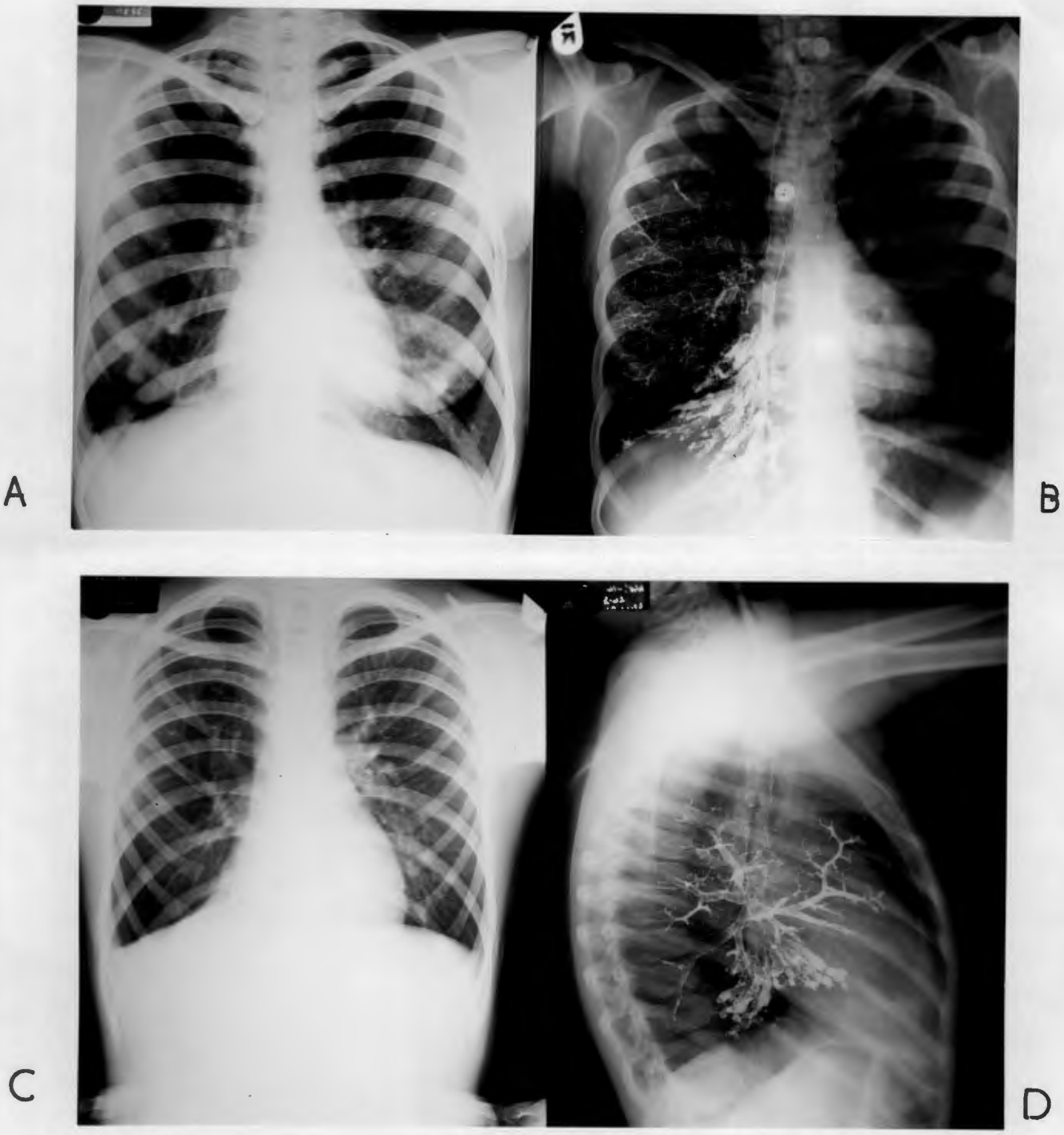

Fig. 27

The AP bronchogram (B) and the lateral bronchogram (D) correspond with the PA radiographs (A) and (C) respectively and are of two different patients. In both the middle and lower lobes are shrunken and their bronchi grossly bronchiectatic. Compensatory enlargement of the upper lobe in each patient is clear, as is the small size of the shrunken lobes, and their position, tucked against the mediastinum with their bronchi vertically dependent.

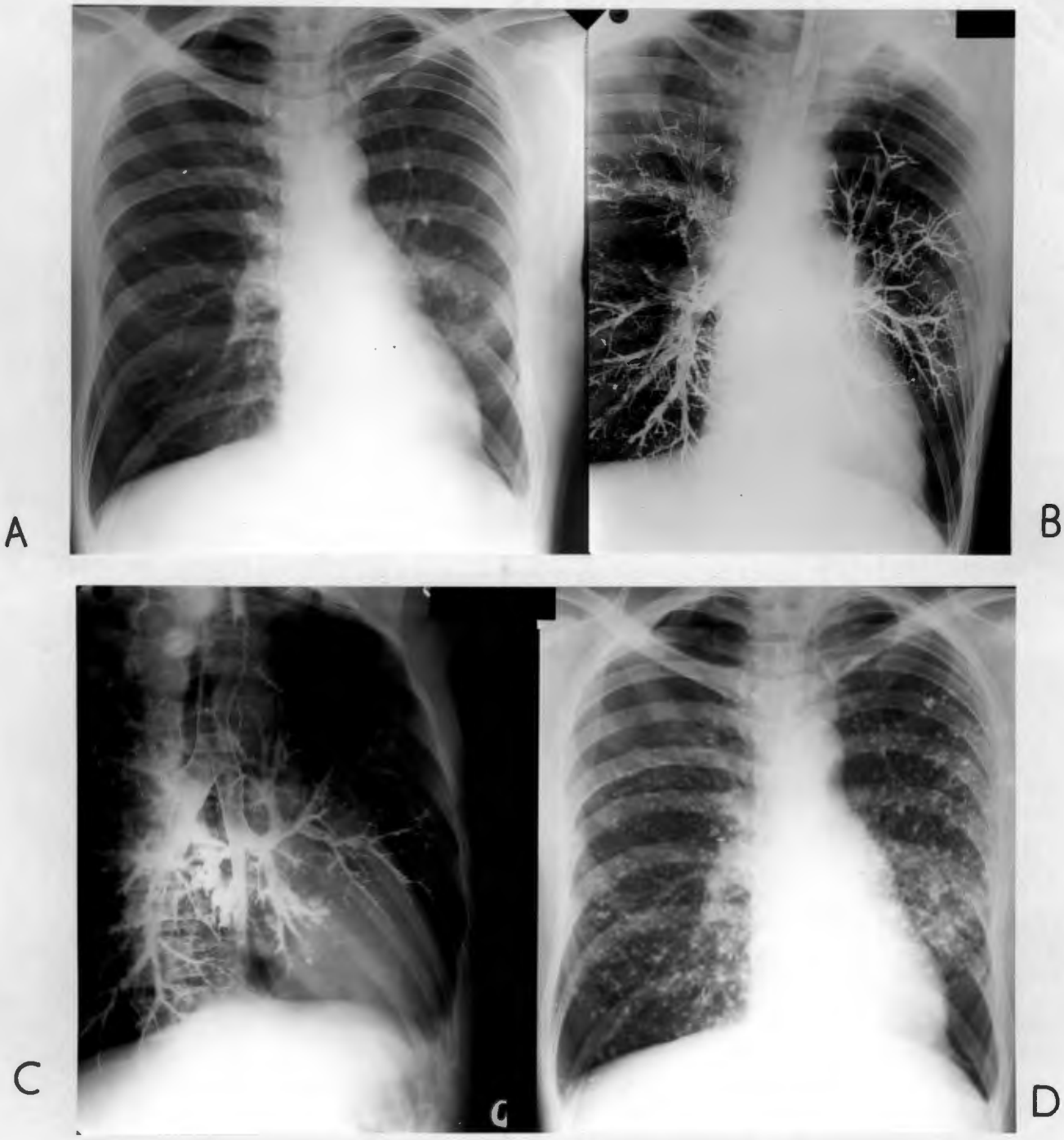

Fig. 28

The left lower lobe and the lower half of the left upper lobe - the whole of the lingular segment of international nomenclature - are shrunken and bronchiectatic (B & C). The only aerated lung in the left hemithorax is the upper half of the left upper lobe, the bronchi of which are widely spaced. The benefit of space occupation induced by temporary interruption of the left phrenic nerve after lower lobectomy and lingulectomy in such a patient probably outweighs the disadvantage of paradoxical movement of the left dome. Lipiodol residue six months after bronchography is clear in (D). In the PA radiograph (A) the shrunken lower lobe and lingular segment lie against the vertebrae behind the cardiac shadow.

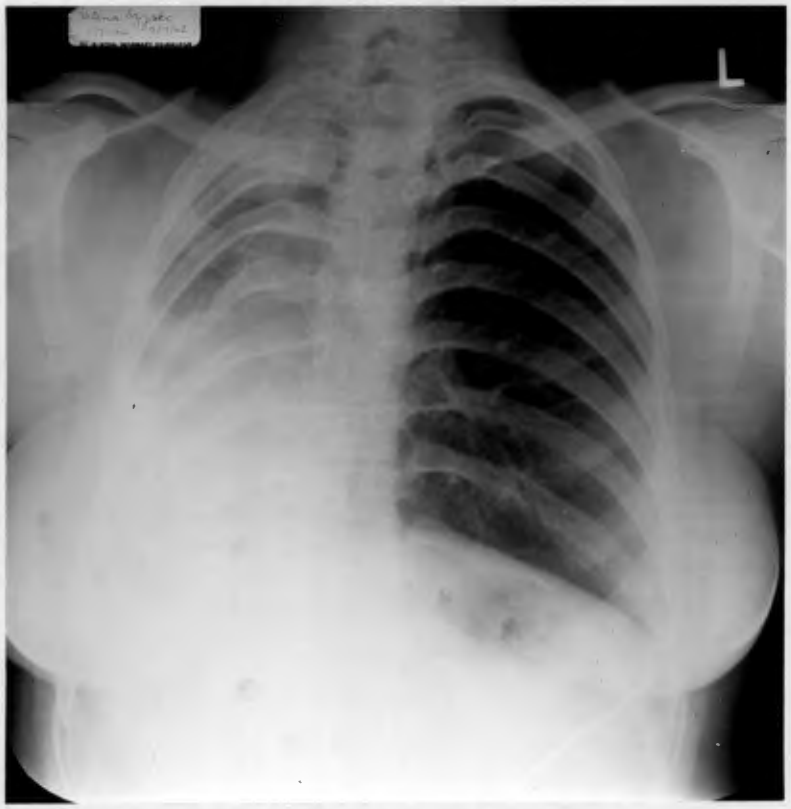

Fig. 29

Herniation of the left lung into the right hemithorax after right pneumonectomy is shown in (C). Pneumonectomy was undertaken for total right bronchiectasis, demonstrated in the pre-operative bronchograms (A) & (B).

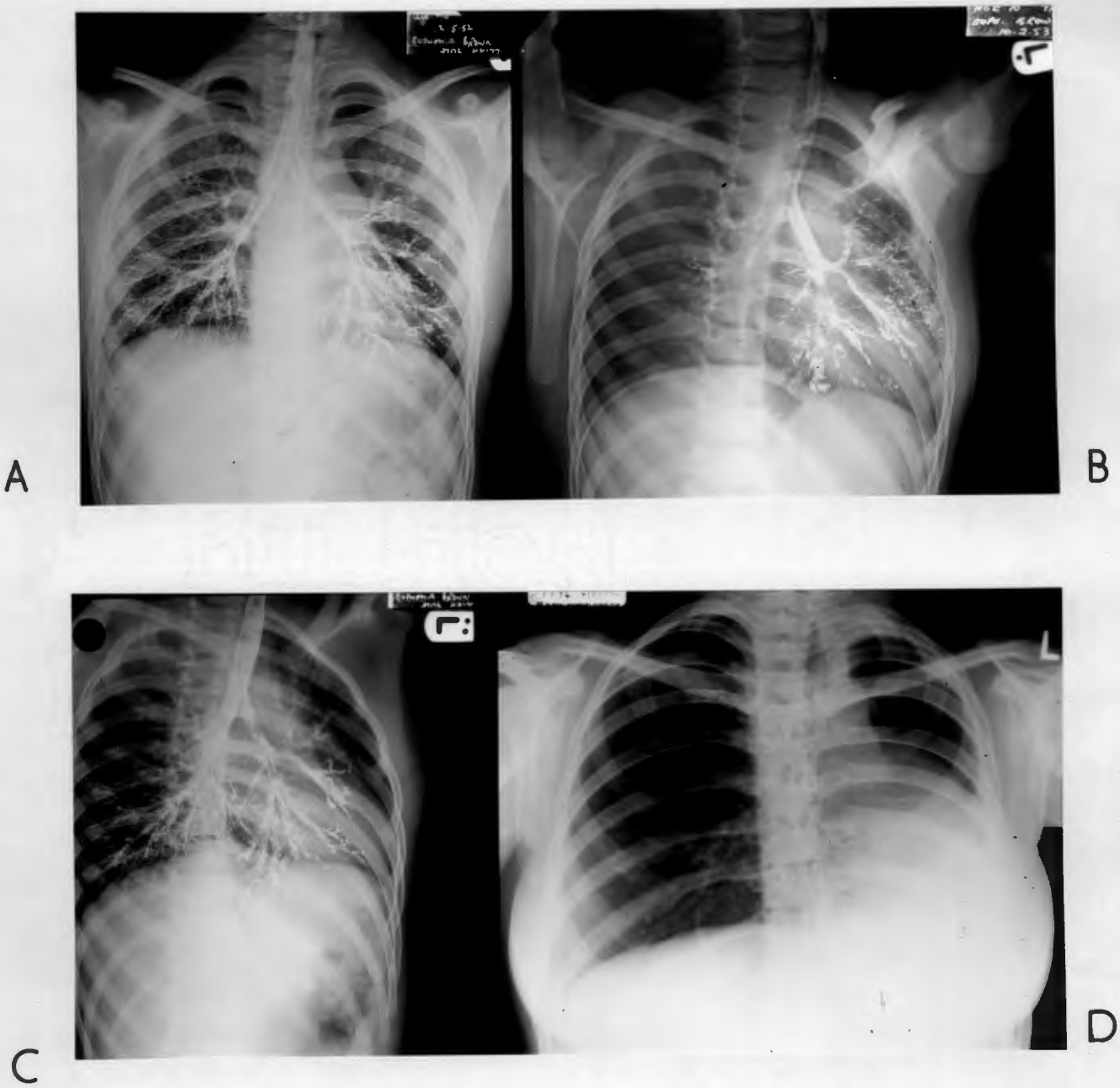

Fig. 30

Herniation of the right lung into the left hemithorax after left pneumonectomy is well shown in (D). Pneumonectomy for total left bronchiectasis in the patient whose films these are may have been inappropriate because she now has occasional episodes of bronchitis, but she was relieved of severe respiratory symptoms by the resection and has married, has a family, and her pulmonary arterial pressure is normal at rest and only very slightly elevated on exercise ten years after pneumonectomy.

A B

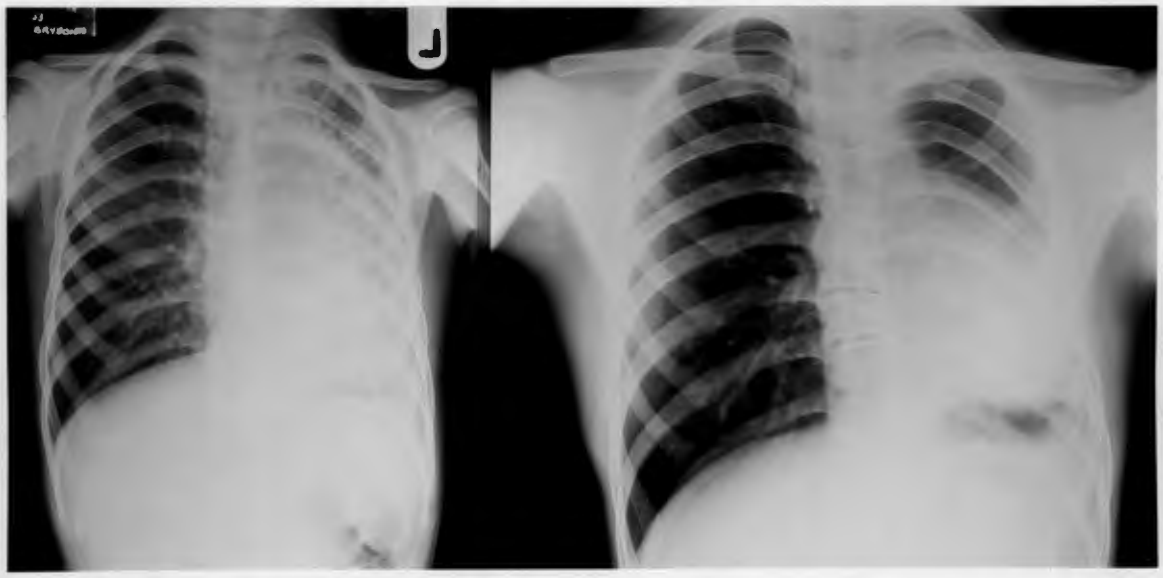

C D

Fig. 31

The pre-operative PA chest radiograph (C) is little different from that made seven years after left pneumonectomy (D). The resection was made for total left bronchiectasis (A & B), and herniation of the right lung anteriorly across the mediastinum into the left hemithorax accounts for the left-sided translucency. In this patient, as in many other in whom left pneumonectomy has been undertaken, the apex beat is palpable high in the left mid-axillary line.

The Distribution of Bronchiectasis in 1038 Patients

From a scrutiny of the bronchograms made in 1038 cases of bronchiectasis, details relevant to which are discussed in Chapters IV and V, the following facts emerge :

The left lung was involved, in whole or in part, more often than the right lung in the ratio 9 : 7.

The left lower lobe, alone or in conjunction with other segments, was the area of lung most frequently affected - in 287 patients. This figure does not include those patients in whom the whole of the left lung was bronchiectatic.

The areas of lung next most commonly involved, alone or in conjunction with other segments but exclusive of total unilateral bronchiectasis, were the middle lobe (280 patients) and the lingular segment of the left upper lobe (260 patients).

Total left bronchiectasis (in 180 patients) was fourth in order of frequency, and compares with total right bronchiectasis in 145 patients.

Right lower lobe bronchiectasis, alone or in conjunction with other segments but exclusive of total unilateral bronchiectasis, occurred as often as did total right bronchiectasis (in 146 patients) and only half as often as left lower lobe bronchiectasis.

Left basal segmental bronchiectasis without involvement of the apical segment of the lower lobe was found in 120 patients, exactly twice as often as was right basal segmental bronchiectasis without involvement of the right apical lower segment - a distribution precisely comparable with that of lower lobar bronchiectasis on the two sides.

The whole of the right upper lobe, alone or in conjunction with other segments but exclusive of total right bronchiectasis, was bronchiectatic in 70 patients, three and a half times as often as was the left upper lobe (20 patients).

Bronchiectasis of the apical segment of a lower lobe, alone or in conjunction with bronchiectasis in other segments outwith the lower lobe, was of approximately equal incidence on the two sides - in 15 patients on the right side and in 14 on the left.

The medial basal segment on the right was the only bronchiectatic part of the lower lobe in 21 patients.

The /

The anterior segment of the right upper lobe was the only bronchiectatic part of this lobe in 29 patients; anterior segmental bronchiectasis on the left was recognised in only 4 patients in all of whom the left upper bronchus existed as a trifurcation and it was the middle of the three divisions which was bronchiectatic.

Lingular bronchiectasis was recognised in 260 patients; in 217 of these the left upper bronchus divided into two nearly equal parts; the lower of these halves was totally bronchiectatic in 163 patients and in the remaining 54 only the lower division of the lower half of a bifurcating left upper bronchus was bronchiectatic - i.e. using international nomenclature the lingular segment was bronchiectatic in 163 patients and half the lingular segment in 54 patients; alternatively 54 patients were shown to have lingular bronchiectasis and 163 lingule-pectoral bronchiectasis. In 43 patients the left upper bronchus divided into three equal or nearly equal parts or the upper division of a bifurcating left upper bronchus was unusually large; in these patients the lower division of a trifurcating left upper bronchus or the lower, small division of a bifurcating left upper bronchus was totally bronchiectatic.

From a scrutiny of the illustrations of normal bronchial anatomy it is arguable that, from their position, length and relatively narrow calibre many of those bronchi most commonly the site of bronchiectasis are more vulnerable to obstruction, whether by external compression or other means. That foreign material is more likely to fall or be aspirated into some bronchi than into others is unequivocal, as is the fact that the position assumed by lobar bronchi with shrinkage of subtended lung makes more difficult the evacuation of bronchial contents from some bronchi than from others. Thus the middle bronchus is long and slender and surrounded at its origin by glands. The left main bronchus, only two-thirds of the diameter of the right, is long and crosses the mediastinum at a somewhat abrupt angle behind the aorta against which it is easily compressed by sub-carinal glandular enlargement. The medial basal bronchus on the right has a semilunar orifice; this, at bronchoscopy, is often visible from the trachea and is an inviting repository for foreign material which in any event falls /

falls more often into the right stem bronchus than into the left. In sleep in one or other lateral position the right upper or lingular bronchi are most dependent, and in the supine position the apical bronchus of either lower lobe. The right stem bronchus narrows somewhat abruptly after the origin of the right upper bronchus and the intermediate bronchus is consequently a common site of lodgement of foreign bodies - teeth, peas, peanuts and articles of similar size especially. When the bronchi which subtend the middle and lower lobes on the right and the lower lobe and lingular segment of the upper lobe on the left become obstructed and the subtended lung shrinks, this does so in a caudal direction; the subserving bronchi, from being of a dependent inclination become directed almost vertically downwards (Figs. 26 and 27) and, in the erect posture, are able to empty themselves only by ciliary action. Furthermore, a shrunken left lower lobe deviates medially against the pericardium and its bronchus not only becomes more dependent but may even appear to kink at its origin from the infero-laterally directed curve of the left stem bronchus. The right upper lobe and the upper half of the left upper lobe, served by the upper division of a bifurcating left upper bronchus, when their related bronchi are obstructed, shrink in a rostral direction; their bronchi are thus directed medially and caudally and drain dependently in the erect position. Left bronchiectasis should therefore be more common than right; middle and lower lobar bronchiectasis should therefore be more common than upper lobar bronchiectasis; the linglar segment behaves as a companion not of its parent lobe but of the left lower lobe. It is recognised that much of the reasoning which relates anatomical vulnerability of bronchi with the distribution of bronchiectasis is based on a post hoc ergo propter hoc argument similar to that offered as the explanation for many morbid anatomical facts and therefore possibly fallacious.

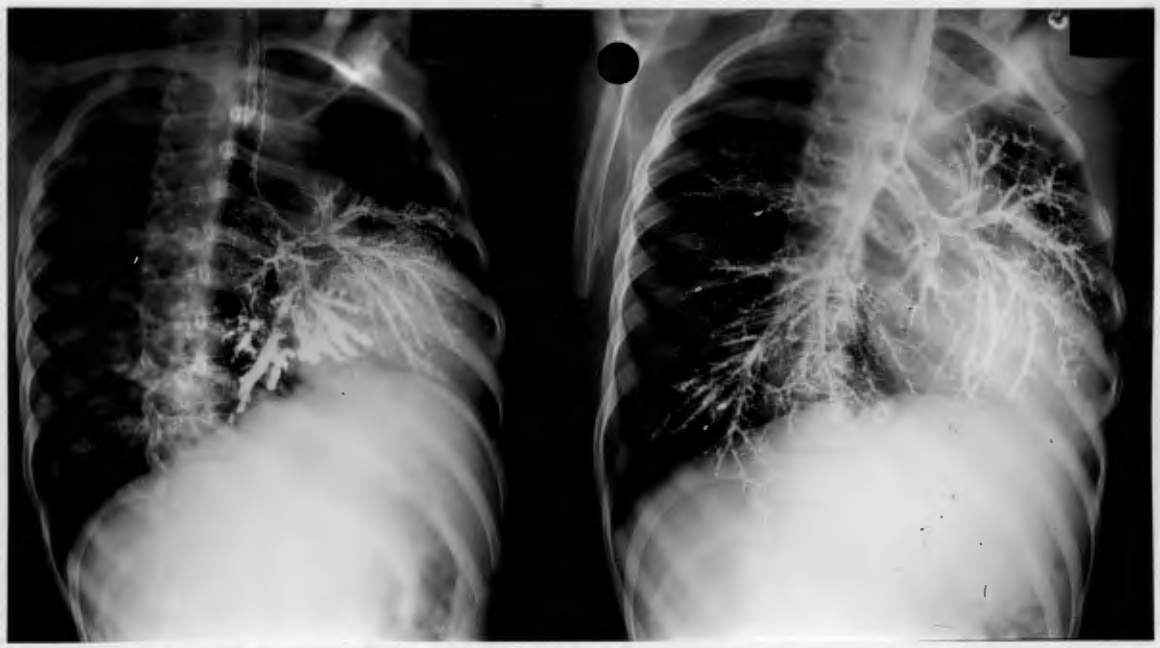

A B

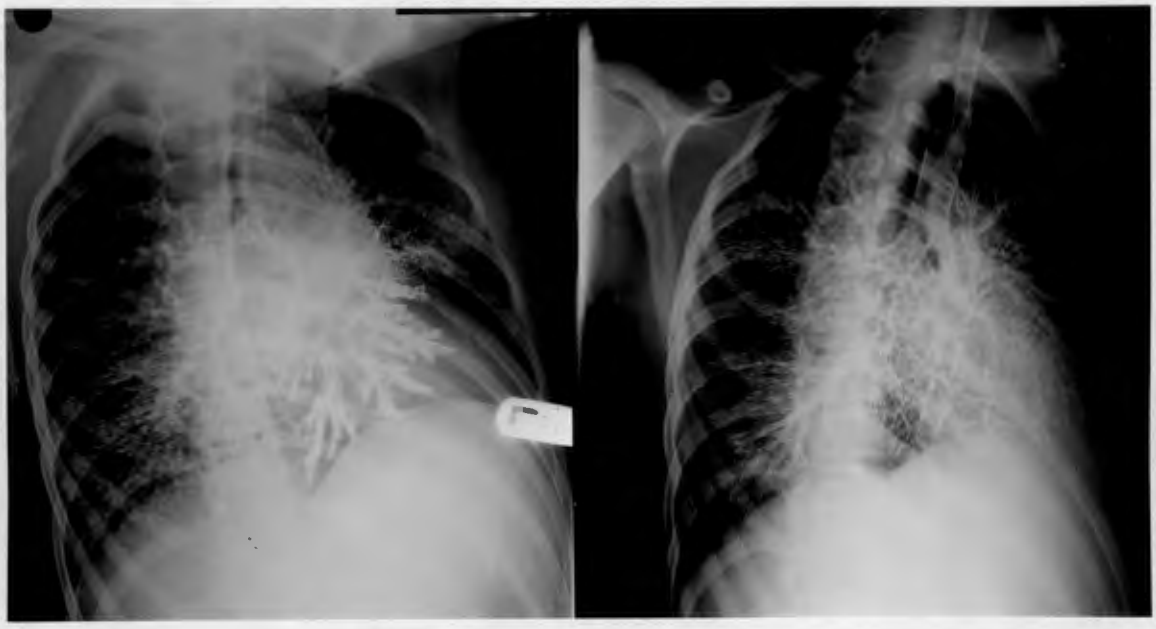

C D

Fig. 32

Following resection of the bronchiectatic left basal segments shown in (A) the trifurcating arrangement of left upper bronchi in the same patient are more clearly demonstrable in the post-operative bronchogram (B), together with the appearance of the apical segment of the left lower lobe, here preserved. In (C) left basal bronchiectasis is associated with bronchiectasis of the lowest division of a trifurcating left upper bronchus. The bronchogram made after left basal segmental resection and "lingulectomy" in this patient are shown in (D).

A B

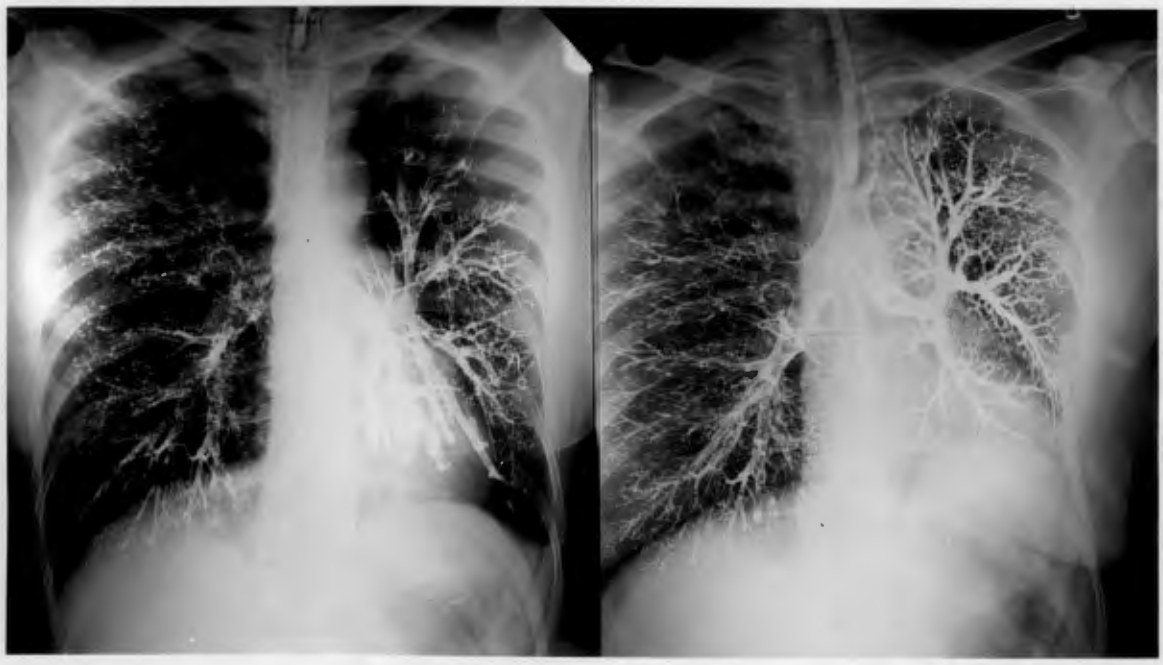

C D

Fig. 33

Bronchiectasis of the left lower lobe in association with bronchiectasis of the lower half of the left upper lobe (A) in which the bronchi are arranged dichotomously, is here compared with bronchiectasis of the left lower lobe in association with bronchiectasis of only the lower division of the lower half of the left upper lobe (C), where the arrangement of bronchi is similarly dichotomous. In each instance post-operative bronchograms (B & D) are illustrated. It is common to label the bronchiectasis in each of these two patients as involving the left lower lobe and the lingular segment

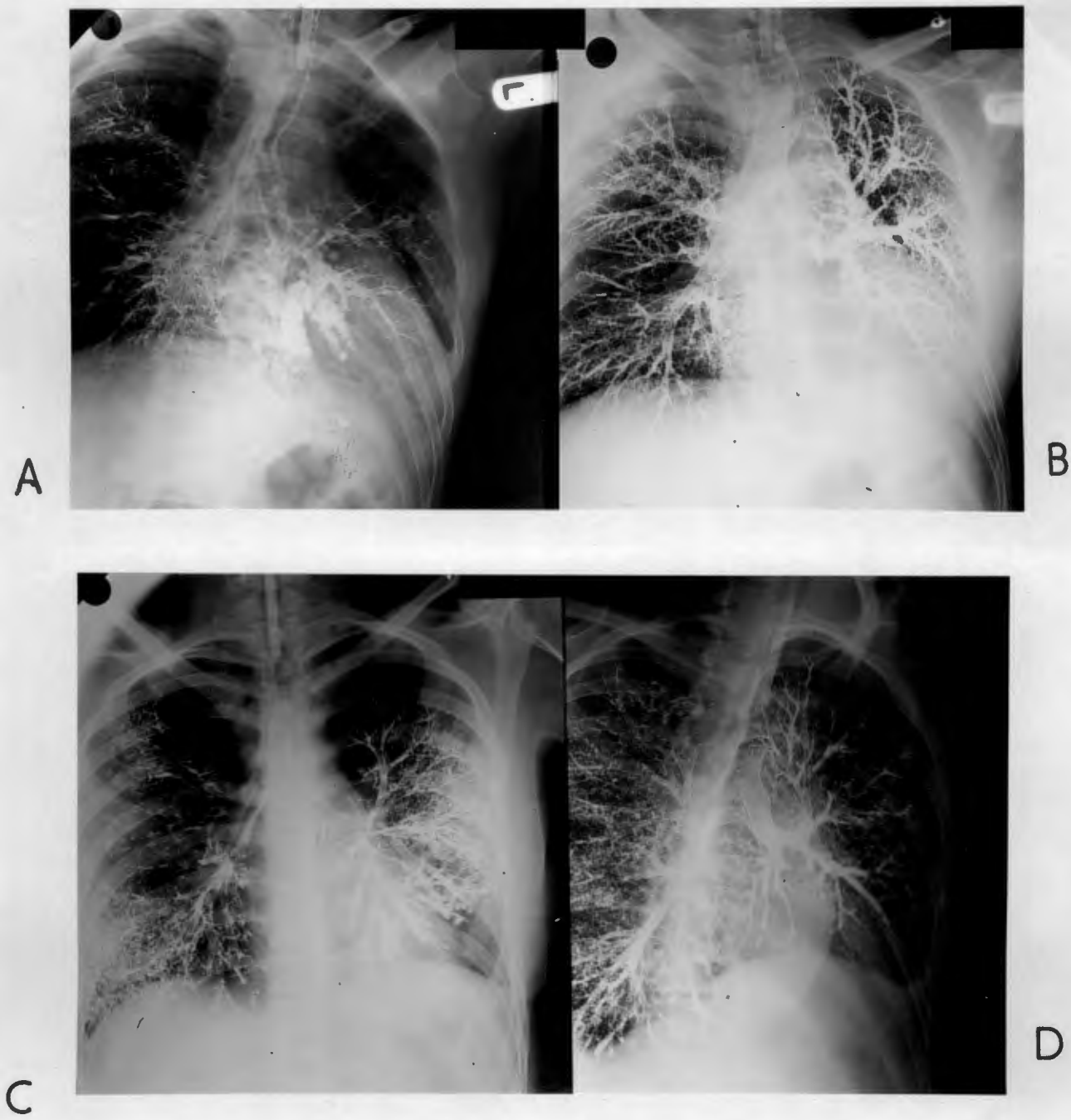

Fig. 34

Bronchiectasis of the left lower lobe is associated with bronchiectasis of the lower division of the lingular segment of a left upper lobe in which the arrangement of bronchi is dichotomous in the oblique view (A). Compare this with bronchiectasis of the basal segments of the left lower lobe in association with bronchiectasis of similar distribution in a left upper lobe of similar anatomical type in (C). In each instance management was by resection and related post-operative films are shown as (B) and (D).

CHAPTER XII

BRONCHOGRAPHY

Bronchographic Contrast Media:

Contrast media which outline tube systems are well established radiodiagnostic adjuncts. Techniques and media may be changed both to increase the margin of safety for the patient and to improve radiographic contrast. In the radiographic demonstration of the bronchi, early techniques, such as the insufflation of barium powder through a bronchoscope (Jackson, 1918) and the instillation of oily suspensions of bismuth, were quickly discarded as dangerous. Iodised poppy-seed oil (Lipiodol) was the first practical bronchographic agent (Sicard and Forestier, 1922) and was the only medium in general use for many years. The main disadvantage of Lipiodol was its long retention in pulmonary parenchyma in a radio-opaque form, especially when alveolar spill had occured, so that the interpretation of serial radiographs used to demonstrate the progress of a pulmonary lesion was complicated. A granulomatous reaction to the oil was also an occasional occurrence.

Dormer (1947) used Lipiodol as a vehicle for the introduction of sulphanilamide powder into the bronchi as a topical therapeutic agent in the control of bronchial infection. The sulphanilamide increased the viscosity of the iodised oil, and it was soon recognised that by its addition alveolar spill was diminished, contrast was greater because the oil was less widely dispersed, and more complete post-bronchographic evacuation of the contrast medium was achieved by coughing, so that subsequent radiographs commencorated less frequently and greasly previous bronchographic attempts. The combination of eight grammes of sulphanilamide powder with 20 ml. of Lipiodol was used for bronchography in the/

the Thoracic Surgical Unit in Edinburgh between 1950 and 1955. Some 800 bronchograms were made. Two patients experienced such severe dyspnoea as a consequence of bronchial obstruction by the viscous material that they very nearly suffocated, and in a third patient the subsequent development of acute nephritis was related to bronchography. Other complications were not encountered, and 75% of the bronchograms produced were then regarded as satisfactory. In a more critical retrospective evaluation of these bronchograms five years later, it was thought that there was justification for dissatisfaction in 45% rather than 25% of the bronchograms. Improvement in bronchographic technique had made unacceptable that which in the past had been regarded as adequate. With more general use of the combination of sulphanilamide with Lipiodol, marketed as Visciodol (Burrascane,1955: Johnson and Irwin,1959), the hazards of sensitivity to sulphanilamide, and of the formation of methaemoglobin, and of widespread bronchial obstruction by a too viscid preparation became apparent.

In the attempt to obviate these disadvantages, water-soluble media were prepared. The first of these was diodone, combined with a thickening agent such as carboxymethylcellulose or polyvinyl pyrrolidone. This contrast medium proved clinically unacceptable because it was excessively irritating to the bronchi. In 1953 a new compound propyliodone, was described. It was originally introduced in an aqueous suspension (Dionosil Aqueous) for which the advantages of rapid disappearance from the lungs and relative freedom from the risks of iodism were claimed. Its use was, however, often followed by a febrile reaction in the patient and, although isotonic with body fluids, it also proved irritating to the bronchial mucosa. The hazards of local anaesthetic side-effects were enhanced because of the need to suppress more effectively the cough reflex with larger doses of topical anaesthetic. Propyliodone in arachis oil (Dionosil Oily) was then/

then introduced as an alternative to the aqueous suspension, and this was shown to be less irritating and, on serial radiographs, was rarely retained in the bronchi or alveoli for longer than 48 hours. In Edinburgh after 1956 the oily suspension of propyliodone was adopted almost routinely as a bronchographic medium. While radiographic contrast was often less effective than with sulphanilamide powder in iodised poppy-seed oil, reactions were not observed, and the standard of bronchograph was regarded as adequate. When bronchography was followed by pulmonary resection granulomatous reaction to the oily vehicle was not observed.

At the end of 1962 a series of bronchograms were made to assess the value of Hytrast as a bronchographic medium (le Roux and Duncan, 1964). Hytrast is an opaque white suspension with a pH of about 7, obtained by the dispersion of a mixture of fine crystals (2 - 5 microns) of N(propyl-2:3-diol)-3:5 diiodo-4-pyridone and 3:5-diiodo-4-pyridone in a slightly hypotonic aqueous solution of sodium carboxymethylcellulose. These compounds differ from propyliodone and diodone in that they are not esters and do not have labile functional groupings. Esters hydrolise in the bronchi and produce acidic ions which are thought to be responsible for the local irritant properties of diodone and propyliodone. The iodine concentration in Hytrast (0.5 g./ml.) is greater than in propyliodone (0.28 g./ml.) so that radiographic contrast should be increased, and, being chemically inert, Hytrast should excite little in the way of reaction in the bronchi. In mice, oral feeding produces evidence neither of acute nor of chronic toxicity. Both in experimental animals and in clinical practice elimination from the bronchi is rapid, two to seven days, and inflammatory or granulomatous reaction has been observed neither in experimental animals nor clinically in operative specimens removed after bronchography with Hytrast.

Hytrast/

Hytrast was used initially as the bronchographic medium in 50 consecutive investigations. It proved so satisfactory that it is now used routinely. In children the quantity of contrast used was calculated from the age of the patient plus 2ml. for each side; in adults 15 to 20 ml. was used for each side.

Five patients in the original series of 50 had previously been submitted to bilateral bronchography and required repetition of the investigation. In four the previous examination had been with Dionosil Oily and in one with sulphanilamide powder in Lipiodol. In all five good bronchograms were achieved, and in all contrast was improved in comparison with previous bronchograms.

In 20 patients Hytrast and Dionosil Oily were compared, in 10 by using Dionosil for the right bronchogram and Hytrast for the left, and in 10 by using Hytrast for the right and Dionosil for the left. In every instance the right bronchogram was made before the left. It was realised that residual contrast medium in the trachea would be carried into the left bronchi so that a small quantity of whichever contrast medium was first used would be mixed with the contrast medium used for the left bronchogram. In all 20 bronchograms Hytrast, whether used for the right or the left side, produced a better bronchogram - contrast was better, alveolar filling was absent, and the bronchogram was generally more pleasing, probably because the bronchi were outlined rather than filled. The capacity of Hytrast to outline rather than fill bronchi is attributed to the viscosity of the excipient (carboxymethylcellulose).

In some of the earlier bronchograms made with Hytrast peripheral bronchi were incompletely filled. This was remedied by an increase in the number of insufflation with which the contrast medium was blown into the bronchi. If 1 ml. of sterile water is added to each 20 ml. of Hytrast a bronchogram of excellent contrast without alveolar filling is achieved with fewer insufflations. Dilution of Hytrast in this way has now been adopted routinely since it shortens the duration of/

of the procedure. The extent of dilution was estimated by experiment and proved satisfactory in the last 25 bronchograms in the original series.

In 35 of the first 50 patients submitted to bronchography with Hytrast there were traces of the contrast medium on the chest radiograph made routinely 48 hours after bronchography, and in 15 there was no trace. Of the 35, all but five had clear chest films four days after bronchography. Clearing in one patient was longer delayed (Fig. 39), but in the remaining four was complete by the seventh day. In none of the 50 patients was there evidence of bronchial irritation as a consequence of bronchography during the minimum of three days of observation after the investigation. Pyrexia, never higher than 100°F, was observed in 12 patients on the first or second day after bronchography; none had fever after the third day and none was disturbed. In four patients pulmonary resection followed bronchography, in three less than two weeks after this investigation, and in one four weeks later; in none of the operative specimens was there evidence of inflammatory or granulomatous reaction to the contrast medium.

In all, more than 200 bronchograms have now been made with Hytrast, followed, in 23 cases by pulmonary resection; no reason has been found to diminish enthusiasm for the use of Hytrast as a bronchographic contrast medium.

Bronchographic Technique:

In Edinburgh, as in most other centers, bronchography was usually undertaken using in adults local anaesthesia and in children general anaesthesia. In 1957 a technique of bronchography in children was developed (le Roux and Masson, 1962) which, since 1961, has been adopted for all patients, children and adults, who require/

require bronchography. This technique depends on general anaesthesia with sodium thiopentone and a relaxant (suxamethonium). After induction of anaesthesia and inflation of the lungs with oxygen delivered through a face-piece, the bronchi are examined under direct vision. Bronchoscopy enables abnormalities to be detected in the major bronchi and the air passages to be cleared of mucus by suction. On completion of bronchoscopy the lungs are again inflated with oxygen, and a cuffed endotracheal tube is introduced under direct vision into the trachea. The cuff of the tube is inflated and the endotracheal tube connected to a Boyle or similar machine. Inflation is continued with oxygen or oxygen and nitrous oxide. The patient is then turned on his right side, lies on an X-ray cassette, and the X-ray tube anode is positioned. A catheter is passed through the endotracheal tube and, from a 20 ml. syringe, the contrast medium is injected rapidly into the trachea. The rubber bung of the Magill T-piece is replaced, and the lungs are inflated - for five breaths if the contrast medium is Dionosil Oily, for seven breaths if the contrast medium is Hytrast diluted, 20 ml. with 1 ml. water and 10 breaths if the contrast medium is undiluted Hytrast. Inflation is slow and forceful since it is by pulmonary inflation that the contrast medium is blown into the dependent lung.

The radiographic plate for the right lateral bronchogram is then exposed, the patient turned onto his back, a second cassette placed under him, and an antero-posterior view of the right side made. During the moment of radiographic exposure the anaesthetist holds the lungs inflated to depress the domes of the diaphragm. The same procedure is then adopted for the left side, where an oblique and not a lateral view is made. The entire procedure, including bronchoscopy, occupies usually less than five minutes, and it is rarely necessary to inject a supplementary dose /

dose of relaxant. The anaesthetist has full control of respiration except during bronchoscopy, and the technique of bronchography by insufflation, as opposed to a technique which demands changes in posture, is time-saving. Tracheo-bronchial toilet at the end of the procedure usually results in the elimination by suction of a considerable volume of contrast medium. The successful and rapid completion of the examination depends to a large extent on good teamwork and no fewer than six people - surgeon, anaesthetist and assistant, theatre sister and two radiographers - must collaborate. And it must be emphasised that an adequate bronchogram is likely to be achieved without disturbing the patient only when undertaken by experts. As in all other branches of surgery, of which radiography here is an adjunct, there is no room for the occasional expenent, whose only achievement will be to endanger the patient in the production of an inadequate bronchogram.

A feature of this technique of bronchography is that it has removed from the investigation all element of mystique. The need for positioning the patient at a number of arbitrary angles for arbitrary periods of time lent, for the uninitiated, an air of profundity to the experienced bronchographer. And there are no longer those moments of suspense while the radiographs are being developed and before their scrutiny, during which it was not known how complete a bronchogram had been achieved or whether only an outline of the oesophagus would be visible. The insufflation technique is precisely definable in terms of position, either right or left, and number of pulmonary inflations with the patient paralysed. With this technique more than 700 bronchograms have now been made and fewer than 2% have proved inadequate for reaching a decision on management of the patient.

A B

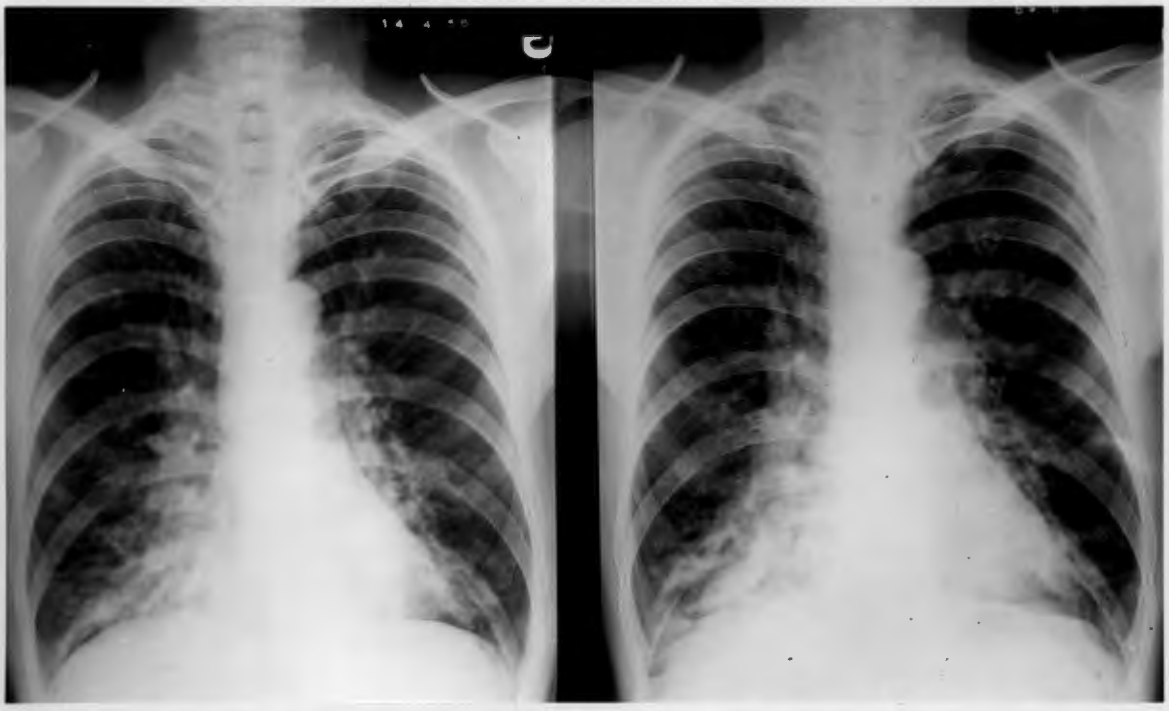

C D

Fig. 35

In the PA chest radiograph (B) lipiodol residue is shown six months after bronchography in a patient with bronchiectasis of the right upper lobe and the apical segment of the right lower lobe(A). In (D) lipiodol residue is clear five years after bronchography - in relation to the posterior ends of the left seventh and eighth ribs, lateral to the shadow of the aortic arch - when this radiograph is compared with the pre-bronchographic PA film (C).

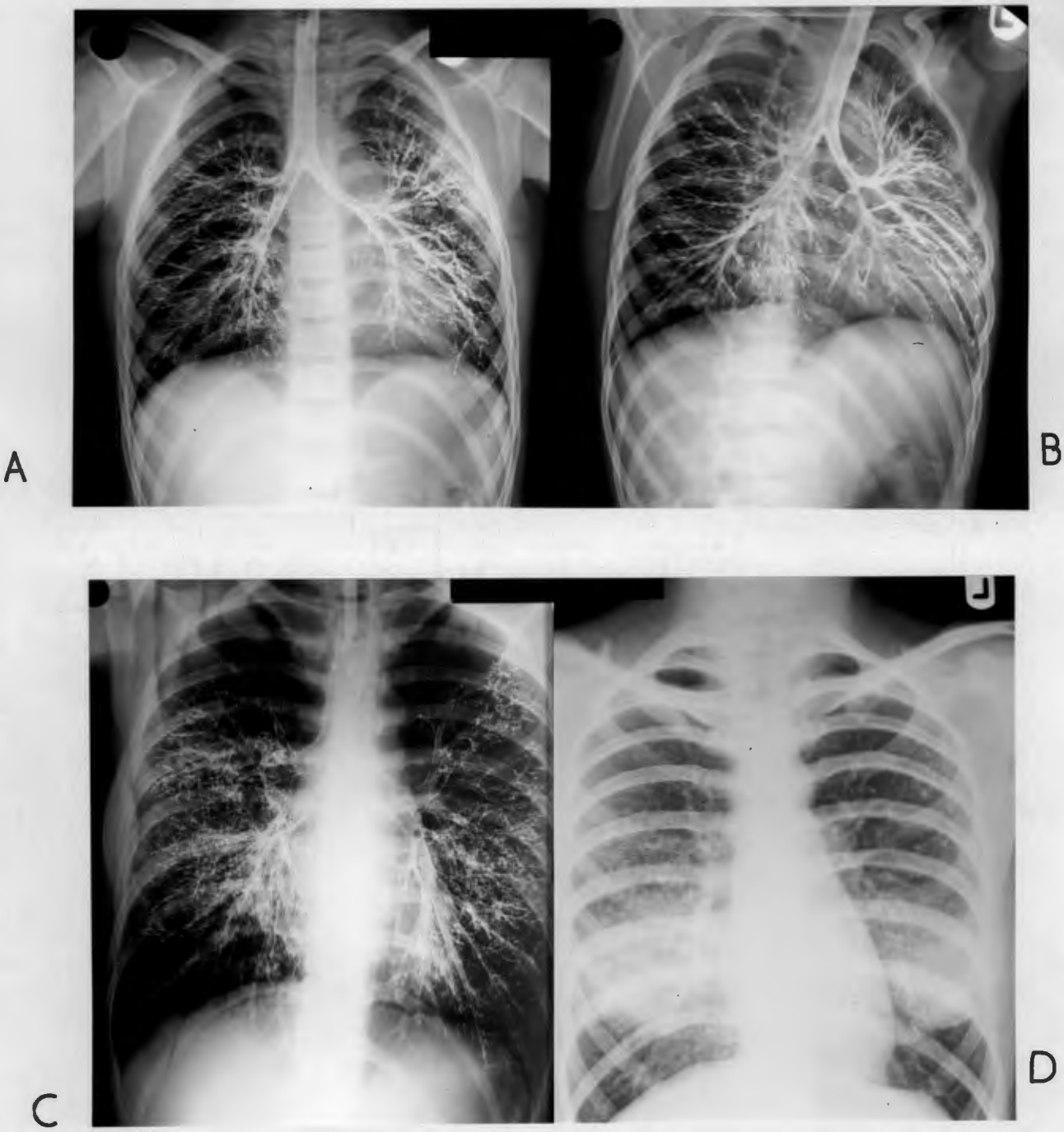

Fig. 36

The bronchogram illustrated as (A) and (B) was made in 1957 by the insufflation technique with lipiodol and sulphanilamide powder as the contrast medium; that illustrated as (C) was made at almost the same time by the aspiration technique in a conscious patient, with the same variety of contrast medium. The difference in peripheral upper lobe filling is clear, especially on the left. Contrast is good and residue, shown in (D), persisted for four months in the patient whose bronchogram is shown as (C).

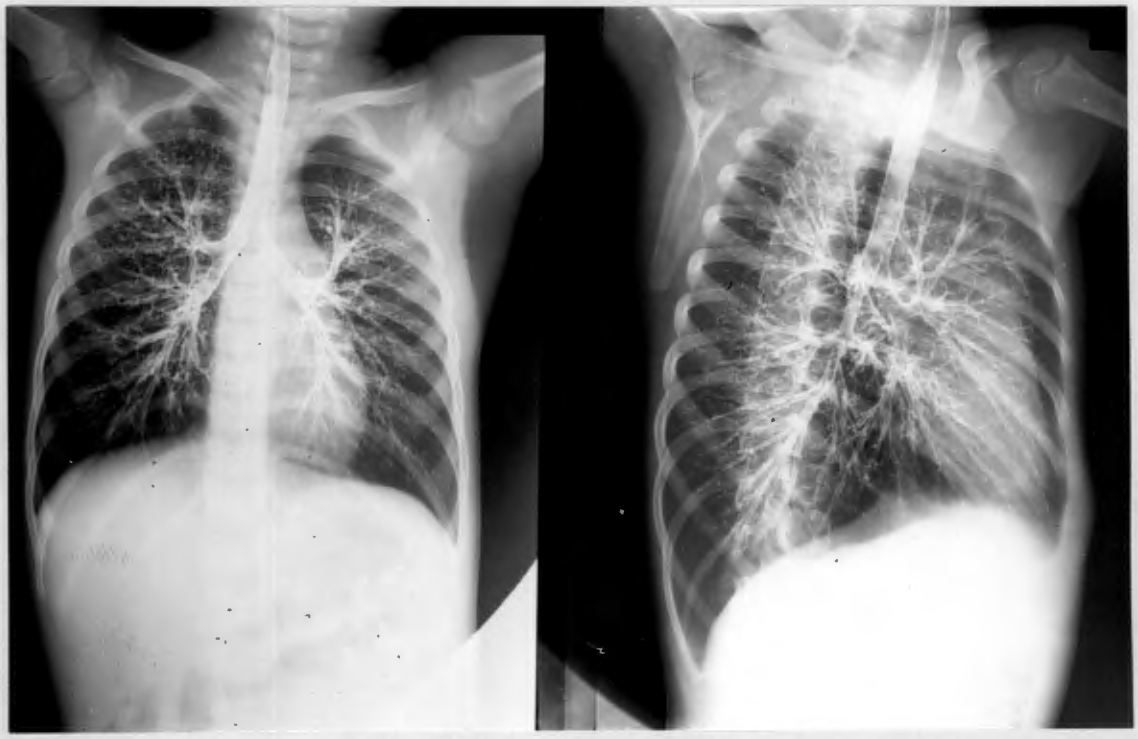

Fig. 37

In the bronchogram illustrated above Hytrast was used on the right and on the left Dionosil Oily. The right side was filled first and, despite 15 pulmonary inflations by the time the film (A) was made there is no alveolar filling on the right. The capacity of Hytrast for outlining rather than filling bronchi is clear, and contrast with Hytrast is increased in comparisson with Dionosil.

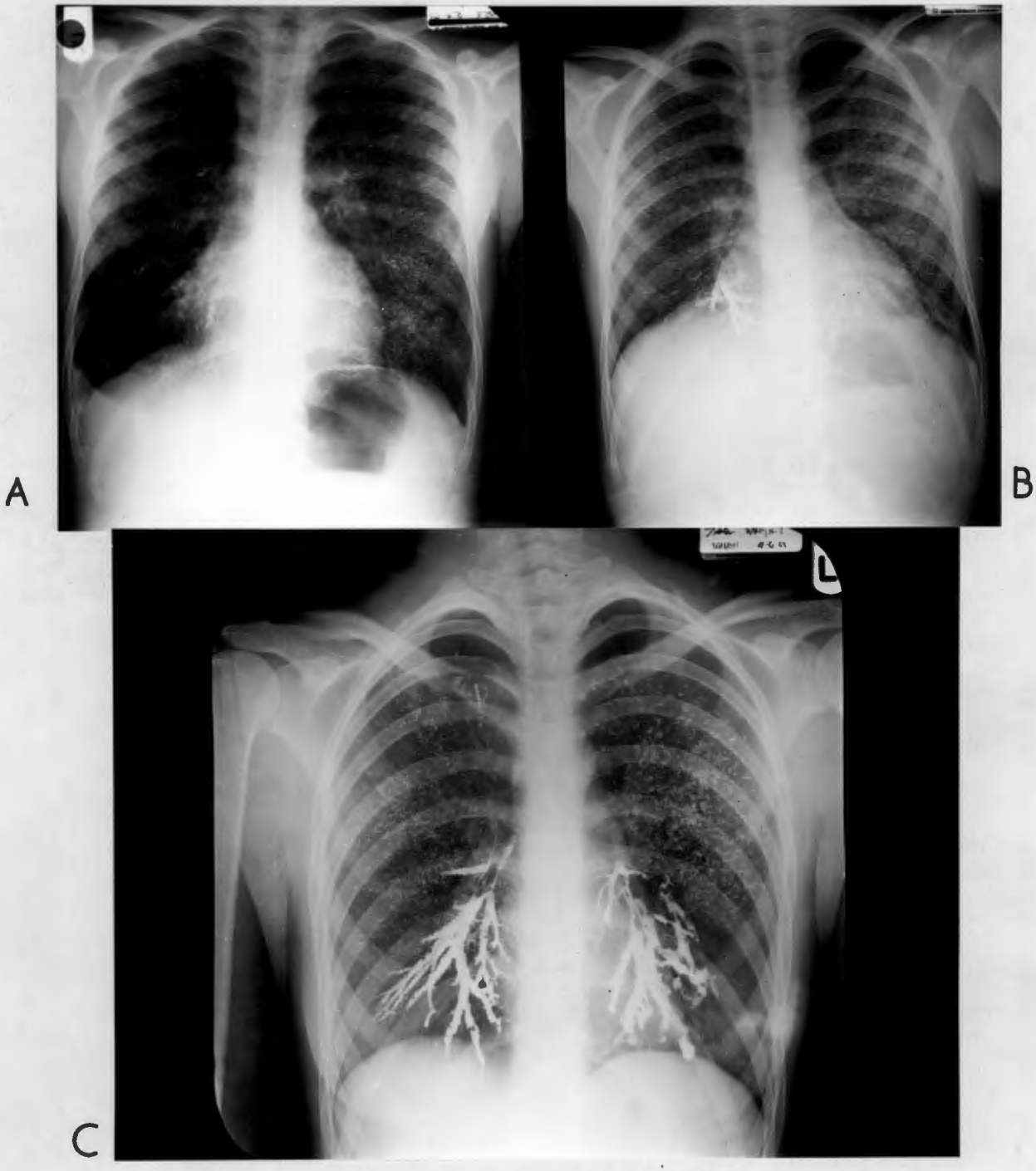

Fig. 38

Residual contrast medium shown radiographically in three different patients on the day following bronchography with Hytrast. In all three the chest radiograph was free of all visible trace of residue on the third day after bronchography.

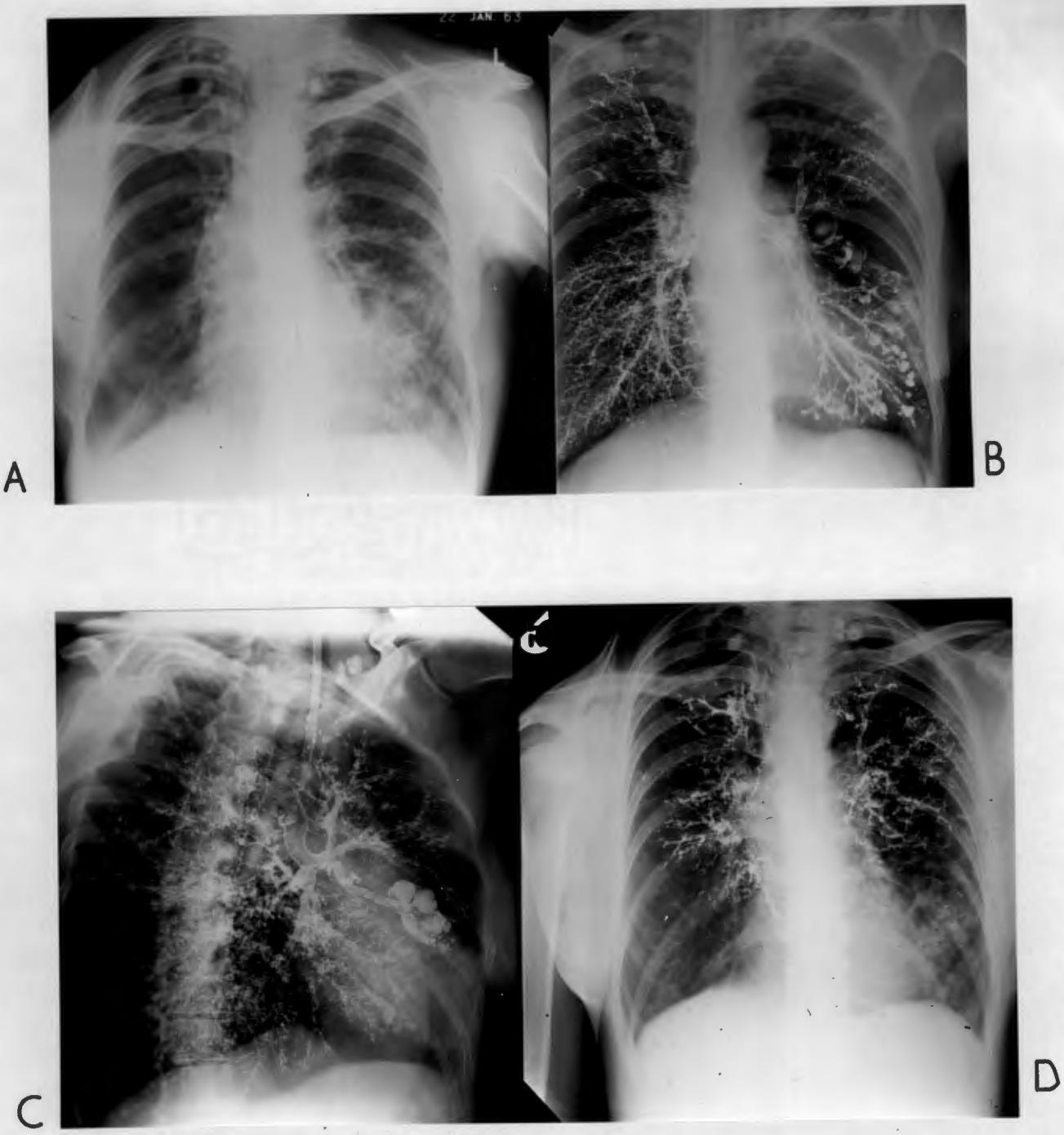

Fig. 39

The patient whose PA film (A) is shown was found by bronchography with Hytrast to have extensive scattered bronchiectasis (B & C). She had, in addition, asthma. Retained Hytrast was visible radiographically nine days after bronchography (D). She next attended 27 days after bronchography and retained Hytrast was no longer visible.

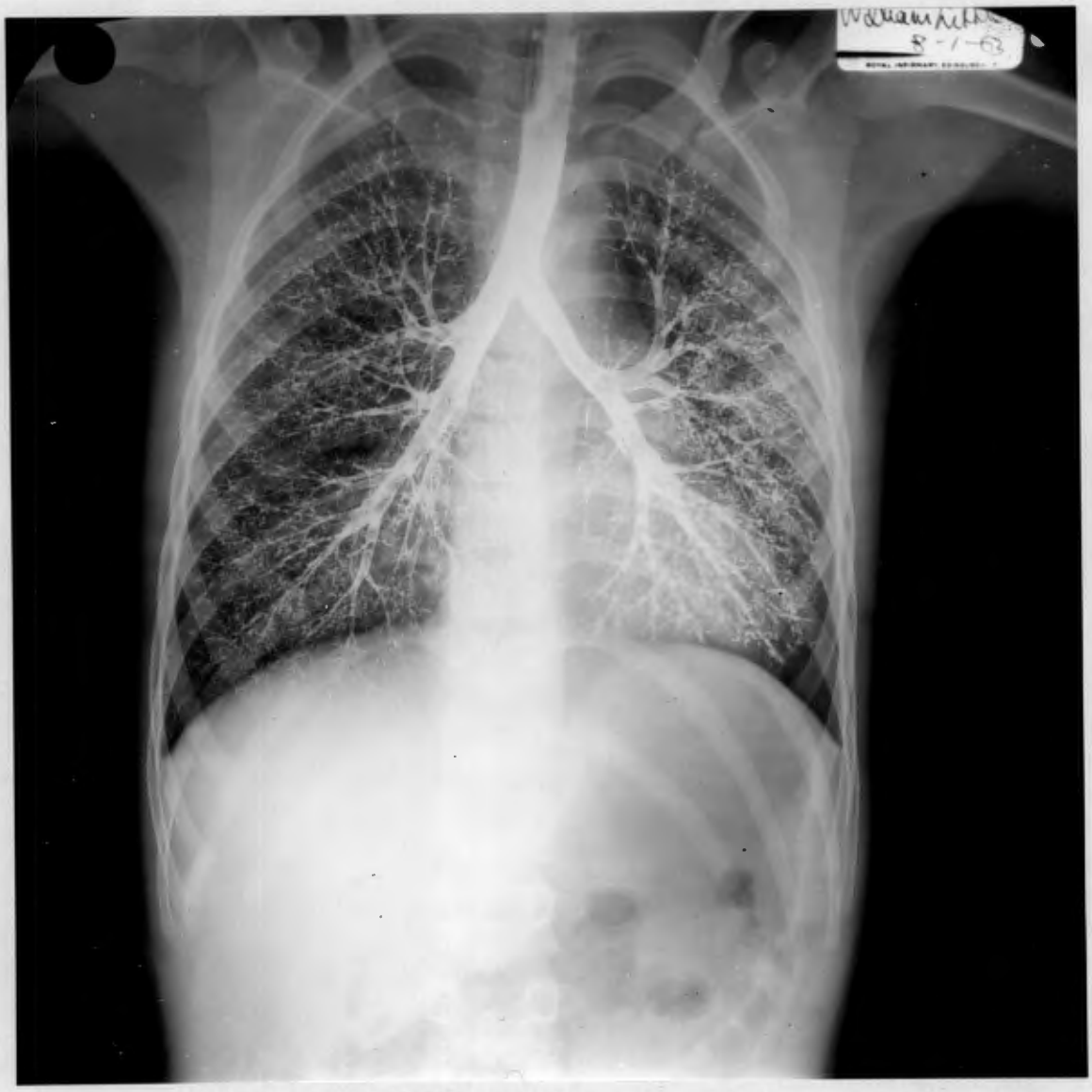

Fig. 40

A normal antero-posterior bronchogram made with Hytrast as the contrast medium and using the insufflation technique. All the bronchi are clearly recognisable, are completely outlined to within a short distance of the chest wall, and there is no alveolar filling

Fig. 41

Another example of a normal bronchogram made with Hytrast as the contrast medium and using the insufflation technique.

CHAPTER IV

THE RESULTS OF MANAGEMENT OF BRONCHIECTASIS IN 1038 PATIENTS

Management, whether surgical or conservative, is outlined in Table I. Resection was undertaken in 409 patients (39%) and 629 patients were regarded as unsuitable for surgical management, declined operation or have not yet been adequately assessed, although some of these last-mentioned have been observed for several years. Of the total of 1038 patients, 532 (51%) were males; 45% of the 409 patients managed surgically were males. Of the patients with total unilateral bronchiectasis 67% were managed surgically; 62% of patients with bronchiectasis which involved a lobe and an ipsilateral segment or group of segments were managed by resection; in the other three groups - unilateral lobar and unilateral segmental bronchiectasis and bilateral bronchiectasis - the rate of resection was, in all, less than 50% of patients seen and, of patients with bilateral bronchiectasis, only 16% were regarded as suitable for surgical management.

The disposition of the disease as outlined in Table I is spurious in so far as it is an analysis based for convenience on the extent of resection undertaken, the extent of resection which would have been undertaken if management had been aggressive, and the bronchographically demonstrated extent of disease at the time of pre-operative assessment. The analysis does not, therefore, recognise the existence of one or two normal segments in a patient with otherwise total unilateral bronchiectasis because surgical management in these circumstances is by pneumonectomy/

pneumonectomy and this extent of bronchiectasis is thus classified as total unilateral; neither does the analysis take congnizance of known bilateral bronchiectasis deliberately managed only by unilateral resection and of bronchiectasis found at post-operative bronchography where none had been thought to be present at pre-operative assessment. Thus in 32 patients unilateral resection (pneumonectomy in eight, lobectomy in two, lobar and ipsilateral segmental resection in 19 and segmental resection in three) was undertaken in the knowledge that there was contra-lateral bronchiectasis, usually fusiform and bronchographically unimpressive in comparison with the gross saccular disease resected, but always within anatomical limits of surgical management, unless related to total contra-lateral disease, should the initial resection not adequately control symptoms or should symptoms recur at a later date. (In a 33rd. patient bilateral resection was undertaken in the knowledge that there was cystic disease in part of the right upper lobe, which was not resected.) Two patients, one of whom underwent lobectomy and the other lobar and ipsilateral segmental resection, in each as part of a planned bilateral resection, declined the second, contra-lateral resection. In ten patients contra-lateral bronchiectasis was found at post-operative bronchography - after lobectomy in four and segmental resection in six. Thus, although only 49 patients are listed in Table I as having been managed surgically for bilateral bronchiectasis, in this group of 409 patients a further 44 patients had bilateral bronchiectasis. Two patients submitted only to lobectomy were found post-operatively to have an abnormal ipsilateral segment.

The number of patients seen each year is shown graphically in Fig.42 . This histograph would appear to show a high incidence of patients with bronchiectasis who/

who presented for the first time for a surgical opinion between 1949 and 1953, with a rapid fall in the incidence of patients seen for the first time thereafter, a large number of patients unsuitable for management by resection amongst the total number seen each year before 1952 or 1953, and an appreciably higher resectability rate after 1957. From such an analysis of the histograph it is tempting to conclude that the incidence of bronchiectasis has fallen and that either the distribution of the disease has changed or that the attitude towards management by resection has become less conservative. None of these conclusions is justified. The increase in the number of patients seen for the first time between 1947 and 1953 reflects nothing more than the establishment and growth of a Thoracic Surgical Unit in the region, a change in attitude amongst general practitioners and physicians to precise investigation of respiratory symptoms, and the admission and investigation over a relatively short period of patients who had accumulated on a waiting list. The diminution of the gap between the number of patients seen and the number managed surgically after 1957 reflects the establishment in the region of a medical unit dealing with respiratory diseases, in which patients with bronchiectasis were investigated, where those with bronchiectasis outwith the range of surgical management were treated without reference to a surgical unit, and from which only those suitable for management by resection of bronchiectasis were referred for surgery, with their investigations completed. There is, therefore, from available figures no evidence of either a change in the incidence or distribution of the disease or in the criteria of acceptability for surgical management.

In Figs. 43 and 44 ages are shown graphically - in Fig.43 of patients managed/

managed conservatively, in the year when first they were referred for a surgical opinion, and in Fig. 44 of patients in the year in which resection was undertaken. The large number of patients over 35 years of age who were regarded as unsuitable for surgical management is clear, and in many of these age was an important contra-indication to resection, when correlated with relative paucity of symptoms, respiratory reserve, and so on; and the large number of children under ten years who are being managed conservatively reflects, in some, only delay in reaching a decision on management so that the severity of symptoms and the influence of puberty can more clearly by established.

BRONCHIECTASIS - 1038 PATIENTS 1947 - 1963

Extent of Bronchiectasis	Managed by Resection			Managed Conservatively		
	Male	Female	Total	Male	Female	Total
Total Unilateral	35	43	78	17	21	38
Unilateral Lobar	78	57	135	117	55	172
Unilateral Lobar and Segmental	26	50	76	20	26	46
Unilateral Segmental	31	40	71	71	52	123
Bilateral	14	35	49	123	127	250
	184	225	409	348	281	629

TABLE I

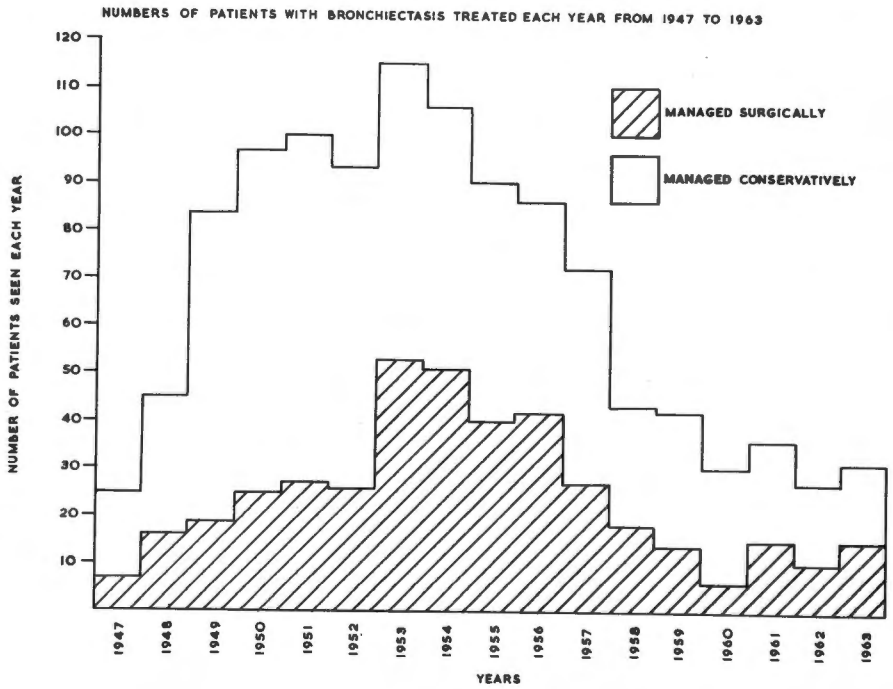

Fig. 42

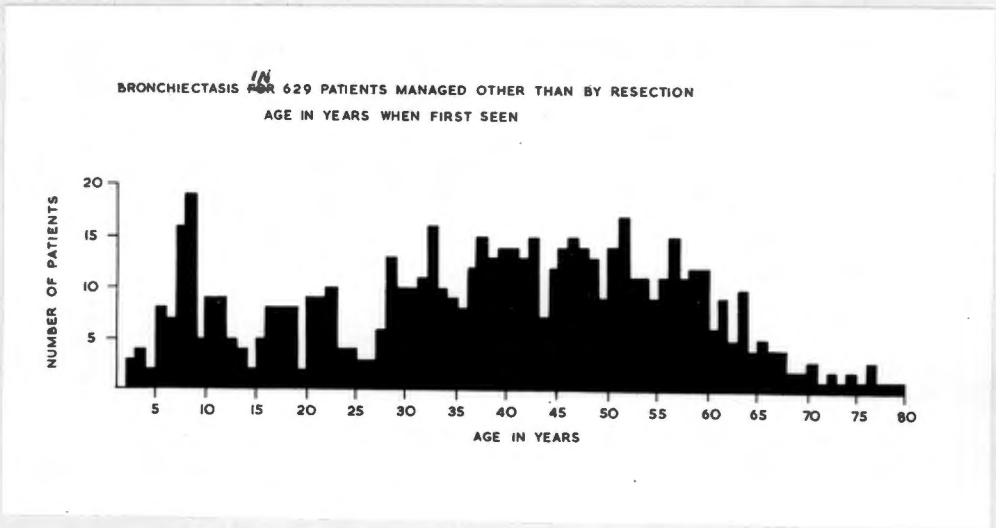
BRONCHIECTASIS IN 629 PATIENTS MANAGED OTHER THAN BY RESECTION
AGE IN YEARS WHEN FIRST SEEN
NUMBER OF PATIENTS
20
15
10
5
5 10 15 20 25 30 35 40 45 50 55 60 65 70 75 80
AGE IN YEARS

Fig. 43

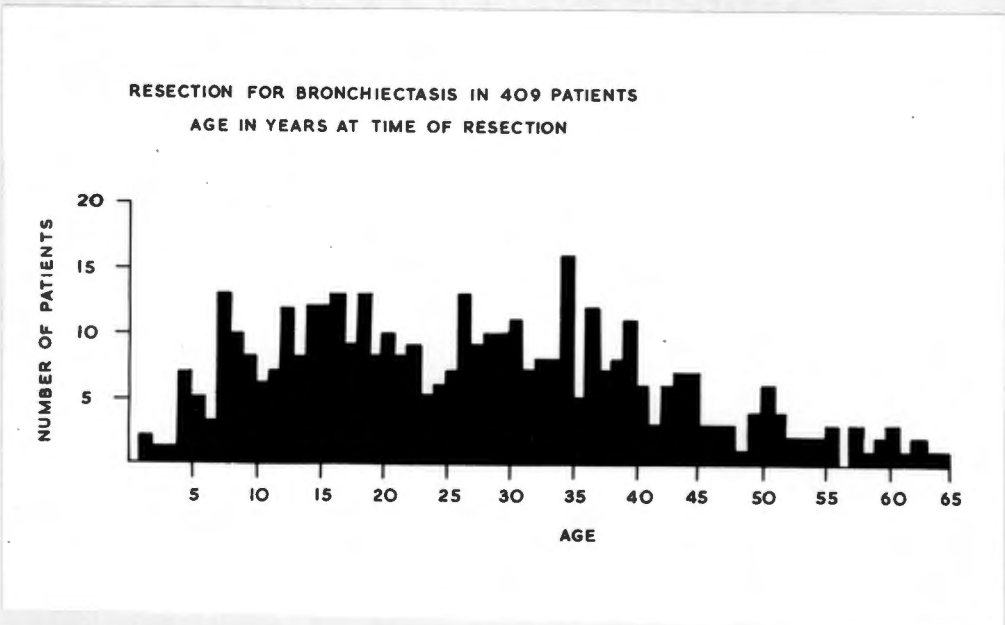
RESECTION FOR BRONCHIECTASIS IN 409 PATIENTS
AGE IN YEARS AT TIME OF RESECTION
NUMBER OF PATIENTS
20
15
10
5
5 10 15 20 25 30 35 40 45 50 55 60 65
AGE

Fig. 44

Total Unilateral Bronchiectasis Managed by Pneumonectomy

Pneumonectomy was the only operation undertaken for bronchiectasis in 78 patients. Details which relate to these patients are shown in Table II. In one other patient, whose case is detailed in the section on bilateral resection, left pneumonectomy and middle lobectomy were undertaken. Of the 78 patients, 35 were male and 43 female; pneumonectomy was right-sided in 26 and on the left in 52; the youngest patient was three years of age and the oldest 65. Ten patients were ten years of age or younger at the time of resection and a further 11 were under the age of 20 years; 14 were in the third decade, 17 in the fourth, 18 in the fifth, and eight were 50 years or older. About two-thirds of the 78 pneumonectomies were undertaken in the five year period 1951 - 1955, and the largest number of resections undertaken in any one year was 15 - in 1953.

Seven patients have died, two directly as a consequence of operation, two within a year of operation from pulmonary infection, and three - 18 months, 4 and 11 years after operation - with cor pulmonale. One of the operative deaths was from haemorrhage and was the consequence of technical inadequacy; the other occurred on the second post-operative day in a patient who had failed to regain consciousness after operation and in whom a cause of death was not demonstrated at necropsy.

Two patients who are alive have the clinical and electrocardiographic features of cor pulmonale and are severely handicapped by dyspnoea; life in four others is importantly modified by recurrent episodes of bronchitis. One patient has hepatomegaly, albuminuria and peripheral oedema and probably has amyloid disease, but histological proof of this diagnosis has not yet been achieved. Two patients /

patients cannot be traced; the others are well. Six female patients, girls at the time of pneumonectomy, are now married, three with children. The men and women in the third, fourth and fifth decades work normally, a few in sheltered employment from which, alternatively, others have emerged following pneumonectomy. None works strenuously in a labouring occupation, except perhaps the women who look after a household without domestic help.

Pneumonectomy in eight patients was undertaken with the knowledge that there was a little contra-lateral bronchiectasis (Fig. 48 and 49). One of these patients may have amyloid disease, one has died with cor pulmonale and one is alive, also with cor pulmonale; five are well and deny symptoms.

Nearly all the patients submitted to pneumonectomy for bronchiectasis gave a history of respiratory symptoms for as long as they could remember. Severe haemoptysis prompted investigation in three patients; two attributed, retrospectively, the onset of symptoms to the inhalation of a foreign body ten and twenty years earlier, and one to tooth extraction. In neither with the history of foreign body inhalation was the foreign body still present; in both the left main bronchus was stenosed. In two other patients there was stenosis of the left main bronchus and in one stenosis of the left upper bronchus. In three patients the resected lung showed the histological features of pulmonary tuberculosis, and it is a presumption in these patients that bronchiectasis was post-tubercular; in none did routine pre-operative investigation establish this diagnosis. Pericardiectomy and left pneumonectomy were undertaken together in one patient and, although clear histological evidence of tuberculosis was not obtained, the pericardium in this patient was partially calcified and tuberculosis is the likely cause of both the pericardial and pulmonary lesions. One patient who underwent /

underwent left pneumonectomy for bronchiectasis had radiographic evidence of healed right upper pulmonary tuberculosis and another had previously been treated for tuberculous orchitis. In neither of these last-mentioned patients was there histological evidence of tuberculosis in the resected specimen. In one patient the resected lung showed the changes of sarcoid and in another the pathologist believed the histological features to suggest pulmonary dysplasia; this specimen has been discarded and the report is unconvincing.

In three resected lungs a carcinoma was found - squamous in two men of 41 and 43 yfears, both of whom smoked, in neither of whom the diagnosis of carcinoma was suspected pre-operatively, and both of whom are alive ten and twelve years after pneumonectomy, one with cor pulmonale. In both these patients the carcinoma was small and peripheral in type. The third carcinoma was undifferentiated and multicentric and was found in a lung resected from a 19 year-old girl who did not smoke and who is well twelve years later. Abnormal clumps of epithelial cells which produce tumour-like formations and which are called tumourlets (Cunningham, Nassau and Walter, 1958) are found in 20% of lobes or lungs resected for bronchiectasis; the carcinomata in these three cases were histologically quite distinctive and different from tumourlets. Two other patients, who were investigated for cough and sputum during the period under discussion, were shown to have right upper lobar bronchiectasis, and were not regarded as surgical subjects because of their ages and the relative paucity of their symptoms, later developed right upper squamous carcinomata of central type - one three and one nine years after initial investigation. Both were managed by pneumonectomy and both are alive; in neither was there glandular metastasis.

Convalescence in two young children was complicated by membranous laryngo-tracheitis which necessitated management by tracheostomy and from which recovery was complete /

was complete. This complication was attributed to trauma from the cuffed endo-tracheal tube used in the control of respiration during operation (Straton and Muir, 1954).

In seven patients the pre-operative history included that of empyema thoracis, managed previously by drainage in two and present at the time of pneumonectomy and managed by pleuro-pneumonectomy in five (Fig.52 and 53). Lung abscess had complicated bronchiectasis in one patient some years before pneumonectomy. Resection in five patients was complicated by empyema; in three of these the empyema was managed by open drainage followed by an extensive thoracoplasty and in two by only open drainage. In one of these last-mentioned two the empyema was recognised two years after pneumonectomy - two years during which the patient had been entirely well except for the week prior to the recognition of the empyema. The relatively conservative approach to the management of postpneumonectomy empyema is a recent change in surgical practice and has proved successful (le Roux,1964a). Thoracoplasty in one other patient was undertaken - probably needlessly - because the resected lung showed the histological features of tuberculosis.

Pulmonary arterial catheterisation at rest and during exercise has been undertaken in twenty patients who were submitted to pneumonectomy for bronchiectasis more than ten years ago. Their ages at the time of catheterisation ranged from 15 to 61 years. In all, mean pulmonary arterial pressure at rest was normal or only very slightly raised and in all but two mean pulmonary arterial pressure after exercise was raised - the range here was 19 - 35 mm. of mercury. The forced expiratory volume in these twenty patients averaged a little more than half the predicted normal for them, and vital capacity averaged two-thirds/

two-thirds of predicted normal. Haemoglobin levels were normal. These patients all regarded themselves as well and in this group were three of the six girls who have married and in whom a series of pregnancies has been uneventful.

TABLE II

TOTAL UNILATERAL BRONCHIECTASIS MANAGED BY PNEUMONECTOMY

	MALE (Ages)	FEMALE (Ages)
RIGHT	8 : 21 : 23+ : 24 : 28 : 32 41 : 42 : 43 : 44 : 50 **Total 11**	5 : 8 : 10● : 13 : 16* : 18 25 : 27 : 40 : 40 : 41 : 42*● 44 : 56 : 65● **Total 15**
LEFT	3 : 5 : 12 : 12 : 18 : 24 26 : 27* : 27 : 27 : 30 : 31* 33 : 35 : 35 : 36+ : 36 : 37 39 : 40 : 43● : 45 : 49 : 50 **Total 24**	9* : 9 : 10 : 10 : 13 : 17 18 : 18 : 19 : 21 : 25* : 29 31 : 35 : 36 : 37 : 37 : 37 39 : 43* : 45* : 45 : 46 : 46 51 : 52 : 55 : 60● **Total 28**

- * Residual Bronchiectasis (8)
- \+ Operative Death (2)
- ● Late Death (5)

Unwell (7)

Number of Operations in Each Year

1947	- 3	1955	- 4
1948	- 4	1956	- 4
1949	- 3	1957	- 4
1950	- 2	1958	- 2
1951	- 8	1959	- 2
1952	- 8	1960	- 1
1953	- 15	1961	- 1
1954	- 12	1962	- 4

1963 - 1

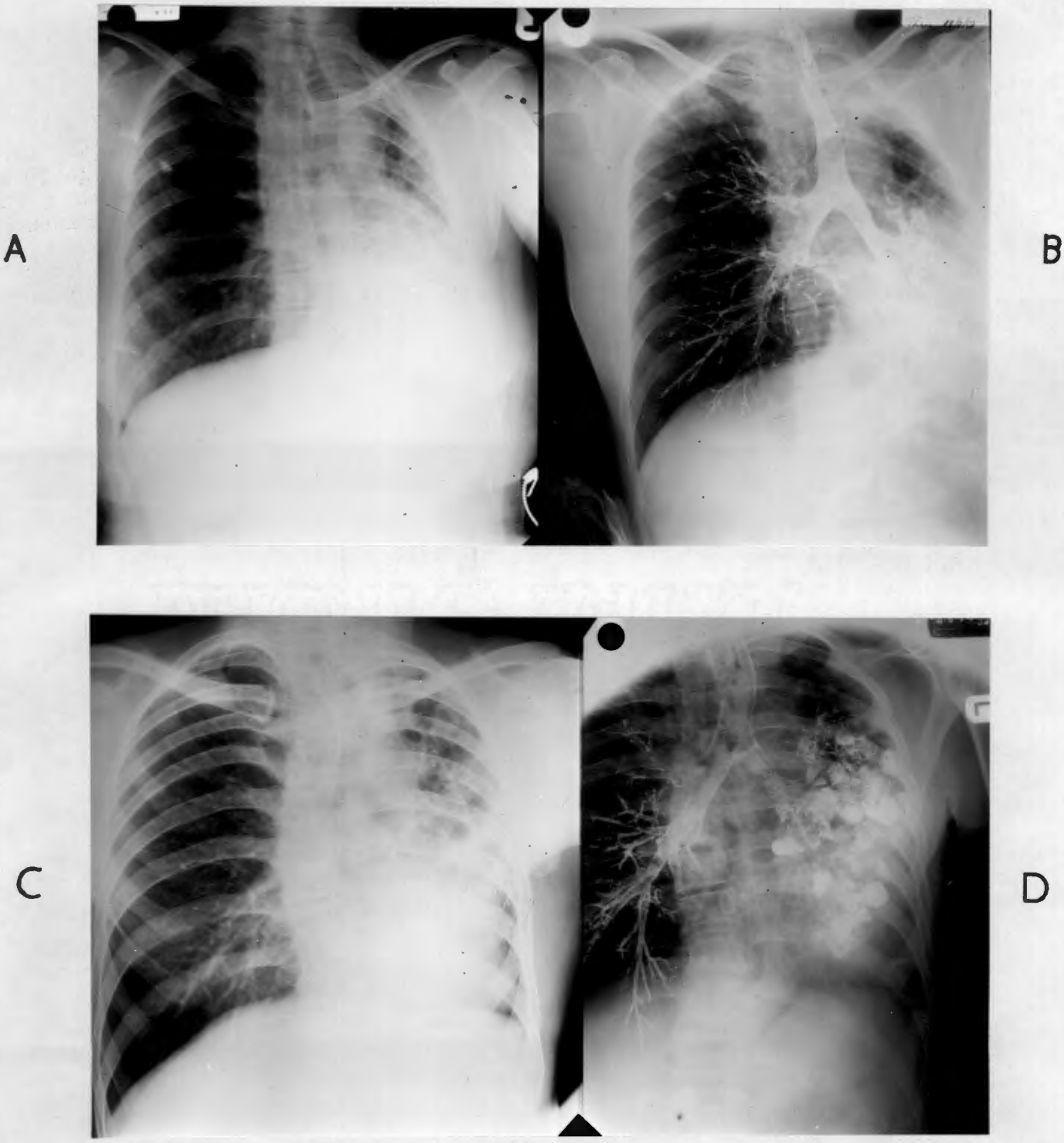

Fig. 45

Total left bronchiectasis in two different patients , each later managed by left pneumonectomy, is shown in the bronchograms (B) & (D). Corresponding pre-operative PA chest radiographs (A) & (C) are illustrated.

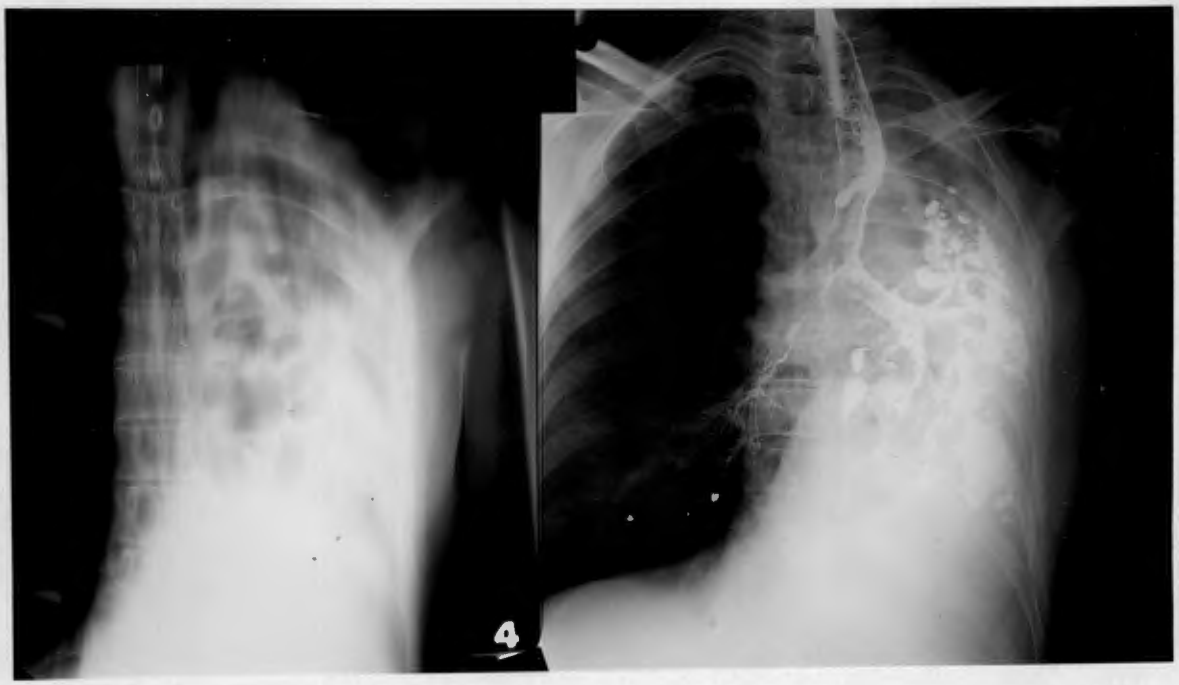

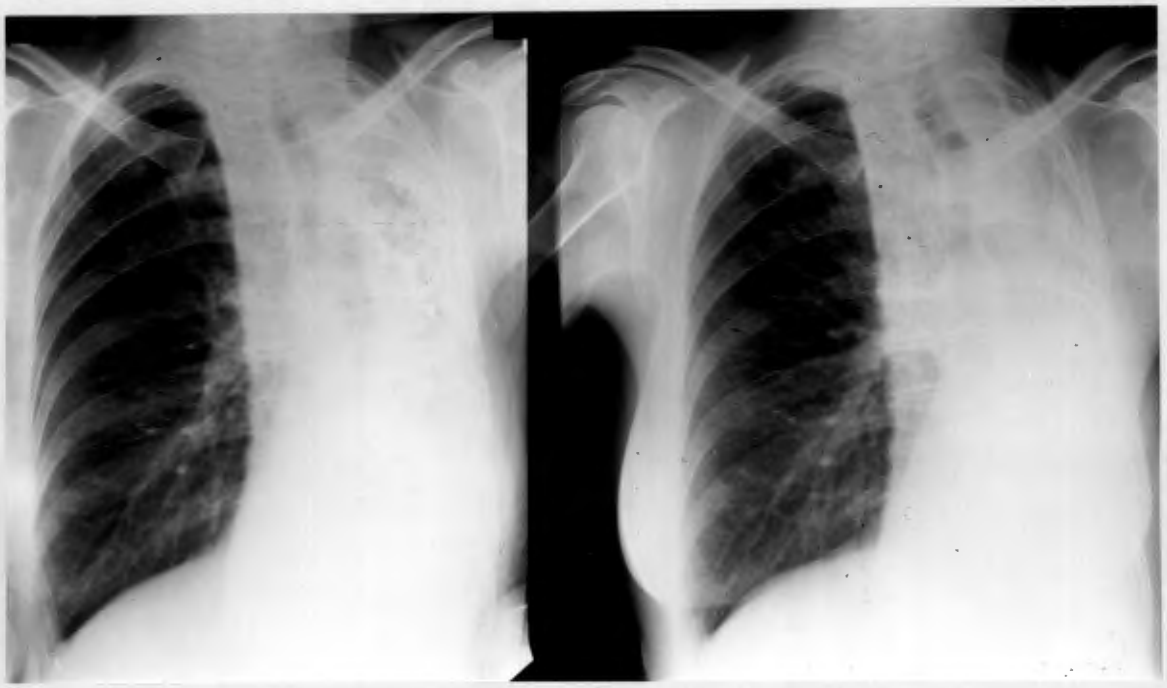

Fig. 46

A totally destroyed left lung is shown in the tomographic cut (A) and the AP bronchogram (B). The PA chest radiograph made after left pneumonectomy is little differeht from that made before - (C) is the pre- and (D) the post-operative film.

A

B

C

D

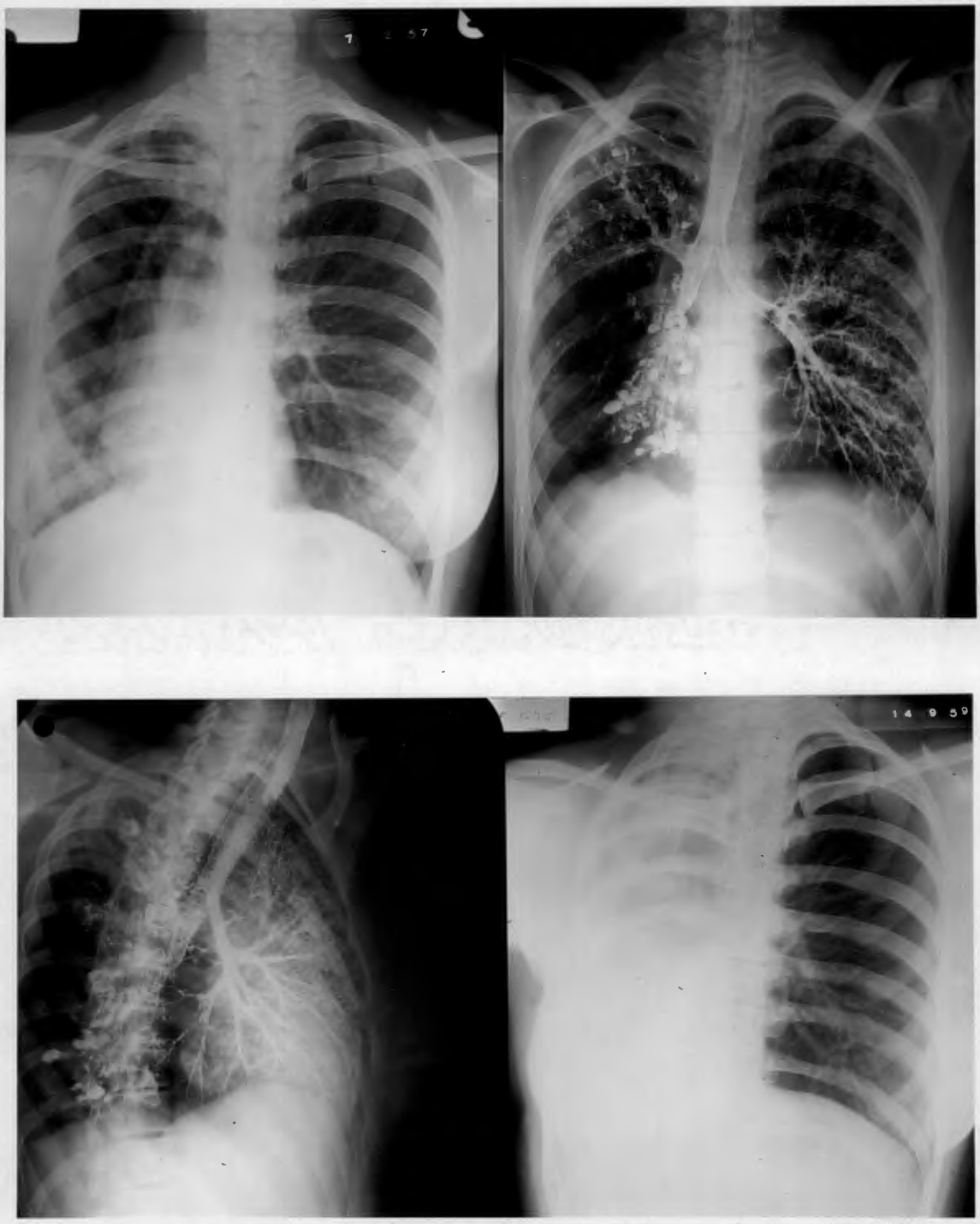

Fig. 47

Total right bronchiectasis, shown in (B) & (C), was managed by right pneumonectomy in the patient whose films these are; symptoms were relieved. The left bronchi are well shown, particularly in (C), and are normal. A pre-operative PA chest radiograph (A) and a post-operative film (D) are shown.

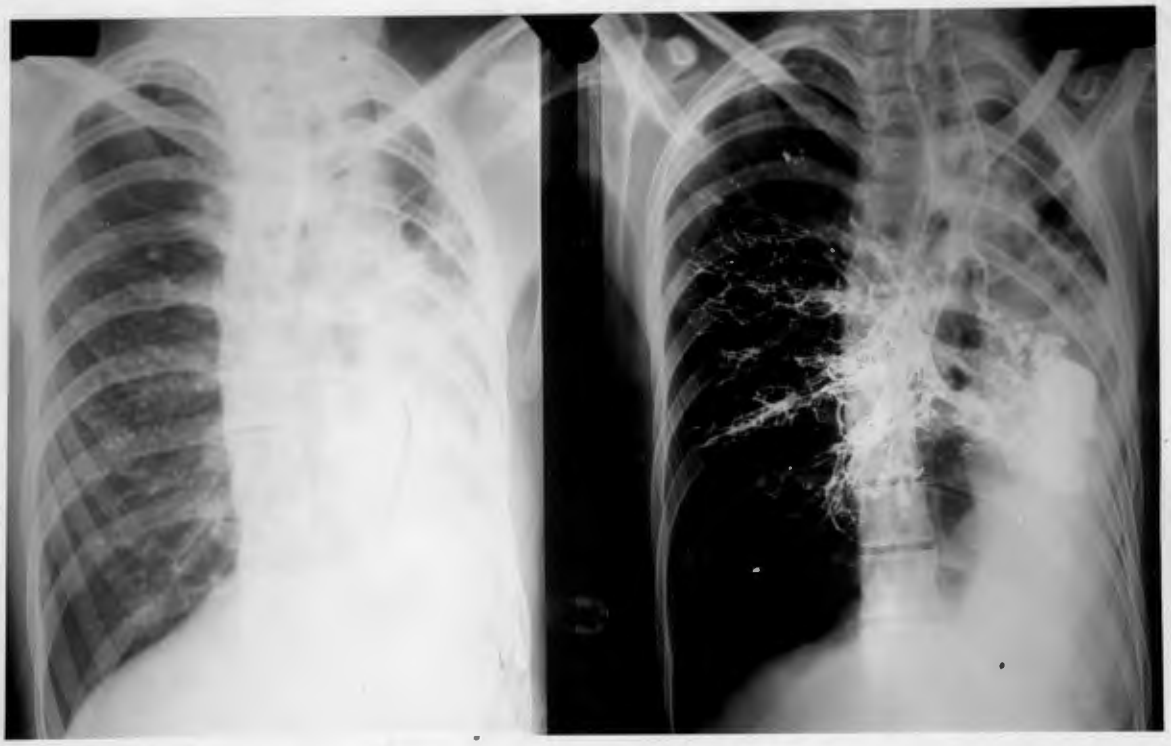

A B

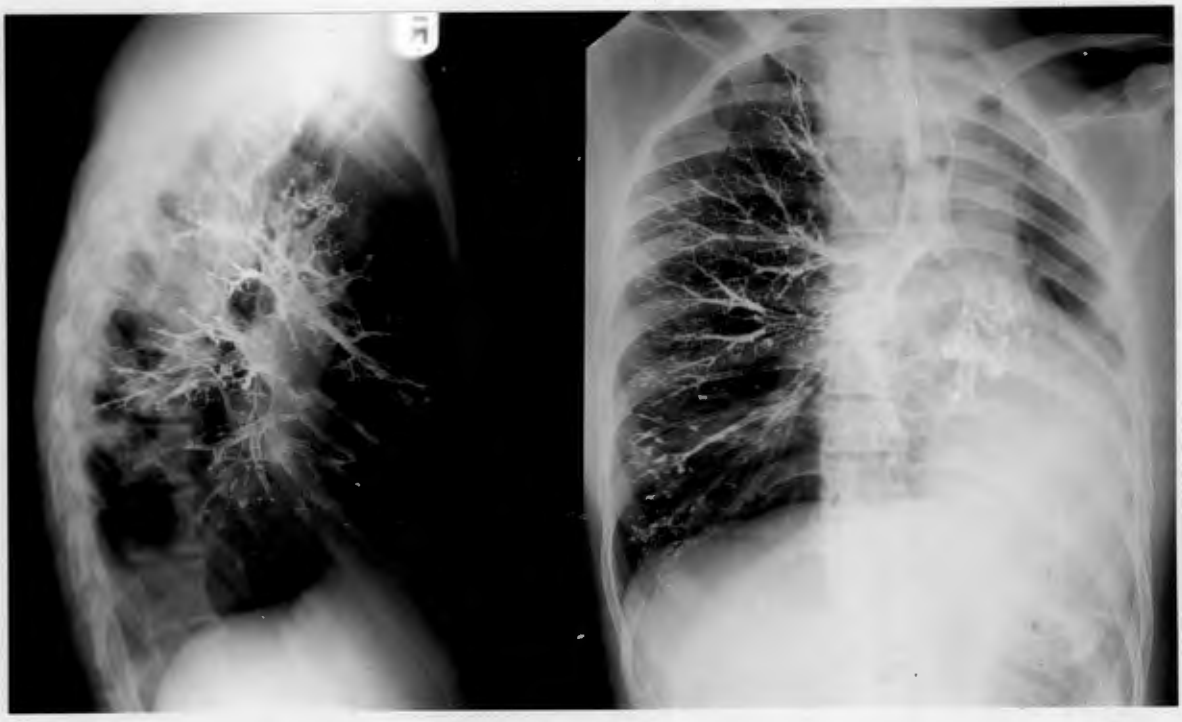

C D

Fig. 48

Total left bronchiectasis (A & B) in the patient whose films these are was managed by pneumonectomy with relief of respiratory symptoms; there is some right basal and some middle lobar bronchiectasis, and this patient may have amyloid disease.

The radiographs (C) & (D) are of a different patient, managed similarly, and in him left pneumonectomy has been followed by relief of all symptoms despite the abnormality of so middle lobar and basal bronchi.

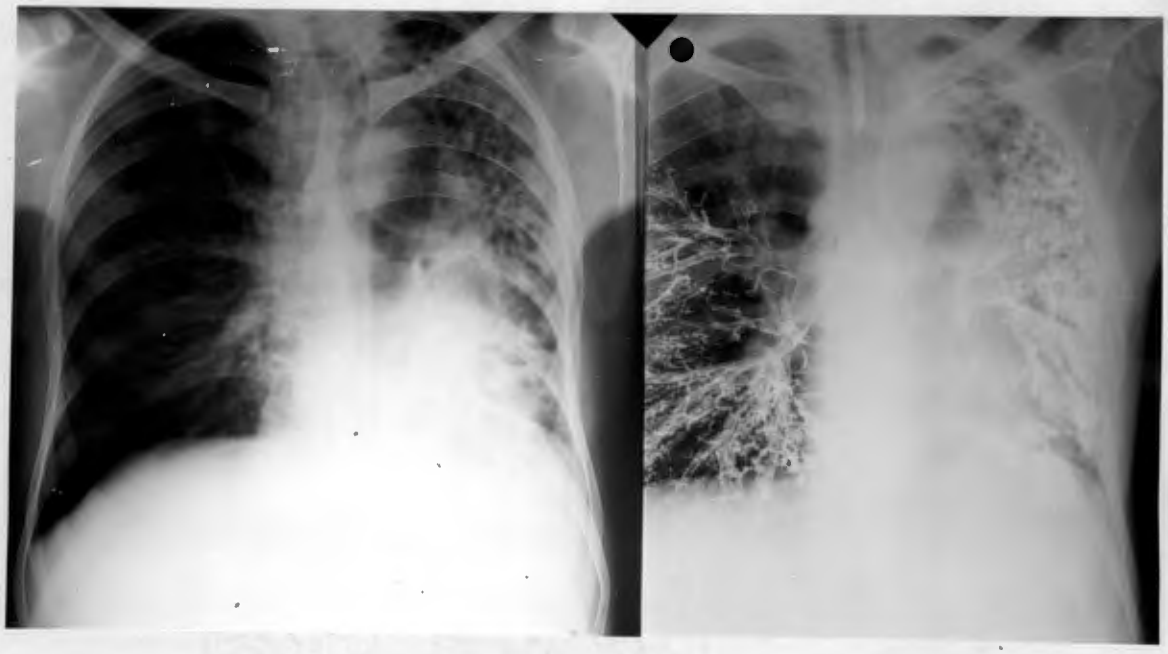

A B

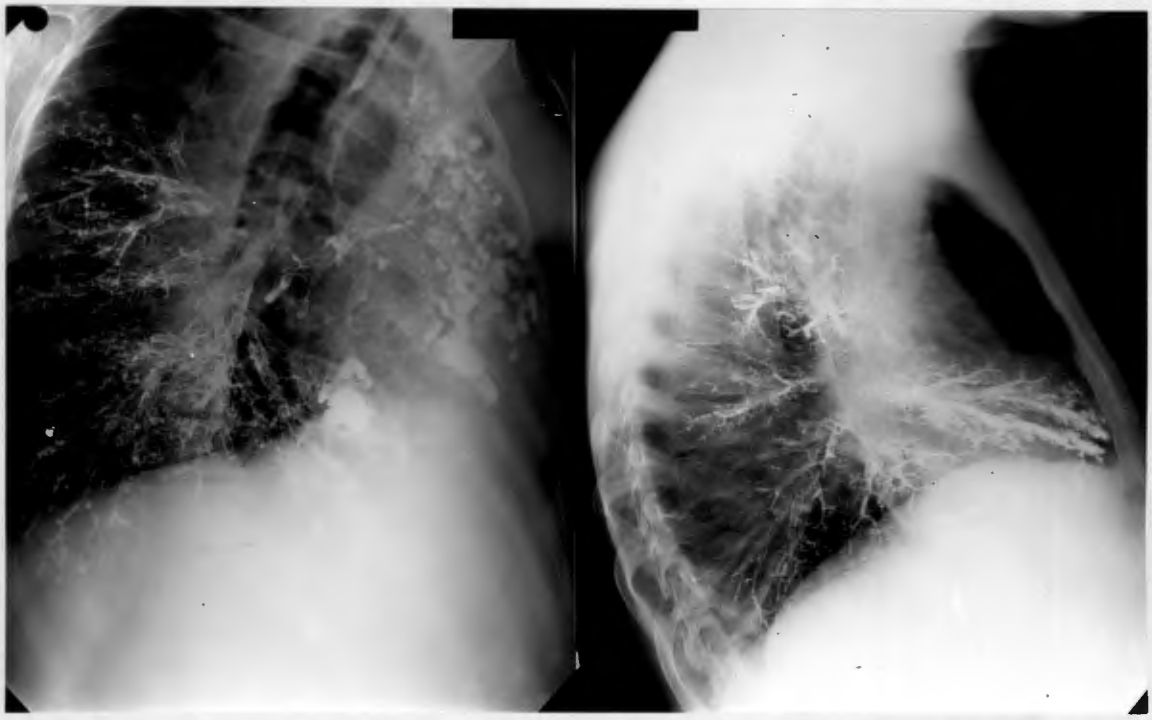

C D

Fig. 49

These are the radiographs from a patient with total left bronchiectasis in whom symptoms were relieved by left pneumonectomy. The middle bronchus, shown in the right lateral bronchogram (D) is abnormal in its distal limits - this abnormality was clearly recognised before pneumonectomy. Honeycombing is well shown in the pre-operative PA chest radiograph (A).

A B

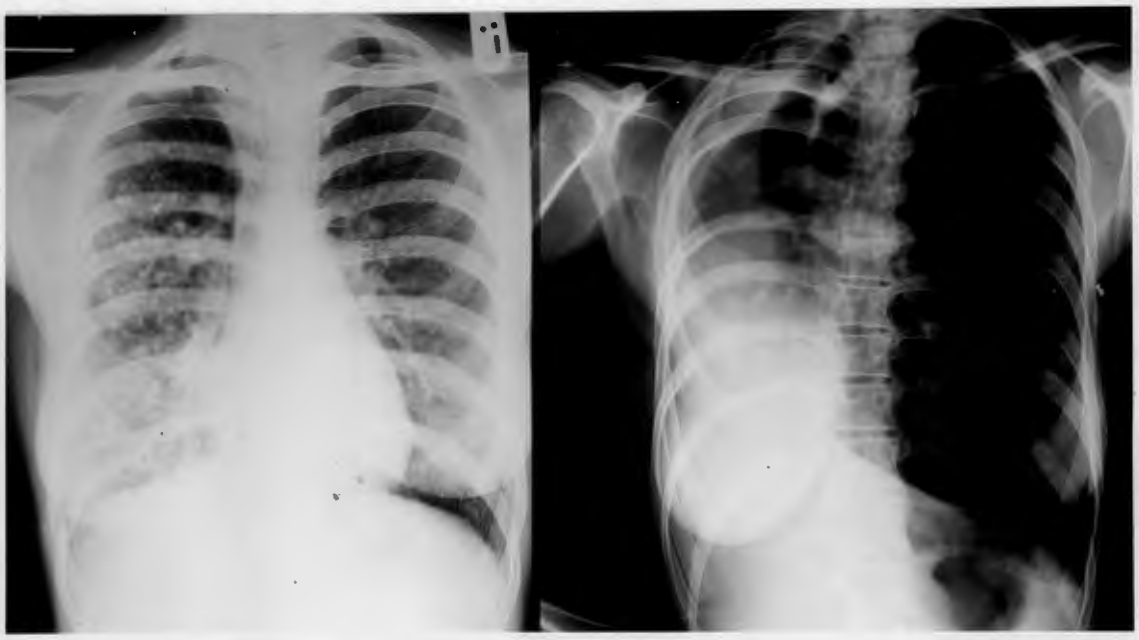

C D

Fig. 50

Total right bronchiectasis (A & B) was managed in the patient whose films these are by right pneumonectomy. Lipiodol residue seen in the pre-operative film (C) is more obvious on the right - lipiodol nearly always remains radiologically obvious longer in areas of bronchiectasis than in relation to normal bronchi. The degree of tracheal deviation, with curvature, shown in the post-operative film (D), is sometimes an encumberance, and may make it difficult for the patient to cough. There appears to be no effective way of avoiding this post-operative phenomenon, the extent of which varies over a wide range. Plombage of the pleural space empty of lung is too often followed by empyema to be justifiable, and in any event does not prevent tracheal deformity, and total thoracoplasty is traumatic, deforming and equally ineffective.

A

B

Fig. 51

Tracheal bowing is a feature not only of pneumonectomy. From the illustration above of total right bronchiectasis it is clear that the tracheal deformity which may result from pneumonectomy may, with all its related disadvantages, result from pulmonary shrinkage.

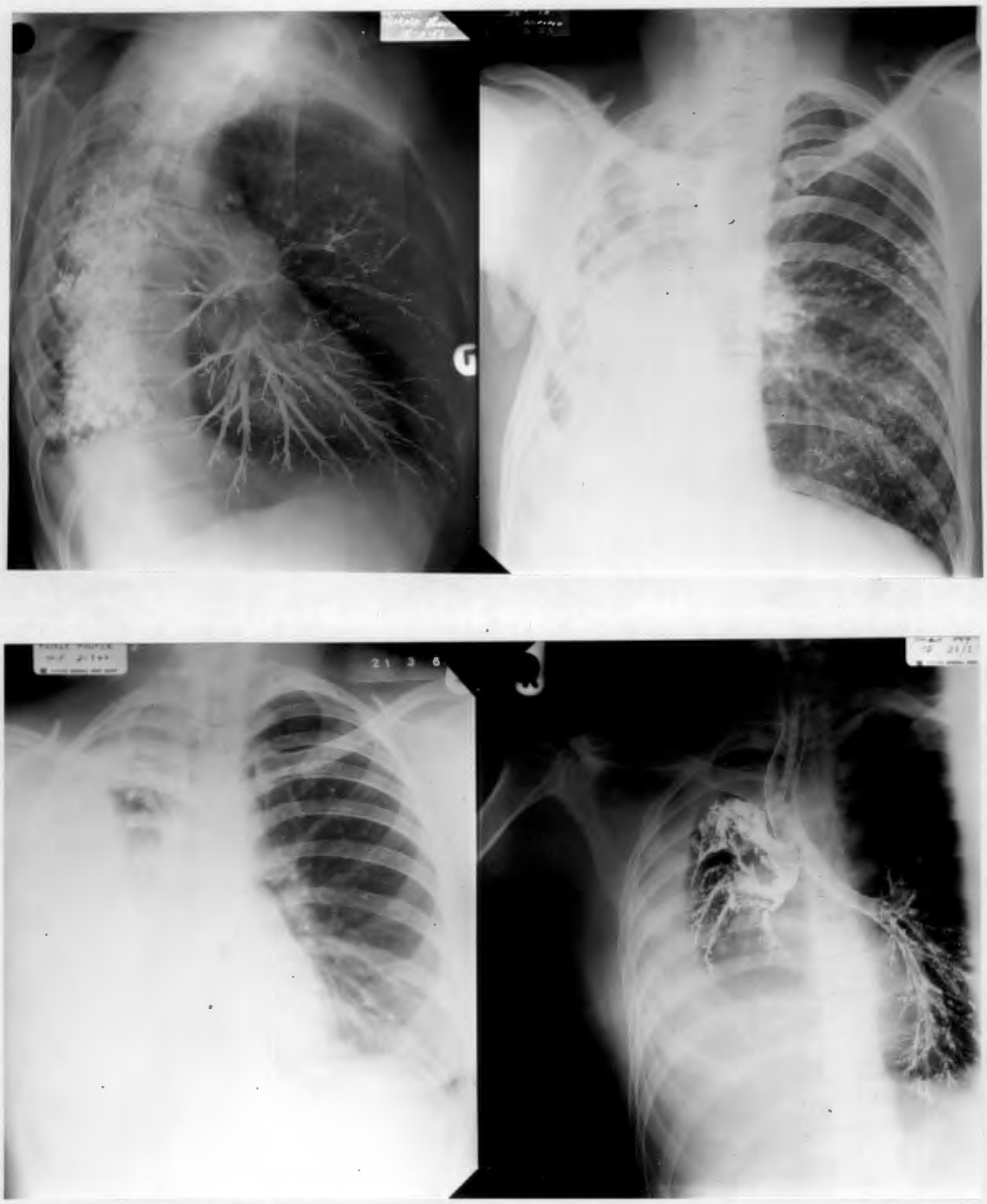

Fig. 52

Total right bronchiectasis shown in the left oblique bronchogram (A) is associated in the patient whose films these are with normal left bronchi. The plain film (B) was made a month after bronchography, immediately before right pneumonectomy, and in it lipiodol residue is clear. Total right bronchiectasis shown in (D) is associated with an empyema, the extent of which is more obvious in the plain film (C); management in the patient whose films these are was by pleuro-pneumonectomy.

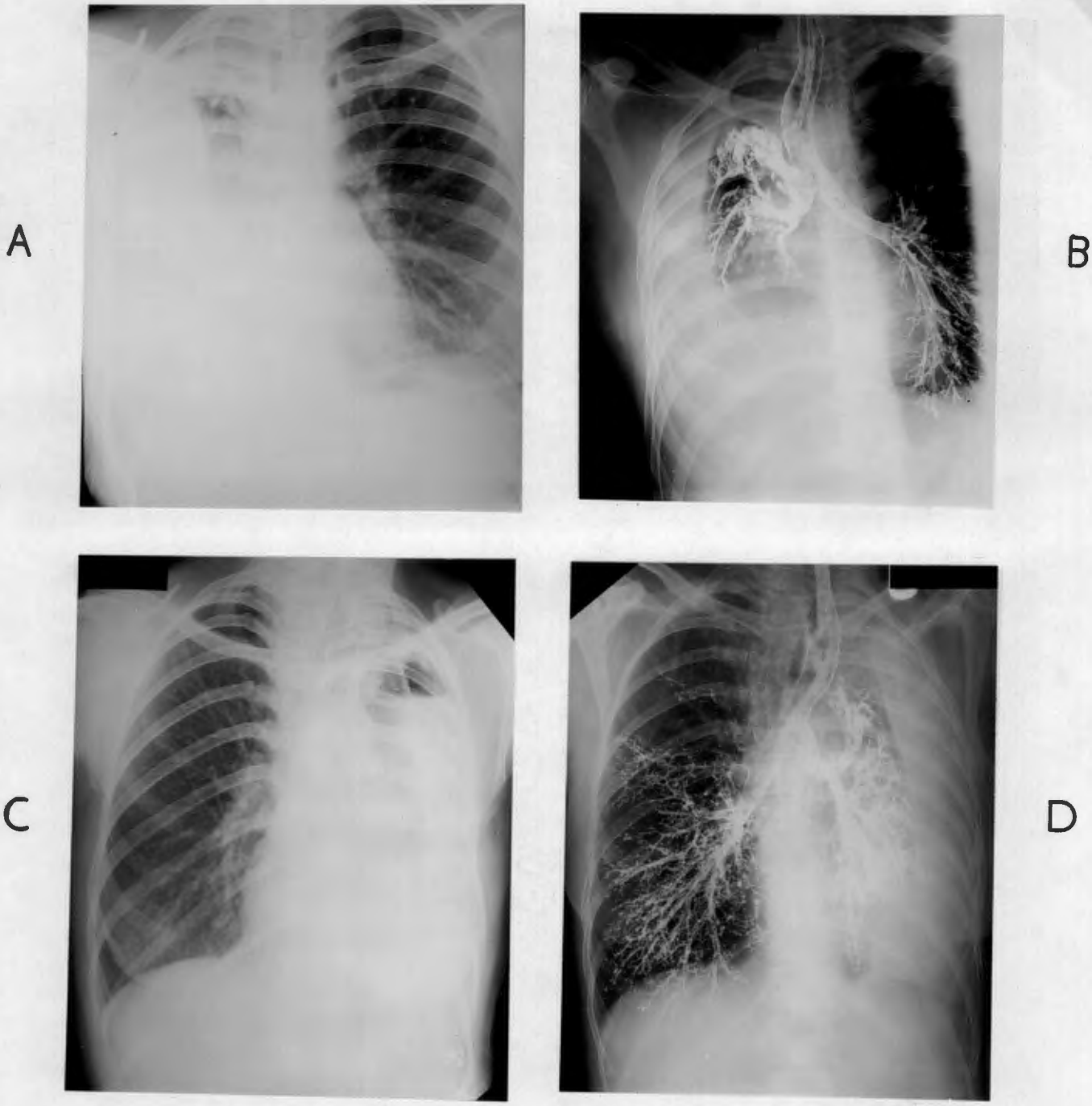

Fig. 53

It is usually possible to distinguish bronchographically between bronchi which are intrinsically normally but distorted by compression from a pleural effusion or empyema (C & D) and those which, similarly distorted, are bronchiectatic (A & B)

Total Unilateral Bronchiectasis Managed Conservatively

In 38 patients total unilateral bronchiectasis or bronchiectasis the extent of which would have demanded pneumonectomy if surgical management had been undertaken, without contralateral bronchiectasis, was managed other than by resection. Details which relate to these patients are shown in Table III. Twelve patients declined management by pneumonectomy; eight of these were under 40 years of age and a further three were in the fifth decade, and these eleven patients were suitable in every way for surgical management of bronchiectasis; a man of 64 was, despite his age, also considered suitable for pneumonectomy. Total left bronchiectasis in one of these 12 patients was associated with stenosis of the left main bronchus and another patient was shown to have total right bronchiectasis after the endoscopic resection of an endo-bronchial chondro-adenoma in the right main bronchus (le Roux, 1964d). This last-mentioned patient has for some years been incarcerated in one of Her Majesty's penitentiaries. Total unilateral bronchiectasis in 11 patients, three of them younger than 40 years, was not resected because each had a respiratory reserve so poor that, even after substantial diminution in the quantity of sputum which they produced, by intensive physiotherapy and appropriate chemotherapy, this was judged inadequate even for thoracotomy, despite the fact that functioning lung would not be resected. Four of these 11 were asthmatic and, while they did not have contralateral bronchiectasis, the contralateral lung was radiographically grossly emphysematous and its bronchi spidery and widely spaced. An elderly man in this group was, on one occasion, found to have sputum which contained tubercle bacilli; this finding was not repeated and a culture was not obtained; he was managed for a prolonged period with anti-tuberculous chemotherapy.

In /

In ten patients, four of them under 40 years of age, total unilateral bronchiectasis was associated with so little in the way of symptoms that it was thought proper to observe them rather than to undertake pulmonary resection. Some of the patients who were submitted to pneumonectomy and who were discussed in the previous section were originally in this group because the severity of their symptoms was not, at first sight, obvious; only these ten still remain in this group, all have been observed for more than four years and six for more than seven years. In four, reference for a surgical opinion followed the recognition of an abnormality on a chest radiograph made for routine purposes. In an elderly man in this group the left main bronchus was stenosed. In respect of this group of patients it might be argued that, since they are well and the bronchiectatic lung is, in each, functionless, they should be submitted to pneumonectomy - to protect them from the general and metastatic effects of infection, and possibly from carcinoma - but since in this group there are none with the clinical evidences of infection and none has purulent sputum, this argument is thought untenable. It remains for only one to develop an empyema or a cerebral abscess, or for the clinical evidences of carcinoma to develop, for this attitude of conservatism to be proved totally unjustified.

Three patients with total unilateral bronchiectasis have died - one from the infective and vascular complications of diabetes the control of which was probably complicated by persisting pulmonary infection, and two, within 18 months of completion of their investigation, with cor pulmonale. In none of these three was resection at any time contemplated because of diminution in respiratory reserve. Two patients, both aged 70 years when first they were referred for a surgical opinion, were not submitted to pulmonary resection on the grounds of age alone.

In/

In one a mutton bone obstructed the left main bronchus, whence it was removed at endoscopy; this patient was unaware of an episode in his earlier life to which the presence of an endo-bronchial foreign body could be related.

Two patients in this group of 38 had a previous history of lung abscess and one of empyema thoracis (managed by open drainage). In none was there evidence of a residual extra-bronchial loculus of pus at the time of their investigation for bronchiectasis.

TABLE III

TOTAL UNILATERAL BRONCHIECTASIS MANAGED CONSERVATIVELY

Reason for not Undertaking Pneumonectomy	Number of Patients	Ages & Sex	Comment
Declined Thoracotomy	12	M.* 31/33/38/46+/64 = 5 F. 17/33/33/36/39/44/45 = 7	*Rt. main bronchus chondroma. +Lt. main bronchus stenosis 11 of 12 under 50 yrs. 8 of 12 under 40 yrs.
Respiratory Reserve Judged Inadequate	11	M. md 31/41+/47a/47+/54a/67* = 6 F. 29/37/45/48+/48+ = 5	*Sputum contained tubero. bacilli +Severe asthma & emphysema a Previous lung abscess md. Mentally defective 3 of 11 under 40 yrs.
Asymptomatic	10	M. md 38/38/61*+ = 3 F. 20*/22+/40*/45*+/52/58*+/61*s = 7	md. Mentally defective * Observed for more than 7 yrs. + MMR finding s Lt.main bronchus stenosis
Died	3	M. 40* = 1 F. 61+/65* = 2	* Cor pulmonale + Diabetic gangrene and infection
Age	2	M. 70*/70+ = 2	* Previous empyema + Retained foreign body in Lt. main bronchus

Ages :

Under 11	- 0
11 to 20	- 2
21 to 30	- 2
31 to 40	- 13
41 to 50	- 10
51 to 60	- 3
61 to 70	- 8

TOTAL - 38 — Males - 17; Females - 21

Youngest - 17 yrs.
Oldest - 70 yrs. (two)

Right - 17
Left - 21

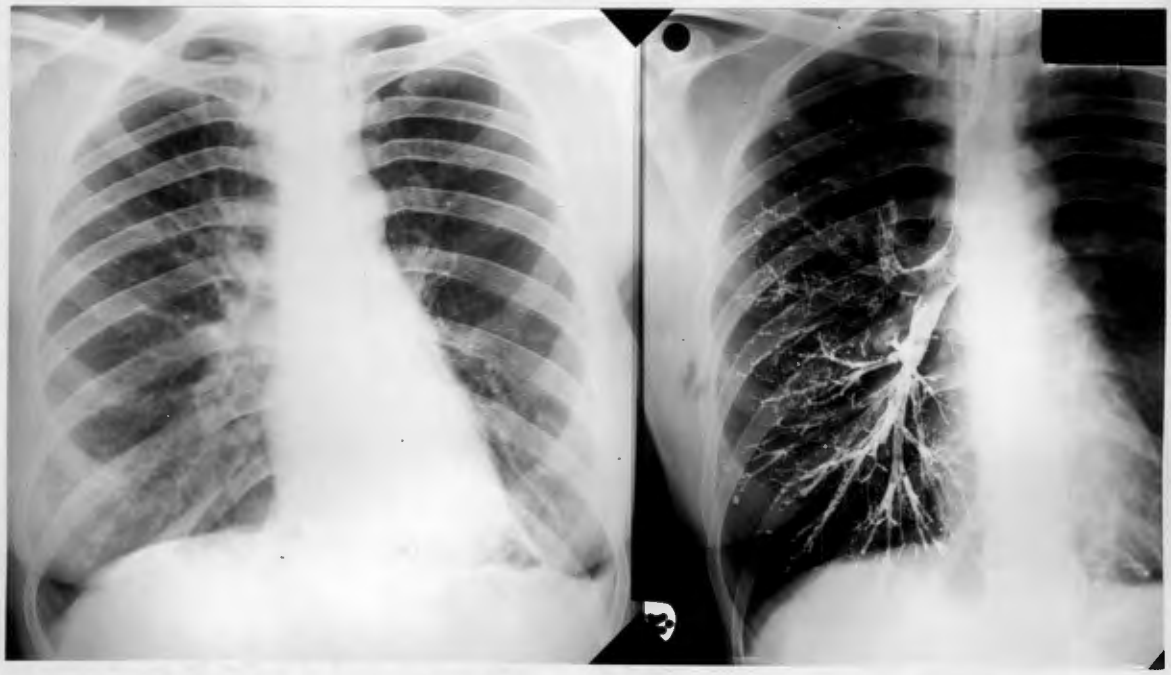

A B

C D

Fig. 54

Total left bronchiectasis in the patient whose films these are was managed conservatively because the only important symptoms were those of bronchospasm and dyspnoea.

A

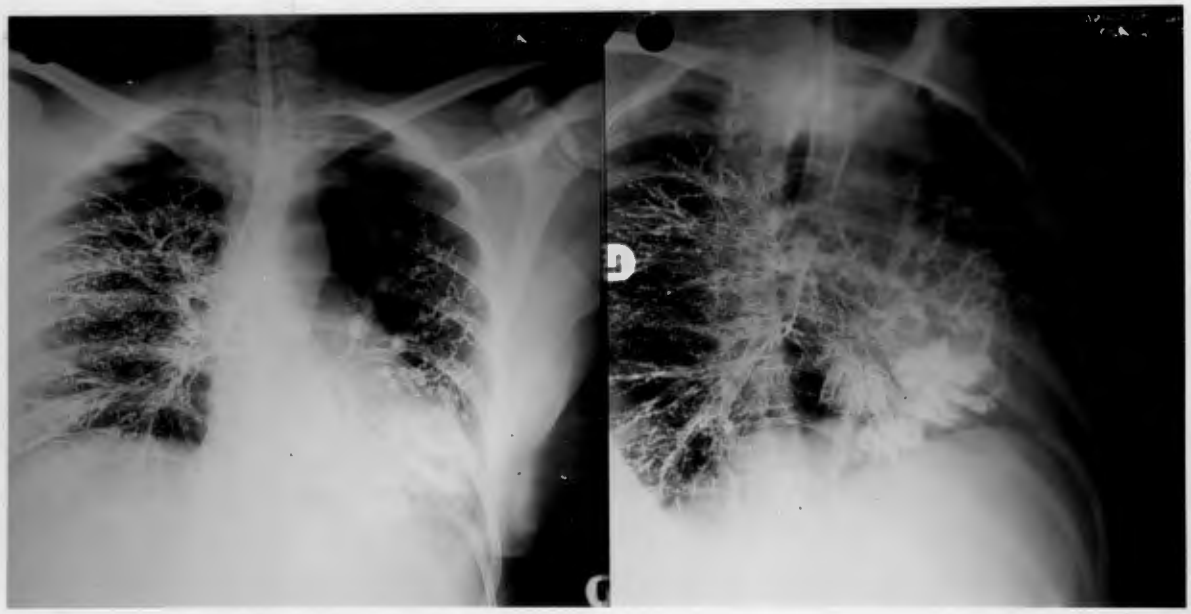

B

C

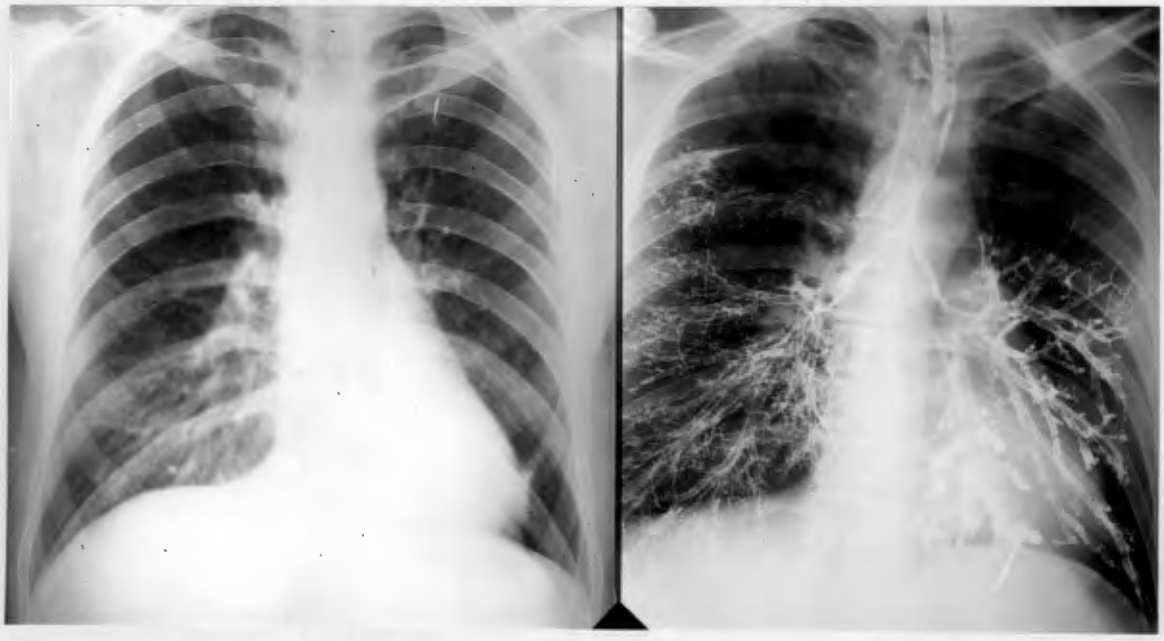

D

Fig. 55

Left bronchiectasis in the two sets of radiographs (A & B) and (C & D) shown above is regarded as total because in each of the patients whose films these are surgical management would involve pneumonectomy. The only segment on the left which may be normal is, in each, the apico-posterior - too small a volume of lung to leave as the only lung in the left hemithorax. Because of lack of symptoms neither patient has been managed surgically.

A B

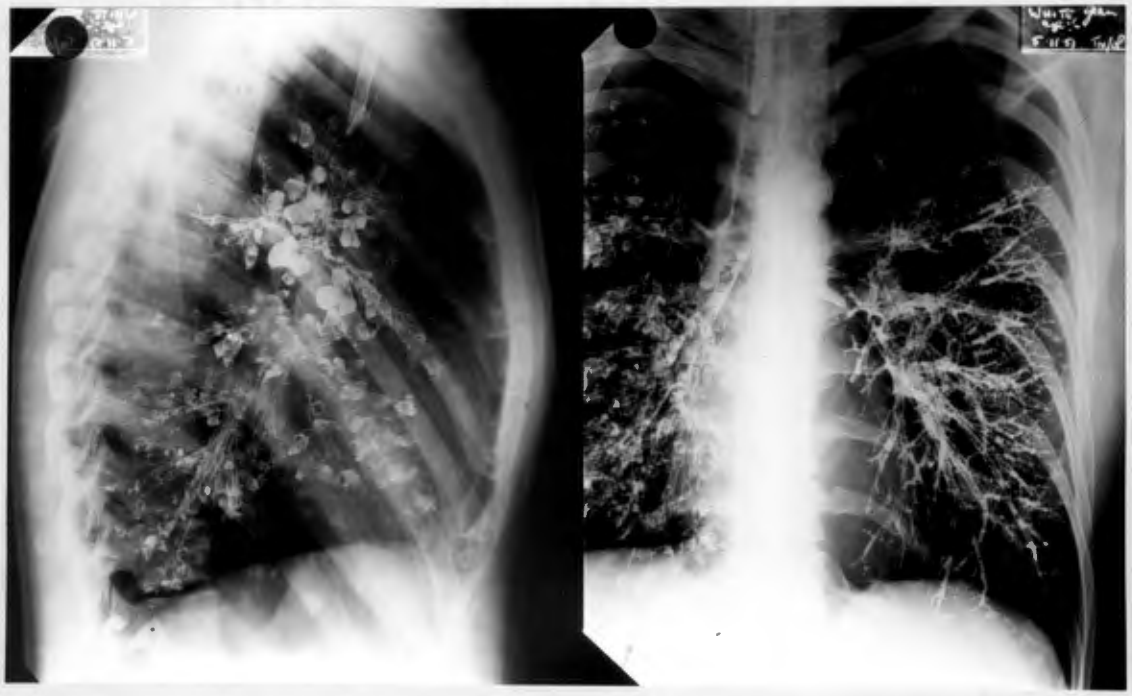

C D

Fig. 56

Total right bronchiectasis in the patient whose films these are has been managed conservatively because of doubt regarding the severity of symptoms. She has been observed for more than ten years and has recently had two episodes of respiratory infection which have been of a severity which suggests the need for more aggressive management of her bronchiectasis.

A

B

C

Fig. 57

In the patient whose films these are detailed investigation was undertaken because a minor respiratory illness had prompted the making of the PA chest film (A). The supracardiac translucency immediately tothe right of the vertebrae is of left lung whichh has herniated to the right across the mediastinum, anteriorly. The bronchograms (B) & (C) show an unusual distribution of bronchiectasis - the right upper and lower lobes and the lateral segment of the middle lobe are shrunken and bronchiectatic. The only normal segment on the right is the medial segment of the middle lobe. Resection of bronchiectasis in this patient would involve pneumonectomy - one segment of the middle lobe is too small a volume of lung to leave alone in a hemithorax since it will not function and will prompte infection - and in this patient paucity of symptoms did not justify resection.

Unilateral Lobar Bronchiectasis Managed by Lobectomy

Unilateral lobectomy without related segmental resection was undertaken in 135 patients - 78 males and 57 females. Details which relate to these patients are shown in Tables IV and V. The left upper lobe was resected in six patients and the left lower lobe in 42. In 18 patients the right upper lobe was resected and in 27 patients the middle lobe; in four, middle and upper lobes together were resected. In seven patients the right lower lobe was resected and in 31 the middle and lower lobes together. About half the total number of lobectomies were undertaken in the four year period 1953 - 1956. An average of five lobectomies each year were undertaken before and after this period.

In this group of 135 patients the youngest was a boy of two years and six patients - three men and three women whose ages ranged from 61 to 64 years - were the eldest. Sixteen patients were ten years of age or younger at the time of lobectomy, 25 were in the second decade, 25 in the third and 34 in the fourth - i.e. three-quarters of the patients submitted to lobectomy were 40 years of age or younger.

In 87 patients lobectomy was right-sided and in 48 left-sided, a right-sided preponderance which is to be anticipated since on the right there are three lobes available for resection and it is only on the right that two lobes together can be resected. In the evaluation of statistics which relate to the surgical management of bronchiectasis it is common to equate the middle lobe with the lingular segment of the left upper lobe, since their bulk is similar and the transverse fissure often incomplete, and to equate middle and lower lobectomy on the right with linguleotomy and lower lobectomy on the left. In the series of resections/

resections for bronchiectasis under review 27 middle lobectomies can be compared with 16 lingulectomies, and 31 right middle and lower lobectomies with 64 lingulectomies and left lower lobectomies, so that, as with pneumonectomy, there is a preponderance on the left of bronchiectasis which requires "lobar" resection.

Two women are known to have died - one in a car accident four years after resection and one from coronary thrombosis 11 years after resection - and two patients cannot now be traced. There was no operative death in this group.

Post-operative bronchograms were made in all but nine patients. Two of these were mentally defective; in them resection was undertaken to facilitate institutional care, which it did. Six of these nine patients were older than 50 years, three of them older than 60, at the time of resection. Of these six, resection in three was for a peripheral pulmonary shadow which persisted in serial radiographs, and which was managed as if it were a carcinoma - by thoracotomy; in these three cases a pre-operative bronchogram was not made, and the diagnosis of lobar bronchiectasis arrived at by bronchography of the resected lobe and the histologist's report. In one patient bronchiectasis was related to the long retention of a foreign body and in another the histological features of tuberculosis were demonstrated in the resected specimen. In a woman of 45 years bronchiectasis was demonstrated after severe pulmonary infection which complicated a gynaecological operation, before which she had not experienced respiratory symptoms. In all but the last of these nine, therefore, age or mental state alone made routine post-operative bronchography in the absence of symptoms difficult to justify.

There is residual bronchiectasis in nine patients. In one of these left lower ~~lower~~ lobectomy was undertaken as part of a planned bilateral procedure which was to include middle and lower lobectomy on the right. The patient was unaware of a change /

change in symptoms after left lower lobectomy - of this likelihood she had been warned - and was in any event disenchanted with thoracic surgery and declined further to submit to resection. She attends occasionally for review and still has symptoms of cough and sputum. Left lower lobectomy was undertaken in two patients in the knowledge that there was right basal bronchiectasis. The left lower lobe in both was shrunken and bronchial dilatation saccular and gross; the right basal bronchiectasis was cylindrical, bronchographically unimpressive, and the subtended segments occupied a normal volume of the hemithorax; and muco-pus was seen at bronchoscopy to re-accumulate only from the left basal bronchi. In these two patients left-sided resection was undertaken in the belief that symptomatic relief would follow, and with the hope that a right-sided resection would not be necessary, but in the knowledge that, should symptoms persist, the right-sided bronchiectasis was within the limits of resectability; in them, the resection of a "sump" was successful in that symptoms were relieved. In two patients an ipsilateral bronchus, in each instance the lower half of the lingular segment, was shown to be bronchographically abnormal after left lower lobectomy. When post-operative bronchograms were compared with pre-operative films in these patients it was abundantly clear that the lingular bronchus had been accepted as normal pre-operatively where in fact its demonstration was inadequate. Bronchiectasis in these patients had not "extended", it had simply not previously been recognised. One of these patients, in whom lobectomy was associated with decortication of an empyema, was symptomless 13 years after resection, and the other, now married and with two children, is well nine years after lobectomy. Contra-lateral bronchiectasis of a segment or subsegment was demonstrated on post-operative bronchograms in three patients, in all of whom the abnormal bronchi were, in retrospect,/

retrospect, inadequately shown on pre-operative films; since the patients have been relieved of symptoms by resection of a grossly abnormal lobe, no further surgical action has been taken.

In 1955 a two-year-old boy was submitted to right upper lobectomy because he had suffered for eighteen months from recurring severe respiratory infections, produced purulent sputum in large volumes and, on rather indifferent bronchograms, had gross saccular bronchiectasis of the right upper lobe. Resection in this boy was undertaken at an unusually early age because of the unusual severity of his symptoms. The boy was made well and symptom-free by lobectomy, and he remains so, but by recent, routine, post-operative bronchography he has been shown to have bronchiectasis of the middle lobe and of the lingular segment of the left upper lobe. Comparison between a bronchogram made at the age of two years and one made at the age of 11 is difficult, but the middle and lingular bronchi were almost certainly abnormal at the time of upper lobectomy; the surgical action taken in this instance has been justified by the outcome despite inadequate premises.

Regarding cause, bronchiectasis managed by lobectomy was, in five patients, related to a previous history of a destructive pulmonary infection - in one a lung abscess, in one Friedlander's pneumonia and in three an unspecified destructive or suppurative pneumonia. In seven patients the lobar bronchus which subtended the bronchiectatic lobe was proximally stenosed, in four patients the histological features of tuberculosis were demonstrated in the resected lobe, and in one patient there was both a stenosis of the bronchus and tuberculosis in the resected lobe. The intermediate and middle bronchi were the most common sites for stenosis. In four patients bronchiectasis was associated with a broncholith; in all four bronchiectasis/

bronchiectasis was middle lobar and in one of the four bouginage of the middle bronchus at bronchoscopy precipitated brisk haemoptysis. Bronchiectasis in two patients was associated with the long retention of a foreign body and in two others was associated with symptoms which followed, in one, a gynaecological operation and, in the other, tonsillectomy. A large oesophageal diverticulum may have been responsible, because of spill from it, for bronchial obstruction and infection in one patient and in another there was a congenital fistula from the oesophagus to the right lower bronchus.

Severe haemoptysis prompted investigation in 10 patients, six of whom were shown to have upper lobar bronchiectasis (right-sided in five) and four of whom were shown to have middle lobar bronchiectasis. One patient with bronchiectasis of the middle lobe had situs inversus, but did not have an abnormality of the frontal or para-nasal sinuses. In six patients an empyema co-existed with bronchiectasis and both lesions were managed at the same operation; in one patient an empyema had been drained many years before lobectomy and of its previous existence there was very little residual evidence. Empyema complicated lobectomy in five patients, in four after upper lobectomy, and in two of these four open drainage was followed by closure of the apical pleural space which was so slow that a small thoracoplasty was made. Membranous laryngo-tracheitis complicated lobectomy in one child but in the management of this a tracheostomy was not required.

One patient developed a squamous carcinoma of the oesophagus seven years after middle lobectomy; the oesophageal tumour was resected through a left thoracotomy and he is well. Right upper lobectomy in 1952 in another patient was followed in 1963 by the development of a left spontaneous pneumothorax in the investigation/

investigation of which he was shown to have a left lower squamous carcinoma of central type. Management was by irradiation because of oesophageal displacement presumed to be from mediastinal glandular metastasis, and at the present time his general state is deteriorating although clinical evidence of metastasis cannot be adduced. This patient is one of seven who, from about 4,000 cases of pulmonary carcinoma and about 350 cases of spontaneous pneumothorax, presented with a pneumothorax and were later shown to have a related bronchial carcinoma. One patient submitted to middle and lower lobectomy is emphysematous and at yearly review has a measured diminution of respiratory reserve and two others submitted to a resection of similar extent have episodes of bronchitis each winter, but are generally well. Of the 135 patients submitted to lobectomy for bronchiectasis all but 11 are well and symptom-free and lead a normal life; three adult males have been accepted for Army Service and four of the female patients are now married and have between them seven children. The 11 patients who are exceptional include two who have died from an unrelated cause but who were relieved of symptoms by the resection undertaken, two who are mentally defective but whose institutional care has been facilitated by surgical management of bronchiectasis, two who cannot now be traced, one with bronchial carcinoma, one who declined the second of two planned resections, one with increasing dyspnoea from emphysema and two with recurring mild bronchitis. Eight others with residual bronchiectasis are well.

TABLE IV

UNILATERAL LOBAR BRONCHIECTASIS MANAGED BY RESECTION

ONE LOBE ONLY

RIGHT

Upper Lobe (18)

Males (Ages)	Females (Ages)
2*: 25: 30: 30: 34	14: 24: 27: 33
35: 35: 35: 35: 51	40: 48 Total 6
58: 62 Total 12	

No. of Resections per Year

1947 - 1
1950 - 1
1952 - 2
1953 - 3
1955 - 2
1956 - 6
1957 - 1
1959 - 1
1961 - 1

Middle Lobe (27)

7: 9: 10: 16: 17	9: 13: 16: 19
26: 33: 34: 35: 41	23: 28*: 30: 31
43: 44: 47: 58	32: 34: 35: 36: 51
Total 14	Total 13

1949 - 1
1953 - 7
1954 - 3
1955 - 2
1956 - 7
1957 - 2
1958 - 3
1962 - 1
1963 - 1

Lower Lobe (7)

20: 23: 32: 45: 50	38
60 Total 6	

1947 - 1
1949 - 1
1952 - 1
1954 - 1
1958 - 2
1960 - 1

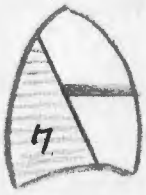

LEFT

Upper Lobe (6)

Males (Ages)	Females (Ages)
15: 54	4: 38: 41: 52•
Total 2	Total 4

1951 - 1
1953 - 1
1954 - 1
1956 - 1
1958 - 1
1962 - 1

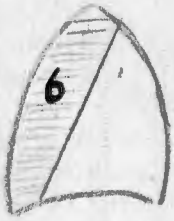

Lower Lobe (42)

5: 8: 8: 9: 10	5: 6: 9: 15*
10: 13: 16: 17	17*: 17*: 18: 25
17: 19: 19: 23*	26: 26: 27: 27: 28
32*: 34: 37: 40	29*: 30: 33: 33: 39
50: 54: 63	45: 47: 52: 64•
Total 20	Total 22

1947 - 6
1948 - 2
1949 - 1
1950 - 1
1951 - 3
1952 - 2
1953 - 5
1954 - 5
1955 - 5
1956 - 2
1957 - 2
1958 - 3
1959 - 2
1961 - 1
1962 - 1
1963 - 1

* Residual Bronchiectasis (8)
• Late Death (2)

TABLE V

UNILATERAL LOBAR BRONCHIECTASIS MANAGED BY RESECTION

TWO RIGHT-SIDED LOBES

MIDDLE & LOWER LOBECTOMY 31		MIDDLE & UPPER LOBECTOMY 4	
Males (Ages)	Females (Ages)	Males (Ages)	Females (Ages)
11: 13: 14: 15: 15	6: 19: 23: 31: 34	29: 38: 39: 47	
20: 21: 23: 27: 28	37: 38: 40*: 51: 61	Total 4	
33: 37: 43: 44: 46	63		
48: 52: 56: 59: 61	Total 11		
Total 20			
1949 - 1	1956 - 4	1950 - 2	
1950 - 3	1957 - 2	1955 - 1	
1951 - 4	1958 - 1	1957 - 1	
1952 - 1	1959 - 4		
1953 - 3	1961 - 1		
1954 - 2	1963 - 1		
1955 - 4			

* Resected Bronchiectasis (1)

A

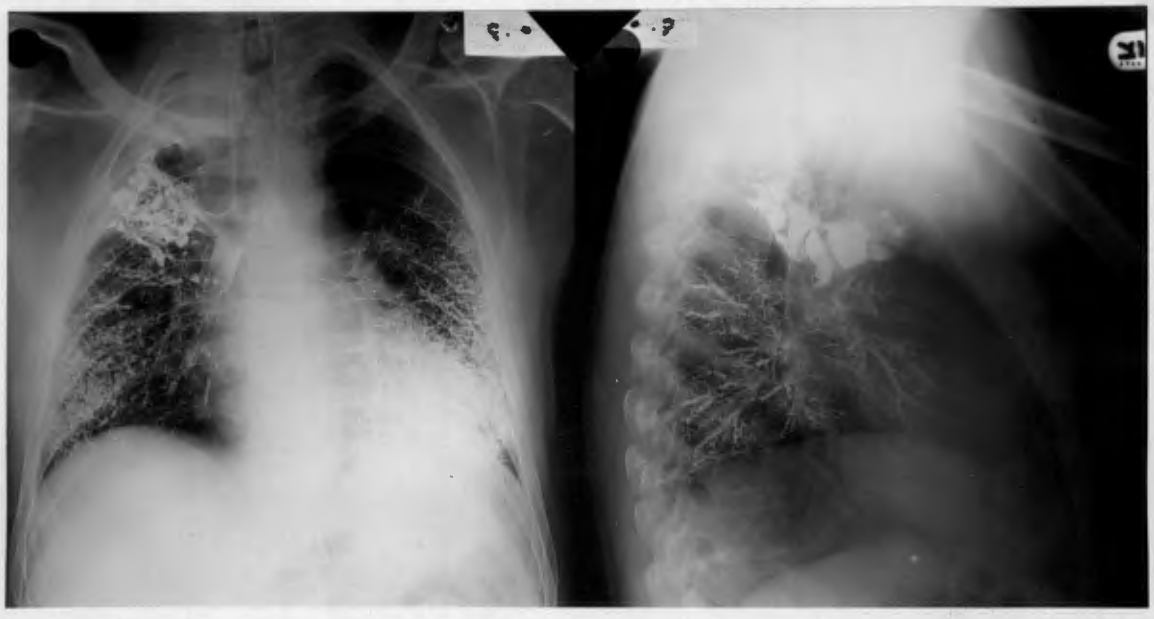

B

C

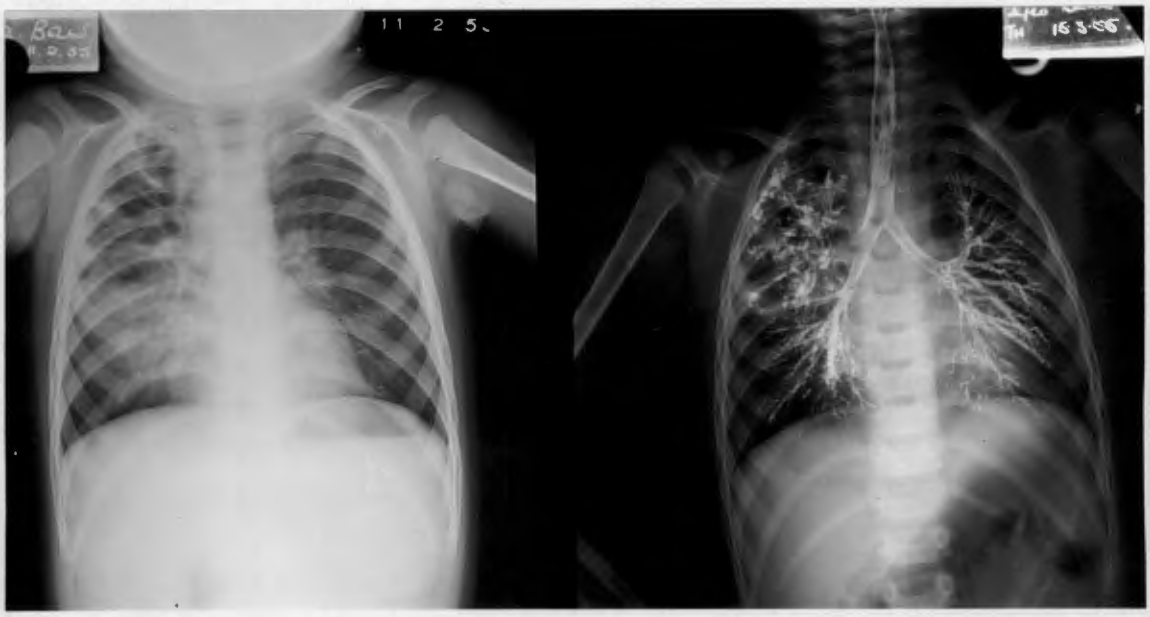

D

Fig. 58

Right upper lobar bronchiectasis demonstrated in two patients whose radiographs are (A & B) and (C & D), some months after clinically complete recovery from a destructive pneumonia. Symptoms in each necessitated, after prolonged observation, upper lobectomy.

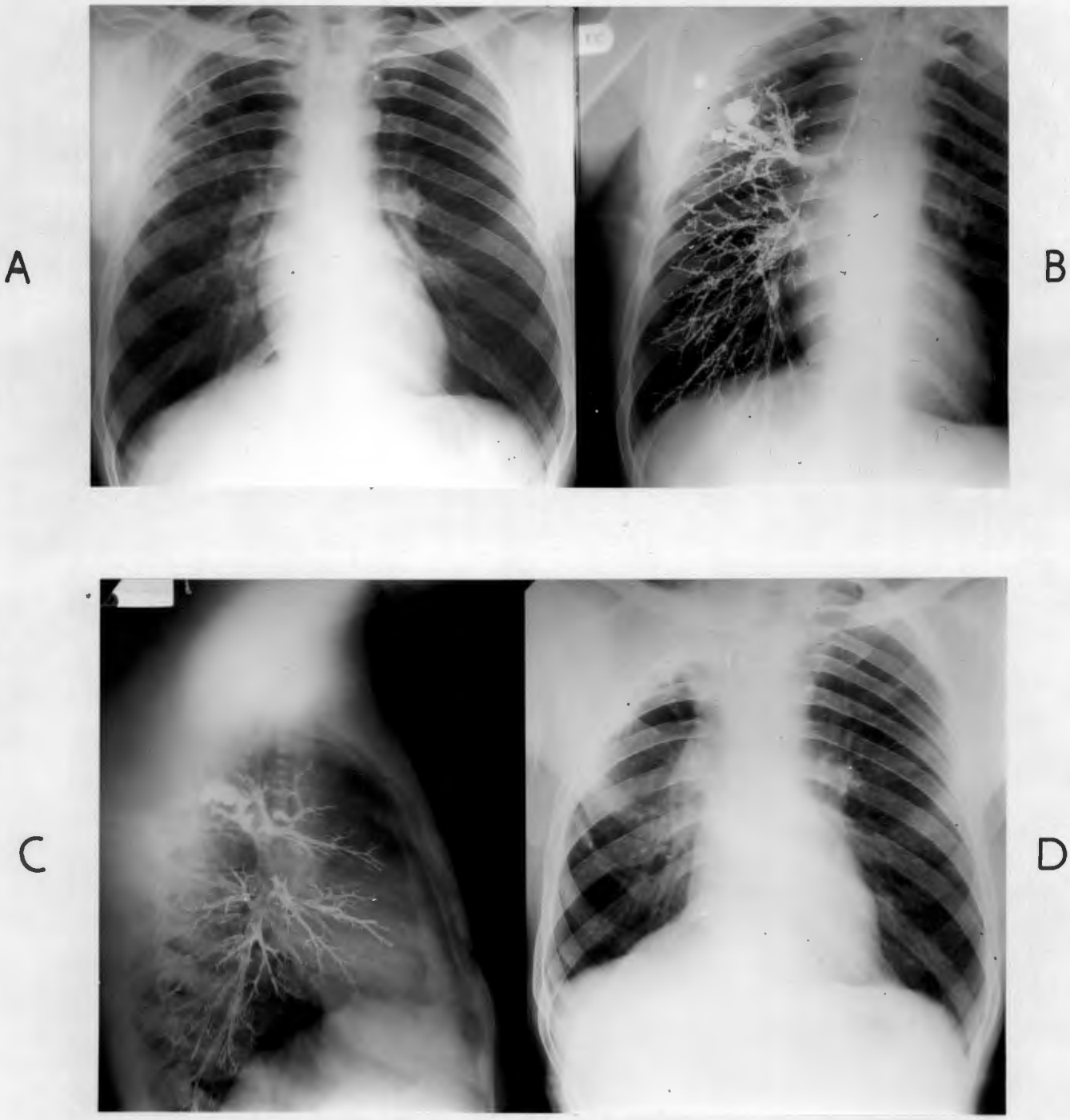

Fig. 59

Right upper lobar bronchiectasis (B & C) was managed in the patient whose films these are by upper lobectomy. An apical empyema complicated thoracotomy and demanded final closure by thoracoplasty (D). Bronchiectasis is called for convenience right upper lobar in this patient because the only normal bronchus shown in the right upper lobe serves only a small part of the anterior segment (C). In the pre-operative plain film (A) the right upper zone can be seen to be abnormal; the cystic spaces shown in this film fill with contrast medium in (B). Haemoptysis prompted investigation.

A

B

Fig. 60

Recovery from a pneumonic illness in the patient whose films these are was slow and the right upper lobe remained partially opaque and shrunken (A). The bronchoscopic appearances were normal; haemoptysis became an obtrusive symptom; the right upper lobe was then shown to be bronchiectatic (B) and was resected. Shrinkage of the upper lobe has been associated with displacement of the middle and lower bronchi which allows of unusually clear recognition of these in the AP bronchogram.

A

B

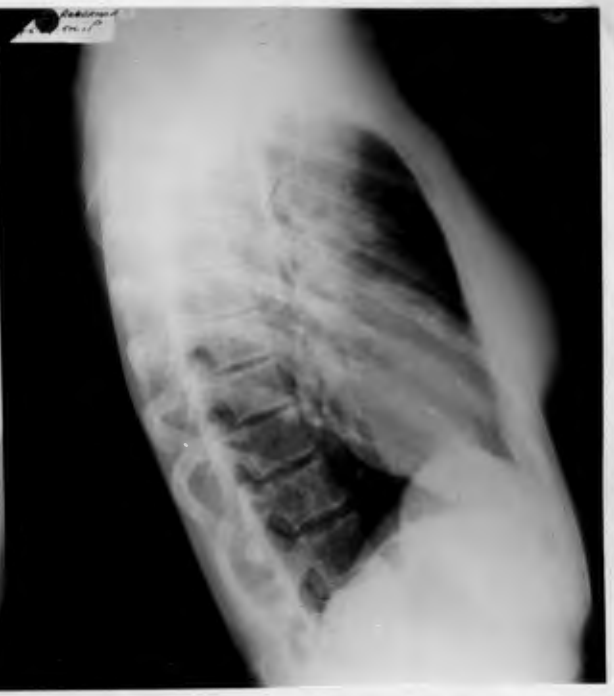

C

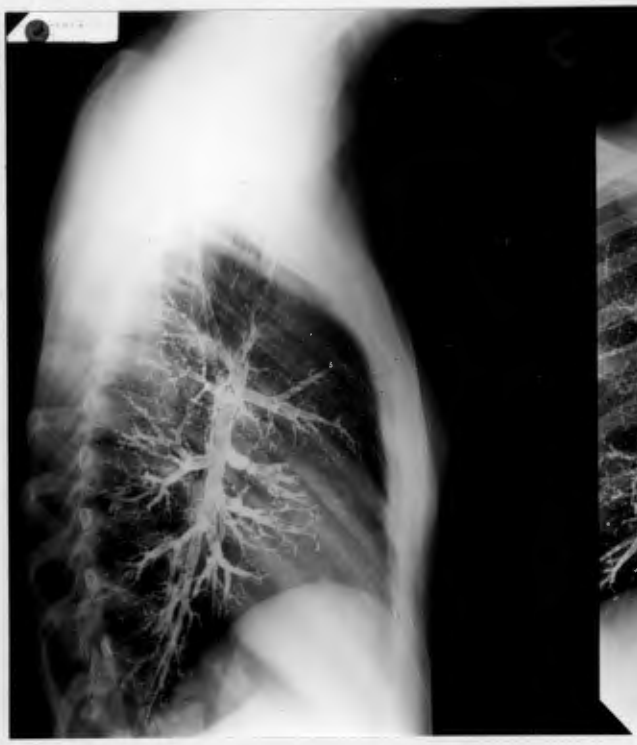

D

Fig. 61

In the patient whose films these are middle lobar bronchiectasis (C & D) was related to a broncholith. Severe haemoptysis had prompted investigation. The appearance of a bronchial stricture in the lateral bronchogram (C) was not confirmed by examination of the resected specimen.

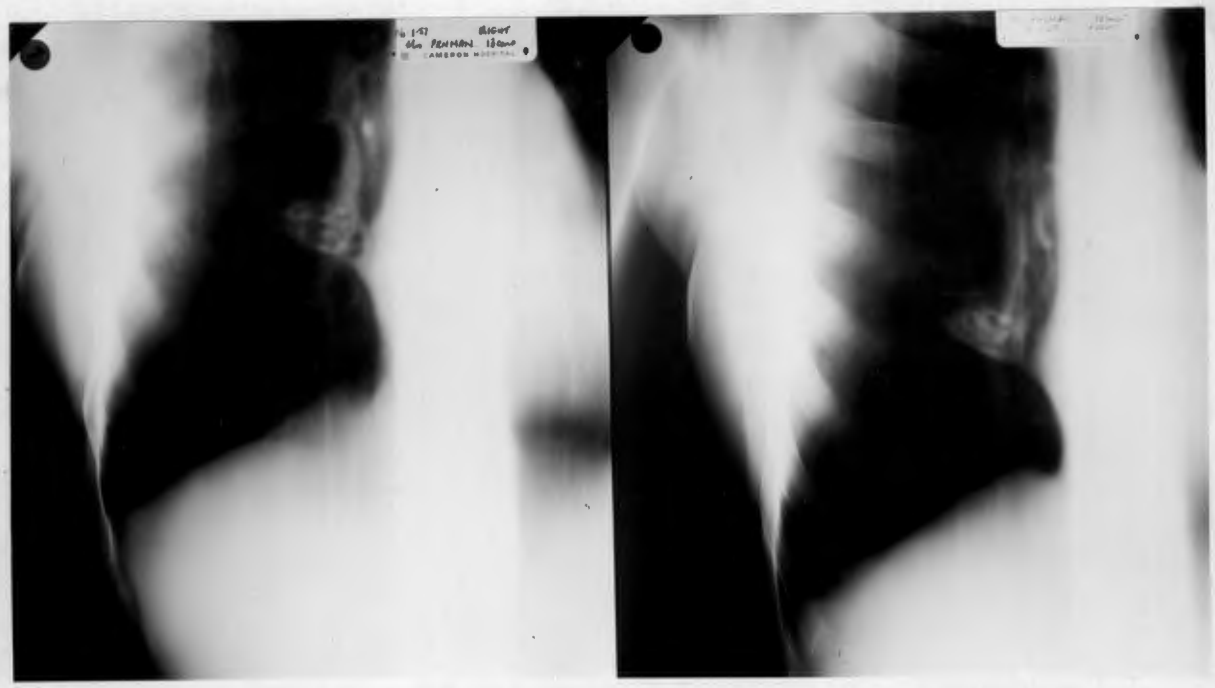

A B

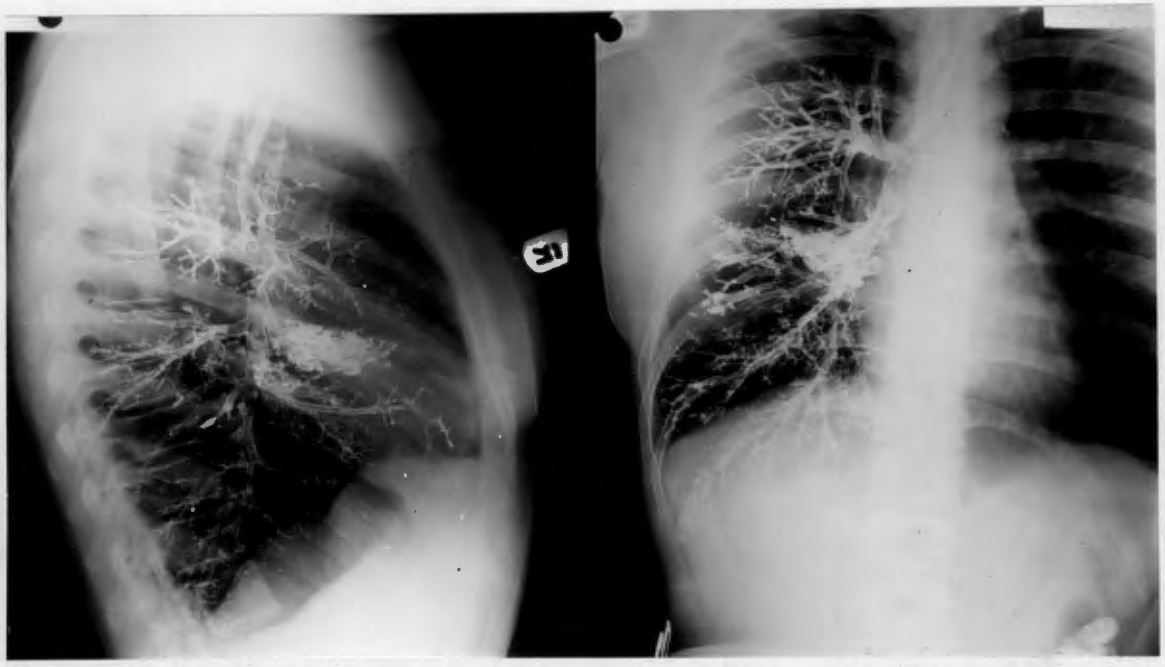

C D

Fig. 62

Bronchiectasis of the middle lobe in a patient in whom the resected lobe was shown histologically to be tuberculous. Pre-operative sputum examination, including culture, had not been informative. The tomographic cuts (A & B) show well the shrunken middle lobe and the cystic spaces within it, outlined by contrast medium in the bronchograms (C & D).

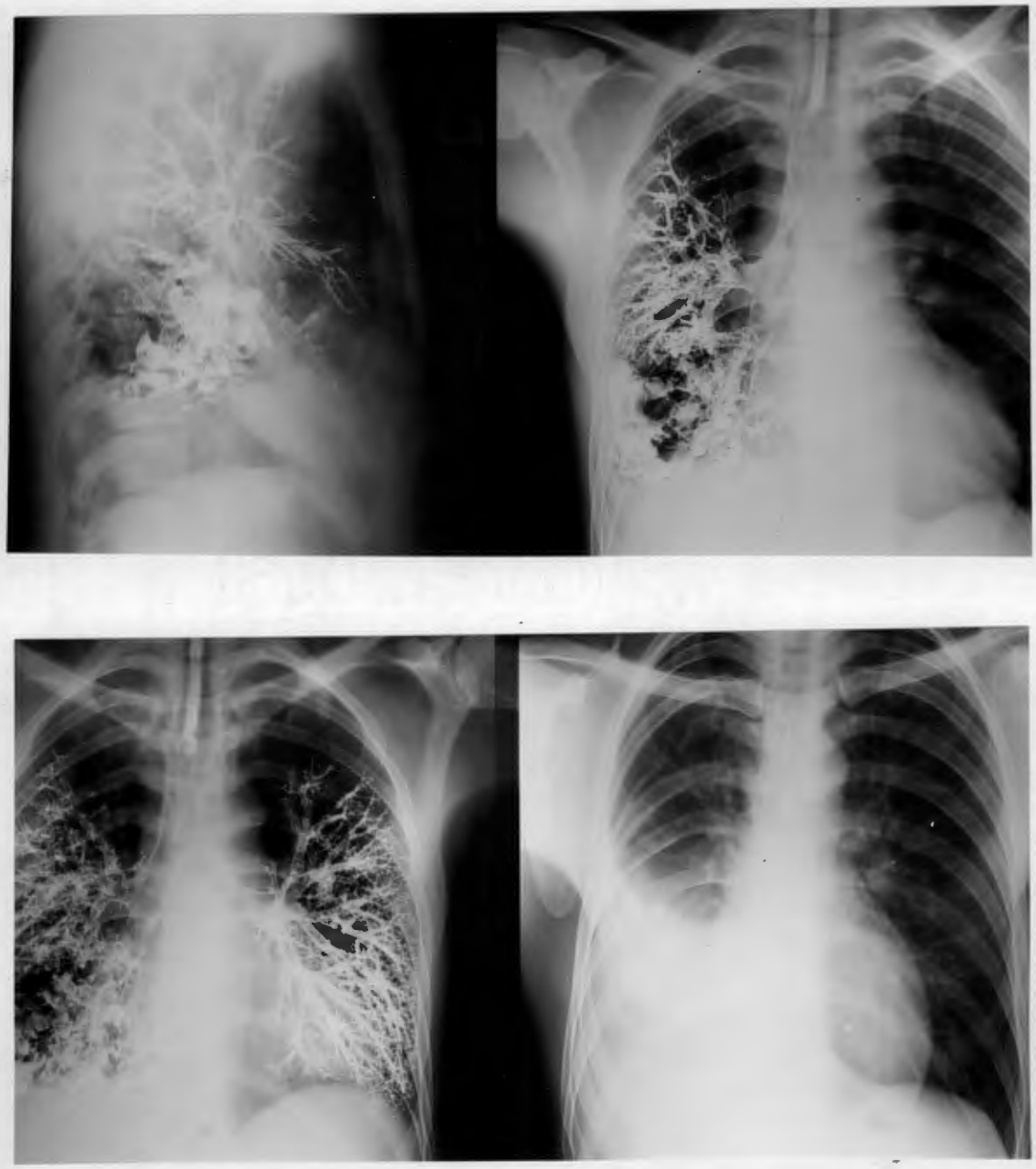

Fig. 63

Bronchiectasis of the middle and lower lobes on the right is, in the films (A), (B) & (C), obvious and gross. Symptoms, in the patient whose films these are, were relieved by middle and lower lobectomy. A post-operative PA chest radiograph (D) is shown. Post-operative bronchograms showed part of the left posterior basal segment to be abnormal and this bronchus, which originates nearest the vertebrae immediately caudal to the left apical lower bronchus, is inadequately filled and probably abnormal in the film (C). This is an example of hindsight in the recognition of bronchographic inadequacies, not of spread of bronchiectasis.

A

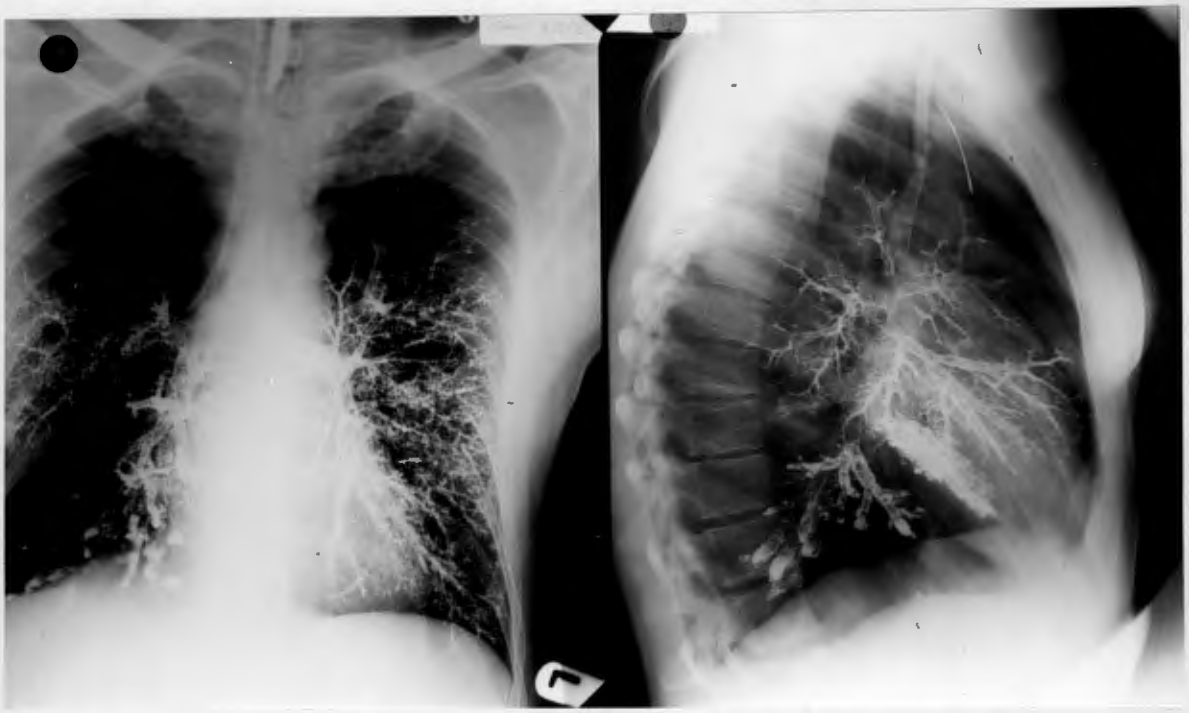

B

C

D

Fig. 64

Examples of bronchiectasis of the middle and lower lobes in two different patients whose bronchograms are (A & B) and (C & D); bronchiectasis in each was managed by resection.

A B

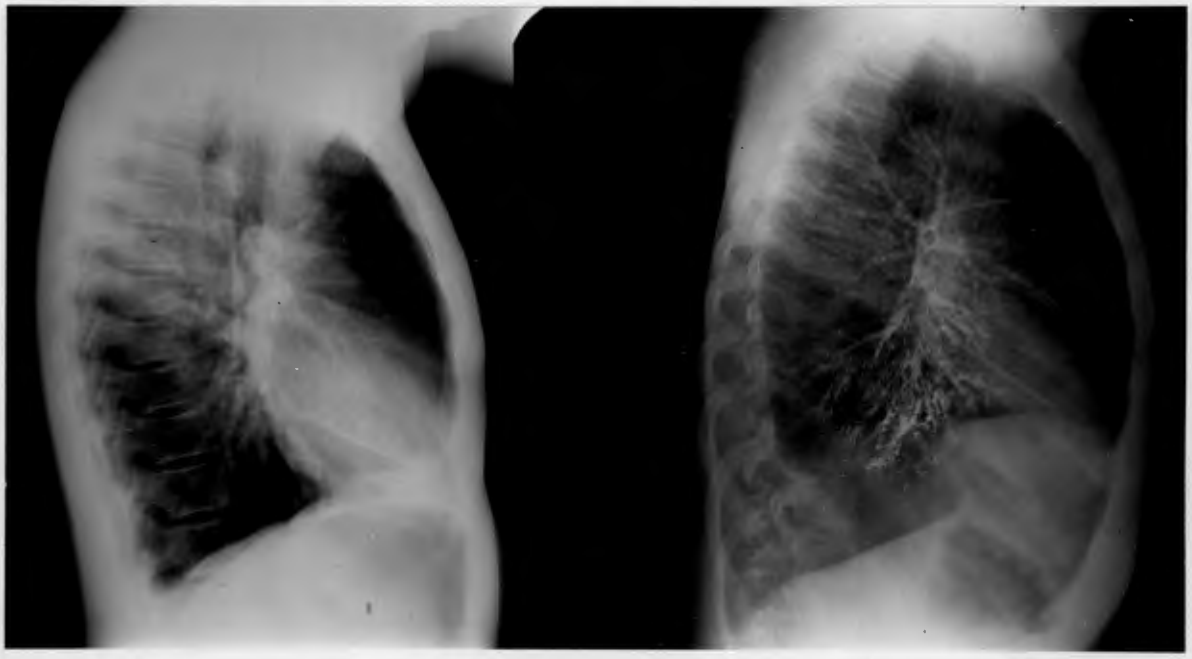

C D

Fig. 65

The middle and lower lobes are shrunken in this set of radiographs and, in the patient whose films these are, had been known to remain so for 3 years. The bronchiectasis demonstrated in these shrunken lobes, while unequivocal, is not bronchographically gross, and yet the severity of symptoms attributable to bronchiectasis left no doubt regarding the need for management by resection. There need by little correlation between the extent of bronchial dilatation demonstrated bronchographically and the severity of symptoms.

A

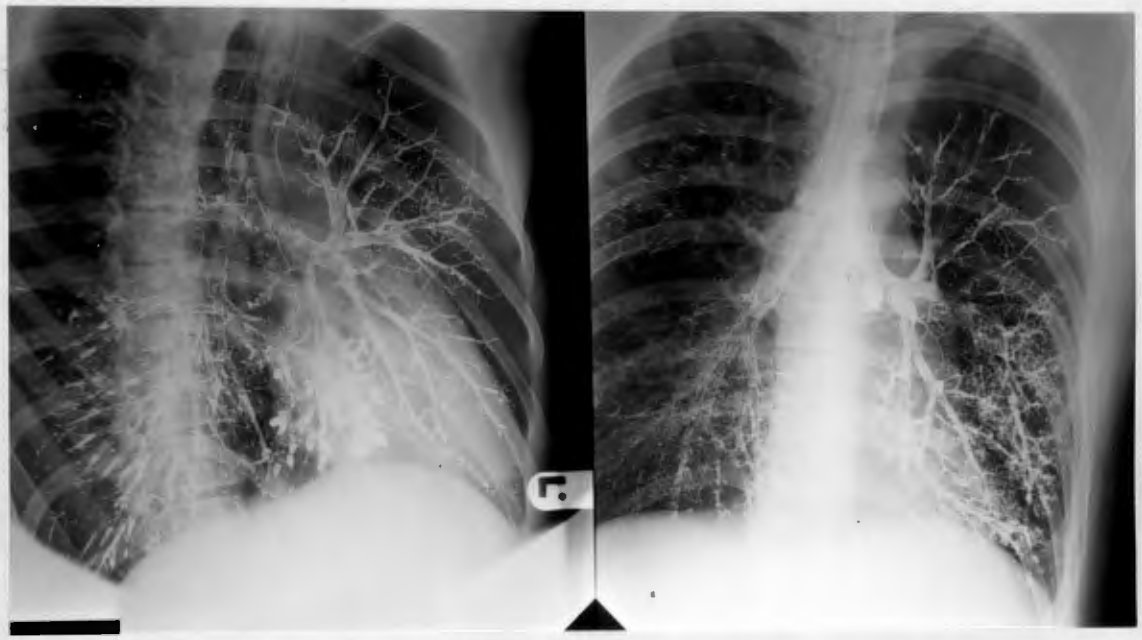

B

C

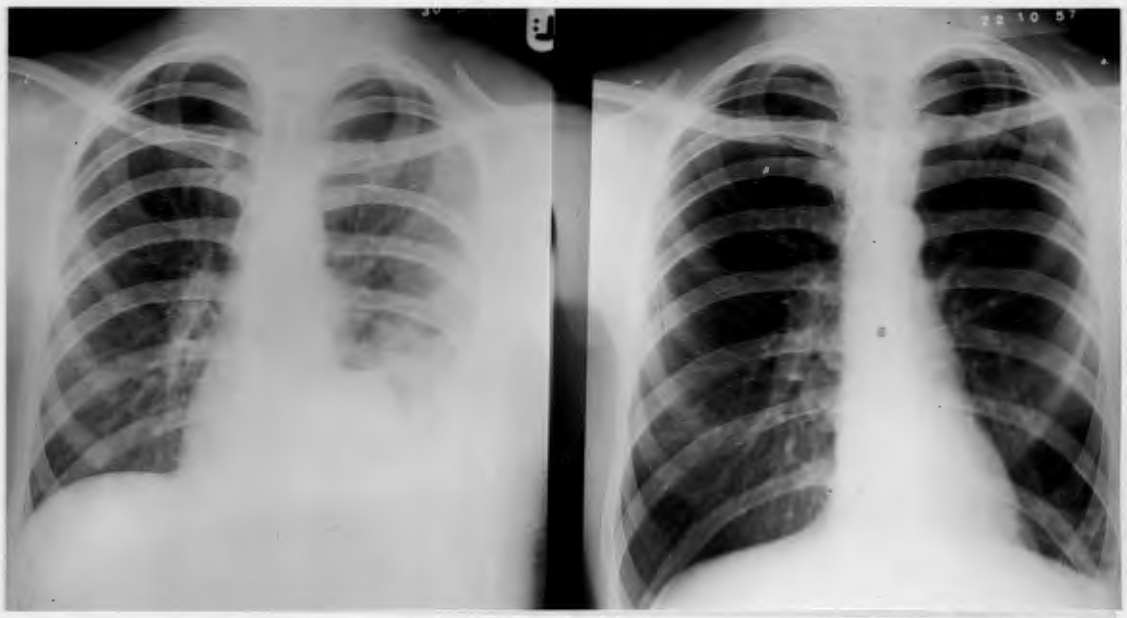

D

Fig. 66

Left lower lobar bronchiectasis (A) was managed in the patient whose films this is by lobectomy; (B) is a post-operative bronchogram. The peaked shadow against the left heart border is that of a pleural effusion, which often has a shape similar to this after left lower lobectomy (C). Regeneration of the resected 5th. left rib is clear in the PA film (D) made 2½ years after the pulmonary resection.

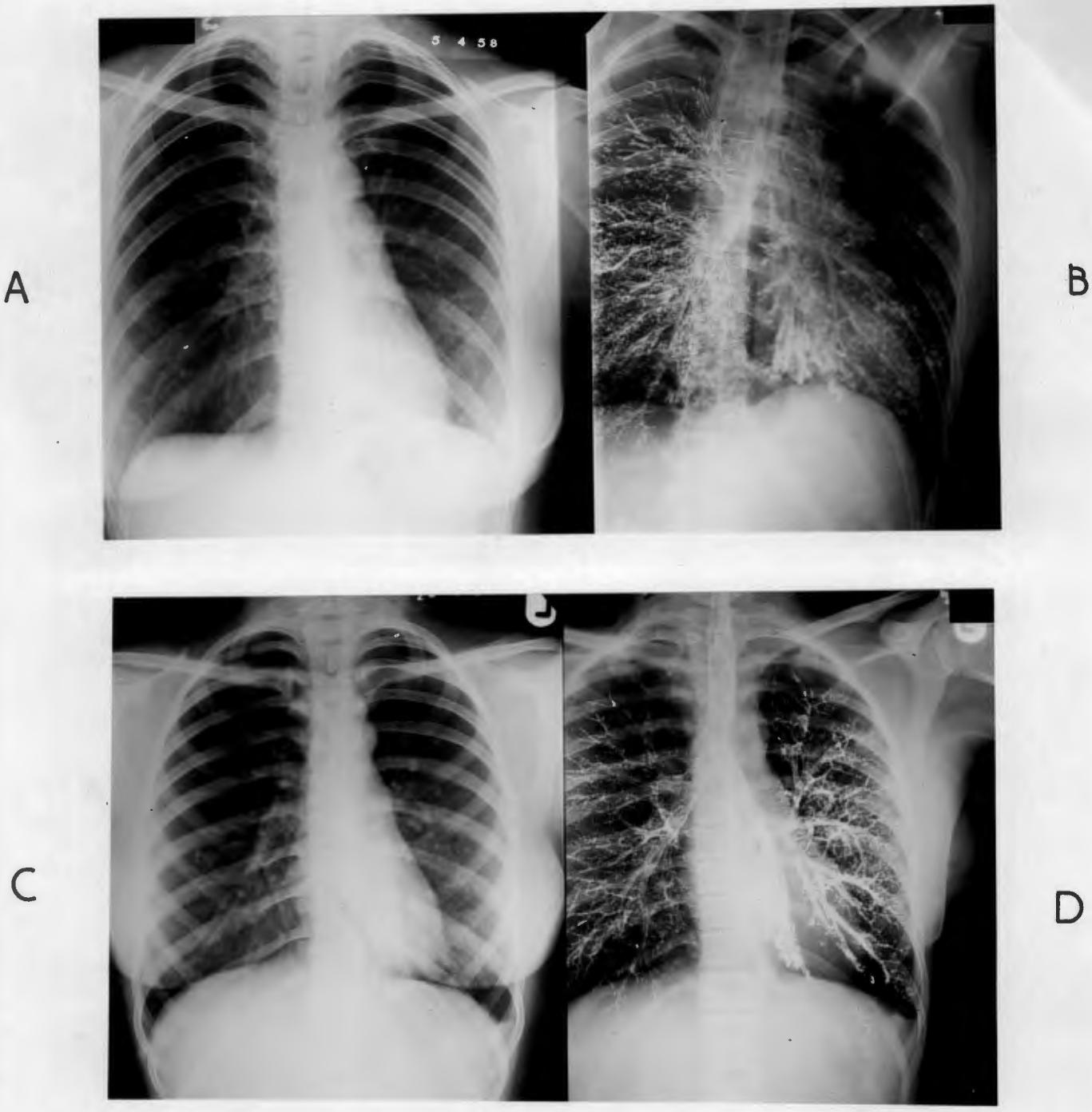

Fig. 67

Bronchiectasis of the left lower lobe is clear in the bronchograms (B) & (D) - of two different patients whose corresponding PA radiographs (A) & (C) are shown. In (D) the lower lobe is very small and an abnormality of a subsegment of lingula - one limb of the "cleft stic -is clear. There is in the bronchogram (B) a similar lingular abnormality, here obscured by the basal bronchi. It is in circumstances such as this that lobectomy alone may be undertaken and the lingular bronchiectasis be recognised for the first time on post-operative bronchograms and only then, retrospectively, on pre-operative films.

Unilateral Lobar Bronchiectasis Managed Conservatively

In 172 patients unilateral lobar bronchiectasis was managed conservatively. Details which relate to these patients are shown in Table VI. More than two-thirds of the patients in this group were males and the lobes most commonly shown to be bronchiectatic were the middle lobe on the right and the lower lobe on the left which, together, account again for nearly two-thirds of the cases.

In this group 67 patients (39%) were over 50 years of age when first they were seen and 11 of these had asthma in addition to other respiratory symptoms; age alone, or age in conjunction with a history of asthma, prompted conservative management in these. Six patients, all younger than 40 years, three of them with bronchiectasis of a shrunken left lower lobe and one with a bronchiectatic and shrunken right middle and lower lobe - these four pre-eminently suitable for surgical management - declined operation. Thirteen patients under the age of 50 years had asthma. Seven of these had right or left upper lobar bronchiectasis and in four the middle lobe was bronchiectatic; their symptoms were predominantly those of asthma so that, if these patients had not been relegated to the group managed conservatively because they had asthma, it is probable that they would have been managed conservatively on the ground of being without symptoms referable to bronchiectasis.

A final decision on the management of lobar bronchiectasis in 12 patients under the age of 11 years and 13 others younger than 20 has not yet been reached, but there is so far no reason to regret the tentative decision to manage these patients conservatively. Five of them presented with an acute empyema which demanded urgently drainage by rib resection and in the routine post-operative investigation of which a bronchogram showed unilateral lower lobar bronchiectasis.

If /

If these patients had been well enough at the time of their presentation with an empyema to tolerate investigation before evacuation of the loculus of pus this investigation would have included bronchography and management would almost certainly have been by decortication of the empyema and lobectomy. All five of these patients are now well and symptomless, but with bronchiectasis which has been associated with, if not responsible for, one severe illness, and there is in these cases a strong argument for palliative lobectomy to which they will probably be submitted in the future. Middle lobar bronchiectasis in one girl followed the retention of a foreign body for only eight days in the intermediate bronchus. The foreign body was a blade of timothy grass and the girl is symptomless and unlikely ever to require lobectomy.

Of the remaining 61 patients in this group of 172, upper lobar bronchiectasis was demonstrated in 11 patients who did not have asthma and who were referred because of a single relatively mild respiratory infection in the investigation of which a radiographic opacity had been found or, more commonly, because of a single small haemoptysis. It is tacitly assumed that in these patients bronchiectasis is post-tubercular - all have a positive Mantoux - and paucity of symptoms has prompted conservative management. Twenty-one other patients who do not have asthma have bronchiectasis of the middle lobe; of these, two have had a lung abscess - in both in the right upper lobe - and two have had a contre-lateral empyema; the others presented because of haemoptysis or because of the detection at mass radiography of a shrunken middle lobe, in many labelled an "interlobar effusion"; paucity of symptoms in all has prompted conservative management, a decision which will be reversed without hesitation should symptoms develop, especially /

especially in the four who have already experienced what is probably an episode of metastatic infection. In nine patients with middle and lower lobar bronchiectasis the lobes are not shrunken and symptoms are insignificant, but in all of these the decision to pursue a conservative course can be revised if symptoms develop because all are relatively young. In four of these nine, and in nine of the 21 patients with middle lobar bronchiectasis, there is recorded the statement that symptoms, minor as they are, are more likely to be those of bronchitis than those of bronchiectasis because, in these 13 patients, bronchi other than those which are clearly bronchiectatic are a little spidery and irregular and it is in these patients that respiratory reserve is least adequate, although in none does diminished respiratory reserve alone preclude surgical management. Nineteen patients with lower lobar bronchiectasis and one with bronchiectasis of the middle and upper lobe on the right have not been managed surgically because investigation was prompted by a minor illness in all except one, who had an empyema in 1947, and observation, over many years in most of them, has appeared to justify a conservative attitude. In these patients the affected lobe or lobes occupy a normal volume of the hemithorax, bronchiectasis is cylindrical, and occasional symptoms and infrequent respiratory infections, common to patients shown not to have bronchiectasis are easily attributable to smoking, atmospheric pollution and virus infections to which the population at large is exposed.

TABLE VI

LOBAR BRONCHIECTASIS MANAGED CONSERVATIVELY

RIGHT-SIDED (117)

Ages	Upper (29)	Middle (55)	Lower (11)	Middle & Lower (19)	Middle & Upper (3)
Under 11	0	6	2 (1 E)	1	0
11 - 20	1	7 (1 FB)	0	0	0
21 - 30	2	4 (1 A)	2 (1 E)	3*	1
31 - 40	7	9 (1 E)	1	4	1*
41 - 50	5	12 (1 A & E)	1	3	0
51 - 60	6	11 (1 E)	1	6	0
61 - 70	6	2	4	2	1
71 - 80	2	4	0	0	0
A = Lung Abscess E = Empyema FB = Foreign Body	Youngest 11. Oldest 78/79. 14 of 29 over 50 years. 6 with asthma 5 under 50. 10 under 50 asymptomatic.	Youngest 3. Oldest 27. 17 of 55 over 50 years. 4 with asthma all under 50. 34 under 50 asymptomatic.	Youngest 4. Oldest 68. 5 of 11 over 50 years. 1 with asthma aet. 43.	Youngest 2 Oldest 63 8 of 19 over 50 years. 3 with asthma all over 50. *one of these declined op.	1 over 50 years of age. *declined operation

LEFT-SIDED (55)

Ages	Upper (9)	Lower (46)	Total (172)
Under 11	0	3	12
11 - 20	1*	5 (1 E)	14
21 - 30	1	7*	20
31 - 40	1 (E)	3	26
41 - 50	2	10	33
51 - 60	2	12	38
61 - 70	2	4	21
71 - 80	0	2	8
	Youngest 19 Oldest 65. 4 of 9 over 50yrs. 3 with asthma 2 under 50 *declined op.	Youngest 3 Oldest 75 18 of 46 over 50 yrs 7 with asthma, 6 over 50 * 3 of these declined operation	

67 from the total of 172 were over 50 yrs. of age. 6 declined operation.
24 had asthma, 11 of these over 50 yrs. 7 with history of empyema, 2 of lung abscess and 1 of foreign body.

Lobar and Ipsilateral Segmental Bronchiectasis Managed by Resection

It may be artificial to distinguish resection of this extent from lobectomy on the one hand and from segmental resection alone on the other. Such distinction has, however, the advantage of reducing the number of cases in each group to facilitate discussion and of allowing a comparison between the complications of lobectomy and of segmental resection alone with those of both procedures in the same patient, even if such comparison fails to demonstrate a significant difference.

Lobectomy and ipsilateral segmental resection was undertaken in 76 patients - 26 males and 50 females. Details which relate to these patients are shown in Table VII. The commonest resection undertaken in this group was left lower lobectomy and linguleotomy; a resection of this extent was undertaken in 64 patients and was, next to pneumonectomy, the commonest single procedure in the whole series. More than one-third of the resections in this group were undertaken in the two-year period 1954-1955. The twelve right-sided resections all included middle lobectomy. In this group of 76 patients the youngest was five years of age, all but four were 40 years old or younger and these four were in the sixth decade.

One patient died on the 14th. post-operative day from pulmonary embolism and one died two years after resection at the age of 53 years from cerebral thrombosis. The others are alive and all but one has been reviewed within the last three years. This patient was submitted in 1947 to left lower lobectomy and linguleotomy as part of a planned bilateral procedure. She declined to undergo the contra-lateral resection/

resection - for right basal bronchiectasis - and has not returned for review since 1954; she is known to be alive. In three other patients left lower lobectomy and linguleotomy were undertaken as part of a planned bilateral procedure. In two - both with middle lobar bronchiectasis associated, in one with medial basal segmental bronchiectasis, and in the other with bronchiectasis of all the right basal segments - symptomatic relief has been so satisfactory after the left-sided resection that these two patients have been transferred to the group in which a bronchiectatic "sump" has been resected in the knowledge of the existence of centre-lateral bronchiectasis within the limits of surgical management. In the third of these patients left lower lobectomy and linguleotomy were undertaken in the knowledge that the middle lobe was bronchiectatic but in the hope that the right-sided resection would not be necessary. Symptoms in this patient, while less obtrusive, persist, and middle lobectomy is planned.

In 15 other patients a left-sided resection - left lower lobectomy and linguleotomy in all of them - was undertaken in the knowledge that there co-existed surgically manageable right-sided bronchiectasis, and in one other patient a right-sided resection (middle lobectomy and medial basal segmental resection) was undertaken knowing that there was lingular bronchiectasis. In these 16 patients the bronchiectasis on the side of resection was gross, saccular and in shrunken lung, while that which remains and which in all has been confirmed as present on post-operative bronchograms, is cylindrical and bronchographically unimpressive. It is clearly recognised that there need not necessarily be any correlation between the severity of symptoms and the apparent grossness of bronchiectasis as shown bronchographically, but such correlation often exists. In these 16 patients relief of symptoms has been gratifying and progress such that there seems little likelihood that the residual bronchiectasis will have to be resected. /

resected. Post-operative bronchography was undertaken in all other patients except one who was 58 at the time of resection.

In one patient left lower lobar and lingular bronchiectasis co-existed with an atrial septal defect of secundum type which was closed with hypothermia through a right thoracotomy six years after the pulmonary resection; the girl is well. In another patient bronchiectasis of the same extent was found at thoracotomy to be related to an intrathoracic foregut duplication. In infancy this girl had an episode of haemorrhage, either haematemesis or haemoptysis, for which a cause was not found and after which she had recurring respiratory infections. The enterogenous cyst, which was resected with the lobe and segment, was densely adherent to the 6th thoracic vertebra in the posterior mediastinum, was 2 cm. in diameter and had not been recognised on pre-operative radiographs. The cyst was shown histologically to be lined by gastric mucosa and this case is believed to be an example of peptic ulceration in a foregut duplication with pulmonary erosion in infancy producing haemorrhage and subsequent pulmonary destruction from infection and possibly from digestion (le Roux, 1962b).

Seventy-two of the 76 patients in this group are known to be well; six female patients have married since resection and have five children between them.

It has already been suggested that it is artificial to include in the group of patients submitted to lobar and ipsilateral segmental resection the relatively large number with bilateral bronchiectasis in whom only a unilateral resection was undertaken, whether this unilateral resection was planned or because a planned bilateral resection was frustrated, since these patients unequivocally have bilateral bronchiectasis. The cases have been arranged in this way only for convenience. The number of each variety of resection is thereby made more readily available /

available if it becomes necessary to compare the numbers and results of a particular resection with other series. It is convenient to tabulate cases in which a bronchiectatic "sump" was resected with the group of resections which compares with that completed for comparison ~~with~~ results within that group. And if this were not done it would be necessary, to be consistent, to remove from tables which ennumerate resections of a particular extent cases found at post-operative bronchography to have bronchiectasis not known to have been present before operation.

TABLE VII

LOBAR & IPSILATERAL SEGMENTAL BRONCHIECTASIS MANAGED BY RESECTION

RIGHT

Middle Lobectomy & Medial Basal Segmental Resection (6)

Males (Ages)	Females (Ages)
22: 30	29: 35: 40: 40*
Total 2	Total 4

1949 - 1
1953 - 1
1954 - 1
1956 - 1
1958 - 1
1959 - 1

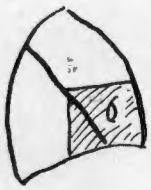

Middle Lobectomy & Right Basal Segmental Resection (3)

30	26: 27
Total 1	Total 2

1952 - 1
1953 - 1
1955 - 1

Middle Lobectomy & Right Anterior Segmental Resection (2)

10: 31

Total 2

1954 - 1
1956 - 1

Middle Lobectomy, Right Anterior & Medial Basal Segmental Resection (1)

11

Total 1

1954 - 1

LEFT

Left Lower Lobectomy & Lingulectomy (64)

Males (Ages)	Females (Ages)
6: 10*: 11*: 12: 13*	5: 8: 8: 8*: 9: 9
14: 15: 16: 17: 20*:	13: 13*: 14*: 15*: 16
21*: 27: 28: 29: 29	17: 17*: 19: 19: 20
30*: 31: 35: 37: 38	20: 20: 21*: 22: 24*
51●	26: 27: 28*: 29: 29*
Total 21	31*: 31*: 32: 32: 33
	34: 34: 35: 35: 37+
	38: 38: 39*: 39*: 51
	53: 58
	Total 43

1947 - 1
1948 - 6
1949 - 3
1950 - 5
1951 - 2
1952 - 3
1953 - 3
1954 - 12
1955 - 11
1956 - 5
1957 - 6
1958 - 3
1959 - 4

*Residual Bronchiectasis (20) + Operative Death (1) ● Late Death (1)

A B

C D

Fig. 68

Bronchiectasis of the left lower lobe and the whole of the lingular segment of the left upper lobe (B & C) was managed by lower lobectomy and linguleotomy. Pulmonary shrinkage on the left is clear in the pre-operative PA radiograph (A). The caudally directed left bronchi immediately above the diaphragm in the post-operative bronchogram (B) are incompletely filled ; these bronchi were more completely filled at bronchography some months later and were normal, but, as is so often the case, radiographic technique and technical faults in film processing have frustrated the reproduction of a complete set of radiographs. On an average fewer than 5% of plain films of the chest and bronchograms are of a quality which justifies their photographic reproduction.

A

B

C

D

Fig. 69

Bronchiectasis of the left lower lobe and the lower division of the lingular segment of a left upper lobe the bronchial anatomy of which is typical of the dichotomous arrangement (A & B) was managed in the patient whose films these are by left lower lobectomy and "lingulectomy" in 1950. The appearance of all the left bronchi in the post-operative bronchogram (C) suggests a diffuse abnormality, not obvious in the AP bronchogram (D). The post-operative bronchograms were made in 1952 with lipiodol and sulphanilamide powder as contrast; at that time the boy was symptomless and has remained so and it is therefore difficult to justify further bronchography with Hytrast to confirm that the appearances on the film (C) are the consequence of radiographic or bronchographic technique and are not significant.

A

B

C

D

Fig. 70

Although the bronchiectatic lower lobe and lower half of lingula shown in the left bronchograms (A) and (B) appear shrunken and to occupy relatively little of the left hemithorax, their resection has clearly been followed by considerable expansion of the remainder of the left upper lobe; in the pre-operative PA radiograph (C) the left hemithorax is, if anything, a little more opaque than the right, and there was no pleural effusion, while in the post-operative PA film (D) an increase in the translucency of the left hemithorax in comparison with the right is pronounced.

Lobar and Ipsilateral Segmental Bronchiectasis Managed Conservatively

Forty-six patients with lobar and ipsilateral segmental bronchiectasis were managed conservatively. Details which relate to these patients are shown in Table VIII. Bronchiectasis in 32 of these patients was left-sided and in all but one of these was limited to the left lower lobe and the lingular segment of the left upper lobe. In all but one of the 14 patients with right-sided bronchiectasis the lobar component included the middle lobe.

Of the 46 patients in this group 17 were over 50 years of age and six of those younger than 50 had asthma. The reason for conservative management in half of the group is therefore self-evident, particularly since symptoms referrable to bronchiectasis were not obtrusive in any of these patients. Four patients, suitable candidates in all respects for management by thoracotomy, declined surgical management, and four patients under 20 years of age are still being assessed, and although generally well may yet require resection of bronchiectasis. One of six patients who presented initially acutely ill with an empyema which demanded urgently management by open drainage and who was shown to have bronchiectasis at routine bronchography after recovery from empyema, has mitral stenosis. A final decision on management in this patient has not yet been reached. He has symptoms neither of bronchiectasis nor of mitral stenosis, but the natural history of mitral stenosis in men is often one of progress without recognised symptoms of the disease until the valve is calcified and less amenable to a conservative, closed valvulotomy as opposed to valve replacement, so that this symptomless patient is faced with the possibility of two palliative procedures - a right-sided pulmonary resection and left thoracotomy for mitral valvulotomy - a prospect which will not be discussed with him until his surgical advisers are satisfied in their own minds regarding/

regarding the need for surgery and the urgency of the procedures, and the order in which they should be undertaken.

In the remaining 14 patients in this group paucity of symptoms of bronchiectasis, which in all was cylindrical rather than saccular and in areas of lung which occupied a normal volume of the hemithorax, and, in six, diminution of respiratory reserve and spirometric evidence of air trapping which suggests emphysema, have prompted conservative management,

TABLE VIII

LOBAR WITH IPSILATERAL SEGMENTAL BRONCHIECTASIS MANAGED CONSERVATIVELY

Total (46) Male 20 : Female 26

E = Empyema
A = Asthma
O = Declined Operation

			Ages
Middle Lobe Bronchiectasis	with	Anterior Segment of Upper (5)	14: 26E: 40A: 48A: 55
		Basal Segments (3)	22: 42°: 47
		Medial Basal Segment (2)	34E: 41A
		Apical Segment of Lower Lobe (1)	42A
Upper Lobe	with	Apical Segment of Lower Lobe (1)	32A
Middle and Upper Lobes	with	Apical Segment of Lower Lobe (1)	29A
		Medial Basal Segment (1)	44

2 Empyemas
6 of 14 with Asthma
1 of 14 over 50 years
1 declined operation
Youngest 14
Oldest 55

Lower Lobe and Lingula - 31 patients

Ages		
Under 11	- 2	
11 - 20	- 1	Youngest 7
21 - 30	- 2	Oldest 72
31 - 40	- 9	3 from this group declined operation
41 - 50	- 2	
51 - 60	-10	15 of 31 over 50 - 2 of them with asthma
61 - 70	- 3	
71 - 80	- 2	4 presented with empyema

Left Upper and Apical Segment of Lower - 1 patient

Age 58

Total - 46 : 17 over 50 yrs. 8 with asthma - 6 of them under 50 yrs.
4 declined operation

Unilateral Segmental Bronchiectasis Managed by Resection

Unilateral segmental bronchiectasis was managed by segmental resection in 71 patients - 31 males and 40 females. Details which relate to these patients are shown in Table IX. Of the 71 resections 51 were left-sided and the commonest resection undertaken was left basal segmental resection and linguleotomy - in 20 patients; linguleotomy alone was undertaken in 16 patients. Two children were submitted to left-sided segmental resection at the age of two years. About three-quarters of the total number of patients in this group were younger than 30 years of age at the time of resection; the two oldest patients were 56 and 61 years respectively. More than one-third of the segmental resections in this group were undertaken in the two-year period 1955-1956; all the patients in the group have been reviewed during the past three years; there were neither early nor late post-operative deaths.

Resection in six patients was prompted by severe haemoptysis. In one of these investigation had initially been undertaken because of a minor haemoptysis and the apical segment of the left lower lobe was shown to be bronchiectatic and was accepted as the source of bleeding; the patient was at that time only 43 years old. Management was conservative and she did not have further trouble for 13 years, when she was re-admitted after a brisk haemoptysis which caused her and her family considerable anxiety. A case such as this - a patient with a single haemoptysis the source of which is demonstrated and who is managed without an operation, perhaps because of age, or because the haemoptysis is small, and who returns with the same symptom, now severe, when she is considerably older and on this ground an even less attractive operative risk - makes it necessary seriously to review and possibly revise the conservative attitude adopted in many similar cases.

Resection/

Resection in one patient included decortication of an ipsilateral empyema and in another patient left apical lower bronchiectasis associated with cough and the production of sputum in large volumes was related to an acute pyogenic lung abscess in the same segment. Empyema complicated resection in one patient in whom an apical pleural space persisted for so long after open drainage of the empyema that a small thoracoplasty was made. In one of the very young patients lingular bronchiectasis was part of Kartagener's syndrome.

Residual bronchiectasis is present in 10 of the 71 patients in this group. In two, who were submitted to a left-sided resection of gross bronchiectasis in shrunken lung, right cylindrical bronchiectasis in non-shrunken lung was known to exist before operation. In these two patients the left resection was undertaken in the hope that the right-sided disease - known to be within the limits of surgical management - would not be a source of symptoms, and this hope has been fulfilled. In one of these patients, in whom the apical segment of the left lower lobe was preserved, this segment may be abnormal on post-operative bronchograms. In one patient bilateral resection had been planned and the bronchographically grosser left bronchiectasis was first resected; this resection was followed by symptomatic relief so impressive that the right resection has not so far been made and seems unlikely ever to be necessary. In seven patients, in whom segmental resection was undertaken in the belief that the resection planned would extirpate all bronchiectasis, routine post-operative bronchography has demonstrated residual bronchiectasis, unequivocal in six and probable in one. This last-mentioned patient, who probably has lingular bronchiectasis after left basal segmental resection, and three others - one with medial basal segmental bronchiectasis on the right after left basal segmental resection and linguleotomy, one with an abnormal subsegment in the anterior segment of the right upper lobe after a left-sided resection/

resection of extent similar to that in the last-mentioned case, and one with medial basal bronchiectasis on the right after lingulectomy - are symptom-free and well. In three patients pre-operative investigations were clearly inadequate, and in retrospect the quality of bronchography in these was of a standard insufficiently good to allow of a decision on surgical management. These three patients still have symptoms which, in two, may demand further surgical action, one having middle lobar and medial basal segmental bronchiectasis after left basal segmental resection and lingulectomy, and one having middle lobar and left basal bronchiectasis after lingulectomy (and who would therefore need two further operations); the third patient is unsuitable for further surgery because all the right bronchi are now recognised to be diffusely abnormal and he is dyspnoeic and emphysematous, not having derived any benefit whatever from lingulectomy; this patient w s quite obviously never a suitable candidate for an operation.

A woman who was 41 years of age in 1953 when she was submitted to right anterior segmental resection because of recurrent haemoptysis developed, four years later, severe asthma of which she did not have a previous history and which quickly progressed until controllable only with steroids. A girl of 17 years was submitted to lingulectomy in 1956; she was relieved of symptoms of cough with purulent sputum for two years, and then she returned because of a recurrence of symptoms; over several months of observation she was shown to have fleeting bilateral pulmonary shadows and sputum with a high content of eosinophils; on recent review she is generally unwell, them, with cough and now mucoid sputum, and more dyspnoeic than before operation. In her, resection achieved little but it is difficult to be sure, from a scrutiny of the records, if pre-operative assessment was in any way inadequate.

Of/

Of the 71 patients in this group 59 are well and have normal post-operative bronchograms; five of these are now married women with five children between them. Seven patients with residual bronchiectasis are well and five patients, three with residual bronchiectasis, have either not been relieved of symptoms or have developed a new respiratory disease. It was earlier mentioned that the resection of diffusely scattered segmental bronchiectasis had been abandoned because of the high incidence of technical failure and the common finding post-operatively that remaining bronchi were abnormal. Segmental bronchiectasis of whatever variety, from the experience here related, appears to carry a higher rate of inadequacy in pre-operative investigation and to be associated more commonly with respiratory disease essentially non-surgical. It may be that the surgical attitude to all segmental bronchiectasis, not only the scattered variety, should become even more cautious.

TABLE XI

UNILATERAL SEGMENTAL RESECTION (71)

Right Anterior Segmental Resection

Males: 7: 13: 21 — Total 3

Females: 22: 41: 44: 48 — Total 4

1953 - 1
1954 - 1
1955 - 7
1956 - 1
1957 - 2
1960 - 1

Right Posterior Segmental Resection

61 — Total 1

1954 - 1

Right Apical Lower Segmental Resection

17: 30: 52 — Total 3

19: 21 — Total 2

1952 - 1
1954 - 1
1955 - 1
1956 - 1
1958 - 1

Right Basal Segmental Resection

19: 26 — Total 2

39 — Total 1

1950 - 1
1956 - 2

Left Anterior Segmental Resection

Males: 16 — Total 1

Females

1960 - 1

Left Apico-Posterior Segmental Resection

44: 45 — Total 2

1953 - 1
1959 - 1

Left Apical Lower Segmental Resection

40 — Total 1

56 — Total 1

1952 - 1
1963 - 1

Left Apical Lower and Posterior Basal Segmental Resection

51 — Total 1

24 — Total 1

1952 - 1
1954 - 1

Lingulectomy and Left Anterior Basal Segmental Resection

15 — Total 1

22 — Total 1

1955 - 1
1957 - 1

Lingulectomy

14: 16: 17: 17*: 19: 28*: 33 — Total 7

2: 14*: 15: 17: 17: 18: 28: 35: 47 — Total 9

1951 - 1
1953 - 3
1954 - 4
1955 - 2
1956 - 4
1959 - 1
1963 - 1

Left Basal Segmental Resection

8: 25: 42 — Total 3

12: 19: 30: 31: 36*: 41* — Total 6

1952 - 1
1953 - 1
1954 - 1
1955 - 3
1956 - 2
1959 - 2

*Residual Bronchiectasis 10
Unwell 2

Left Basal Segmental Resection & Lingulectomy

5: 8: 13: 14: 19: 21*: 37: 37* — Total 8

2: 3*: 8: 9: 11: 13: 16: 22: 25: 27*: 29*: 33 — Total 12

1950 - 1
1955 - 4
1956 - 5
1957 - 4
1958 - 2
1959 - 2
1960 - 1
1961 - 1

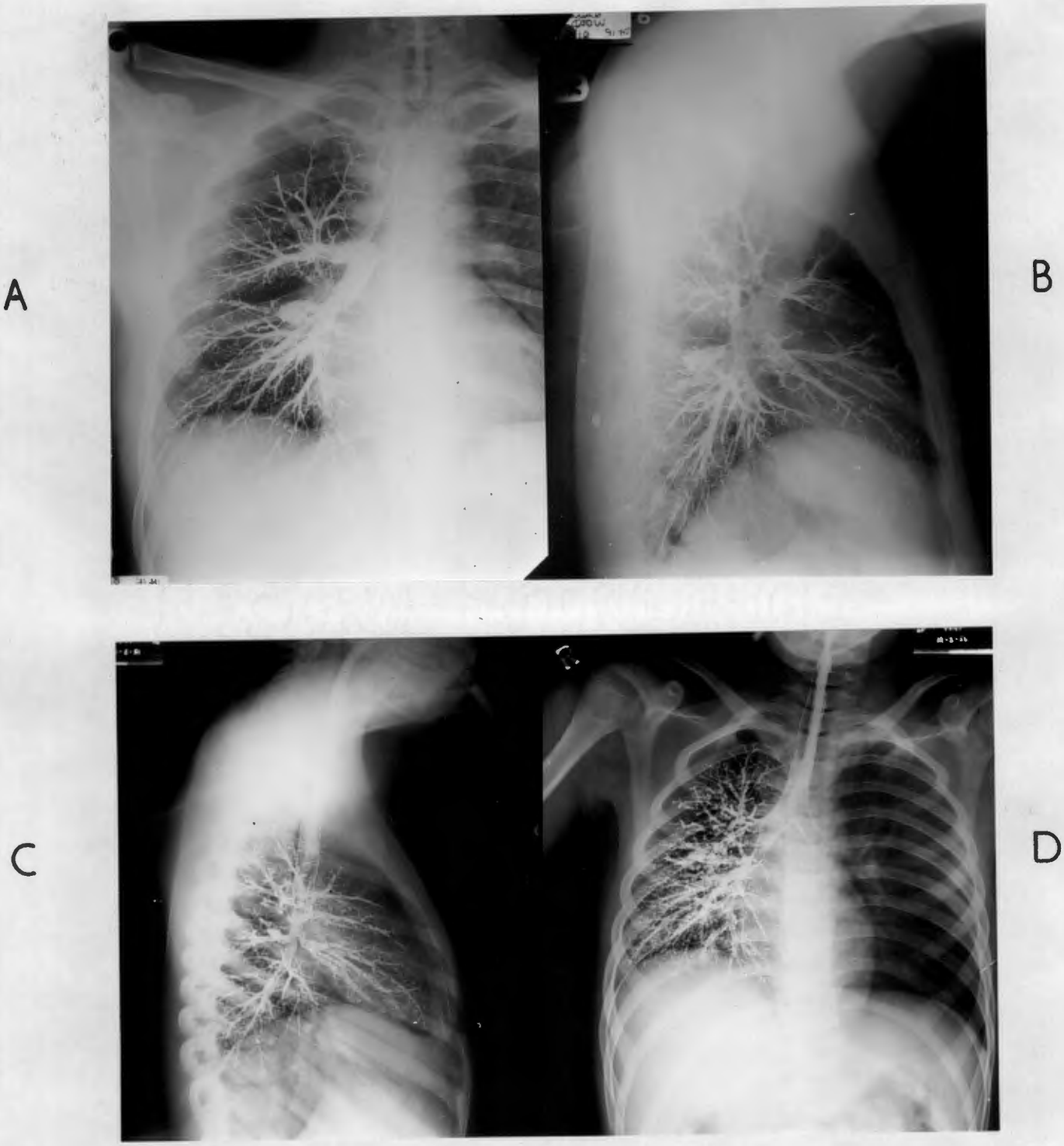

Fig. 71

Bronchiectasis of the apical segment of the right lower lobe in two patients whose films are (A & B) and (C & D) was managed by resection; in each haemoptysis was the presenting symptom.

A B

C D

Fig. 72

Bronchiectasis of the right anterior segment (B & C) was managed by resection. Haemoptysis prompted investigation in the patient whose films these are. A pre-operative lateral view (A) and a post-operative PA view (D) are shown. Rib resection was undertaken to facilitate access and the regenerated 6th. left rib is visible in (D).

A

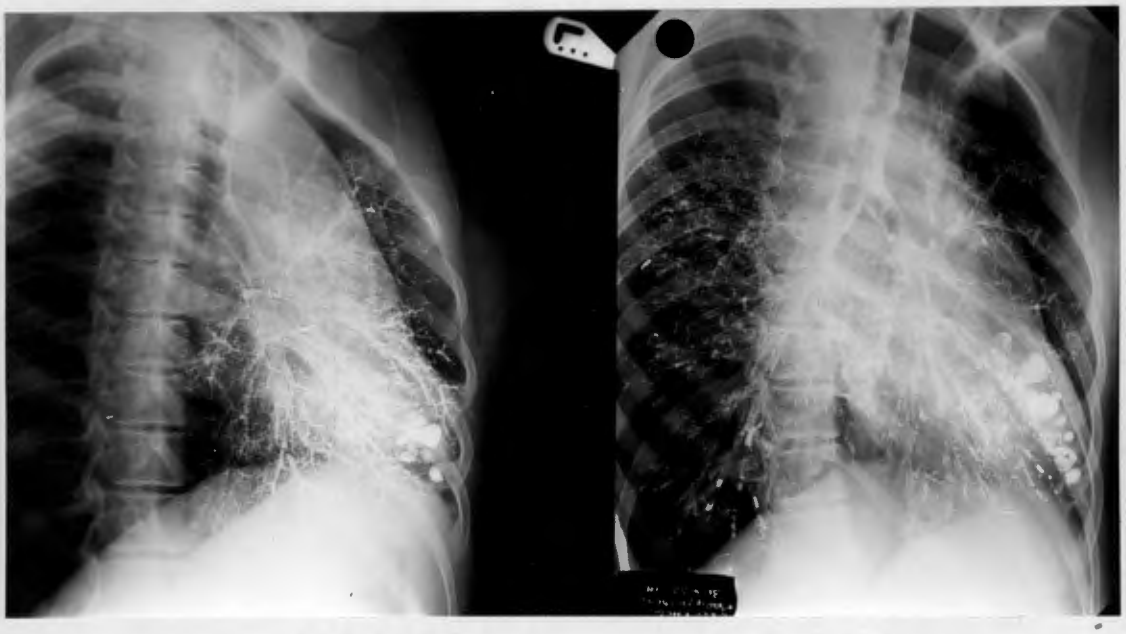

B

C

Fig. 73

Bronchiectasis of the lower half of the lingular segment (A & B) in a patient in whom the bronchi of the left upper lobe are arranged dichotomously, was managed by resection. The post-operative bronchographic appearances are shown in (C)

A

B

C

D

Fig. 74

Bronchiectasis of the lower half of the lingular segment and of the left basal segments - grossest in lingular and in lung of normal volume in the left lower lobe - was managed by resection because of severity of symptoms

A B

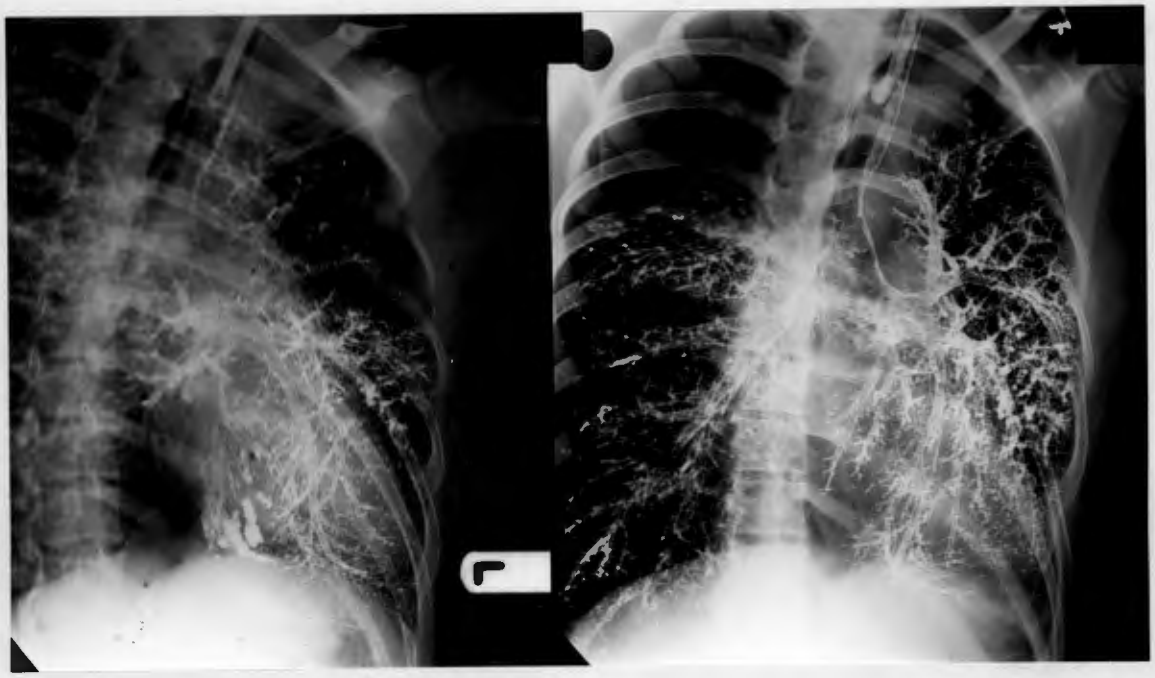

C D

Fig. 75

The left oblique bronchogram (C) shows bronchiectatic left basal segments which were resected. The normality of the bronchi of the apical segment of the left lower lobe is abundantly clear when the post-operative bronchogram (D) is scrutinised. Pre- and post-operative PA chest radiographs (A & B) of the patient whose bronchograms these are, are shown.

A

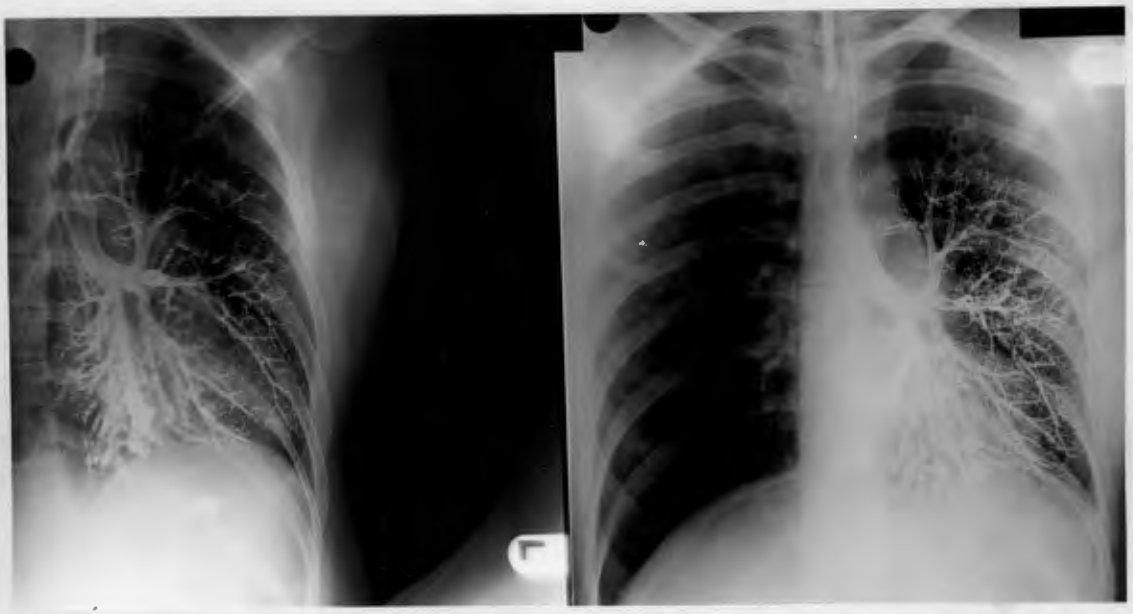

B

C

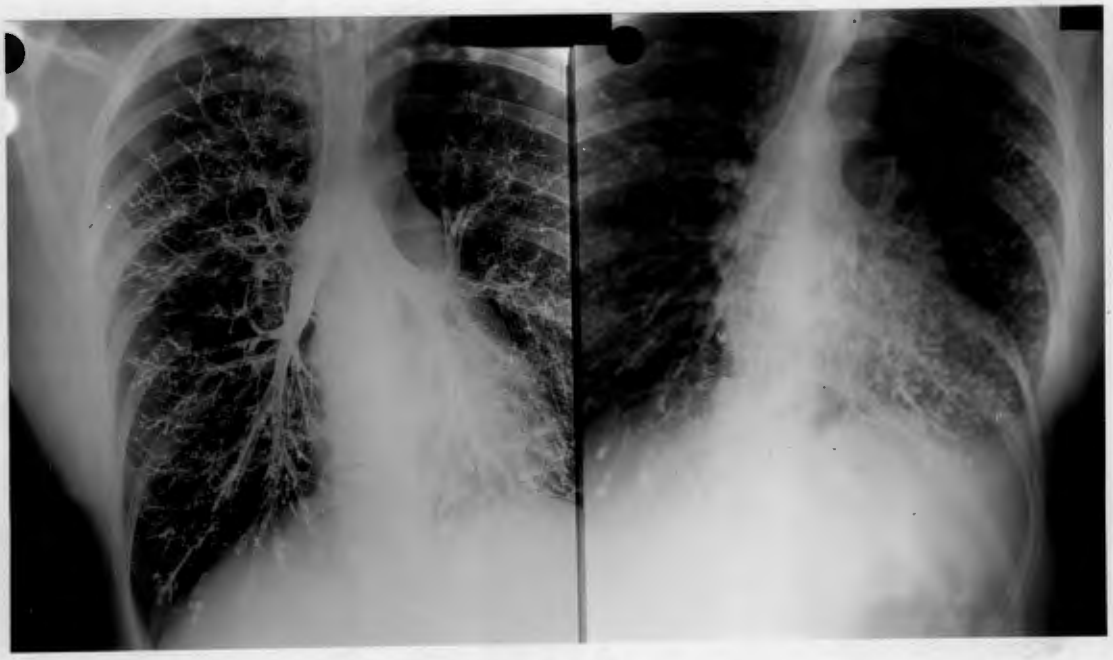

D

Fig. 76

Bilateral basal bronchiectasis in the patient whose films these are was managed only by left basal segmental resection in the clear knowledge that some right basal bronchi were abnormal because only the left basal segments were shrunken. Relief of symptoms was achieved. The bronchi of the apical segment of the left lower lobe are well seen in the oblique bronchogram (A), and the advisibility of leaving this segment is questionable in this instance after scrutiny of these bronchi in the post-operative bronchogram (D). Right basal bronchiectasis is clear in both pre- and post-operative bronchograms (C) & (D).

A

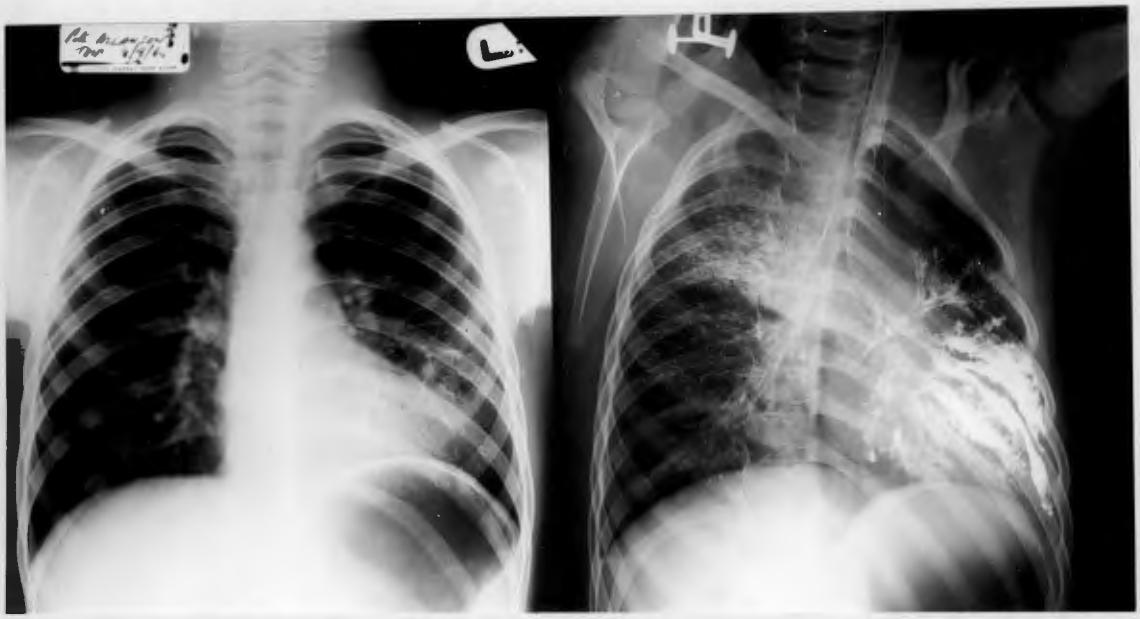

B

C

D

Fig. 77

Cystic spaces at the left heart border in the PA film (A) suggest the diagnosis of left-sided bronchiectasis but contribute little to precise anatomical localisation of the disease to the lingular segment of a bifurcating left upper lobar bronchial arrangement (B) and the basal segments of the left lower lobe. The right bronchi are normal (C & D). Management was by left basal segmental resection and lingulectomy.

A

B

C

Fig. 78

Pulmonary resection of an extent greater than lobectomy may, even in children, be preceded by thoracotomy with rib resection; the object of rib resection is to shrink the hemithorax to facilitate its occupation by what lung remains. The thoracoplastic effect of resection of even a single rib is unequivocal, and rib regeneration, in children particularly, is often rapid and surprisingly complete. The PA chest radiograph (A) was made on the day of discharge from hospital of the patient whose bronchograms are shown as Fig. 77. Lower lobectomy and linguleotomy had been associated with subperiosteal resection of the 5th. left rib. The film (B) was made 15 days later and rib regeneration is already clear. Eight weeks later (C) the left 5th. rib can be seen to be little different from other ribs.

Unilateral Segmental Bronchiectasis Managed Conservatively

Unilateral segmental bronchiectasis of a variety and extent amenable to surgical management was not resected in 123 patients - 71 males and 52 females. Details which relate to these patients are shown in Table X. In 76 patients bronchiectasis was left-sided and in 47 it was right-sided. Bronchiectasis in more than a third of the total number of patients in this group involved the lingular segment of the left upper lobe or the basal segments of the right lower lobe.

Of these 123 patients 35 were older than 50 years when first they were referred for a surgical opinion; 12 patients younger than 50 years had asthma and two others declined thoracotomy. Sixteen patients younger than 20 years when first they were seen are, after completion of routine investigations, being managed conservatively to allow of a more precise assessment of the severity of their symptoms. One patient died from an unrelated cause within a few weeks of her first being investigated. In the 57 who remain for discussion, resection was not undertaken because of paucity of symptoms (in 19 patients), or because of lack or respiratory reserve and symptoms suggestive of bronchitis and emphysema (in 38). In 23 of these 57 patients bronchiectasis was confined to a single segment in one or other of the upper lobes and all these patients presented because of an isolated haemoptysis or after the finding of a radiographic abnormality at mass miniature radiography; in all these patients the Mantoux test was positive and it is presumed that in them bronchiectasis was post-tubercular. The remaining 34 patients presented for investigation because a pulmonary opacity which had been found to persist after a relatively minor respiratory illness made it necessary to exclude the diagnosis of pulmonary carcinoma, or again because of haemoptysis or an abnormal mass /

mass miniature radiograph. In some of these the need for management by resection has not been finally ruled out; none needs medical treatment and all continue to be observed.

TABLE X

SEGMENTAL BRONCHIECTASIS MANAGED CONSERVATIVELY

Total 123: Males - 71: Females - 52.

RIGHT (47)

Basal Segments (19)

2 under 20 years - youngest 7
21-40 yrs.: 7 patients - 1 with asthma
1 with empyema
2 declined op.
10 over 40 years - 1 died
1 with asthma

Apical Segment of Lower Lobe (4) + (2)

Ages: 20/35/43/50

with posterior seg. of upper lobe - aet.11
with anterior seg. of upper lobe - aet.57

Segments of Right Upper Lobe (22)

All over 30 years
18 under 50 years
Oldest 67 years

LEFT (76)

Basal Segments (24)

3 under 20 years - youngest 5
31 - 60 yrs.: 11 patients - 5 with asthma
oldest 75 yrs.
only 6 younger than 4 yrs.

Basal Segments & Lingular Seg. (10)

Youngest - 7 yrs.
7 older than 40 yrs, 4 with asthma

Lingular Segment (18) + (3)

6 under 11 yrs.; youngest 2 yrs.
9 under 50 yrs - 1 declined op.

with apical lower segment in 2 patients
with anterior basal segment in 1 patient

Apical Segment of Lower Lobe (9) + (2)

All over 40 yrs.
3 over 60 yrs.
Oldest - 65 yrs.

with posterior seg. of upper lobe in 2
two with asthma

Other Segments of Upper Lobe (10)

21 - 40 : 4
41 - 60 : 5
Oldest - 65

A

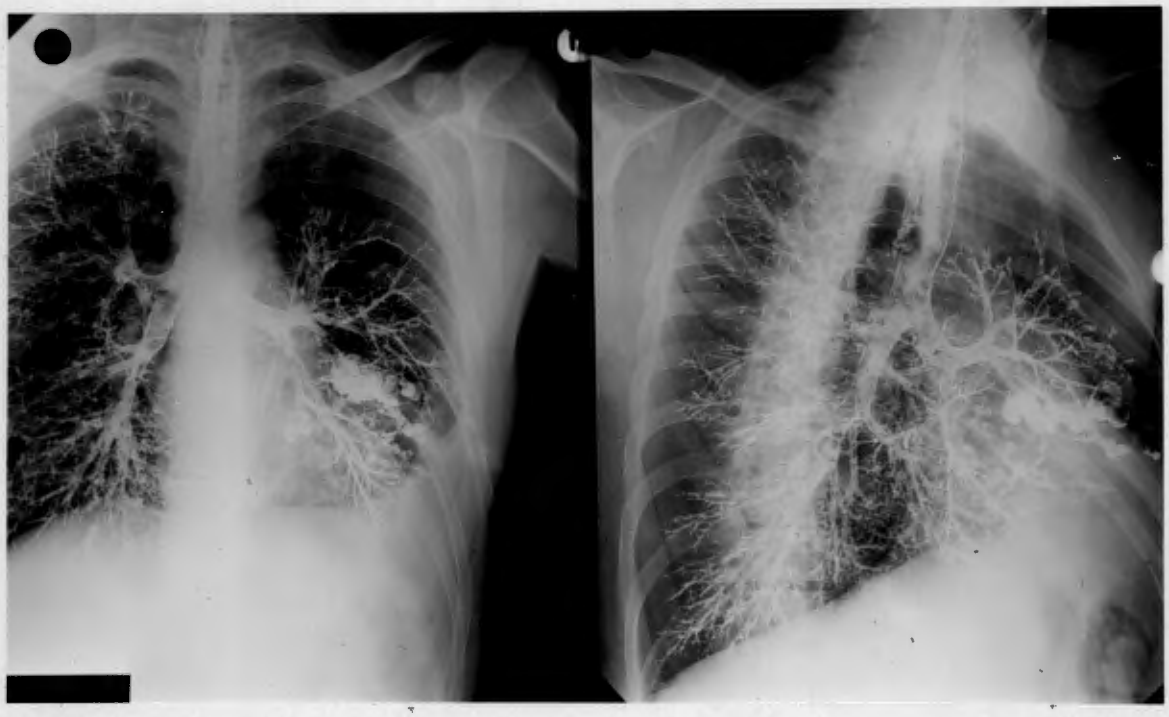

B

Fig. 79

The patient whose radiographs these are had severe asthma. Because of this bronchiectasis of half the lingular segment and of one of the left basal segments was managed conservatively.

Bilateral Bronchiectasis Managed Surgically

Bilateral resection for bronchiectasis was undertaken in 49 patients. Details which relate to these patients are shown in Table XI. Thirty-five of these patients were female and 14 were male. Resection was undertaken in four patients under 10 years of age and in 20 patients younger than 20 years. The oldest patient was 45 years and three were a little younger than 40 years. The ages given are those at the time of the first resection; many of these patients were younger when first they attended for consultation. Apart from left pneumonectomy in one patient in this group, left-sided resections involved part or all of the lower lobe in ten patients, part or all of the lower lobe and the lingular segment of the upper lobe in 34 patients, and the lingular segment alone in four patients. Right-sided resections included part or all of the middle lobe in 11 patients, part or all of the lower lobe in 15 patients, part or all of the middle and lower lobes together in 17 patients, and in six patients the anterior segment of the right upper lobe was resected, in one as the only right-sided resection and in five together with parts of the middle or lower lobes, or both.

The most extensive resection undertaken (Case 1) was middle lobectomy followed eight months later by left pneumonectomy. In this boy the middle lobe and the left lung were shrunken, airless and radiographically opaque. Symptoms of cough and the production of copious quantities of purulent sputum were relieved and respiratory function was, by measurement, improved by these resections, and the boy, now a man, is well and works as a farm-hand.

Three lobes and a segment were resected from two patients - in both, the middle and lower lobes on the right and the lower lobe and the lingular segment of the upper/

upper lobe on the left (Cases 2 and 3). These extensive resections were undertaken more than 13 years ago in children of 10 and 14 years respectively. The girl is now married and has a family and claims to be well, without dyspnoea. She is overweight and her exercise tolerance is, by recent assessment, less good than five and ten years after resection. In her the resected lobes and segment were shrunken, airless pus sacks which occupied very little space in each hemithorax and which were the source of a large volume of foetid sputum. That her life has been made pleasant and trouble-free by the resections is unequivocal. It remains likely that her life will be shortened because of the disease which necessitated bilateral pulmonary resection, and there is a little residual bronchiectasis in a subsegment of the right anterior segment. The boy in whom a resection of similar extent was undertaken was rejected for Army Service - because of the fact of his having had bilateral thoracotomies, not because of symptoms. He has recently been experiencing episodes of bronchitis in the winter and a recent bronchogram, of a quality better than that made originally, shows part of the anterior segment of the left upper lobe to be abnormal. This is not evidence of "spread" of bronchiectasis, only of improvement in bronchographic technique. This patient may well become a respiratory cripple because of bronchitis and emphysema, and his life-span is likely to be abbreviated, but in him, too, this will be because of the disease which necessitated bilateral pulmonary resection and which deprived him of so much functioning lung, and not because of the resections, which were of airless pus sacks, the removal of which was followed by remarkable increase in growth rate and improvement in general well-being, and freedom from severe and frequently recurring respiratory illnesses and the daily production of large volumes of offensive sputum.

Resections/

Resections of an almost similar extent - the apical segment of the left lower lobe was preserved - were undertaken in two patients (Cases 4 and 5), in one recently and with the knowledge that part of the right anterior segment was cystic. Both these patients were relatively old and both had experienced such severe symptoms for so long that life for them had become intolerable. It is in adult patients, in whom symptoms of cough and sputum create a social barrier, that resection, even if only incomplete, may be undertaken for reasons which are partly psychological. In the 18 months since completion of surgical management the transformation in one of these patients (Case 5) has been obvious to all. She still has cough and a little sputum, but her social life is now normal, she has gained weight and has not missed a day at work. For the ten years before resection she had, on an average, been unable to work for half of every year, despite the exhibition of appropriate antibiotics as short- or long-term therapy and despite studious devotion daily to postural drainage, and during this time she had not attended a social function or eaten a meal away from her home because of embarrassment occasioned by her symptoms. In both these patients, the second of whom is equally well, the apical segment of the left lower lobe is large and, on recent bronchograms, serves a measurable function in space occupation, thereby preventing over-inflation of the rest of the ipsilateral lung, and there is no reason to believe that respiratory function is anything but normal. Experience in these two cases, as well as in many other throughout the series in which the apical segment of a lower lobe was preserved, confirms the propriety of preserving this segment, which may be remarkably large. The experience of Collis(1953) is similar - that of Hoffman(1955) is different.

Three/

Three lobes(middle and lower on the right and lower on the left) were resected in one patient (Case 6) and two lobes (middle and left lower in one and right and left lower lobes in three) in four patients (Cases 8, 9, 10 and 11). One of these patients has occasional episodes of winter bronchitis; the others are well and two who were girls at the time of resection are now married women with five children between them.

Middle and lower lobectomy on the right was associated with left basal segmental resection in one patient (Case 7) and in six patients middle lobectomy was associated with left lower lobectomy and lingulectomy (Cases 12 - 17). In one of these the first, left-sided, resection was incomplete in so far as part of the lingular segment was shown by bronchography, which was designed to precede the right-sided resection, to have been left unresected at the first operation. A second left-sided resection was therefore undertaken before middle lobectomy. This patient is now well and has three children; the other six patients are all well.

Lower lobectomy and lingulectomy on the left were associated with right lower lobectomy in one patient (Case 18), with resection of the medial basal segment in one patient (Case 19), with resection of the middle lobe and the medial basal segment in two patients (Cases 20 and 21), with resection of the lateral segment of the middle lobe in one patient (Case 22), with middle lobectomy and resection of the anterior segment of the right upper lobe in one (Case 23), with resection of the right basal segments in four patients (Cases 24 - 27), and with resection of the right posterior basal segment in one patient (Case 28). One of these patients continues to have para-nasal sinus infection and another is bronchitic, asthmatic and emphysematous, and requires anti-spasmodics and frequent recourse to chemotherapy. While this patient does not yet classify as a respiratory cripple, she/

she is unaware of having derived any benefit from resection; neither she nor her parents is aware of significant change in symptoms or improvement in general well-being, a little reduction in cough and sputum being offset by the development of bronchospasm. Retrospective evaluation is never satisfactory, but in this patient, from a scrutiny of the records, there is nothing which would have suggested the likelihood of an unsatisfactory outcome to surgical management of bronchiectasis, and none of the pre- and post-operative bronchograms suggests the diagnosis of bronchitis with bronchiectasis. The other 10 patients in this group are well.

Resection of the left basal segments without the apical segment of the left lower lobe, and lingulectomy, were associated with resection of the middle lobe in two patients (Cases 29 and 30), with middle lobectomy and resection of some or all of the right basal segments in seven patients (Cases 31 - 37), and with resection of the lateral segment of the middle lobe and two right basal segments in one patient (Case 38). One of these patients has Raynaud's disease, but is without respiratory symptoms; one is a severe bronchitic, with asthma inadequately controlled even with steroids, and is a respiratory cripple improved in no way and possibly made worse by resection, which retrospectively was clearly an ill-judged undertaking; one is thin and a little dyspnoeic and has occasional episodes of bronchitis but is unequivocally improved by resection, is married and has two children, one of which is severely asthmatic; and one patient complains of cough and sputum but has now been observed for a fortnight in hospital on four separate occasions and would appear to be symptomless. This patient has two children and is divorced. The others are well.

Lingulectomy/

Linguleotomy in four patients was associated with middle lobectomy and resection of the anterior segment of the right upper lobe in two(Cases 39 and 40), with middle lobectomy and resection of the medial basal segment of the right lower lobe in one (Case 41), and with middle and lower lobectomy and resection of a sub-segment of the right anterior segment in one (Case 42). In this last-mentioned patient very little of the right upper lobe was resected and the right-sided pulmonary residue adequately fills that hemithorax. One girl from this group, who was observed for five years before the first resection was undertaken and for a total of 12 years, is abnormally thin and has winter episodes of bronchitis but is not dyspnoeic. Two female patients are married and have children; one of them was dyspnoeic during a second pregnancy four years after completion of surgical management of bronchiectasis, and at that time her maximum ventilatory volume was 47 l./min. as compared with a normal predicted for her of 84 l./min. Since delivery she has not complained of dyspnoea. The other married woman is well. The fourth patient in this group is well, but post-operative bronchograms show him to have residual medial basal bronchiectasis on the right.

Resection of the right basal segments in five patients (Cases 43 - 47) was associated with left lower lobectomy in two, with left basal segmental resection and linguleotomy in one, with left basal segmental resection in one, and with resection of one left basal segment and the lingular segment of the left upper lobe in the last of the five. One woman, married and with two children, has occasional episodes of bronchitis; in her the last of the two resections was 10 years ago. A man in this group delayed for eight years before he would submit to the second resection, and is now symptom-free; the other three are well.

Left lower lobectomy in one patient (Case 48) was associated with resection of

The/

the right anterior segment, and in the last patient in this group of 49 submitted to bilateral resection, middle lobectomy and resection of the anterior segment of the right upper lobe and medial basal segment of the right lower lobe were associated with resection of the left basal segments. Both these last-mentioned patients are well, the last after three pregnancies.

In six of the 49 patients submitted to bilateral resection for bronchiectasis neither resection included segmental resection. Convalescence in five of these patients was uneventful and in one patient, in whom resection was undertaken in 1949, convalescence was complicated by empyema thoracis. In here bronchiectasis had been complicated before thoracotomy by both lung abscess and empyema (Case 18).

In 14 patients lobectomy on one side was associated with segmental resection on the other, and in the remaining 29 patients segmental resection was undertaken on both sides. A difference in the smoothness of convalescence after lobectomy on one side in comparison with segmental resection on the other could not be appreciated. In general, the second of two resections disturbed the patients less than the first, and in only three patients in whom segmental resection was undertaken was air leakage long continued; in none was a further thoracotomy required for the management of broncho-pleural fistula.

The apical segment was the only part of the lower lobe preserved on one side in 17 patients and on both sides in five patients. In none of these patients was the residual apical lower segment shrunken on plain films and in none was there crowding of the bronchi within this segment bronchographically.

Of the 49 patients submitted to bilateral resection the first thoracotomy was undertaken in 30 patients in the four-year period 1952-1955; the first thoracotomy in/

in nine patients was undertaken before this period and in the remaining ten after 1956. The fact that nearly two-thirds of the bilateral resections were embarked upon during a continuous period less than one-third of that under review has no particular significance and does not indicate a passing enthusiasm for bilateral resection. The Thoracic Surgical Unit in Edinburgh before 1952 was unable to cope with the surgical material referred to it because of a shortage of surgical staff, and a waiting list, both of patients who required investigation and of those in whom investigation was already complete and who were awaiting surgery, had accumulated. In respect of bronchiectasis, and especially bronchiectasis which was bilateral, this enforced delay was regarded as nothing but beneficial, since it reduced the likelihood of embarking upon an extensive programme without certainty that the severity of symptoms justified this course. During the four year period when the first of most of the bilateral resections was undertaken, staffing arrangements changed so that a large volume of surgery for pulmonary carcinoma, tuberculosis and mitral stenosis could be undertaken and yet leave operating time to deal with the backlog of patients who required resection for bilateral bronchiectasis. The allocation of patients to a waiting list early in the last decade accounts for the delay between a patient first being seen and the first resection. In five children the decision on whether or not to embark upon a course of surgical management was deliberately delayed for three to five years because the history of these patients' respiratory symptoms was difficult to assess and their social circumstances made it difficult to judge the severity of their complaints. One patient, a girl of 19 years, was observed for seven years before the first resection was undertaken because she was reluctant to undergo thoracotomy. She accepted surgical management only when her symptoms constituted a bar to change in her social life.

The/

The interval between the first and second resection ranged from three months to eight years. Special circumstances which included the need for continued hospitalisation between resections prompted the completion of treatment in three months in a woman of 45 years. It is generally accepted, with little factual evidence, that a second thoracotomy is undesirable within six months of a previous contra-lateral thoracotomy. The second resection was undertaken in most patients six to 18 months after the first. In six patients the second resection was undertaken more than two years after the first - in two because the patients were abroad with their parents, between resections, in one because of the length of the waiting list between 1949 and 1952, in one because of the need for prolonged treatment of para-nasal sinus infection, in one because the first, left-sided, resection was incomplete and a second left operation was necessary before middle lobectomy could be undertaken, and in one because the patient declined for eight years to undergo the second resection, because of domestic circumstances.

The less extensive bronchiectasis was, in general, first resected, the object being to have available as much contra-lateral functioning lung, untrammelled by bronchiectasis, when the more extensive resection was undertaken. When bronchiectasis was of equal or nearly equal extent on the two sides, the selection of a side for the initial thoracotomy was arbitrary. In a few patients an argument precisely the reverse of that first offered was used in determining the thoracotomy which should first be undertaken - that the larger sump should first be resected to obtain maximum relief of symptoms, as early as possible in a course of treatment, and to achieve maximum reduction of sputum before the second operation was undertaken With proper pre-operative preparation it is nearly always possible in a patient with bronchiectasis to diminish sputum to negligible quantities for the operative period so/

so that any arguement which attempts to justify on this basis the side on which first to operate in a patient with bilateral bronchiectasis is likely to be spurious. One clear advantage of resecting first the grosser bronchiectasis has emerged, however, and that is the possibility of achieveing with this so impressive a reduction in symptoms that the second resection is no longer necessary. An argument advanced for undertaking first the less extensive resection is that, in the event of a surgical accident at the first operation which necessitates a resection more extensive than that planned, all available lung on the remaining side, bronchiectatic or not, is available, whereas, if the more extensive resection is first undertaken and a surgical accident complicates the second, less extensive, resection and necessitates a resection greater than that planned, the patient may be deprived of a volume of lung in excess of the compatible with adequate respiratory function. Such an argument can be based only on the assumption that there is functional reserve in bronchiectatic lung planned for resection, which suggests a basis for selection different from that used in this series; but such an arguement cannot be rejected out of hand since it is unlikely to be advanced theoretically; experience of such surgical accidents would with justification not only determine a particular surgeons's attitude towards the side first to resect in a patient with bilateral bronchiectasis, but would also considerably dampen enthusiasm for bilateral resection. Nowhere in the management of bronchiectasis is there place for the occasional pulmonary surgeon, and accidents perpetrated in training reflect only on those who have neglected to supervise the trainee.

TABLE XI

BILATERAL RESECTIONS

Total - 49 Males - 14 : Females - 35

No.	Age when First Seen		Sex	Extent of Resection Right	Extent of Resection Left	Side First Resected	Interval Between Resections	Year Treatment Completed
1	20	1952	M	Middle Lobe	Total	R	8 mos.	1955
2	10	1949	M	Middle & Lower Lobes	Lower Lobe & Lingular	R	17 mos.	1950
3	14	1950	F	Middle & Lower Lobes	Lower Lobe & Lingula	R	8 mos.	1951
4	38	1952	M	Middle & Lower Lobes	Basal Segs. & Lingula	R	7 mos.	1953
5	45	1961	F	Middle & Lower Lobes	Basal Segs. & Lingula	L	3 mos.	1962
6	21	1948	F	Middle & Lower Lobes	Lower Lobe	R	12 mos.	1953
7	37	1952	F	Middle & Lower Lobes	Basal Segs.	R	15 mos.	1954
8	8	1954	M	Middle Lobe	Lower Lobe	L	11 mos.	1956
9	14	1949	F	Lower Lobe	Lower Lobe	R	21 mos.	1951
10	27	1949	F	Lower Lobe	Lower Lobe	L	27 mos.	1951
11	12	1949	F	Lower Lobe	Lower Lobe	R	15 mos.	1951
12	32	1952	F	Middle Lobe & Lingula	Lower Lobe & Lingula	R	15 mos.	1955
13	20	1953	M	Middle Lobe	Lower Lobe & Lingula	R	8 mos.	1955
14	36	1948	M	Middle Lobe	Lower Lobe & Lingula	L	24 mos.	1953
15	18	1956	M	Middle Lobe	Lower Lobe & Lingula	R	8 mos.	1957
16	23	1956	F	Middle Lobe	Lower Lobe & Lingula	L	8 mos.	1956
17	16	1950	F	Middle Lobe	Lower Lobe & Lingula	L	34 mos.	1955
18	12	1947	F	Lower Lobe	Lower Lobe & Lingula	R	9 mos.	1949
19	35	1949	F	Medial Basal Segment	Lower Lobe & Lingula	R	9 mos.	1952
20	6	1953	F	Middle Lobe & Medial Basal Segment	Lower Lobe & Lingula	R	6 mos.	1958

No.	Age when First Seen		Sex	Extent of Resection Right	Extent of Resection Left	Side First Resected	Interval Between Resection	Year Treatment Completed
21	19	1951	F	Middle Lobe & Medial Basal segment	Lower Lobe & Lingula	R	9 mos.	1959
22	18	1952	M	Lateral Seg. & Middle Lobe	Lower Lobe & Lingula	R	11 mos.	1954
23	7	1950	F	Middle Lobe & Anterior Seg.	Lower Lobe & Lingula	L	8 mos.	1952
24	4	1950	F	Basal Segments	Lower Lobe & Lingula	L	15 mos.	1955
25	35	1954	F	Basal Segments	Lower Lobe & Lingula	L	8 mos.	1956
26	20	1950	M	Basal Segments	Lower Lobe & Lingula	R	11 mos.	1955
27	18	1949	F	Basal Segments	Lower Lobe & Lingula	L	3 yrs.	1952
28	12	1951	F	Posterior Basal Segment	Lower Lobe & Lingula	L	5 yrs.	1960
29	11	1952	M	Middle Lobe	Basal Segs. & Lingula	R	9 mos.	1956
30	18	1949	F	Middle Lobe	Basal Segs. & Lingula	R	18 mos.	1955
31	20	1959	F	Middle Lobe Medial & Post. Basal Segs.	Basal Segs. & Lingula	L	16 mos.	1961
32	14	1953	F	Middle Lobe Ant. Lat. & Medial Basal Segments	Basal Segs. & Lingula	R	12 mos.	1955
33	29	1956	F	Middle Lobe & Post. Basal Segment	Basal Segs. & Lingula	L	16 mos.	1959
34	34	1952	M	Middle Lobe & Basal Segs.	Basal Segs. & Lingula	R	12 mos.	1955
35	15	1953	F	Middle Lobe & Basal Segs.	Basal Segs. & Lingula	L	15 mos.	1956
36	9	1950	F	Middle Lobe & Medial Basal Segment	Basal Segs. & Lingula	R	8 mos.	1954
37	17	1954	F	Middle Lobe & Medial Basal Segment	Basal Segs. & Lingula	R	6 mos.	1957

No.	Age when First Seen		Sex	Extent of Resection Right	Extent of Resection Left	Side First Resected	Interval Between Resection	Year Treatment Completed
38	13	1957	F	Lateral Seg. of Middle Lobe & Lat.& Post. Basal Segments	Basal Segs. & Lingula	L	19 mos.	1958
39	14	1953	F	Middle Lobe & Ant. Seg. of Upper	Lingula	R	9 mos.	1954
40	5	1950	F	Middle Lobe & Ant. Seg. of Upper	Lingula	R	15 mos.	1952
41	5	1952	M	Middle Lobe & Medial Basal Seg.	Lingula	R	14 mos.	1958
42	39	1954	F	Middle and Lower Lobe & Subsegment of Anterior	Lingula	L	6 mos.	1956
43	6	1953	M	Basal Segs.	Lower Lobe	L	30 mos.	1958
44	23	1955	F	Basal Segs.	Lower Lobe	L	12 mos.	1956
45	19	1951	F	Basal Segs.	Basal Segs. & Lingula	R	8 mos.	1953
46	14	1954	F	Basal Segs.	Basal Segs. ~~& Lingula~~	R	12 mos.	1956
47	27	1953	M	Basal Segs.	Post.Basal Segment & Lingula	L	8 yrs.	1961
48	34	1952	F	Ant. Seg.of Upper Lobe	Lower Lobe	L	13 mos.	1954
49	21	1955	F	Middle Lobe Medial,basal & Ant. Seg.	Basal Segs.	L	11 mos.	1956

A

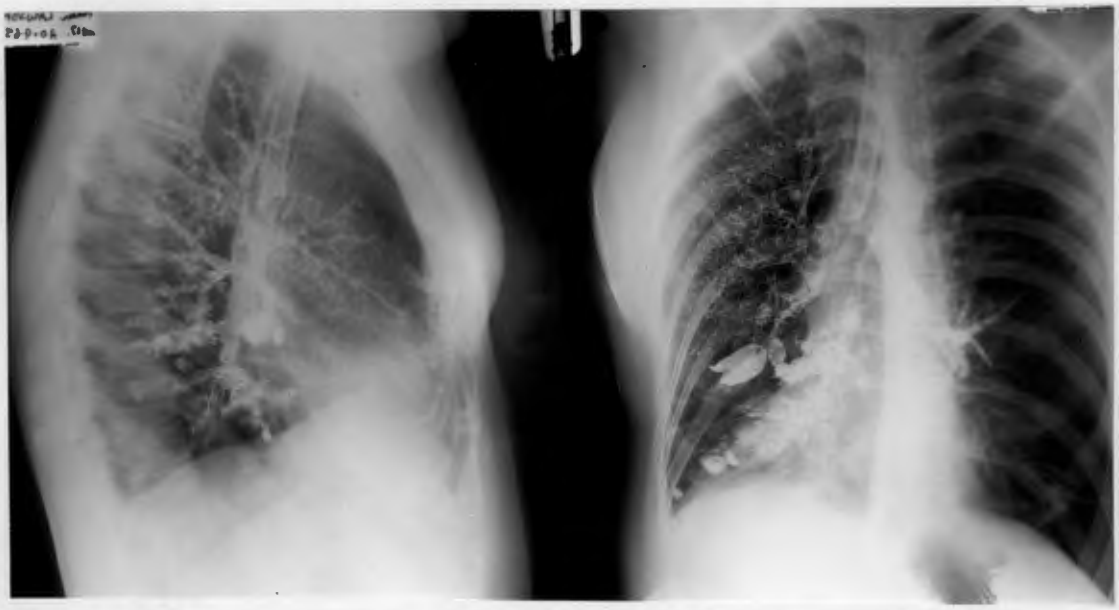

B

C

D

Fig. 80

Bronchiectasis of the middle and lower lobes on the right and of the left basal segments and the lower half of the lingular segment of the left upper lobe was managed in the patient whose films these are by bilateral resection despite her age (45 years) and the recognition of cystic spaces anteriorly in the right upper lobe, because of the severity of symptoms and because the lung planned for resection was shrunken. (Case 5)

A B

C D

Fig. 81

Post-operative bronchograms made after completion of bilateral resection of bronchiectasis in the patient whose pre-operative films are shown as Fig. 80. The cysts in the right anterior segment are clear in the lateral film (A), in the middle of the hemithorax just above the diaphragm. The remaining bronchi are normal. (Case 5)

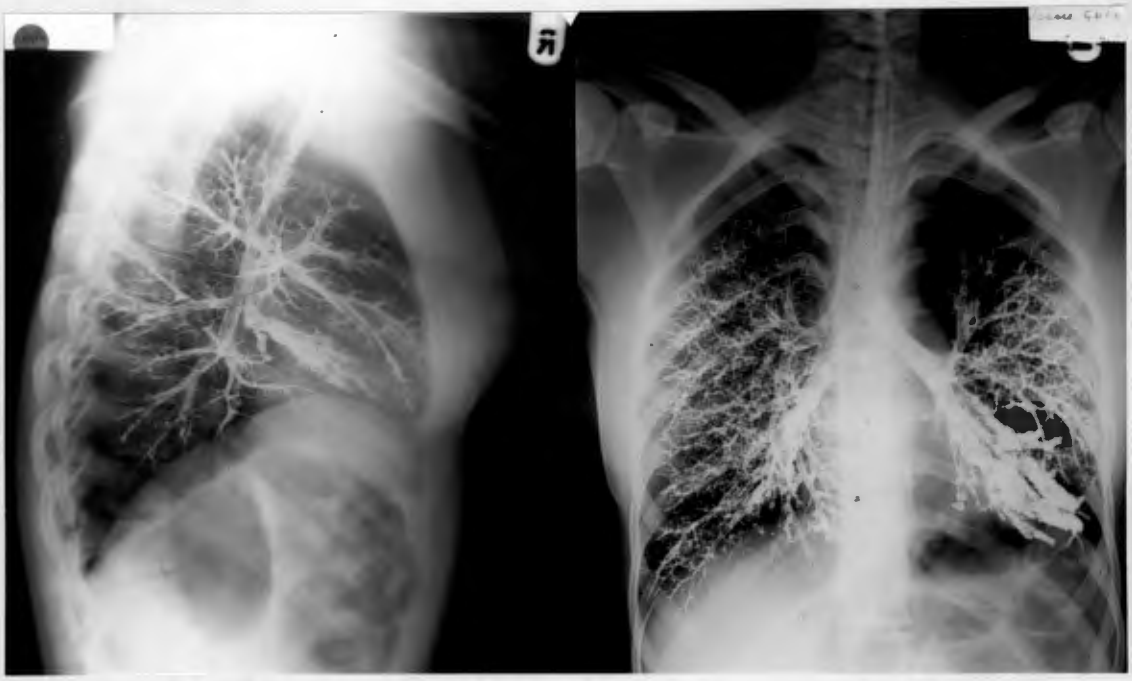

A B

C D

Fig. 82

Bronchiectasis of the middle lobe and of the medial basal segment of the right lower lobe is associated with bronchiectasis of the lingular segment of a left upper lobe in which the anatomical arrangement is dichotonous , and of the left basal segments. Management was by resection and the patient whose films these are is well. (Case 37)

A

B

C

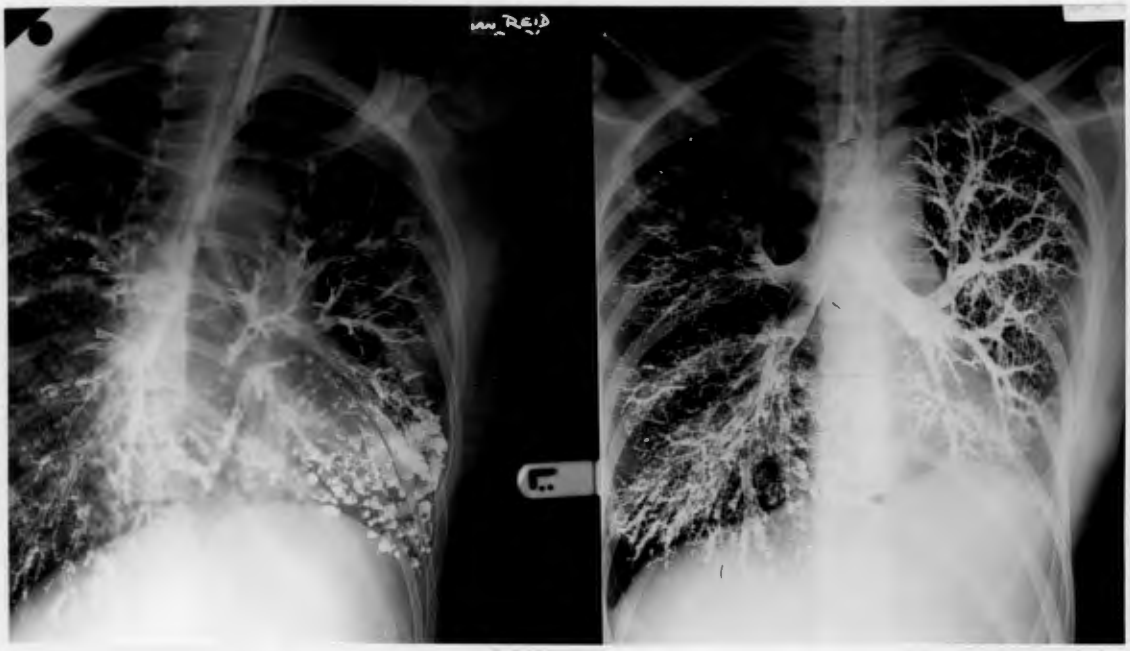

D

Fig. 83

Bronchiectasis of the left basal segments and the lower half of the lingular segment is associated with bronchiectasis of the lateral segment of the middle lobe and the medial and posterior basal segments of the right lower lobe; management was by resection. The right-sided disease can be identified in (A), (B) & (D), this last a film made after the left resection had been completed and before right thoracotomy. (Case 38)

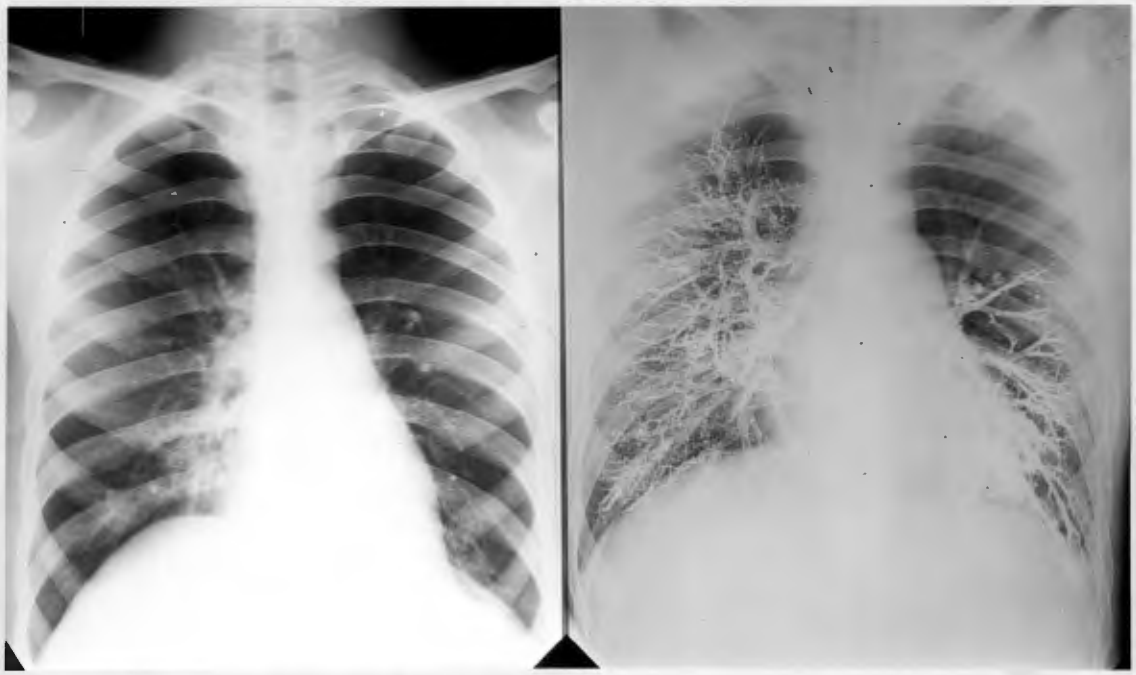

A B

C D

Fig. 84

Bronchiectasis of the left lower lobe and of the lower half of the lingular segment (B & D) is associated with middle lobar bronchiectasis (C). In the patient whose films these are the medial basal segment was found, at right thoracotomy, to be shrunken and rubbery and was resected with the middle lobe. The patient is well after bilateral resection. (Case 20)

A

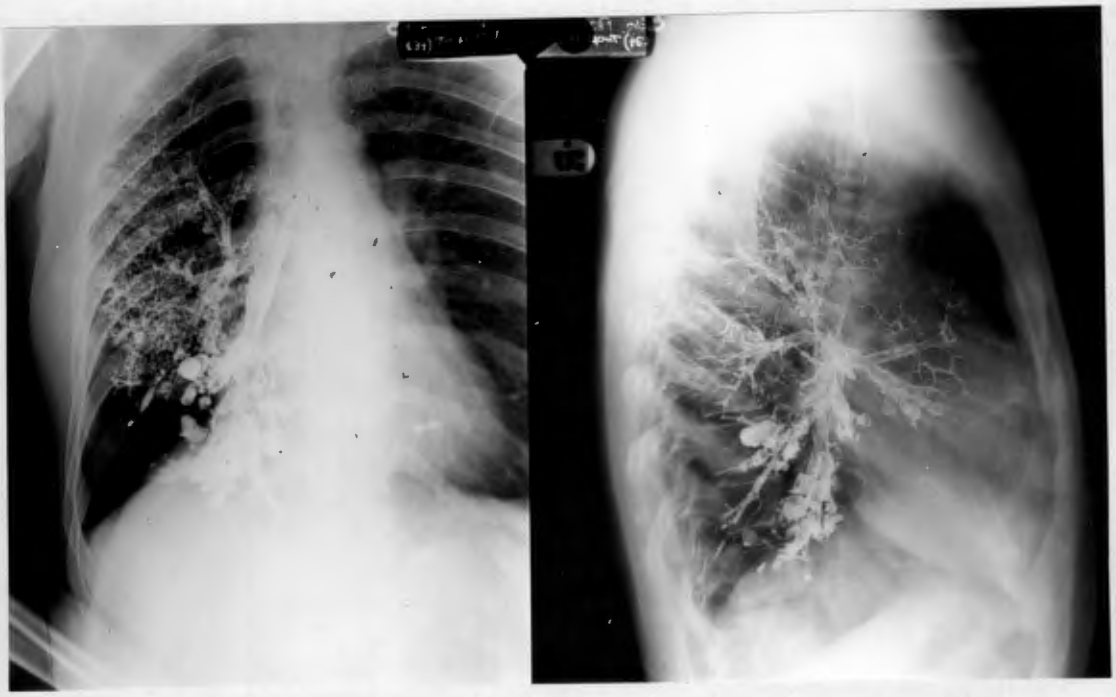

B

C

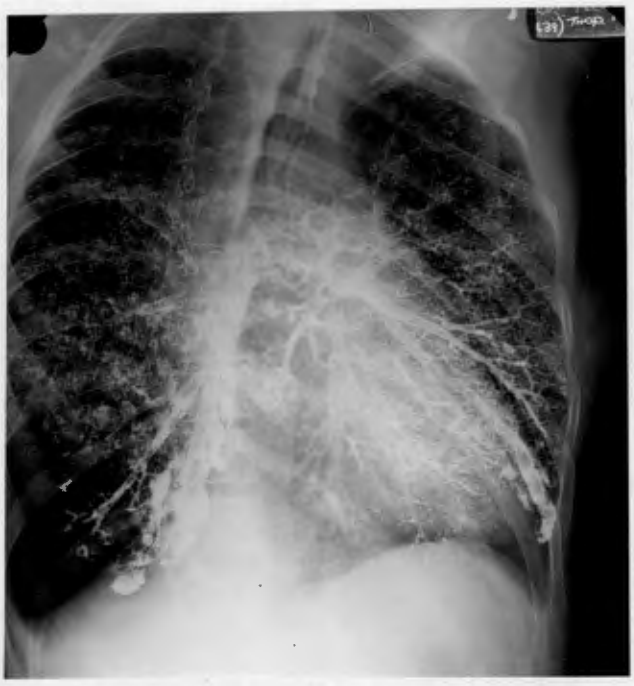

Fig. 85

Bronchiectasis of the middle and lower lobes on the right is here associated with with bronchiectasis of the right anterior segment and bronchiectasis of the lower half of the lingular segment of the left upper lobe, the bronchi in which are arranged dichotonously. Bilateral resection was undertaken. (case 42)

A

B

C

Fig. 86

Bilateral bronchiectasis in the patient whose films these are was managed first by right and then by left basal segmental resection. Only one of the four right basal segments was normal and this was detached from the apical segment of the lower lobe; it was thought unwise to leave it. The bronchograms (B) & (C) were made before the second resection was undertaken and show clearly the left basal bronchiectasis and the bronchi of the apical segments of both lower lobes, the right devoid of basal segments. (Case 46).

Bilateral Bronchiectasis Within Surgical Limits but Managed Conservatively

In this group there are 49 patients - 27 females and 22 males. Details which relate to these patients are shown in Table XII. That the number of patients corresponds precisely with the number submitted to bilateral resection is fortuitous. The permutations of lobar and segmental bronchiectasis on the two sides, while roughly similar in the resected and unresected groups, illustrate some noteworthy differences which are probably not significant - for example, the commonest combination of bilateral bronchiectasis within surgical limits but not resected is bilateral basal bronchiectasis, while only one example of this combination of bronchiectasis was managed by resection. The patients in the group here discussed are regarded as comparable with the group of 49 patients submitted to bilateral resection because any one of these patients, on clinical and bronchographic evidence, would be regarded as suitable for management by resection of bronchiectasis of a gross and saccular variety and a source of purulent sputum in large volumes, in shrunken lobes or segments. But four patients declined operation; five, all under the age of 50 years, had bronchospasm as well as cough with purulent sputum; and 22 patients were older than 50 years. Of the remaining 18 a final decision has not yet been reached in 10, most of them under 30 years of age at the present time, and in eight conservative management, without the need for daily postural coughing and with only very occasional recourse to chemotherapy when normally minimal symptoms are aggravated by an exacerbation of infection, has been so successful that the patients, who are now reaching the older age groups, are unlikely lightly to accept a change in management which involves bilateral thoracotomy, and such a change in management will be suggested only should they develop /

develop metastatic infection or should present management, which interferes in no way with their normal daily life, cease to be effective.

TABLE XII

BILATERAL BRONCHIECTASIS WITHIN SURGICAL LIMITS BUT MANAGED CONSERVATIVELY

Extent of Bronchiectasis: Right	Extent of Bronchiectasis: Left	Number of Patients	Ages
Basal Segments	Basal segments	7	27*/31*/32/51/53/56/60/
Lower Lobe	Lower Lobe	5	1[illegible]*/48/51/57/61/
Middle Lobe	Lower Lobe & lingular	4	12/59/59/62/
Middle Lobe & basal Segments	Lower Lobe & lingular	3	8/10/59
Basal Segments	Lower Lobe & lingular	3	51/53/67
Middle Lobe	Lingular segment	3	11/50/61
Upper Lobe	Upper Lobe	3	28@/32/[illegible]/50
Middle & Lower Lobes	Lower Lobe & lingular	2	32/40@/
Middle Lobe	Upper Lobe	2	28/58
Upper Lobe	Lower Lobe	2	41*/52
Middle Lobe & apical seg. of lower lobe	Upper Lobe	2	47/63
Middle Lobe & anterior seg. of upper lobe	Lower Lobe	2	36/45
Middle & Lower Lobes	Lingular Segment	1	61
Middle Lobe	Basal segments	1	17
Middle lobe & basal segments	Lower lobe	1	41
Basal Segments	Basal segs. & lingular	1	17
Upper Lobe	Lingular segment	1	36
Posterior basal seg.	Posterior basal seg.	1	44
Middle lobe, anterior & ant. basal seg.	Lingular segment	1	68
Apical lower seg.	Lingular segment	1	56
Middle lobe & post. seg.	Anterior basal seg.	1	46@
Posterior basal seg.	Lower Lobe	1	49@
Medial basal seg.	Lower lobe & lingular	1	50
Total		49	

Total: 49

Females: 27
Males: 22

Youngest: 8 yrs.
Oldest: 68 yrs.

Under 11 - 2 patients
11 - 20 - 5
21 - 30 - 3
31 - 40 - 7
41 - 50 - 10
51 - 60 - 15
61 - 70 - 7

32 patients over 40 years of age

22 patients over 50 years of age

* Declined operation (4)

@ Asthmatic (5) - all under 50 years.

A

B

C

Fig. 87

Bronchiectasis of the middle lobe and of the medial basal segment of the right lower lobe (A & B) is here associated with gross saccular bronchiectasis of the left lower lobe and bronchographically less gross bronchiectasis of the lingular segment. Furthermore, there is little doubt in (B) regarding the presence of bronchiectasis in part of the left "anterior" segment of international nomenclature. Symptoms in the patient whose films these are are severe; hesitation regarding recourse to surgical management stems from the extent of left-sided resection necessary to ablate completely the demonstrated bronchiectasis. This patient may well be managed in the future by a left-sided "sump" resection, but with the presence and extent of right-sided bronchiectasis clearly recognised before operation. In the era of surgical enthusiasm with poor bronchographic technique left lower lobectomy would have been undertaken and this would have been called a surgical failu

A

B

C

Fig. 88

Bronchiectasis of the middle lobe and of the basal segments of the right lower lobe is, in these films, associated with bronchiectasis of at least the left basal segments and the lingular segment of the left upper lobe. The child whose radiographs these are is young and the quality of bronchography not good. Conservative management will be pursued until the severity of symptoms has been evaluated and until better bronchograms have been made, but bilateral resection will probably be undertaken.

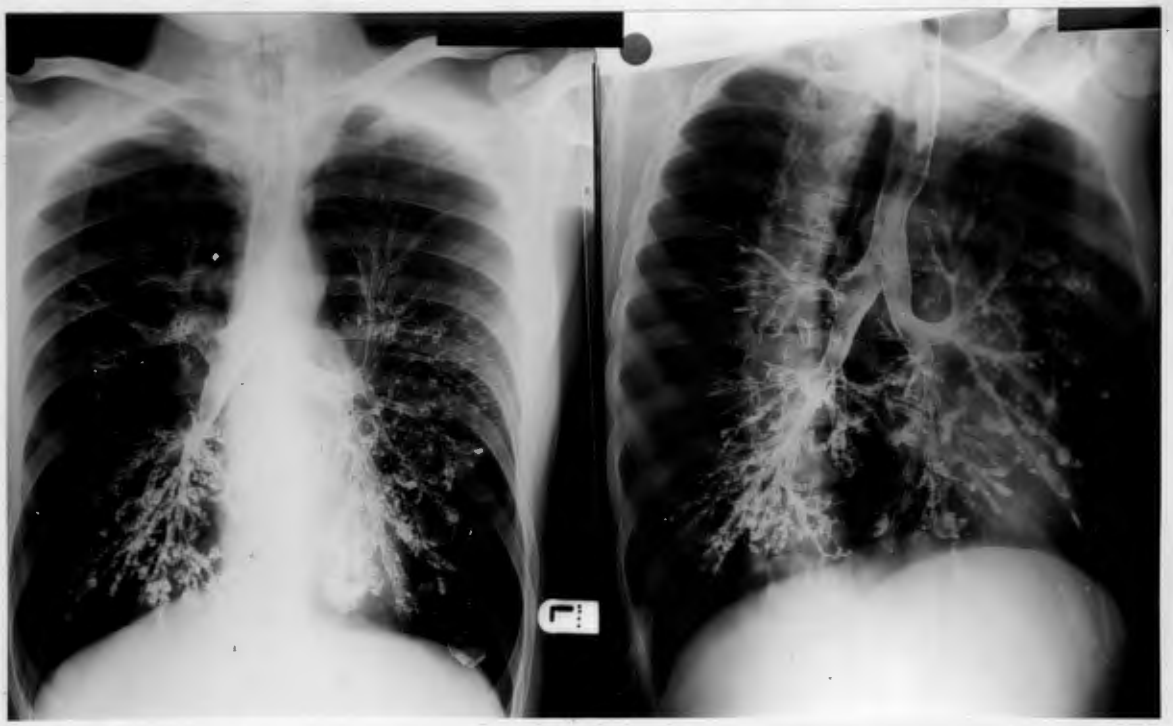

A B

C D

Fig. 89

Bronchiectasis of the middle and lower lobes on the right and of the lower lobe and lingular segment on the left in two patients - one elderly and one with asthma - with severe symptoms despite which resection has not been contemplated.

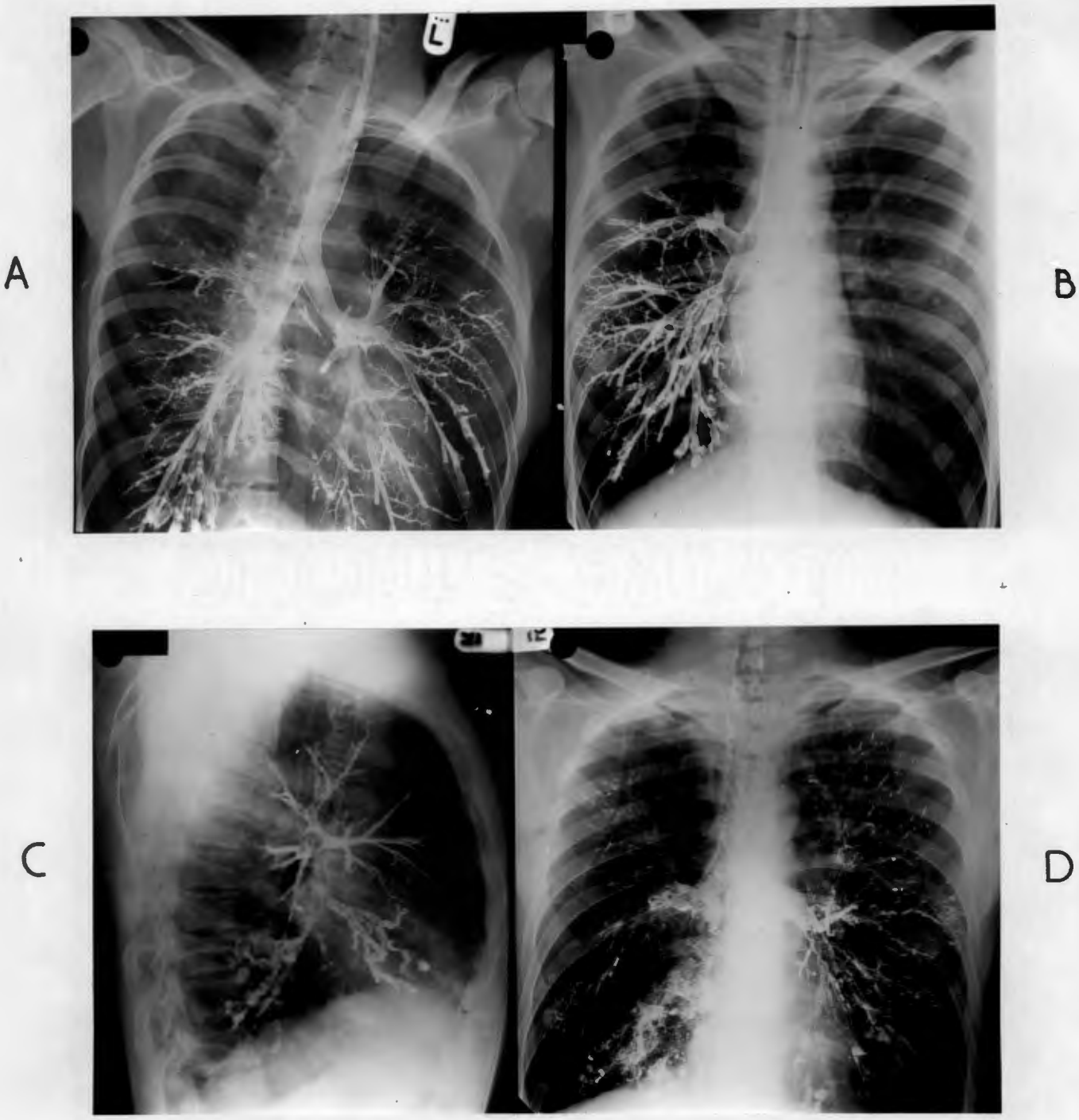

Fig. 90

Bronchograms from two patients with bilateral bronchiectasis are illustrated. In (A) & (B) the lower half of the lingular segment and the middle lobe and right basal segments are abnormal. The bronchi are spidery and the patient whose films these are was clearly bronchitic. The extent of bronchiectasis in (C) & (D) is greater - only the upper lobe is normal on the right and the left basal bronchi are bronchiectatic. In this patient age and relative paucity of symptoms has, so far, prompted conservative management.

Bronchiectasis Too Extensive for Resection

In this group there were 165 patients - 85 males and 60 females. Details which relate to these patients are shown in Table XXII. In 88 patients bronchiectasis was total - no normal segment was demonstrated bronchographically. Fourteen of these 88 patients have died from infection in the period under review - eight from acute respiratory infection, three children with septicaemia, and three from cerebral infection, ventriculitis in two and multiple cerebral abscesses in one. In 31 patients total unilateral bronchiectasis, left-sided in 18 and right-sided in 13, was shown to be associated with extensive contra-lateral bronchiectasis, most extensive in one patient in whom the only normal segment was the lingula. Three of these 31 patients presented because of empyema thoracis and two with the clinical features of hypertrophic pulmonary osteoarthropathy; four have died, one with amyloid disease and three from acute respiratory infection.

In 36 patients middle and lower lobar bronchiectasis on the right is associated with left lower lobar bronchiectasis and bronchiectasis of the lingular segment of the left upper lobe. These patients were regarded as unsuitable for management by resection because in none was the bronchiectasis in significantly shrunken lung, respiratory function was limited, and resection would have left these patients with only an upper lobe of normal size on the right and an upper lobe diminished by resection of the lingular segment on the left. These small volumes of lung would have had to fill hemithoraces of normal size and the inevitable pulmonary distension which would have resulted would, it was judged, have made these patients respiratory cripples. The important difference between these 36 patients/

patients and those in whom bronchiectasis of similar extent, or very nearly similar extent, was managed by resection was the state of the lung subtended by the abnormal bronchi. Middle and lower lobectomy on the right and lower lobectomy and linguloctomy on the left were undertaken only when these volumes of lung were small, shrunken, airless pus sacks found in patients in whom aerated lung filled very nearly completely hemithoracies of normal size. Six of the 36 patients were under 11 years of age, the youngest was seven, and one of these children has died from respiratory infection. The oldest patient in this group was 57 years and presented with an empyema. Three other patients in this group of 36 have died, one with cor pulmonale, one with respiratory infection and one from an undetermined cause.

Bronchiectasis of the left lower lobe and the lingular segment of the left upper lobe was associated in seven patients with bronchiectasis of the middle and lower lobes and the anterior segment of the right upper lobe. All these patients were men and two have died, one with brain abscess and one with cor pulmonale. In the last three patients in this group of 165, bronchiectasis was of an extent similar to that in the last-mentioned seven but of different distribution.

TABLE XIII

BRONCHIECTASIS TOO EXTENSIVE FOR RESECTION

DISTRIBUTION		No. of	SEX		AGE	COMMENTS
Right	Left	Patients	Male	Female		
Total	Total	88	40	48	1st decade - 15 2nd 16 3rd 11 4th 18 5th 13 6th 15	Youngest a girl of 2yr Oldest 2 women of 58. Empyema in 2. 14 have died - 3 in 1st decade 2 4th 3 5th 6 6th
Total	Basal Segs.	2	1	1	32: 35	
	Upper Lobe	2		2	23: 59	
	Lower Lobe & Lingular	4	2	2	28: 30: 38: 42	
	Lower Lobe	4	3	1	20: 34: 48: 53*	
	All but Ling.	1		1	37	
Lower Lobe		3	2	1	8: 9: 37	4 have died Empyema in 3
Middle & Lower Lobes		8	5	3	6: 8: 8: 31: 37 40: 47: 56	* with osteoarthropathy
Middle Lobe & Basal Segs.		1		1	35	
Upper Lobe	Total	2	2	~~5~~	39*: 55	
Upper & Middle Lobes		3	1	2	3: 43: 62	
Basal Segs.		1	1		67	
		31				
Middle & Lower Lobes	Lower Lobe & Lingular segment	36	19	17	1st decade - 6 2nd 6 3rd 8 4th 7 5th 7 6th 2	Youngest aged 7 has died. Oldest, 57 had empyema 3 others have died
Middle & Lower lobes & Anterior Segment	Lower Lobe & Lingular segment	7	7		7: 30: 32: 32: 44: 46: 50	
As Above	Lower Lobe only	1	1		42	2 have died
Upper & Lower Lobes	Lower Lobe & Lingular segment	1		1	35	
As Above	Basal Segs. & Lingular	1	1		8	

Total - 165 Males - 85 Females - 80 24 have died

Scattered or Doubtful Bronchiectasis

Bronchiectasis in 36 patients was diffusely scattered, but not total, or its existence doubtful on available bronchograms. Sixteen of these patients were under the age of ten and all but five were under the age of 40 years. Twenty were female and 16 were males. Six of these 36 patients, including the five over 40 years, gave a history of frequent and severe episodes of bronchospasm, and in all the children there was a history of wheeze during frequent episodes of acute respiratory infection. In all these patients there is a bronchographic abnormality. In ten of them none of the bronchi is normal but none is clearly outlined and where bronchi are dilated, dilatation is irregular and scattered. In 14 the bronchi are widely spaced, and dilatations are scattered amongst bronchi which are abnormally narrow and spidery. In 12 there are some normal bronchi and cylindrically dilated bronchi are widely scattered amongst the five lobes in a haphazard arrangement not comparable with any of the regularly recurring combinations of bronchiectasis previously described.

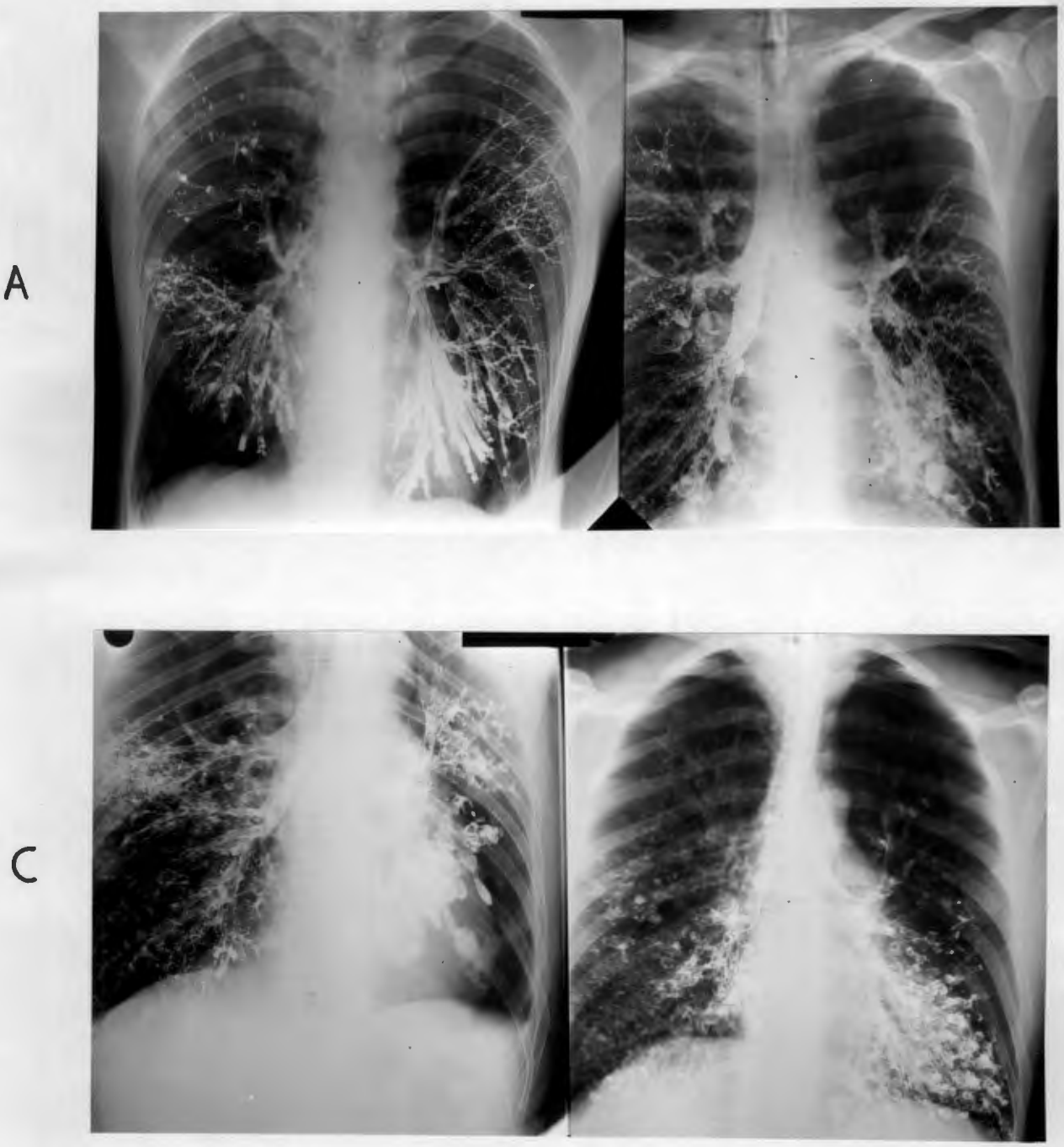

Fig. 91

The bronchograms shown above demonstrate extensive bronchiectasis in four different patients outwith the anatomical limits of surgical management. In the patient whose film is (A) left pneumonectomy would have been required, there is right basal bronchiectasis, and function was poor. In (B) all of both lungs is abnormal. In (C) half the left upper lobe and half the middle lobe may be normal; the remainder is bronchiectatic. In (D) the apical segments of the upper lobes are the only bronchographically normal bronchi shown .

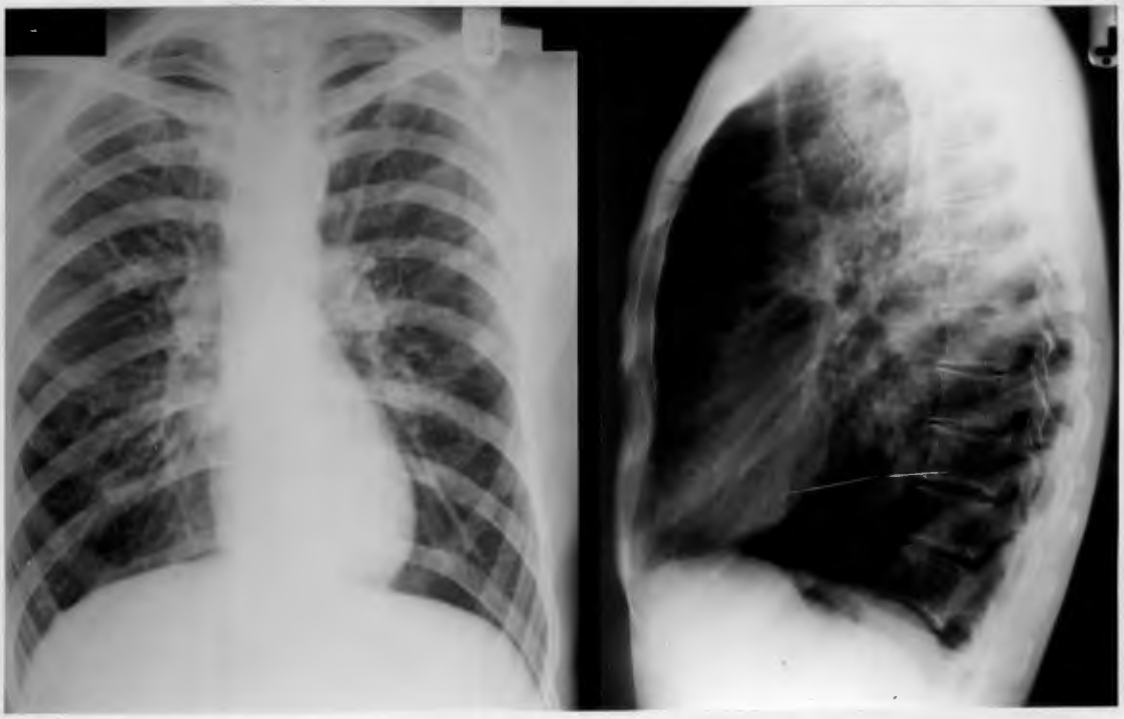

A B

C D

Fig. 92

Bronchiectasis which includes nearly the whole of both lungs and which is unsuitable for surgical management is illustrated (C & D). Deficiencies of bronchographic technique are most common when bronchiectasis is gross and extensive. The bronchiectasis demonstrated above is distributed in areas of lung most commonly the site of pulmonary tuberculosis - the upper lobes and the apices of the lower lobes - and this is post-tuberculous bronchiectasis in a patient not included in this series because bronchography in him was an episode in the management of tuberculosis, not bronchiectasis.

A

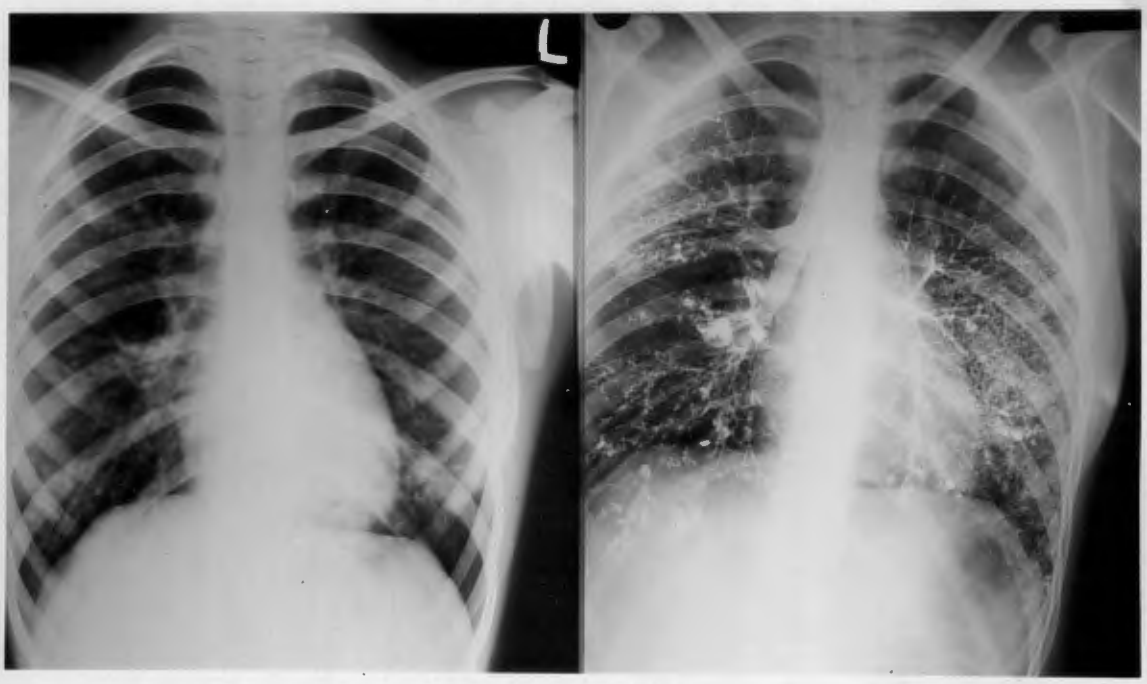

B

C

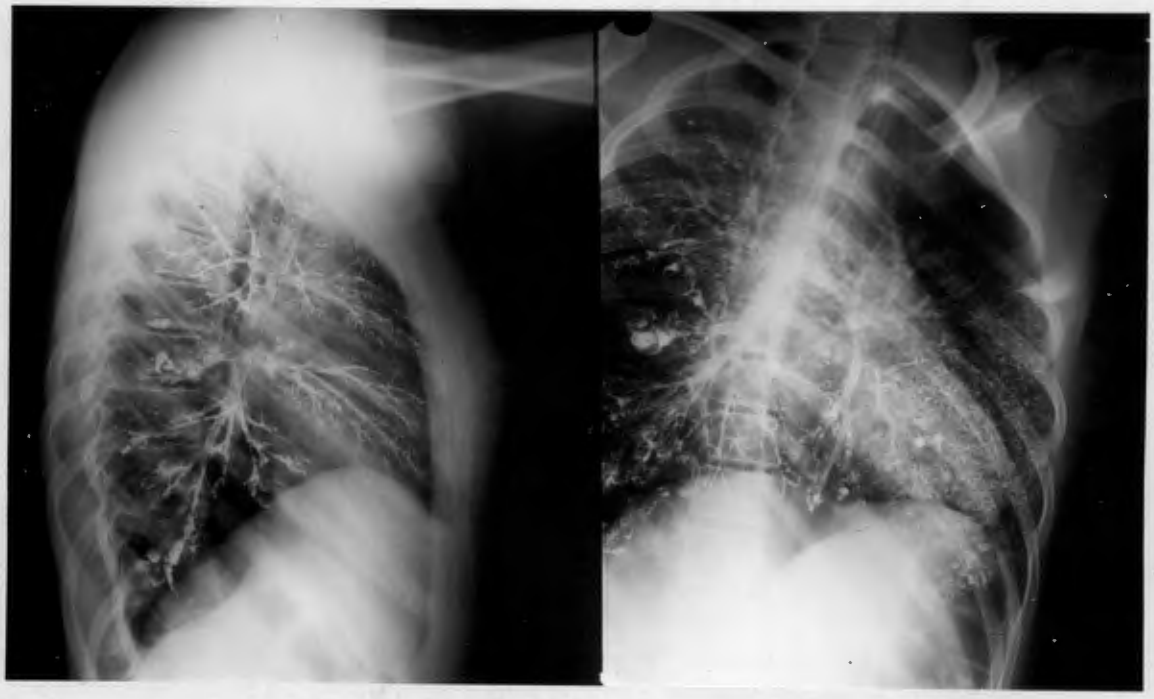

D

Fig. 93

Scattered bilateral bronchiectasis of a disposition anatomically unsuited to surgical management in a patient with asthma.

A

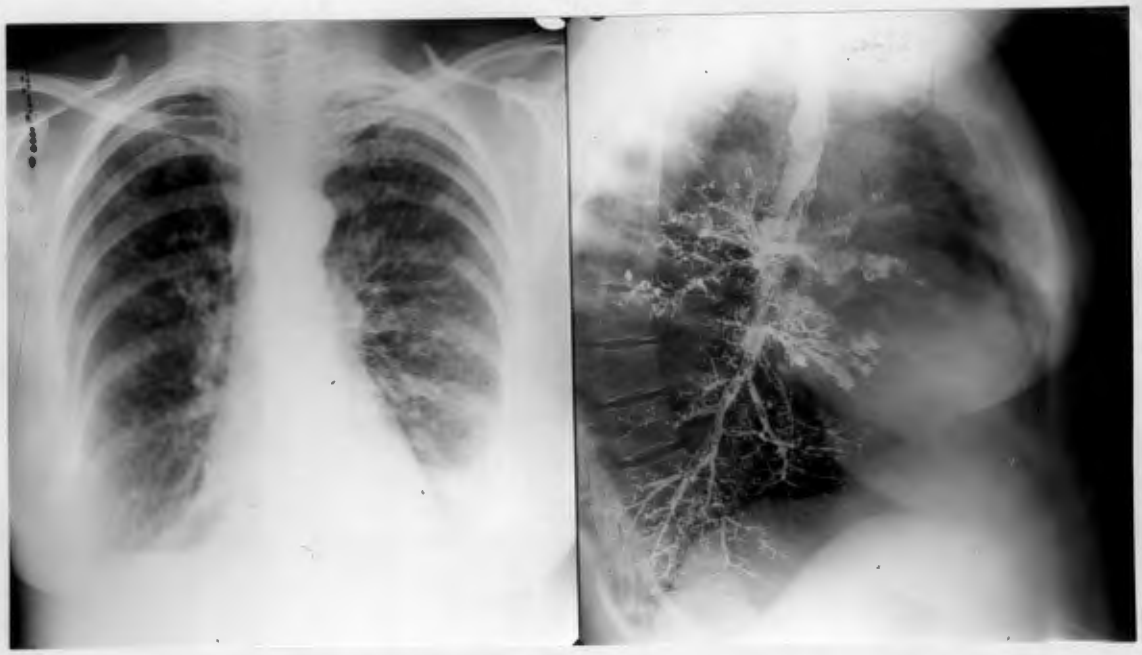

B

C

D

Fig. 94

Scattered bronchiectasis which includes most of the upper lobes and the middle lobe can be seen in the bronchograms (B), (C) & (D). Neither apical lower segment is adequately demonstrated. Asthma, and the anatomical distribution of the disease made the patient whose films these are unsuitable for surgical management.

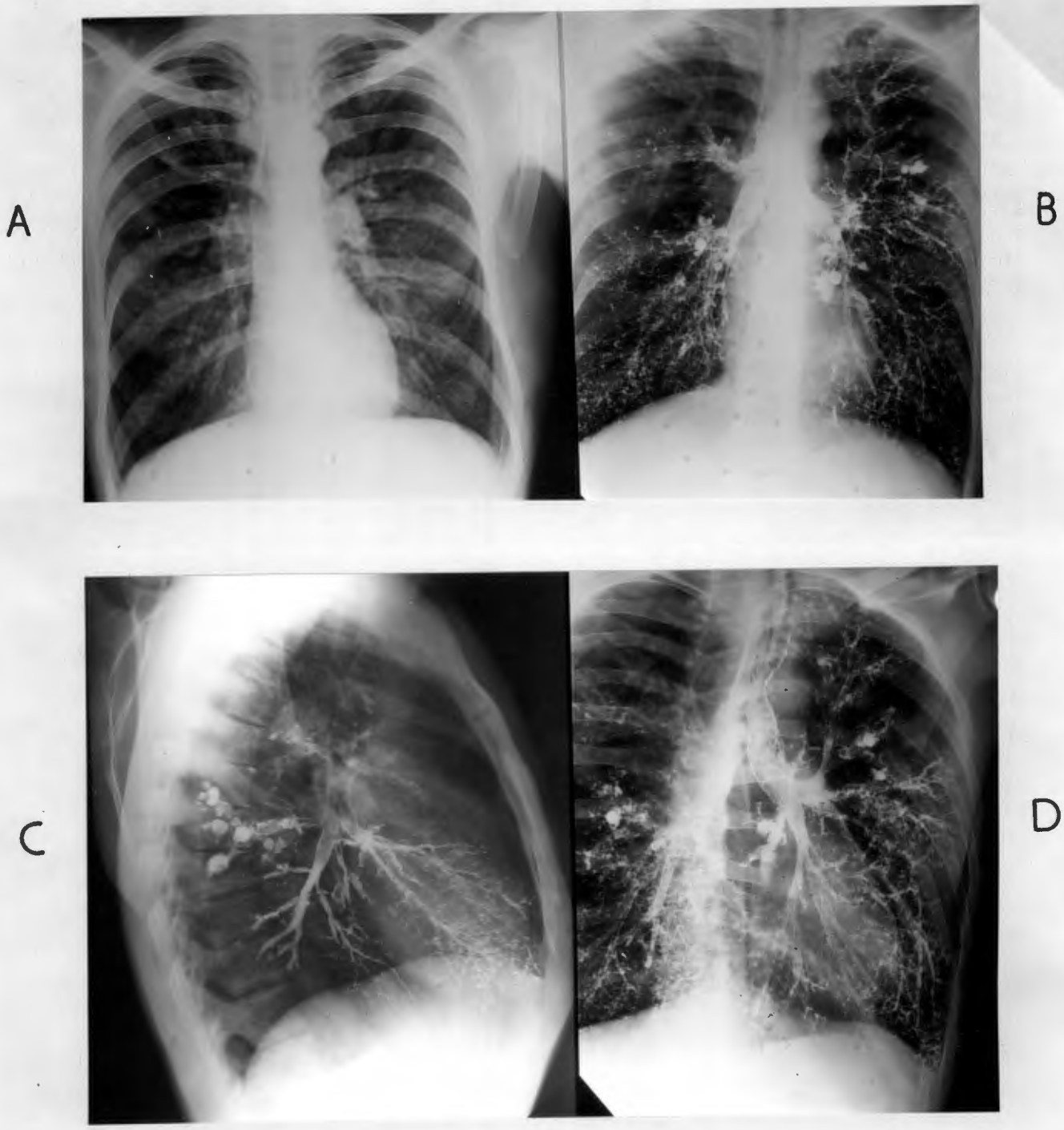

Fig. 95

Scattered bilateral bronchiectasis in a patient with asthma; the bronchiectasis is, in any event, of an anatomical distribution unsuitable for surgical management, since it is of the scattered uni-segmental variety.

A

B

C

D

Fig. 96

In the right-sided bronchogram (A) & (B) only one segment of the upper lobe is normal - the apical. Surgical management in this patient would therefore involve pneumonectomy if right-sided bronchiectasis is to be resected - and there was left-sided bronchiectasis, although this was bronchographically unimpressive. In a patient such as the one whose films these are there may be a place for resection of a bronchiectatic "sump". Right-sided bronchiectasis of the same extent (C) in another patient is associated with extensive left saccular bronchiectasis; bronchiectasis in this case is outwith surgical limits.

A B

C

Fig. 97

Total left bronchiectasis (C) is, in this series of bronchograms, associated with at least right posterior segmental bronchiectasis. This is another instance where management by resection of the left-sided "sump", on bronchographic evidence alone, appears reasonable, but the patient's age and dyspnoea have prompted conservative treatment.

A

B

C

Fig. 98

Total left bronchiectasis with at least middle lobe bronchiectasis can be recognised in the bronchograms (A) & (B). The patient, whose plain film is (C), has died from pulmonary infection.

CHAPTER V

THE PLACE OF SURGERY IN THE MANAGEMENT OF BRONCHIECTASIS

The Original Plan and its Modifications

The place of surgery in the management of bronchiectasis as originally planned was outlined earlier. Management of bronchiectasis by resection was to be recommended to all patients whose symptoms could be attributed only to bronchiectasis and in whom the disease was unilateral or, if bilateral, limited to shrunken lobes and segments devoid of respiratory function; all demonstrable bronchiectasis should be resectable and resected; partial resections were not to be undertaken; the elderly with symptoms from surgically managable bronchiectasis would be submitted to unilateral resection but, in them , bilateral resection would not be undertaken.

It is clear from the analysis in the previous chapter that this plan was modified to accommodate some patients with gross bronchiectasis on one side and some bronchographically unimpressive contra-lateral disease by the resection of only the gross bronchiectasis. It had been argued that patients would not appreciate only a reduction in the quantity of sputum which they were producing; that the bronchographic demonstration of greater width of bronchial dilatation, and sacculation as opposed to fusiform dilatation, were not necessarily evidence of the source of most sputum, even with supporting bronchoscopic evidence, and were therefore inappropriate reasons for the resection of part of the full extent of demonstrated bronchiectasis; and that partial ablation of bronchiectasis would/

would not constitute adequate protection from metastatic infection, empyema and other local and general complications of bronchiectasis. Resection of only the bronchographically gross as opposed to all bronchiectasis was, after 1951, undertaken as a planned procedure in some patients, and, in a small number in whom bilateral resection was planned, the relief of symptoms which followed resection of the more extensive and bronchographically grosser disease was so impressive that a second resection has not been undertaken. It is not yet finally known if this modification in surgical management is justified, but in patients managed in this way resection limited to ablation of a bronchiectatic "sump" has so far proved rewarding.

It was not anticipated that the need would arise firmly to establish a diagnosis for, and therefore investigate by bronchography, patients both chronologically and physiologically old, and age alone was, therefore, not regarded, at the outset, as a contra-indication to resection of bronchiectasis; in fact a small number of patients were not managed surgically despite the demonstration of limited bronchiectasis of unilateral distribution, purely on the grounds of age in some, and in others both because of relatively advanced age and the facility with which symptoms in them could be controlled.

In other respects the plan for the surgical management of bronchiectasis was followed. Inadequacies in the standard of preliminary investigation became apparent in some patients, but with improvement in bronchographic technique since 1957 post-operative bronchography has not shown bronchiectasis where previously none was suspected.

Nearly all the patients managed surgically were investigated because of symptoms of cough and purulent sputum. Severe haemoptysis prompted investigation in 19 patients, 10 of whom required lobectomy (upper lobectomy in six and middle lobectomy /

lobectomy in four), six segmental resection and three pneumonectomy. However, in three patients pulmonary resection was undertaken not because of symptoms but in each because of a radiographic opacity which did not clear, which in one was ingravescent, and which was interpreted pre-operatively as probably related to pulmonary carcinoma. These are the only patients in whom a further aspect of the plan was modified in so far as in them resection was not undertaken specifically because of symptoms.

Results of Surgical Management of Bronchiectasis in 409 Patients

In the group of 409 patients in whom bronchiectasis was managed by resection there were three operative deaths - an operative mortality of less than 1%. Operative mortality is never negligible, but this is small. Two patients died after pneumonectomy; one of these died from haemorrhage and death in this patient was clearly the result of failure of surgical technique; the other patient did not recover consciousness after operation and, while in him death was not explained, it must be ascribed to surgical mismanagement. To ascribe the third death - from pulmonary embolism after lobar and ipsilateral segmental resection - to misfortune outwith surgical control in no way minimises it as an individual disaster and, for the very reason that it is uncontrollable, death in these circumstances, since it is always a possibility, constitutes for many a deterrent from referring patients for surgical management.

Of the remaining 406 patients eight have died. Two patients - a ten-year-old girl and a woman of 65 years - died within six months of pneumonectomy from bronchopneumonia, and three patients, one of whom had residual bronchiectasis, died 18 months, four and 11 years after pneumonectomy with cor pulmonale. Two patients died from vascular lesions - cerebral thrombosis in one and coronary thrombosis in the other - two and eleven years after lobectomy and ipsilateral segmental resection and lobectomy alone, respectively. The last late post-operative death was the result of a car accident four years after lobectomy. While it is difficult to decide how many of these deaths can be related directly or indirectly to resection of bronchiectasis in these patients, it is convenient to ascribe them all, however remotely, to surgical interference with the status quo in the individual and to class them all as unsatisfactory results of surgery; the/

the total mortality is then 2.6%. The two deaths from pulmonary infection and the three with cor pulmonale after a resection of similar extent can be related most directly to surgical management, even if resection in these patients was no more than an incident in the natural history of their disease. In this series, therefore, pneumonectomy carries the highest operative risk with two early and five late deaths in 78 resections. It is artificial to inflate to a percentage figures which relate to fewer than 100 patients, but probably necessary for purposes of comparison; the total mortality in relation to pneumonectomy is then 9% and the immediate operative mortality 2.5%.

Post-operative assessment in four patients is incomplete because they cannot now be traced; there remain for analysis 394 patients. Details which relate to these are shown in Table XIV.

Of 394 patients 365 are well and symptom-free - by independent, perhaps even hostile, assessment. Of these 365 patients, post-operative bronchograms have not been made in 65 - in 57 who had been submitted to pneumonectomy and in eight others, seven of whom had been submitted to lobectomy and one to lobar and ipsilateral segmental resection. The reasons for not making post-operative bronchograms in these eight patients have already been given; the two mentally defective patients who complete the total of nine who did not have bronchograms made after lobectomy are classified in the Table as disabled for reasons not respiratory. It has been the practice not routinely to make post-operative bronchograms after pneumonectomy; such routine bronchography would be difficult to defend since this could not in any circumstances be classified as an investigation undertaken in the interests of a symptomless patient, because a further resection would not be contemplated. Moreover, an investigation is never without risk, and the risk of bronchography/

TABLE XIV

RESECTION OF BRONCHIECTASIS IN 409 PATIENTS

RESULTS

Results	Extent of Resection & Number of Patients				
	Pneumonectomy (78)	Lobectomy (135)	Lobe & Ipsilateral Segmental Resection (76)	Segmental Resection (71)	Bilatera Resecti (49)
Operative Death (3)	2	-	1	-	-
Late Death (8)	5	2	1	-	-
Well with Normal Bronchogram (258)	-	109	53	59	37
Well : No post-operative Bronchogram (65)	57	7	1	-	-
Well with residual bronchiectasis					
i)known to exist before op.(33)	5	2	18	7	1
ii)found post-operatively (9)	-	6	-	-	3
Untraced (4)	2	2	-	-	-
Still with Respiratory Symptoms(25)	6	4	2	5	8
Disabled for Non-Respiratory Reasons (4)	1	3	-	-	-

bronchography must be increased if only one lung remains. In 33 of the 365 patients who are well the presence of contra-lateral bronchiectasis beyond that which it was planned or found necessary to reseet was known before operation; in nine patients who are well residual bronchiectasis not known previously to be present was demonstrated post-operatively, but in none of these nine was the pre-operative bronchogram, on retrospective scrutiny, adequate, and in none has bronchiectasis been shown where normal bronchi had previously been outlined. The results of surgical management in 394 patients may, therefore, be said to be in every way satisfactory in 66% (258 patients); satisfactory, despite the absence of post-operative bronchographic evidence of normality in 65 patients, in 82% (325 patients); and satisfactory, despite the absence of post-operative bronchographic evidence of normality in 65 patients and residual bronchiectasis in a further 42, in 92% (365 patients). Just as there is "no virtue in producing a normal bronchographic appearance if a patient continues to have cough, sputum and bronchospasm" so is there no justification for not acknowledging the success of an operation which relieves symptoms because an acceptable state of bronchographic tidiness has either not been demonstrated or not been achieved.

Four patients cannot be classified as well because of collateral disease - mental deficiency in two whose mental state is such that an assessment of improvement is difficult but in whom respiratory symptoms no longer complicate institutional care, contra-lateral bronchial carcinoma in one (these three had all been submitted to lobectomy), and suspected but yet unproven amyloid disease in the fourth, who has residual bronchiectasis after pneumonectomy but who denies respiratory symptoms.

Respiratory/

Respiratory symptoms persist in 25 patients. In six of these pneumonectomy had been undertaken; of these six, two (one with residual bronchiectasis) are severely handicapped by dyspnoea and have cor pulmonale, and life in the other four is importantly modified by episodes of bronchitis. In four others of the 25 patients in whom respiratory symptoms persist after surgical management of bronchiectasis, lobectomy had been undertaken; in one of these lobectomy was part of a planned bilateral procedure the second part of which has not been completed because the patient does not wish further to submit to thoracotomy; two patients have episodes of bronchitis in the winter but are usually symptom-free; the last is emphysematous with a diminishing respiratory reserve. Two patients have respiratory symptoms after lobectomy and ipsilateral segmental resection; both were known to have bilateral bronchiectasis within the limits of surgical management before they were submitted to an operation; one declines further surgical management and one is being further assessed with a view to middle lobectomy. Of five patients submitted to segmental resection who still have respiratory symptoms, the standard of pre-operative bronchography in three was clearly inadequate, and two of these will probably be submitted to another operation; in the third bronchiectasis is, and always was, outwith the scope of surgical management, and in this patient failure to recognise the inadequacy of pre-operative bronchograms resulted in a gross error in selection for surgical management. Of the two other patients submitted to segmental resection who still have respiratory symptoms, one has severe asthma and one probably has pulmonary eosinophilia. Of eight patients with respiratory symptoms which have persisted after bilateral resection/

resection, four are included in the group of unsatisfactory results because they have episodes of bronchitis each winter, and two, who have residual bronchiectasis, because they are a little breathless; these six patients are unequivocally less often and very much less severely unwell than before completion of surgical management. In the last two patients symptoms are not only unrelieved by resection but are ingravescent, with bronchospasm as an additional burden. Selection for management by resection in one of these last-mentioned two was, in retrospect, clearly a gross and avoidable error of judgement; not obviously so in the other.

It is possible to set aside some of these 25 unsatisfactory results because they do not necessarily reflect on either surgical technique or judgement. Thus, from a scrutiny of the bronchograms of the six patients with respiratory symptoms after pneumonectomy, it is difficult to imagine that they could be any better had each retained the resected lung, so little space did it occupy, so completely was it destroyed, and so large was the volume of purulent sputum each was producing; and furthermore, pneumonectomy has corrected what, in them, was in effect an arterio-venous fistula in the pulmonary circuit. Planned bilateral resection was twice frustrated by withdrawl of confidence by the patients - perhaps these represent surgical failures because the attitude of these patients should have been appreciated and they should have been differently handled from the start. In three patients symptoms may yet be relieved by a further operation; pre-operative assessment in two of these was inadequate. In nine patients symptoms are slight, and they were severe before operation; in them it must remain a matter of opinion whether or not surgical management has failed completely, and of conjecture whether or not/

not they would have been as well if they had never been submitted to resection of bronchiectasis. The patient with asthma has a new set of symptoms and has been cured of haemoptysis; asthma may be precipitated by thoracotomy. The patient with pulmonary eosinophilia probably had this at the time of her first investigation and in her bronchiectasis was probably unimportant and resection ill-judged. In the last three patients in the group of unsatisfactory results resection should not have been undertaken, and in two of the three this error was avoidable.

The Cause of Bronchiectasis in Those Managed Surgically

Bronchiectasis in 41 patients managed surgically can be related causatively to an episode in the history or associated with an abnormality found during investigation, at thoracotomy or in the resected specimen.

i) Foreign Body: (4) Bronchiectasis in two of 135 patients treated by lobectomy was related to foreign body retention; in two of 78 patients with total unilateral bronchiectasis managed by pneumonectomy there was a history of foreign body inhalation; in neither was the foreign body found at the time of investigation of respiratory symptoms; in both, the left main bronchus was stenosed.

ii) General Anaesthesia and a Previous Operation: (4) Symptoms in one patient in whom bronchiectasis was managed by pneumonectomy dated from tooth extraction, and in two patients, whose bronchiectasis was managed by lobectomy, symptoms dated from tonsillectomy in one and a gynaecological operation in the other. Bilateral resection was undertaken in one patient whose symptoms dated from a severe respiratory illness which included lung abscess and empyema and which complicated tonsillectomy.

iii) Bronchial Stenosis: (10) Bronchiectasis was demonstrated distal to a stenotic bronchus in ten patients, three of whom required pneumonectomy and seven lobectomy; the cause of bronchial stenosis in these ten patients was not established. In two other patients with bronchial stenosis there was a history of foreign body inhalation, and in a third patient with bronchial stenosis the resected lobe showed the histological features of tuberculosis, although the histological features of the stenotic area were non-specific.

iv) Tuberculosis: (11) In three patients in whom bronchiectasis was managed by pneumonectomy the resected lung was shown to be tuberculous; in a fourth patient managed for bronchiectasis by left pneumonectomy and by pericardiectomy for constrictive pericarditis a tuberculous aetiology was presumed but not proven; in a fifth patient managed by pneumonectomy for total left bronchiectasis the right upper lobe was a little shrunken and was shown radiographically to contain punctate calcification which was presumed to be evidence of healed tuberculosis, but evidence of tuberculosis was not demonstrated in the resected lung. The resected specimens in six patients in whom bronchiectasis was managed by lobectomy were shown to have the histological features of tuberculosis; one of these patients had, in addition, a stenosed bronchus presumed to be but not established as tuberculous. Tuberculosis was demonstrated in one patient managed by bilateral resection.

v) Destructive/

v) Destructive Pneumonia: (5) In five patients in whom bronchiectasis was managed by lobectomy there was a clear history of an acute pulmonary infection following which symptoms attributable to bronchiectasis persisted; in one the pulmonary infection had been shown to be a Friedlander's pneumonia; in the second a lung abscess, the site of which was later shown to be bronchiectatic, had been associated initially with an acute illness followed but not preceded by symptoms attributable to bronchiectasis; in the last three patients in this group there was a history of an unspecified pulmonary infection associated with pulmonary destruction and the slow clearing of a radiographic shadow in which there were cavities with fluid levels.

vi) Broncholith: (4) In four patients with middle lobar bronchiectasis in all of whom investigation was prompted because of haemoptysis, a broncholith was shown to be associated with bronchiectasis. The co-existance of these two lesions is probably evidence only of an aetiology common to both and possibly tuberculous, rather than evidence of a more direct relationship between cause and effect.

vii) Other Causes: (3) Unilobar bronchiectasis was associated in one patient with a large oesophagal diverticulum, and probably related to aspiration from this. In a second patient bronchiectasis was related to an oesophago-bronchial fistula presumed, from its tubular and muscular structure, to be congenital, although symptoms had developed relatively late in life. In a third patient a foregut duplication the lining of which included gastric mucosa was found at thoracotomy for left lower lobar and lingular bronchiectasis, and was related causally with the bronchiectasis.

A foreign body was accepted as the cause of bronchiectasis in four patients - one with lobar, one with total unilateral and two with segmental bronchiectasis - in whom the disease was managed conservatively. In three other patients whose total unilateral bronchiectasis was managed other than by resection an associated and probably causative lesion was found at bronchoscopy - an endo-bronchial chondro-adenoma in the right main bronchus in one and stenosis of the left main bronchus in two.

Complications/

Complications

i) Of Resection for Bronchiectasis: Early and late post-operative mortality has already been discussed. Other complications are:-

a) Membranous tracheo-bronchitis: This complicated pneumonectomy in two children and lobectomy in a third; management in two included tracheostomy; recovery in all was complete.

b) Empyema: This complicated pulmonary resection for bronchiectasis in 12 patients - in five after pneumonectomy, in five after lobectomy, in one after segmental resection and in one patient after the first of two resections for bilateral bronchiectasis; this patient presented with bronchiectasis already complicated both by lung abscess and empyema.

ii) Of Bronchiectasis: Empyema, lung abscess, septicaemia, cerebral infection or amyloid disease complicated bronchiectasis in 46 patients, and were the cause of death in eight. Acute respiratory infections were the cause of death in two patients after pneumonectomy and in 13 others in whom a resection had not been undertaken. Respiratory infection was a feature of the disease in nearly all other patients and it is difficult to label this a complication as distinct from a feature of the disease in any particular patient. Cor pulmonale was the cause of death in three patients after pneumonectomy and in four in whom resection was not undertaken; many patients, some elderly, with extensive bronchiectasis managed conservatievly, have the clinical and electro-cardiographic features of cor pulmonale.

a) Empyema: This complicated bronchiectasis as distinct from an operation for bronchiectasis in 34 patients. In 15 of these 34 patients, 10 of whom had a previous history of chronic pulmonary infection, an empyema the duration of which was probably relatively short and the contents of which were shown by aspiration to be thick, was managed by open drainage. Routine investigation, which included bronchography, during or after healing of the empyema in this group of 15 patients showed them to have bronchiectasis. In seven of them bronchiectasis was demonstrated only on the same side as the empyema, in six bronchiectasis was bilateral, and in two contra-lateral and not ipsilateral. In all fifteen patients gravity of illness at the time of their referral for a surgical/

surgical opinion was such that evacuation of pus was regarded a s a matter of urgency. Subsequent to the management of the empyema none has been submitted to resection of bronchiectasis - because of the extent of bronchiectasis in some and in others because of age, lack of symptoms or disinclination on the part of the patient. In none has empyema or other infection again complicated bronchiectasis, and most have now been observed for more than five years following management of empyema.

Ipsilateral bronchiectasis was demonstrated in 12 patients all of whom presented because of empyema but who were so little disturbed by the loculus of pleural pus which they harboured that detailed investigation could be undertaken before the pus was evacuated. In five bronchiectasis was total on the side of the empyema and pleuro-pneumonectomy was undertaken - on the rig t side in three and on the left in two. In two patients middle and lower lobectomy was combined with resection of a right empyema; in one, middle lobectomy and decortication were together undertaken; decortication in four patients was combined with, in two, left lower lobectomy, in one left lower lobectomy and linguleotomy, and in one segmental resection. Decortication with middle lobectomy and with left lower lobectomy (the first of planned bilateral resections in this patient) were complicated by post-operative empyema.

In five patients whose bronchiectasis was managed by resection and in two with bronchiectasis managed conservatively an empyema had complicated bronchiectasis many years earlier; residual evidence of empyema made resection tedious and difficult in four of these patients.

Empyema is, therefore, a complication of untreated bronchiectasis in 3% of patients, a complication of resection for bronchiectasis in 3% of patients, and a complication of resection of bronc iectasis combined with decortication of empyema in two of 12 patients.

b) Lung Abscess: This had been an episode in the previous history of five patients with bronchiectasis. In two of these bronchiectasis was managed by resection - pneumonectomy in one and segmental resection in the other. Two patients with a history of lung abscess who were shown to have lobar bronc iectasis and one with a similar history and total unilateral bronchiectasis were managed conservatively. In two of these five patients the lung abscess had been in an area of lung shown later to be bronchiectatic, and in three in an area of lung in which bronchiectasis was later not shown to be present.

c) Metastatic Infection: Three children with total bilateral bronchiectasis died from septicaemia and four patients, three of them with total bilateral bronchiectasis and one with extensive bilateral disease, died from cerebral infection, ventriculitis in three and localised cerebral abscess in one.

d) Amyloid Disease: One patient submitted to pneumonectomy for bronchiectasis is presumed to have amyloid disease because of hepatomegaly albuminuria and peripheral oedema; rectal and gum biopsy have not given histological proof of this and congo red excretion is not diagnostically abnormal. A second patient with extensive bilateral bronchiectasis unsuitable/

unsuitable for surgical management has died with amyloid disease.

e) Carcinoma Carcinoma and bronchiectasis co-existed in the resected lung in three of 78 patients in whom total unilateral bronchiectasis was managed by pneumonectomy

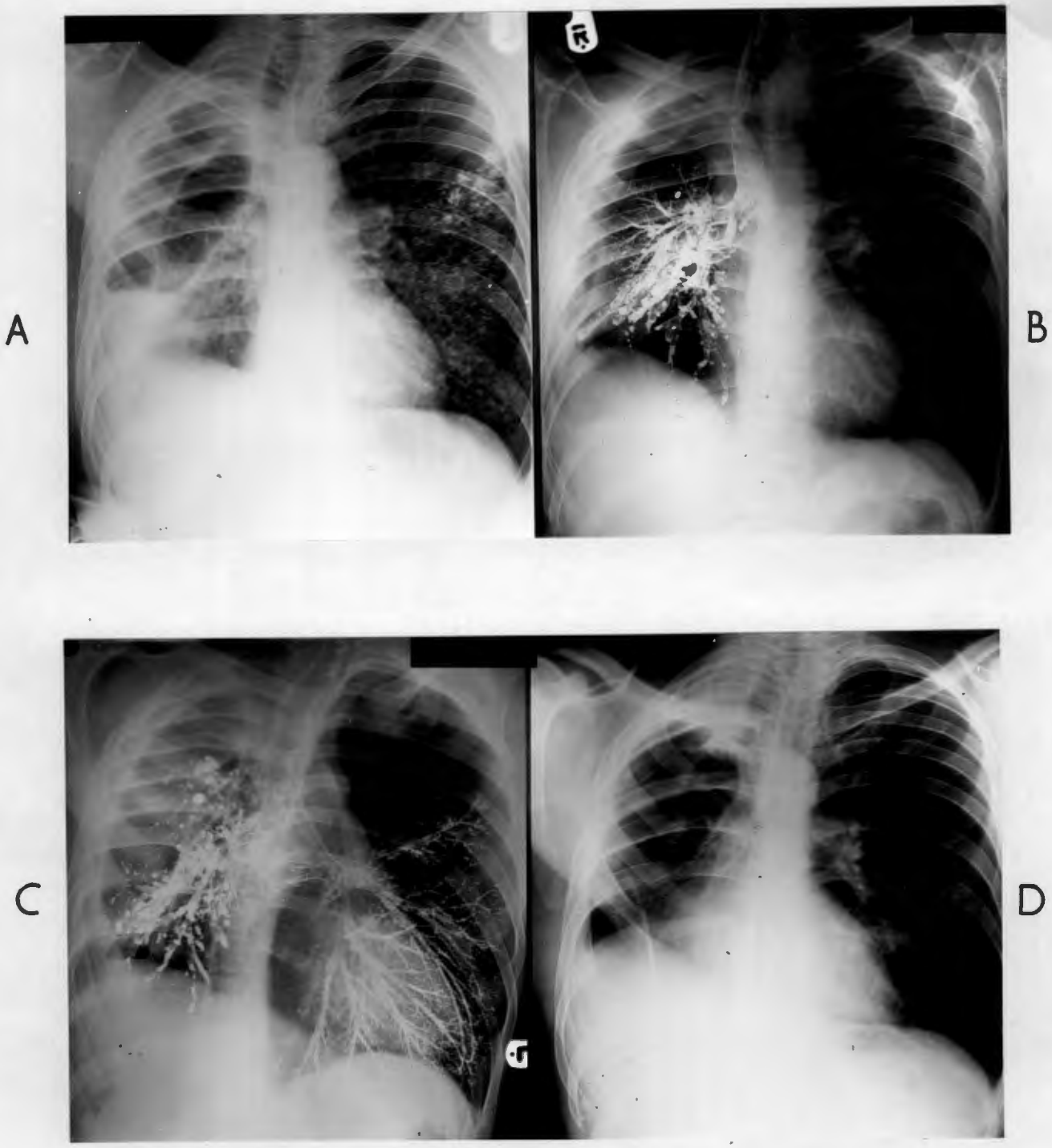

Fig. 99

In the investigation of the patient whose PA chest radiograph is shown as (A) middle and lower lobe bronchiectasis (B) was found to be associated with a right empyema. The left bronchi, as far as they were shown, were normal. Management was by middle and lower lobectomy and decortication of the empyema. A late post-operative film (D) is illustrated. The deficiencies of filling of the apical and posterior segmental bronchi of the left upper lobe in (C) were common in bronchograms made 10 years ago - deficiencies now remedied by use of the insufflation technique.

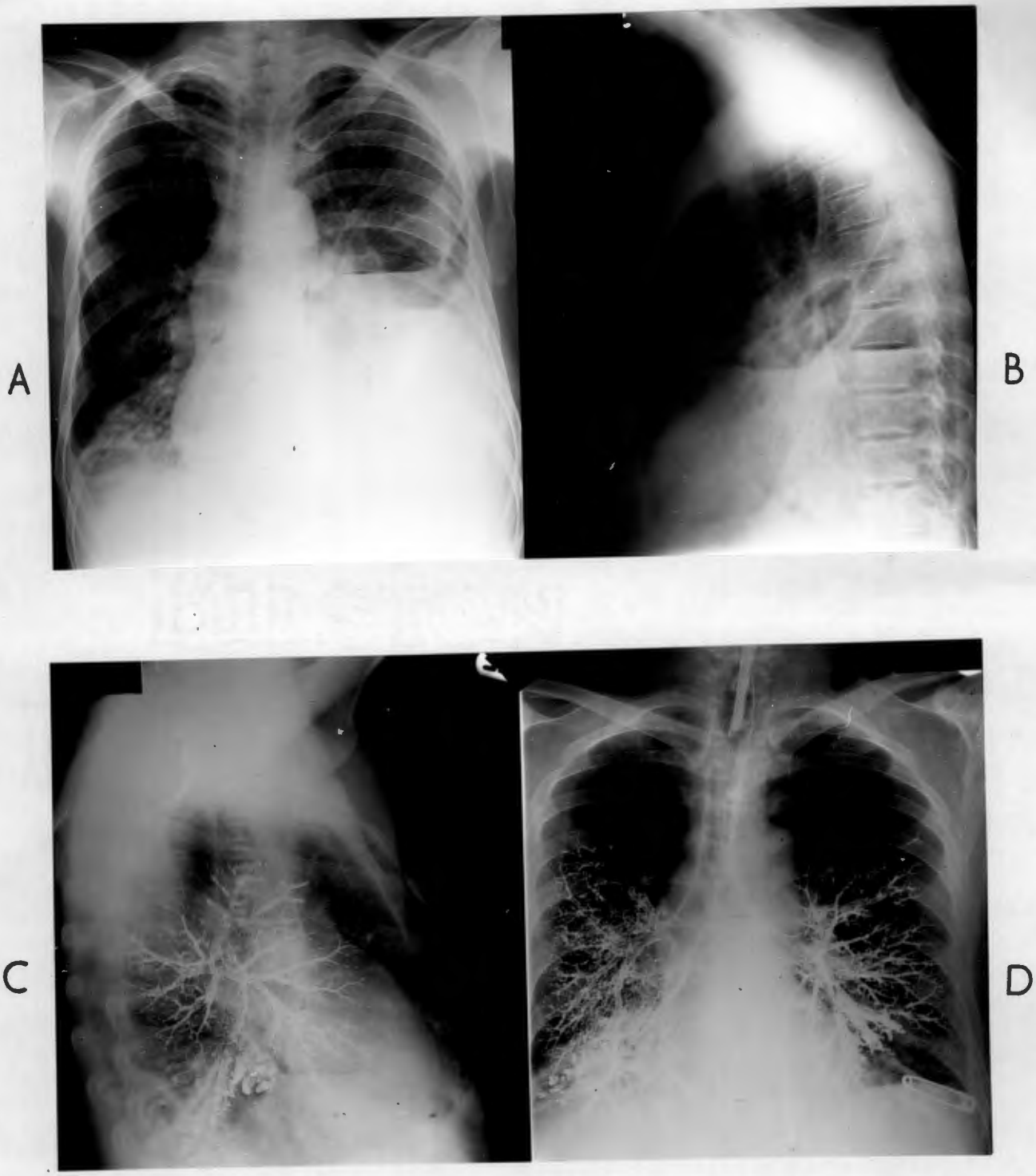

Fig. 100

A large left empyema (A & B) managed by open drainage was shown subsequently at bronchography to have developed in a patient with bronchiectasis of shrunken right middle and lower lobes. The left basal bronchi are not well filled but were, on these and other radiographs, regarded as probably normal.

Mortality Amongst Patients with Bronchiectasis Treated Medically

Of 629 patients with bronchiectasis managed other than by resection 28 have died - a mortality of 4.5%. Three patients with total unilateral bronchiectasis have died - one from the infective and vascular complications of diabetes, and two with cor pulmonale. One patient with bronchiectasis of an isolated segment died in somewhat mysterious circumstances and possibly from suicide, but in her symptoms were so slight that death can only tenuously be related to bronchiectasis. Of 165 patients with bronchiectasis outwith the limits of surgical management 24 have died - a mortality in the group of 14.5%. Death in all but one can be related directly to bronchiectasis - respiratory infection in 13, septicaemia in three, cerebral infection in four, amyloid disease in one, cor pulmonale in two. The cause of death in the last patient is unknown and may be unrelated.

The Reasons for Not Undertaking Resection in 601 Surviving Patients:

While it is a little artificial to subdivide the reasons for managing this group of patients other than by resection in such a way that only one reason is made to apply to each patient, this has the advantage of facilitating addition.

i) Declined Thoracotomy (28) Twelve patients with total unilateral bronchiectasis, six with lobar bronchiectasis, four with lobar and ipsilateral segmental bronchiectasis, two with segmental and four with bilateral bronchiectasis within anatomical limits suitable for surgical management, declined thoracotomy. It is in these patients particularly that an assessment of progress would be valuable, because they can be compared/

compared almost precisely with the patients managed by resection. But eight of the 38 cannot now be traced, having left the region, five will not attend for re-assessment, three claim to be entirely well when they attend for review, but from the general practitioner's report on each they lose working days regularly because of respiratory infection, and only 12 seem able to retain an adequate rapprochment with the surgical unit whose advice they declined, perhaps because they are genuinely wel

ii) Age: (143): Two patients with total unilateral bronchiectasis were 70 years of age. Of 141 patients over 50 years of age who were managed conservatively, 67 had lobar bronchiectasis (11 of these also had asthma), 17 had lobar and ipsilateral segmental bronchiectasis, 35 segmental and 22 bilateral bronchiectasis.

iii) Asthma: (47): Thirteen patients with lobar bronchiectasis, si with lobar and ipsilateral segmental bronchiectasis, 12 with segmental and five with bilateral bronchiectasis had asthma; these 36 patients were all younger than 50 years. Eleven patients with total unilateral bronchiectasis were managed conservatively because of poor respiratory reserve. Of these eleven patients, four younger than 50 years had severe asthma, all the remainder wheezed and were bronchitis, and two o these were older than 50 years.

iv) Bronchitis: (57): Symptoms, which included wheeze and bronchographic changes suggestive of bronchitis outwith those areas shown conclusively to be bronchiectatic, prompted conservative management in 57 patients. Of these patients bronchiectasis in 38 was limited to one or two segments, affected the middle lobe in nine patients and the middle and lower lobes together in four, and in six patients involved a lobe with a related ipsilateral segment.

v) Anatomically Unsuitable: (177): Bronchiectasis in 36 patients was diffusely scattered and in 141 was outwith the anatomical limits of surgical management.

vi) Paucity of Symptoms: (93): Symptoms in 93 patients were either regarded as so slight as not to justify surgical action, or were absent - in patients investigated because of the chance finding of a radiographic opacity, for example. In 48 of these patients bronchiectasis was lobar, in eight lobar and ipsilaterally segmental, in 19 segmental, in eight bilateral and in ten unilaterally total.

vii) Management Still Undecided: (56): Management in 56 patients is still undecided, despite prolonged observation in many, most of whom are young. Bronchiectasis in 25 of these is lobar, in 16 segmental, in ten bilateral and in five lobar and segmental. In none of these patients has the decision been made regarding the need for surgical management; parental supervision is, in many of the younger ones, such that it is difficult to assess the severity of symptoms; all have required management by chemotherapy at intervals, usually widely scattered, and in some of the older patients with whom the possibility of an operation has been discussed domestic circumstances have delayed the making of a final decision.

CONCLUSIONS REGARDING THE PLACE OF SURGERY IN THE MANAGEMENT OF BRONCHIECTASIS

The disease state to which the name bronchiectasis is attached has been shown to be variable over a wide range, both anatomically and symptomatically. If bronchiectasis in the 1038 patients reviewed in this thesis is representative of the range of the disease, it is possible to summarise its natural history in the following way :

Of /

Of every 100 patients found after investigation to have bronchiectasis the disease in

17 patients will be anatomically unsuitable for surgical management; in the remainder the anatomical extent of bronchiectasis will be within the limits defined as surgical, but

14 patients will be older than 50 years when first they are investigated, life in these patients will have been little disturbed prior to their attendance for assessment, and subsequent to investigation life in them will pursue a relatively uneventful course;

10 patients younger than 50 years will have symptoms predominantly those of bronchitis or asthma or have a respiratory reserve so poor that thoracotomy is precluded;

9 patients younger than 50 years will present either without symptoms and because of an abnormality, either clinical or radiographic, found by chance, or with symptoms so evanescent that management of any sort is not called for;

3 patients will die without an operation and probably as the direct consequence of bronchiectasis, which is usually outwith the range of surgical management, either anatomically or on the grounds of age or collateral disease; and in

47 patients the apparent severity of symptoms and the
—— anatomical extent of the disease will be such that
100 surgical management is contemplated.

Of these last-mentioned 47 patients
3 will decline thoracotomy, and in
5 a decision on the need for surgical management will be deferred so that factual evidence regarding the severity of symptoms can be obtained; most of these will be children. In
39 patients resection will be completed with the object of
— removing all bronchographically demonstrated disease in all
47 but 3 of the 39, in these 3 because it is judged that partial resection will adequately control symptoms; an empyema will complicate resection in one of the 39, and relief of symptoms b y a resection of the planned extent will, in 2 others, be inadequate.

Such/

Such a summary serves, at least partially, to define the attitude in Edinburgh at the present time to the place of surgery in the management of bronchiectasis, since the summary is that of past and reasonably satisfactory experience upon which management in the future will be based. The anatomical limits of "surgical" bronchiectasis have been defined. It remains to define "symptoms"; to defend the submission to surgical rather than to medical care of patients with bronchiectasis within anatomical limits of surgical management in whom symptoms are attributable only to bronchiectasis; and to defend conservative management - management only by observation - in those with "surgical" bronchiectasis which has been recognised because of a complication or which is associated with symptoms judged insufficient to justify the discomfort of an operation and even the minimal risks which attach to management by resection.

The symptoms of bronchiectasis which are most likely to suggest the need for surgical management are cough with purulent sputum, haemoptysis, or all three. These symptoms must be of a severity which constitutes a disturbance to normal life. Although the recognition of haemoptysis and of purulent sputum does not present a problem, it is the disturbance to normal life which either of these precipitates in the individual patient which is variable. With regard to haemoptysis, a single, isolated and small haemoptysis has rarely been the basis for recourse to surgical management; repeated small or a single large haemoptysis are standard grounds for advising resection of bronchiectasis. In most patients the fact of haemoptysis, while it may not endanger life, proves so distressing that advice to submit to an operation is usually quickly accepted. If enough of the younger patients have have presented with a single small haemoptysis, on the ground of which localised, often unisegmental, bronchiectasis/

bronchiectasis has been left unresected, present at an advanced age with severe haemoptysis and need an operation when they are very much less suitable surgical risks, the conservative attitude towards bronchiectasis which presents in this way may need to be changed.

The production of purulent sputum - daily, usually in the morning, and sometimes at other times of the day - in quantities sufficient to delay, or to determine a way of life by influencing appetite or by demanding recourse to posture, and cough, precipitated by change in posture or by exposure to changes in atmosphere or temperature, are grounds for advising surgical management of bronchiectasis if these symptoms can reasonably be attributed to bronchiectasis which is within the anatomical limits of resection. The need ~~for~~ for surgical management is regarded as even more essential if life is disturbed by recurrent episodes of acute respiratory infection which demand recourse to chemotherapy and which involve absence from school or work. That symptoms of the type and severity outlined can be relieved and life in the individual rendered free from absence from work and social embarrassment , by daily posturing and continuous or intermittent recourse to chemotherapy does not, it must be strongly emphasised, recommend this form of management as an alternative to surgery where bronchiectasis is surgically manageable.

Treatment of any sort - medical or surgical - carries risks and involves discomfort and the expenditure of time, but treatment is thrust upon a patient not officiously but because of the real need to manage symptoms. Resection is anatomically expensive, but not of normal lung, only of lung already destroyed; the discomfort of an operation is great, but evanescent; the risks are real but small. The need for the daily postural emptying of the bronchi is uncomfortable and time-consuming; it is irritating to ~~meeke~~ take pills and chemotherapy/

chemotherapy carries occasional major risk and, in some, is accompanied by major or minor discomforts - alterations in bowel habit, of normal oral flora, of infection with resistent organisms - and in some patients the emergence of resistence is so rapid that even the development of new antibiotics is at a rate which does not keep pace with the demand in them for change in the chemotherapeutic regime. The experience of an individual patient with an arithmetical turn of mind is illustrative - he calculated that the time it was necessary to devote each year to the postural emptying of his bronchi to maintain freedom from respiratory infection involved the loss of more work-hours than those lost if he did not posture and was ill once or twice each year with an acute respiratory illness, for which he was treated with an antibiotic; following one such illness, however, (his calculations having been justified by the saving of time for some years) he developed as a complication of chemotherapy pruritis ani which disturbed him greatly for six months after the acute episode of respiratory infection and so influenced him that he postured long an determindly, thereafter; in him bronchiectasis was associated with asthma and was, in any event, anatomically unsuited to surgical management. In defence of surgical management, therefore, it is true to say that the success rate is high, success is real, and once surgical management is completed the patients are free from the need for surveillance and the risks both of the disease and of alternative forms of treatment, with the complications which attach to them.

With the rate of surgical success in properly selected patients high and the risks of surgery small, what is the place of prophylactic resection in the management of bronchiectasis in the patient who presents with, for example, an empyema which by investigation after drainage is shown to be related to bronchiectasis/

bronchiectasis within surgical limits? The problem here is similar to that in law - how many bites is the dog to be allowed? If surgically manageable bronchiectasis has declared itself once the only way of making certain that it will not do so a second time is by its resection, and it is both arguable and rational, therefore, to resect all suitable bronchiectasis which presents with a complication. This form of management is adopted when the patient with, again for example, an empyema is well enough to have the cause of this investigated before it is drained. Management in these circumstances, if empyema and bronchiectasis are on the same side, is by resection of both - nobody would contemplate the management of an empyema by decortication and leave unresected ipsilateral bronchiectasis. But this involves only one operation. The patient too ill for management in this way is quickly made well by the drainage of the empyema, and reluctance on the part of the patient to submit further to surgical treatment after healing of the empyema is understandable. However rational it is, therefore, to resect bronchiectasis which has declared itself with a complication, but which is otherwise relatively silent, management of this variety of bronchiectasis in the individual patient has, in this series, nearly always been conservative, and in this group of patients bronchiectasis has not again been complicated. And bronchiectasis the extent of which is known to be within surgical limits but which has been managed conservatively because of paucity of symptoms has also not been complicated, in the period under review, by empyema, lung abscess or other lesion. This may be nothing more than chance, and the attitude of conservatism in these two groups of patients may need to be revised. It only remains for carcinoma to declare itself in a lung known for many years to be totally bronchiectatic/

bronchiectatic, but symptomless, for haemoptysis to endanger life at an advanced age in a patient known for many years to have a single bronchiectatic segment, for cerebral abscess to develop as a complication of bronchiectasis anatomically localised and associated with symptoms judged insufficient to necessitate resection, for this surgical conservatism to be called in question and for management by resection to be advised in all patients with bronchiectasis of an appropriate anatomical distribution.

SUMMARY

The anatomical distribution and the symptomatology of the disease called bronchiectasis are variable over a wide range and the purpose of this thesis has been to define where, in this range, surgery has a place in management.

Some aspects of the history, pathogenesis and natural course of the disease were discussed. The anatomical distribution of bronchiectasis in a consecutive series of 1,038 patients was defined in the context of accepted anatomical nomenclature and with particular reference to the variable size of the lingular segment. The anatomical limits of pulmonary resection were defined. For the accurate diagnosis of the distribution of bronchiectasis, bronchography of a consistently high standard is a pre-requisite; bronchographic media were discussed and a simple and routinely successful technique of bronchography was described.

Patients with bronchiectasis in the series reviewed were classified into groups according to the anatomical distribution of the disease. Within these groups some patients were managed conservatively and some by resection; reasons were given for the different forms of management within each group. A further group of patients in whom the disease was anatomically outwith the range of surgery was analysed. The criteria which make a patient with bronchiectasis suitable for surgical management were defined; of the patients in the series 47% were suitable for management by resection and resection was undertaken in 39%. A particular case was made for the resection in selected patients of some and not all bronchiectatic segments. Hospital mortality amongst those managed surgically was less than 1% and in more than 90% of patients in whom bronchiectatic lung was resected symptomatic relief was achieved and has continued.

It /

It was suggested that in properly selected patients surgical management is preferable to management by medical means, even if these too can be shown to be successful, and reasons for this preference were given.

BIBLIOGRAPHY

Adams R. and Churchill E.D. (1937). J.thorac.Surg., 7, 206

Anderson D.H. (1938). Amer.J.Dis.Child., 56, 344

Andral G. (1831). A Treatise on Pathological Anatomy. Vol.2. Translated by R.Townsend and W.West, Dublin

Antony M. (1823. Philad.J.med.phys.Sci., 6, 108

Ballon H., Singer J.J. and Graham E.A. (1932). J.thorac.Surg., 1, 154,296,397 and 502

Barr H.S. (1955). J.clin.Path., 8, 19

Baylin G.J. (1944). Amer.J.Roentgenol., 2, 303

Black C. (1853). Lond.Edinb.Monthly J.med.Sci., 16, 497

Block M.H. (1881). Quoted by Meade, R.H.(1961).

Boyden E.A. (1949a). Dis.Chest, 15, 657

Boyden E.A. (1949b). Surgery, 26, 167

Boyden E.A. and Hartmann J.F. (1946). Amer.J.Anat., 79, 321

Bradshaw H.H., Meyers R.T. and Cordell A.R. (1957). Ann.Surg., 145, 644

Bradshaw H.H., Putney F.J. and Clerf L.H. (1941). J.Amer.med.Ass., 116, 2561

Bremer J.L. (1939). J.thorac.Surg., 8, 412

Brock R.C. (1943). Guy's Hosp.Rep., 92, 26

Brock R.C. (1950a). Thorax 5, 5

Brock R.C. (1950b). Proc.Roy.Soc.Med., 43, 1095

Brock R.C. (1954). The Anatomy of the Bronchial Tree. 2nd.ed. Oxford Univ. Press, London

Brunn H.B. (1929). Arch.Surg., 18, 490

Bruton O.C. (1952). Pediatrics 9, 722

Burrascano J.J. (1955) Sea View Hosp.Bull., 15, 149

Chesterman J.T. (1957). Brit.J.Surg., 45, 155

Churchill E.D. (1937). J.thorac.Surg., 6, 286

Churchill E.D. (1938). New England J.Med., 218, 97

Churchill E.D. and Belsey R. (1939). Ann.Surg., 109, 481

Clark N.A. (1963). Brit.med.J., 1, 80
Clarke S.K.R., Cornee B.D., Gambier D.M., Macrae J. and Peacock D.B. (1964) Brit.med.J., 1, 1536
Collis J.L. (1953). Thorax 8, 323
Corrigan D.J. (1836). Dublin med.J., 13, 266
Coryllos P.N. (1930). Arch.Surg., 20, 767
Crafford C. (1938). On the Technique of Pneumonectomy in Man. Stockholm
Cruikshank A.H. (1948). J.Path.Bact., 60, 520
Cunningham G.J., Nassau E. and Walter J.B. (1958). Thorax 13, 64

Davidson M. and Lee Lauder F.P. (1938). Brit.J.Radiol., 11, 65
Davies H.M. (1913). Brit.J.Surg., 1, 288
Demons A. (1886). Bull.Soc.Chir.Paris, 12, 450
Dormer B.A. and Wiles F.J. (1947). Clin.Proc., Cape Town, 6, 10
Doyen E. (1895). P.V.Ass.franc.Chir., 9, 104

Field C.E. (1949). Pediatrics 4, 21, 231, and 355
Field C.E. (1961). Arch.Dis.Childh., 36, 587
Franklin A.W. (1958). Arch.Dis.Childh., 33, 19
Fried B.M. (1943). Arch.intern.Med., 72, 565

Ginsberg R.L., Cooley J.C., Olsen A.M. and Kirklin J.W. (1955). J.thorac.Surg. 30 331
Gluck T. (1881). Berl.klin.Wschr., 18 645
Graham E.A. (1925). Arch.Surg., 10, 392
Graham E.A., Singer J.J. and Ballon H.C. (1935). Surgical Diseases of the Chest. Lea & Febiger, Philad.
Gross (1899). Beitr.klin.Chir., 288
Gudbjerg C.E. (1955). Acta radiol.Stockh., 43, 209
Gudbjerg C.E. (1957). Acta radiol.Stockh., Suppl.143

Hasse K.E. (1841). Anatomische Beschreibung der Krankheiten der Circulations und Respirations-Organe. Leipzig.
Hedblom C.A. (1931). Surg.Gynec.Obstet., 52, 406
Helm W.H. and Thomson V.C. (1958). Quart J.med., 27, 353
Hewett C. (1876). Brit.med.J., 1, 317
Hewlett T.H. and Zipperman H.H. (1960). J.thorac.Surg., 40, 71
Hitzrot J.M. (1920). Ann.Surg., 71, 785

Hoffmann E. (1955). Thorax, 10, 137
Hutchison J.H. (1955). Lancet, ii, 844

Jackson C. (1918). Amer.J. Roentgenol., 5, 454
Janes R.M. (1933). Brit.J.Surg., 21, 257
Johnson P.M. and Irwin G.L. (1959). Radiology, 72, 816

Kartagener M. (1933). Beitr.Klin.Tuberk., 83, 489
Kent E.M. and Blades B. (1942). J.thorac.Surg., 12, 18
Krause F. (1898). Quoted by Meade, R.H. (1961)

Laennec R.T.H. (1824). A Treatise on the Diseases of the Chest. Translated by J.Forbes, London
Lancet (1955). ii, 489
Lancet (1958). i, 631
Lancet (1958). ii, 734
le Roux B.T. (1962a). Thorax, 17,77
le Roux B.T. (1962b). J.thorac.Surg., 44,225
le Roux B.T. (1962c). J.thorac.Surg., 44,214
le Roux B.T. (1962d). Thorax, 17, 357
le Roux B.T. (1964a). Thorax, 19, 203
le Roux B.T. (1964b). Thorax, 19, 236
le Roux B.T. (1964c). Brit.J.Surg. in press
le Roux B.T. and Duncan J.G. (1964). Thorax, 19, 37
le Roux B.T. and Masson A.H.B. (1962). Brit.J.Anaesth., 34, 200.
Lindskog G.E. and Hubbell D.S. (1955). Surg.Gynec. Obstet., 109, 643
Lilienthal H. (1925). Thoracic Surgery, W.B.Saunders Co.,London & Philad.
Love S.H.S. and Morrow W.F.K. (1954). Anaesthesia, 9, 74.
Lowe C.V., May C.D. and Reed S.C. (1949). Amer.J.Dis.Child., 78, 349
Lowson D. (1893). Brit.med.J., i, 1152

Macewen W. (1895). From "The Life and Teachings of Sir William Macewen" by A.K.Bowman, Wm.Hodge & Co., London, 1942
McKim A. (1952). Amer.Rev.Tuberc., 66, 457.
Mannix W.A, Gerbasi F., O'Brien C.E., Adler R.H., McAlpine W.A. and Kerr H. (1953). J.thorac.Surg., 26,14
Marcus (1883). C.R.Soc.Biol.Paris, 323.
Meade R.H. (1961). A History of Thoracic Surgery. C.Thomas,Springfield, U.S.A.

Meyer W. (1914). Trans.Amer.Surg.Ass., 32, 593
Miller J.A. (1934). J.thorac.Surg., 3, 246
Murphy J.B. (1898). J.Amer.med.Ass., 3, 356

Nissen R. (1931). Zbl.Chir., 47, 3003

Ogilvie A.G. (1941). Arch.intern.Med., 68, 395

Parkhouse J. (1957). Brit.J.Anaesth., 29, 447
Paterson J.F. (1952). Canad.med.Ass.J., 66, 433
Pean J. (1895). P.V.Ass.franc.Chir.,9, 72
Pennybacker J.B. and Holmes Sellors T. (1948). Lancet, ii, 90
Perry K.M.A. and King D.S. (1940). Amer.Rev.Tuberc., 41, 531
Perry K.M.A. and Holmes Sellors, Sir Thomas, (1963). Chest Diseases, Butterworth London
Pilcher R. (1946). Lancet, i, 843

Reid. L.M. (1955). Thorax, 10, 199
Rienhoff W.F. (1933). Johns Hopk.Hosp.Bull., 55, 390
Roberts J.E.H. and Nelson H.P. (1933). Brit.J.Surg., 21, 277
Robinson F. (1917). Surg.Gyneo.Obstet., 24, 194
Rokitansky C. (1842). Lehrbuch der pathologischer Anatomie, Wien

Sant 'Agnare P.A.di (1956). Amer.J.Med., 21, 406
Sauerbruch F. (1927). Arch.klin.Chir., 148, 721
Scannell J.G. (1947). J.thorac.Surg., 16, 530
Schmid. H. (1881). Berl.klin.Wschr., 51, 757
Shenston N.S. and Janes R.M. (1932). Canad.med.Ass.J., 27, 138
Siegmund. H. (1922). Virchows Arch., 236, 191
Sicard J.A. and Forestier J.A. (1922). Bull.Soc.méd.Hôp.Paris, 46, 463
Spencer H. (1963). Pathology of the Lung, Pergamon Press.
Stokes (1837). Disease of the Larynx and Windpipe, Hodge & Smith, Dublin
Strand C. (1956). Ann.intern.Med., 44, 630.
Straton J. and Muir A.P. (1954). Anaesthesia, 9, 105
Streete B.G. and Salyer J.M. (1960). J.thorac.Surg., 40, 383

Thorax (1950). International Nomenclature accepted by Thoracic Society, 5.222
Tuffier T.(1891). Sem.Med. 2.202

Whittemore J. (1927). Ann.Surg., 86, 219
Whitwell F. (1952). Thorax, 7, 213
Wynn-Williams N. (1953). Brit.med.J., i, 1194
Wynn-Williams N. (1957). Tubercle, 38, 133