

FIBROBLAST VIABILITY IN THE ALLOGRAFT HEART VALVE LEAFLET

DAVID JOHN WHEATLEY

M.B., Ch.B. (Cape Town) F.R.C.S. (Edinburgh)

Senior Lecturer in Cardiac Surgery,
University of Edinburgh.

Consultant Cardiac Surgeon,
Edinburgh Royal Infirmary.

SUBMITTED FOR DEGREE OF MASTER OF SURGERY (Ch.M)
TO THE UNIVERSITY OF CAPE TOWN

From:

Department of Cardiac Surgery,
National Heart Hospital, Westmoreland Street, London.

Department of Cardio-thoracic Surgery,
Mearns Kirk Hospital, Glasgow.

Wellcome Surgical Research Institute,
Garscube Estate, Glasgow.

December 1975

The animal research work which forms part of this thesis
was financed by a grant of £3,610 from
the Scottish Hospital Endowments Research Trust.

The copyright of this thesis vests in the author. No quotation from it or information derived from it is to be published without full acknowledgement of the source. The thesis is to be used for private study or non-commercial research purposes only.

Published by the University of Cape Town (UCT) in terms of the non-exclusive license granted to UCT by the author.

3c	Homograft Aortic Valve Replacement	44
3d	Reconstruction of Right Ventricular Outflow with a Valved Homograft Conduit	59

SECTION 4

AIMS OF INVESTIGATION	74
Definition of Terms	75

SECTION 5

IN VITRO STUDY OF HEART VALVE LEAFLET VIABILITY	79
5a Tissue Culture, Protein and Collagen Synthesis in Antibiotic Sterilised Canine Heart Valves	80
Composition of Antibiotic-Nutrient Solution	82
5b Viability in Human Heart Valves prepared for Grafting	92

SECTION 6

IN VIVO STUDY OF POST-IMPLANTATION VIABILITY OF HEART VALVE LEAFLETS	99
6a Design of Animal Model	100
Need for Animal Model	100
Choice of Animal Species	102
Method of Valve Insertion	103
Choice of Implantation Period	107
6b Methods used in Animal Study	109
Preparation of Donor Valve	109
Assessments at time of Allograft Valve insertion	111
Insertion of Allograft Valve into Host	115
Assessments at time of Allograft Valve Removal	123

6c	Results of Animal Study	131
	Numbers of dogs	133
	Assessments at time of Allograft Valve insertion	134
	Assessments at time of Allograft Valve removal	140
	Function of implanted valve	140
	Structural state of implanted valve	152
	Microscopic appearance of implanted valve	166
	Tissue culture growth of implanted valve	195
	Origin of cells grown in tissue culture	196
	Protein and Collagen synthesis	197

SECTION 7

CONCLUSIONS	198
In vivo Study of Post-implantation Viability of heart valve leaflets	199
Question of whether fibroblast viability is maintained following isotopic allotransplantation of a viable valve	201
Question of whether, in antibiotic sterilised valves, the state of fibroblast viability can be shown to influence valve structure and function following isotopic allotransplantation	206
Summary	207
In vitro Study of Tissue Culture, Protein and Collagen Synthesis in Antibiotic Sterilised Canine Heart Valves	208
In vitro Study of Viability in Human Heart Valves prepared for Grafting	208
SUMMARY	208

SECTION 8

ACKNOWLEDGEMENTS	210
------------------------	-----

SECTION 9

REFERENCES	214
------------------	-----

SECTION 1INTRODUCTION

This thesis represents a personal experience in the use of allograft heart valve tissue in cardiac surgery gained from clinical practice and supplemented by a research investigation designed to clarify certain unresolved problems in this field.

My initial clinical interest in the use of allograft heart valves was stimulated during 1970 and 1971 when working in the Cardiothoracic Unit of Wentworth Hospital, Durban, where the frame-mounted human aortic valve was used as an attractive alternative to the prosthetic valves then available for the replacement of diseased heart valves.

During 1972 and 1973 a major impetus to my interest was provided by a clinical surgical attachment to the National Heart Hospital, London. This is a centre well known for pioneering and continuing work in the field of homograft valve use. As Senior Surgical Registrar to Mr. J. Keith Ross, Mr. Donald Ross and Mr. L. Gonzalez-Lavin I became thoroughly familiar with the clinical use of homograft heart valves, and from them originates much of the stimulation and continued encouragement responsible for this thesis.

For the past two years I have been engaged in a research project designed to clarify problems raised in the establishment of a clinical allograft valve practice in Glasgow. Continued liaison during this period with the Homograft Department of the National Heart Hospital has ensured the contemporary clinical relevance of the research project and has strengthened the important link between research work and clinical practice.

ASPECTS OF THESIS IN WHICH WORK HAS BEEN DONE PERSONALLY:

Every operation in the Animal study (Section 6) has been done personally, with the assistance of a veterinary nurse. This has included anaesthesia, assessment of pressures and performance of angiography and measurement of valves, and post-operative care of the animals.

The obtaining of donor tissue has always been done personally, as has been the mixing of Antibiotic-nutrient solutions and care of valve tissue during storage.

The majority of the tissue culture work has been done personally. Assessment of histological findings has been done personally, but in this specialised field I have relied on help from others, in particular Professor R. E. B. Hudson, for subsequent checking of conclusions.

All the illustrations for the thesis have been done personally.

All the clinical investigations for the writing of Section 3c and 3d have been done personally.

The establishment of clinical allograft valve replacement in Glasgow, which provided much of the impetus for this work, was a personal undertaking, and involved me in the obtaining of valve tissue, its preparation, and the clinical surgery.

The opportunities given to me are much appreciated and are acknowledged in Section 8.

PARTS OF THESIS IN WHICH WORK HAS BEEN DONE BY OTHERS:

Assessment of protein and collagen synthesis has been performed by Professor J.O.'D. McGee.

Some of the tissue culture work has been performed by Dr. C. G. A. McGregor for me under my guidance - this was a very exacting aspect of the work and I am grateful to him for his help here.

PARTS OF THESIS IN WHICH WORK HAS BEEN DONE BY OTHERS: (Cont.)

The specimens for the Animal Study were cut and mounted for me by the Victoria Infirmary Department of Pathology - largely by Dr. McGregor.

Photography has been done by the Photographic Departments of the Veterinary School or the Victoria Infirmary.

Identification of chromosomes has been done for me by Dr. Harvey or Dr. Logue of the Animal Reproduction Department at the Veterinary School.

In each case I was familiar with the principles and techniques of the investigations, and have acknowledged this help in Section 8.

PUBLICATION OF ASPECTS OF WORK COVERED BY THIS THESIS:

Section 3d has appeared as a publication - "Reconstruction of Right Ventricular Outflow with a Valved Homograft Conduit" by D.J. Wheatley, S. Prusty and D. N. Ross - in Thorax, Volume 29 No. 6, page 617, November 1974. The data included in this part of the thesis has also been presented at the Society of Thoracic and Cardiovascular Surgeons of Great Britain in Cambridge, in 1973 by me. The article has been written by me and has considerable relevance to this work, and is therefore included.

Section 5a has been submitted for publication to the journal "Cardiovascular Research" under the title "Tissue Culture, Protein and Collagen Synthesis in Antibiotic Sterilised Canine Heart Valves", with authors C. G. A. McGregor, J. F. Bradley, J. O'D. McGee and D. J. Wheatley.

Section 5b, with title "Viability in Human Heart Valves prepared for Grafting" with the same authors has been submitted

PUBLICATION OF ASPECTS OF WORK COVERED BY THIS THESIS (Cont.):

to the same journal. Both articles have been accepted for publication and will appear in 1976, probably in March. In view of the part played in the study by the other authors, as well as the contemporary clinical relevance the work has been submitted for publication, but its inclusion in this thesis is mandatory in view of the relevance to the animal study.

SECTION 2

BACKGROUND TO THESIS

"FIBROBLAST VIABILITY IN THE ALLOGRAFT HEART VALVE LEAFLET"

Choice of Heart Valve Substitutes

The cardiac surgeon continually faces the problem of choosing a suitable replacement for diseased heart valves. This problem also arises in certain congenital defects requiring a valved conduit for reconstruction.

The ideal valve for this purpose is not yet established. This is reflected in the wide variety of alternatives available (McGoon, 1971; Karp et al., 1974; Longmore, 1975).

In spite of considerable ingenuity of design and production of prosthetic valves, many difficulties have been encountered. The major problem remains the ever-present hazard of thrombo-embolism and the need for long-term anticoagulation. Although earlier problems of mechanical failure, haemolysis and poor haemodynamic function are less frequent, they have not been eliminated (Starr, 1975; Bjork, 1975).

In an attempt to overcome the problems of thrombo-embolism various biological tissues have been used for valve construction (Puig et al., 1975; Ionescu et al., 1974). The most notable of these has been the fascia lata valve (Senning, 1967). However, poor long-term results have marred initial successes (Ionescu, 1975; McEnany et al., 1972), and most of these forms of biological valves have been abandoned (Senning, 1975; Parker, 1975).

The Allograft Heart Valve

Transplantation of a healthy valve from the same species (a "homograft" heart valve, or "allograft" heart valve - the more recently preferred term for tissue grafted from one individual to another of the same species) offers an attractive solution to the

problem. Allograft (homograft) valves offer optimal haemodynamic characteristics, with freedom from haemolysis and the risk of sudden mechanical failure (Ross, 1972 and 1975; Yacoub, 1975; Angell et al., 1975a).

The Need for Sterilisation and Preservation

Although initially small numbers of allograft valves were obtained under sterile conditions and not subjected to sterilisation or prolonged storage before implantation, this raises practical problems. In addition, the sterility of such autopsy material is unreliable (Yacoub and Kittle, 1970). Thus, for practical reasons it is necessary to make use of routine autopsy material to obtain sufficient suitable valves. This dictates the need for a method of valve sterilisation. Also, some form of storage is necessary to allow the accumulation of a suitable range of valves for clinical use.

Thus, a variety of methods for the sterilisation and preservation of allograft valves has been described, most commonly involving the use of ethylene-oxide, beta-propiolactone, or gamma-irradiation for sterilisation, and some form of freezing and low-temperature storage for preservation (Longmore et al., 1966; Pickering, 1966; Barnes et al., 1970; Malm et al., 1967).

Late Failure of Allograft Valves

From the time of the first use of the allograft valve in the sub-coronary position in 1962 (Ross, 1962) a high incidence of late valve failure has detracted from otherwise excellent clinical results (Ross, 1975; Wallace et al., 1974). This failure has been ascribed to methods used in the past for

sterilisation and preservation of the allograft valve

(Aparicio et al., 1975; Missen and Roberts, 1970; Gavin et al., 1972; Bolooki et al., 1972; Hoeksema et al., 1967; Ross, 1972 and 1975; Hudson, 1966; Smith, 1966; Clark, 1973).

Antibiotic Sterilisation

Antibiotic sterilisation of allograft valves is now widely used, with much improved long-term results (Barratt-Boyes and Roche, 1969; Barratt-Boyes et al., 1972; Angell et al., 1973a; Ross, 1975; Yacoub, 1975).

Importance of Viability in Allograft Valves

It has been suggested that viability of the valve at the time of implantation may be an important factor influencing long-term function in allograft valves (Kosek et al., 1969; Angell et al., 1972).

Reports of experimental work in dogs showing survival of living donor cells in the leaflets of transplanted allograft heart valves (Mohri et al., 1967a, 1967b and 1968; Buch et al., 1971; Kosek et al., 1969; Angell et al., 1973a) have encouraged speculation that living cells in viable valves continue to survive after allotransplantation in man. Such living valves would be capable of remoulding, repairing and strengthening the implanted valve, thus providing a living, self-repairing permanent replacement (Al-Janabi et al., 1972 and 1973; Al-Janabi, 1975; Lockey et al., 1972; Hammon et al., 1974; Angell et al., 1973a; Kosek et al., 1969).

Maintenance of Viability in Allograft Valves

Such has been the emphasis on preserving viability in allograft valves prepared for clinical use that many antibiotic formulae have been recommended which will not impair viability, but which, at the same time, will satisfactorily sterilise the valve (Angell et al., 1973b; Lockey et al., 1972; Waterworth et al., 1974; Yacoub, 1975).

Further, the addition of a nutrient medium to such formulae has been advised, in an attempt to improve preservation of valve viability (Al-Janabi, 1972 and 1975; Lockey et al., 1972).

Also, storage of viable valves at -195°C , using 15% dimethyl sulphoxide as a cryoprotective agent, has been used with the aim of indefinitely retaining viability in valves for clinical use (Al-Janabi, 1975).

Tests of Viability

As a result of this belief in the importance of allograft valve viability, several tests, some very elaborate, have been advocated for the assessment of valve viability - either demonstration of tissue culture growth of leaflet fibroblasts, or demonstration of biosynthetic activity in leaflet fibroblasts (Angell et al., 1973a and 1973b; Al-Janabi et al., 1972 and 1973; Al-Janabi, 1975; Yacoub, 1975).

Conflicting Evidence Regarding Viability

Not all workers are convinced about the importance of valve viability. Notably, the New Zealand group of Barratt-Boyes, which in fact pioneered antibiotic sterilisation of allograft valves and reported improved long-term results, believe that the histological changes in fresh allografts are essentially the same as in chemically

sterilised valves (Gavin et al., 1973a). They believe that donor cells do not survive in antibiotic sterilised valves following allotransplantation (having disappeared in fact by 40 days) despite evidence of viability at the time of insertion (Gavin et al., 1973b).

Furthermore, the experimental evidence for continued donor cell survival in valves following allotransplantation is conflicting. There are reports of rapid loss of leaflet cellularity following transplantation of fresh valves in dogs (Beall et al., 1961; Duran et al., 1965; Duran and Whitehead, 1968) which conflict with evidence for continued donor cell survival. Even in the reports showing post-implantation survival (Mohri et al., 1968) it is apparent that progressive loss of donor cells occurs. It is of considerable interest that Mohri's group compared viable valves with non-viable beta-propiolactone sterilised valves, and concluded that the non-viable grafts appeared superior to the viable up to 12½ months because of better maintained leaflet pliability.

Alternatives to Allograft Valves

The recent ready availability of a promising alternative to the allograft valve - the glutaraldehyde preserved heterograft valve - (Hancock Laboratories Incorporated, 1975; Johnson et al., 1975; Horowitz et al., 1974; Carpentier et al., 1974; Carpentier et al., 1975), which appears to offer the same advantages as the allograft valve with satisfactory durability to date, makes it important to assess carefully the claims made for viability in allograft valves.

The Need for Investigation of Fibroblast Viability in the
Allograft Heart Valve Leaflet

It is probably true to state that the case for the allograft valve in 1975 is based on the assumption of living cells within the valve leaflets surviving after implantation to provide a living valve substitute (Reid, 1975).

In striving to maintain viability of fibroblasts within leaflets of allograft valves prior to their implantation considerable problems arise, namely:-

- 1) The problem arises of attempting to reconcile two conflicting aims - the killing of bacteria and fungi on the surface of the valves, but not at the same time killing the cells within the leaflets of the valve. This is the reason for the large number of antibiotic formulae which have been used, and is also the reason that antibiotic sterilisation may not be entirely reliable (Lockey, 1975; Waterworth et al., 1974).
- 2) A degree of urgency is imposed on harvesting of valves, with efforts being required to obtain autopsy material with minimal delay after death.
- 3) A time limit is imposed on storage periods for clinical use (at present 8 weeks at the National Heart Hospital), but logically an obligation exists to use the valves with minimal delay.
- 4) The requirement for some form of viability assessment arises, to monitor the effect that sterilisation and storage procedures are having on allograft valve viability.

- 5) There is an ever-present hazard that the temptation to reduce exposure to potentially cytotoxic antibiotics to a minimum may result in incomplete valve sterilisation, with endocarditis in the recipient. The pitfalls of bacteriological tests on antibiotic sterilised valves have been pointed out by Waterworth et al. (1974) and Lockey (1975).

- 6) There is the possibility that undue attention to the problems of viability may detract attention from other, possibly more important factors, such as the physical effects on the collagen, elastic tissue or ground substance of the valve of various sterilisation and storage procedures (Gavin et al., 1973a; Carpentier et al., 1975). As an example of this possibility, it is reported that structural integrity is impaired in viable valves cooled to -195°C with dimethyl sulphoxide (Al-Janabi - personal communication).

Clearly, these problems would be largely resolved by accurate knowledge of the state of fibroblast viability of heart valve leaflets available for grafting, and the effect on that viability of antibiotic sterilisation and storage. Even this is a source of considerable difference of opinion (Gavin et al., 1973c).

Also, an investigation into the state of viability following implantation of a viable allograft valve is of pressing importance in view of the conflicting and uncertain evidence from animal experimentation. Because of the present availability of acceptable alternatives to the allograft valve - either the

glutareldehyde preserved heterograft or the recent improved prosthetic valves (Barnhorst et al., 1975) - the need to substantiate or to refute the claims made for continued donor fibroblast survival following allograft valve implantation, and the modification of such valves by these cells, becomes more urgent and important.

The need for this investigation became apparent during early 1974 in the process of establishing clinical Allograft Heart Valve surgery in Glasgow. At this stage the problems already referred to, of harvesting, sterilising and preserving allograft valves were highlighted by personal practical experience. In addition, it became clear that with improvements in prosthetic valve design, and the appearance of a clinically well-tried heterograft valve on the market, the defence of the allograft valve became more difficult, and in fact, appeared to depend on the alleged survival of donor fibroblasts which could favourably modify the implanted valve.

Thus an Investigation was undertaken - the results of which form the basis of Sections 5 and 6 of this Thesis.

Initially, a study was made of leaflet fibroblast viability in fresh canine heart valves, and the effects of antibiotic sterilisation and storage were investigated (Section 5b).

Making use of the experience gained from these 'in vitro' studies, and 'in vivo' experimental study was undertaken in dogs, in an attempt to determine whether or not fibroblast viability is maintained following implantation of an allograft valve, and whether or not such viability could be shown to influence valve structure and function (Section 6).

Additionally, a personal assessment was made of a consecutive group of 100 patients having allograft aortic valves inserted between 1967 and 1972 at the National Heart Hospital with a standard surgical technique, but with changes in the preparation of the allograft valve (Section 3c).

A personal review of Reconstruction of Right Ventricular Outflow with a valved homograft conduit (reported in 1974) describes National Heart Hospital experience with this form of surgery (Section 3d).

The remainder of the Thesis consists of a review of the experimental work relevant to the field, and the evolution of clinical allograft heart valve transplantation (Sections 3a and 3b), and the conclusions drawn from the investigation (Section 7).

SECTION 3

ALLOGRAFT HEART VALVE TRANSPLANTATION IN CLINICAL PRACTICE

3a EXPERIMENTAL BASIS AND EVOLUTION OF CLINICAL ALLOGRAFT
HEART VALVE TRANSPLANTATION

Initial Experimental Work:

The first detailed experimental study of aortic valve allografts was reported by Lam, Aram and Munnell in 1952 (Lam et al., 1952) from the Henry Ford Hospital, Detroit. It is of interest that even in this early report the authors state that "it was wondered if such a valve homograft might have an equal or better chance of success than the plastic valvular prostheses of Campbell and of Hufnagel". The relative merits of allograft valves, other tissue valves, and prosthetic valves are still debated (Karp et al., 1974) and with parallel improvements in allograft heart valve techniques and prosthetic valve design have provided grounds for debate for many years (McGoon, 1971).

Lam's group used the canine aortic valve, removed under sterile conditions, and transplanted this into the descending thoracic aorta of dogs, either immediately, or following storage in Tyrode's solution for up to two weeks. In an initial series of 27 dogs 7 survived long enough for sacrifice between 1 and 6 months. The valves implanted into these 7 dogs showed increasing loss of functional capacity due to shrivelling of the cusps and thrombosis. It appeared that such a valve graft offered no promise of success and the authors' conclusion agreed with that of Hufnagel, (1951) who had earlier mentioned his own lack of success with the allograft valve.

Lam's group then investigated a second series of dogs in which an attempt was made to allow function of the implanted valve by rendering the recipient's own aortic valve incompetent. (1)

Of 48 animals only 18 lived for one month or more - and their implanted valves were inspected after 1 to 16 months. In 9 of the 18 survivors the implanted valve leaflets approximated the normal in appearance, although there was difficulty in demonstrating their function due to spontaneous correction of the recipient's aortic valve insufficiency by adaptation of the uninjured leaflets.

The authors speculated that in the presence of permanent aortic insufficiency an allograft valve might function indefinitely.

The experimental model used by Lam's group - insertion of a valve within its cuff of aortic root and adjacent myocardium into the descending aorta, together with induction of regurgitation in the host animal's own aortic valve to provide a stimulus for function of the implanted valve - has been applied by other workers (Brewin, 1956; Duran et al., 1965; Duran and Whitehead, 1956; Beall et al., 1961).

Clinical Application by Murray in Toronto:

Murray et al., (1956) showed experimentally that allograft valves would function in the presence of aortic regurgitation of the host and used allograft valves in the descending aorta of 6 patients as treatment for aortic regurgitation. These valves had been removed aseptically and kept in a saline penicillin mixture at 4°C for up to 5 weeks. Murray (1960) and Kerwin et al. (1962) reported well maintained function in these valves, and again in 1964 Bigelow et al. (1964) reported 5 of Murray's patients to be doing well between 2 and 8½ years after insertion of their valve, and Heimbecker (1968) reported good function 7 to 13 years later.

Study of Beall, Morris, Cooley and DeBakey:

A study of the fate of allograft aortic valves reported by Beall et al. (1961) showed more promising results than preceding studies. In this study the aortic valve was removed from donor dogs under sterile conditions and refrigerated from 2 to 28 hours in an antibiotic electrolyte solution. Such valves were placed in 25 animals in the descending thoracic aorta, and the host dog's aortic valve was made incompetent by avulsing a leaflet with a hook passed via the subclavian artery. 4 operative deaths and 5 deaths in the first month occurred, leaving 16 animals for study 1 to 13 months after operation. Of the 13 which had been examined after death the valves of 9 showed slight thickening of the leaflets, but they remained pliable and capable of function. During the first month after insertion the leaflets microscopically showed polymorph and lymphocytic infiltration, and over a period of months the leaflets developed an acellular appearance. Competence could not be demonstrated in 4 of the 13; 2 of these valves were in good condition and 2 were shrunken, and it was thought that loss of function in these two valves was associated with spontaneous disappearance of the aortic insufficiency in the animal's own aortic valves.

The same group also reported the use of aortic valve allografts in the descending aorta of 3 patients, with clinical improvement 7, 6 and 5 months after operation respectively.

Aortic Valve Replacement in the sub-coronary Position:

The use of the allograft aortic valve in the descending aorta was paralleled by the use of a prosthetic valve in the same site (Hufnagel et al., 1954 and 1958). In 1960 the first successful clinical aortic valve replacement by a ball-valve in the sub-coronary position was performed by Harken (1960) and this achievement was matched by Donald Ross in 1962 with an allograft valve (Ross, 1962).

Duran and Gunning (1962) reported that they had confirmed the findings of Lam et al. (1952), Murray et al. (1956) and Beall et al. (1961) and described a method for removing the aortic valve from cadavers, fashioning it, and inserting it in the subcoronary position.

The technique of Duran and Gunning was applied clinically in July 1962 by Ross (Ross, 1962) who successfully implanted a freeze-dried allograft aortic valve into a 43 year old man with severe aortic stenosis. In 1964 Ross was able to report 12 patients who had undergone aortic valve replacement with an ethylene oxide sterilised and freeze dried allograft aortic valve (Ross, 1964). Of considerable interest and relevance to current practice in this field is a statement in the discussion by Ross that "It is realised that these valves are not living homografts but they seem to be accepted by the host and function satisfactorily. They do, however, open the way to living homograft valve replacements once the immunological problems are overcome. On the other hand the antigenicity of the cusps may be low, being virtually avascular structures".

Very shortly after the pioneering work of Ross in London, Barratt-Boyes performed the first aortic homograft valve replacement at Green Lane Hospital, Auckland, New Zealand, a centre destined to become famous for its use of allograft valve tissue. (Barratt-Boyes, 1964). Between August, 1962 and the end of 1968, 590 aortic homograft valve replacements were performed in this centre (Barratt-Boyes and Roche, 1969). It was shown that the mortality for this surgery was comparable to that for implantation of prosthetic valves; that emboli do not originate from a homograft valve, and that incompetence is uncommon.

Following the success of Ross in London and Barratt-Boyes in New Zealand the use of allograft heart valves was more widely adopted. In addition such valves were used, mounted on a frame or within a supporting tube, to replace the mitral valve and tricuspid valve, and used together with the ascending aorta as a valved conduit it found application in the reconstruction of the right ventricular outflow in certain congenital cardiac conditions. (Angell et al., 1968 and 1967; Rastelli et al., 1969 and 1967; Ross and Sommerville, 1966; Yacoub and Kittle, 1969; Gonzalez-Lavin and Ross, 1970; Karp and Kirklin, 1969; Stinson et al., 1968; Wallace et al., 1969 and 1971).

With increasing clinical use of allograft heart valves in the mid-1960's it soon became clear that these valves had advantages over the then available prosthetic valves. These advantages were absence of thrombo-embolic complications, lack of need for anti-coagulants, absence of haemolysis, good haemodynamic performance, and freedom from sudden mechanical failure. (Barratt-Boyes and Roche, 1969; Ross, 1966; Angell et al., 1968).

However, the disadvantages of allograft valves also became clear. These were the difficulty in obtaining a large supply of suitable valves; knowing how best to prepare and store them; and the occurrence of late changes in the valves leading to increasingly severe valve dysfunction which required reoperation in a significant number of patients (Missen and Roberts, 1970; Yacoub and Kittle, 1970; Hudson, 1966; Smith, 1967; Bigelow et al., 1967).

The valves used ~~by~~ Murray in the descending aorta with clinical success (Murray et al., 1956) as well as the first 16 valves inserted by Barratt-Boyes between 1962 and 1964 (Gavin et al., 1973a) were removed under sterile conditions from cadavers and stored in electrolyte solutions for relatively short periods before implantation as 'fresh' grafts.

Obtaining sterile tissue from cadavers is neither practical nor reliable. In order to have a steady supply of suitable valves with a satisfactory range of sizes it is necessary to use routine autopsy sources. Valves obtained under these conditions are very likely to be grossly contaminated with bacteria and fungi. Blood cultures taken under sterile conditions from inside the heart immediately

after opening the chest of 45 refrigerated cadavers between 6 and 48 hours after death were positive in 85% (Yacoub and Kittle, 1970), and cultures of aortic wall strips were positive in all instances.

Thus it was apparent that some form of sterilisation was required. The techniques which had been applied to sterilisation of arterial homograft segments were used (Flewett et al., 1955 ; Eastcott et al., 1954). The first valves to be used by Ross had in fact been sterilised with ethylene oxide and freeze-dried (Longmore et al., 1966; Ross, 1964). Many techniques for the sterilisation and preservation of allograft heart valves were advocated, including ethylene oxide sterilisation and freeze-drying (Longmore et al., 1966; Pickering, 1966), exposure to beta-propiolactone (Barnes et al., 1970), exposure ~~to~~ formalin (Paneth and O'Brien, 1966) or irradiation (Malm et al., 1967), followed by freeze-drying with storage at room-temperature, refrigeration, or storage at -79°C (Gerbode, 1970; Rob, 1968).

It was also recognised that these methods of sterilisation and preservation carried the risk of damaging the allograft valve. The appearance of cracks in valve leaflets subjected to freeze-drying was reported by Mohri et al. (1968) and as a result of this his group abandoned this method of freezing, favouring storage in 20% glycerol in Ringer's solution at -80°C . Impairment of tensile strength of strips of pericardium, aortic wall, and valve leaflets following freeze-drying had been demonstrated (Harris et al. 1968; King et al., 1967). Clark (1973) also found that freezing alters the mechanical behaviour of valvular tissue, resulting in generalised stiffening. Leaflet rupture in

beta-propiolactone sterilised valves was reported by Smith (1967) and decrease in tensile strength of beta-propiolactone sterilised tissue was reported by several workers (Pritchard et al., 1966; Harris et al., 1968; Mohri et al., 1968a).

Brock (1968) predicted that freeze-dried allograft valves would calcify and fail in view of his experience with freeze-dried aortic grafts. Calcification was reported in the aortic wall or annulus at 17 to 24 months after implantation in four beta-propiolactone sterilised valves, two of which had been freeze-dried (Smith, 1967). Missen and Roberts (1970) reported calcification in 24 of 39 implanted valves that had originally been sterilised with ethylene oxide and freeze-dried and had been placed for 9 to 62 months.

Cusp rupture was seen in 21 of the 39 valves reported by Missen and Roberts, and had also been reported by Hudson (1966) in ethylene oxide-sterilised and freeze-dried valves, and by Barratt-Boyes and Roche (1969) in beta-propiolactone sterilised and freeze-dried valves. Barratt-Boyes and Roche considered that both leaflet rupture and calcification were related to the method of preparation of the valve, and had not seen these complications in their untreated valves. They described a method of antibiotic sterilisation which they hoped would not damage the acid mucopolysaccharides, collagen and elastin which make up the leaflet, and recommended Hanks solution containing penicillin 50 units/ml, streptomycin 1 mg/ml., kanamycin 1 mg/ml., and amphotericin B 25 ug/ml. These workers noted that the leaflets of untreated valves, removed between 4 months and 5½ years after insertion,

contained fibroblasts, and considered that these fibroblasts represented host reaction rather than survival of grafted donor fibroblasts.

Experimental Studies on the Fate of Allograft Heart Valves:

The clinical application of heart valve transplantation stimulated a number of experimental studies aimed at assessing the long-term fate of such valves. Considerable interest centred on the question of the influence of preparation techniques on long-term fate of the valves and the question of whether or not an immune response occurred.

Work of Duran and Colleagues at Oxford:

This group used a canine model similar to that described by Lam et al., (1952) and Beall et al. (1961) - in which the allograft aortic valve within its sleeve of adjacent myocardium and aortic wall is placed in the descending aorta of a dog which has its own aortic valve damaged to produce aortic regurgitation thus inducing the implanted valve to function.

In one experiment (Duran et al., 1965) to demonstrate the fate of the allograft aortic valve in the dog they used canine valves obtained within 6 hours of death and stored in saline or Gross's solution for up to 14 days at 4°C - conditions which were considered to keep the tissue viable.

Considerable technical difficulties were experienced with these experiments - in the group of 18 dogs in which aortic incompetence of the recipient was not induced only 8 survived between 1 and 34 days (two of these had to be sacrificed because of paraplegia and the remaining 6 died of massive haemorrhage). The allograft valve leaflets showed

thickening and retraction in 5 of the 8, and were normal only in the 3 surviving 6 days or less.

In the group of 20 dogs in which aortic incompetence of the recipient was induced 10 died on the table and 6 survived long enough for examination of the implanted valve at 7 days, 22 days, 44 days, 3 months, 10 months and 12 months. All the leaflets of these animals' allograft valves were thin and pliable.

Histologically the leaflets showed a cellular infiltration of lymphocytes, plasma cells and occasional polymorphs with surface proliferation of fibroblasts when examined within the first 3 weeks of implantation. Thereafter the leaflets appeared hyaline and acellular.

The authors concluded that the valves in the group in which aortic incompetence had been induced in the recipient were in perfect condition, in striking contrast to the thickened leaflets of the group without host aortic incompetence, thus confirming the need for function for continued grafted valve integrity.

Although the authors assumed the allograft valves to be viable no tests were made for viability. It is noted that although their first 15 valves were obtained under sterile conditions the other 23 were not, as "it was noted that all non-sterile specimens became sterile once placed in Gross's solution for over 12 hours". It is thus open to question whether the allograft leaflets were in fact viable in view of the delay in removal and the possibility of bacterial contamination, as well as the fact that valves were stored for up to 2 weeks - by which time tissue culture growth of freshly procured sterile canine leaflets stored at 4°C in electrolyte solutions has subsequently been shown to be either absent or delayed (Reichenbach et al., 1971)

In a later study Duran and Whitehead (1966) compared the fate of fresh allograft valves with freeze-dried allograft valves using the same technique as described in their earlier study (Duran et al., 1965) with aortic incompetence induced in the recipient dogs. Again the operative losses were high; only 13 of 25 animals receiving fresh valves were available for study between 6 hours and 12 months, and 15 of 26 animals receiving ethylene oxide sterilised and freeze-dried valves were available for study between 6 hours and 16 months, and 5 were retained for long-term studies.

Histologically, the first changes in the fresh valves were seen at 48 hours when the endothelial and fibroblast nuclei of the valve were pale and the valve was slightly oedematous. At 22 days most of the fibroblastic nuclei of the valve had disappeared; and valves implanted longer than this were devoid of nuclei.

In the freeze-dried valves nuclear lysis was virtually complete between 3 and 6 days. In two valves, implanted 13 and 16 months the valve was anuclear, delicate and composed entirely of collagen. The striking difference between the two types of valves was the much quicker loss of nuclei from the freeze-dried valves. The authors felt that the freeze-dried valves gave the better result in view of the earlier nuclear loss and the possibility that fibro-endothelial organisation of complicating thrombus is prevented.

Studies by Mohri's group at University of Washington, Seattle:

In view of accumulating evidence of clinical success with allograft heart valve implantation (Bigelow et al., 1964; Ross, 1964; Barratt-Boyes, 1964) it appeared that these valves were not being subjected to the rejection that would be expected with allogeneic tissue.

Clinical studies had also failed to detect antibodies in the serum of allograft valve recipients (Davies et al., 1965; Hudson, 1966). It was suggested that the explanation may be low antigenicity of the allograft valve, or the "privileged site" of the subcoronary position.

A study was therefore planned to attempt to evaluate this problem using dogs (Mohri et al., 1967b), and this work was then extended to evaluate the fate of viable and non-viable valves.

In the first report (Mohri et al., 1967b) 2 series of dogs were described. In one series, fresh, viable allograft aortic valves were implanted subcutaneously in 6 dogs. These dogs were subsequently given skin grafts removed from the valve donor animal and stored for 14 days. Using suitable control animals it was shown that the subcutaneously implanted valve did not result in acceleration of skin graft rejection. Polymorphs and mononuclear cells were present in the implanted leaflets early on; by 52 days leaflets were not identifiable. Lymphocytes and plasma cells were prominent in the fibrous tissue surrounding the implanted tissue.

The authors pointed out that the subcutaneous site for implantation did seem likely to have provided a sufficient stimulus for sensitization. The conclusion, therefore, was that the allograft aortic valve demonstrated low antigenicity.

In a second series, a single aortic valve leaflet, with a small amount of adjacent myocardium and aorta, was used as an allograft replacement for a leaflet of male experimental dogs. Female donors were chosen for the source of fresh valves - thus allowing assessment of cell origin in subsequent tissue culture by identification of sex chromatin bodies. Some of the recipient dogs had previously been sensitised by skin grafting from the donor dog.

All 20 dogs survived the operation - a tribute to the technique of total circulatory arrest with the aid of surface-induced deep hypothermia (Mohri et al., 1966a). 3 died within the first 3 months, and these, together with 4 others sacrificed at intervals up to 3 months, provided the basis for histological examination.

The histological appearances were different from those of the subcutaneously implanted valves. By the 6th day the leaflet showed increased ground substance, increased stromal connective cells with mitotic activity, and some polymorphs. At 20 days the leaflets were thickened and had abundant plump, oval, and elongated cells with mitotic figures. Lymphocytes and plasma cells were not present in the graft. By the third month the leaflet continued to be thickened and showed proliferation of fibroblastic-type cells with mitosis in the valve stroma. No differences were observed between the valves implanted into sensitised and non-sensitised dogs.

Tissue culture of the implanted leaflets revealed outgrowth of fibroblastic-type cells within 4 to 5 days. Sex chromatin bodies were demonstrable in 31%, 36% and 28% of cells grown from specimens obtained at 9, 30 and 60 days

respectively. Control fresh aortic leaflets from female dogs showed sex chromatin in 37% of cells.

Thus the donor origin of the proliferating fibroblastic-type cells in the leaflets was concluded. No difference in durability of the leaflets in sensitised or non-sensitised recipients was noted.

The study thus suggested low antigenicity of the allograft aortic valve, a possible privileged site of the subcoronary position, and the absence of graft rejection up to 3 months post-implantation, with survival of transplanted donor cells up to 3 months.

Mohri's group (Mohri et al., 1967a) later reported the fate of the remaining allograft leaflets beyond 3 months of implantation and showed that the initial thickening had disappeared by 4 months, at which time leaflet cellularity appeared normal. A short segment of acellularity near the base of the leaflet at 6 and 10 months was thought possibly to be the result of mechanical injury at the time of leaflet insertion. Tissue culture of transplanted leaflets revealed outgrowth of fibroblastic-type cells in all specimens recovered up to 6 months postoperatively. Sex chromatin bodies were present in 15% of cells and 16% of cells from valves in place for 4 and 6 months respectively. Prior sensitization by skin grafting did not alter the fate of the fresh allograft leaflet.

A similar study with betapropiolactone sterilised leaflets showed that all donor cells disappeared by 40 days after transplantation. There was no thickening of these leaflets and better preservation of leaflet pliability.

It was concluded that functional durability of the leaflet was not affected by the method of graft preparation, although betapropiolactone treated valves appeared possibly better than fresh valves. No evidence of graft rejection was found histologically up to 11 months postimplantation, and tissue culture of the fresh allograft leaflet demonstrated persistent donor cells at least 6 months postimplantation.

Mohri and his co-workers (Mohri et al., 1968b) went on to compare the long-term fate of viable and non-viable aortic valve allografts. This was stimulated by the reports of leaflet rupture in non viable leaflets (Smith, 1967; Hudson, 1966).

Reporting on the dogs operated on for their earlier studies they noted in the viable grafts prominent fibrosis and scarring of the myocardium and aortic wall by 12 months. The leaflets gradually lost pliability and showed some limitation of leaflet excursion. One leaflet implanted for 23 months showed retraction of its margin with shortening of the free edge and height of the leaflet. Markedly decreased leaflet cellularity was seen by 11 and 12 months.

Tissue culture growth was demonstrable from the explants from the free edge of the leaflet. The percentage of sex chromatin positive cells fell with time - being 37% in 3 controls; 32% in 3 valves implanted 2 months; 15% in 2 valves implanted 6 months; and 20% in one valve implanted 12 months.

Evidence of connective tissue extension over the host-graft junction from aorta and endocardium was present at 3 months, and by 6 months a connective tissue sheath extended onto the base of the leaflet - this varied in extent from specimen to specimen.

In the non-viable grafts (sterilised by betapropiolactone) there was less organisation and scarring of graft myocardium and at 12½ months leaflets were of nearly normal thickness with well preserved pliability. The non-viable grafts showed disappearance of leaflet cells by 40 days and acellularity up to 6 months. Extension of a connective tissue sheath onto the base of the leaflets occurred by 3 months, and gradually extended. At 1 year some host substitution of the leaflet was seen.

Thus, persistence of donor cells up to 12 months was demonstrated in viable implanted allograft valve, but diffuse or segmental acellularity were observed in late specimens. The non-viable grafts appeared superior to viable grafts up to 12½ months because of better maintained leaflet pliability.

Studies by Palo Alto and Stanford group in California:

The problem of late failure in chemically treated, frozen, irradiated, or freeze-dried allograft aortic valves prompted the Stanford University group to investigate fresh valves (Kosek et al., 1969). This group suggested the theoretical possibility of viable fibrocytes in such valves being capable of remoulding and repair of the valve. They described the features of allograft valves removed from 11 of the 120 patients in whom they had inserted fresh valves during the preceding 4 years, and in addition, tested fresh allograft valves in 40 dogs.

These workers found that fresh grafts retain viable fibrocytes capable of proliferation and elaboration of ground substance and collagen. Host sheath formation above and below the leaflet of the allograft valve extended a variable

distance onto the leaflets causing some thickening and rigidity, but no retraction of the leaflet. Some of the leaflet fibrocytes became swollen and increased in number, with abundance of granular endoplasmic reticulum indicative of active protein synthesis. Within 4 weeks there was pronounced increase in mucopolysaccharide ground substance, separating collagen fibres. The pattern of collagen and elastin became disordered or replaced by whorls of new connective tissue. The workers stated that the proliferating fibroblasts thicken the leaflet 5 to 10 times normal, thereby increasing its integrity with little alteration in function.

It was also noted that some fibroblasts suffered pyknosis, karyorrhexis, and disruption. The changes were considerably reduced in valves removed after 6 to 12 months, and were more marked in the canine than the human valves.

In a later study of the role of rejection (Buch et al., 1971) this same group created a 3-leaflet composite mitral valve, consisting of 1 autograft leaflet (from the experimental animal's own pulmonary valve); 1 heterograft leaflet (porcine); and one allograft leaflet. This fresh, composite valve was implanted in the mitral position of 20 dogs, using cardiopulmonary bypass. 2 operative deaths, and 6 early deaths from endocarditis occurred; the remaining 12 animals were sacrificed between 5 days and 1 year.

At 5 days all leaflets showed hypercellularity, which persisted in the autograft and the allograft at 3 months (the heterograft then being devoid of fibroblasts). Thickening persisted at 1 year in the autograft and the allograft, and the allograft leaflet was considered to be

showing mild degenerative changes as a result of host rejection. The structural changes in the canine allograft were similar to those in the human allografts, and this group went on to suggest that avoidance of major ABO incompatibilities between donor and recipient would be wise. (The wisdom of this suggestion has subsequently been refuted by Balch and Karp (1975) who found no relationship between success or failure of aortic valve allotransplantation and ABO Rhesus blood group compatibility. It is known that ABO blood group antigens are present in many tissues, including heart and blood vessels; and that ABO incompatibility in kidney transplants can elicit a vigorous rejection response (Starzl et al., 1964)).

Others have investigated the problem of rejection in allograft heart valves. Baue et al. (1968) confirmed the differing responses to allograft valves depending on the site of implantation - accelerated rejection occurred in sensitised animals if the leaflets were placed subcutaneously in dogs, but no difference was observed between the sensitised and non-sensitised groups if the valve was placed in the pulmonary area.

Suzuki et al. (1970) compared fresh allografts, beta-propiolactone sterilised allografts, and betapropiolactone sterilised heterografts in the mitral position of 29 dogs - the 23 survivors were examined between 1 and 29 months. The 8 fresh allograft valves showed progressive oedematous, inflammatory reactions, with a myxomatous stroma containing inflammatory cells, fibrocytes and fibroblasts. There were varying areas of focal necrosis. These workers noted a variable response between leaflets - some being more nodular and thicker than others. They concluded that although the valve appeared cellular, viable and covered with endothelium, continued fibroblastic proliferation suggested that such valves would eventually become scarred and incompetent.

Tector et al. (1971), investigating subcutaneously placed allograft valves in dogs suggested the possibility of aortic valve allografts in the subcoronary position undergoing a chronic type of rejection that is responsible for some of the graft failure.

Lower et al. (1960) had demonstrated evidence of rejection in pulmonary valve allografts - these were infiltrated by plasma cells and round cells, in contrast to autograft valves which were not.

McKenzie et al. (1965) showed necrosis occurring in allograft mitral valves, but considered that the findings were not due to rejection. Paton et al. (1967) and Kwong et al. (1967) suggested that allograft valve survival was improved in dogs treated with Imuran, but clinical use of immunosuppressives has not been used since the first human allografts were not clearly influenced by this treatment (Rosa, 1964).

Heslop et al (1973) investigated the antigenicity of aortic valve allografts in rats. This study had the advantage of allowing use of inbred rats of known isohistogenic strains. These workers inserted into the abdominal aorta grafts consisting of myocardium and aorta with valve leaflets (analagous to clinical graft); aorta only; and leaflets only. Similar grafts were inserted subcutaneously. They were able to show that antigenicity resided predominantly in the rim of the cardiac muscle (although a significant contribution from donor leucocytes could not be excluded). The antigenicity of the aortic portion was slight, and the leaflets were apparently not immunogenic. Histology of valves implanted for 2 weeks in the aorta showed that in the syngeneic grafts the leaflets were cellular and normal; in the allogeneic grafts the leaflets were acellular and showed oedema and degeneration of collagen.

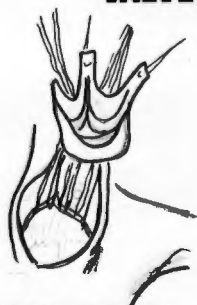This appears to be an important study; it shows the lack of immunogenicity of the leaflets, but presence of immunogenicity of other components of the graft (especially the muscle); but, also, it shows the rapid loss of cells in allogenic leaflets after only 2 weeks (relevant in the

choice of time-scale for the proposed experimental study). These valves would have been non-functioning - but this cannot be the explanation of the acellularity as the non-functioning syngeneic leaflets remained cellular.

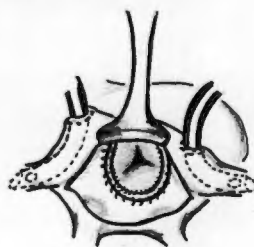
Considerable ingenuity has been shown in the implanation of allograft cardiac valves in experimental animals in the past (Willman et al., 1961; Lower, 1961; Magovern, 1961; Litwak, 1961; McKenzie et al., 1965; Van Vhet et al., 1965; Brewin, 1956; Absolon, 1961; Litwak et al., 1952) but these studies shed little light on the question of viability in allograft valves.

3b Current applications of allograft heart valves in clinical practice

VALVE REPLACEMENT



AORTIC VALVE



MITRAL VALVE

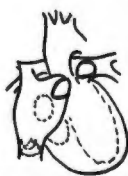

"FREE" GRAFT



"MOUNTED" GRAFT (FRAME OR TUBE)

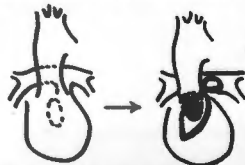
**RIGHT VENTRICULAR
OUTFLOW
RECONSTRUCTION**



**TRICUSPID ATRESIA
OR
SINGLE VENTRICLE**



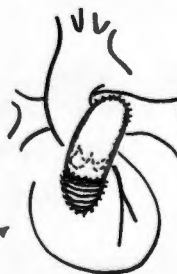**PULMONARY ATRESIA
OR
SEVERE FALLOT**



TRANSPOSITION + V-S-D



TRUNCUS ARTERIOSUS



3b CURRENT APPLICATION OF ALLOGRAFT HEART VALVES IN
CLINICAL PRACTICE

VALVE REPLACEMENT

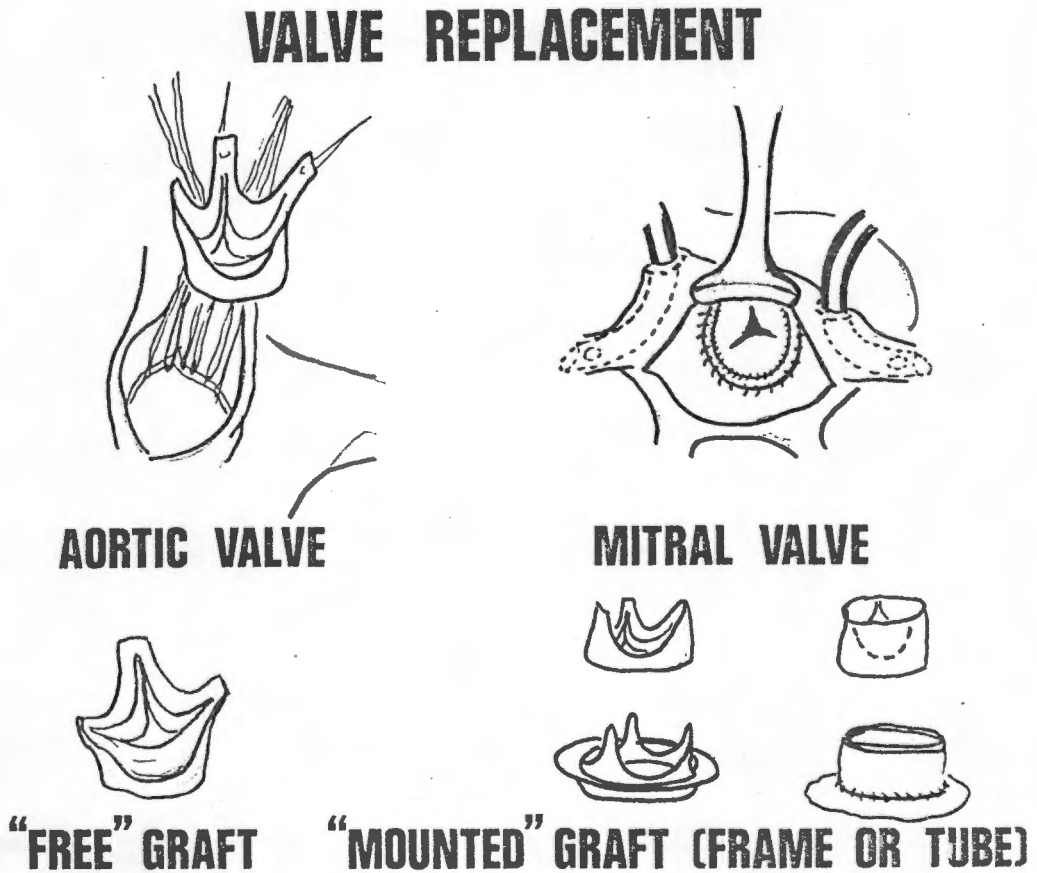


Figure 3b - 1

As shown diagrammatically in Figure 3b-1 the allograft aortic valve can be used to replace any of the heart valves.

Its most widespread current use is in the replacement of the aortic valve. Here it is usually placed in the aortic annulus of the host as a 'free' graft. The allograft aortic valve is trimmed to remove as much as possible of the adjacent myocardium, and the aorta is cut away from the sinuses to avoid

covering of the host coronary ostia. A double suture line technique, as described by Barratt-Boyes and Roche (1969) is used. For the lower suture line either interrupted sutures or a continuous suture are used - the lower suture line being inserted with the valve turned inside-out and pushed through the annulus of the host into the left ventricle. After completion of the lower suture line the valve is pulled back up into the aortic root for completion of the upper suture line. Some of the technical points that have been helpful in valve insertion are referred to in Section 3c.

For replacement of other cardiac valves it is necessary to mount the allograft aortic valve on a frame or within a supporting tube. A frame-mounted aortic valve can be inserted into the aortic annulus as well, and this does allow quicker insertion with reliable accuracy of valve positioning.

The results of allograft replacement of the aortic valve are given in detail for a series of 100 patients operated on by Mr. J. Keith Ross at the National Heart Hospital in Section 3c. The results of allograft aortic valve replacement by Mr. Donald Ross at the National Heart Hospital are similar (Ross, 1975) - 311 patients are reviewed with 10 year follow-up. In this group there has been a 16% incidence of valve failure, but this has affected the earlier freeze-dried valves. The allograft aortic valve remains the valve of choice for aortic valve replacement in this centre.

The experience with the use of allograft aortic valves in the mitral position has not been as satisfactory in many centres (Angell et al., 1975a; Lennox, 1975; Oh et al., 1973) and this has related to long-term failure. These valves

worked well, with good haemodynamic properties and freedom from thromboembolism. However, the experience of Yacoub (1975) has been remarkably good using the aortic allograft valve mounted in a semi-flexible tube of dacron. 428 patients had mitral valve replacement by this technique between August 1969 and March 1974. A very low incidence of late complications has been seen, and haemodynamic performance, and freedom from thromboembolism and haemolysis, make this the method of choice for mitral valve replacement for this author.

Balch and Karp (1975) report 385 patients having aortic allograft valve replacement at the Alabama Medical Centre between 1968 and 1973. The valves had been frozen to -72°C and sterilised by irradiation, and kept for up to 6 months before being discarded if not used. 35 failures had occurred during this time in the series of 385 valves.

Wallace et al. (1974) report 229 patients undergoing aortic allograft valve replacement between May 1965 and October 1972 at the Mayo Clinic. The first 92 valves had been betapropiolactone sterilised and stored in Hanks solution; the remaining 137 valves had been sterilised by irradiation and stored at -70°C . There were 11 hospital deaths (4.8%). 20% of survivors had an aortic diastolic murmur at time of hospital dismissal - this was the only significant variable in predicting probability of reoperation for valve failure; no significant difference in late valve failure was seen between the two methods of sterilisation. 34 required reoperation for replacement of the allograft valve from 4 to 91 months after initial operation.

Angell et al. (1973a) reported 189 patients receiving isolated aortic replacements and followed for 5 years. These valves were procured under sterile conditions initially; but later sterilised with antibiotics. 5 year survival was 80% and half of the deaths were accounted for by valve-related causes; 30% of living patients had valve-related complications, including regurgitation or reoperation.

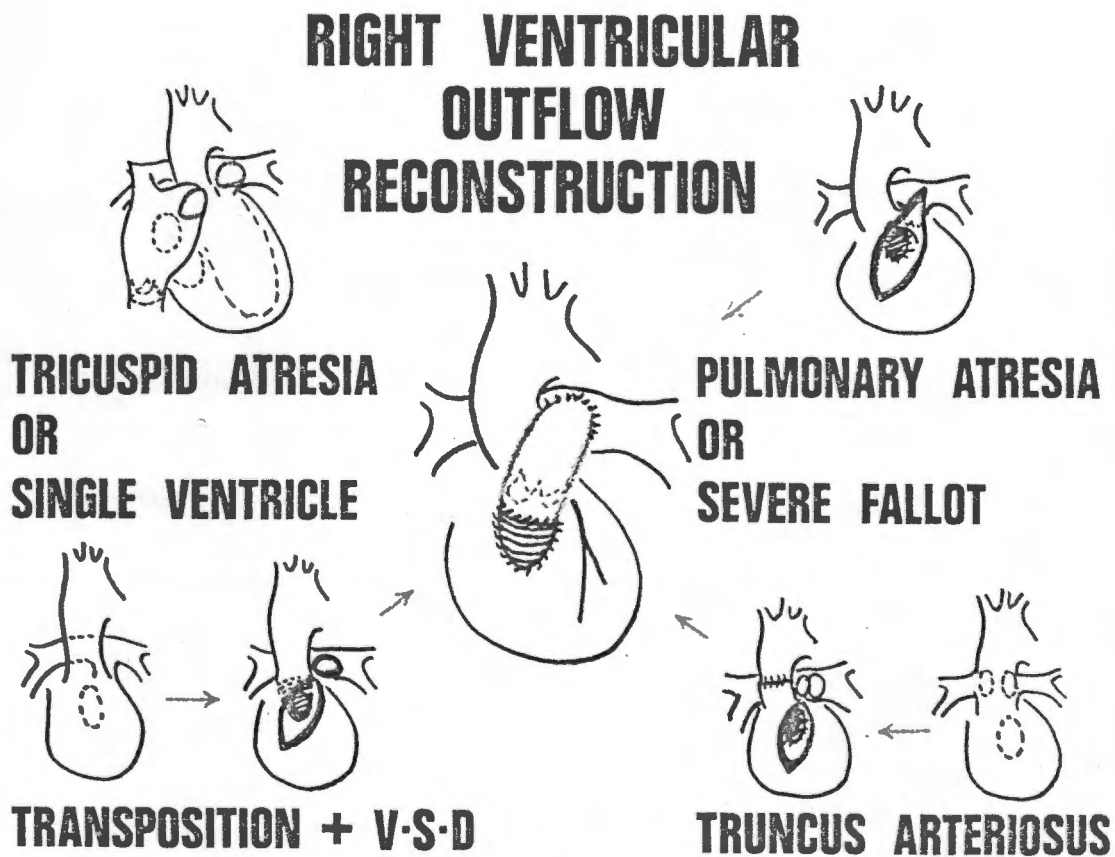
RIGHT VENTRICULAR OUTFLOW RECONSTRUCTION

Figure 3b - 2

As shown diagrammatically in Figure 3b-2 the allograft aortic valve can be used together with the ascending aorta and cuff of adjacent mitral valve and myocardium as a valved conduit for the reconstruction of the right ventricular outflow in a number of congenital cardiac defects.

Section 3d reviews experience with this procedure at the National Heart Hospital. The use of a homograft or allograft conduit remains the procedure of choice at this centre for reconstruction of the right ventricular outflow (Ross, 1975b). Continued good results from this form of

reconstruction were reported by Ross and Somerville at the British Cardiac Society Meeting in November, 1975 in London.

McGoon et al. (1973) reported the use of an allograft conduit of ascending aorta including its valve, between the right ventricle and pulmonary artery (the "Rastelli operation"). In 111 operations at the Mayo Clinic the procedure was used for reconstruction in truncus arteriosus (55 cases), transposition of the great arteries with pulmonary stenosis (36 cases), pulmonary atresia (11 cases) and miscellaneous conditions (9 cases). The operation carried a hospital mortality of 32% for the entire group - worst for transposition of the great arteries with pulmonary stenosis under the age of 5 years and patients with truncus arteriosus and high pulmonary vascular resistance. This risk was a reflection of the problems associated with the conditions, and did not imply any difficulty with the use of allograft conduits for the reconstruction.

3c

HOMOGRAFT AORTIC VALVE REPLACEMENTA personal review of 100 consecutive patientsJune 1975SUMMARY

100 consecutive patients who had isolated aortic valve replacement with a homograft valve have been followed for 21 to 83 months. There were two hospital deaths. 85% of patients had competent valves at time of discharge; 14% had mild valve incompetence. Anticoagulants were not used and three thromboembolic episodes occurred, confirming the relative freedom of homograft valves from this complication.

Preparation of the homograft valve was altered twice in the series in the hope of reducing the incidence of late valve failure. 42 ethylene oxide sterilised valves and 26 gamma irradiated valves have shown a 30% incidence of valve failure over a 4 to 7 year period. 32 antibiotic sterilised valves have not shown valve failure over 2 to $4\frac{1}{2}$ years, encouraging the hope that these will prove more durable than the earlier valves.

Although homograft heart valves have advantages over prosthetic valves, their use has been restricted by concern regarding late valve failure. This has been ascribed to earlier valve preparation techniques and it is hoped that current techniques of antibiotic sterilisation will reduce the incidence of such failure.

It is therefore of interest to report 100 consecutive patients who had isolated aortic valve replacement with a homograft aortic valve between November, 1967 and July, 1972 at the National Heart Hospital, London, by Mr. J. Keith Ross or his registrar. Surgical technique varied little; but valve preparation was altered from ethylene oxide sterilisation to gamma irradiation, and finally to antibiotic sterilisation during the series (Lockey et al. 1972).

Clinical details

Of the 100 patients 75 were male and 25 female. Ages ranged from 14 years to 67 years (average 43 years).

Two patients were symptom-free; 14 were in cardiac failure; the remainder had symptoms of either chest pain on effort, syncope, or exertional dyspnoea (Grade II or III of the New York Heart Association classification).

27 patients gave a history of previous rheumatic fever. 19 patients had previously been treated for infective endocarditis.

The valve lesion was predominantly aortic stenosis in 39 patients (usually calcific), aortic regurgitation in 23 patients (often following previous infective endocarditis), and mixed in 38 patients.

59 patients had heavily calcified valves and this frequently obscured the likely aetiology, but 28 patients were judged to have congenital aortic stenosis, 27 had valves which appeared rheumatic in aetiology, and in the remaining 55 the aetiology was uncertain.

Surgical technique

All patients were operated on by the median sternotomy approach with normothermic cardiopulmonary bypass. Coronary perfusion was used in all.

25 patients had additional procedures. 9 of these were left ventricular septal myotomy where subvalve hypertrophy was judged to be excessive and obstructive, 2 had closure of ventricular septal defect, and the remaining 14 had open mitral valvotomy with or without annuloplasty, mitral leaflet advancement or tricuspid annuloplasty.

Early in the series an oblique aortotomy was made down to the non-coronary sinus; later this was modified to a part-vertical/part-transverse aortotomy which left the host non-coronary sinus intact, thereby facilitating placement of the grafted valve commissures to avoid distorting its non-coronary sinus (Figure 3c-1).

Aortic root tailoring was used when the root was large. Sutures placed beneath the commissures reduced the annulus size ensuring an accurate fit for the grafted valve. This manoeuvre was used in 25 patients (Figure 3c-2).

Less commonly the aortic root was enlarged by incorporation of a Dacron gusset into an oblique aortotomy where a small root had been anticipated - especially if the graft non-coronary leaflet appeared likely to prolapse as a result of its commissures being pulled together by aortotomy closure. This was done in 6 patients (Figure 3c-3).

Initially in the series, and when the aortic root was small, the lower suture line was of interrupted sutures; later the continuous suture technique of Barratt-Boyes was used (Barratt-Boyes and Roche, 1969).

Valve preparation

42 patients received homograft aortic valves which had been sterilised with ethylene oxide. 34 of these were flash frozen to -79°C and stored at that temperature, the remaining 8 were freeze-dried and stored at room temperature.

26 patients received homograft aortic valves which had been sterilised by gamma irradiation. 21 of these were flash frozen to -79°C and stored at that temperature, the remaining 5 were freeze-dried and stored at 4°C .

Most recently in the series, from February 1970, 32 patients have received homograft aortic valves sterilised in antibiotics and stored at 4°C in Hank's Solution or Nutrient medium (Lockey et al. 1972).

Follow-up assessment:

Primary interest has been in the assessment of function of the homograft valve. This assessment is not always easy to make clinically. It is well recognised that presence or absence of symptoms relates poorly to the functional state of the aortic valve, and furthermore, the assessment of the clinical findings is not always easy, particularly in post-operative patients. It is possible to demonstrate mild to moderate aortic regurgitation angiographically in some patients who show no clinical evidence of regurgitation.

The clinical appreciation of aortic stenosis can be difficult in these patients - a systolic ejection murmur is commonly present from the time of operation and evidence of left ventricular hypertrophy may not entirely regress post-operatively. One patient required replacement of a severely stenosed calcified homograft aortic valve where clinical recognition of the situation was in all probability delayed by the diagnostic difficulties. This is an uncommon manifestation of valve failure - increasing regurgitation is the usual consequence.

Recognising these difficulties an attempt was made to assess clinically the functional state of the homograft valve. Information has been obtained from clinical, radiological and electrocardiographic findings at 6-monthly hospital visits in the majority; in the rest referring physicians have supplied the necessary data. Findings at re-operation have provided incontrovertible evidence in cases of valve failure.

At follow-up patients have been grouped into the following categories:-

- A Normally functioning valve. Here there is no clinical evidence of valve stenosis or incompetence.

- B Mild valve dysfunction. Here clinical evidence of a minor leak is present (sufficient to give rise to a diastolic murmur, but no other evidence of regurgitation).

- C Moderate valve dysfunction. Clinical evidence of more important regurgitation is present in addition to a diastolic murmur.

- D Severe valve dysfunction. Here dysfunction is severe enough to warrant re-operation. Most in this category have in fact undergone re-operation which has confirmed valve failure.

RESULTS

In the series of 100 patients there were 2 hospital deaths. 4 patients who have left the country cannot be traced; one died at two months, and 93 are available for follow-up.

Ethylene Oxide Sterilised Valves

In the group of 42 patients who received homograft aortic valves sterilised with ethylene oxide there was one hospital death on the first post-operative day from low output state. This patient had had infective endocarditis and had pre-operatively suffered a major infarct of his left ventricle following a coronary embolus.

Follow-up is available for 39 patients in this group.

At present 12 have normally functioning valves (category A) at between 54 and 82 months (average 68 months) after surgery.

A further 12 have mild valve dysfunction (category B) at between 60 and 83 months (average 69 months) after surgery. 9 of these changed from A to B between 2 and 50 months (average 19 months) and 3 have been stable in this category for 78, 77 and 62 months respectively.

3 patients have moderate valve dysfunction (category C) at 60, 72 and 82 months respectively - one initially A changed to C at 12 months; one initially B changed to C at 29 months, and one has remained stable in this category for 82 months.

One patient of this group died at 28 months of carcinoma of the breast, the homograft valve having functioned normally (category A).

11 patients have required replacement, having deteriorated into category D between 27 and 67 months (average 48 months) post-operatively and re-operation has been performed in 10 of these at

an average of one month later. In only one did infective endocarditis at 25 months appear to be a factor in deterioration of the valve. In 9 the patient was in category A for between 2 and 37 months (average 19 months); in 2 the patient was in category B immediately after the original operation for 20 months and 15 months respectively.

Figure 3c-4 shows in histogram form the functional status of the ethylene oxide sterilised homograft valves at each year after surgery. Follow-up as yet does not extend to 5 and 6 years in all but the trend of an increasing proportion of dysfunctioning valves with time is clear.

Gamma Irradiated Valves:

In the group of 26 patients who received valves sterilised by gamma irradiation there was one death at 2 months after surgery - valve function had been satisfactory at time of discharge but the patient developed signs of mild aortic regurgitation prior to sustaining a fatal hemiplegia overseas. This valve was not processed at the National Heart Hospital, and in retrospect, its early failure, almost certainly complicated by infection, seems related to its preparation.

Follow-up is available for 24 patients in this group.

At present 5 have normally functioning valves (category A) at between 49 and 66 months (average 59 months) after surgery.

A further 8 have mild valve dysfunction (category B) at between 49 and 77 months (average 68 months) after surgery. 7 of these changed from A to B between 4 and 66 months (average 36 months) and one has remained in category B from the time of operation for 72 months.

3 patients have moderate valve dysfunction (category C) - 2 having changed from A to C at 70 and 72 months respectively, and one having been initially B changed to C at 46 months.

8 have required replacement, having deteriorated into category D between 7 and 76 months (average 51 months) and operation has been performed in 7 of these at an average of 2 months later. No evidence of infective endocarditis was present in any. Deterioration had been gradual in 4; relatively rapid - over a few weeks - in 4.

Figure 3c-5 shows in histogram form the functional status of the gamma irradiated homograft valves at each year after surgery. Again, an increasing proportion of dysfunctioning valves with time is apparent.

Antibiotic Sterilised Valves:

In the group of 32 patients who received antibiotic sterilised valves there was one hospital death - an unexpected sudden death attributed to a dysrhythmia which occurred on the 4th post-operative day - and autopsy failed to show any valve-related cause for death.

There have been 2 late deaths not related to the valve at 36 months (systemic lupus erythematosus) and 12 months (myocardial infarction). Autopsies in both showed the homograft valve to be satisfactory, confirming the clinical assessments (category A).

Follow-up has been unobtainable in one case.

Of the 30 available for follow-up 19 have normally functioning valves (category A) at between 21 and 43 months (average 33 months) after surgery.

8 have mild valve dysfunction (category B) at between 30 and 55 months (average 39 months). 7 of these changed from A at between 2 and 55 months (average 19 months); one has been in category B from the time of operation for 41 months.

One patient has moderate valve dysfunction (category C) at 40 months, having changed from B at 4 months.

None has required replacement.

Figure 3c-6 shows in histogram form the functional status of the antibiotic sterilised valves at each year after surgery. The short follow-up for this group clearly makes comparison with the other groups difficult.

Thrombo-embolism

Patients have not routinely been anticoagulated after surgery. Apart from the patient who died at 2 months with hemiplegia two patients had minor embolic episodes - one a hemiparesis at 3 months, and one a transient blindness of one eye at 2 weeks. The relative freedom of homograft valves from thromboembolism is confirmed in this series.

Re-operation

Re-operation has been undertaken in 17 patients with 3 deaths.

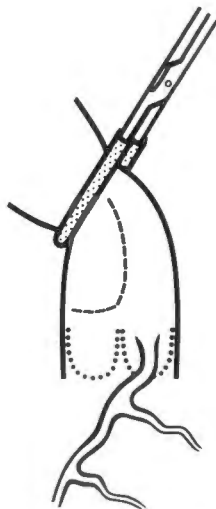
7 patients had a second homograft valve inserted (antibiotic sterilised) without mortality and these valves are functioning normally at this stage (between 3 and 30 months post-operatively).

9 patients had prosthetic valves inserted, and one had a fascia lata valve which in turn was replaced by a Starr Edwards valve after 5 years.

The findings at re-operation were similar in all. Calcification of the homograft valve, particularly at the bases of the leaflets, was present in variable degree. Fenestrations and tears of the leaflets had resulted in severe regurgitation in all except one where extensive calcification had caused such leaflet rigidity that stenosis had occurred.

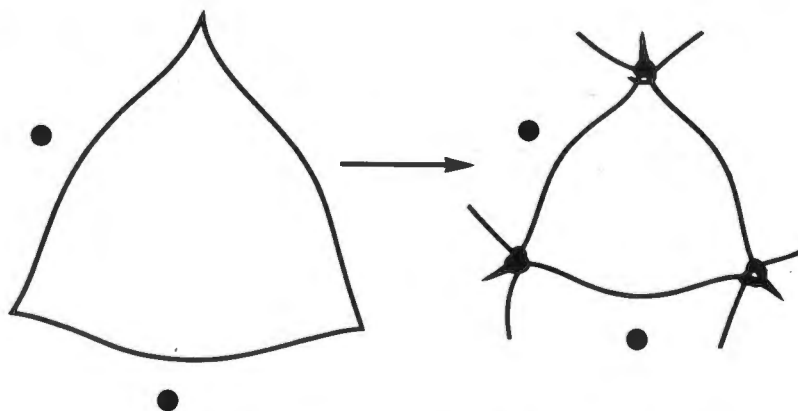
Histologically, the leaflets were homogenous cell-free structures, with areas of calcification and structural disruption (Olsen, 1975).

Figure
3c - 1



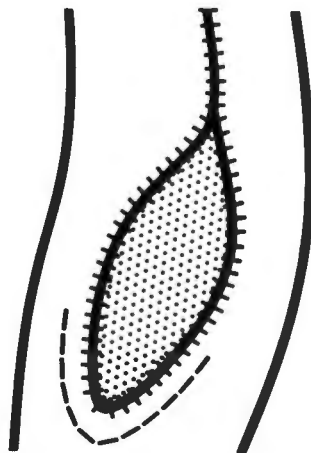
**PART VERTICAL—PART TRANSVERSE
AORTOTOMY LEAVING HOST NON—
CORONARY SINUS INTACT**

Figure
3c - 2



**AORTIC ROOT TAILORING
SUTURES AT COMMISSURES**

Figure
3c - 3



**SMALL AORTIC ROOT ENLARGED
WITH DACRON GUSSET**

ETHYLENE OXIDE STERILISED VALVES

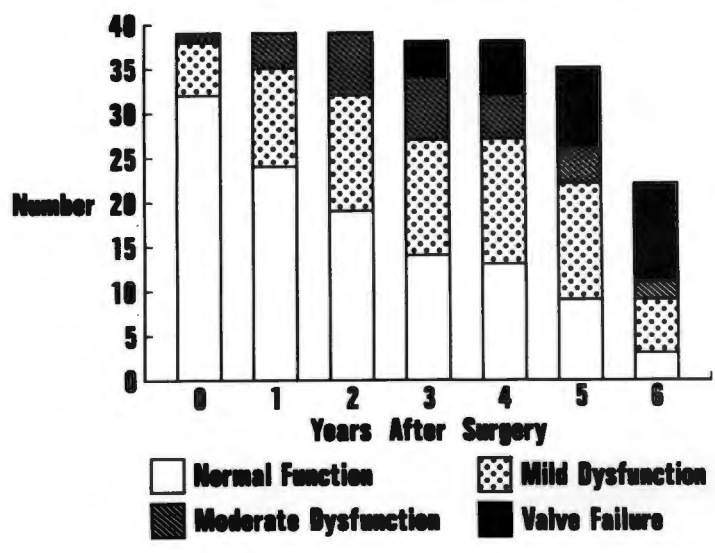


Figure 3c - 4

GAMMA IRRADIATED VALVES

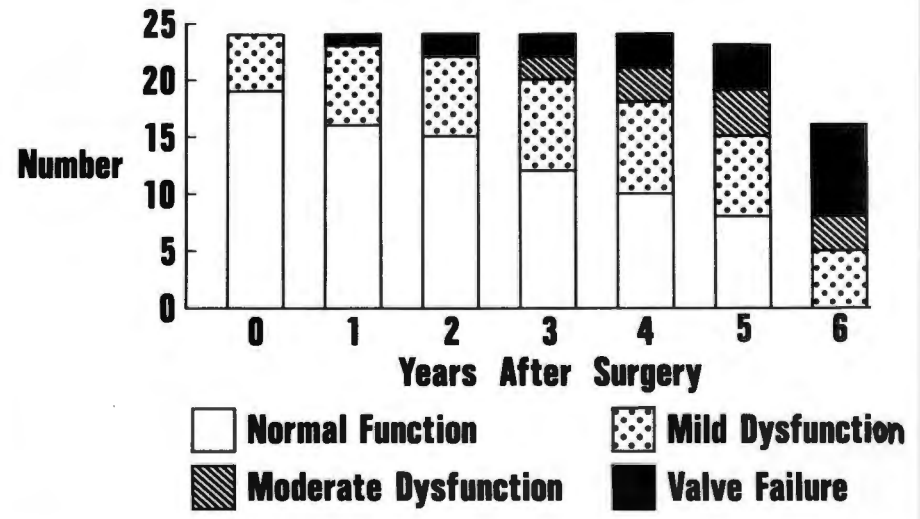


Figure 3c - 5

ANTIBIOTIC STERILISED VALVES

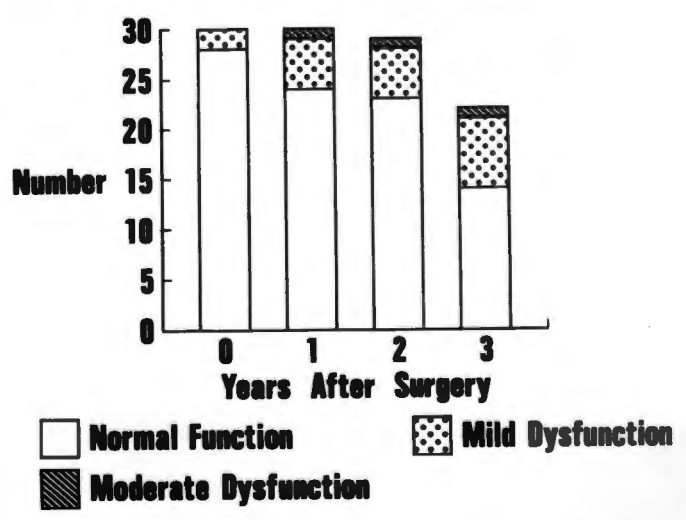


Figure 3c - 6

DISCUSSION

This series clearly demonstrates the feasibility of replacing the aortic valve with a homograft valve with low operative mortality - the two hospital deaths in the 100 patients do not appear to be related to the type of valve used. Other series have demonstrated low hospital mortality of the order of 5% which has been at least as good as that for prosthetic valves (Wallace et al., 1974; Ross, 1972; Karp et al., 1974).

Technically, homograft valve insertion is more demanding than prosthetic valve insertion but the points outlined in surgical technique were found helpful. An early diastolic murmur at the time of hospital discharge has been taken as being indicative of slight malposition of the homograft valve and was present in 15% of patients in this series. This is similar to other reported series (Wallace et al., 1974; Angell et al., 1973a)

The homograft aortic valve remains a good substitute for the diseased aortic valve in spite of continuing improvements and modifications in prosthetic valve design (Ross, 1972). Relative freedom from thrombo-embolism and excellent haemodynamic properties are their main advantages. The low incidence of thrombo-embolism without anticoagulation in this series is in keeping with that reported by other centres (Wallace et al., 1974; Karp et al., 1974; Barratt-Boyes and Roche, 1969).

However, from the time of the first clinical homograft valve replacement in 1962 (Ross, 1962) concern has been expressed about long-term integrity of such valves. Late valve failure has been ascribed to earlier preparation techniques (Barratt-Boyes and Roche, 1969; Gavin et al., 1973b) and antibiotic sterilisation has been adopted in the expectation of reducing the incidence of late failure (Angell et al., 1973a).

Ethylene oxide sterilised valves have been followed for between 54 and 83 months (average 69 months) in this series and 11 of the 39 patients have required replacement for valve failure. However, 24 still have normally functioning valves or mild regurgitation evident only as a diastolic murmur.

In the group of 24 gamma irradiated valves followed for between 49 and 77 months (average 65 months) 8 have required replacement for valve failure while 13 still have competent or mildly regurgitant valves.

Comparison with the antibiotic sterilised homograft valves in the group of 30 is difficult in view of the shorter follow-up period (21 to 55 months - average 35 months) but none has required replacement and 27 have competent or mildly regurgitant valves.

In the first two groups (ethylene oxide sterilised and gamma irradiated valves) there is thus about a 30% incidence of valve failure requiring re-operation over a follow-up period of 4 to 7 years.

Wallace et al. (1974) report 34 patients of 218 with beta-propiolactone sterilised or irradiated valves requiring replacement between 4 and 91 months (average 42 months). Karp et al. (1974) estimate that 10 to 15% of patients with irradiated homografts will need replacement at 5 to 6 years.

Barratt-Boyes and Roche (1969), Ross (1972) and Angell et al. (1973) report good results with antibiotic sterilised valves, although Gavin et al. (1973) report that the pathological changes in such valves following removal from patients are qualitatively similar to those observed in chemically sterilised valves although there are quantitative differences. Clearly further follow-up data is required, particularly in this reported series, but this series

does demonstrate the unsatisfactory long-term failure rate in ethylene oxide sterilised and gamma irradiated valves and shows promise of better results from antibiotic sterilisation of the homograft valve.

3d

RECONSTRUCTION OF RIGHT VENTRICULAR OUTFLOW
WITH A VALVED HOMOGRAFT CONDUIT

D. J. Wheatley, S. Prusty, and D. N. Ross

Department of Surgery, National Heart Hospital, London W.1

WHEATLEY, D. J., PRUSTY, S., and ROSS, D. N. (1974). Thorax, 29, 617 - 623. Reconstruction of right ventricular outflow with a valved homograft conduit. Since 1966 a conduit of homograft ascending aorta with its valve has been used for reconstruction of the right ventricular outflow. This technique has been applied to 123 operations for pulmonary autograft replacement of the aortic valve, 48 operations for correction of severe Fallot's tetralogy or pulmonary atresia, five operations for truncus arteriosus, two operations for transposition of the great arteries with ventricular septal defect, and six operations for tricuspid atresia or common ventricle. Ease of insertion and satisfactory function have encouraged us in the use of this form of conduit.

The problem of providing an adequate pathway for blood from the right ventricle to reach the pulmonary arteries arises in a number of cardiac surgical procedures. These include severe forms of Fallot's tetralogy, pulmonary atresia, truncus arteriosus, and transposition of the great arteries with ventricular septal defect.

In 1966 a conduit of homograft ascending aorta with its valve was first used to solve this problem in a patient with pulmonary atresia (Ross and Somerville, 1966). The patient remains alive and the technique is now well established. This paper reports experience with this technique since 1966 at the National Heart Hospital.

SURGICAL TECHNIQUE

The homograft conduit consists of ascending aorta with its valve together with remnants of the anterior leaflet of the mitral valve. This tissue is obtained at routine necropsy within 48 hours of death and is currently sterilized and stored at 4°C in an antibiotic-nutrient medium (Lockey, Al-Janabi, Gonzales-Lavin, and Ross, 1972).

The insertion of the conduit presents few technical problems. The graft is trimmed to a suitable length and the coronary orifices of the graft are sutured. The graft is positioned to take advantage of its natural curvature, thus reducing distortion of the valve. The distal end of the graft is anastomosed with a continuous suture to the opened-out distal pulmonary artery or the region of the pulmonary artery bifurcation and may be extended out into one or other pulmonary artery as required. Proximally the graft is 'countersunk' as far as possible into the right ventricle to give a satisfactory angle of origin; this requires trimming of the edges of the right ventriculotomy. There is usually a defect present anteriorly between the graft and the right ventricle and this is closed with a Dacron or pericardial gusset (Fig. 1).

The conduit functions well and provides a competent valve for the right ventricular outflow. Calcification commonly appears in the aortic wall of the graft and is visible radiologically after about six months. However, it does not appear to impair valve function nor involve the cusps (Somerville and Ross, 1972).

APPLICATIONS OF THE TECHNIQUEPULMONARY AUTOGRAFT REPLACEMENT OF THE AORTIC VALVE

Considerable experience has been gained in reconstructing the right ventricular out-flow with a homograft conduit in the operation of aortic valve replacement with pulmonary autograft (Gonzales-Lavin, Geens, Sonerville, and Ross, 1970). Since 1967, 123 operations for aortic valve replacement have been performed using the patient's autogenous pulmonary valve, which is excised early in the course of the operation once the need for replacement of the aortic valve has been confirmed (Figure 3d-2).

The pulmonary valve offers an ideal valve for replacement, not having been exposed to sterilization or storage techniques. The operation is technically demanding and it has been limited to younger patients. There have been no problems relating to the use of homografts in this application of right ventricular outflow reconstruction. In the group of 123 patients there have been 16 hospital deaths and three late deaths. Results in the survivors are gratifying (Ross, 1972). Thirty-five of these patients have had normally functioning homograft outflow conduits for five years or more. One of the late deaths occurred at five and a half years; no explanation was found and the homograft valve in the right ventricular outflow was remarkable for its normal appearance and integrity.

CORRECTION OF SEVERE FALLOT'S TETRALOGY AND PULMONARY ATRESIA

Since 1966, 48 patients with severe Fallot's tetralogy or pulmonary atresia have had right ventricular outflow reconstruction using this technique. Although 24 were considered at operation to have pulmonary atresia of

type 1 or type 11 (Somerville, 1970), and 24 to have severe Fallot's tetralogy with a hypoplastic infundibulum, pulmonary valve ring, or main pulmonary artery, the distinction may be difficult to make preoperatively, and from a surgical point of view they are varying degrees of the same basic problem. Indeed some patients who have been shown to have severe Fallot's tetralogy prior to systemic-pulmonary anastomosis have on re-investigation failed to opacify the right ventricular outflow, and the appearance at surgery has been of pulmonary atresia.

In this difficult group of 48 patients there have been 21 hospital deaths. Reconstruction of the right ventricular outflow with a valved homograft conduit has not been technically difficult, although in one case a problem arose from compression of the graft by the sternum on closure of the chest. This was appreciated only after re-opening of the chest for low cardiac output state, and the patient subsequently died.

The age range of this group was 18 months to 34 years (Table I). The 18 month-old child was unsuccessfully operated on under emergency conditions following cardiac arrest during left thoracotomy for a Blalock anastomosis.

Previous palliative systemic-pulmonary anastomoses were present in 37 of the patients (Table II). These shunts were closed as a preliminary step to correction. In some patients a previous Waterston palliative anastomosis appeared to have kinked the right pulmonary artery and led to preferential filling of the right lung and lack of development of the segment of right pulmonary artery behind the aorta and of the left pulmonary artery. In seven

patients it was necessary to dissect the right pulmonary artery off the aorta at the Waterston anastomosis and patch the right pulmonary artery to enlarge it at the shunt site.

A vertical incision has been preferred in the right ventricular outflow where the outflow is known to be atretic or narrowed as this incision can readily be extended up into the pulmonary artery if necessary (Figure 3d-3). The coronary arterial anatomy must be borne in mind in planning the incision. An anomalous left anterior descending artery is a particular hazard; division of such a vessel led to the death of one of our patients.

In all cases the ventricular septal defect was patched with Dacron cloth (one patient had three ventricular septal defects). In addition an atrial septal defect was closed in four patients. Other procedures required at the time of correction (in addition to closure of any systemic-pulmonary anastomosis) are shown in Table III.

The major cause of death was failure to relieve right ventricular hypertension (Table IV), right ventricular pressure usually being equal to or in excess of left ventricular pressure immediately after correction. This was associated with a progressively falling arterial PO_2 and bleeding from the conduit anastomotic lines. In 10 patients died, unresolved right ventricular hypertension was the major factor in the death. This was not due to obstruction in the homograft conduit, and pressures in the distal pulmonary arteries were similarly raised. The same problem has been encountered in severe Fallot's tetralogy treated by patch enlargement of the right ventricular outflow. Increased

pulmonary vascular resistance due to high flow systemic connections, or hypoplastic pulmonary vessels well out into the lungs, have explained these deaths.

The ratio of right to left ventricular pressure after correction on the operating table has given a fairly good indication of the prognosis (Table V). In 19 of the 27 survivors the right ventricular pressure was half or less than half of the left ventricle.

There was one totally unexplained death at two months, where the right ventricular outflow reconstruction looked entirely satisfactory at post-mortem examination. Results in the survivors have been good and there has been no evidence of dysfunction of the homograft conduit, with the exception of one patient whose central venous pressure remained elevated and was shown to have a gradient of 60 mmHg across the conduit 11 days after surgery. In seven patients the conduit has functioned well for over five years. Duration of homograft conduit function is shown in Table VI.

CORRECTION OF TRUNCUS ARTERIOSUS Correction of truncus arteriosus has been limited to five cases in our experience. There were two deaths. The pulmonary arteries were isolated from the truncus and the ventricular septal defect was closed, after which a valved aortic homograft conduit was used to reconstitute a right ventricular outflow in the usual manner described (McGoon, Rastelli, and Ongley, 1968; Weldon and Cameron, 1968) (Fig. 3d-4).

CORRECTION OF TRANSPOSITION OF THE GREAT ARTERIES WITH VENTRICULAR SEPTAL DEFECT Experience with correction of transposition of the great arteries with ventricular septal defect and left ventricular outflow tract obstruction has

been limited to two cases. After placing a patch to redirect left ventricular blood through the ventricular septal defect into the aorta a conduit of homograft aorta is used to reconstruct a right ventricular outflow - the proximal end of the divided pulmonary artery having first been oversewn (Rastelli, McGoon, and Wallace, 1969) (Figure 3d-5).

CORRECTION OF TRICUSPID ATRESIA AND CORRECTION OF COMMON VENTRICLE Recently this technique has been applied in a modified form to the problems of tricuspid atresia and to common ventricle. Here the right atrium is adapted to function as a 'right ventricle' and a conduit is used as a right ventricular outflow (Fontan and Baudet, 1971; Ross and Somerville, 1973) (Figure 3d-6).

Two of the four tricuspid atresia patients have survived, but the two common ventricle patients were near-terminal when operated on and did not survive postoperatively. However, initial function was promising and it is possible that the technique may have application in this field.

DISCUSSION

The need for construction of an outflow tract for the right ventricle is common to many conditions. The technique of using a valved conduit as outlined is one approach to the problem (McGoon, Wallace, and Danielson, 1973). This technique has given satisfactory results in our experience well as in other centres (Brawley et al., 1972). However, further observation is required before the long-term fate of such a conduit can be assessed.

Various other conduits are currently in use (Kouchoukos, Barcia, Bargeron, and Kirklin, 1971), tubes of Dacron with or without prosthetic, heterograft or homograft valves giving satisfactory results in other centres. Our early experience with tubes made of fascia lata containing a fascial valve was uniformly unsuccessful in 11 patients (Ross and Somerville, 1971). We have been concerned about the possible adverse effect of pulmonary regurgitation where a valve is not used, and prosthetic valves may be responsible for silent thromboembolism to the lungs.

Results of using homograft aortic segments to replace sections of the aorta resected for aneurysm or coarctation showed that although calcification is heavy in the non-viable grafts their function as conduits is retained for eight to 17 years after implantation (Brock, 1968). Long-term results following homograft aortic valve implantation suggest that reasonable long-term valve function can be expected, and the use of viable homograft tissue may improve the outlook further (Barratt-Boyes, 1971; Angell, Shumway, and Kosek, 1972; Ross, 1972). Although it may appear that a homograft aorta with its valve used in the pulmonary position may last longer, as it is subjected to lower pressures, the observation of better survival of pulmonary grafts over aortic grafts has been reported in experimental conditions (Eguchi and Asano, 1968; Pierce, Thompson, Kazama and Waldhausen, 1971).

The management of the outflow tract in severe Fallot's tetralogy is a subject for debate (Trusler, Iyengar, and Mustard, 1973). We feel that the emphasis in the past on relief of obstruction may be succeeded by a greater

appreciation of the need for providing a reasonably competent pulmonary valve. Although isolated pulmonary regurgitation may be benign, it may not be well tolerated where there is an increase in pulmonary vascular resistance. Although we continue to manage the outflow tract of Fallot's tetralogy by patching where necessary, the severer forms of outflow tract hypoplasia appear to have been more satisfactorily dealt with by the use of a homograft aortic conduit with its valve. Good long-term function to date and ease of insertion of the conduits have encouraged us in their use in this situation.

TABLE I

SEVERE FALLOT'S TETRALOGY/PULMONARY ATRESIA.
Age at operation and relation to hospital death

Age (yr)	No. of Patients	Hospital Deaths
Under 2	1	1
2 - 4	3	2
5 - 12	24	9
Over 12	20	9

TABLE II

SEVERE FALLOT'S TETRALOGY/PULMONARY ATRESIA.
Previous systemic-pulmonary anastomoses

	No. of Patients	Hospital Deaths
Waterston	17	8
Blalock	12	4
Potts	3	0
Waterston+Blalock	4	2
Waterston+Blalock+Potts	1	1
	37	15
No previous shunt	11	6

TABLE III

SEVERE FALLOT'S TETRALOGY/PULMONARY ATRESIA:

Other procedures required at time of surgery

	No. of Patients	Deaths
Multiple ventricular septal defect closure	1	1
Closure of atrial septal defect	4	3
Closure of patent ductus arteriosus	5	3
Aortic valve replacement	1	1
Correction of hemi-truncus	1	0
Division of collaterals via thoracotomy	2	2

TABLE IV

SEVERE FALLOT'S TETRALOGY/PULMONARY ATRESIA:

Major factors in death

	No. of Patients
Unresolved right ventricular hypertension	10
Coronary arterial damage	2
Infection (endocarditis 1; septicaemia 2)	3
Obstruction of conduit by sternum	1
Bleeding	3
Emergency operation - critically ill patient	2

TABLE V

SEVERE FALLOT'S TETRALOGY/PULMONARY ATRESIA:
Right/left ventricular pressure after correction

	No. of Patients	Deaths
Less than 70%	27	6
More than 70%	11	10

TABLE VI

SEVERE FALLOT'S TETRALOGY/PULMONARY ATRESIA:
Duration of homograft conduit function

Duration (yr)	No. of Patients
8	2
7	1
6	3
5	1
4	3
3	5
2	8
1	3

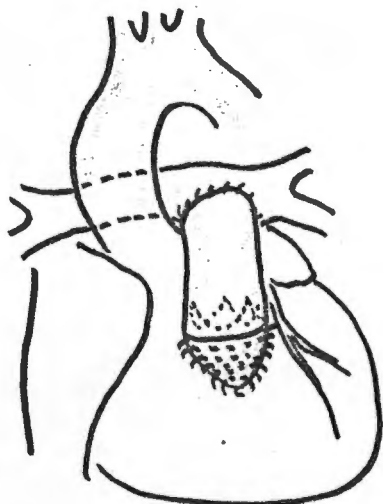


Figure 3d - 1 Reconstruction of right ventricular outflow - homograft conduit in place.

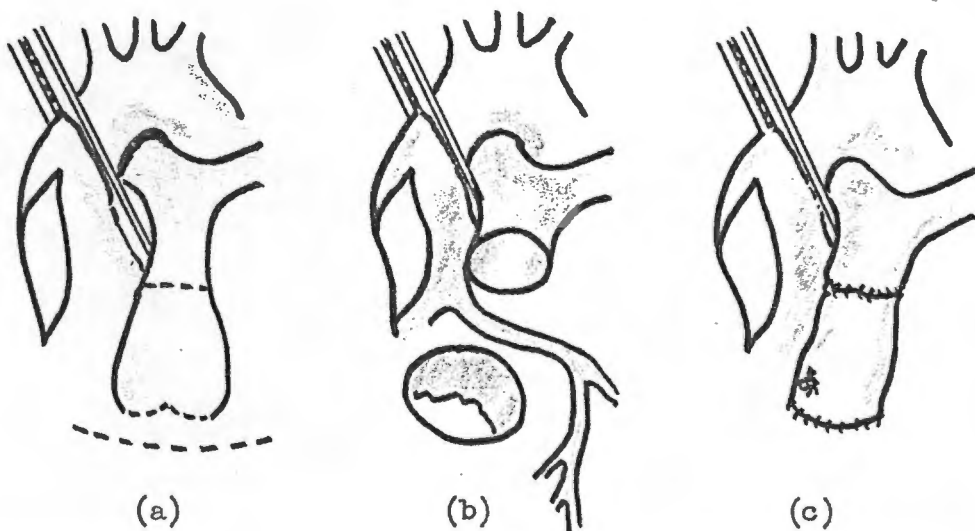
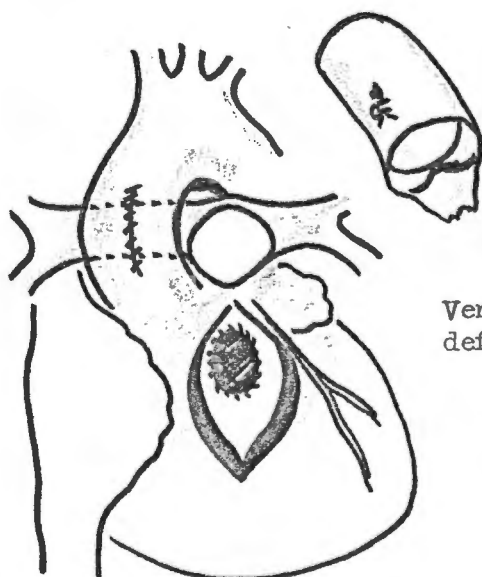


Figure 3d - 2 (a, b) Pulmonary valve excised for use in aortic position; (c) Right ventricular outflow reconstituted with homograft.



Ventricular septal defect closed -
Homograft conduit ready for insertion

Figure 3d - 3 Right ventricular outflow reconstruction in pulmonary atresia.

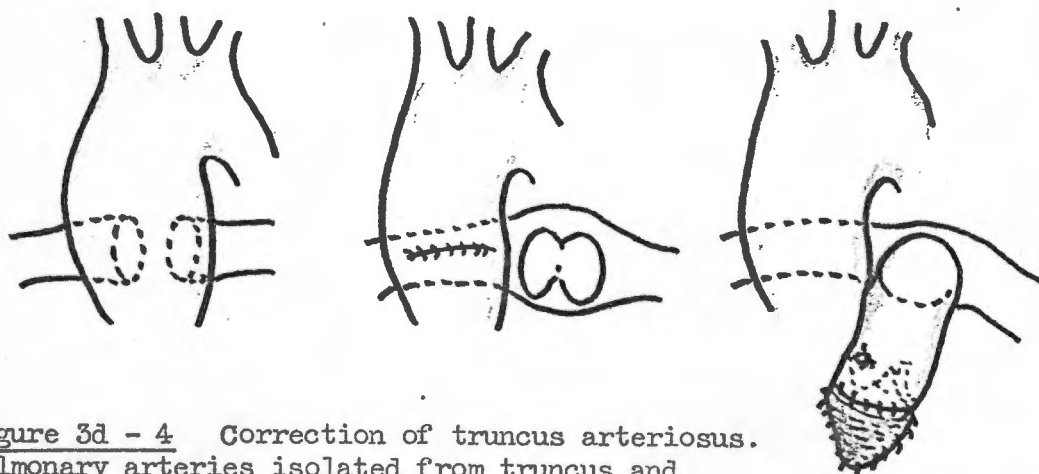


Figure 3d - 4 Correction of truncus arteriosus. Pulmonary arteries isolated from truncus and joined to right ventricle by homograft.

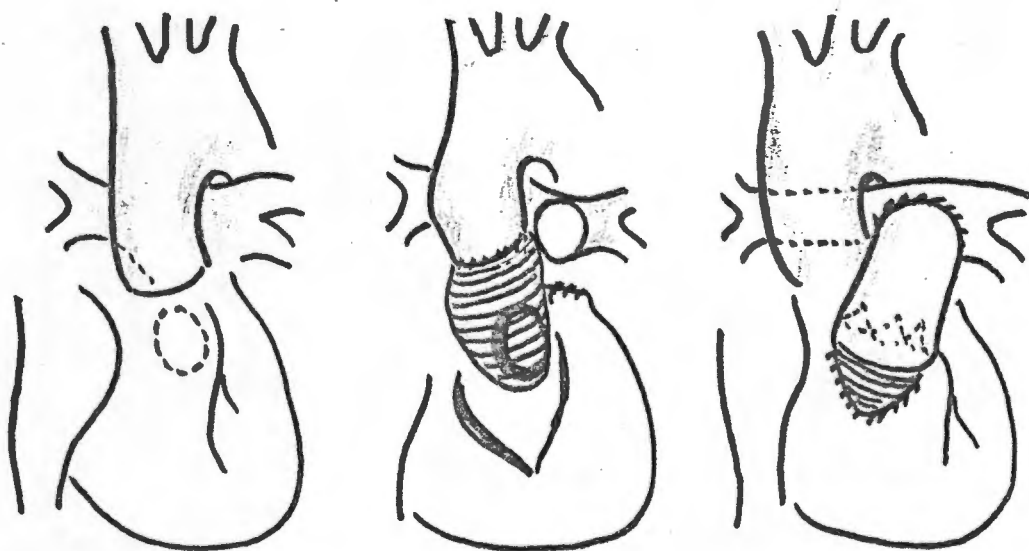


Figure 3d - 5 Correction of transposition of great arteries. Patch directs blood via ventricular septal defect to aorta.

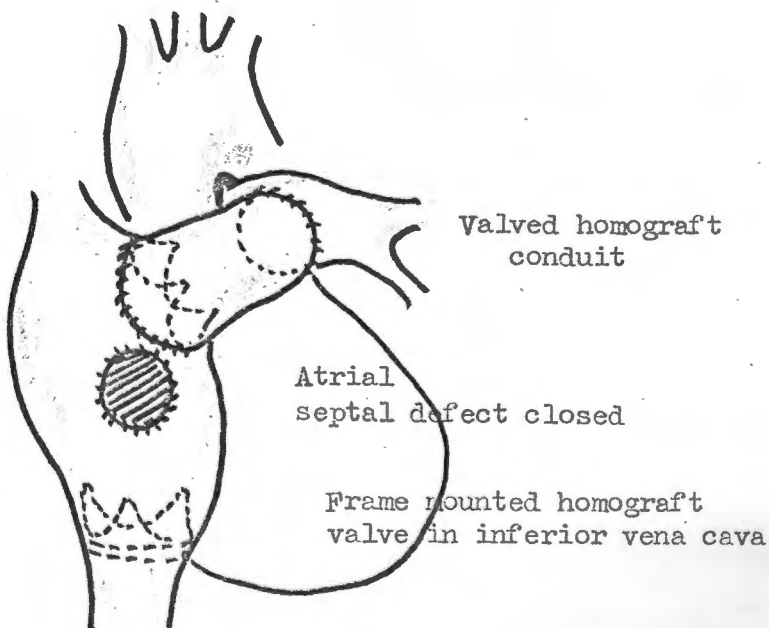


Figure 3d - 6

Reconstruction for tricuspid atresia or common ventricle

SECTION 4

AIMS OF INVESTIGATION

The aims of the investigation were as follows:-

- 1) To determine the effect of antibiotic sterilisation and storage on heart valve fibroblast viability.
- 2) To determine whether fibroblast viability is maintained following isotopic allotransplantation of a viable valve.
- 3) To determine whether, in antibiotic sterilised valves, the state of fibroblast viability can be shown to influence valve structure and function following isotopic allotransplantation.

Definition of Terms for Purposes of this Investigation:

Antibiotic sterilisation and storage.

This refers to the exposure of a heart valve intended for transplantation (i.e. valve leaflets with cuff of adjacent vessel and myocardium) to a mixture of antibiotics in a cell nutrient medium, and their storage at 4°C for up to 8 weeks in the same mixture. The particular mixture used in this investigation is that in clinical use at the National Heart Hospital, London, and recommended by Waterworth et al. (1974). Details of this mixture are given in Figure 5a-1.

Heart valve.

Heart valve refers to an aortic or pulmonary valve, which consists of three leaflets, together with the valve annulus and adjacent cuff of myocardium and vessel wall.

Fibroblast viability.

All investigations of viability have been made on the leaflets of the valve, since it is the fate of the leaflets which is important, and since previous workers have similarly investigated leaflet viability (Reichenbach et al. 1971; Gavin et al. 1973c; Mohri et al. 1967a, 1967b, 1968; Buch et al. 1971; Kosek et al. 1969). The definition of viability is difficult as the various cellular functions by which cells or tissues are recognised as being living or 'viable' are impaired or lost at varying rates following cell injury or deprivation of oxygen or nutrients.

It has therefore been necessary to define viability in terms of particular parameters of cellular function, and a large number of methods have been described for the assessment of cell or tissue viability (Malinin and Perry, 1967).

The most commonly used method of assessing heart valve leaflet viability has been the demonstration of growth of connective tissue cells (fibroblasts) from the leaflet tissue in tissue culture (Angell et al. 1973b; Reichenbach et al. 1971; Mohre et al. 1967a; Buch et al. 1971). Tissue culture of valve leaflets is relatively simple and unequivocal, and its wide use by previous workers makes this method an essential choice for one method of defining viability.

In an attempt to define viability in more quantitative terms the autoradiographic demonstration of tritiated thymidine incorporation into nuclear desoxyribonucleic acid has been described by Al-Janabi et al. (1972). This same group (Al-Janabi et al. 1973) subsequently described assessment of protein synthesis by heart valves by measuring uptake of isotopically-labelled proline. This method appeared to offer a particularly relevant assessment for this study in view of the postulated continued protein and collagen synthesis by implanted allograft valves (Angell et al. 1973a; Lockey et al. 1972). Measurement of protein and collagen synthesis by measuring uptake of tritiated proline was therefore used as a further parameter of viability.

Thus, for this investigation, viability of the cells of the heart valve leaflets (fibrocytes - or fibroblasts, as they are known when young, active, or growing in tissue culture) has been defined in two ways:

- 1) Ability to grow in tissue culture, and
- 2) Ability to synthesise protein and collagen.

As will be shown in Section 5a, canine valves obtained from healthy animals within $\frac{1}{2}$ hour of death can be shown to be viable in terms of being 1) able to show fibroblast growth in tissue culture, and 2) able to synthesise protein and collagen.

After one week of storage in Antibiotic-Nutrient Solution these valves show no impairment of viability using these criteria.

However, with increasing storage time the ability to synthesise protein and collagen is lost but ability to show fibroblast growth in tissue culture is retained for longer.

After 4 weeks of storage in Antibiotic-Nutrient Solution viability could not be demonstrated using these criteria.

A further parameter of leaflet viability which has been applied in assessing viability is the presence or absence of cells in histological sections. Clearly, if cells are totally absent the particular piece of tissue seen is not viable - this has been used as a criterion for non-viability by many workers (Duran and Whitehead, 1966; Duran et al., 1965; Mohri et al., 1968; Angell et al., 1973a; Gavin et al., 1973a).

With the evidence concerning the state of viability of canine valves removed within $\frac{1}{2}$ hour of death and stored in Antibiotic-Nutrient Solution presented in Section 5a, it would appear satisfactory to assume viability in such valves if stored for less than one week; and non-viability if stored in excess of 4 weeks. In the animal study described in Section 6 these assumptions were confirmed by assessing tissue culture growth of control valves in each case.

Isotopic allotransplantation.

Allotransplantation is taken to mean the removal of tissue from one individual and its insertion into another individual of the same species (e.g. human to human, or dog to dog). The term homotransplantation or homografting is synonymous. An allograft or homograft, is thus transplanted tissue from the same species.

An isotopic graft is a graft to the same site within the recipient as the tissue occupied in the donor - e.g. aortic valve of donor grafted to aortic valve position in recipient.

Precise definition is required in view of the known difference in the fate of heart valves transplanted into differing sites in the recipient animal (e.g. subcutaneously implanted leaflets evoke an inflammatory response and disappear, but subcoronary implanted leaflets do not - Mohri et al., 1967).

Valve structure and function:

Retraction, thickening, distorsion or rupture of leaflets have been noted in valves failing clinically (Gavin et al. 1973a; Hudson, 1966). It has been suggested that proliferating fibroblasts thicken the implanted leaflets, increasing integrity with little alteration in function (Angell et al. 1973a). Thus in this investigation valve structure and function will be assessed by noting changes in leaflet dimensions and the ability of the valve to function as a competent, non-obstructive valve.

SECTION 5

In Vitro Study of Heart Valve
Leaflet Viability

5a TISSUE CULTURE, PROTEIN AND COLLAGEN SYNTHESIS IN
 ANTIBIOTIC STERILISED CANINE HEART VALVES

McGregor, C.G. A., Bradley, J.F., McGee, J.O.D., and Wheatley, D. J.

from

Departments of Pathology, Victoria and
Royal Infirmaryes, Glasgow

SUMMARY

Viability of canine heart valve leaflet fibroblasts was assessed after varying periods of sterilisation and storage in antibiotic-nutrient solution. Tissue culture and assessment of protein and collagen synthesis showed that tissue obtained under optimal conditions rarely retains viability beyond 3 weeks in antibiotic-nutrient solution and is severely impaired after two weeks.

Fibroblast viability in heart valves prepared by antibiotic sterilisation for grafting has been considered an important factor in ensuring long-term integrity of the implanted valve (Angell et al., 1973a; Lockey et al., 1972).

Many methods have been employed to assess fibroblast viability, including tissue culture (Angell et al., 1973b), autoradiography (Al-Janabi et al., 1972), protein synthetic activity (Al-Janabi et al., 1973), electron microscopy (Gavin et al., 1973) and selectivity in uptake or exclusion of dyes by fibroblasts (Chalcroft et al., 1974).

Tissue culture has been widely used to assess viability as it is unequivocal and relatively simple but it lacks quantitation in that the proportion of viable cells in a piece of tissue is not determined. Ultrastructural changes in antibiotic sterilised canine valve leaflets have been shown not to be uniformly distributed (Gavin et al., 1973) indicating the need for a quantitative method for viability assessment. A technique of measuring ¹⁴C-proline uptake, as described in a preliminary report by Al-Janabi et al. (1973) gives a quantitative assessment of fibroblast viability.

For valid experimental studies adequate quantities of fresh healthy tissue are required. Practical difficulties in obtaining such tissue from human sources has necessitated the use of animal tissue. Canine tissue has been almost extensively investigated by previous workers in this field (Angell et al., 1973a; Hammon et al., 1974; Duran et al., 1965; Gavin et al., 1973; Reichebach et al., 1971).

This section reports a study of the effects of antibiotic sterilisation and storage on the viability of canine valve leaflet fibroblasts using a combination of tissue culture and assessment of protein and collagen synthetic activity. Many antibiotic combinations have been used for sterilisation of heart valves in clinical practice; we have used the antibiotic formula recommended by Waterworth *et al.* (1974) in Nutrient medium as used in clinical homograft preparation (Al-Janabi, 1974)

Figure 5a-1.

COMPOSITION OF ANTIBIOTIC-NUTRIENT SOLUTION 500 ml	
(Waterworth <i>et al</i> 1974; Al-Janabi 1974)	
Antibiotics in Sterile Water	Nutrient Medium Composition
Benzylpenicillin 500 mg in 2.5 ml water	Sterile water 340 ml
Gentamycin sulphate 500 mg in 2.5 ml water	TC 199 (10x conc) * 44 ml
Polymixin B Sulphate 5 mg in 1 ml water	Calf Serum No 1 * 35 ml
Nystatin 1, 250, 000 units in 50 ml water	4.4% Sodium bicarbonate 25 ml
56 ml	444 ml

* Wellcome Reagents Limited, Beckenham, Kent.

Figure 5a - 1

MATERIALS AND METHODS

Source of Tissue:

Aortic and pulmonary valves were removed within $\frac{1}{2}$ hour of death from healthy dogs being destroyed at a Local Authority Home. Those for immediate assessment were removed under sterile conditions; the remainder were placed in freshly mixed Antibiotic Nutrient Solution (Figure 5a-1) and placed in storage at 4°C within 3 hours of procurement. The aortic and pulmonary valves from each animal were stored together, with adjacent cuffs of vessel and myocardium in 100 ml of Antibiotic Nutrient Solution as described for clinical homograft valve storage (Lockey et al., 1972) for up to 8 weeks.

Tissue Culture:

A primary explant technique was used. After excision of the leaflets from the stored tissue each leaflet was thoroughly washed sequentially in three 10 ml volumes of TC199* to remove excess antibiotics. Leaflet tissue was minced with scissors and placed between plastic coverslips (Thermanox^R)** lying in a Petri dish to which nutrient medium (TC199* with 30% foetal bovine serum with added glutamine 2 mM) was added. The tissue was incubated at 37°C in a moist atmosphere of 95% air and 5% carbon dioxide. Assessment and feeding were done at 48 hour intervals. Growth was arbitrarily defined using a scale of + to +++ as shown in Figure 5a-2. Cultures were kept for 4 weeks.

Protein and Collagen Synthesis:

The ability of each valve to synthesise protein and collagen was assessed as a means of testing tissue viability. Each valve was divided into two aliquots and chopped finely with scissors.

* from Wellcome Reagents Limited, Beckenham, Kent.

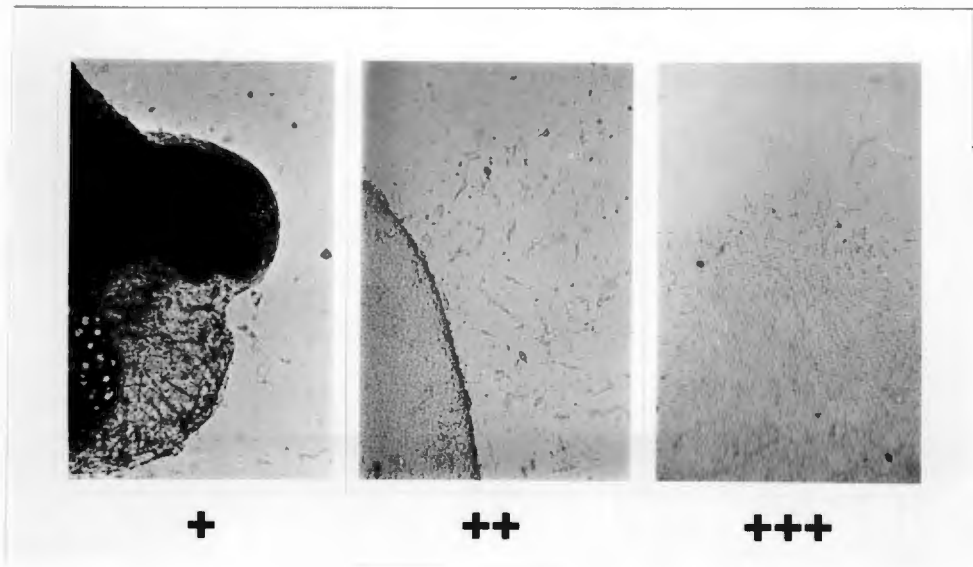
** from Lux Scientific Corporation, California 91360.

One half of each valve was boiled in Minimum Essential Medium (Gibco-Biocult-Scotland) for 15 minutes before incubation with isotope. This served as a control. Both halves of each valve were then incubated in 5 mls of Minimum Essential Medium containing $5\mu\text{Ci}$ of 3,4- ^3H proline at 37°C . for 3 hours in a 95% O_2 and 5% CO_2 atmosphere. After the incubation the tissue was recovered by centrifugation at 2,000 g for 15 minutes. The tissue was then resuspended in 0.05 M Tris, pH 7.6 and homogenised in a Silverson Emulsifier. Protein concentration in the homogenate was measured by the method of Lowry et al. (1951) using bovine serum albumin as a standard.

Protein synthesised by each valve was measured in duplicate by spotting 200 μl of the homogenate into 3 MM Whatman filter paper discs. The discs were then processed through 10% and 5% trichloroacetic acid, ethanol ether (3:1 V/v) and dried in ether; each wash lasted 30 minutes. The radioactivity in each disc was then measured in a liquid scintillation counter using Bray's solution as fluor cocktail.

The amount of collagen synthesised by each valve was measured as follows. Trichloroacetic acid was added to the homogenate to a final concentration of 10%. The precipitated protein was recovered by centrifugation and the collagen extracted from the pellet with 2 ml 5% trichloroacetic acid at 90°C for 30 minutes. The supernatant was removed by centrifugation and dialysed overnight against tap water. The total amount of newly synthesised collagen present in the dialysed supernatant was measured by the method of Peterkofsky and Diegelmann (1971). The amount of protein and collagen synthesised by each valve is expressed as cpm/mg of tissue protein or dpm/mg tissue protein used in each incubation.

Figure
5a - 2



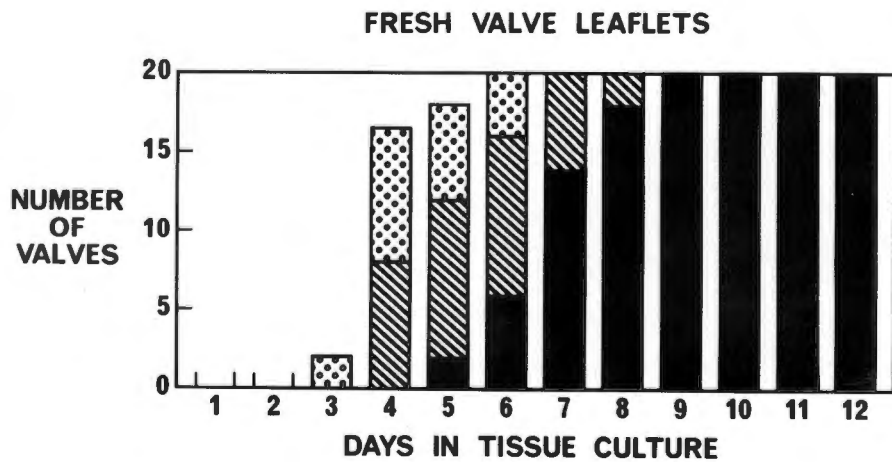
Arbitrary scale for grading tissue culture growth

- + Early cellular outgrowth from explant
- ++ Outgrowth established from entire edge of explant
- +++ Confluent sheet of cells

+ GROWTH
 ++ GROWTH
 +++ GROWTH

Key to Figures 5a - 3 to 5a - 7

Figure
5a - 3



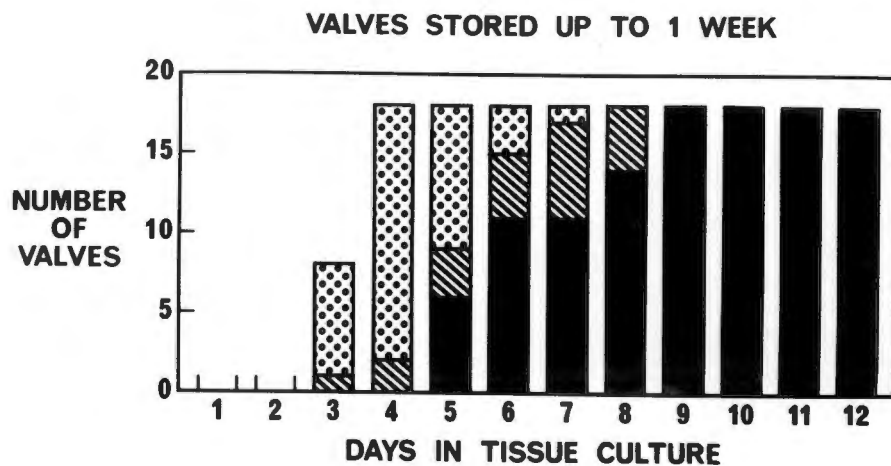


Figure 5a - 4

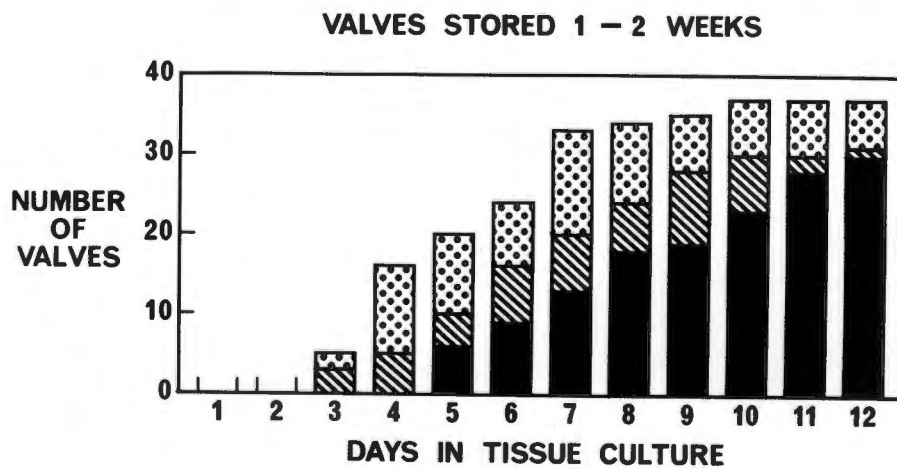


Figure 5a - 5

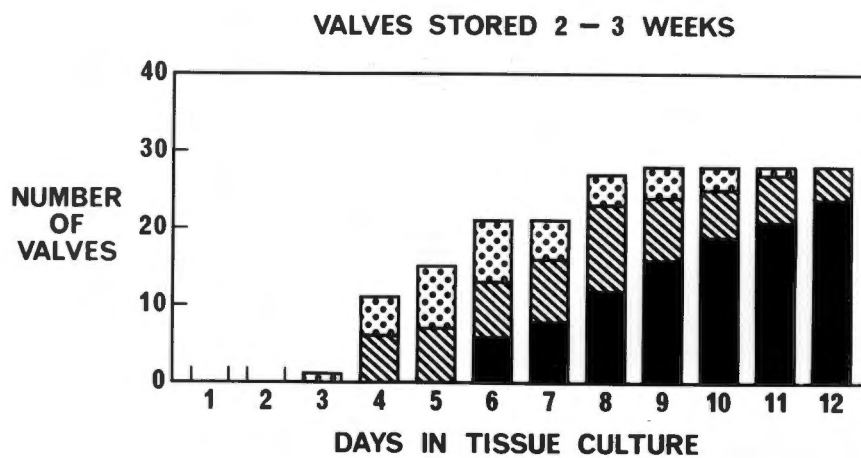


Figure 5a - 6

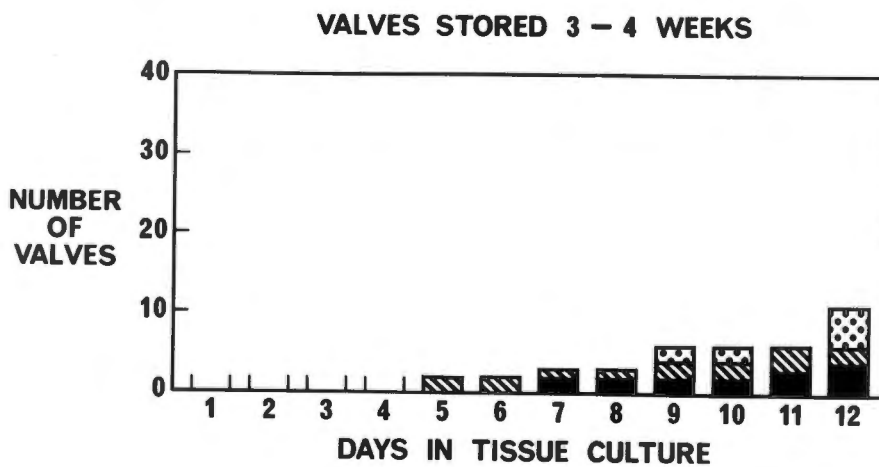


Figure 5a - 7

RESULTS

Tissue Culture

Fresh Valves:

Ten fresh aortic and ten fresh pulmonary leaflets were assessed for growth in tissue culture. All specimens showed growth. Earliest fibroblast outgrowth (+ growth) was evident at 3 or 4 days and a confluent sheet of fibroblasts (+++ growth) was established in all by 9 days (Figure 5a-3). Aortic and pulmonary leaflets behaved identically.

Stored Valves:

18 out of 20 valves (9 aortic and 9 pulmonary) stored for up to one week showed growth comparable to fresh valves (Figure 5a-4).

37 of 40 valves (18 aortic and 19 pulmonary) stored for one to two weeks showed growth which proceeded more slowly (Figure 5a-5).

28 of 40 valves (14 aortic and 14 pulmonary) stored for two to three weeks showed growth which was still further delayed (Figure 5a-6).

11 of 40 valves (5 aortic and 6 pulmonary) stored for three to four weeks showed growth which was markedly delayed (Figure 5a-7), and in fact the pulmonary and aortic valves of only one animal could be grown after 26 days of storage.

No new growth occurred later than twelve days in tissue culture.

None of the 40 valves stored for more than four weeks showed growth in tissue culture.

Protein and Collagen Synthesis

The ability of each stored valve to synthesise protein and collagen was used as an index of tissue viability. Three aortic

and three pulmonary valves were removed from storage at intervals from 1 - 8 weeks and checked in this way. Four freshly removed aortic and four pulmonary valves were similarly assessed. As shown in Figures 5a-8 and 5a-9 valves stored for 1 weeks are capable of protein and collagen synthesis, but this synthetic activity declines rapidly thereafter such that they are incapable of protein and collagen synthesis after 3 weeks.

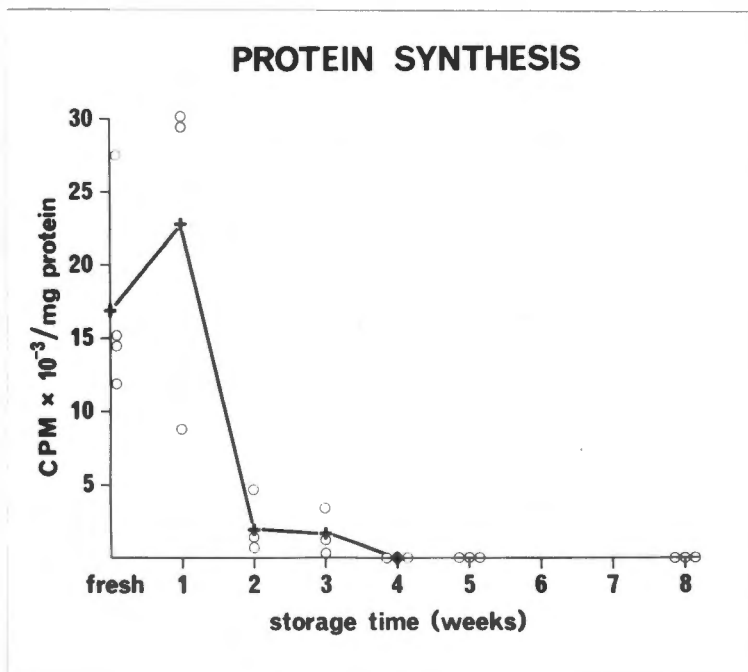


Figure
5a - 8

Graphs drawn through mean values

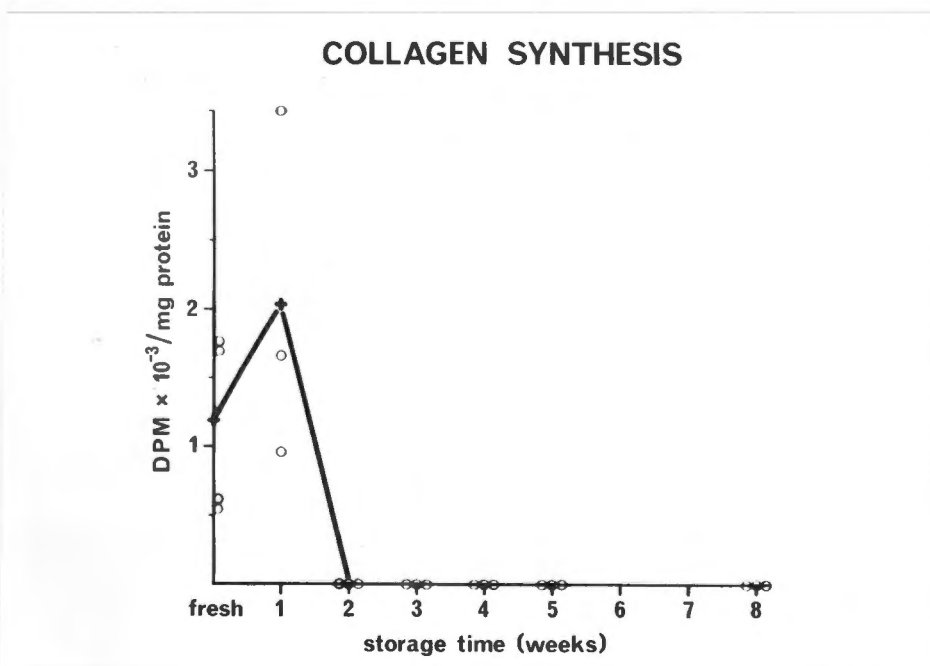


Figure
5a - 9

DISCUSSION

Canine valves assessed in this study were obtained under optimal conditions for maintenance of viability. Tissue culture growth, and protein and collagen synthetic activity, could be readily demonstrated in all such fresh tissue examined. After storage for up to one week in Antibiotic Nutrient Medium, no obvious impairment of viability was noted using the assessments described. However, the adverse effects of storage in Antibiotic Nutrient Medium became evident with storage times of more than 1 week.

After storage for between 1 and 2 weeks tissue culture growth was delayed, and after storage for between 2 and 3 weeks, there was failure of growth in 30% of specimens, and delayed growth in the remainder. After storage for between 3 and 4 weeks only 28% of specimens showed growth and this growth was delayed. None of the valves stored for more than 4 weeks in Antibiotic Nutrient Medium showed tissue culture evidence of viability.

Protein and collagen synthesis was not impaired after 1 week of storage in Antibiotic Nutrient Medium but after 2 weeks protein synthesis was considerably reduced and collagen synthesis was not detectable. After more than 3 weeks of such storage virtually no protein synthesis was demonstrable.

These findings are similar to those of Reichenbach et al. (1971) who found that canine aortic valves would not show growth in tissue culture after storage in Waymouth medium for more than 14 days at 4°C, although it is interesting that when stored at 37°C in Waymouth medium tissue culture growth could be demonstrated after 5 weeks of storage. These workers did not use antibiotics in the storage media, and it would therefore appear that the antibiotics in this study did not severely impair viability.

The work of Gavin et al. (1973c) who found significant cellular damage on electromicroscopy after only one week in Hanks' solution, and more severe damage in cells exposed to antibiotics, also supports the findings of this study.

Thus, in canine valves obtained under optimal conditions, viability can only be retained with any degree of reliability for up to 2 weeks of storage in Antibiotic Nutrient Medium. After this period viability is considerably impaired and is virtually absent after 3 weeks.

Such conditions are impossible to achieve in routine human autopsy material. This must therefore cast considerable doubt on the concept of valve viability in clinical heart valve transplantation where storage periods of up to eight weeks are described for antibiotic sterilised valves (Al-Janabi, 1975b).

5b VIABILITY IN HUMAN HEART VALVES PREPARED FOR GRAFTING

McGregor, C.G.A., Bradley, J.F., McGee, J.O.D. and Wheatley, D. J.

from

Departments of Pathology,
Victoria and Royal Infirmarys, Glasgow

SUMMARY

Viability of antibiotic sterilised and stored human heart valves obtained at routine autopsy was assessed by tissue culture, and protein and collagen synthesis.

Only 3 of 23 examined showed any evidence of viability, in striking contrast to the earlier work (Section 5a) on canine valves obtained under optimal conditions. These findings justify doubts regarding pre-implantation viability in human heart valves prepared for grafting.

Transplantation of allograft heart valves is an accepted method for replacement of diseased valves (Angell et al., 1973a; Ross, 1972; Barratt-Boyes and Roche, 1969) and for reconstruction in certain congenital cardiac defects (Wheatley et al., 1974).

Structural changes have occurred in transplanted allograft valves leading to late valve dysfunction detracting from otherwise excellent clinical results from a number of centres (Wallace et al., 1974; Missen and Roberts, 1970; Karp et al., 1974; Aparicio et al., 1975). These changes have been ascribed to earlier methods used for valve sterilisation and storage, such as exposure to betapropio-lactone, ethylene oxide or gamma irradiation with subsequent freezing (Smith, 1967; Hudson, 1966).

Initial good results with fresh valves prompted the suggestion that viable donor fibroblasts may be an important factor in long-term structural integrity (Mohri et al., 1968; Kosek et al., 1969; Buch et al., 1971) and that these viable fibroblasts may continue to synthesise collagen and remould and repair the implanted allograft valve (Lockey et al., 1972; Al-Janabi et al., 1972; Angell et al., 1973b; Hammon et al., 1974).

Procurement of fresh human tissue is clearly impractical and of uncertain sterility (Yacoub and Kittle, 1970). Use, therefore, has to be made of routine autopsy material which is inevitably heavily contaminated and in which cellular degeneration has had time to occur. Many formulae of antibiotic combinations have been suggested to achieve sterility while retaining fibroblast viability (Angell et al., 1973b). Waterworth et al. (1974) have assessed the efficacy of sterilisation with different antibiotic formulae and recommended a mixture of Penicillin, Gentamycin, Polymixin B sulphate and Nystatin, with nutrient medium added in an attempt to retain viability (Lockey et al., 1972) (Figure 5a-1)

In the study of viability in antibiotic sterilised and stored canine heart valves (Section 5a) using tissue culture, protein and collagen synthesis, it was found that viability was considerably impaired after 2 weeks of storage. That study showed failure of tissue culture growth in 30% of 40 specimens stored between 2 and 3 weeks and failure in 72% of 40 specimens stored between 3 and 4 weeks. Similarly protein and collagen synthetic activity declined rapidly after 1 week of storage; collagen synthesis in fact being undetectable after 2 weeks. The antibiotic nutrient formula used was that recommended for clinical use by Waterworth et al. (1974). The canine valves studied were obtained under optimal conditions for the maintenance of viability and sterility, in that they were removed immediately after death. These conditions cannot be obtained in the autopsy room and this raised serious doubts about the viability of human valves collected for clinical use.

This section, therefore, reports a study of viability in human valve tissue removed at autopsy for potential valve replacement. Clinical criteria were applied in the selection of valves and viability was assessed by means of tissue culture and quantitative assessment of protein and collagen synthesis. The methods used in this study are identical to those in the canine study and shown to be reproducible.

MATERIALS AND METHODS

Human aortic valves were removed at routine autopsy subject to the following criteria: patients were under 55 years of age, without intrinsic valvular heart disease, and death-to-autopsy period was less than 48 hours. Details are shown in Figure 5b-1. The valves were placed immediately in antibiotic nutrient solution (Figure 5a-1) and stored at 4°C. Six valves were assessed within 24 hours; seventeen valves were assessed at periods of 1 to 8 weeks as shown in Figure 5b-1.

A primary explant technique for tissue culture was used as described for the canine valve study (Section 5a).

Protein and collagen synthesis was assessed using tritiated proline uptake as described in the canine study (Section 5a). The proline uptake and tissue culture studies were performed in separate laboratories and each group's results were unknown to the other.

HUMAN VALVES IN ANTIBIOTIC NUTRIENT MEDIUM

Time of Assessment	Donor's age (years).	Death-to-Autopsy time (hours)
Within 24 hours (6 valves)	19 years	40 hours
	22	42
	45 *	9
	24	29
	55	10
	42	24
After 1 week	47	30
	41 *	12
	42	18
	55	8
After 2 weeks	28 *	6
	49	23
	54	24
After 3 weeks	51	14
	30	17
	51	18
	42	42
After 5 weeks	45	24
	51	5
	7	40
After 8 weeks	48	20
	35	27
	53	24

* Growth in tissue culture demonstrable.

RESULTS

Tissue Culture:

Of the entire group of 23 valves only 3 showed growth in tissue culture - these being a 45 year old patient with 9 hour autopsy delay and 24 hour antibiotic exposure; a 41 year old with 12 hours autopsy delay and 1 week of antibiotic exposure; and a 28 year old with 6 hour autopsy delay and 2 weeks of antibiotic exposure (Figure 5b-1).

Protein and Collagen Synthesis:

Protein and collagen synthesis was undetectable in all except the valve of the 28 year old with 6 hour autopsy delay and 2 weeks of antibiotic exposure, which showed protein synthesis at a level of 1,000 cpm/mg tissue protein and no detectable collagen synthetic activity.

DISCUSSION

This study has shown that for practical purposes human heart valves obtained at routine autopsy for clinical transplantation are rarely viable. In fact, only 3 of the 23 assessed grew in tissue culture and protein synthetic activity at a low level could be demonstrated in only one.

This may not be surprising considering the inevitable post-mortem cellular degeneration and infection which must affect the valve fibroblasts. Interestingly, the valve which did show tissue culture growth and protein synthesis was removed from a young patient only 6 hours after death.

Our findings conflict with those of Al-Janabi et al. (1972) who report fibroblast growth by tissue culture in 70% of valves obtained within 48 hours of death and stored up to 4 weeks. The disparity may be explained by our stricter criteria for tissue culture growth. Also Al-Janabi et al. (1973) report protein synthetic activity in a small number of valve leaflets after antibiotic storage. However, it must be pointed out that the levels of activity reported were extremely low even after only 24 hours' storage when compared with the values reported by our group for fresh and 1-week stored canine tissue (Section 5a). Furthermore, the methodology described may not adequately have removed free ^{14}C -Proline from the estimations.

The findings reported in this paper are supported by those of Gavin et al. (1973c) who found significant cellular damage on electromicroscopy after only one week in Hanks' solution and more severe damage in cells exposed to antibiotics.

The doubts raised by this study regarding pre-implantation viability in clinical allograft valve practice must clearly also apply to the speculations regarding post implantation fibroblast activity.

SECTION 6

IN VIVO STUDY OF POST-IMPLANTATION VIABILITY
OF HEART VALVE LEAFLETS

The aims of this study were:

TO DETERMINE WHETHER FIBROBLAST VIABILITY IS MAINTAINED
FOLLOWING ISOTOPIC ALLOTRANSPLANTATION OF A VIABLE VALVE.

and

TO DETERMINE WHETHER, IN ANTIBIOTIC STERILISED VALVES, THE
STATE OF FIBROBLAST VIABILITY CAN BE SHOWN TO INFLUENCE VALVE
STRUCTURE AND FUNCTION FOLLOWING ISOTOPIC ALLOTRANSPLANTATION.

6a DESIGN OF ANIMAL MODELNeed for Animal Model:

Opportunities for examining transplanted antibiotic sterilised heart valves in clinical practice are relatively uncommon. Valve failure with antibiotic sterilised valves is less common than with the earlier chemically sterilised and frozen, or irradiated and frozen valves (Ross, 1975; Gavin et al. 1973; Angell et al. 1973), thus fewer are removed. In the series of 100 valves reported in Section 3c none of the antibiotic sterilised valves had failed, and two recovered at autopsy following non-valve-related death were reported as being grossly normal but were not available for histological examination.

Those valves removed for reasons of valve failure may not be representative of the majority of valves which function normally. Gavin et al. (1973a) were able to report six 'fresh' valves removed up to $8\frac{1}{2}$ years after implantation, and 4 of these were removed because of valve failure. Gavin et al. (1973b) further reported 42 antibiotic sterilised valves removed up to $3\frac{1}{4}$ years after implantation, but 16 of these were removed for valve failure and 22 were recovered at autopsy following hospital death - leaving only 4 recovered from patients dying late from non-valve-related causes. Kosek et al. (1969) reported 11 fresh valves removed from patients who died or required valve replacement. Similarly, of about 400 fresh grafts used at the National Heart Hospital only 11 have been removed - nearly all for valve failure (Al-Janabi, 1975a).

A further problem with reported clinical series is that the state of viability of the antibiotic sterilised valves is usually not stated or not assessed, although it has frequently been assumed that the valves are viable (Gavin et al. 1973a; Kosek et al. 1969).

The report by Al-Janabi et al. (1972) of pre-implantation viability has been questioned by Gavin et al. (1973) and is in conflict with the findings described in Section 5b. Thus, it is impossible to be certain of pre-implantation viability in the small number of reported fresh or antibiotic sterilised valves that have been removed.

It is therefore necessary to make use of an animal model as this allows the use of donor tissue of optimal viability as well as removal for study at any time of normally functioning implanted valves. An animal model is particularly appropriate to this study, as assumptions regarding post-implantation donor fibroblast survival are based to a large extent on reports of animal work in dogs (Mohri et al. 1967a, 1967b and 1968; Buch et al. 1971; Kosek et al. 1969).

Choice of Animal Species:

Almost all published experimental work on allograft valve transplantation related to dogs (Lam et al. 1952; Beall et al. 1961; Duran et al. 1965; Mohri et al. 1967a, 1967b and 1968; Buch et al. 1971; Hammon et al. 1974).

In addition canine heart valve tissue has been investigated for viability by a number of workers (Reichenbach et al. 1971; Angell et al. 1973b; Gavin et al. 1973c).

The use of the dog for the animal model would therefore allow comparison with a considerable amount of published work, both in the in vitro and in vivo studies.

In addition, the ready availability of dogs, both for obtaining fresh valve tissue and for experimental surgery, makes the dog the clear choice.

The use of the dog also allowed the operative technique of Eguchi and Asano (1968) to be used. This relatively simple technique has not been described in other species.

Isolation of X and Y chromosomes is relatively simple in the dog, and the use of a canine model had the advantage of making this investigation simpler than if another species were chosen.

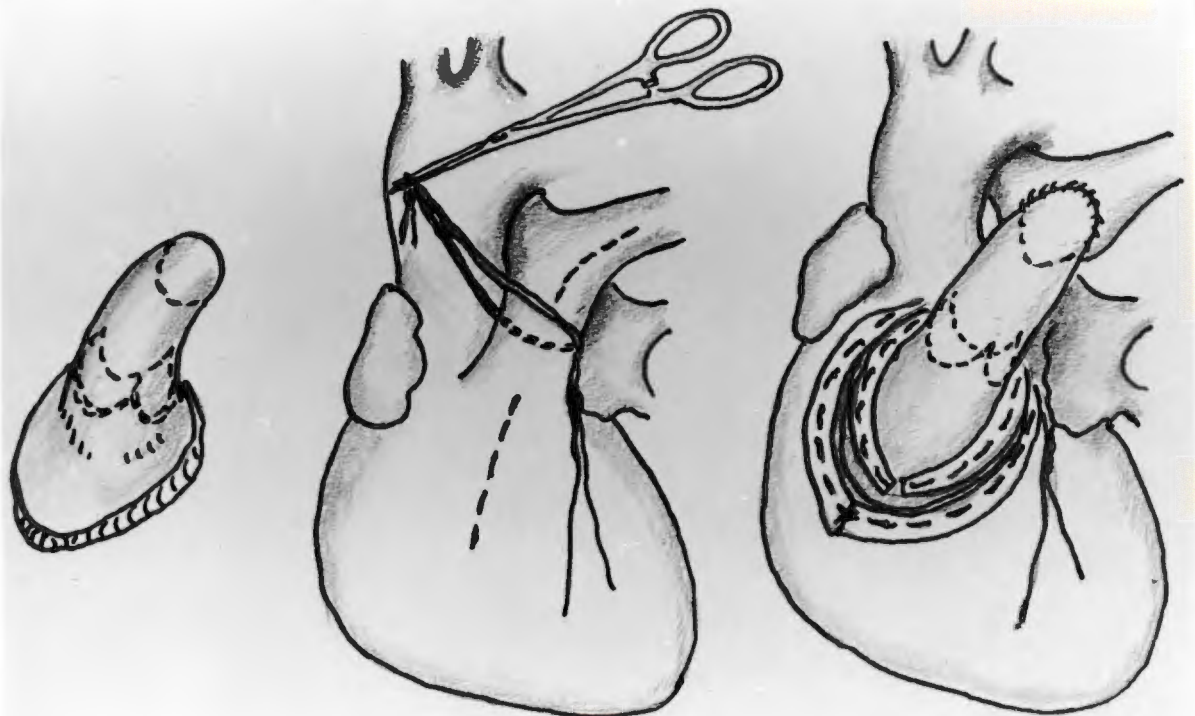
Method of Valve Insertion:

Several studies have demonstrated that the implanted allograft must function in order to maintain its structural integrity. Lam et al. (1952) were the first to speculate that function was important for continued allograft valve integrity as a result of their experience in implantation of such valves in the descending aorta of dogs with or without aortic regurgitation of the host's aortic valve. Murray et al. (1956), Beall et al. (1961) and Duran et al. (1965) used a similar animal model and demonstrated the need for function in the allograft valve, as well as the prohibitive mortality for this form of implantation.

The work of Mohri et al. (1967) provided further evidence of the need for the allograft valve to be placed in a suitable site in the host for continued structural integrity - subcutaneously implanted valves rapidly evoked an inflammatory response and later could not be identified; by contrast, leaflets placed in the aortic annulus retained structure and function.

Buch et al. (1971) used the mitral position for assessing changes in allograft leaflets with a frame-mounted valve. This requires the use of cardiopulmonary bypass or total circulatory arrest with the aid of surface-induced deep hypothermia (Mohri et al. 1966a). Although this did not cause a high mortality for these workers the techniques are complex, and a similar technique in dogs reported by Hammon et al. (1974) carried a 33% mortality. An additional disadvantage of this technique is the inevitable handling necessary for mounting the valve on a frame, and this has led to difficulty in interpretation of subsequent changes (Mohri et al. 1967a).

A simple operation for placing a semilunar valve in the right ventricular outflow tract of a dog was described by Eguchi and Asano (1968). The principle of this technique is illustrated in Figure 6a-1.



OPERATIVE TECHNIQUE

(Eguchi & Asano)

Figure 6a-1

Technique of Insertion of a Valve-bearing Conduit into the Right Ventricular Outflow Tract of the Dog (Eguchi and Asano, 1968)

Both the work of Eguchi and Asano (1968) and the work of Pierce et al. (1971) demonstrated the low mortality of this operation and its relative simplicity.

This method of valve insertion appeared to offer certain advantages for this study, viz:

- 1) As the valve would lie within a conduit of its own annulus, adjacent artery and myocardium, any trauma to the leaflets could be reduced to a minimum during surgical manoeuvres.
- 2) Normal physiological conditions could be anticipated, particularly if the pulmonary valve were inserted, as the conduit would carry the full cardiac output, and the valve would lie without distortion, functioning at the pressures normal for that valve prior to transplantation.
- 3) The use of a valve-bearing conduit would allow considerable physical separation of leaflets from host tissue, minimising subsequent difficulty with interpretation of histological changes due to alterations at the host/graft interface.
- 4) The presence of myocardium in the conduit would ensure that the clinical situation was simulated closely - myocardium is inevitably present in aortic valve grafts, as well as in conduits used to reconstruct the right ventricular outflow (Section 3d). The similarity of the completed operation described by Eguchi and Asano (Figure 6a-1) and the clinical operation illustrated in Figure 3d-1 is striking.
- 5) The relative simplicity of the procedure, lack of need for cardiopulmonary bypass and demonstrated low mortality were further attractive features.

The in vitro study (Section 5a) had shown that aortic and pulmonary valves behave similarly in respect of viability, confirming the report of Al-Janabi et al. (1973). Thus it appeared perfectly

acceptable to implant the pulmonary valve and use the aortic valve from the same donor, handled identically, as a control for pre-implantation viability testing.

One potential problem was anticipated with this operation. The animals used in the studies of Eguchi and Asano (1968) and Pierce et al. (1971) received conduits prepared in formalin or mercurial solution; only two dogs received fresh grafts. It appeared likely that viable antibiotic sterilised conduits would show necrosis and possible disruption of the myocardial portion of the conduit. It was anticipated that sudden exsanguination in some animals would occur, and for this reason short-term implantation was not planned until the number of 'inadvertent' short-term survivors was apparent.

Choice of Implantation Period:

In clinical practice the main concern is with long-term structural integrity and function of the allograft heart valve. However, this has been well shown to be influenced by preparation techniques before implantation (Angell et al. 1973a; Ross, 1975), and it has been postulated that implantation of valves which have living fibroblasts in the leaflets will allow continued repair and restructuring of the implanted valves (Angell et al. 1973a; Al-Janabi, 1975a; Hammon et al. 1974).

Evidence for continued survival of donor fibroblasts within the implanted allograft valve leaflet is conflicting. Mohri et al. (1967a, 1967b and 1968). Buch et al. (1971) and Kosek et al. (1969) have demonstrated survival of donor fibroblasts in such valves for up to 5 years, and furthermore, that donor cells actively synthesise collagen (Angell et al. 1973a). On the other hand, the experimental studies of Duran et al. (1965) and Duran and Whitehead (1966) showed rapid loss of donor leaflet cells. Gavin et al. (1973a and 1973b) reported total loss of leaflet cellularity within as short a time as 40 days in human allograft valves.

Thus it appeared likely that the answer to the problem of whether donor fibroblast viability was retained following implantation could be assessed within a short time of implantation. Indeed, in view of the conflicting opinions regarding leaflet fibroblast origin (Gavin et al. 1973a) it appeared to be advantageous to look at the implanted leaflet within a relatively short period after implantation to reduce the possibility of ingrowth of host fibroblasts which may be a source of confusion in the interpretation of findings.

Initial studies confirmed that by 8 weeks the changes in the implanted leaflets were clear-cut (see Section 6c) and it was therefore decided to use an implantation period of 8 weeks, but also to look at valves early after implantation (the anticipated muscle disruption in some animals occurred at about one week and provided some of the 'short-term' implanted valves), and in two cases an intermediate period of 4 weeks was chosen to illustrate the rate of change in the leaflets.

6b METHODS USED IN ANIMAL STUDYPreparation of Donor Valve:

Healthy foxhounds, between 20 and 24 Kg in weight, were used as donor animals.

These donor dogs were selected from animals used for acute (non-survival) experimental surgery at the Wellcome Surgical Research Institute.

Pulmonary and aortic valves were removed under sterile conditions immediately after sacrifice of the donor animal. The pulmonary valve was removed within a conduit consisting of a cuff of right ventricular outflow tract muscle and the main pulmonary artery, including its bifurcation and the origin of the left and right branches. Such a conduit is shown in Figure 6b-1. This conduit has been everted to demonstrate the pulmonary valve; this was not normally done as every effort was made to avoid handling the leaflets and inflicting injury on them; the valve was viewed within the conduit to confirm its normal appearance.

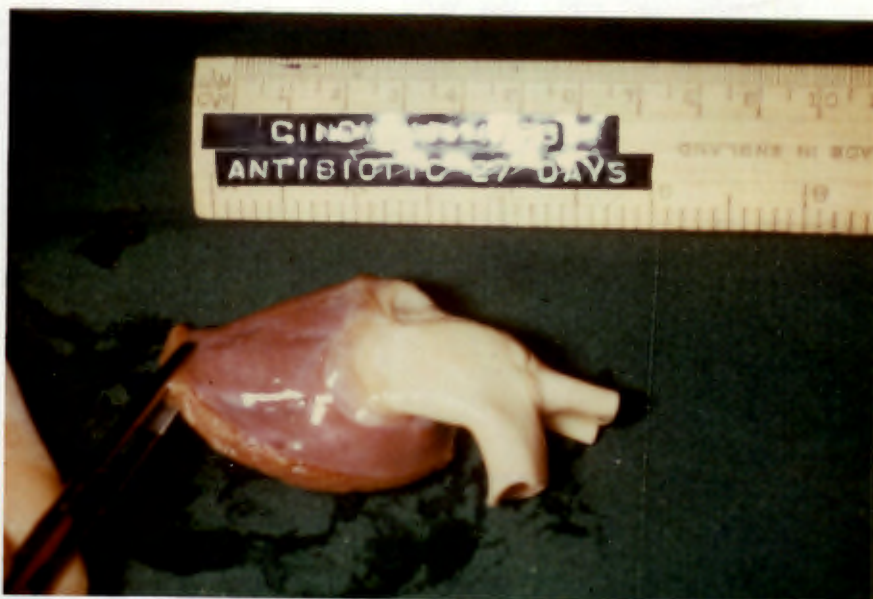

Figure 6b-1

Pulmonary Valve Bearing Conduit (Everted to show valve)

Care was taken during dissection to avoid injury to the pulmonary valve-bearing conduit and as much muscle as possible was trimmed away. This trimming was completed at the stage of valve insertion, leaving less muscle than is shown in Figure 6b-1.

The aortic valve of the same donor animal, together with adjacent myocardium, mitral valve and aorta was also dissected from the donor heart.

The pulmonary valve-bearing conduit and the aortic valve with its adjacent tissue were placed together in a screw-topped glass jar containing 100 ml of freshly mixed Antibiotic-Nutrient Medium (Table 5a-1). This was achieved within $\frac{1}{2}$ hour of death of the donor animal. The donor valve specimens were then placed in a constant temperature refrigerator at 4°C until required for implantation.

When Viable valves were required the storage period in the Antibiotic-Nutrient Medium did not exceed 5 days.

When Non-viable valves were required the storage period in Antibiotic-Nutrient Medium exceeded 4 weeks (in practice ranged from 33 to 41 days).

Assessments at time of allograft valve insertion:

1) Confirmation of state of viability of implanted valve:

The determinant of viability was the length of storage time in Antibiotic-Nutrient medium, as described in Section 6b (Preparation of donor valve). However, for confirmation, the control aortic valve was assessed for tissue culture growth once the operation had been completed. One leaflet of the control valve was washed sequentially in three 10 ml volumes of TC199 to remove excess antibiotics. The tissue was then minced and explants were placed between coverslips for tissue culture as described in Section 5a. In this way it was possible to confirm that the control valve was in fact either viable or non-viable by tissue culture assessment, and by implication, that the identically handled, implanted valve was either viable or non-viable, since the similar behaviour of aortic and pulmonary valves in respect of viability had been shown (Section 5a).

2) Confirmation of histological normality of implanted valve:

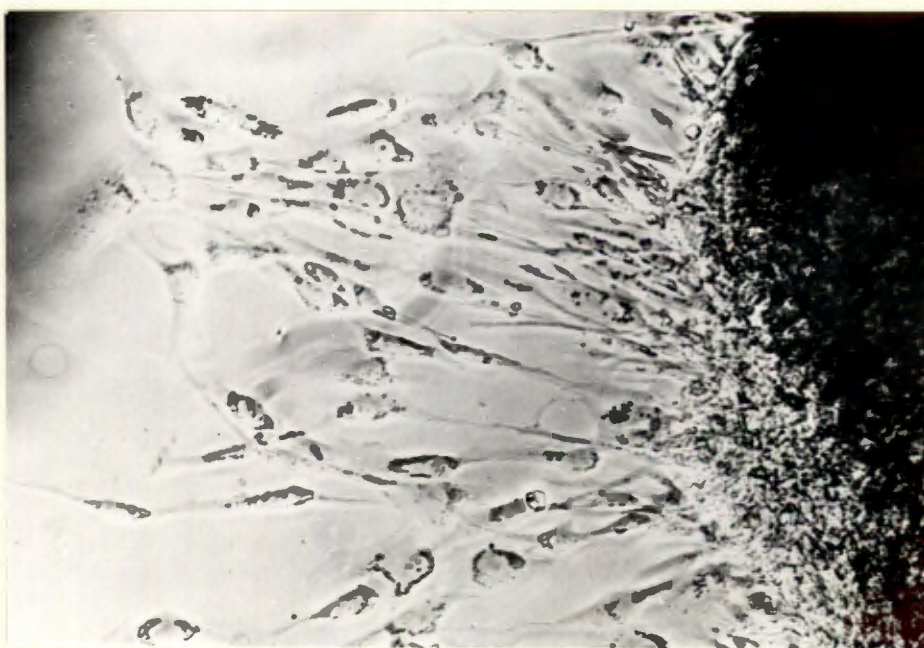
Histological sections, stained with haematoxylin and eosin, were made on the remaining control valve leaflets in the manner described in the later section on "Assessments at time of allograft valve removal." This confirmed the normal appearance of the adjacent myocardium and aortic wall as well as the leaflet tissue.

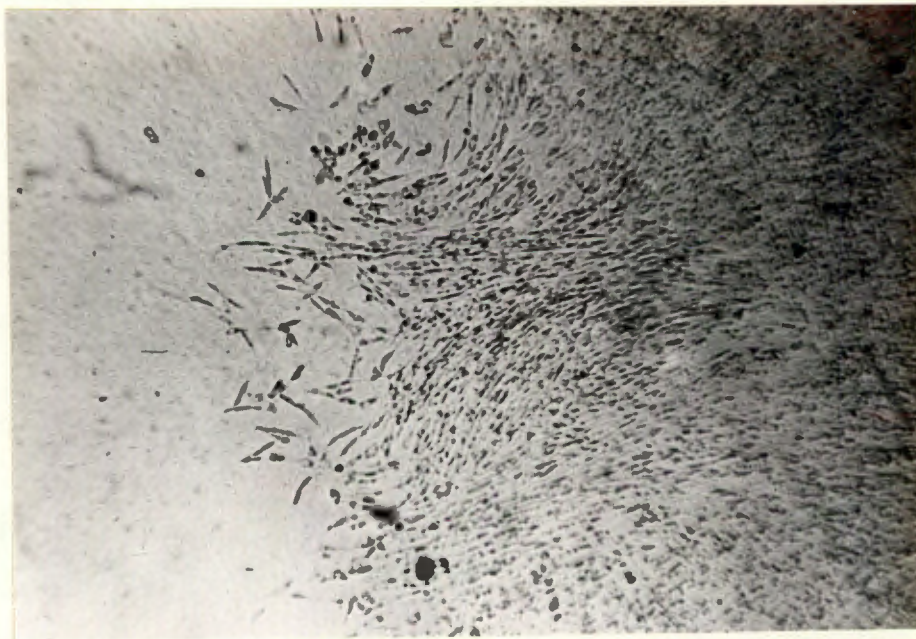3) Confirmation of normal physiological function of implanted valve:

Prior to insertion of the valve-bearing conduit pressure measurements were made proximal and distal to the host dog's own pulmonary valve. Following insertion of the conduit similar measurements were made to assess whether any stenosis or regurgitation was demonstrable in the implanted valve. Convincing evidence of normal physiological function was further provided by the 'normal' undistorted appearance of the conduit and the presence of a clearly palpable closing shock over the conduit valve.

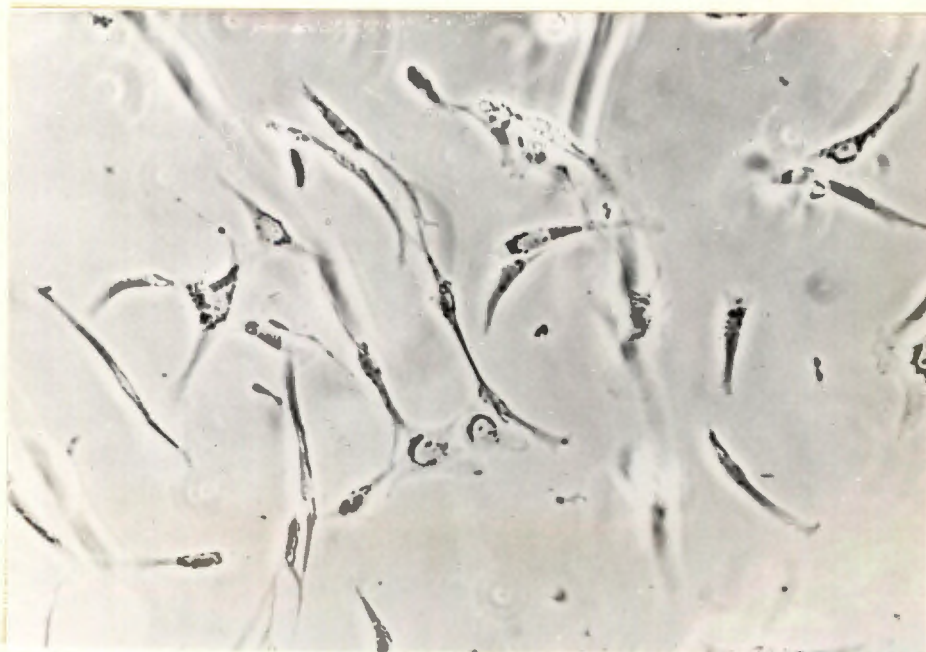


Explant of viable canine heart valve leaflet -
showing commencing fibroblast outgrowth





Well established tissue culture growth of fibroblasts
from viable canine heart valve leaflet.
Mitotic activity visible.



Insertion of allograft valve into host:

Healthy foxhounds, weighing between 20 and 24 Kg, were used as host animals. As far as possible the weight of donor and recipient was matched accurately. In each case donor and recipient were of opposite sex.

The dog was premedicated with Acetyl Promazine one hour before intravenous induction of anaesthesia with thiopentone sodium. A cuffed endotracheal tube was used for ventilation with a Palmer pump, and 50% Oxygen and 50% Nitrous Oxide was given. Intermittent halothane ($\frac{1}{2}$ - $1\frac{1}{2}\%$) and intravenous suxamethonium were given as necessary.

The animal was positioned for left thoracotomy as shown in Figure 6b-2. The right femoral artery was cannulated for continuous pressure monitoring and for blood sampling for blood gas analysis.

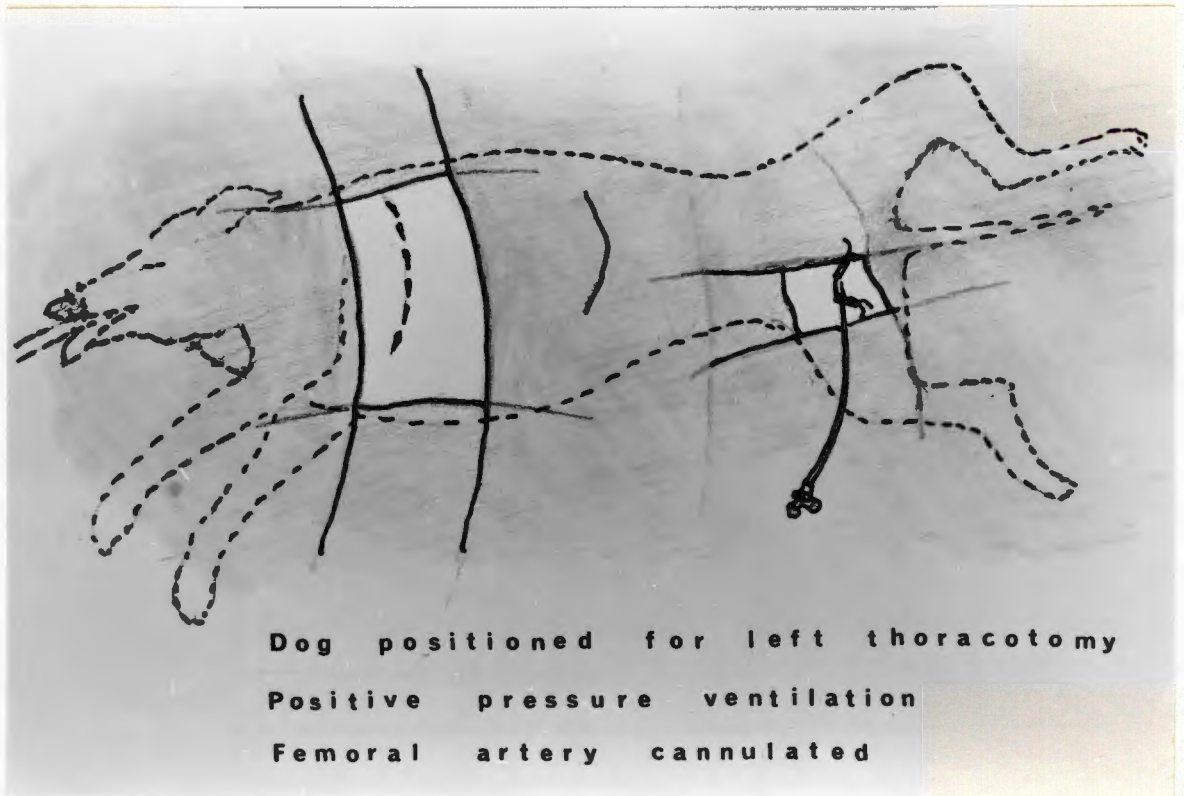


Figure 6b-2

Left thoracotomy was performed, dividing as little as possible of latissimus dorso muscle. The left chest was entered through the bed of the unresected 5th rib (Figure 6b-3).

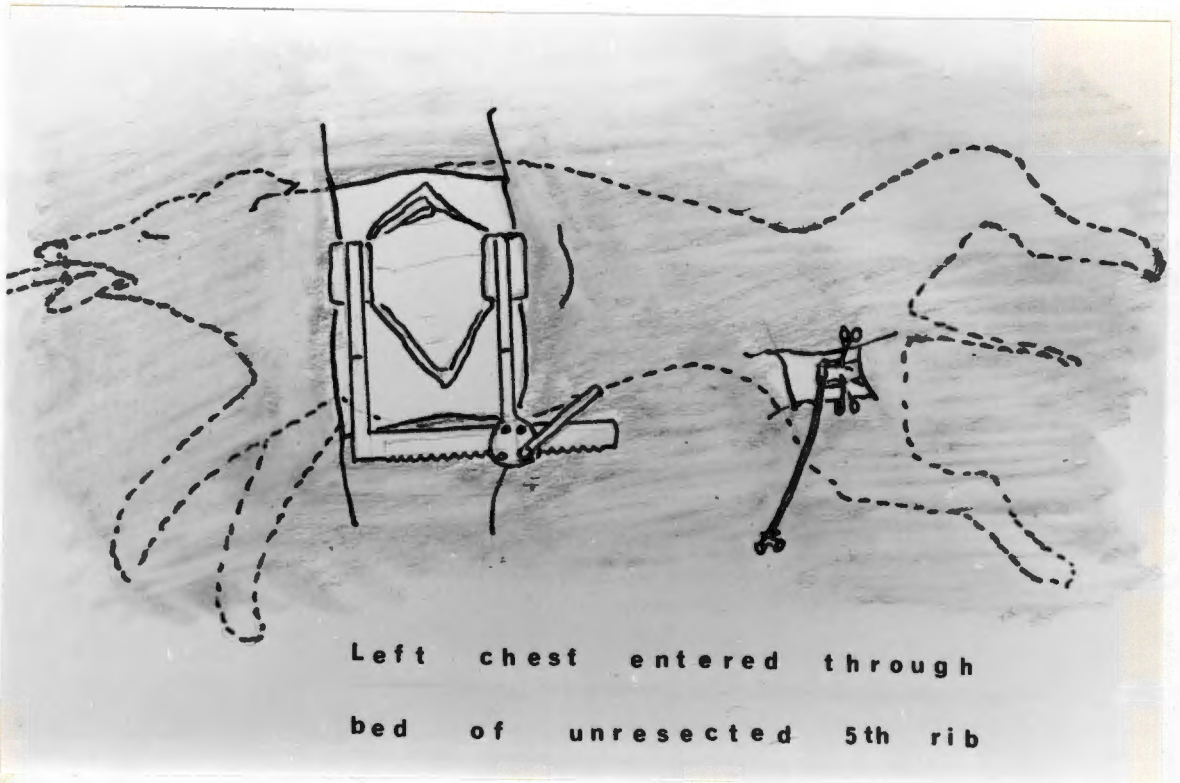


Figure 6b-3

The pericardium was opened anterior and parallel to the phrenic nerve, and an anterior extension of this pericardial incision provided wide access to the heart (Figure 6b-4).

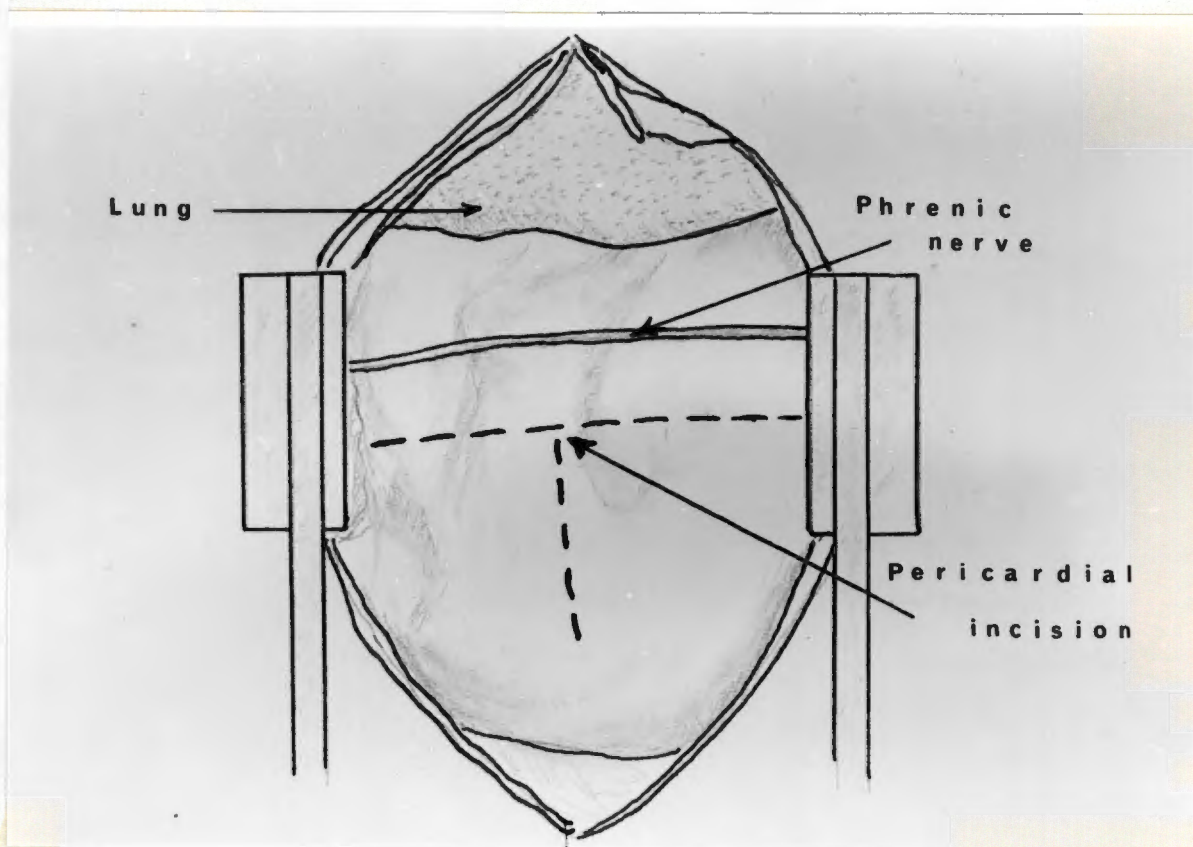


Figure 6b-4

After stitching back the opened pericardium and removing obscuring fat from the aortic root a view of the heart was obtained as shown in Figure 6b-5. Dissection was required along the left branch of the pulmonary artery to improve access to the region of the bifurcation.

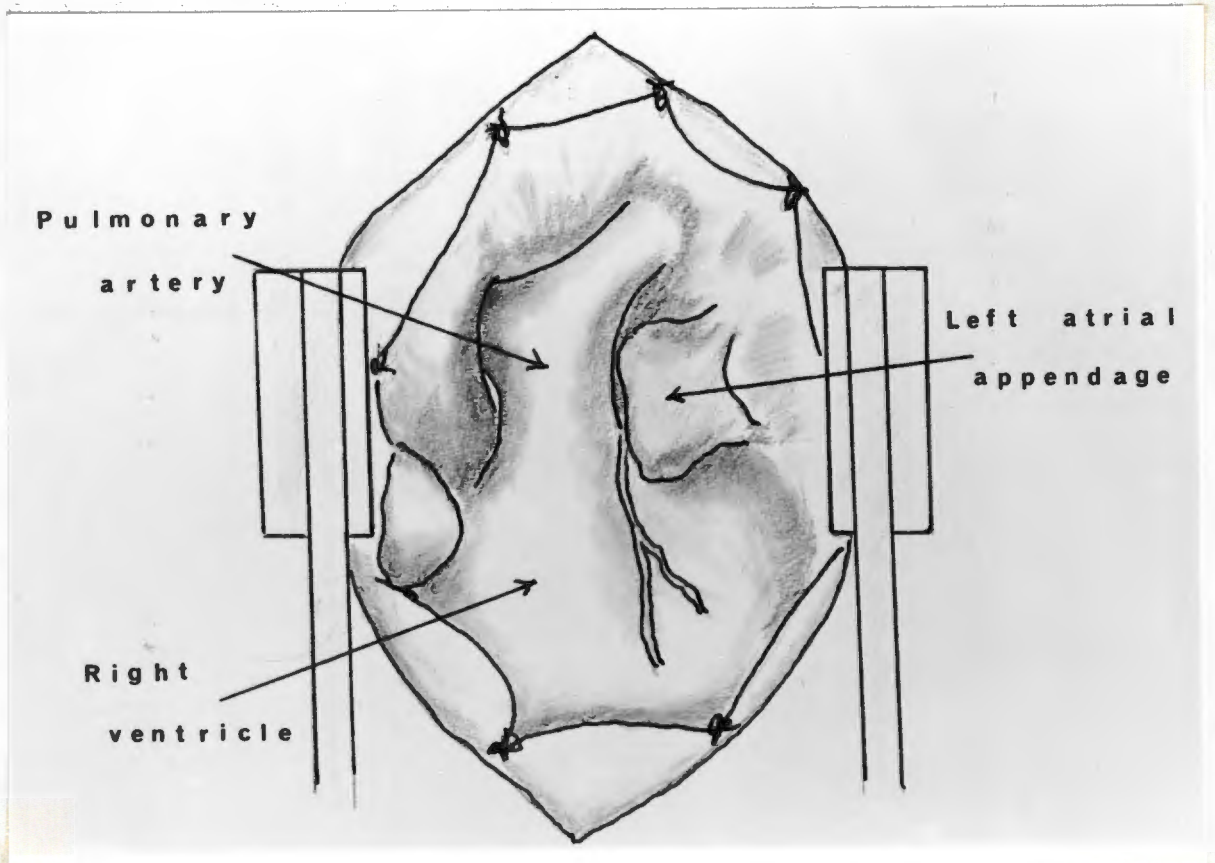


Figure 6b-5

A heavy ligature was placed around the main pulmonary artery for subsequent ligation - this required careful dissection between the aorta and pulmonary artery to avoid injury to the thin-walled and delicate pulmonary artery. A light Satinsky vascular clamp was applied to the region of the main pulmonary artery bifurcation and origin of left branch, and an incision of 2 to 2.5 cms was made starting on the left side of the pulmonary artery and extending across the bifurcation onto the left branch as shown in Figure 6b-6. Blood flow to both lungs continued during this stage of the operation - that to the right lung, which remained fully ventilated, was unimpaired. The bevelled distal end of the donor pulmonary

valve-bearing conduit was then anastomosed to the incised host vessel using continuous 6/0 Prolene suture material.

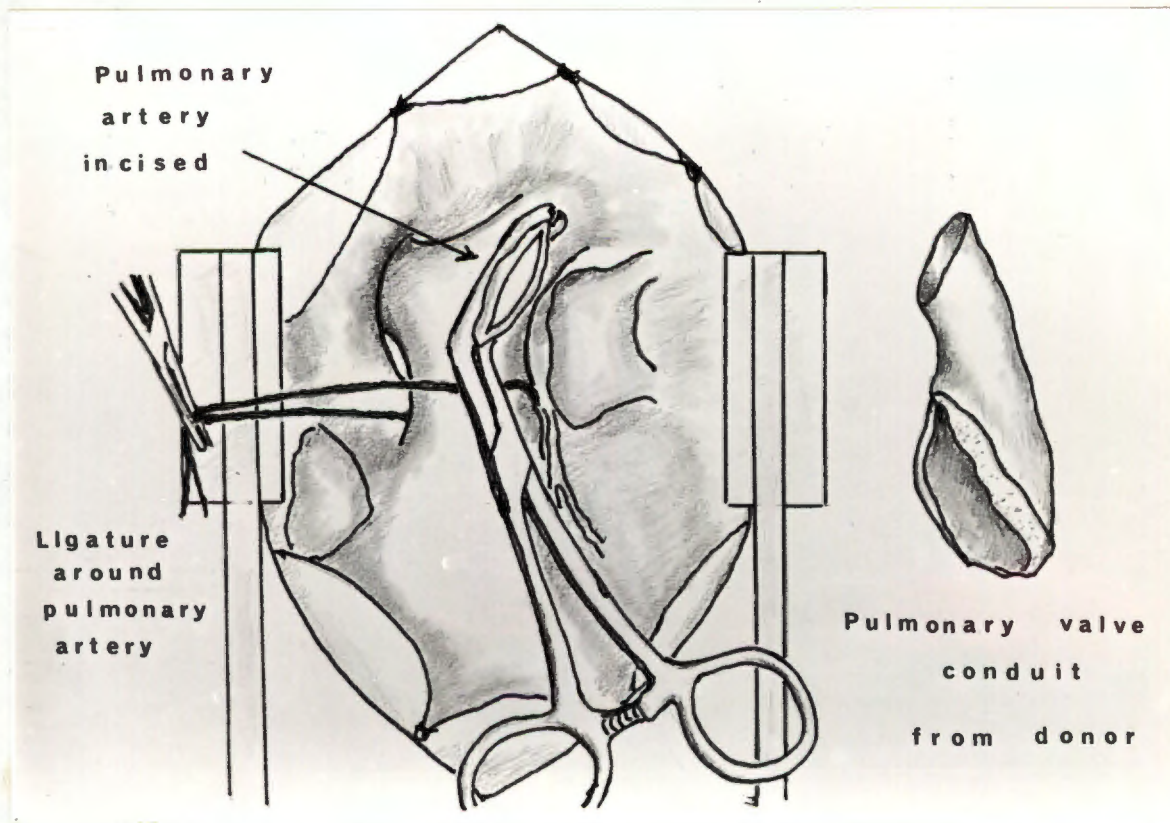


Figure 6b-6

With a vascular clamp on the conduit pulmonary artery the small Satinsky clamp was removed from the host pulmonary artery and haemostasis was confirmed - this rarely required further suturing provided that the initial suturing had been meticulous. A large Satinsky vascular clamp was then applied to the right ventricular outflow tract as shown in Figure 6b-7, enclosing a fold of myocardium in a line with the host pulmonary artery and extending up to and including the pulmonary annulus, care being required to avoid the anterior descending branch of the left coronary artery.

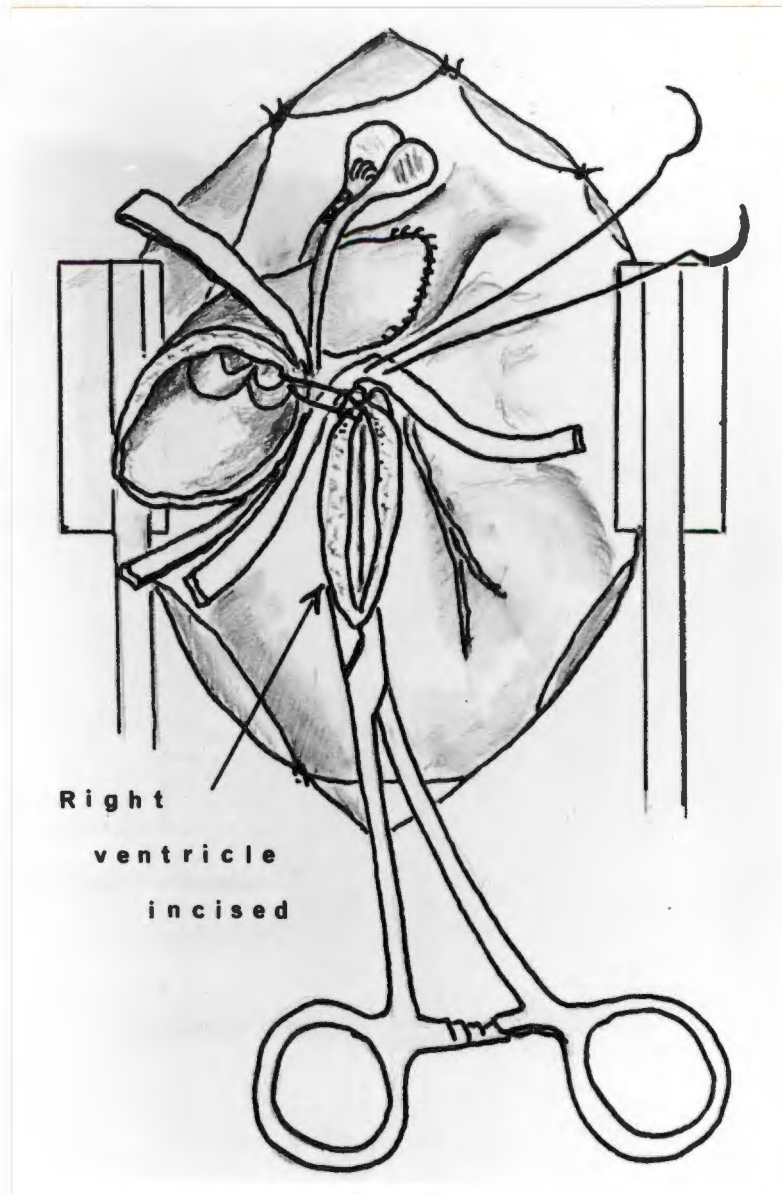


Figure 6b-7

Clamping of the right ventricular myocardium usually caused ventricular tachycardia for 1 to 2 minutes, with a fall in blood pressure from the usual 110 to 160 mm Hg to about 70 mm Hg, but later use of a bolus of intravenous lignocaine (20mg) reduced this period considerably. Normal rhythm invariably returned, and once the heart had recovered from the application of the clamp the right

ventricle was incised for 4 to 4.5 cms. A strip of Teflon was used to buttress the suture line on both conduit and host myocardium. Continuous 2/0 Prolene was used to anastomose the trimmed proximal end of the conduit to the host right ventricular outflow.

Following completion of the proximal anastomosis and removal of the Satinsky clamp the host pulmonary artery was ligated. This forced all the right ventricular output through the conduit and the conduit assumed a very satisfactory position without obvious distortion. Closure of the grafted valve was readily palpable. The appearance of the completed operation is shown in Figure 6b-8.

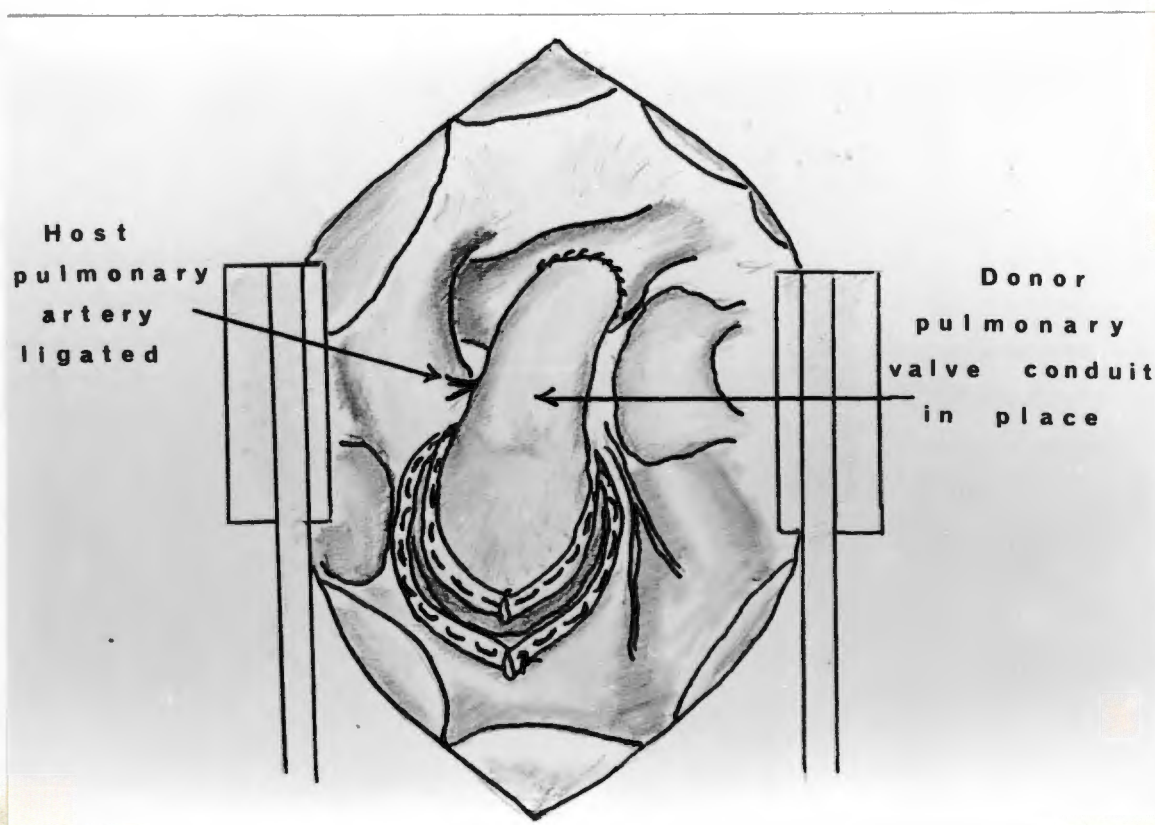


Figure 6b-8

Pressure measurements were made to confirm satisfactory function of the implanted valve, and similar measurements obtained prior to insertion of the graft were available for a control in each case.

The pericardium was not closed. After confirmation of haemostasis the thoracotomy was closed with a single Argyle tube for chest drainage. This tube was removed as soon as blood drainage ceased - usually within 1 - 2 hours.

Recovery from this procedure was rapid. The dog was conscious within a few minutes of discontinuing anaesthesia. Once the chest tube had been removed the dog was returned to the kennel. Within 4 - 6 hours most dogs were able to get up on their feet, and by next day they were drinking and eating and able to walk about.

Streptomycin and Penicillin (Streptopen 2 ml) were given twice daily for 5 days. Omnopon was used for analgesia during the first night, but no other drugs were given. A blood transfusion was given to two dogs in which post-operative blood loss exceeded 200 ml.

Assessments at time of allograft valve removal:

1) Assessment of function of implanted allograft valve:

At elective removal of the implanted allograft valve the left thoracotomy was reopened in the anaesthetised animal. Pressure measurements were made proximal and distal to the implanted valve for comparison with the record obtained under identical conditions at the time of valve insertion.

Further assessment of the functional state was more impressively obtained by direct visual inspection of the valve from above once the animal had been sacrificed and the conduit pulmonary artery had been opened.

2) Assessment of structural state of implanted allograft valve:

The conduit was opened, the incision being placed through a commissure to avoid damage to the valve leaflets. The appearances of the anastomotic lines, myocardium, pulmonary artery and valve leaflets of the conduit were noted, with particular attention to the size, thickness, integrity and mobility of the leaflets, and the presence of any thrombus within the conduit. A single photograph was taken of the opened conduit, care being taken to avoid contamination of the tissues and handling of the leaflets. The 35 mm colour slide thus obtained, while not of optimal quality because of the restraints on the photographer in the interests of maintaining sterility, was available as a permanent record of the valve's appearance. A print of such a slide again loses further in quality, but an example is shown in Figure 6b-9.

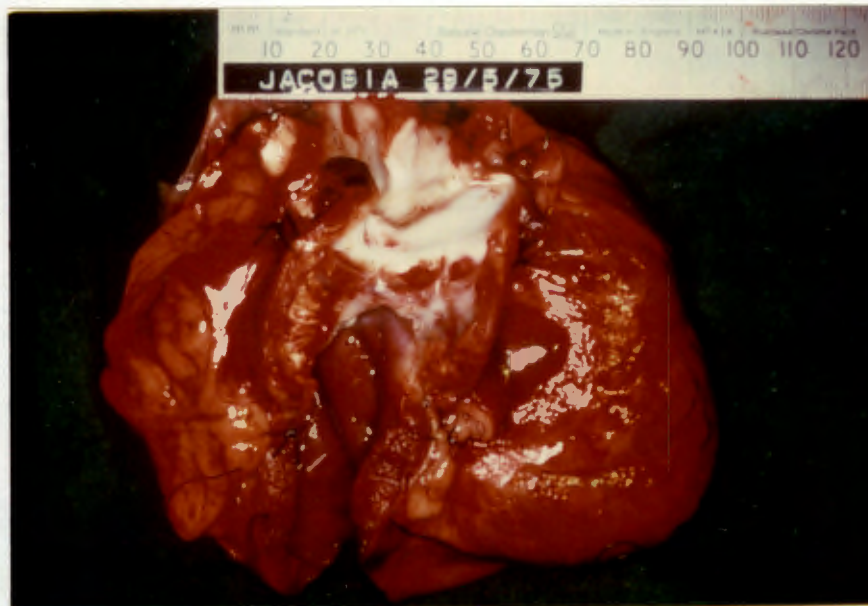


Figure 6b-9

Excised heart showing opened allograft conduit

Once a single leaflet had been removed under sterile conditions for tissue culture another representative leaflet was removed in a block of adjacent myocardium and pulmonary artery and was mounted on a cork square in a perspex container containing 0.9% saline solution. This allowed a better quality photograph of a leaflet to be made with the leaflet in a more natural position. The container used for this purpose is shown in Figure 6b-10. A control pulmonary valve leaflet from a normal dog of same size was similarly photographed.




Figure 6b-10

Further information regarding the structural state of the implanted leaflets was available from the histological slides.

The third leaflet of the valve was excised at its base. This required care and judgement, particularly when the leaflet was very shrunken and thickened, as defining the base of the leaflet was not always easy. The excised leaflet was then laid carefully onto a glass slide and its outline was drawn onto the under-surface of the glass slide to allow subsequent measurement of surface area. A control pulmonary valve leaflet from a dog of same weight was measured in identical fashion.

3) Assessment of microscopic appearance of implanted allograft valve:

The excised leaflet, together with adjacent myocardium and pulmonary artery, which was used for the photograph in the

perspex container was used for preparation of standard histological sections through the middle of the leaflet. The tissue was placed in formol corrosive for fixation and hardening for one week. Sections were then cut with a razor knife through the middle of the leaflet as shown in Figure 6b-11, dehydrated in alcohol and embedded in paraffin wax. Sections of uniform 5 micron thickness were cut and stained with Haematoxylin and eosin, elastic, trichrome and Periodic Acid Schiff stains.

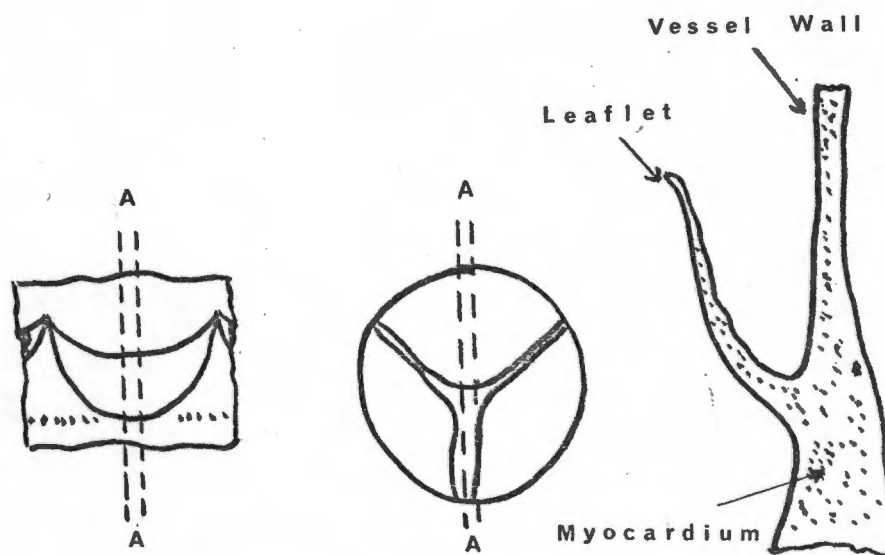


Figure 6b-11

Preparation of histological sections

4) Assessment of tissue culture growth of implanted allograft valve:

Half of the leaflet that had been removed under sterile conditions from the opened conduit was minced with scissors and explants were placed between plastic coverslips for tissue culture in TC199, with 30% foetal bovine serum with added glutamine as described in section 5a.

5) Assessment of origin of cells grown in tissue culture:

The remaining half of the leaflet removed under sterile conditions from the opened conduit was finely cut up with scissors under sterile conditions in Waymouth medium with 20% foetal calf serum and added glutamine 2mM. The explants were transferred between glass coverslips into Leighton tubes (one explant per tube) containing the same tissue culture medium for incubation at 37°C. This study was done independantly of that referred to in the preceding paragraph (4) at the Department of Animal Reproduction of the University of Glasgow Veterinary School.

Once a confluent sheet of fibroblast growth had become established colchicine was added (0.1 ml of Biccult Colchicine 25 ug/ml in 2 ml of Waymouth medium). Colchicine arrests mitosis at metaphase (Tjio and Levan, 1956; Ford et al. 1958). After a further 12 hours of incubation at 37°C the coverslips were removed from the Leighton tubes and separated in 0.2% potassium chloride in water for $\frac{1}{2}$ hour (this causes cells to swell and disperses the chromosomes); then fixed overnight in 3:1 Methyl alcohol : acetic acid at 4°C. The coverslips were then dried and stained with Giemsa stain.

Photomicrographs were made of cells with visible chromosomes. The chromosomes were then arranged as shown in Figure 6b-12.

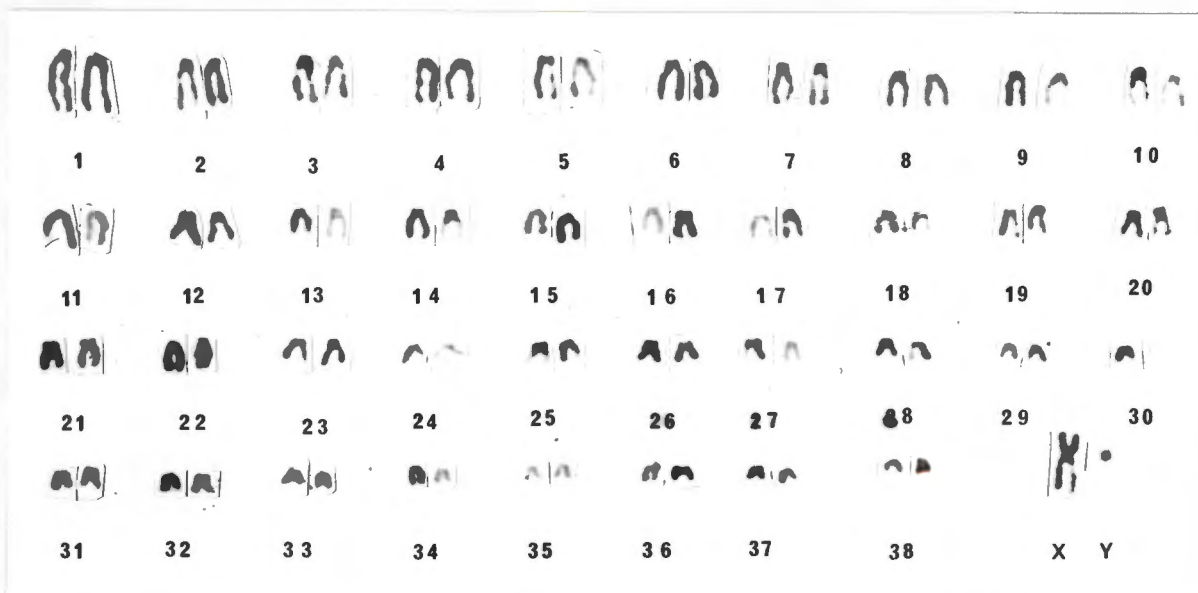


Figure 6b-12

Chromosomes of a cell grown in tissue culture
of an allograft heart valve

Identification of the X and Y chromosomes was relatively simple. Figure 6b-12 shows the 39 pairs of chromosomes isolated from a cell grown in tissue culture of an allograft heart valve leaflet after 8 weeks implantation. The 39th pair of chromosomes are readily identifiable as an X and a Y, showing the male origin of that particular cell.

6) Assessment of protein and collagen synthesis
by the implanted allograft heart valve:

The leaflet that was used for measurement of surface area on a glass slide was next taken to the Research Laboratory of the Glasgow Royal Infirmary for immediate assessment of protein and collagen synthetic activity using the method described in Section 5a. The experimental dog's own pulmonary valve was used as a control for this investigation.

Figure 6b-13 summarises the assessments at time of allograft valve removal.

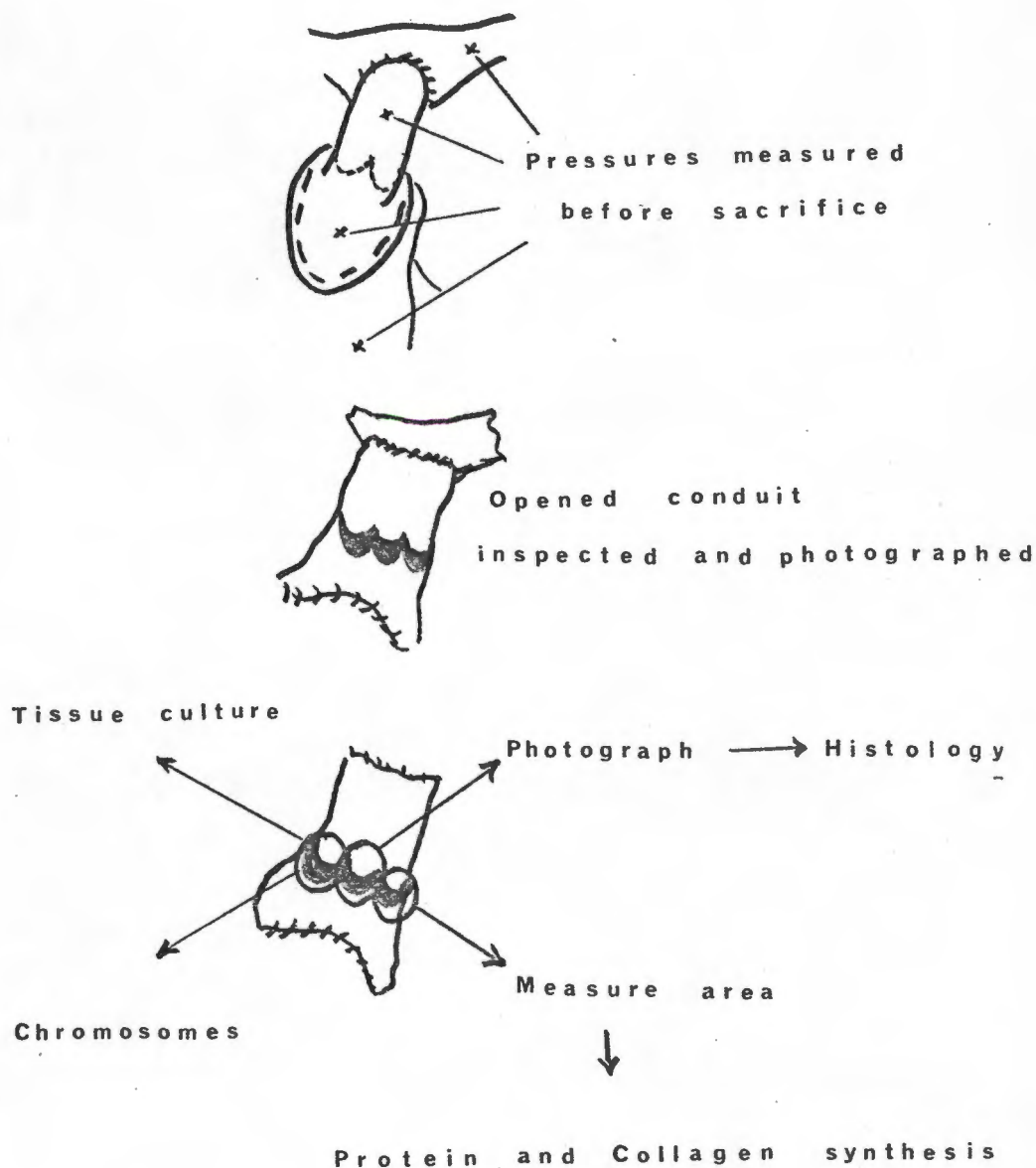


Figure 6b-13

All these assessments were made for each of the 8 week implanted valves. Some of the one week implanted valves, were obtained following disruption of the conduit myocardium; in these cases bacteriological smears were taken for culture from within the conduit and around the perforated area to exclude the presence of infection. In these cases it was not possible to assess protein and collagen synthesis because of the lack of time to plan this investigation.

30 dogs were operated on for insertion of an allograft pulmonary valve as described in Section 6b.

Early in the series two operative deaths occurred (dogs number 2 and 8) due to a combination of operative blood loss from the distal anastomosis, hypotension as a result of excessive halothane administration compounded by blood loss, and intractable ventricular fibrillation following intracardiac adrenaline administration. Greater appreciation of the hypotensive effect of halothane as well as its tendency to induce myocardial irritability, well demonstrated in this series, led to reduction in the concentration of halothane used and the addition of intermittent suxamethonium, with improvement in the arterial blood pressure maintained throughout the operation.

The operation usually took between 2 and $2\frac{1}{2}$ hours from start to finish, and the proximal and distal anastomoses took 20 to 25 minutes each. Continued steady blood loss in two dogs from the intercostal tube necessitated blood transfusion of 300 ml in each case, but in no other case was blood transfusion required.

With the exception of the technical difficulties which led to the death of the two dogs already referred to the operations were remarkably uneventful and recovery was smooth, prompt and without incident in all cases.

No evidence of infection was detected in any of the dogs. Most had a temperature of $103 - 104^{\circ}\text{F}$ for 2 to 3 days and this gradually settled to 101°F (normal for these dogs) without any evidence of pulmonary or wound infection.

One of the animals developed progressive abdominal swelling following operation. This was soon realised to be due to pregnancy, confirmed by abdominal X-ray, and 4 weeks after surgery 11 puppies were born uneventfully. 5 days later the animal became unwell, with tachycardia, anaemia, pleural effusions, pulmonary congestion, ascites, and paroxysmal ventricular tachycardia on electrocardiography. Treatment by suppression of lactation and procainamide 250 mg 6 hourly was followed by full recovery within 5 days. Besides keeping the animal nursing staff busy with hand weaning, the incident did demonstrate that the operation was well tolerated and did not impair cardiac output to a clinically detectable degree during pregnancy and parturition. The stress of lactation may have precipitated cardiac failure due to the fact that this particular dog had a viable allograft valve, which suffered severe shrinkage and became incompetent.

Conduit Disruption

As mentioned in Section 6a (Method of valve insertion) it was anticipated that disruption of necrotic conduit myocardium might occur. This did in fact occur in 7 animals (5 with viable and 2 with non-viable grafts) between 5 and 7 days. In each instance death was sudden and unexpected. Autopsy showed the chest to be full of blood which had escaped from a perforation of the conduit myocardium close to the proximal suture line. The entire conduit myocardium was soft and friable. Bacteriological examination confirmed that this area of the conduit was sterile.

Conduit disruption appeared to be an inherent hazard of this operation, but it caused no difficulty apart from adding an element of unpredictability to the supply of 'short-term' implanted valves.

<u>ALLOGRAFT VALVE IMPLANTATION</u>				
<u>TIME IMPLANTED</u>	<u>VIABLE VALVES</u>		<u>NON-VIABLE VALVES</u>	
	<u>Dog's Name</u>	<u>Storage</u>	<u>Dog's Name</u>	<u>Storage</u>
'Short-term' 5 - 7 days	Cody	1 day	Gupta	35 day
	Bobby	1	Dinty	33
	Iris	5	Berta	35
	Angie	2	Chuck	36
	Hank	5	Limus	41
	Polly	3	Gyp	37
'Intermediate' 4 weeks	Liam	5		
	Kobie	3		
'Long-term' 8 weeks	Cyrus	1	Cindy	37
	Jacobia	5	Simba	34
	Dumas	1	Alta	34
	Zachary	1	Quita	40
	Milne	5	Hilda	40
	Sellie	1	Herbie	39
	Juno	1		
	Pearl	2		

Figure 6c-1

Figure 6c-1 shows details of the numbers of dogs for each category of valve. 'Storage' refers to the number of days the grafted valve had been kept in Antibiotic-Nutrient medium, and hence indicates whether the valve was viable or non-viable (see Section 6b - Assessments at time of allograft valve insertion (1)).

From the 28 operative survivors the following allograft valves were available for study:

6 viable valves implanted for 5 - 7 days

2 viable valves implanted for 4 weeks

8 viable valves implanted for 8 weeks

6 non-viable valves implanted for 5 - 7 days

6 non-viable valves implanted for 8 weeks

An 'intermediate' implantation period for the non-viable valves was not considered necessary in view of the similarity of histological changes at 1 week and at 8 weeks in these valves.

6c RESULTS OF ANIMAL STUDYAssessments at time of allograft valve insertion1) Confirmation of state of viability of implanted valve:

14 of the 16 control aortic 'viable' valves grew promptly in tissue culture, the rate of growth being similar to that for fresh canine valves as shown in Section 5a, thus confirming the viability of the implanted valves in this 'viable' group.

One of the 16 control aortic 'viable' valves showed initial growth in tissue culture, which ceased after 2 days; and another one of the 16 failed to show evidence of tissue culture growth. The explanation of this failure to confirm the expected viability in these valves is not clear - one valve had been stored for 1 day; the other for 5 days - and it is likely that the failure of tissue culture growth was due to a technical problem with the technique of tissue culture, rather than impairment of viability of the tissue. One of these valves was used for 'short-term' implantation; the other for 'long-term' implantation. The subsequent leaflet changes were in keeping with the others in their respective groups, lending support to the assumption that the valves were in fact viable.

None of the 12 'non-viable' valves showed any evidence of tissue culture growth. This was in keeping with the findings of Section 5a where none of the 40 valves stored in Antibiotic-Nutrient medium for more than 4 weeks showed tissue culture growth.

2) Confirmation of histological normality of implanted valve:

Histologically, the control aortic valve leaflet, the control adjacent myocardium and aorta, showed a normal appearance in each instance, although evidence of mild oedema of the leaflet was present in the 'non-viable' group as illustrated later in this section.

3) Confirmation of normal physiological function of implanted valve:

In each case the conduit assumed a very satisfactory position once the anastomoses were completed and the host main pulmonary artery had been ligated.

An easily palpable closing shock was present over the conduit valve in each case.

In three dogs angio-cardiographic confirmation of the satisfactory anatomical position of the implanted conduit was obtained; the procedure was not considered necessary in the remaining dogs. The quality of the angiography was not optimal because of the unsuitable radiological facilities available for angiocardiology. However, in the angiocardiology that were obtained the conduit lay in a very satisfactory position, not being obviously different from the normal right ventricular outflow tract before implantation of the conduit.

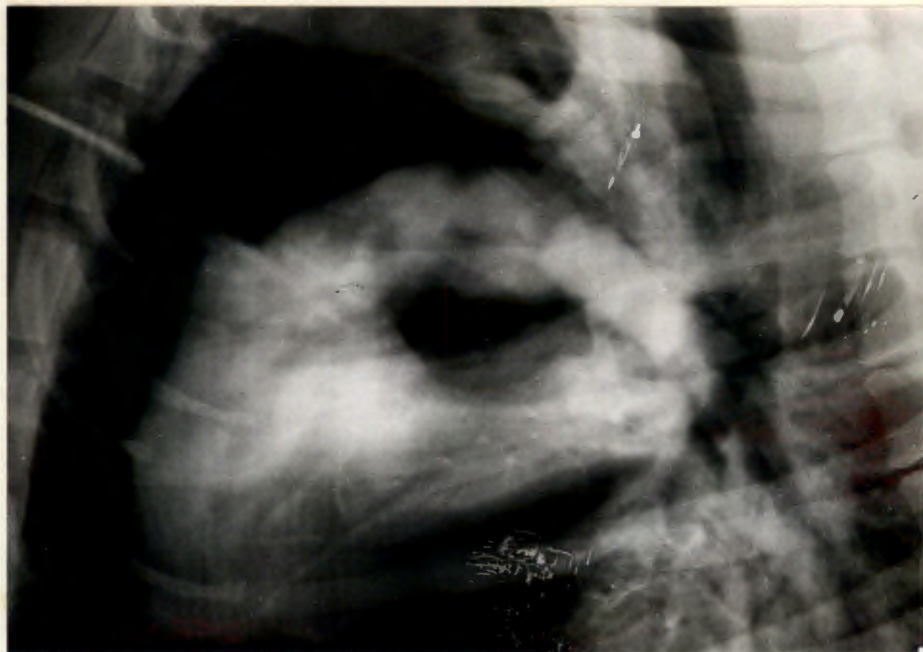
Pressure measurements were made as shown in Figure 6c-2 before and after implantation of the conduit. Figures 6c-2 and 6c-3 show typical tracings.

Right ventricular systolic pressure ranged between 20 and 40 mm.Hg. in 24 of the 28 surviving dogs prior to implantation of the conduit. In 4 dogs the right ventricular systolic pressure was lower, and this was almost certainly due to excessive halothane administration, which was noted to have a marked hypotensive effect in this series.

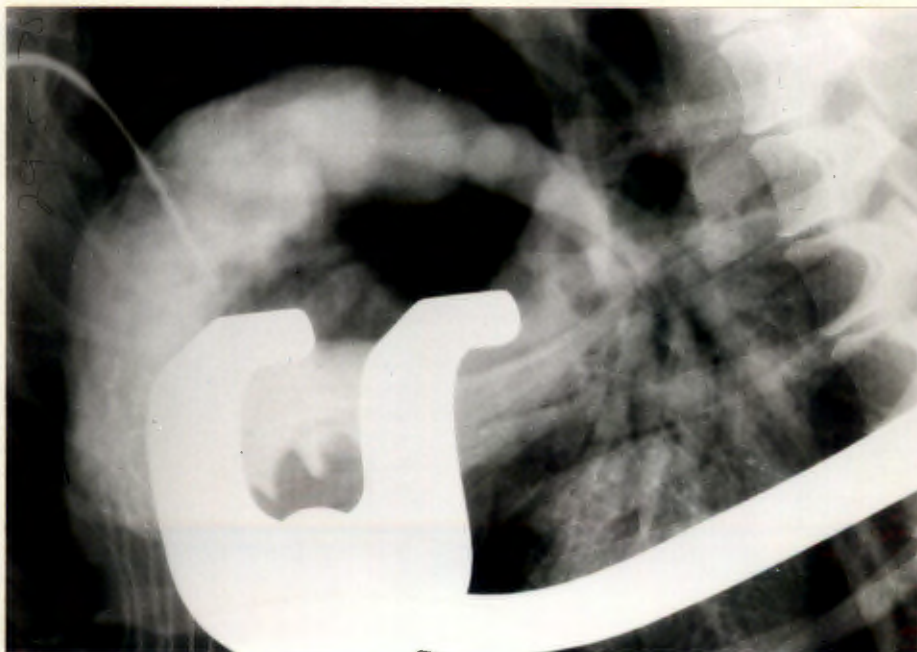A gradient was commonly present across the normal host pulmonary valve prior to insertion of the conduit, and measured between 5 and 10 mm.Hg. in 18 of the 28 dogs.

Although pulmonary arterial diastolic pressure is normally low in the dog clear evidence of a difference between pulmonary

arterial diastolic pressure and right ventricular end diastolic pressure was always present, both in the host animal prior to implantation, and in the conduit, giving clear evidence of function of the implanted conduit valve in each instance (Figures 6c-2 and 6c-3).



Angiographic appearance of dog's right ventricular outflow and pulmonary artery - prior to insertion of conduit



Angiographic appearance of same dog - after insertion of conduit - showing satisfactory anatomical position of conduit

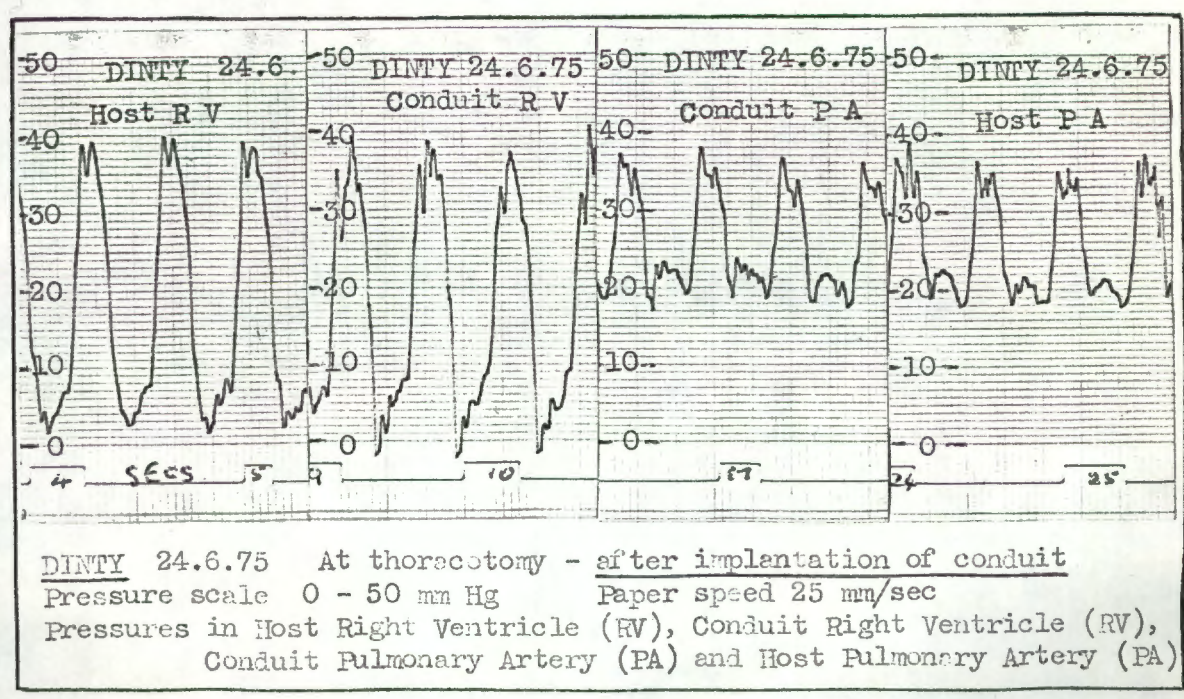
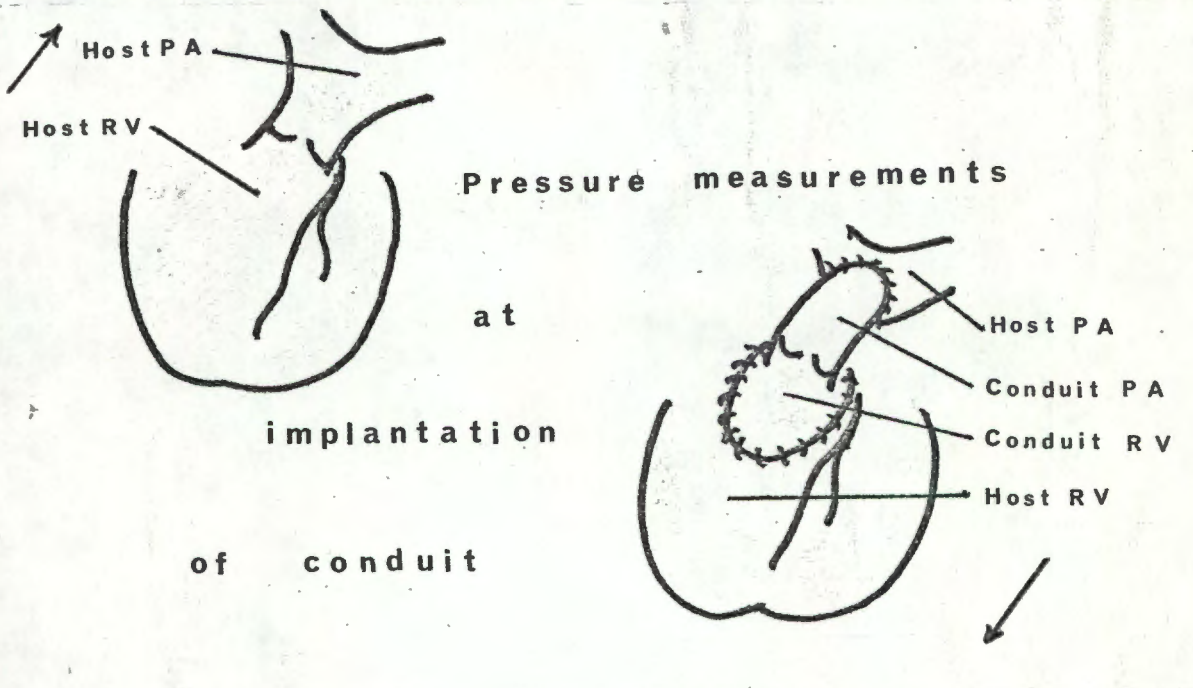
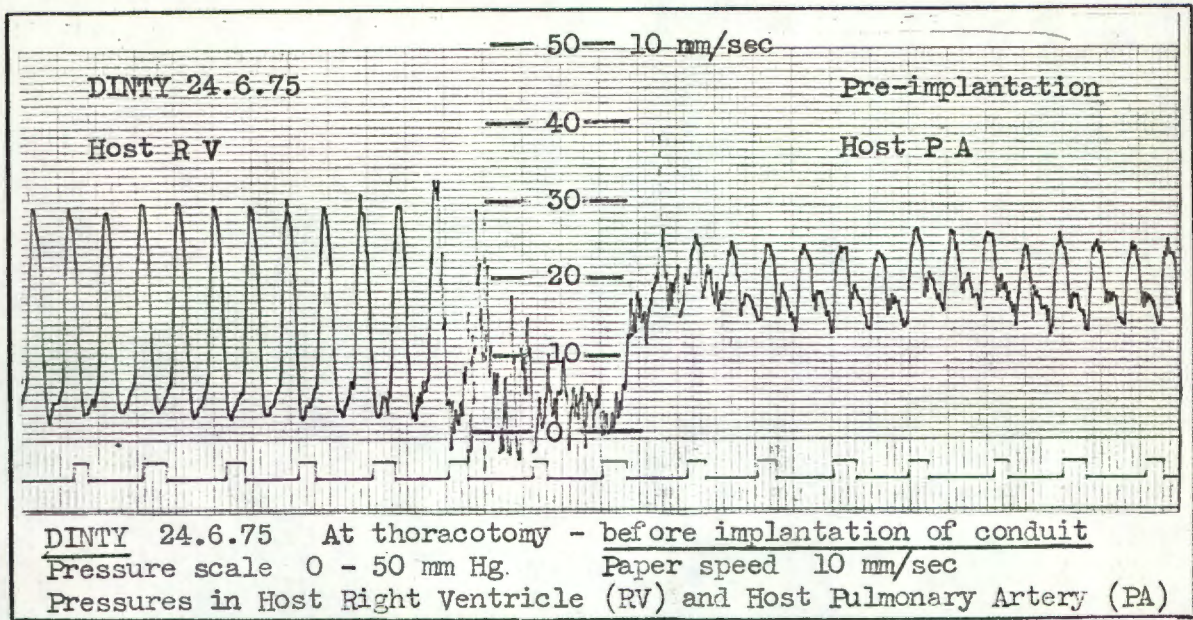
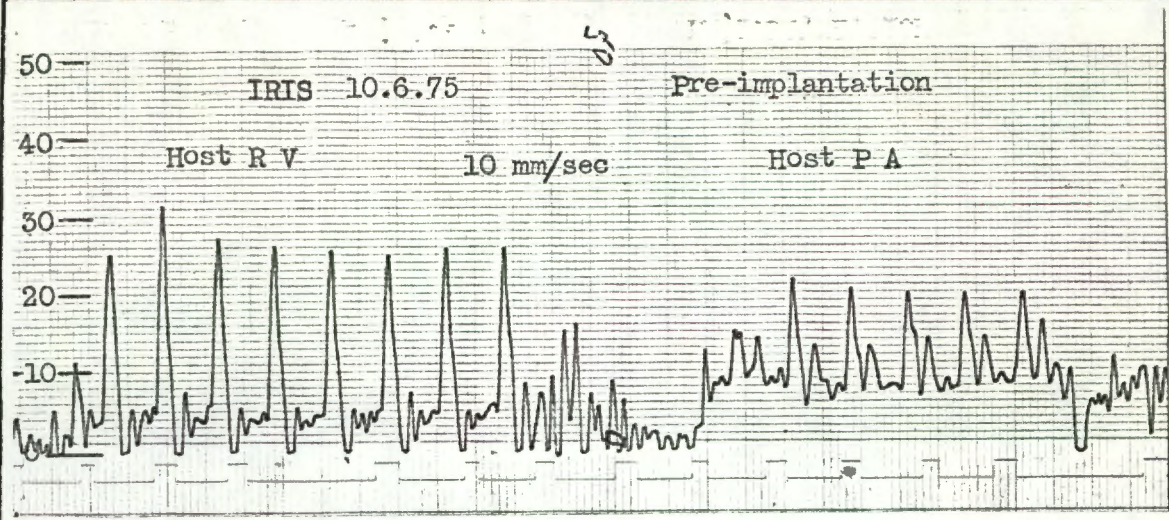
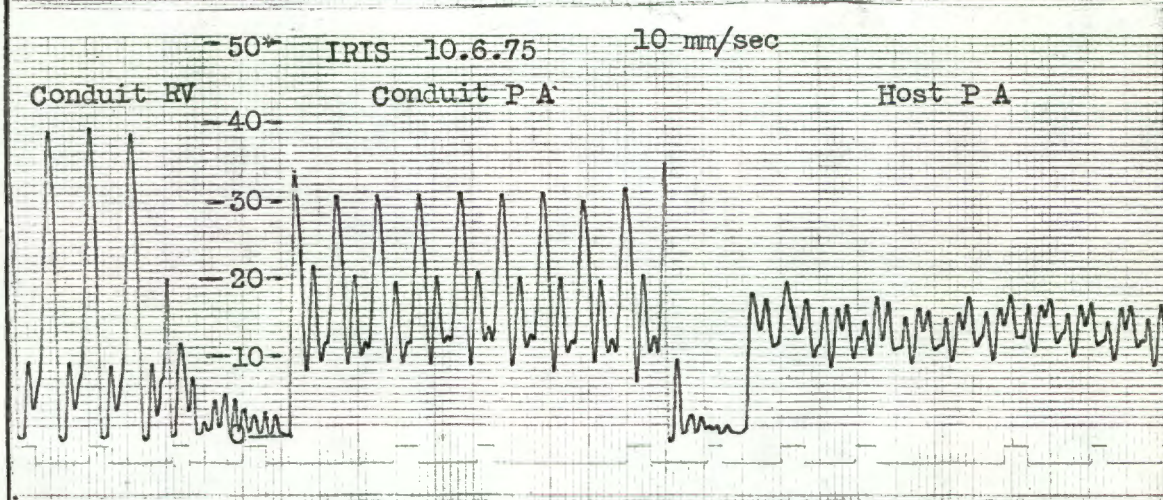
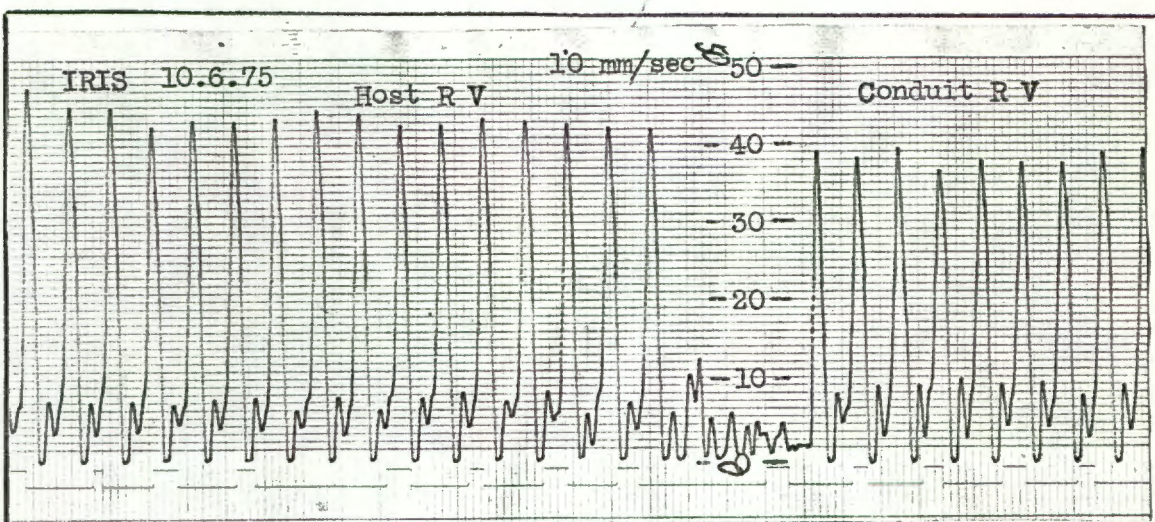


Figure 6c-2



IRIS 10.6.75 At thoracotomy - before implantation of conduit
Host R V 26/0 Host P A 20/7
Normal gradient over pulmonary valve; normal Pulmonary artery diastolic pressure



IRIS 10.6.75 At thoracotomy - after implantation of conduit
Host R V 44/0 Conduit R V 38/0 Conduit P A 32/9 Host P A 17/9
Normal gradient over conduit valve; normal pulmonary artery diastolic pressure

Good Haemodynamic Function of Conduit

Figure 6c-3

6c RESULTS OF ANIMAL STUDYAssessments at time of allograft valve removal.

21 of the 28 implanted allograft valves were removed at elective operation and the assessments described in Section 6b were made.

7 of the 28 (all 'short-term' valves) were removed at autopsy following conduit disruption. Pressure measurements and assessment of protein and collagen synthesis were not possible in these.

1) Assessment of function of implanted allograft valve:

All dogs coming to elective removal of their allograft valve had remained well and active during the period of valve implantation, with the sole exception of the one animal referred to earlier which developed transient heart failure during lactation.

In about half this group a soft systolic murmur was audible over the chest, but a diastolic murmur was not audible in any of the dogs.

At re-operation, the implanted conduit was seen to lie in a very satisfactory position. There were invariably light adhesions between it and the overlying lung.

Pressure measurements made proximal and distal to the conduit valve (as described in Section 6c 'Assessments at time of allograft valve insertion') showed the following:-

<u>Viable Valves</u>	{	Short-term	-	Normal function
		Intermediate	-	Normal function
		<u>Long-term</u>	-	<u>Loss of function</u>
<u>Non-viable Valves</u>	{	Short-term	-	Normal function
		<u>Long-term</u>	-	<u>Normal function</u>

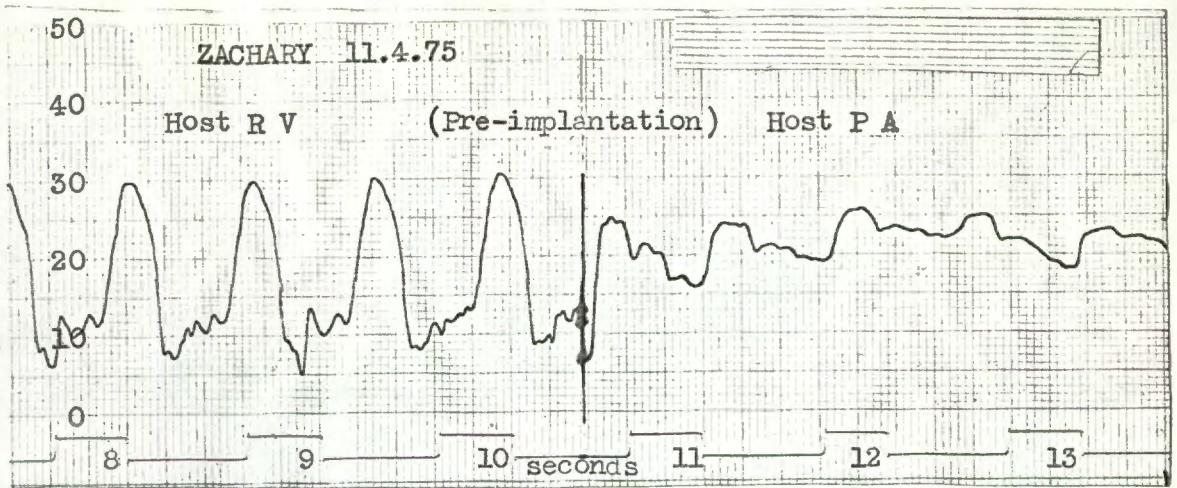
Figure 6c-4 shows the pressure records obtained from ZACHARY at the time of implantation of a viable valve. There is good function of the conduit valve shown by the absence of significant gradient over the valve, and well maintained pulmonary arterial diastolic pressure. Figure 6c-5 shows the striking difference between the record at implantation and the record obtained 8 weeks later. Right ventricular end-diastolic pressure is elevated and pulmonary arterial diastolic pressure is equal to right ventricular end-diastolic pressure - indicating right ventricular failure and pulmonary regurgitation.

By contrast, Figure 6c-6 shows the pressures recorded in CINDY at the time of implantation of a non-viable valve. After 8 weeks of implantation the pressure record obtained at re-operation shows that conduit valve function is retained.

The finding of retained function in the non-viable valves after 8 weeks of implantation was constant one. Figures 6c-7 to 6c-10 show clear haemodynamic evidence of retained function in non-viable allograft valves after 8 weeks of implantation.

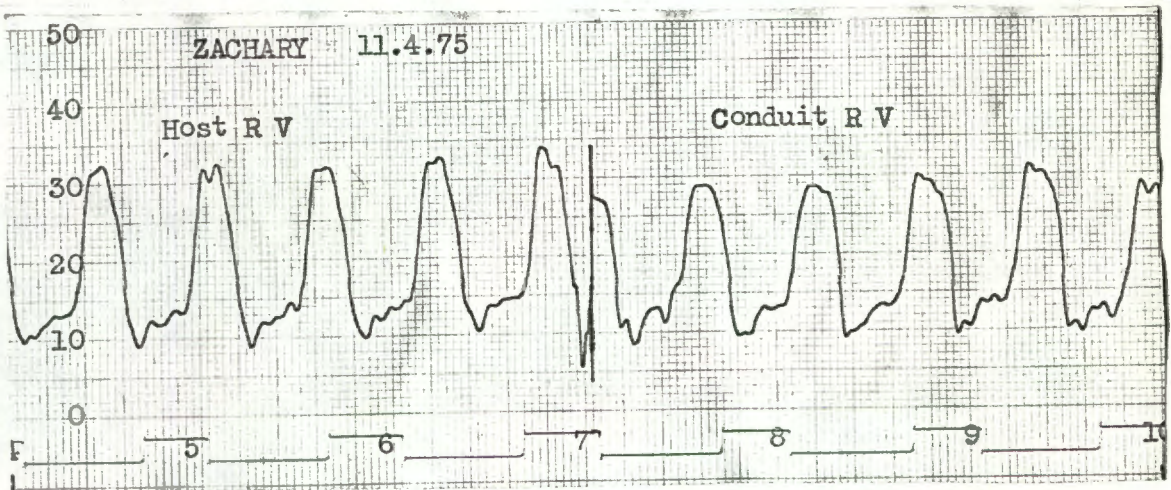
In only one of the 8 viable valves implanted for 8 weeks was a normal pressure record obtained at re-operation; and in this dog the implanted valve had a normal appearance.

The remaining 7 of the 8 viable valves showed haemodynamic evidence of virtually total loss of valve function at 8 weeks. In each instance there was clear evidence of normal valve function at the time of implantation of the conduit (Figures 6c-11 to 6c-14).

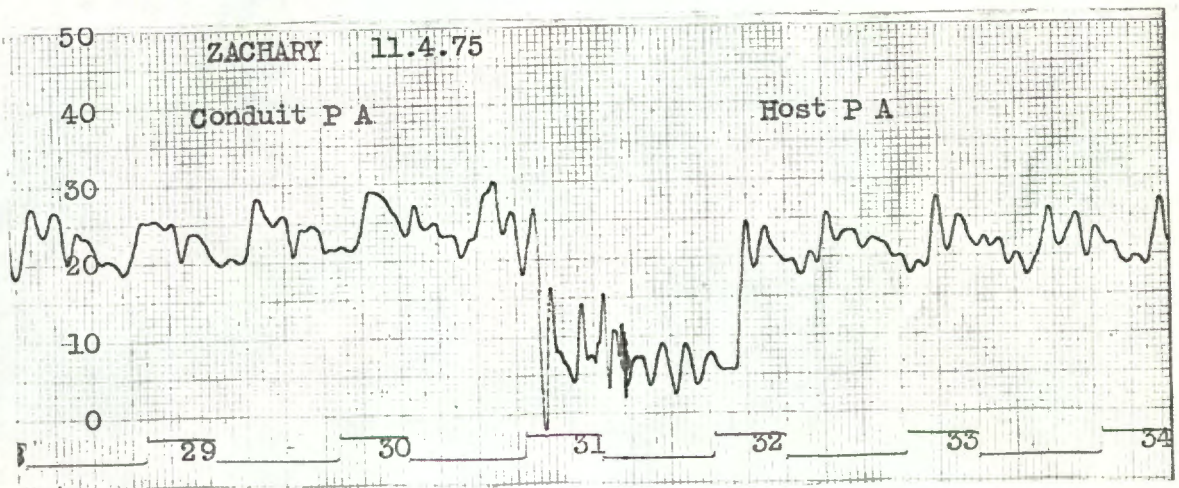


ZACHARY 11.4.75 At thoracotomy - before implantation of conduit
 Host R V 30/6 Host P A 25/18
 Normal gradient over host pulmonary valve
 Normal pulmonary artery diastolic pressure

Before implantation



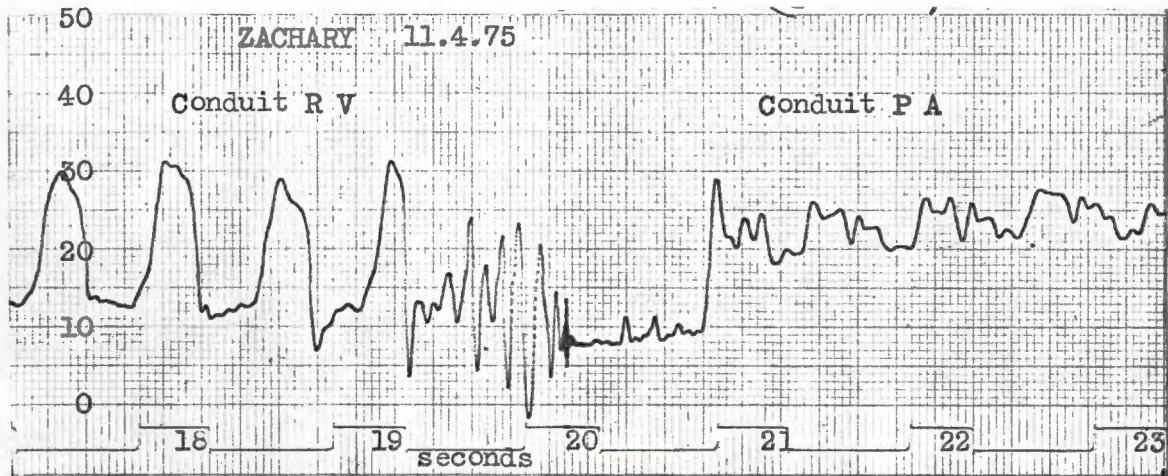
ZACHARY 11.4.75 At thoracotomy - after implantation of conduit
 Host R V 33/9 Conduit R V 30/9



ZACHARY 11.4.75 At thoracotomy - after implantation of conduit
 Conduit P A 30/20 Host P A 28/18
 No gradient over conduit valve; clear evidence of conduit valve competence

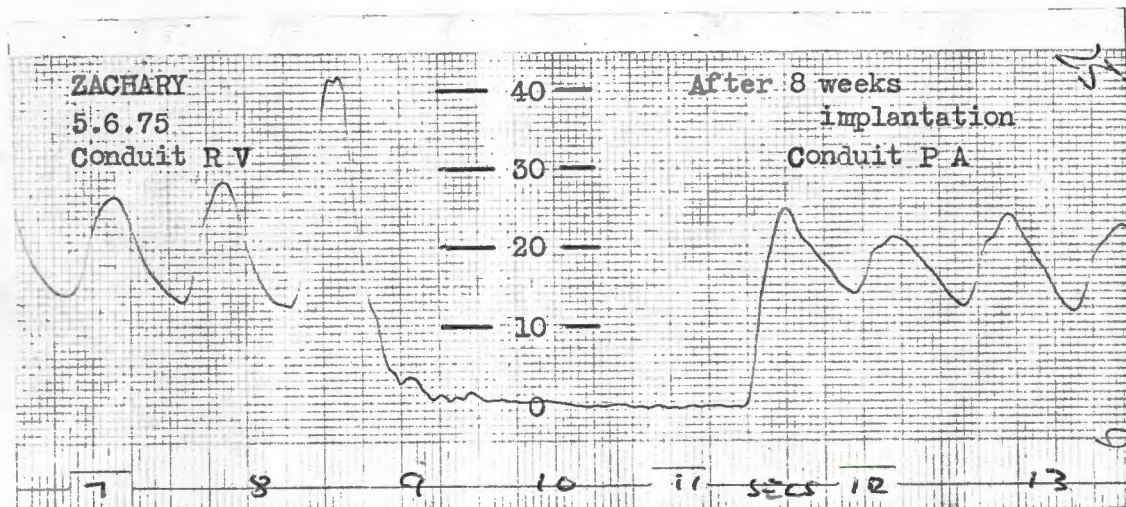
Good Conduit Function

Figure 6c-4



ZACHARY 11.4.75 Viable Valve at time of implantation
Conduit R V 30/10 Conduit P A 28/20
Clear evidence of conduit valve competence

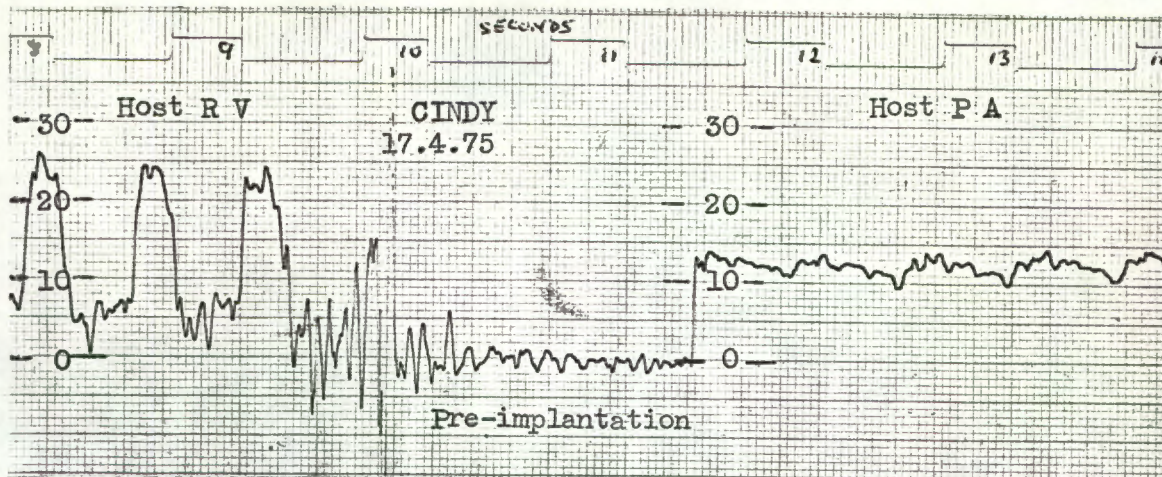
Viable Valve - Normal Function at implantation



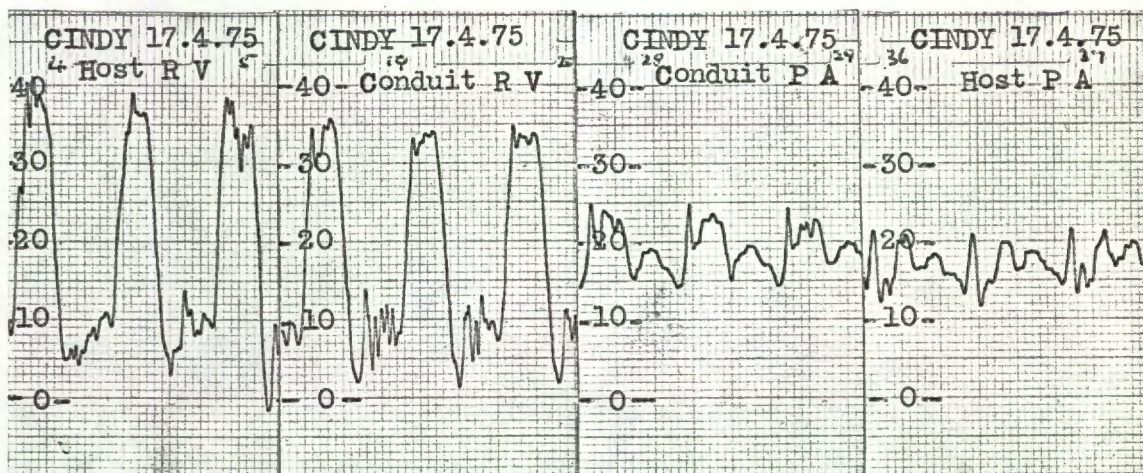
ZACHARY 5.6.75 Same valve after 8 weeks implantation
Conduit R V 28/12 Conduit P A 25/12
No evidence of conduit valve competence

Same Valve - Loss of Function after 8 weeks

Figure 6c - 5

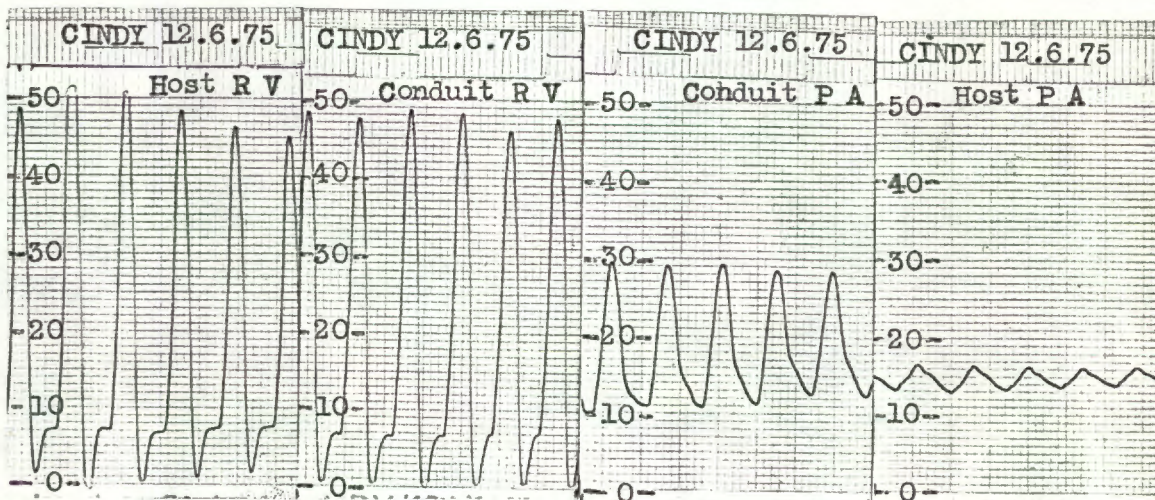


CINDY 17.4.75 At thoracotomy - before implantation of conduit
 Host R V 25/0 Host P A 15/10 Normal gradient over valve
 Normal pulmonary artery diastolic pressure



CINDY 17.4.75 At thoracotomy - after implantation of conduit
 Host R V 38/0 - 5 Conduit R V 35/2 Conduit P A 25/15 Host P A 21/13
 Normal gradient over conduit valve; normal P A diastolic pressure

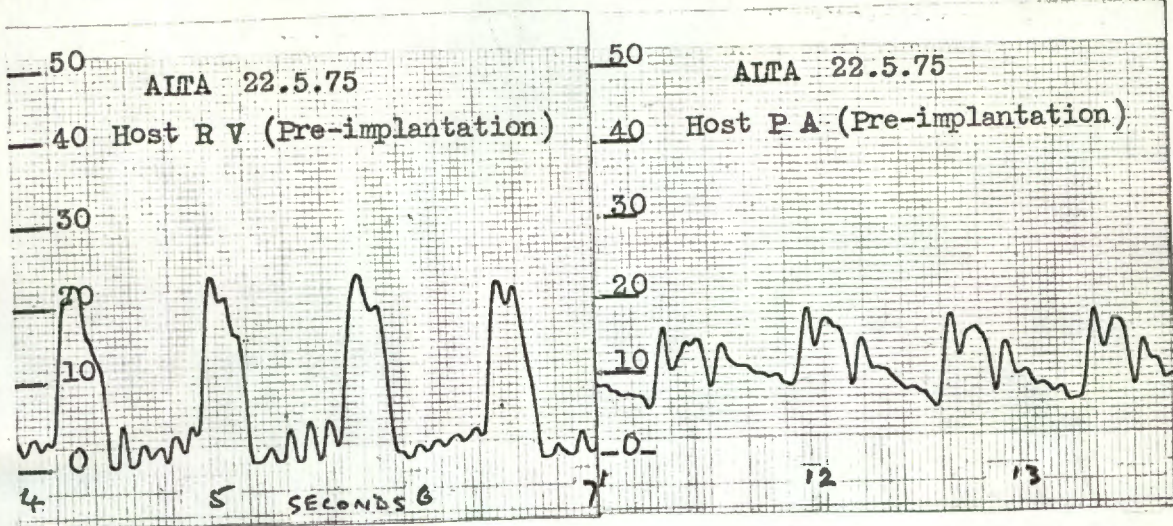
NON-VIABLE VALVE



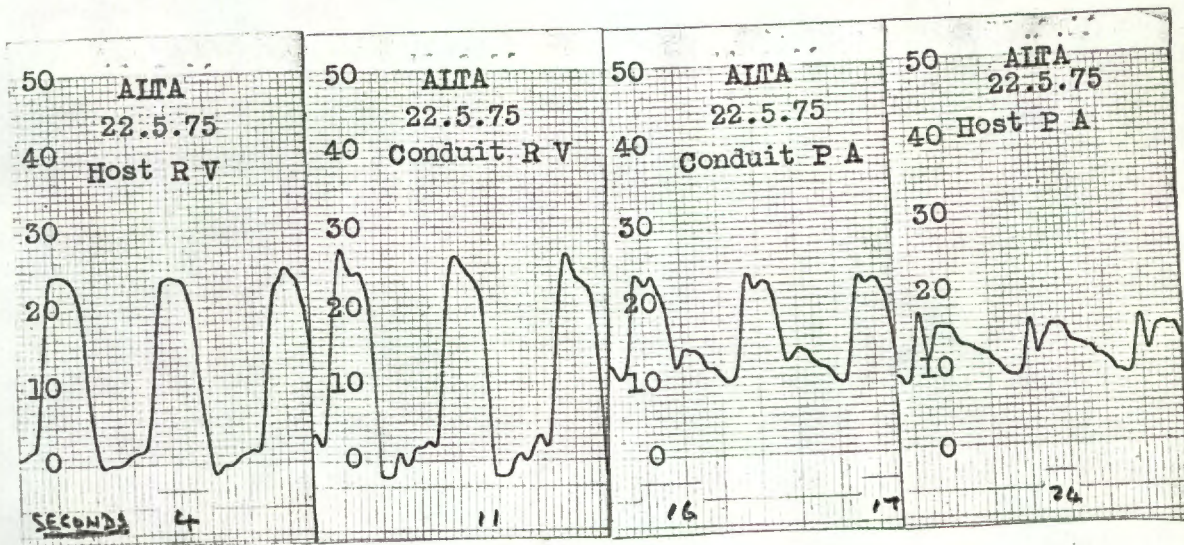
CINDY 12.6.75 At thoracotomy for removal of conduit 8 weeks later
 Host R V 50/0 Conduit R V 45/0 Conduit P A 29/12 Host P A 17/13
 Normal gradient over conduit valve; normal P A diastolic pressure

Normal Function Retained in Non-Viable Valve

Figure 6c-6

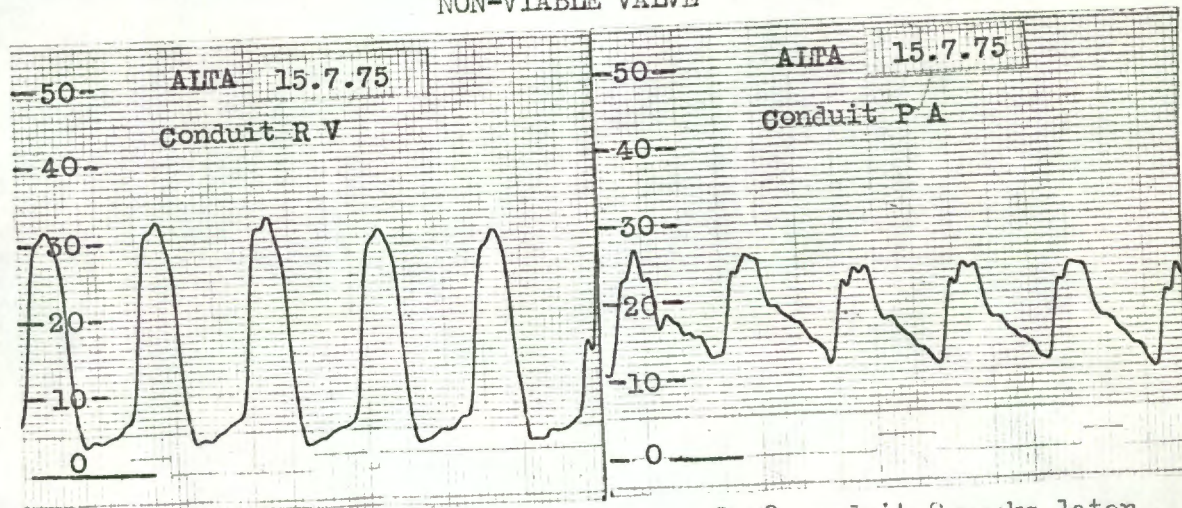


AITA 22.5.75 At thoracotomy - before implantation of conduit
 Host R V 24/0 Host P A 17/6 Normal gradient over valve
 Normal pulmonary artery diastolic pressure



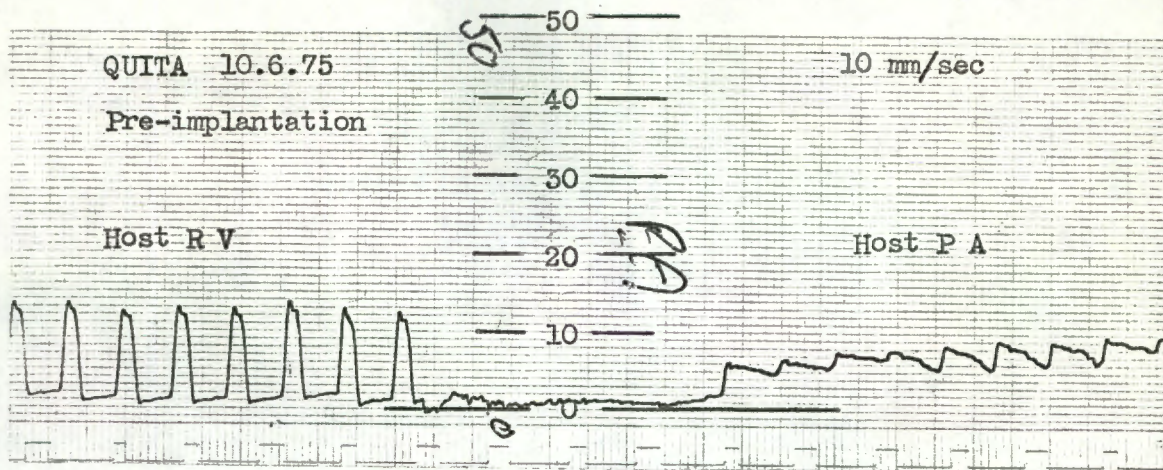
AITA 22.5.75 At thoracotomy - after implantation of conduit
 Host R V 24/0 Conduit R V 26/0 Conduit P A 23/9 Host P A 16/9
 Normal gradient over conduit valve; normal P A diastolic pressure

NON-VIABLE VALVE

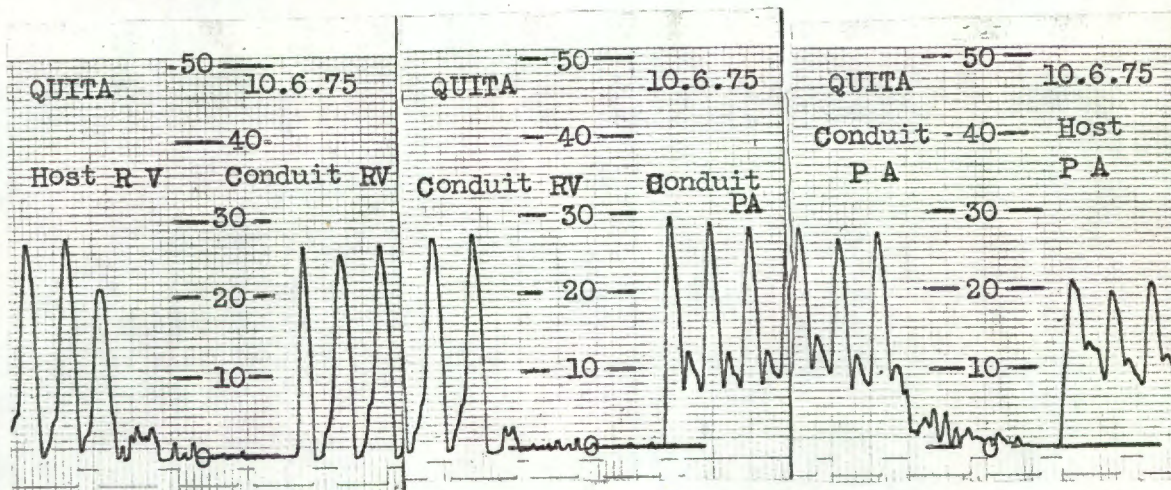


AITA 15.7.75 At thoracotomy for removal of conduit 8 weeks later
 Conduit R V 32/3 Conduit P A 25/12
 Normal gradient over conduit valve, normal P A diastolic pressure

Normal Function Retained in Non-Viable Valve

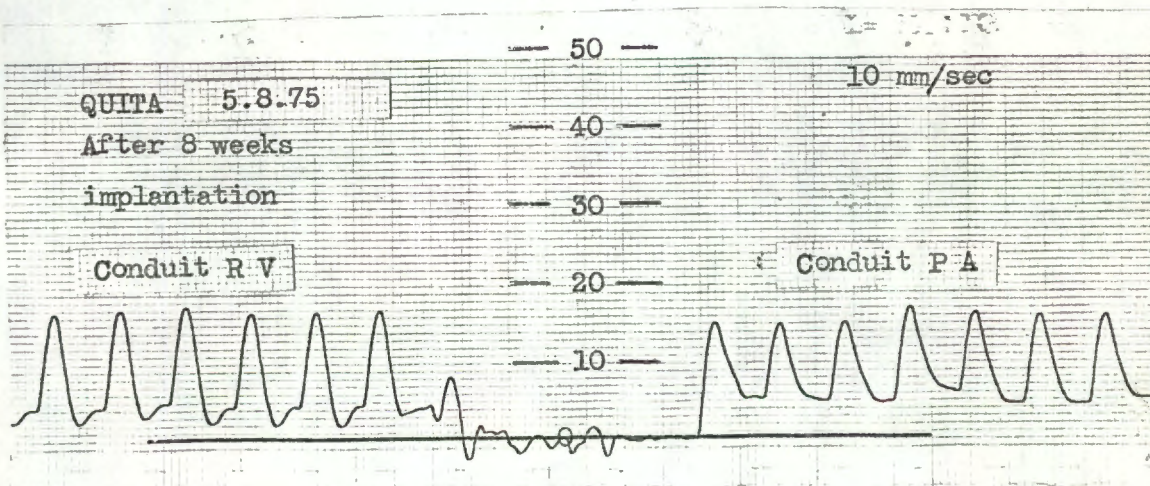


QUITA 10.6.75 At thoracotomy - before implantation of conduit
 Host R V 13/0 Host P A 10/6 Normal gradient over valve
 Normal pulmonary artery diastolic pressure



Quita 10.6.75 At thoracotomy - after implantation of conduit
 Host R V 27/0 Conduit R V 26/0 Conduit P A 27/8 Host P A 21/8
 No gradient over conduit valve; normal P A diastolic pressure

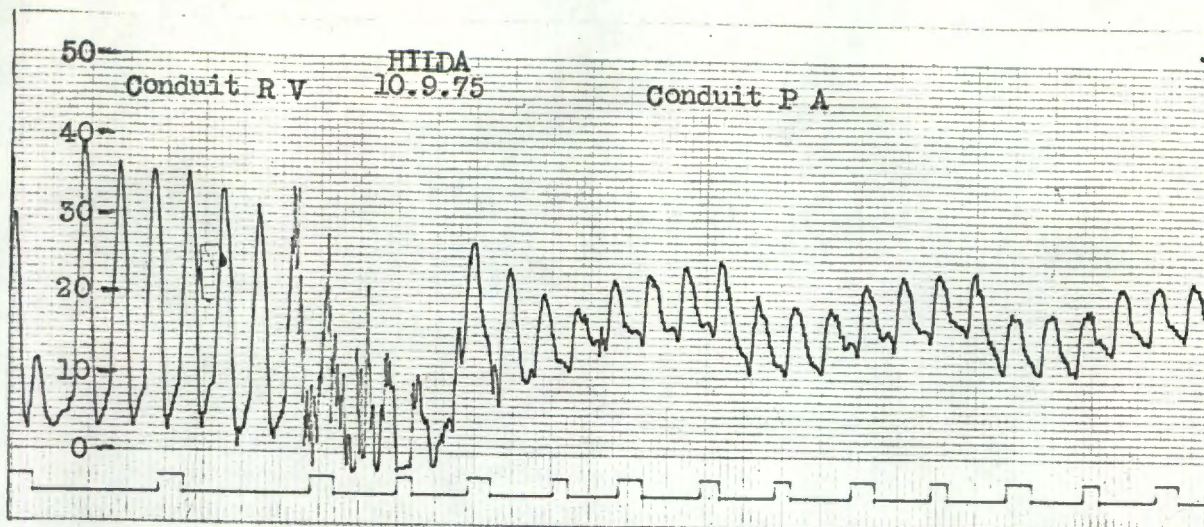
NON-VIABLE VALVE



QUITA 5.8.75 At thoracotomy for removal of conduit 8 weeks later
 Conduit R V 17/2 Conduit P A 13/5
 No gradient over conduit valve, normal P A diastolic pressure

Normal Function Retained in Non-Viable Valve

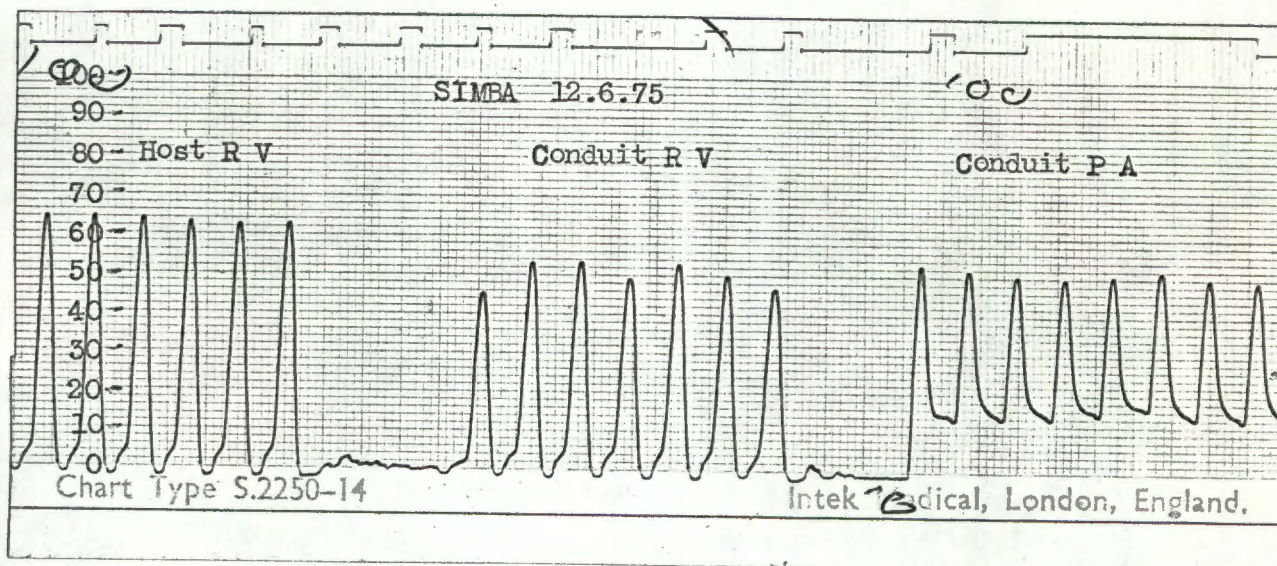
Figure 6c-8



HILDA 10.9.75 Non-viable Valve implanted 8 weeks
 Pressure scale 0 - 50 mm Hg
 Paper Speed 10 mm/sec
 Pressure measured in Conduit Right Ventricle (R V)
 and Conduit Pulmonary Artery (P A)

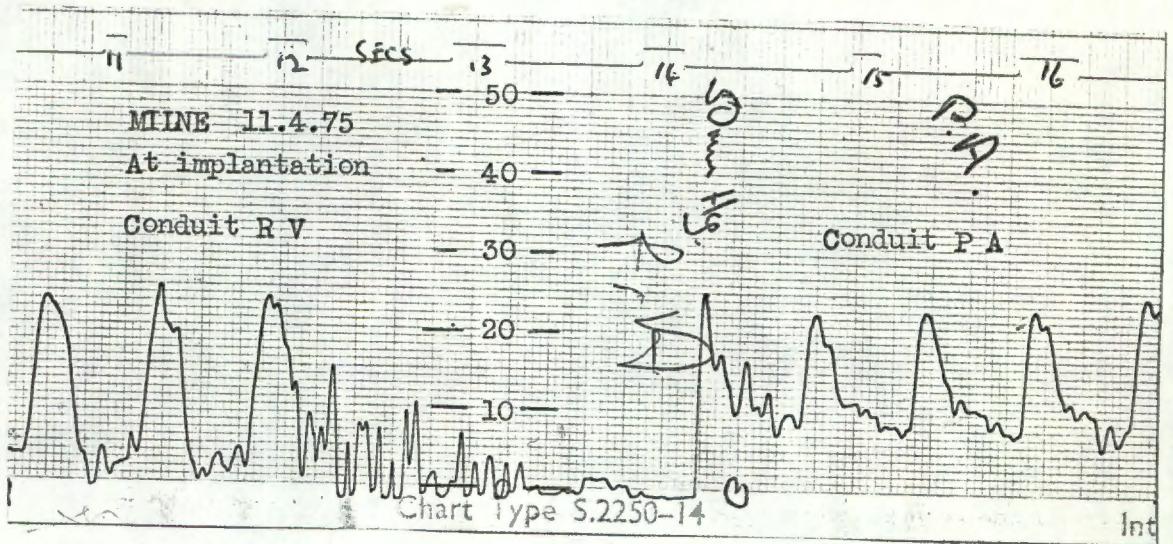
Figure 6c-9

Normal Function Retained in Non-Viable Valve



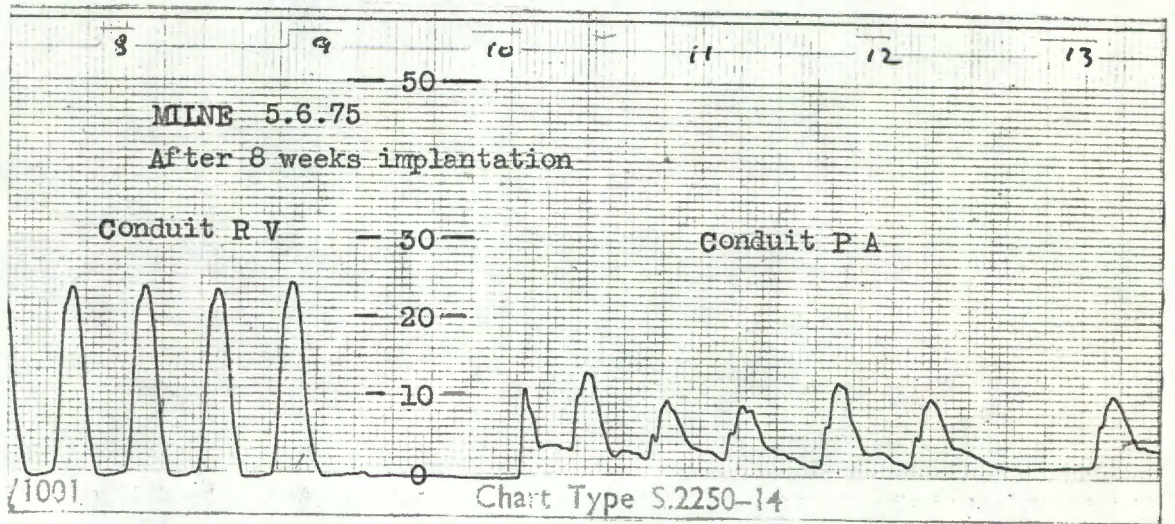
SIMBA 12.6.75 Non-viable Valve implanted 8 weeks
 Pressure scale 0 - 100 mm Hg
 Paper Speed 10 mm/sec
 Pressure measured in Host Right Ventricle (R V)
 Conduit Right Ventricle (R V)
 and Conduit Pulmonary Artery (P A)

Figure 6c-10



MILNE 11.4.75 Viable valve at time of implantation
Conduit R V 24/0 Conduit P A 23/7
Conduit valve is competent.

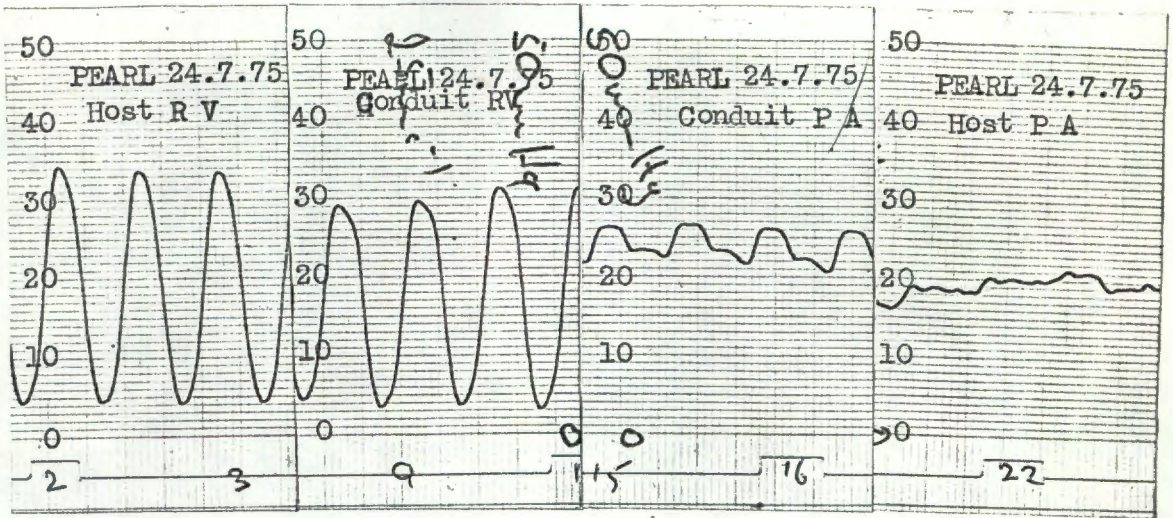
Viable Valve - Normal Function at implantation



MILNE 5.6.75 Viable valve implanted 8 weeks
Conduit R V 24/0 Conduit P A 12/1
Conduit valve is now incompetent and has a gradient over it.

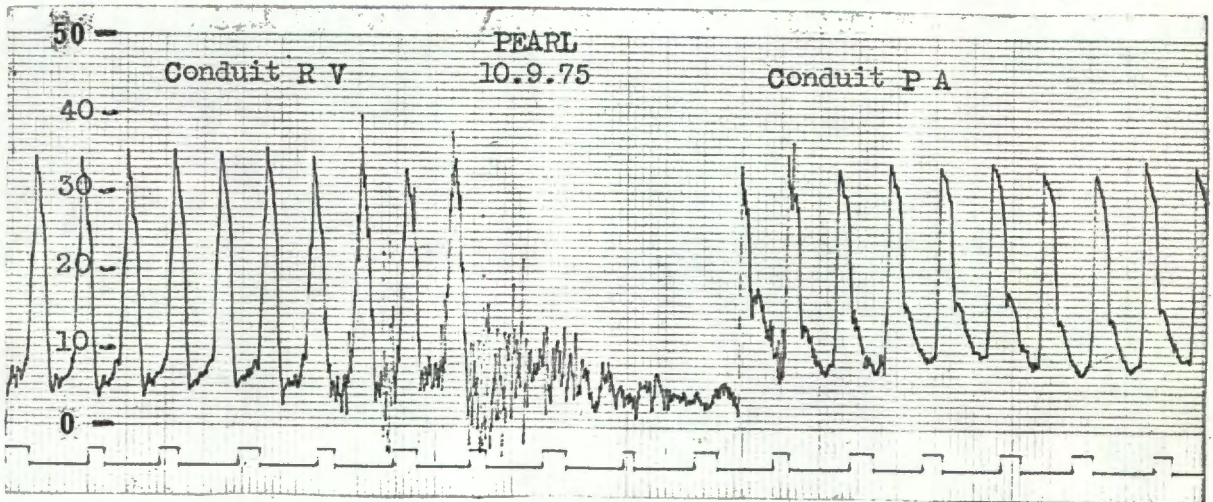
Same Valve - Loss of Function after 8 weeks

Figure 6c-11



PEARL 24.7.75 Viable valve at time of implantation
 Pressure scale 0 - 50 mm Hg Paper Speed 25 mm/sec
 Pressure measured in Host Right Ventricle (R V),
 Conduit Right Ventricle, Conduit Pulmonary Artery (P A)
 and Host Pulmonary Artery
 Conduit R V 30/3 Conduit P A 27/21
 Conduit valve competent.

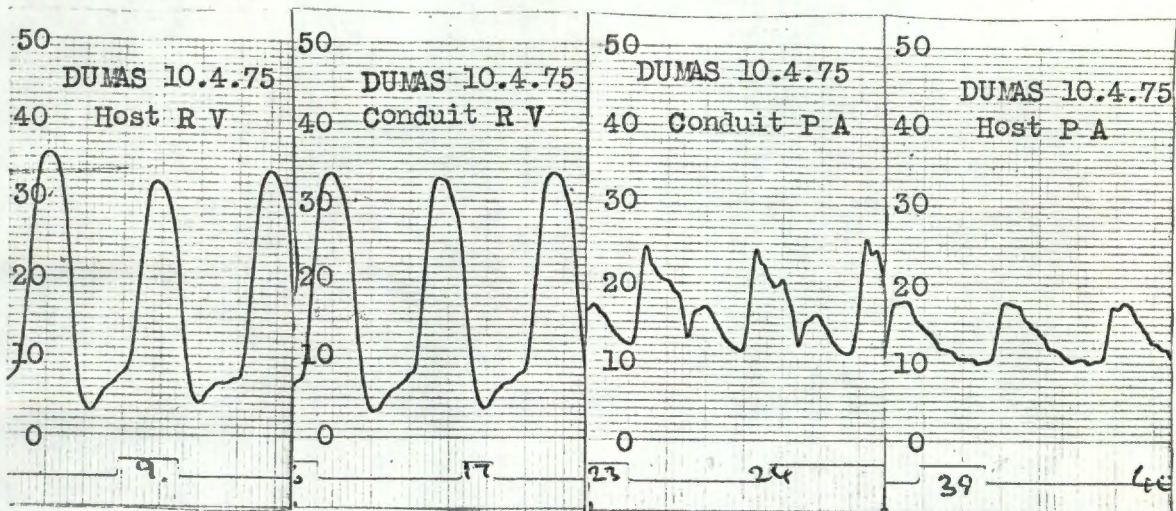
Viable Valve - Normal Function at implantation



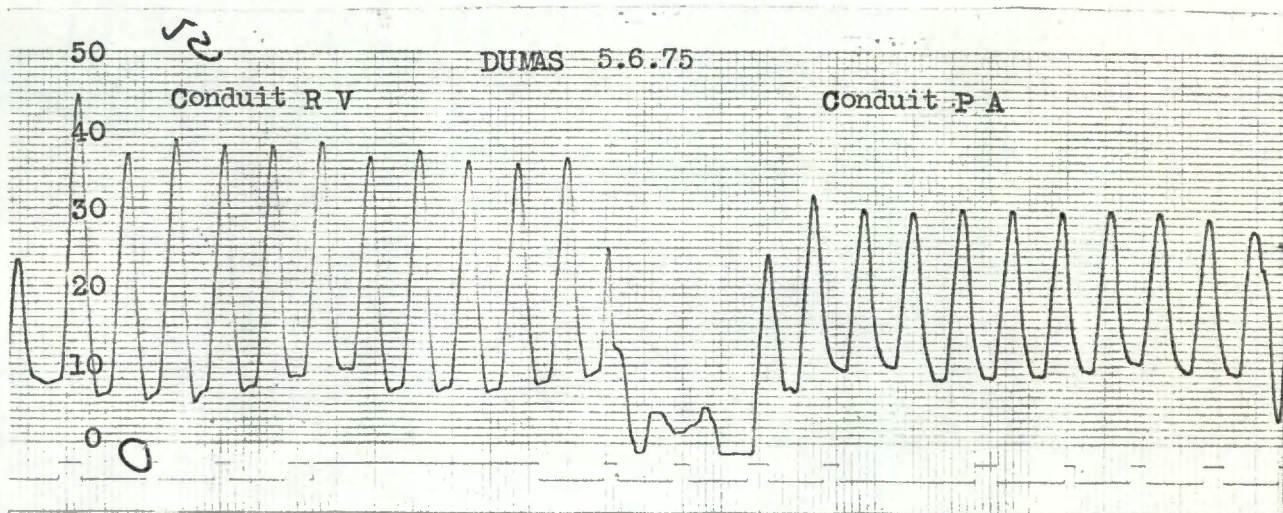
PEARL 10.9.75 Viable Valve implanted 8 weeks
 Pressure scale 0 - 50 mm Hg
 Paper Speed 10 mm/sec
 Pressure measured in Conduit Right Ventricle (R V)
 and Conduit Pulmonary Artery (P A)

Same Valve - Loss of Function after 8 weeks

Viabie Valve - Normal Function at implantation

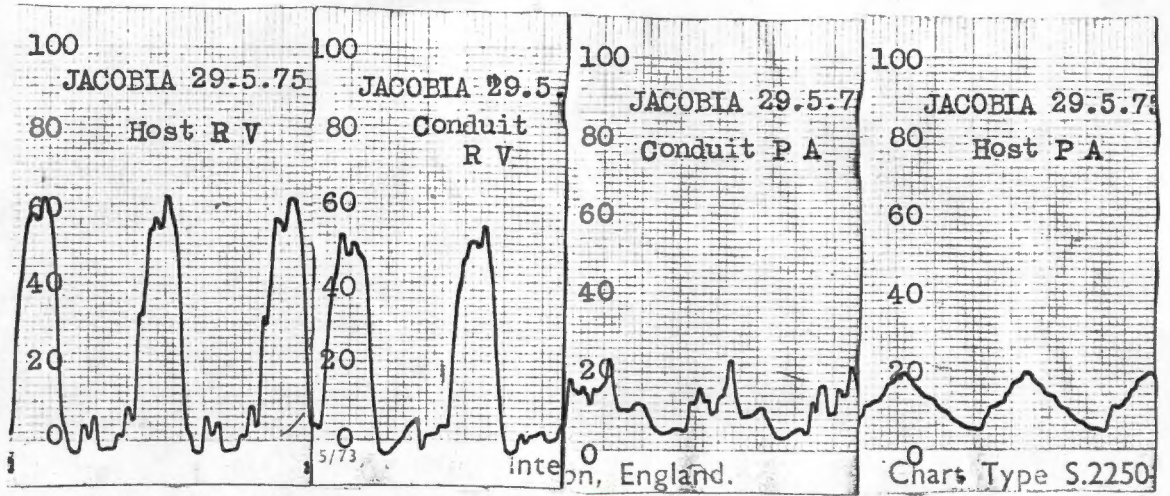


Dumas 10.4.75 Viable valve at time of implantation
 Pressure scale 0 - 50 mm Hg Paper Speed 25 mm/sec
 Pressure measured in Host Right Ventricle (R V), Conduit
 Right Ventricle, Conduit Pulmonary Artery (P A) and
 Host Pulmonary Artery.
 Conduit R V 33/3 Conduit P A 25/11
 Normal pulmonary valve gradient; competent valve



DUMAS 5.6.75 Viable Valve implanted 8 weeks
 Pressure scale 0 - 50 mm Hg
 Paper Speed 10 mm/sec
 Pressure measured in Conduit Right Ventricle (R V)
 and Conduit Pulmonary Artery (P A)

Same Valve - Loss of Function after 8 weeks



JACOBI A 29.5.75 Viable valve implanted 8 weeks
Conduit R V 55/0 Conduit P A 24/4

Loss of Function in Viable Valve
Figure 6c-14

2) Assessment of structural state of implanted allograft valve:

'Viable' valves implanted for 5 - 7 days ('short-term')

In this group of 6 all opened conduits appeared little changed from the time of their implantation. In one case there was a thin layer of thrombus on the myocardium of the conduit and in one sinus of the valve - the leaflets looking mildly reddened; but in all other cases the leaflets appeared normal. The anastomotic suture lines were satisfactory and the opening from the host to donor right ventricle and donor to host pulmonary artery was wide and unobstructed in each case. The myocardium of the conduit was very soft, and had in fact disrupted in 5 of the 6 in this group.

'Viable' valves implanted for 4 weeks ('intermediate')

The two conduits in this group appeared virtually normal, but the myocardium of the conduit was noticeably thinner and paler than the adjacent host myocardium, and the valve leaflets were thickened and opaque. The valves appeared to be haemodynamically competent and there was no appreciable shrinkage of the leaflets of the valves.

'Viable' valves implanted for 8 weeks ('long-term')

7 of the 8 opened conduits in this group showed gross shrinkage and retraction of the valve leaflets, such that valve competence was impossible (confirming the haemodynamic findings). The valve annulus was noticeably shrunken in these, and in 4 the proximal anastomosis seemed to have shrunk, although these changes did not appear severe enough to constitute haemodynamic obstructions. There was adherent thrombus present in 3 sinuses of one valve, and one sinus of another. The striking changes, however, were in the leaflets, which were grossly shrunken and deformed to the extent of being totally functionless.

Inexplicably, one of the 8 'viable' valves showed no shrinkage

or thickening and the valve was competent. There is no reason to doubt the viability of the implanted valve - it had been stored for only 1 day, and its control aortic valve showed prompt growth in tissue culture.

'Non-viable' valves implanted for 5 - 7 days ('short-term')

The appearances of the opened conduits in this group were the same as for the 'viable - short-term group'. 2 of the 6 in this group had disrupted the soft conduit myocardium. Thrombus was present in 1 sinus of the valves of 2 conduits.

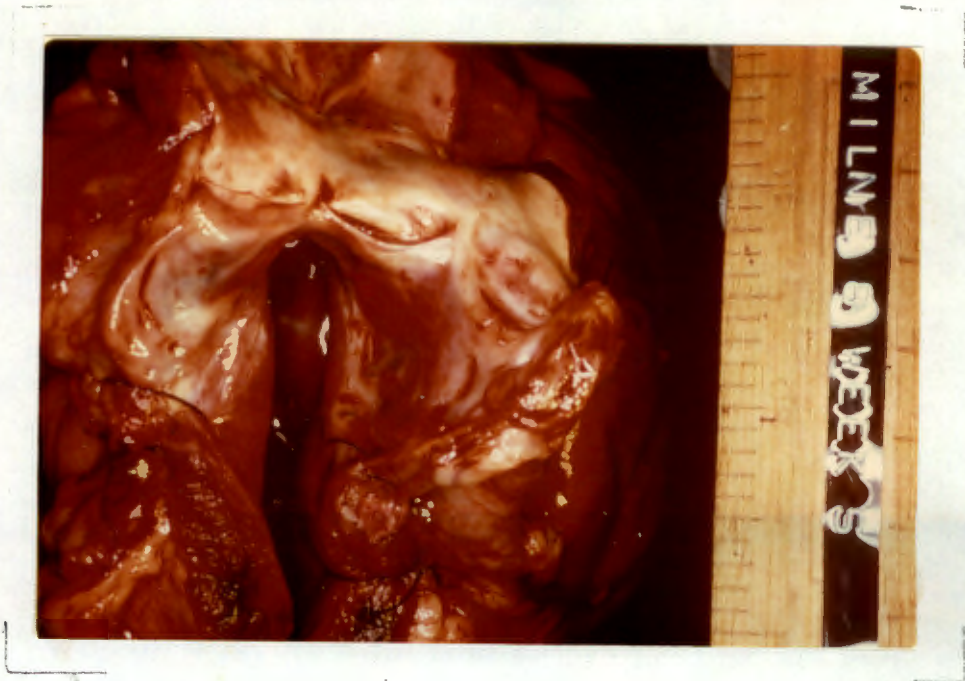'Non-viable' valves implanted for 8 weeks ('long-term')

All 6 opened conduits in this group showed valve leaflets of normal dimensions, that were clearly capable of normal function. The conduit muscle was pale and tough, as in the case of the 'viable' valves at the same stage, but the contrast in the appearance of the valve leaflets was striking. The anastomoses and the valve annulus appeared to be of normal dimensions. Adherent thrombus was present in one sinus of each of two valves.

Figure 6c-15 shows the appearance of the opened conduit with a 'viable' valve after 8 weeks of implantation. The shrinkage and retraction of the valve leaflets can be seen.

Figure 6c-16 shows an opened conduit with a 'non-viable' valve after 8 weeks of implantation. The leaflets are of normal size, but this is not clearly shown because of the need to avoid wiping or manipulating the leaflets in order to conserve sterility and avoid histological injury.

Figures 6c-17 to 6c-28 illustrate the changes and the striking differences between the 'viable' and 'non-viable' valves after 8 weeks of implantation more clearly. Figure 6c-19 is an example of a normal control canine pulmonary valve leaflet suspended in saline solution to allow the leaflet to lie free from the pulmonary



Conduit opened after 8 weeks implantation

Viable Valve

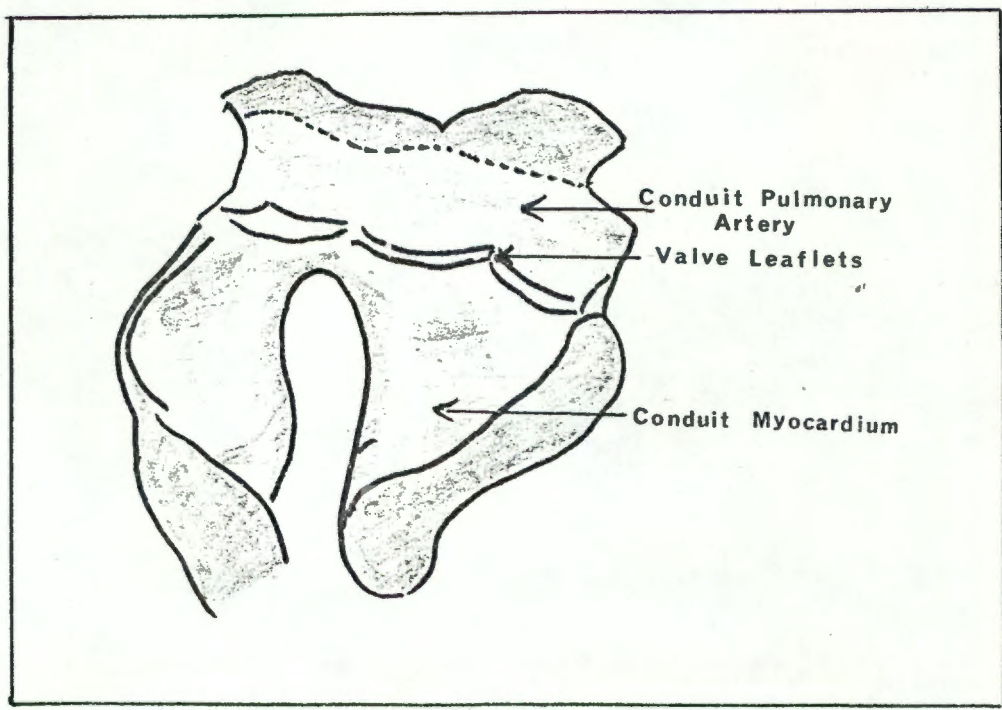
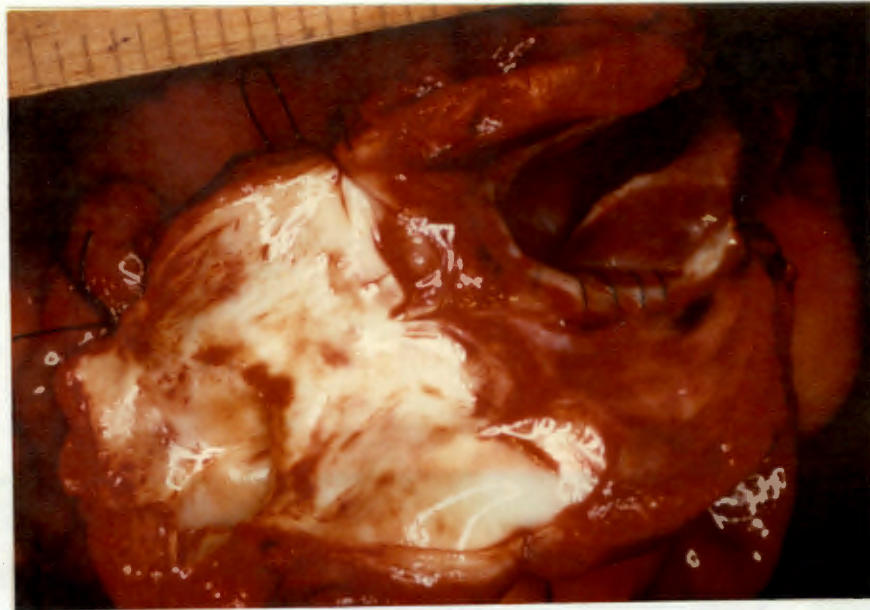

Figure 6c - 15



Conduit opened after 8 weeks implantation

Non-viable Valve

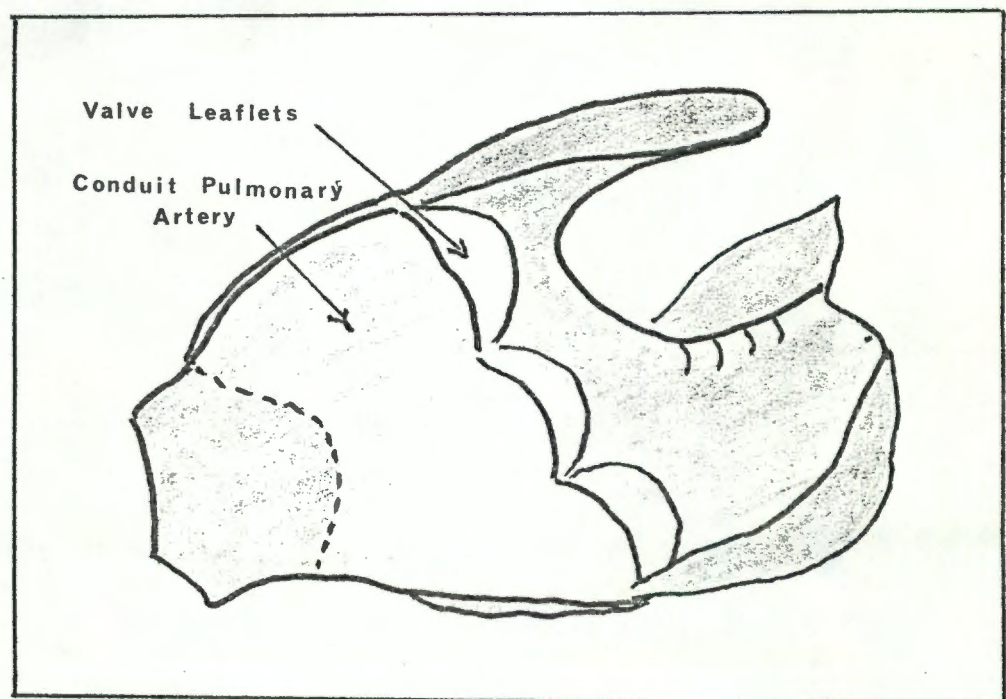


Figure 6c - 16

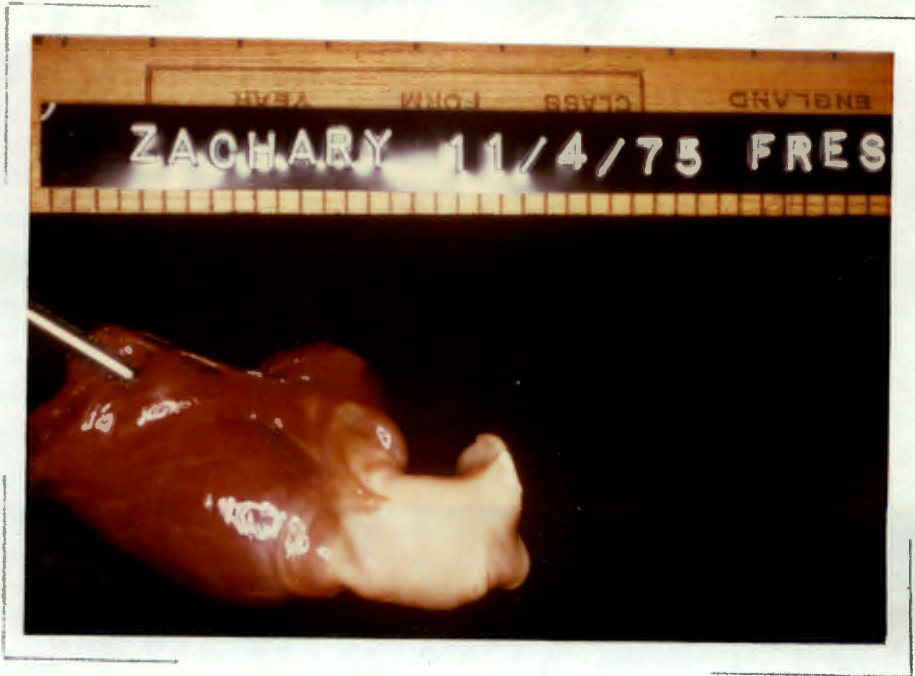

Figure 6c - 17

Conduit everted to show valve - prior to trimming of myocardium for implantation.

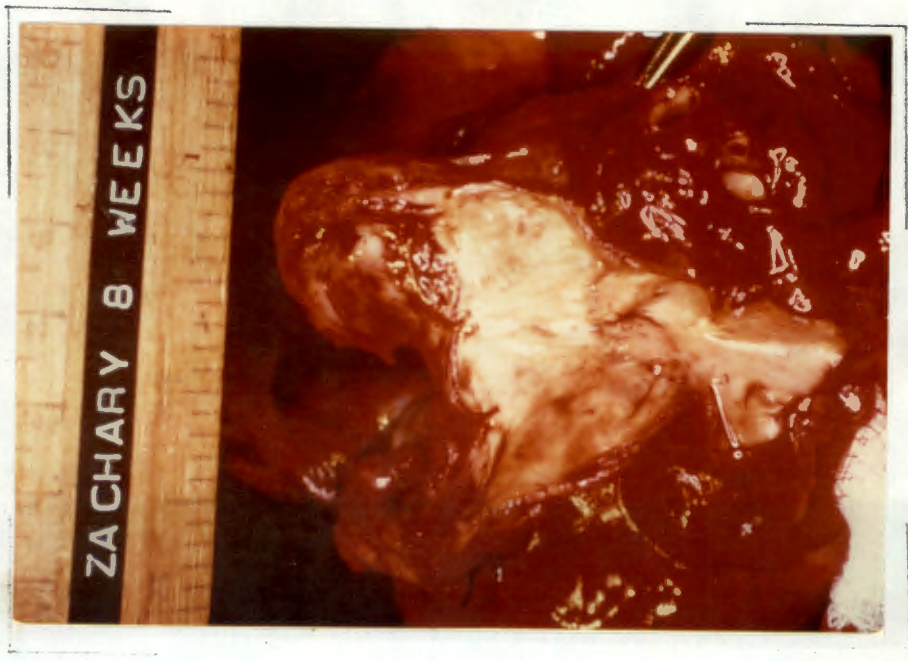

Figure 6c - 18

Same conduit - opened after 8 weeks implantation



Figure 6c - 19

Control Fresh Pulmonary Leaflet



Figure 6c - 20

Viable Leaflet after 8 weeks implantation



Figure 6c - 25

Control Fresh Pulmonary Leaflet

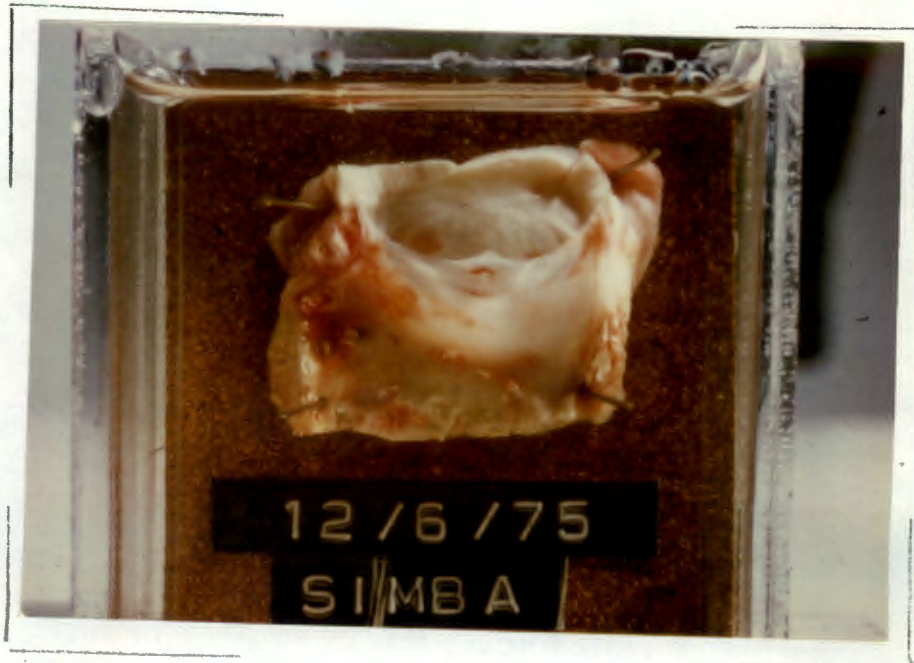

Figure 6c - 26

Non-viable Leaflet after 8 weeks implantation



Figure 6c - 27

Control Fresh Pulmonary Leaflet

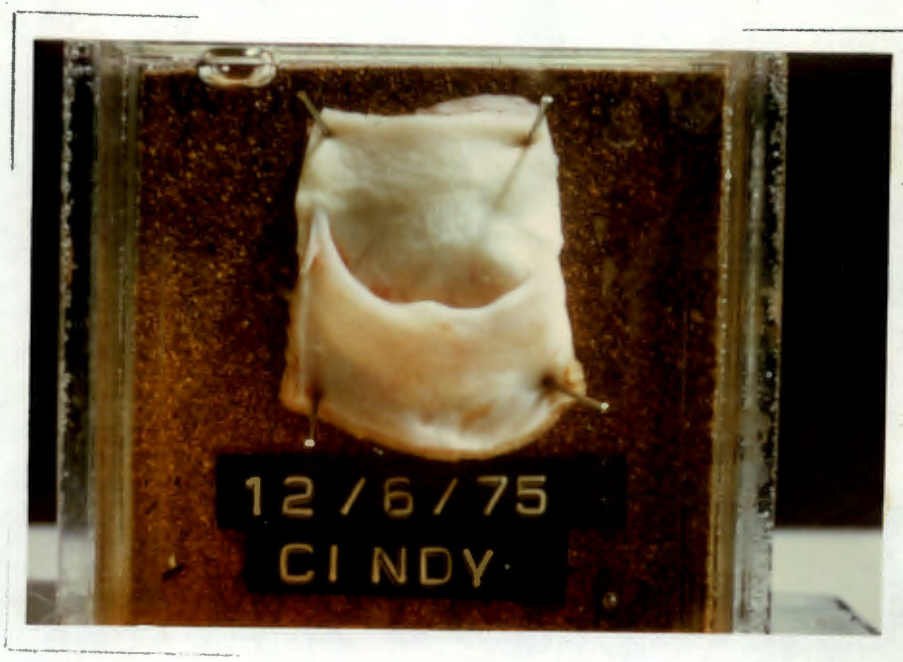

Figure 6c - 28

Non-viable leaflet after 8 weeks implantation

artery wall and show the delicate, thin, white, translucent nature of the normal leaflet. The 'viable' valves show shrinkage of the annulus (the leaflet commissures are closer together than in the controls from dogs of same weight), and the leaflet tissue is shrunken and retracted. The 'non-viable' leaflets are thicker and opaque, but of normal size.

Measurement of valve leaflet area:

As described in Section 6b one leaflet of each valve was measured to assess surface area. The leaflet chosen was the posterior one, and this was representative of the whole valve as all three leaflets showed similar changes in each case. As a control, the posterior pulmonary leaflet of a dog of same weight was chosen. Surface area was measured by drawing the leaflet outline onto graph paper.

As shown in Figure 6c-29 the shrinkage occurring in the 'viable' valve leaflets after 8 weeks is striking (with the sole exception of the valve already mentioned) - the mean surface area for this group was 48 sq. mm. and the controls 114 sq. mm.

By contrast the mean surface area of the 'non-viable' valve leaflets was 115 sq. mm. and the controls 107 sq. mm.

These figures clearly demonstrate the shrinkage of the 'viable' leaflets, and the normal size of the 'non-viable' leaflets at 8 weeks, but they imply a degree of precision that is not entirely warranted in view of the difficulty (explained in Section 6b) of judging exactly where the leaflet ended and the pulmonary artery began.

VALVE LEAFLET SURFACE AREA (sq.mm)



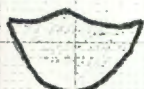


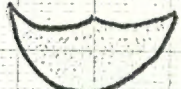
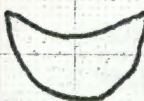







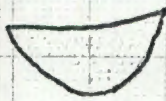







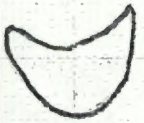

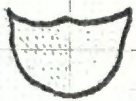

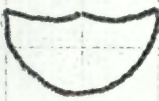

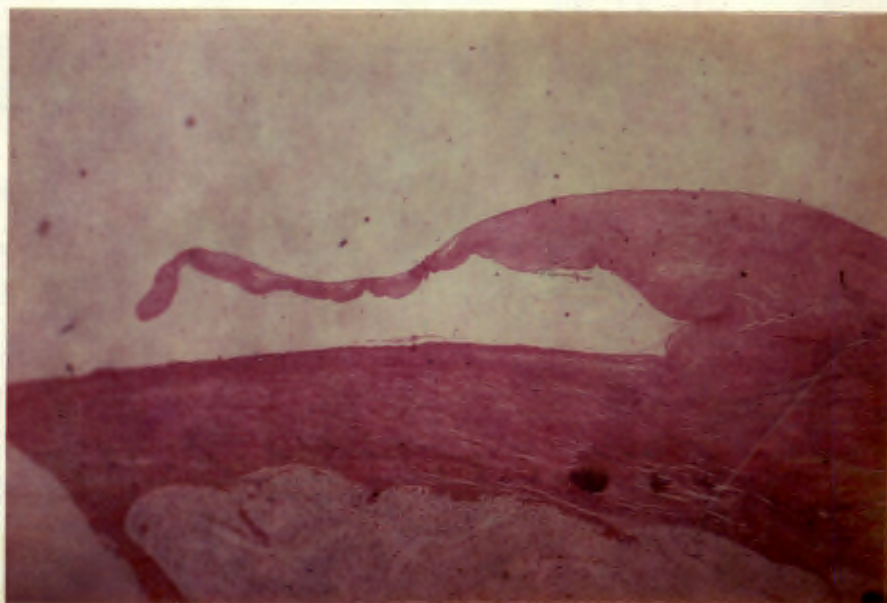
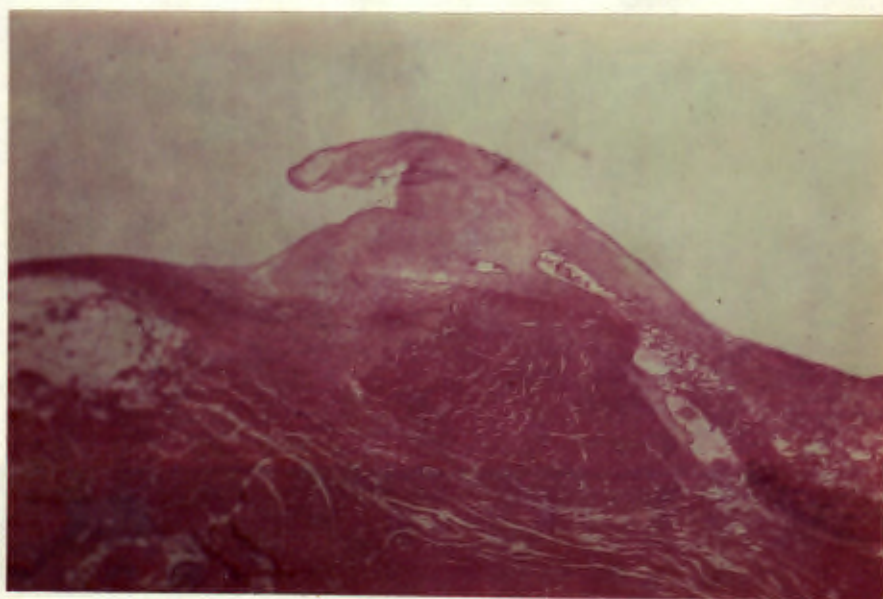<u>Controls</u>	<u>Area</u>	<u>Viabile Leaflets</u>	<u>Area</u>	<u>Controls</u>	<u>Area</u>	<u>Non-viable Leaflets</u>	<u>Area</u>
	113		27				
	108		30		113		116
	112		40		130		139
	95		28		109		102
	112		61		100		131
	124		27		85		99
	112		146		103		100
	135		21				
<u>MEAN</u>	114 sq.mm.		48 sq.mm.		107 sq.mm.		115 sq.mm.
<p>Highly significant difference p < 0.01</p>				<p>Difference not significant p > 0.5</p>			

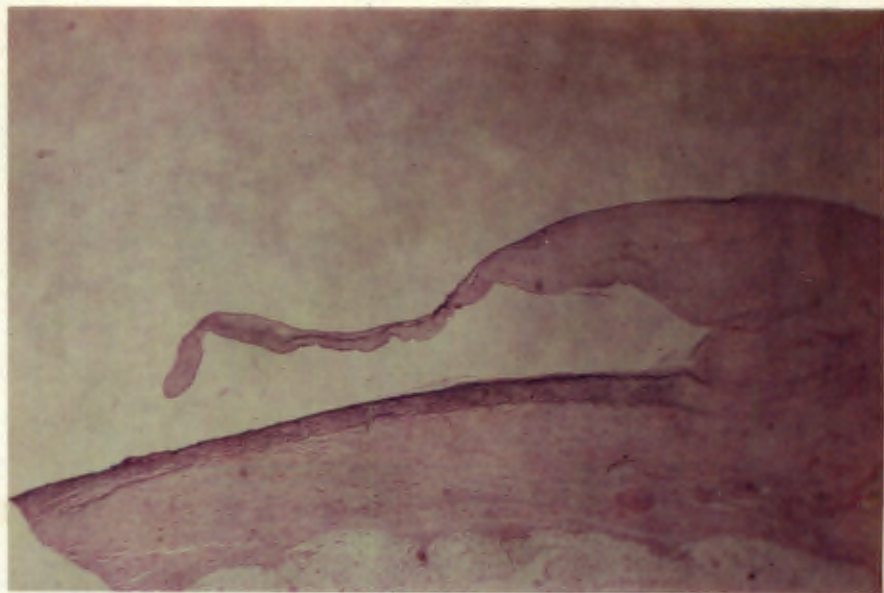Figure 6c - 29



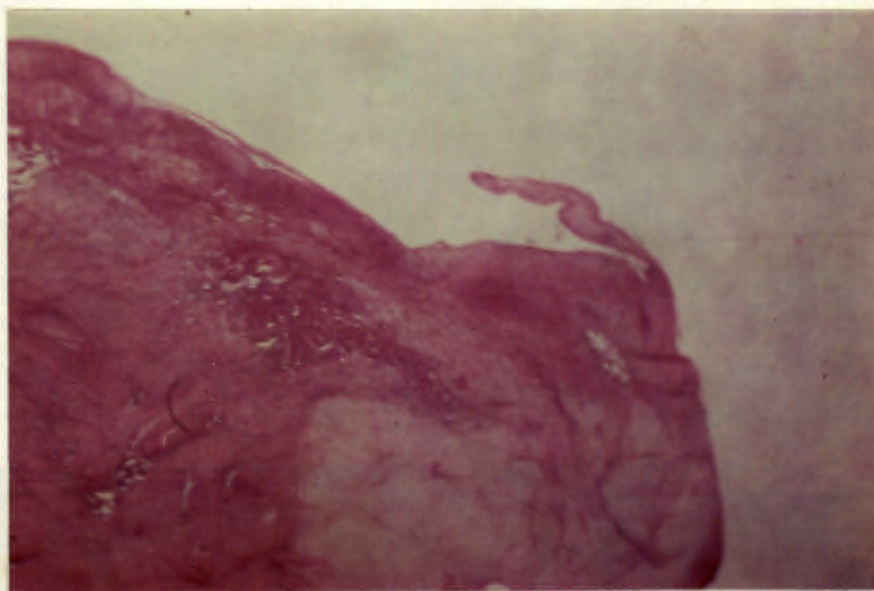
"Non-Viable" allograft valve after 8 weeks implantation
- showing normal dimensions (H & E x 10)



"Viable" allograft valve after 8 weeks implantation
- showing gross shrinkage (H & E x 10)



"Non-Viable" allograft valve after 8 weeks implantation
- showing normal dimensions (Elastica x 10)



"Viable" allograft valve after 8 weeks implantation
- gross shrinkage again evident (H & E x 10)

3) Assessment of microscopic appearance of valves

Normal canine pulmonary valve leaflet:

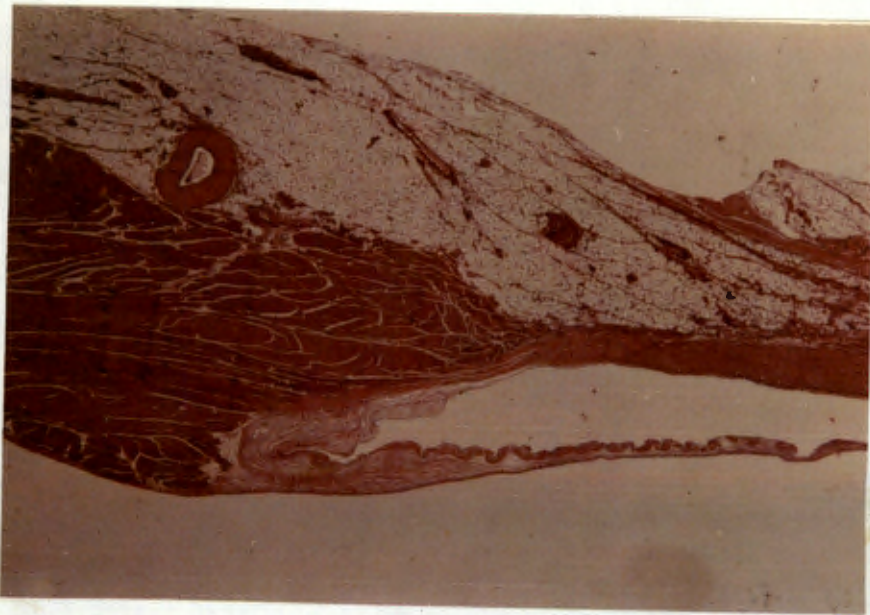
The histological appearances of a normal canine pulmonary valve leaflet are shown in Figures 6c-30 to 6c-36.

All the photographs illustrating histological appearances are of sections cut through the middle of the leaflets as described in Section 6b (see Figure 6b-11).

The valve leaflet consists of a framework of collagen and elastic fibres in a mucopolysaccharide ground substance, bounded at the surfaces by an endothelium. Interspersed between the fibres, and fairly uniformly distributed throughout the leaflet, are the connective tissue cells or fibrocytes (when young and active, or when growing in tissue culture these same cells are known as fibroblasts).

In the sections illustrated the collagen fibres are seen as a densely packed and rather convoluted layer on the pulmonary arterial side of the leaflet (the 'holding face') and a flatter, less densely packed layer on the ventricular side of the leaflet (the 'deforming face'). The fibrocyte nuclei are typically spindle shaped, but depending on the plane of the section through the nucleus may appear round or oval.

As shown in Figures 6c-31 and 6c-35 the elastic fibres are closely packed on the ventricular side of the leaflet, with a particularly dense layer just below the endothelium of the ventricular surface. A similar, but thinner, layer is present on the pulmonary arterial side of the leaflet. These subendothelial concentrations of elastic tissue, well seen on the elastic-stained slides, identify the outline of the original leaflet and demarcate new tissue laid down on the surface after implantation.



H+E

x 10

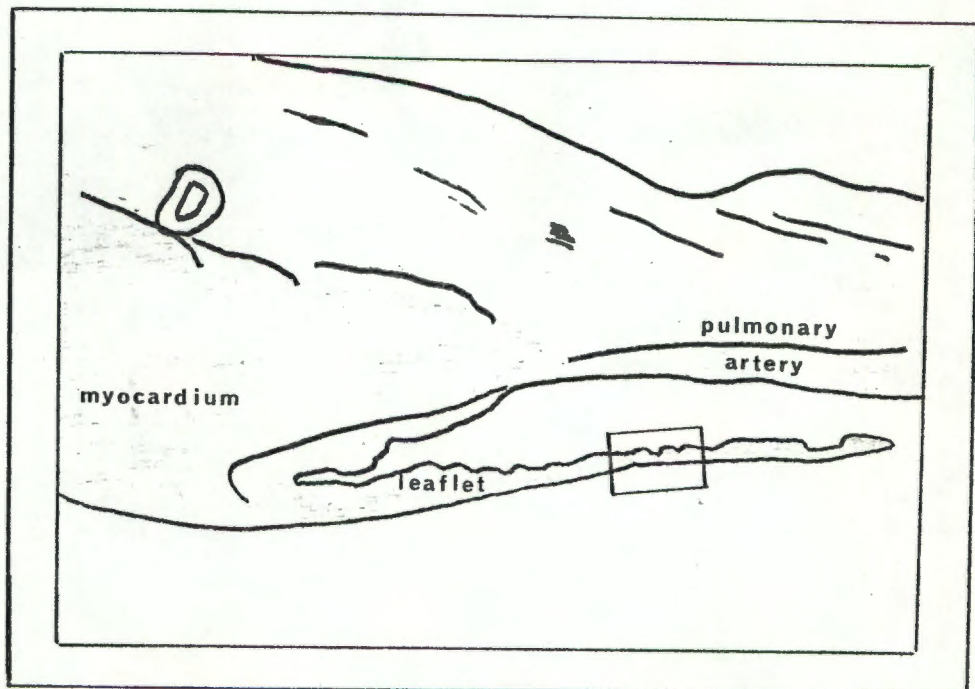


FIGURE 6c - 30

Normal canine pulmonary valve leaflet

The rectangle shown on the leaflet defines
the field covered in Figure 6c - 32



Figure 6c - 31

Normal canine pulmonary valve leaflet

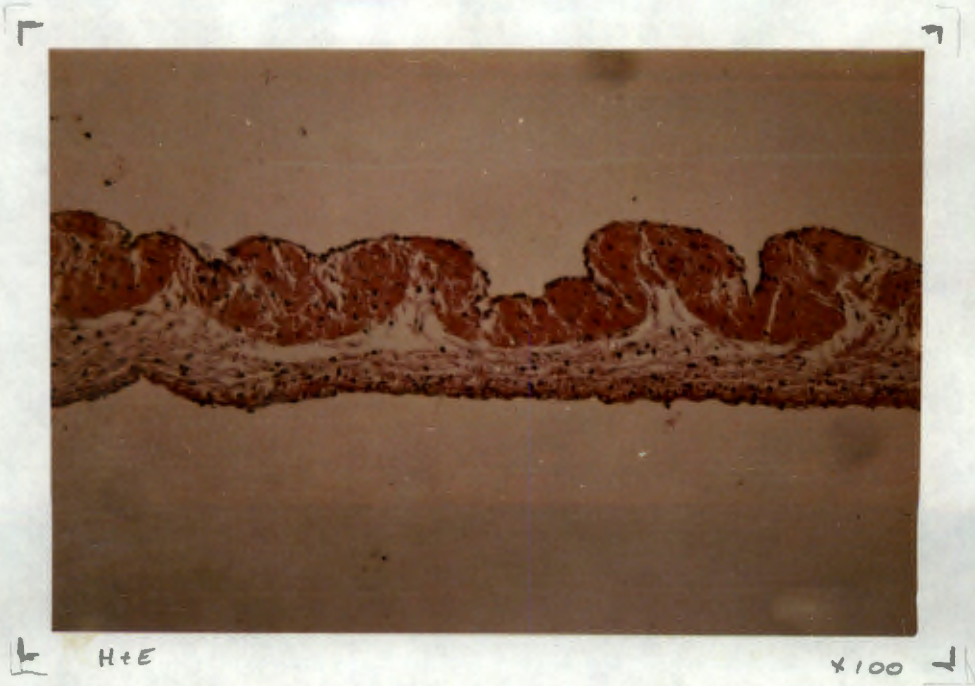


Figure 6c - 32

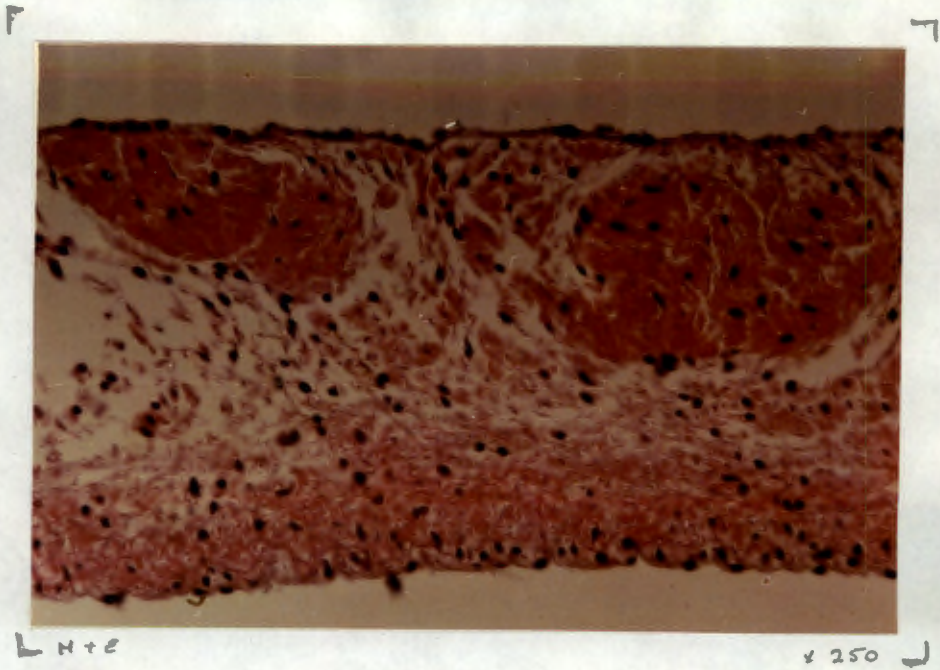


Figure 6c - 33

Normal canine pulmonary valve leaflet

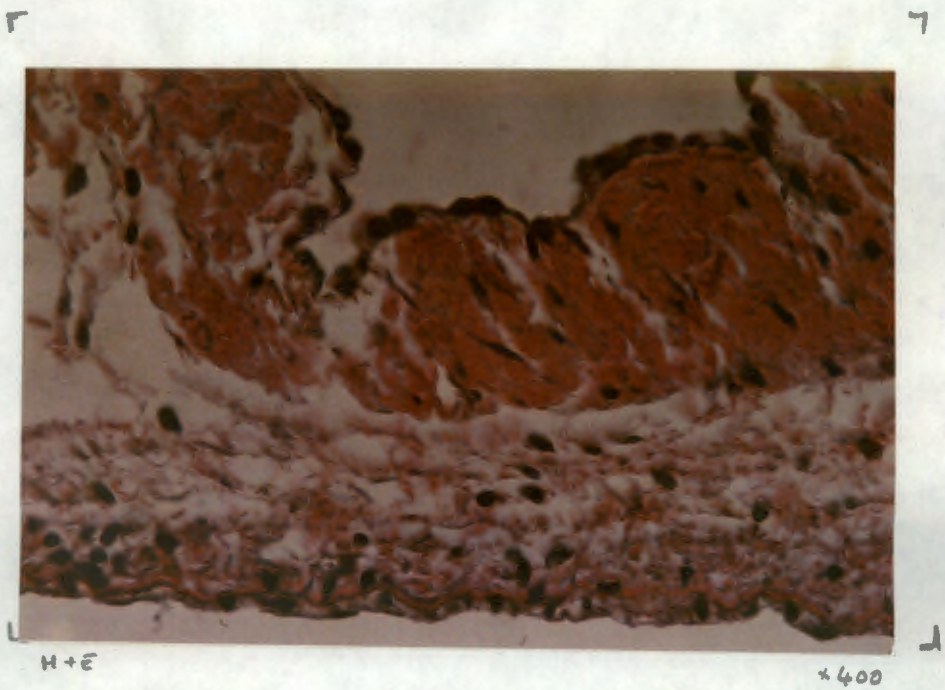
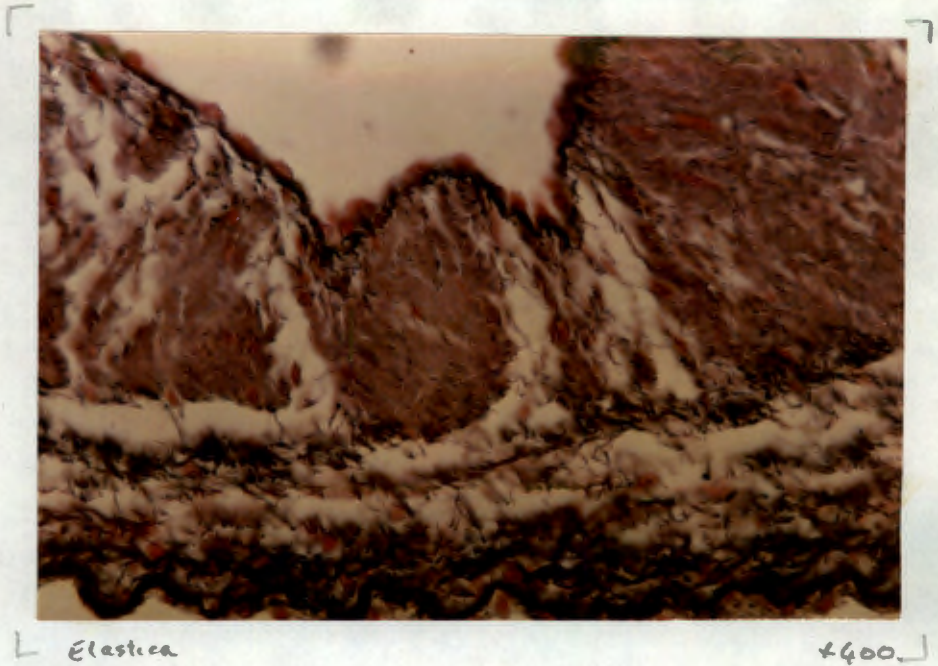


Figure 6c - 34

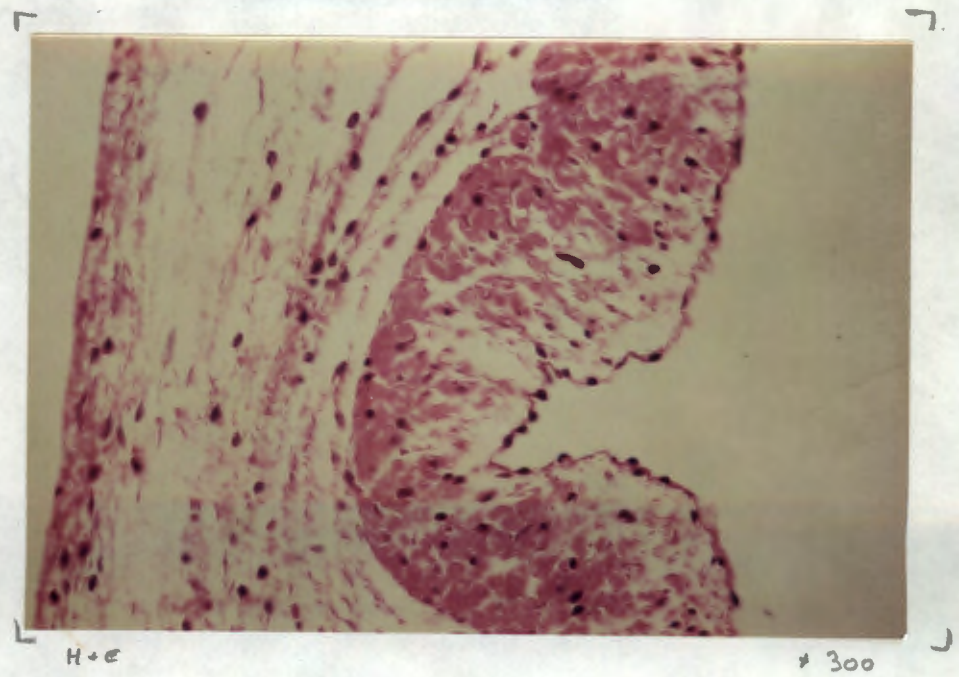


Elastica

x400

Figure 6c - 35

Normal canine pulmonary valve leaflet



H+E

x300

Figure 6c - 36

Canine pulmonary valve leaflets following sterilisation and storage

After 4 weeks storage in Antibiotic-nutrient medium at 4°C the leaflets showed some separation of collagen fibres, thought to be due to oedema of the leaflets. The fibrocytes appear normal (Figure 6c-37).

After 8 weeks storage in Antibiotic-nutrient medium at 4°C the leaflets showed further separation of fibres and some of the fibrocytes show early nuclear degeneration (Figure 6c-38).

Viable leaflets after 5 - 7 days of implantation ('short term')

All the leaflets in this group of 6 valves were slightly thickened, and considerably more cellular, than the control leaflets (Figures 6c-39 to 6c-44).

The increased cellularity was due to the presence of inflammatory cells, mostly macrophages and plasma cells, but polymorphs and red cells were also present. The cellularity was most marked near the valve surfaces. Endothelium was not visible over most of the leaflets, being obscured or covered by inflammatory cells.

Fibrocytes were identifiable within the leaflets, and their appearance was normal.

The elastic stain (Figure 6c-42) showed that separation of the elastic fibres had occurred, and also that layers of inflammatory cells were present on the leaflet surfaces.

Viable leaflets after 4 weeks of implantation ('intermediate')

The leaflets of the 2 valves in this group showed uniform changes throughout the leaflets. Considerable thickening was present due to the presence of inflammatory cellular tissue on

both surfaces of the leaflet - approximately doubling the leaflet thickness. The cells in this tissue were mainly macrophages, with a few polymorphs, lymphocytes and plasma cells.

The basic architecture of the original valve leaflet was fairly well preserved, but the elastic stain showed the elastic fibres to be separated. The leaflet itself showed considerable cellularity - due to the presence of macrophages and fibrocytes, but also a few polymorphs and lymphocytes. There were a large number of degenerating cells with pyknotic nuclei scattered throughout the leaflets.

An endothelium was present over the distal $1/3$ of the ventricular surface of one leaflet, but as it was situated on the surface of a layer of inflammatory tissue laid down on the original leaflet it was presumably not the original endothelium of the leaflet.

Figures 6c-45 and 6c-46 show a section of one such leaflet.

Viable leaflets after 8 weeks of implantation ('long-term')

The leaflets of 7 of the 8 valves in this group showed variable degrees of shrinkage from tip to base of leaflet, with slight thickening due to the presence of additional tissue on the surfaces (usually cell-free tissue, but occasionally containing plasma cells).

The leaflets of all 8 valves were essentially cell-free, but three showed 'islands' of considerable cellularity causing considerable local thickening. The nodule at the tip of the leaflet illustrated in Figures 6c-47 and 6c-48 is one such cellular island. However, the vast majority of the leaflet area in the sections containing these cellular islands was uniformly cell-free and featureless.

Figure 6c-49, 6c-50 and 6c-51 could well illustrate the histological appearance of any of the 8 viable valves at this stage.

Occasional inflammatory cells (mostly macrophages) were present on the leaflet surface, and endothelium was absent.

Thus it was clear that the viable leaflets showed an increase in cellularity after one week of implantation, largely due to the presence of an inflammatory reaction. This was still present at 4 weeks, but at this stage there was evidence of considerable cell destruction. By 8 weeks the leaflets were virtually devoid of cells, the islands of persistent cellularity seen in 3 of the 8 valves being in no way representative of the bulk of leaflet tissue at this stage.

Non-viable leaflets after 5 - 7 days of implantation ('short-term')

The leaflets of all 6 valves in this group were of normal dimensions, with little alteration in basic architecture and virtually no inflammatory tissue on the surfaces.

The leaflets were uniformly devoid of cells, very occasional pyknotic nuclei being the only evidence of previous cellularity.

Figures 6c-55 to 6c-60 show the amorphous, cell-free appearance of these leaflets at this time. This contrasts with the increased cellularity of the viable valves at the same period of implantation (Figures 6c-41 and 6c-43).

One of the valves illustrated shows thrombus in the sinus of the valve. Endothelium was not present on any leaflet.

Non-viable leaflets after 8 weeks of implantation ('long-term')

The leaflets of all 6 valves in this group were of near normal dimensions, slight thickening being present toward the base of the leaflets.

Figures 6c-61 to 6c-65 illustrate the typical cell-free appearance with preservation of basic leaflet architecture seen in valves of this group. Endothelium is not present, and there is little inflammatory tissue on the leaflet surface.

Thus, in non-viable leaflets the cells have totally disappeared after 1 week of implantation, and the inflammatory response present in viable valves at this time is absent. The structural damage to the leaflets, evident at 8 weeks in viable valves, is not seen in non-viable valves.

Areas of Cellularity in 'long-term' viable valves:

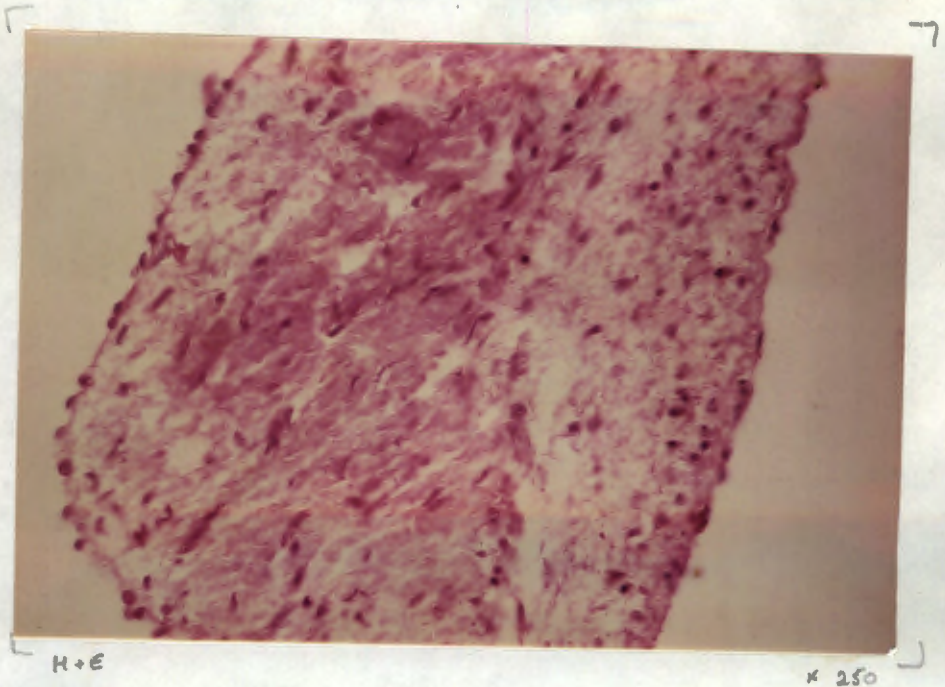
In view of the fact that persistence of cellularity in leaflets of viable donor valves has been reported by Mohri et al. (1967a, 1967b and 1968); Buch et al. (1971); and Kosek et al. (1969) it is of interest to note the presence of cells in small 'islands' that were seen in 3 viable leaflets after 8 weeks of implantation.

Figures 6c-65 and 6c-66 show such areas of cellularity at the tip of a leaflet; however the totally cell-free nature of the rest of the leaflet is shown in Figure 6c-67, and this was the appearance of more than 80% of this section.

Figure 6c-68 shows another example of such a cellular area at the tip of a leaflet; Figure 6c-69 shows the cell-free nature of the majority of this leaflet.

The third example of such a cellular area is seen in Figure 6c-47.

Many of the cells in these areas are typical fibrocytes; the rest are mononuclear cells with more rounded nuclei which could be either macrophages, or the 'dysplastic' fibroblasts described by Mohri et al. (1967a) and Angell et al. (1973a).

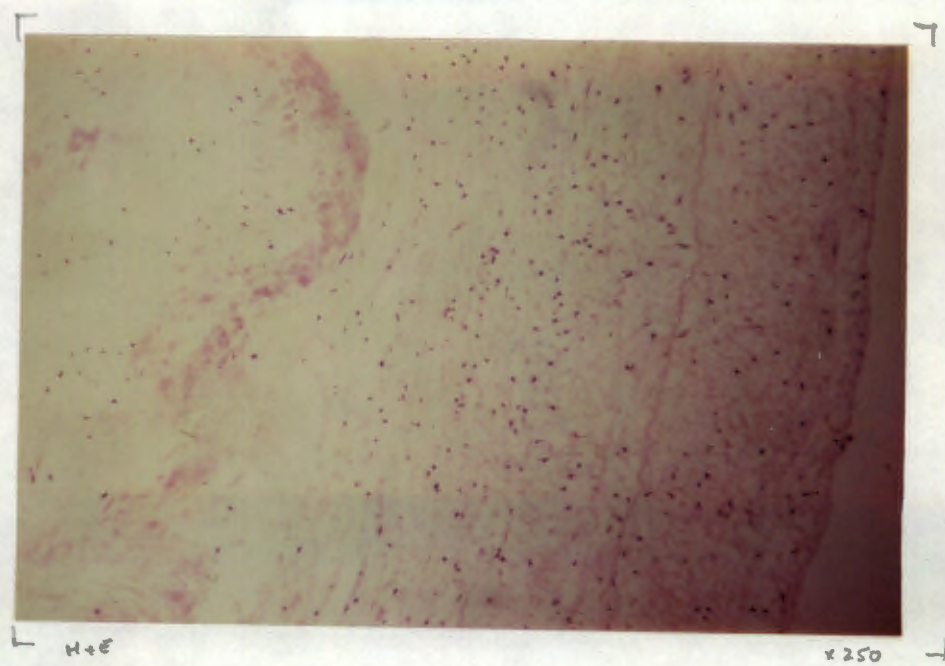


H+E

x 250

Figure 6c - 37

After 4 weeks storage in Antibiotic-nutrient medium

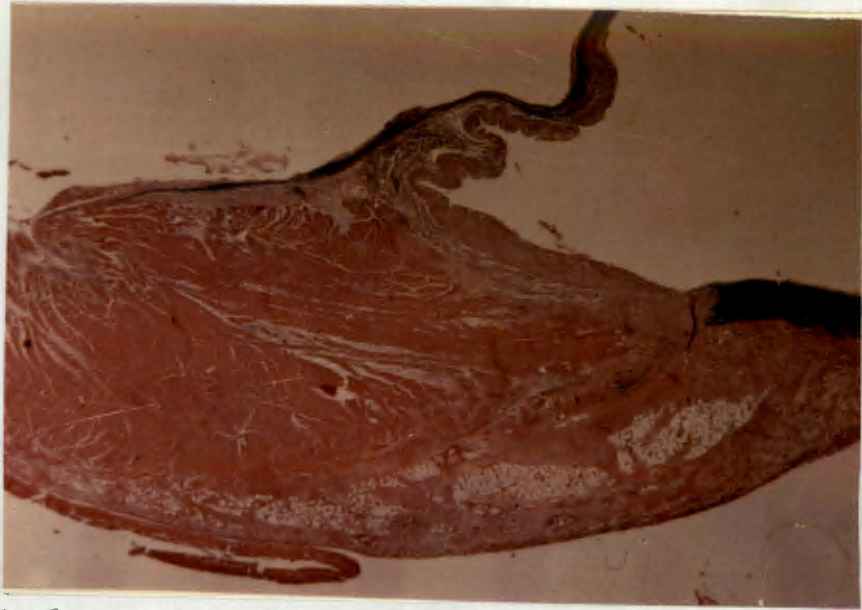


H+E

x 250

Figure 6c - 38

After 8 weeks storage in Antibiotic-nutrient medium

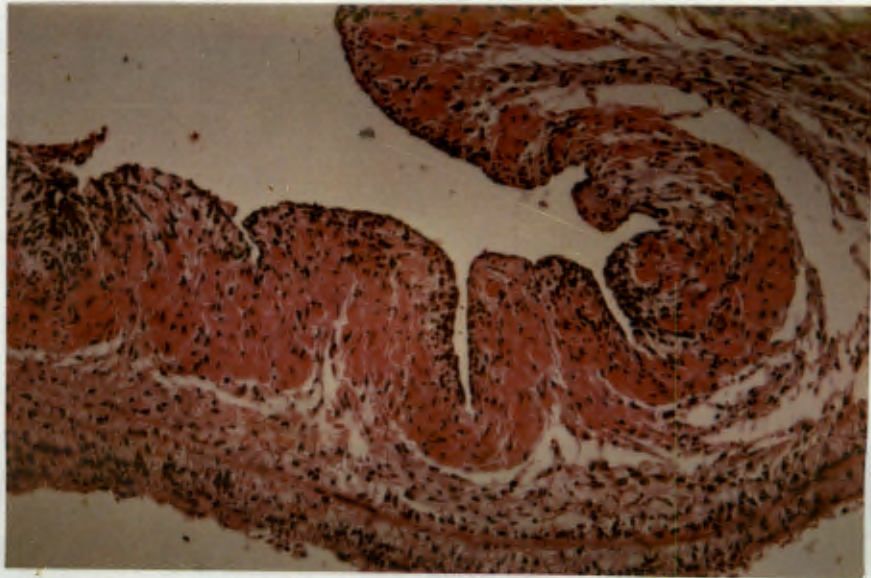


Elastic

x 10

Figure 6c - 39

Viable Leaflet implanted 1 week ('Cody')



H+E

x 100

Figure 6c - 40

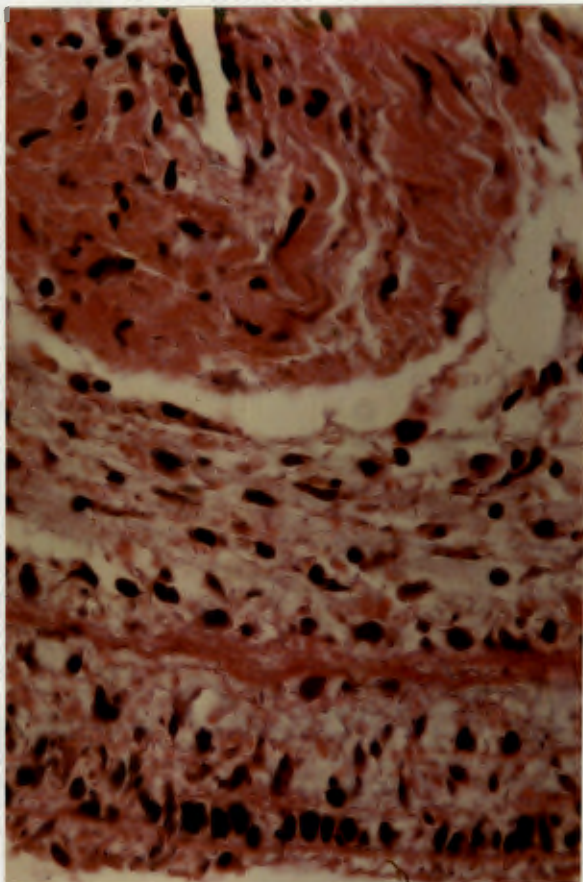


Figure
6c - 41

H+E X400

Viable Leaflet implanted 1 week ('Cody')

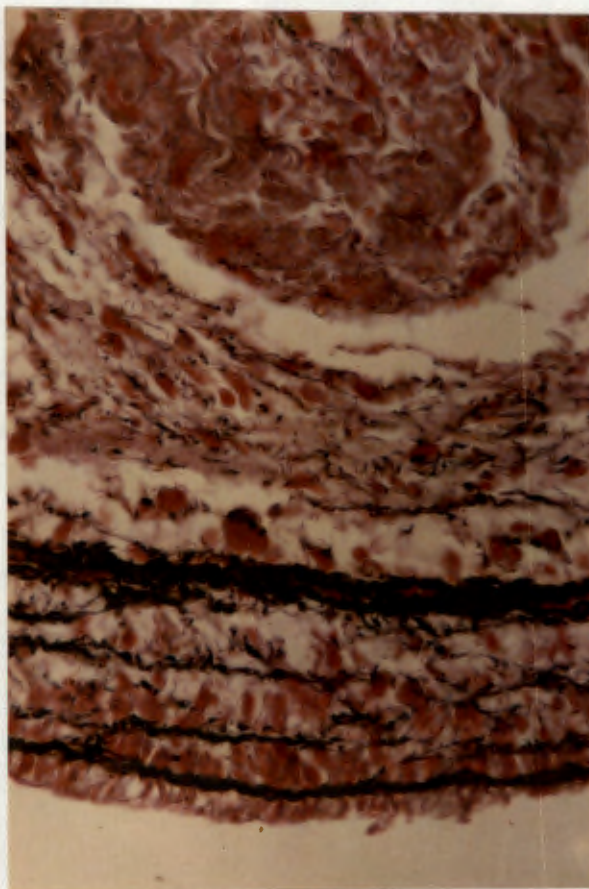


Figure
6c - 42

Elastica X400

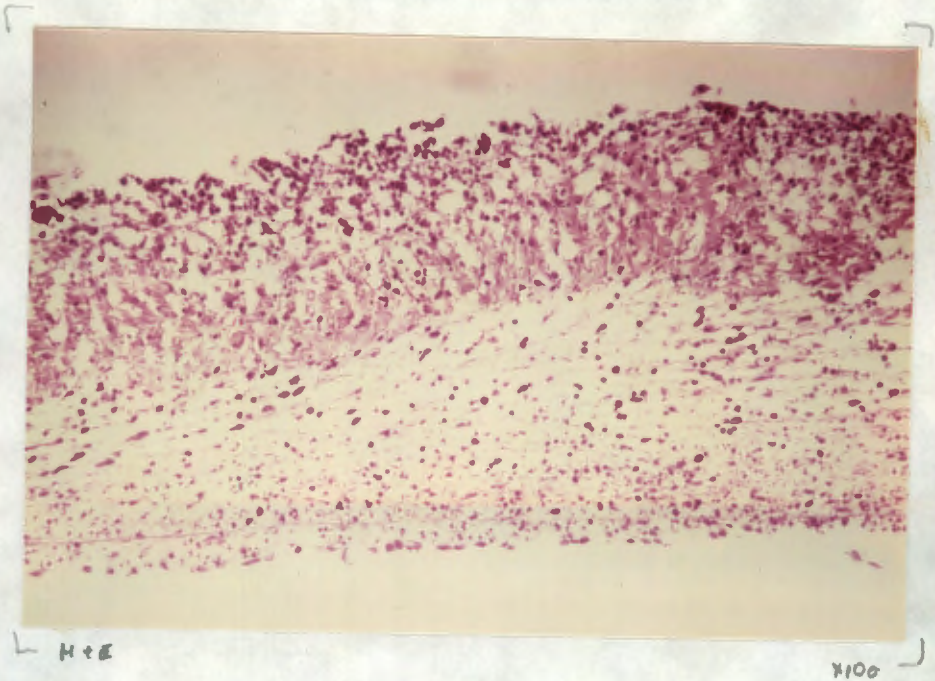


Figure 6c - 43

Viable Leaflet implanted 1 week ('Bobby')

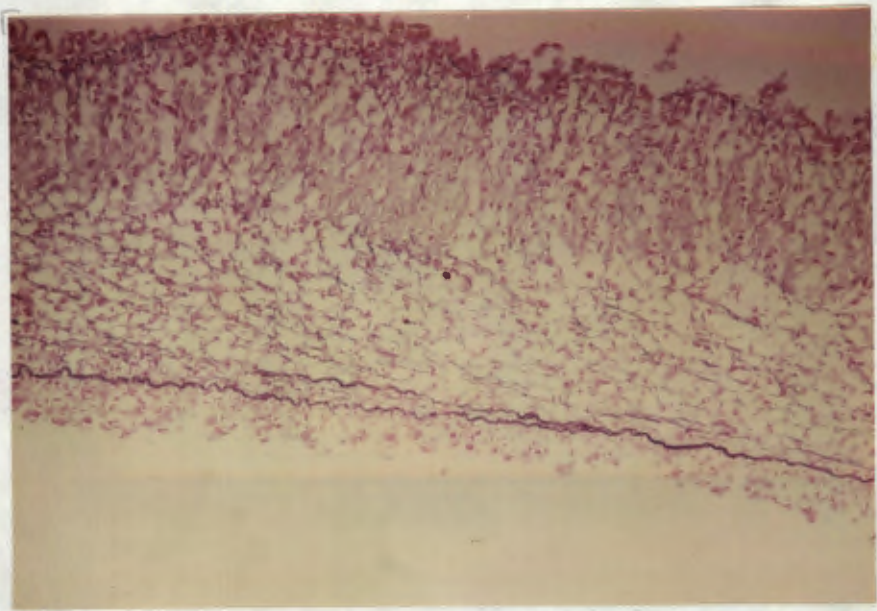


Figure 6c - 44

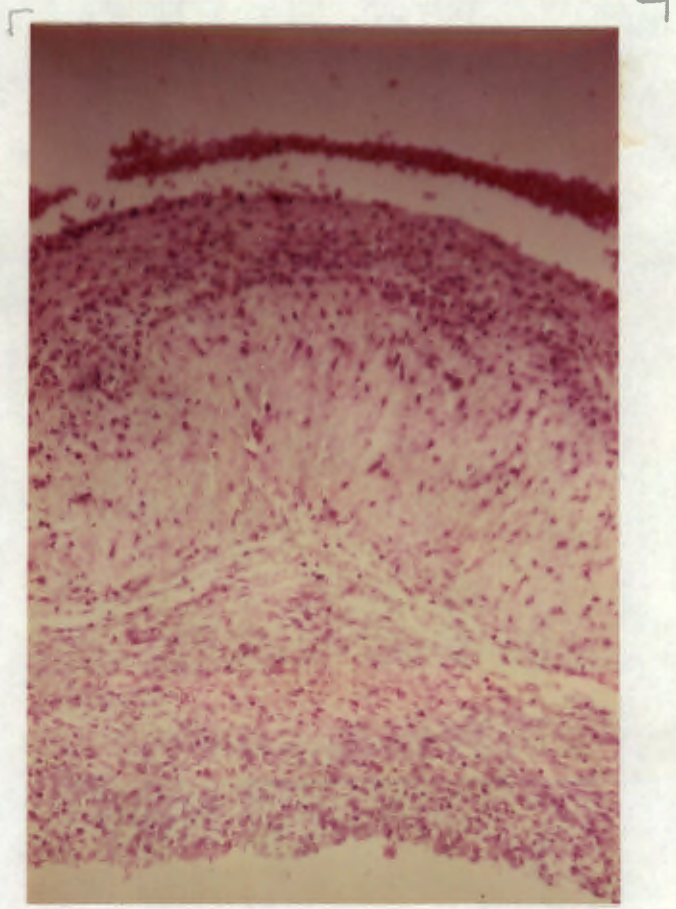


Figure
6c - 45

H+E X 125

Viable Leaflet implanted 4 weeks ('Liam')

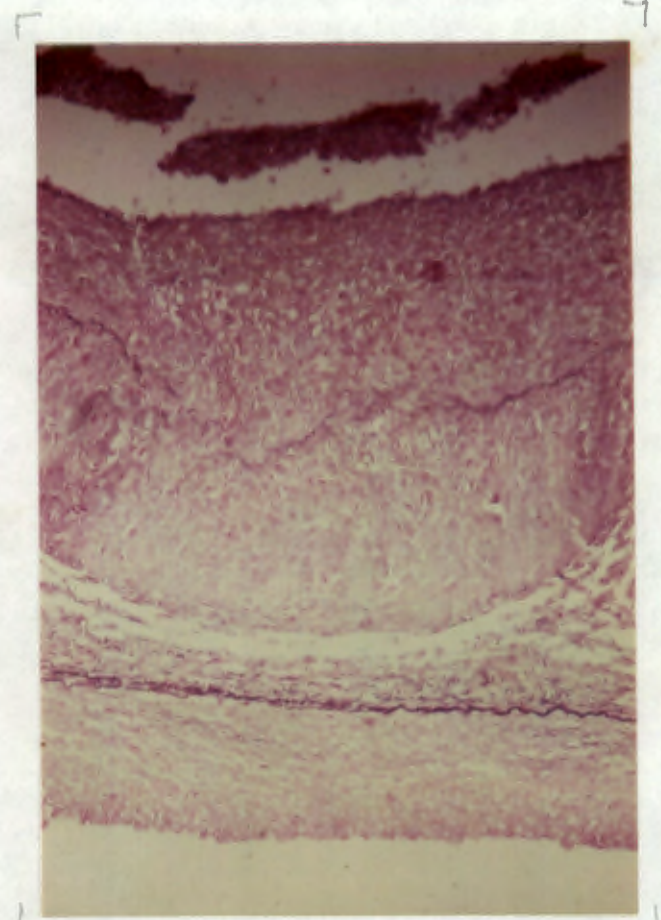


Figure
6c - 46

Elastic X 125

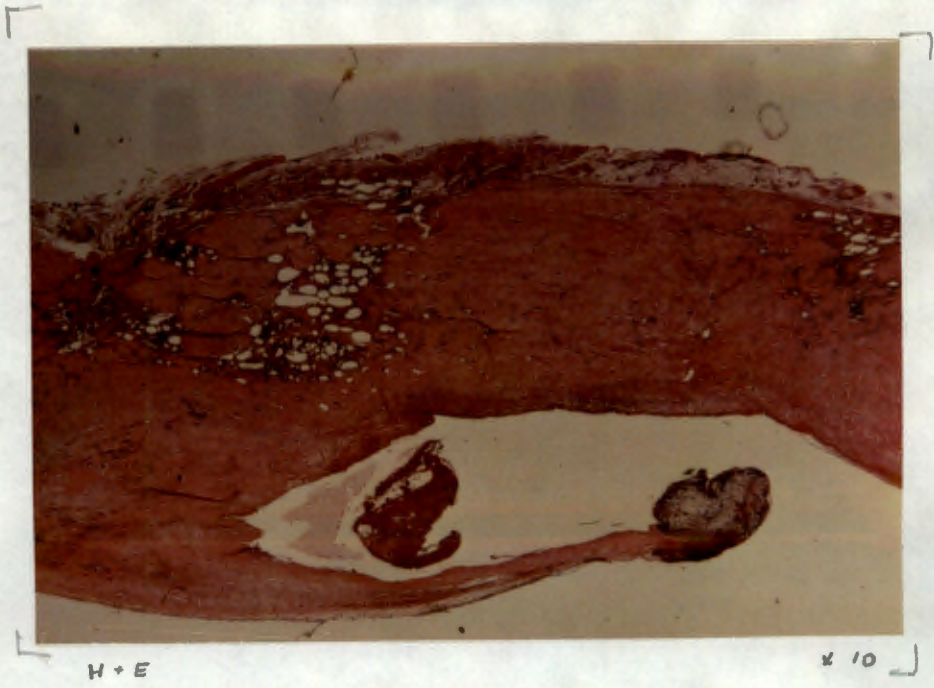

Figure 6c - 47

Viable Leaflet implanted 8 weeks ('Dumas')

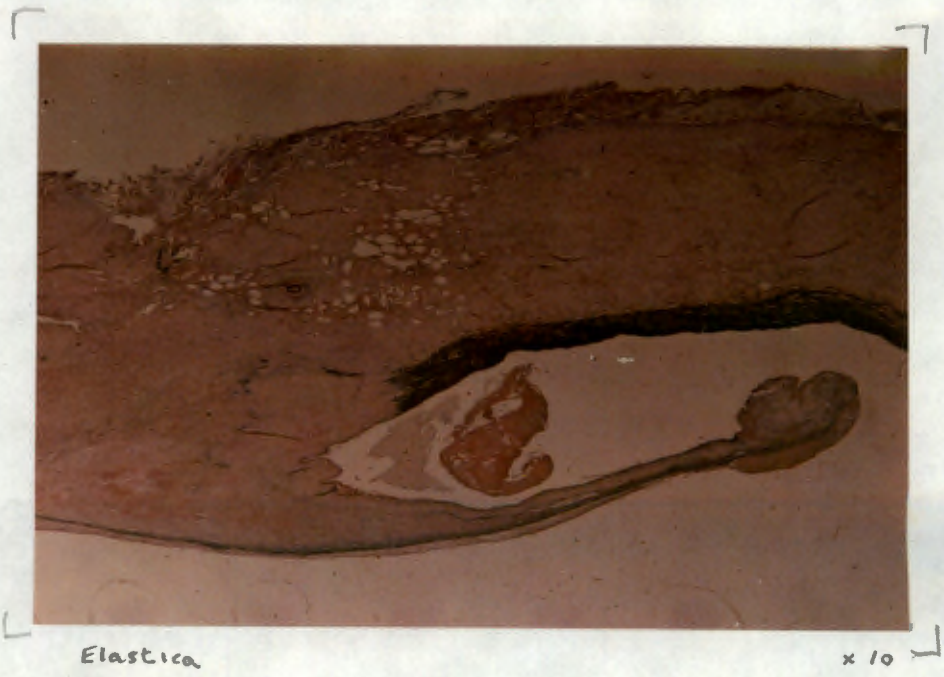

Figure 6c - 48

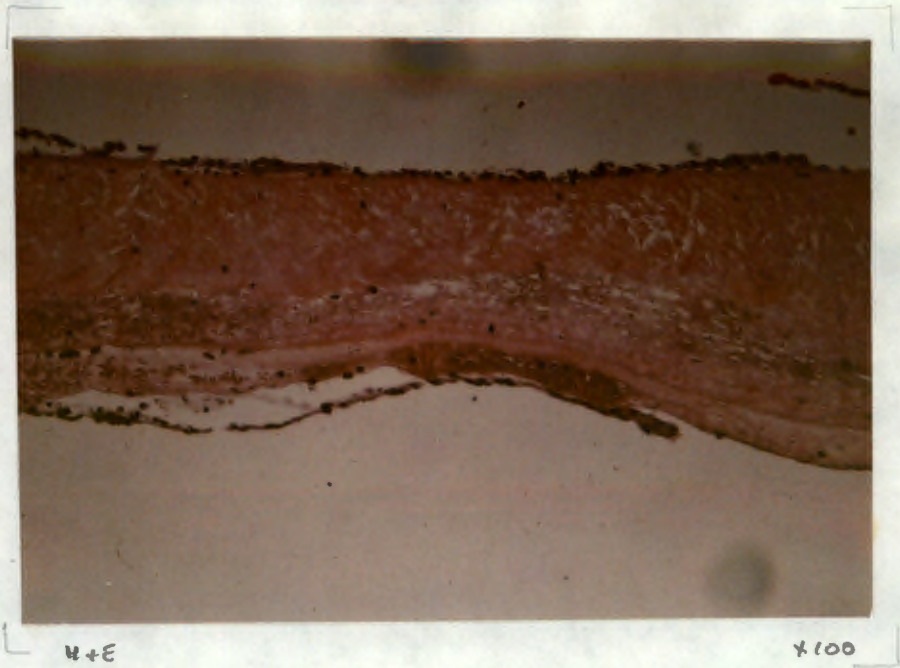


Figure 6c - 49

Viable Leaflet implanted 8 weeks ('Dumas')

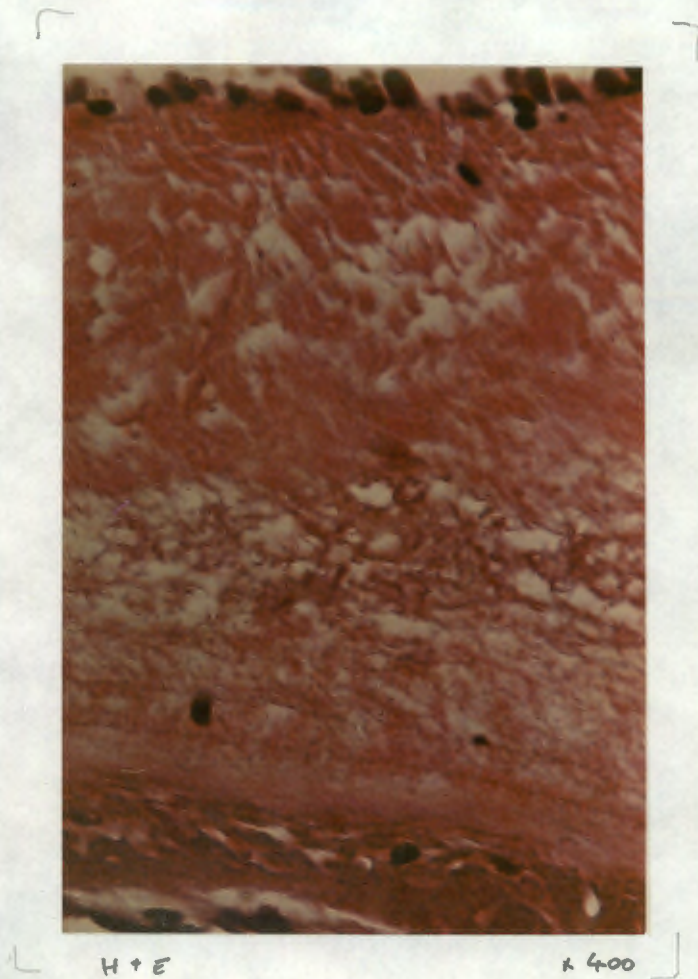


Figure 6c - 50

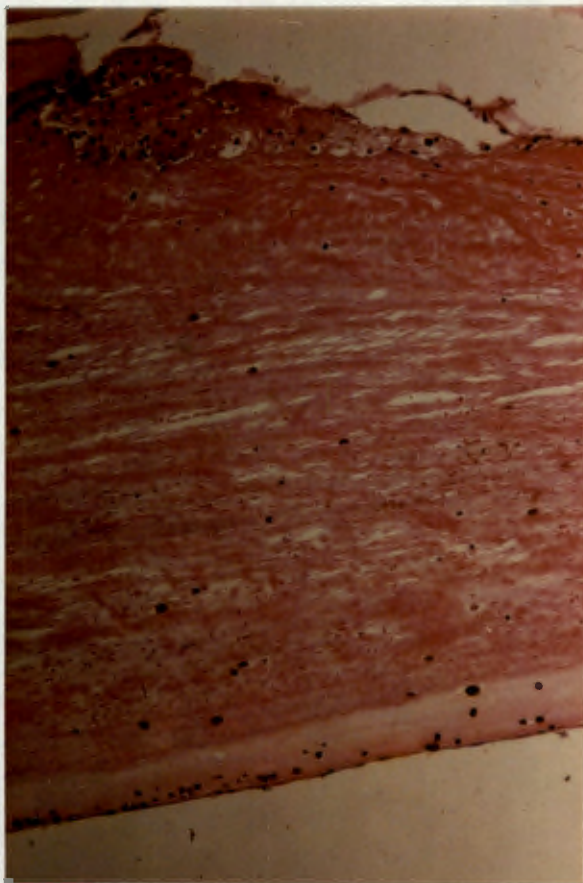


Figure
6c - 51

H+E x100

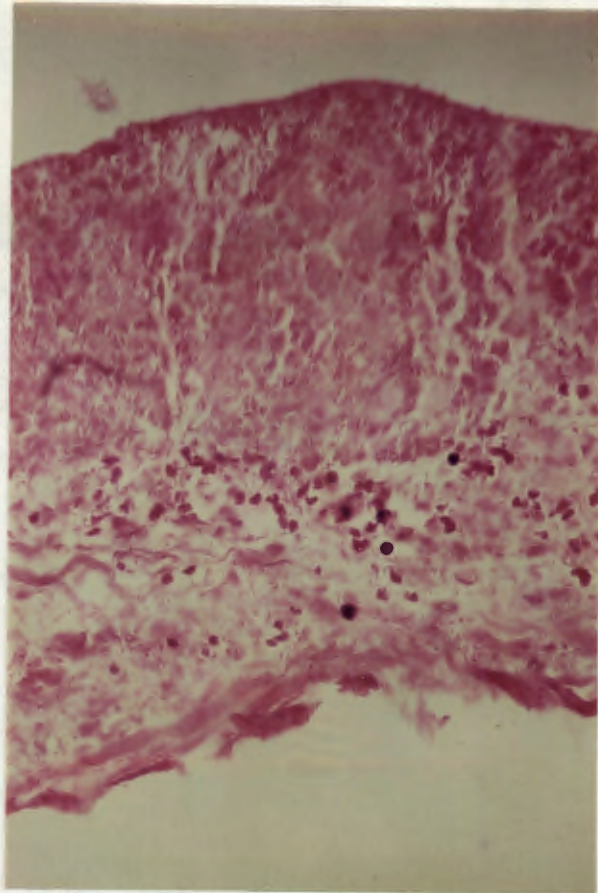
Viable Leaflet implanted 8 weeks ('Dumas')



Figure
6c - 52

Elastica

x400

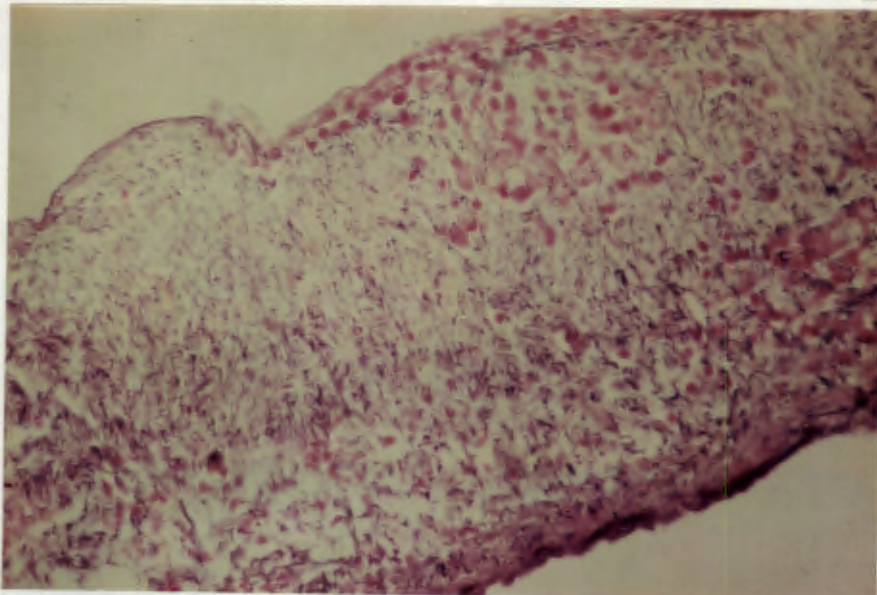


H + E

x 250

Figure 6c - 53

Viable Leaflet implanted 8 weeks ('Jacobia')



Elastica

x 250

Figure 6c - 54

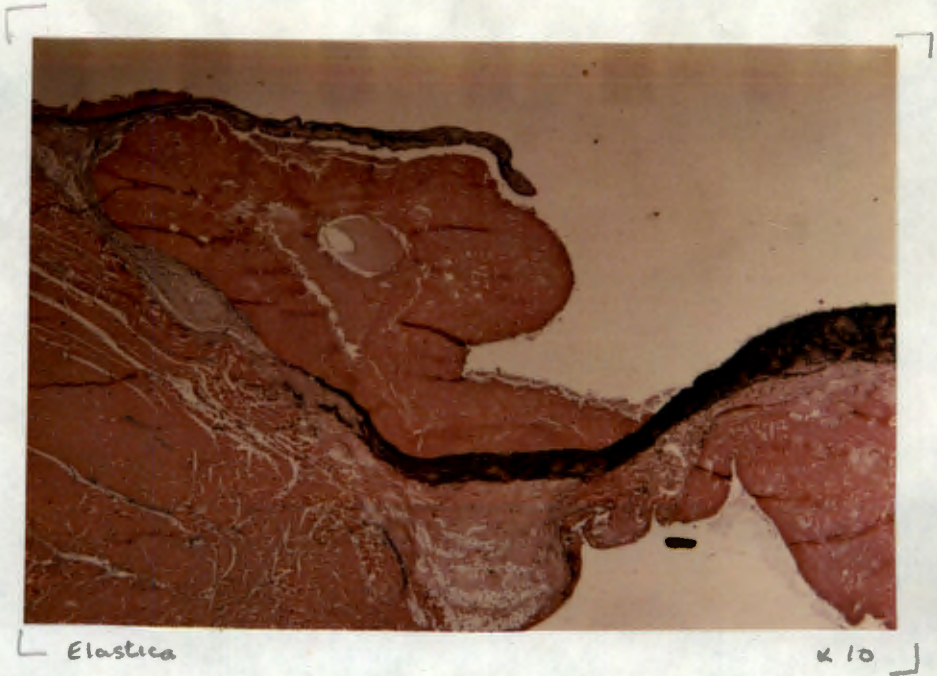

Figure 6c - 55

Non-viable Leaflet implanted 1 week ('Dinty')

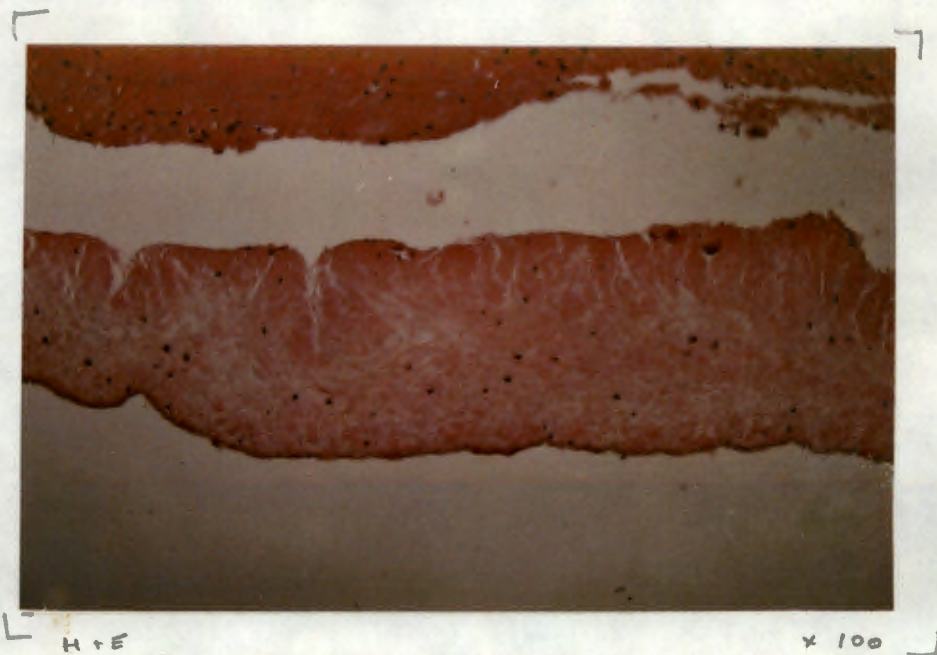

Figure 6c - 56

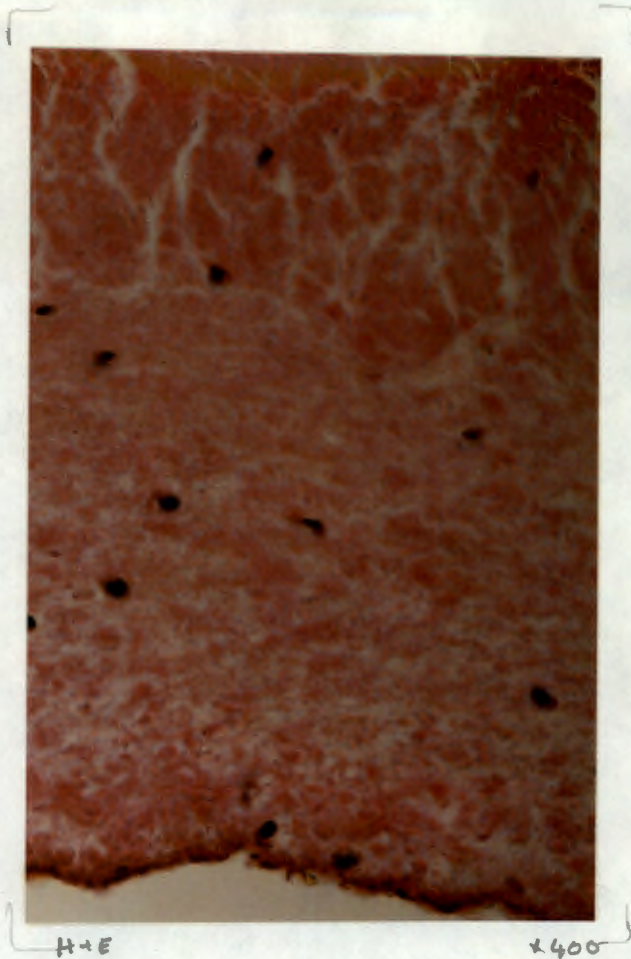


Figure 6c - 57

Non-viable Leaflet implanted 1 week ('Dinty')

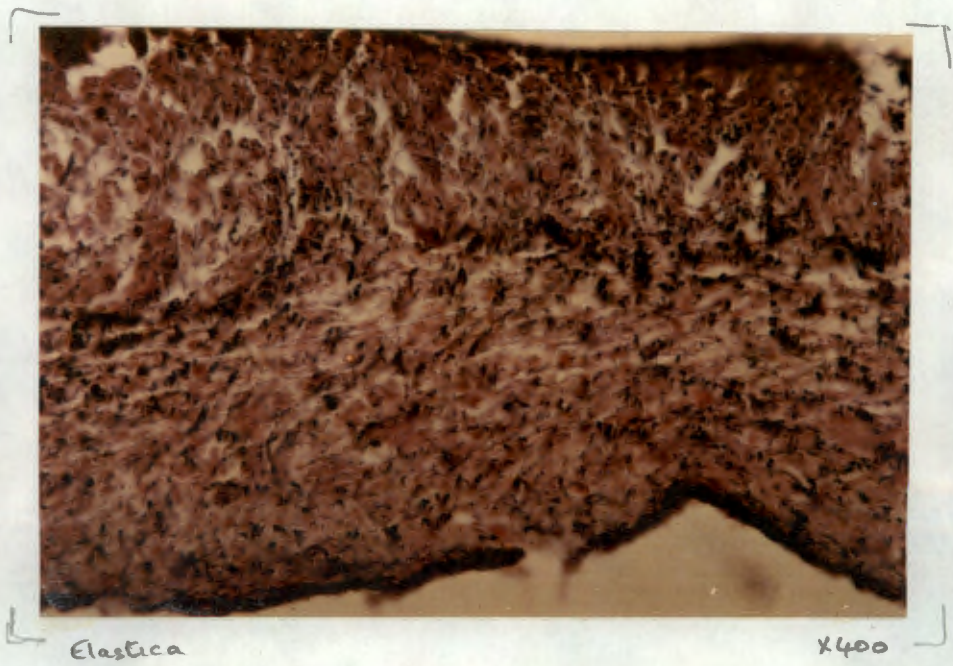


Figure 6c - 58

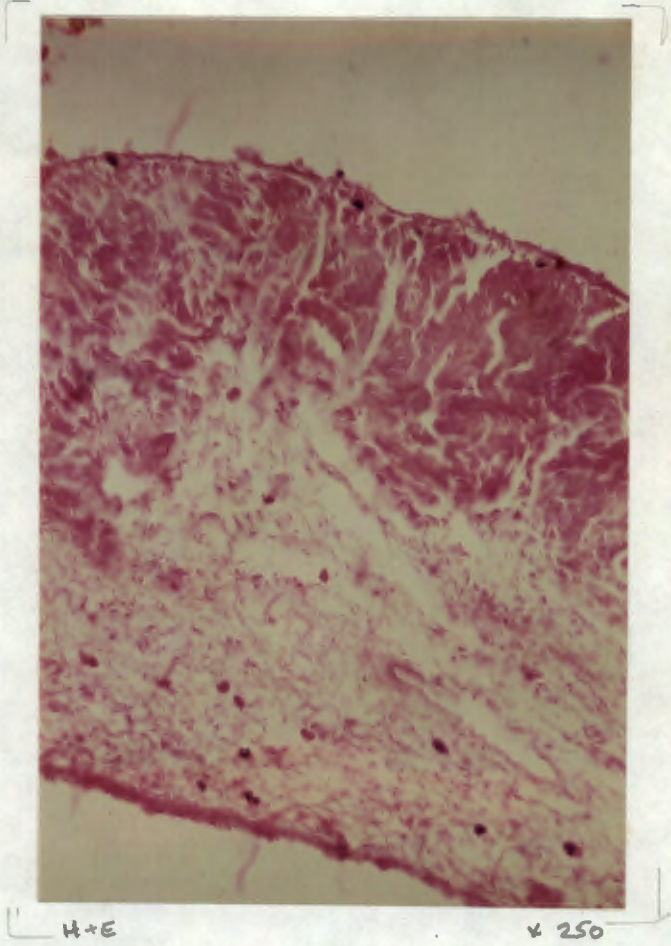


Figure
6c - 59

Non-viable Leaflet implanted 1 week ('Berta')

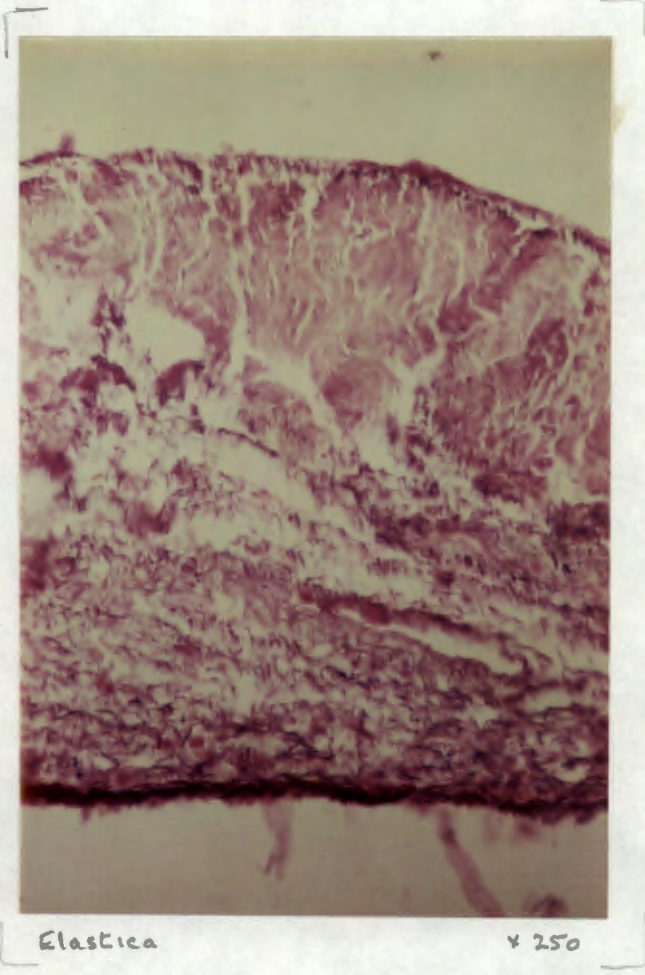


Figure
6c - 60

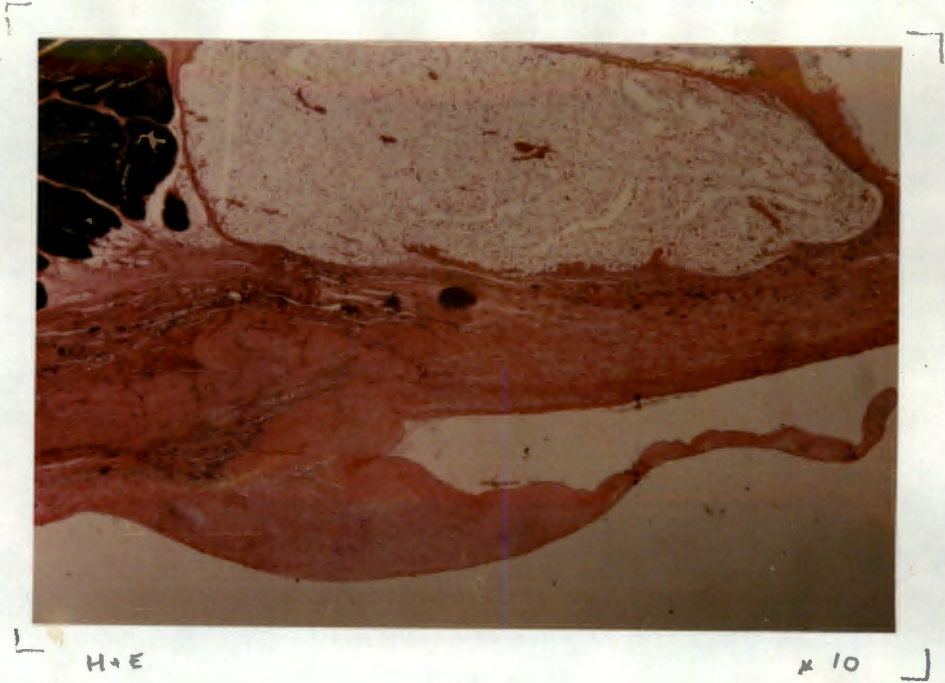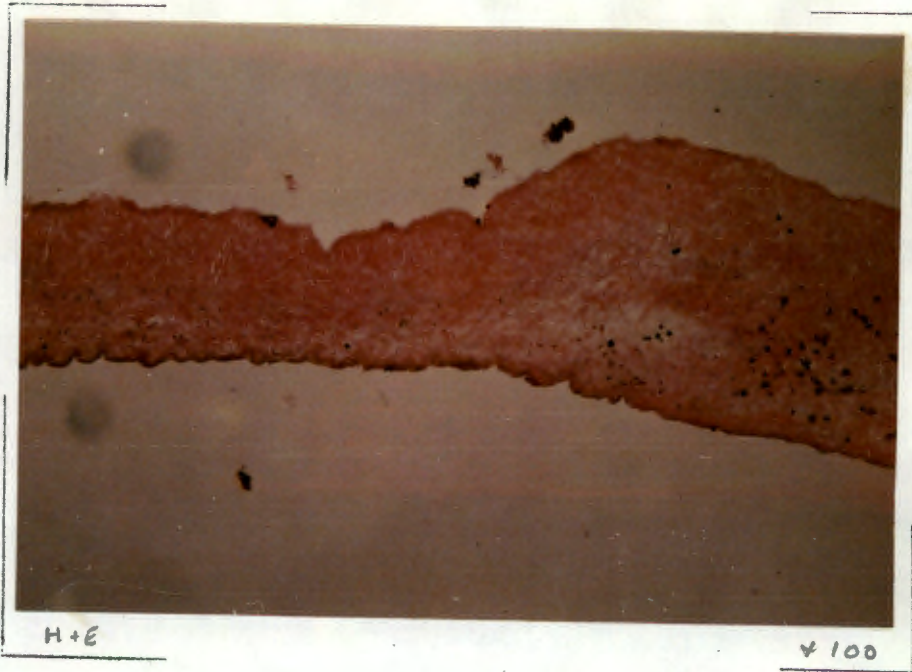


Figure 6c - 61

Non-viable Leaflet implanted 8 weeks ('Alta')



Figure 6c - 62



Non-viable leaflet implanted 8 weeks ('Alta')



Figure 6c - 63

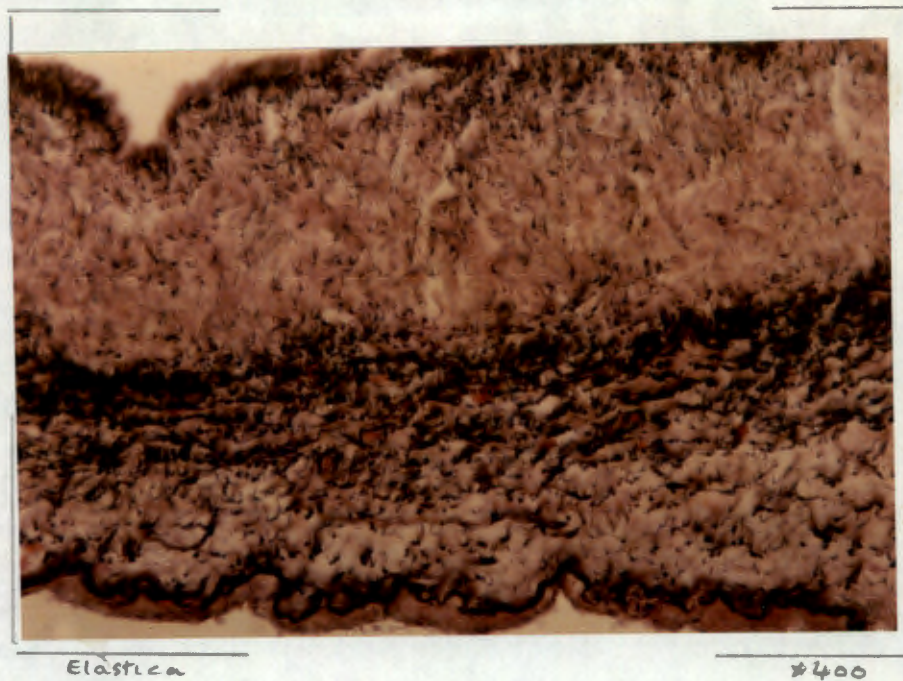


Figure 6c - 64

Non-viable leaflet implanted 8 weeks ('Alta')

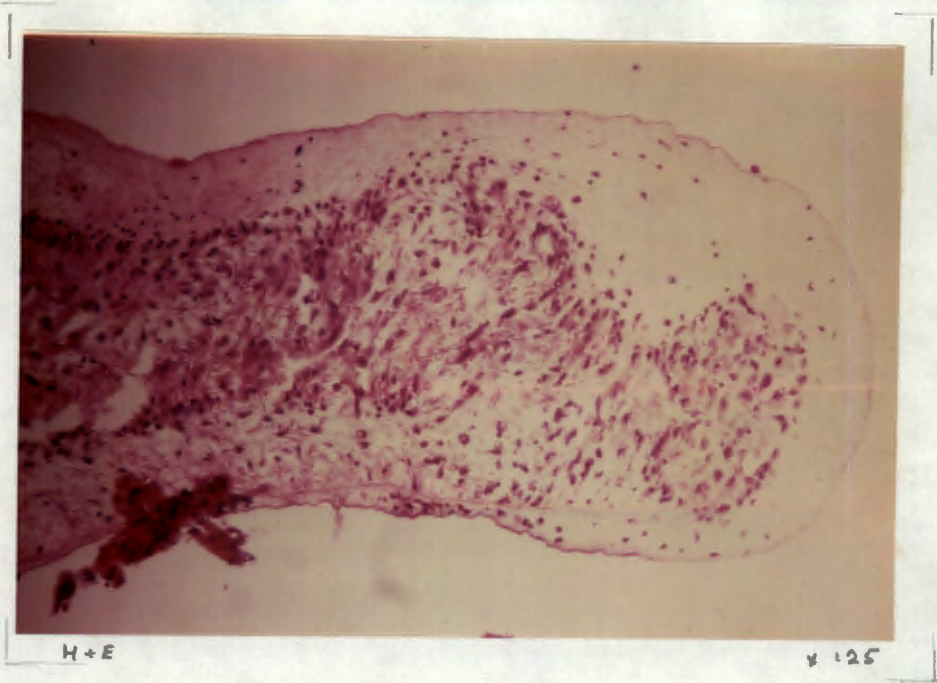


Figure 6c - 65

Area of cellularity at tip of viable valve
leaflet after 8 weeks implantation
See Figure 6c - 67

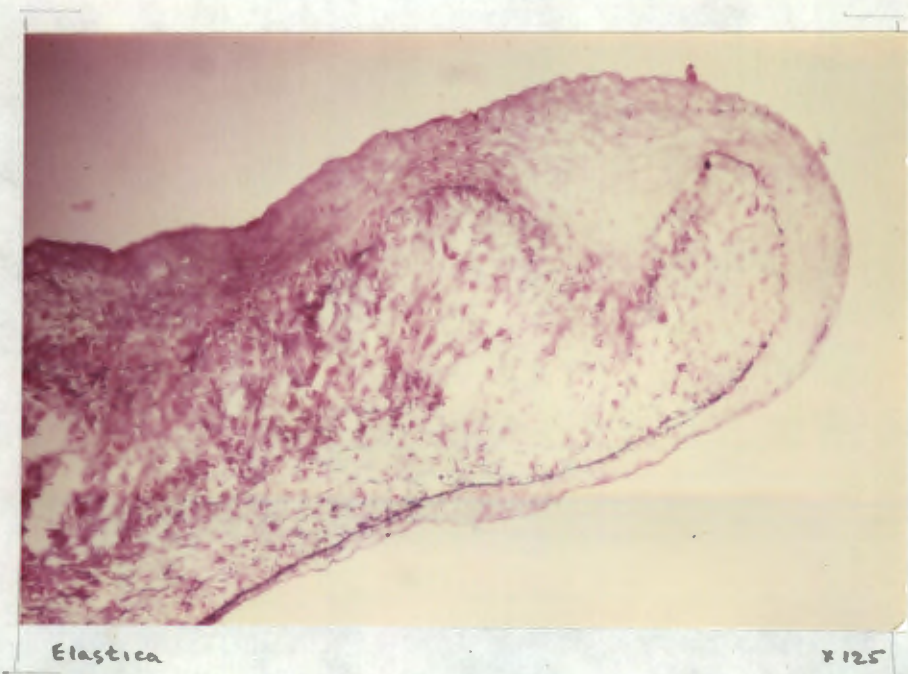

Figure 6c - 66

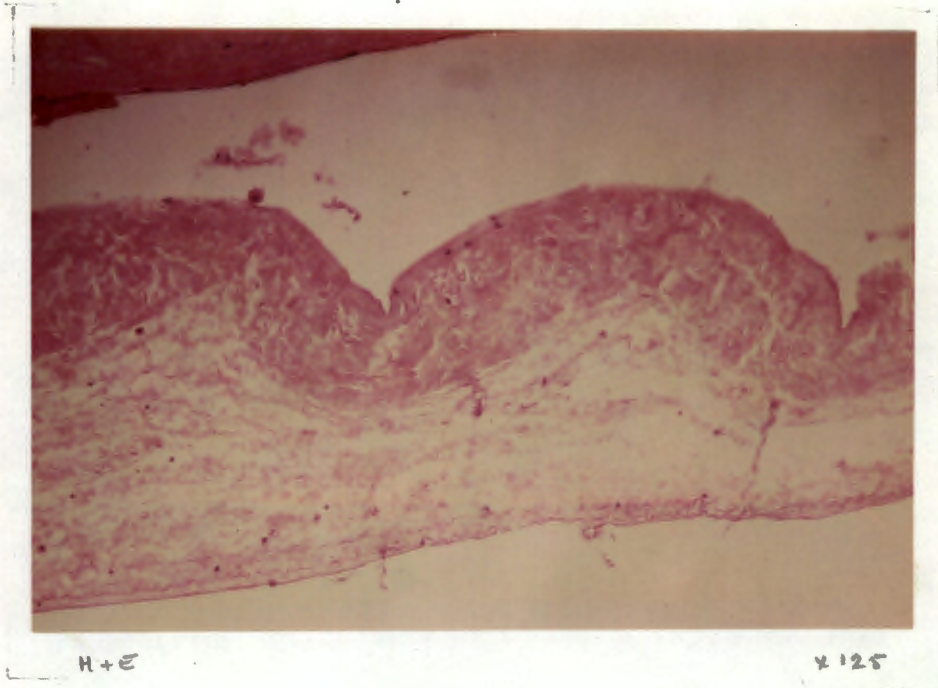


Figure 6c - 67

Same viable valve after 8 weeks implantation as shown in Figures 6c - 65 and 6c - 66 showing a cell-free appearance typical of most of section

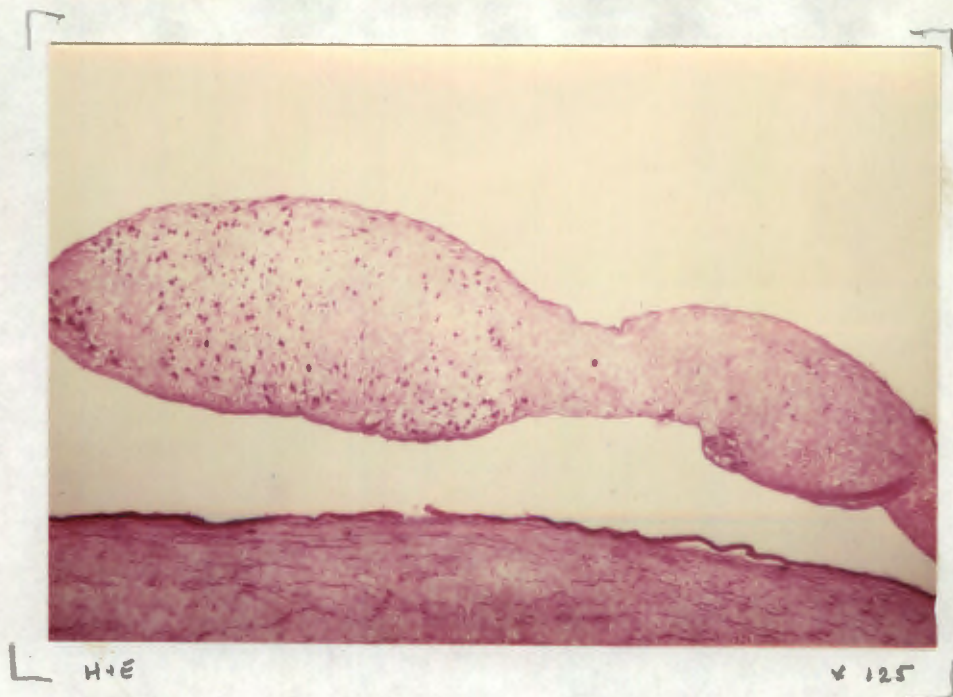


Figure 6c - 68

Cellular area at tip of viable
valve after 8 weeks implantation

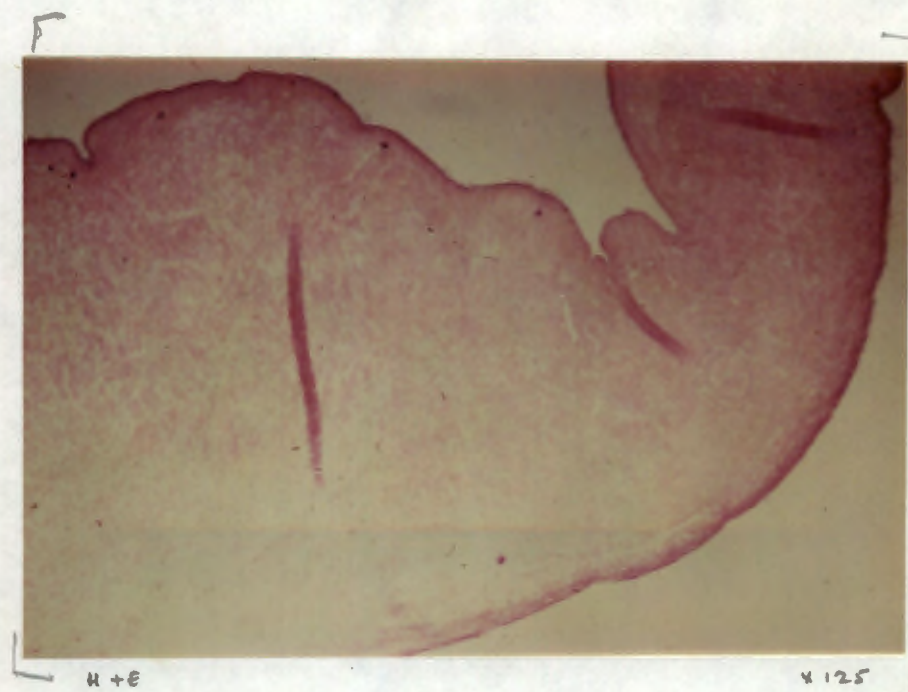

Figure 6c - 69

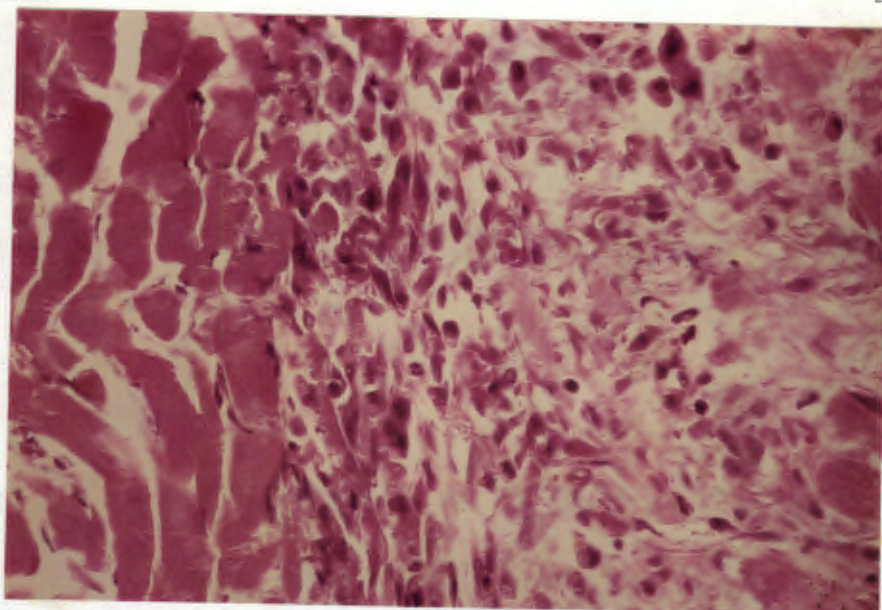
Same valve showing a more
representative cell-free area

Changes in the myocardium and pulmonary artery
of the conduits

The myocardium and pulmonary artery of both viable and non-viable conduits showed loss of cellularity, particularly affecting the myocardium, over large areas by one week, with an infiltration of polymorphs, macrophages and plasma cells.

At 8 weeks large areas of necrotic muscle and pulmonary artery were present, and invasion by macrophages and fibroblasts with ingrowth of granulation tissue was occurring around the periphery of these necrotic areas. Figure 6c-70 shows the invasion of necrotic myocardium by granulation tissue in a conduit implanted for 8 weeks.

A surface growth of fibrocytes overlying the myocardial portion of the conduit was present in those conduits implanted for 8 weeks, whether originally viable or non-viable. At this stage after implantation, however, the advancing fibrous tissue did not reach the base of the leaflets, and did not constitute a host fibrous sheath on the leaflets as described by Angell et al. (1973a).



H+E

x250

Figure 6c - 70

Invasion of necrotic myocardium by granulation
tissue in a conduit after 8 weeks implantation

4) Assessment of tissue culture growth of implanted valves

Half of one of the leaflets removed under sterile conditions from the opened conduits was set up in tissue culture as described in Section 5a.

The results were as follows:-

Viable Valves

Short-term	-	All 4 examined showed prompt tissue culture growth within 5 days.
Intermediate	-	1 of 2 valves showed tissue culture growth within 10 days.
Long-term	-	6 of the 8 valves in this group showed sluggish growth after about 10 days; 4 of these 6 however ceased growing after a further 7 to 10 days and died.

Non-viable Valves

Short-term	-	None of the 6 in this group showed tissue culture growth.
Long-term	-	2 of the 6 in this group showed tissue culture growth, which was delayed (being evident at 10 days) and which ceased after a further 10 days.

Healthy control canine valves showed the usual prompt growth within 4 - 5 days, indicating that the poor growth was not ascribable to technique.

5) Assessment of origin of cells grown in tissue culture

The other half of the leaflet removed under sterile conditions from the opened conduits was set up independantly in tissue culture as described in Section 6b 'Assessment of origin of cells grown in tissue culture'. Similar difficulties were experienced in growing the tissues of the long-term valves, and this did not appear to be a technical difficulty as control healthy canine valves grew promptly, as did control tissue in the independant study described in the preceding paragraph.

As a result of the poor yield of healthy fibroblasts in tissue culture it was possible only to identify chromosomes in two animals - both with 'viable' valves.

One animal ('Dumas') - a male recipient with a female donor valve - showed only 2 cells with clearly identifiable chromosomes; here Y chromosomes were clearly identifiable, showing the male origin of those cells - i.e. their host origin.

The second animal ('Pearl') - a female recipient with a male donor valve - showed 28 cells with clearly identifiable chromosomes; here Y chromosomes were clearly identifiable in all, showing the male origin of those cells - i.e. their donor origin. Figure 6b-12 shows the chromosomes of one of the cells from this valve.

6) Assessment of Protein and Collagen Synthesis by the Implanted Allograft Valve

The methods described in Section 5a for the assessment of Protein and Collagen Synthesis were applied to one leaflet of each of the removed 'long-term' valves.

The results are shown below; those showing tissue culture growth are indicated (+):

	Protein Synthesis *	Collagen Synthesis **	Tissue Culture Growth
<u>Viabile Valves</u>			
Cyrus	0	0	-
Jacobia	0	0	+
Dumas	46,000	0	+
Zachary	11,250	0	+
Milne	0	0	-
Sellie	75,000	0	+
Juno	0	0	+
Pearl	0	0	+
<u>Non-viable Valves</u>			
Cindy	0	0	-
Simba	0	0	+
Alta	2,000	0	+
Quita	0	0	-
Hilda	0	0	-
Herbie	0	0	-
Average of 4 fresh controls	15,000	1,150	+

* Protein Synthesis in cpm/mg protein

** Collagen Synthesis in dpm/mg protein

SECTION 7

CONCLUSIONS

IN VIVO STUDY OF POST-IMPLANTATION VIABILITY OF HEART VALVE LEAFLETS

The results reported in Section 6c indicate:-

At time of valve insertion:

- i) Allograft pulmonary valve-bearing conduits could be implanted in the right ventricular outflow of dogs with a relatively low operative mortality (2 deaths in 30 operations).
- ii) Normal physiological function of the allograft valves was shown after implantation in all cases.
- iii) The state of viability of the allograft valves was accurately defined by established criteria (Section 5a), dependant solely on the duration of prior storage in Antibiotic-nutrient solution.

At time of valve removal:

- i) Allograft valves which were 'viable' at insertion showed -
 - a. After one week of implantation - normal valve function; slight thickening of valve leaflets; and increased leaflet cellularity due to an inflammatory reaction. (6 valves).
 - b. After 4 weeks of implantation - normal valve function; further leaflet thickening; inflammatory cellular reaction, but areas of focal necrosis in the leaflets. (2 valves).

- c. After 8 weeks of implantation - 7 of the 8 valves showed total loss of function, due to gross shrinkage and retraction of leaflets. There was virtually complete loss of leaflet cellularity - 3 of the 8 showed small focal areas of cellularity.

- ii) Allograft valves which were 'non-viable' at insertion showed -
 - a. After one week of implantation - normal valve function; leaflets devoid of cells; no inflammatory reaction. (6 valves).

 - b. After 8 weeks of implantation - normal function retained; leaflets not shrunken; devoid of cells.(6 valves).

- iii) Allograft valve viability was lost during 8 weeks of implantation.

Evidence for this loss of viability was:-

- a. The progression from normal cellularity at time of implantation, to an inflammatory reaction after one week of implantation, with evidence of focal necrosis at 4 weeks, and finally, virtually total acellularity at 8 weeks.

- b. Sluggish tissue culture growth in only 6 of 8 valves at 8 weeks, which ceased in 4, and was active enough in only 2 to allow chromosome identification.

- c. Demonstration of protein synthetic activity in only 3 of 8 valves at 8 weeks, and absence of collagen synthetic activity in all 8.

DISCUSSIONThe question of whether fibroblast viability is maintained following isotopic allotransplantation of a viable valve:

The animal model used in this study was chosen to simulate as closely as possible the clinical situation of allograft valve implantation.

The potential pitfalls inherent in making assumptions regarding human clinical behaviour from results of animal experiments are well recognised. However, such assumptions have been made in this field, and this has been the justification for the assumption that allograft leaflet viability is maintained after implantation (Section 2).

The conflicting experimental findings of various groups, reviewed in Section 3a, range from the finding of rapid loss of cellularity in viable leaflets within 3 weeks of implantation (Duran et al., 1965; Duran and Whitehead, 1966; Beall et al., 1961) to the findings of prolonged donor cell survival and increased leaflet cellularity for at least 6 months (Mohri et al., 1967a, 1967b, 1968b; Buch et al., 1971; Kosek et al., 1969).

This experimental study has clearly shown rapid loss of leaflet cellularity in 'viable' valves by 8 weeks.

An indication of a possible explanation for the conflicting experimental findings in the past is raised by the presence of focal areas of increased cellularity in certain sections. These were small foci, seen in 3 of the 8 long-term 'viable' leaflets. In the context of the early hypercellularity with inflammatory response at 1 week; going on to virtually total loss of cellularity by 8 weeks, these foci cannot be seen as evidence that viability is retained, but rather than they are the last remaining areas of viability in otherwise dead leaflet tissue.

It is not clearly established from this study whether these areas are of host or donor origin. However, a donor origin appears the more likely in view of the fact that the cellular areas are concentrated within the original leaflet tissue (as defined by the elastic stain); and they are not continuous with any cellular areas toward the base of the leaflet and host tissue. In fact, the conduit was chosen with deliberate physical separation of host and donor tissue in mind, in an attempt to clarify just such a problem. Also, these cellular areas were not seen in the non-viable leaflets.

These cellular areas fit the descriptions and illustrations of the cellular leaflets described following implantation of viable valves by Mohri et al. (1967a, 1967b and 1968), Buch et al. (1971) and Kosek et al. (1969).

The allograft valve has been implanted experimentally in various ways. In this study, as in the studies of Duran et al. (1965) and Beall et al. (1961), the valve was implanted as part of a conduit, necessitating implantation of a relatively large amount of donor tissue. In the studies of Mohri et al. (1967a and 1967b), Buch et al. (1971) and Kosek et al. (1969) the allograft leaflets were implanted either singly, or on a frame, which involved smaller quantities of donor tissue.

It has been shown by Heslop et al. (1973) that the myocardial component of the allograft valve is the main site of antigenicity. The aortic wall is only marginally antigenic, and the leaflets are apparently not antigenic. Thus, differing experiments, using differing methods of leaflet implantation with varying amounts of the components of the valve-complex, could well provoke differing immune responses - allowing varying donor leaflet fibroblast survival.

valves implanted for 8 weeks. Protein synthetic activity (at a low level) could be demonstrated in one of these. This illustrated the difficulties of assessment of post-implantation viability, and indicates the possible room for doubt about claims of viability in leaflets removed after implantation (Al-Janabi, 1975a).

Clearly, some donor cells at least, are still surviving at 8 weeks, as evidence by identification of chromosomes of donor sex in cells growing in tissue culture from a viable valve implanted for 8 weeks. The use of chromosome identification to allow determination of origin was preferred to the use of sex chromatin (Barr body) identification. The incidence of Barr bodies varies in different tissues, and increases as cells become more crowded and their nuclei become smaller. Older cells are more likely to contain Barr bodies than younger ones. In rapidly dividing tissues, the incidence of Barr bodies is lower than in cells in which mitoses have become rare (Mittwoch, 1973). The decrease in Barr-body-positive cell percentage has caused difficulty in interpretation in this field previously (Mohri et al., 1968b; Gavin, 1973a).

The identification of chromosomes was possible only in two valves - this was due to difficulty in obtaining sufficiently active tissue culture growth from the recovered leaflet explants. It is thus considered to be a reflection of much impaired viability of the implanted valves.

It must be remembered that the histological sections were made through the middle of one leaflet of each valve. Between 10 and 20 sections, each 5 microns thick, were cut for each valve, which itself measured between 10 and 20 millimetres wide (see Figure 6b-11 and Figure 6c-29). Thus, the histological picture is of only a small sample of each valve.

Even where retained viability has been shown for relatively long times after implantation, it is clear that leaflet cellularity decreased considerably by 11 to 12 months (Mohri et al., 1968b).

That an immune response is elicited by the allograft valve in the intra-cardiac position, has been demonstrated by many workers (Buch et al., 1971; Kosek et al., 1969; Baue et al., 1968; Lower et al., 1960; Tector et al., 1971). The inflammatory response demonstrated in all 6 'viable' valves at one week of implantation in this study was shown not to be due to infection and was not present in any of the 6 'non-viable' controls. The histological features were compatible with acute rejection and resembled the changes seen in acutely rejected canine and human cardiac allografts (Roitt, 1972; Pappas et al., 1967; Hudson, 1975). Loss of leaflet endothelium, which has been called the hallmark of visceral allograft rejection, was also seen (Kosek et al., 1969).

By the criteria for viability used in the in vitro canine study (Section 5a) the evidence for retained viability in the 8-weeks-implanted viable leaflets was very poor:

6 of the 8 valves in this group showed tissue culture growth, but it was sluggish or transient growth, being sufficiently active in only two cases to allow identification of chromosomes in the cells - and in one of these a donor origin was established.

Protein synthetic activity was absent in 5 of the 8 valves, and collagen synthetic activity could not be demonstrated in any of the 8.

It is of interest to note that tissue culture growth (sluggish and transient) could be shown in 2 of the 6 'non-viable'

While there is no reason to expect that this is not a representative sample, it is clearly the explanation of apparently cell-free leaflets showing tissue culture growth or protein synthetic activity, as both these investigations were made on one entire leaflet each.

The question of whether, in antibiotic sterilised valves, the state of fibroblast viability can be shown to influence valve structure and function following isotopic allotransplantation:

In this animal model it was shown that pre-implantation viability, far from being advantageous, resulted in gross distortion of the valve leaflets with consequent loss of function. Non-viable valves, in striking contrast, showed minimal alteration of basic leaflet architecture, with retention of normal function.

It would appear from this study, that the acute rejection process evoked by the viable valve, causes severe structural damage to the valve leaflets.

Although other workers have suggested that viable valves may not be as good as non-viable valves in terms of long-term structural state (Duran and Whitehead, 1966; Mohri et al., 1968b; Suzuki et al., 1970) the differences have not been as strikingly shown as in this study, and there has not been a report of a comparison between viable and non-viable antibiotic sterilised valves such as this one.

The suggestion by Angell et al., (1973a) that the thickening seen in the viable valves following implantation is advantageous, is not supported by the appearance of the few foci of cellularity in this study, which were associated with gross distortion.

SUMMARY

The animal study has shown that under the conditions chosen to simulate clinical allograft valve implantation, fibroblast viability in viable antibiotic sterilised valve leaflets is not maintained following implantation.

Furthermore, gross leaflet distortion and consequent loss of function is seen in the viable antibiotic-sterilised leaflets; by contrast, non-viable antibiotic sterilised leaflets retain structure and function and behave in the manner of clinical allograft leaflets at this stage of implantation.

IN VITRO STUDY OF TISSUE CULTURE, PROTEIN AND COLLAGEN SYNTHESIS IN
ANTIBIOTIC STERILISED CANINE HEART VALVES

This study, reported in Section 5a, has shown that leaflet fibroblast viability could be reliably retained for at least one week of storage in Antibiotic-nutrient solution, but after 3 weeks of storage it is rarely present, and by 4 weeks of storage it is absent.

These valves were obtained under optimal conditions for the maintenance of viability. Such conditions could not be approached in human work. This study therefore casts considerable doubt on viability in human heart valves used in clinical practice.

IN VITRO STUDY OF VIABILITY IN HUMAN HEART VALVES

PREPARED FOR GRAFTING

This study, reported in Section 5b, has shown that human valves obtained from routine autopsy sources are rarely viable. This confirms the doubts raised by the canine study (Section 5a).

SUMMARY

Thus, in combination, Section 5 and 6 clearly indicate that the efforts to maintain leaflet fibroblast viability in heart valve leaflets in clinical practice are unnecessary, as are the tests for viability that have been advocated.

It is clear that virtually all allograft human valves used following antibiotic sterilisation and storage by the method described for clinical use, have been non-viable valves. Indeed, the striving for improved viability may be hazardous, as implantation of a viable valve in the human may well result in the changes seen in the in vivo canine study with viable valves.

Review of the literature suggests that very few, if any of the valves used in clinical practice were in fact viable. The valves used originally by Murray et al. (1956) had been stored in electrolyte solution, and as shown by Reichenbach et al. (1971) such viability is rapidly lost. This also applies to the valves inserted by Barratt-Boyes between 1962 and 1964, and the report by Gavin et al. (1973a) supports this view. Gavin et al. (1973c) clearly believe that donor valve viability is not retained prior to implantation, using their formula for antibiotic sterilisation. They also believe that cellularity of antibiotic sterilised valves is lost by 40 days after implantation (Gavin, 1973b).

The findings of this study, therefore, should contribute considerably to answering the questions raised in Section 2 regarding the preparation and clinical use of allograft heart valves.

SECTION 8

ACKNOWLEDGEMENTS

ACKNOWLEDGEMENTS

In the preparation of this thesis I have drawn on the experience and skills of a large number of people in a variety of specialised fields. To them I wish to express my gratitude for the help and advice which has been so freely given.

For help, advice and continued encouragement in the surgical field, special mention must be made of the debt of gratitude to Mr. Donald Ross, Director of Surgery at the National Heart Hospital, London, who has played such an important role in this sphere of cardiac surgery, and who has taught me so much of clinical cardiac surgery.

It is difficult to single out for individual mention any particular members of the National Heart Hospital staff as this thesis has been stimulated by the experience of this unit as a whole. However, my gratitude to Mr. J. Keith Ross, Mr. L. Gonzalez-Lavin, and Mr. Magdi Yacoub for their enthusiastic help in imparting their considerable surgical experience to me during my surgical training deserves particular mention.

Dr. Eunice Lockey, recently clinical pathologist at the National Heart Hospital, has been most helpful with planning of the thesis, and advice about bacteriological and pathological aspects; Dr. Nawal Al-Janabi has helped with aspects of preparation techniques, and Dr. E. Olsen, pathologist, has helped with aspects of pathology at the National Heart Hospital.

Particular mention must be made of the help given by Professor R. E. B. Hudson, recently Professor of Pathology at the Institute of Cardiology and the National Heart Hospital, London, who very kindly and patiently reviewed the histological slides of the animal work, and who helped in confirming the accuracy of the

reported statements and conclusions about this aspect of the work. The help of such a noted expert in this field was invaluable. Professor Alan Morgan of the Department of Histopathology, Westminster Hospital, London, has also given valuable help and advice.

In Glasgow, the help of many people is gratefully acknowledged:

Professor L. Blumgart, for help and encouragement, and for acting as advisor and sponsor for the thesis.

Mr. W. M. Bain, Reader in Cardiac Surgery, for help, and as co-recipient of the Scottish Hospital Endowments Research Trust grant which has financed much of the work in Glasgow.

Mr. R. S. Barclay, Senior Surgeon, Cardio-Thoracic Unit, Mearnskirk Hospital, for help and encouragement and facilities of his staff and unit.

Dr. J. E. Craik, Chairman of Laboratory Division, Victoria Infirmary, for the use of the facilities of the Department of Pathology for tissue culture, and preparation of histological slides; Mr. A. W. Kerr for his enthusiastic technical help; Dr. H. M. McCallum, pathologist, for her help with tissue culture techniques and interpretation of histological findings; and Mrs. A. Dunsmore, Librarian of the Victoria Infirmary.

Mr. S. Saunders and his staff of the Department of Medical Illustration at the Victoria Infirmary for preparation of illustrations.

Professor Jim McGee (now Professor of Pathology at Oxford) for his expert help in assessment of protein and collagen synthesis, and his assistance in assessing the results in this specialised field.

Mr. Frank Kennedy, Surgeon, Western Infirmary, for help in planning the project and confirming its statistical validity.

Dr. A. Murray Harper and his staff of the Wellcome Surgical Research Institute; Dr. Mary Stewart, Veterinary Surgeon, for help with the animal research project.

Dr. M. Harvey and Dr. D. Logue, Department of Animal Reproduction, University of Glasgow Veterinary School, for help with chromosome identification; Mr. Alan May and the Photographic Department staff of the Veterinary School for photography.

Professor Fergusson-Smith and Mrs. Marie Fergusson-Smith of the Department of Medical Genetics, Yorkhill, for teaching me the techniques of tissue culture.

Dr. Chris McGregor, for considerable help with tissue culture and preparation of histological specimens.

Miss Margaret Roberts for typing the manuscript.

Thanks are due to the Scottish Hospital Endowments Research Trust for provision of a grant of £3,610 which made the work possible.

REFERENCES

- Absolon, K. B. (1961) In Prosthetic Valves for Cardiac Surgery.
p. 151. Ed. K. A. Merendino: Springfield, 1961.
- Al-Janabi (1974) Personal Communication.
- Al-Janabi, N. (1974) Long Term Preservation of Fresh Viable
Aortic Valve Homograft by Freezing.
British Journal of Surgery, 61: 229.
- Al-Janabi (1975a) Viability of Homografts and Problems of Long
Term Storage - in The Current Status of Cardiac Surgery,
p. 209 - 214. Ed. D. B. Longmore, Medical and Technical
Publishing Co. Ltd., Lancaster 1975.
- Al-Janabi (1975b) Personal Communication.
- Al-Janabi, N., Gibson, K., Rose, J. and Ross, D. N. (1973)
Protein Synthesis in Fresh Aortic and Pulmonary Valve
Allografts as an Additional Test for Viability.
Cardiovascular Research 7: 247.
- Al-Janabi, N., Gonzalez-Lavin, L., Neirotti, R., and Ross, D. N.
(1972) Viability of Fresh Aortic Valve Homografts. A
Quantitative Assessment. Thorax 27, 83.
- Al-Janabi, N. and Ross, D. N. (1973) Enhanced Viability of
Fresh Aortic Homografts stored in Nutrient Medium.
Cardiovascular Research 7, 817.
- Angell, W. W., Stinson, E. B., Iben, A. B. and Shumway, N. E.
(1968) Multiple Valve Replacement with the Fresh Aortic
Homograft.
Journal of Thoracic and Cardiovascular Surgery 56: 323.
- Angell, W. W., Shumway, N. E. and Kosek, J. C. (1972)
A five year study of viable aortic valve homografts.
J. Thoracic and Cardiovascular Surgery, 64: 329.
- Angell, W. W., deLanerolle, P. and Shumway, N. E. (1973a)
Valve Replacement: present status of homograft valves.
Progress in Cardiovascular Diseases 15: 589.

- Angell, W. W., Wuerflein, R. D., Chun, C. W. and Shumway, N. E. (1973b) Antibiotic Sterilisation of aortic homografts. *New Zealand Medical Journal* 77: 31.
- Angell, W. W., Wuerflein, R. D. and Shumway, N. E. (1967) Mitral valve replacement with the fresh aortic valve homograft. *Surgery*, 62: 807.
- Aparicio, S. R., Donnelly, R. J., Dexter, F. and Watson, D. A. (1975) Light and electron microscopy studies on homograft and heterograft heart valves. *Journal of Pathology* 115: 147.
- Balch, C. M. and Karp, R. B. (1975) Blood group compatibility and aortic valve allotransplantation in man. *Journal of Thoracic and Cardiovascular Surgery* 70: 256.
- Barnes, R. W., Rittenhouse, E. A., Mohri, H. (1970) A clinical experience with the beta-propiolactone sterilised homologous aortic valve followed up to four years. *Journal of Thoracic and Cardiovascular Surgery* 59: 785.
- Barnhorst, D. A., Oxman, H. A., Connolly, D. C., Pluth, J. R. Danielson, G. K., Wallace, R. B. and McGoon, D. C. (1975) Isolated replacement of the aortic valve with the Starr-Edwards prosthesis. A 9 year review. *Journal of Thoracic and Cardiovascular Surgery* 70: 113.
- Barratt-Boyes, B. G., (1964) Homograft aortic valve replacement in aortic incompetence and stenosis. *Thorax* 19: 131.
- Barratt-Boyes, B. G. (1971) Long-term follow-up of aortic valvar grafts. *British Heart Journal* 33, Suppl. 60.
- Barratt-Boyes, B. G., Agnew, T. M., Cole, D., Kerr, A., Monro, J. L., Lower, J. B. and Brandt, P. W. T. (1972) Homograft valves. *Medical Journal of Australia* 2, special supplement. Proc. Int. Cardiology and Cardiac Surgery Conference, Melbourne, 1971 p. 38.
- Barratt-Boyes, B. G., Brandt, P. W. T., Smith, J. C. and Lowe, J. B. (1969) Aortic homograft valve replacement. A long-term follow-up of an initial series of 101 patients. *Circulation*: 40, 763.

- Barratt-Boyes, B. G. and Roche, A. M. G. (1969) A review of aortic valve homografts over a six and one-half year period. *Annals of Surgery* 170, 483.
- Baue, A. E., Donawick, W. J. and Blakemore, W. S. (1968) The immunologic response to heterotopic allovital aortic valve transplants in presensitised and non-sensitised recipients. *Journal of Thoracic and Cardiovascular Surgery* 56: 775.
- Beall, A. C., Morris, G. C., Cooley, D. and De Bakey, M. E. (1961) Homotransplantation of the aortic valve: *Journal of Thoracic and Cardiovascular Surgery* 42: 497.
- Bigelow, W. G., Trimble, A. S., Aldridge, H. E., Bedard, P., Spratt, E. M. and Lansdown, E. L. (1967) The Problem of insufficiency following homograft replacement of the aortic valve. *Journal of Thoracic and Cardiovascular Surgery* 54: 478.
- Bigelow, W. G., Yao, J. K., Aldridge, H. E., Heimbecker, R. O. and Murray, G. D. W. (1975) Clinical homograft valve transplantation. *Journal of Thoracic and Cardiovascular Surgery* 48: 333.
- Bjork, V. (1975) Five years experience with the Bjork-Shiley disc valve in aortic mitral and tricuspid valvular disease. In current status of Cardiac Surgery p. 160. Ed. D. B. Longmore. Medical and Technical Publishing Co.Ltd. Lancaster, 1975.
- Bolooki, H., Rubinson, R. M., Prochazka, J. and Jude, J. R. (1972) A simple method of aortic homograft valve sterilisation and preservation. *Journal of Thoracic and Cardiovascular Surgery* 63: 249.
- Braunwald, N. S. and Detmer, D. E. (1968) A critical analysis of the status of prosthetic valves and homografts. *Progress in Cardiovascular Diseases* 11: 113.
- Brawley, R. K., Gardner, T. J., Donahoo, J. S., Neill, C. A., Rowe, R. D. and Gott, V. L. (1972) Late results after right ventricular outflow tract reconstruction with aortic root homografts. *Journal of Thoracic and Cardiovascular Surgery* 64: 316.

- Brewin, E. G. (1956) The use of tissue transplants in the surgery of cardiac valvar disease. An experimental study. Guy's Hospital Report 105: 328.
- Brock, R. C. (1968) Long-term degenerative changes in aortic segment homografts, with particular reference to calcification. Thorax, 23: 249.
- Buch, W. S., Kosek, J. C., Angell, W. W. (1970) Deterioration of formalin-treated aortic valve heterografts. Journal of Thoracic and Cardiovascular Surgery 60: 673.
- Buch, W. S., Kosek, J. C. and Angell, W. W. (1971) The role of rejection and mechanical trauma on valve viability. Journal of Thoracic and Cardiovascular surgery 62: 696.
- Carpentier, A., Deloche, A., Relland, J., Fabiani, J. N., Forman, J., Canikeri, J. P., Soyer, R. and Dubost, C. L. (1974) Six-year follow-up of glutaredehyde-preserved heterografts. Journal of Thoracic and Cardiovascular Surgery 68: 771.
- Carpentier, A., Relland, J. and Dubost, C. L. (1975) Tissue Valve Preparation. In Current Status of Cardiac Surgery p. 219 Ed. D. B. Longmore, Medical and Technical Publishing Co. Ltd. Lancaster, 1975.
- Chalcroft, S. C. W., Gavin, J. B. and Seelye, R. N. (1974) A method for evaluating the effects of allograft sterilisation procedures on the viability of human fibroblasts. Thorax 29: 539.
- Clark, R. E. (1973) Stress-strain characteristics of fresh and frozen human aortic and mitral leaflets and chordae tendineae. Implications for clinical use. Journal of Thoracic and Cardiovascular Surgery 66: 202.
- Davies, H., Lessof, M. H., Roberts, C. I. and Ross, D. N. (1965) Homograft replacement of the aortic valve. Follow-up studies in twelve patients. Lancet 1: 926.
- Duran, C. G. and Gunning, A.J. (1962) A method for placing a total homologous aortic valve in the subcoronary position. Lancet 2: 488.

- Duran, C. G., Manley, G., and Gunning, A. J. (1965)
The behaviour of homotransplanted aortic valves in the dog.
British Journal of Surgery 52: 549.
- Duran, C. M. G. and Whitehead, R. (1966) Experimental homologous
aortic valve transplantation. A comparison between fresh
and freeze-dried grafts.
British Journal of Surgery: 53, 1049.
- Eastcott, H. H. G., Holt, L. B., Peacock, J. H. and Rob, C. G. (1954)
Preservation of arterial grafts by freeze drying. A
simplified method. Lancet 1: 1311.
- Eguchi, S. and Asano, K. (1968) Homograft of pulmonary artery
or ascending aorta with valve as a right ventricular outflow.
Journal of Thoracic and Cardiovascular Surgery 56: 413.
- Flewett, T. M., Zinnemann, K. S., Oldfield, M. W. C.,
Shucksmith, H. S. and Dexter, F. (1955)
A single-stage method of freeze-drying arteries for grafting.
Lancet 1: 888.
- Fontan, F. and Baudet, E. (1971) Surgical repairs of tricuspid
atresia. Thorax 26, 240.
- Ford, C. E., Jacobs, P. A. and Lajtha, L. G. (1958)
Human Somatic Chromosomes.
Nature 181: 1565.
- Gavin, J. B., Barratt-Boyes, B. G., Hitchcock, G. C. and
Herdson, P. B. (1973a) Histopathology of 'fresh' human aortic
valve allografts. Thorax 28, 482.
- Gavin, J. B., Herdson, P. B. and Barratt-Boyes, B. G. (1972)
The pathology of chemically-sterilised human heart valve
allografts. Pathology 4, 175.
- Gavin, J. B., Herdson, P. B., Monroe, J. L. and Barratt-Boyes, B. G.
(1973b) Pathology of antibiotic-treated human heart valve
allografts. Thorax 28, 473.
- Gavin, J. B., Monroe, J. L., Wall, F. M. and Chalcraft, S. C. W. (1973c)
Five ultrastructural changes in the fibroblasts of canine
heart valves prepared for grafting. Thorax 28, 748.

- Geha, A. S., Titus, J. L. and McGoon, D. C. (1967)
Fixation of aortic valve homografts with metal rings.
Journal of Thoracic and Cardiovascular Surgery 54: 605.
- Gerbode, F. (1970) (editor) Proceedings of the first international workshop on tissue Valves.
Annals of Surgery, Volume 172 (Supplement): 1 - 24.
- Gibson, K., Al-Janabi, N. and Ross, D. N. (1973)
Effect of storage on succinic dehydrogenase and acid phosphatase activity in aortic and pulmonary valve homografts.
Cardiovascular Research 7: 813.
- Gott, V. L., Daggett, R. L., Koepka, D. E., Rowe, G. C. and Young, W. P. (1962) Journal of Thoracic and Cardiovascular Surgery 44: 713.
- Gonzalez-Lavin, L., Geens, M., Somerville, J. and Ross, D. N. (1970)
Autologous pulmonary valve replacement of the diseased aortic valve.
Circulation 42: 781.
- Gonzalez-Lavin, L. and Ross, D. N. (1970)
Homograft aortic valve replacement. A five year experience at the National Heart Hospital, London.
Journal of Thoracic and Cardiovascular Surgery, 60: 1.
- Hammon, J. W., O'Sullivan, M. J., Oury, J. and Fosburg, R. B. (1974) Allograft cardiac valves. A view through the scanning electron microscope.
Journal of Thoracic and Cardiovascular Surgery, 68: 352.
- Hancock Laboratories Incorporated (1975) Technical Bulletin I, Anaheim, California.
- Harken, D. E., Soroff, H. S. and Taylor, W. J. (1960)
Partial and Complete prostheses in aortic insufficiency.
Journal of Thoracic and Cardiovascular Surgery 40: 744.
- Harris, P. D., Kovalik, A. T. W., Beach, R. M. (1969)
A comparative study of selected physical properties of aortic homografts and heterografts.
Journal of Thoracic and Cardiovascular Surgery 57: 830.

- Harris, P. D., Kovalik, A. T. W., Marks, J. A. and Malm, J. R. (1968)
Factors modifying aortic homograft structure and function.
Surgery 63: 45.
- Heimbecker, R. O. (1968) In discussion of paper by Angell, W. W.,
Stinson, E. B., Iben, A. B. and Shumway, N. E. (1968).
Multiple valve replacement with the fresh aortic homograft.
Journal of Thoracic and Cardiovascular Surgery 56: 331.
- Heslop, B. F., Wilson, S. E., Hardy, B. E. (1973)
Antigenicity of aortic valve allografts.
Annals of Surgery 177: 301.
- Hoeksema, T. D., Titus, J. L., Ginliani, E. R. and Kirklin, J. W. (1967)
Early results of use of homografts for replacement of the
aortic valve in man.
Circulation 35, 9 (Suppl. I)
- Horowitz, M. S., Goodman, D. J., Fogarty, T. J. and Harrison, D. C.
(1974) Mitral valve replacement with the glutaraldehyde
preserved porcine heterograft. Journal of Thoracic and
Cardiovascular Surgery 67, 885.
- Hudson, R. E. B. (1966) Pathology of the human aortic valve
homograft. British Heart Journal, 28: 291.
- Hudson, R. E. B. (1975) Personal communication.
- Hufnagel, C. A. (1951) Aortic plastic valvular prosthesis.
Bulletin of Georgetown University Medical Centre, 34: 38.
- Hufnagel, C. A. and Conrad, P. W. (1961) Prostheses for aortic
valve replacement in prosthetic valves for cardiac surgery,
p. 451. Ed. K. A. Merendino, C. A. Thomas, Springfield, 1961.
- Hufnagel, C. A., Harvey, W. P., Rabil, P. J., McDermott, F. (1954)
Surgical correction of aortic insufficiency.
Surgery, 35: 673.
- Hufnagel, C. A., Vilkgas, P. D. and Nahas, H. (1958)
Experiences with new types of aortic valvular prostheses.
Annals of Surgery, 147: 636.

- Ionescu, M. I. (1975) Experience with Tissue Heart Valves in Current Status of Cardiac Surgery, p. 260.
Ed. D. B. Longmore, Medical and Technical Publishing Co. Ltd., Lancaster, 1975.
- Ionescu, M. I., Pakrashi, B. C., Marn, D. A. S., Bartek, I. T and Wooler, G. H. (1974) Long-term evaluation of tissue valves. *Journal of Thoracic and Cardiovascular Surgery*, 68: 361.
- Johnson, A. D., DiDonna, G. J., Peterson, K. L., Le Winter, M., Blair, G., Niwayama, G. and Daily, P. O. (1975) Functional evaluation of the porcine heterograft in the mitral position. *Circulation* 52-2 (Suppl. I) I-40.
- Karp, R. B. and Kirklin, J. W. (1969) Replacement of Diseased Aortic Valves with Homografts *Annals of Surgery*, 169, 91.
- Karp, R. B., Kirklin, J. W., Kouchoukos, N. T. and Pacifico, A. D. (1974) Comparison of three devices to replace the aortic valve. Supplement II to *Circulation* 49 and 50 II - 163.
- Kay, E. B., Suzuki, A., Tambi, A., Demaney, M. and Zimmerman, H. A. (1970) Comparative analysis of the Starr-Edwards ball valve, the Kay-Suzuki disc valve, and transplant valves with surgical correction of aortic valve disease. *American Journal of Cardiology*, 25: 535.
- Kerwin, A. J., Lenkei, S. C. and Wilson, D. R. (1962) Aortic valve homograft in the treatment of aortic insufficiency. Report of Nine Cases, with one followed for six years. *New England Journal of Medicine*, 266: 852.
- King, H. M., Heimbecker, R. O., Trimble, A. S. (1967) Importance of technique in sterilising and preserving human aortic valves. *Surgical Forum* 18: 119.
- Kosek, J. C., Iben, A. B., Shumway, N. E. and Angell, W. W. (1969) Morphology of fresh heart valve homografts. *Surgery* 66: 269.
- Kouchoukos, N. T., Barcia, A., Bargerion, L. M. and Kirklin, J. W. (1971) Surgical Treatment of Congenital pulmonary atresia with ventricular septal defect. *Journal of Thoracic and Cardiovascular Surgery* 61, 70.

- Kwong, K. H., Paton, B. C. and Hill, R. B. (1967)
Experimental use of immunosuppression in aortic valve
homografts and heterografts.
Journal of Thoracic and Cardiovascular Surgery 54: 199.
- Lan, C. R., Aran, M. H. and Munnell (1952) An experimental
study of aortic valve homografts.
Surgery, Gynaecology and Obstetrics, 94, 129.
- Layton, C. A., McDonald, A., McDonald, L., Towers, M., Weaver, J.
and Yacoub, M. (1972) The syndrome of absent pulmonary valve.
Total correction with aortic valvular homografts.
Journal of Thoracic and Cardiovascular Surgery 63: 800.
- Lennox, S. C. (1975) Mitral valve replacement
In the Current Status of Cardiac Surgery p. 196
Ed. D. B. Longmore, Medical and Technical Publishing Co. Ltd.,
Lancaster, 1975.
- Lennox, S. C., Blasovsky, A., Chang, V. P., Cleland, W. P.,
Ghadiahi, P. E. and Aparicio, S. G. R. (1971)
Frame-mounted homografts for mitral valve replacement.
Journal of Thoracic and Cardiovascular Surgery, 62: 337.
- Litwak, R. S. (1961) in Prosthetic Valves for Cardiac Surgery,
p. 164 Ed. K. A. Merendino, C. A. Thomas, Springfield 1961.
- Litwak, R. S., Gadboys, H. L., Scott, G. B. and Ferrara, I. F.
(1952) Journal of Thoracic Surgery, 24: 165.
- Lockey, E. (1975) Problems of sterilisation in homograft
preparation. in Current Status of Cardiac Surgery p. 215.,
Medical and Technical Publishing Co. Ltd., Lancaster, 1975.
- Lockey, E., Al-Janabi, N., Gonzalez-Lavin, L. and Ross, D. N. (1972)
A method of sterilising and preserving fresh allograft heart
valves. Thorax, 27, 398.
- Longmore, D. B. (1975) The current status of cardiac surgery,
Medical and Technical Publishing Co. Ltd., Lancaster, 1975.
- Longmore, D. B., Lockey, E., Ross, D. N. and Pickering, B. N. (1966)
The preparation of aortic valve homografts.
Lancet II 463.

- Lower, R. R. (1961) in Prosthetic Valves for Cardiac Surgery, p. 159 Ed. K. A. Merendino, Springfield, 1961.
- Lower, R. R., Pillsbury, R. C., Angell, W. W. and Kosek, J. C. (1966) Homograft Heart Valves. Circulation, 33(Suppl. 1) I - 135.
- Lower, R. R., Stafer, R. C., Shumway, N. E. (1960) A study of pulmonary valve autotransplantation. Surgery, 48: 1090.
- Lower, R. R., Stafer, R. C. and Shumway, N. E. (1960) Autotransplantation of the pulmonic valve into the aorta. Journal of Thoracic Surgery 39: 680.
- Lowry, O. H., Rosebrough, N. J., Far, A. L. and Randall, R. J. (1951) Protein measurement with the Folin phenol reagent. Journal of Biological Chemistry 193: 265.
- Magovern, G. J. (1961) in Prosthetic Valves for Cardiac Surgery, p. 161, Ed. K. A. Merendino, C. A. Thomas, Springfield, 1961.
- Malinin, T. I. and Perry, V. P. (1967) A review of tissue and organ viability assay. Cryobiology 4, 104.
- Malm, J. R., Bowman, F. O., Harris, P. D. and Kowalik, A. T. W. (1967) An evaluation of aortic valve homografts sterilised by electron beam energy. Journal of Thoracic and Cardiovascular Surgery 54: 471.
- McEnany, M. T., Ross, D. N. and Yates, A. K. (1972) Valve failure in seventy-two frame-supported autologous fascia lata mitral valves. Two-year follow-up. Journal of Thoracic and Cardiovascular Surgery 63: 199.
- McGoon, D. C. (1971) Choice of grafts or prostheses for valvular replacement. British Heart Journal 33 (Suppl.) 35.
- McGoon, D. C., Rastelli, G. C. and Ongley, P. A. (1968) An operation for the correction of truncus arteriosus. Journal of the American Medical Association: 205, 69.
- McGoon, D. C., Wallace, R. B. and Danielson, G. K. (1973) The Rastelli operation. Its indications and results. Journal of Thoracic and Cardiovascular Surgery 65: 65.

- McKenzie, M. B., Titus, J. L., Ellis, F. H. and Pappas, G. (1965)
Experimental semilunar valve homografts. Morphologic
features. *Journal of Thoracic and Cardiovascular Surgery*,
50, 410.
- Merendino, K. A. (1961) *Prosthetic Valves for Cardiac Surgery*,
C. A. Thomas, Springfield, 1961.
- Missen, G. A. K. and Roberts, C. I. (1970) Calcification and
cusp rupture in human aortic valve homografts sterilised
by ethylene oxide and freeze-dried.
Lancet 2: 962.
- Mittwoch, U. (1973) *Genetics of sex differentiation*.
Academic Press, New York and London.
- Mohri, H., Reichenbach, D. D., Barnes, R. W. and Merendino, K. A.
(1967a) A biologic study of the homologous aortic valve
in dogs.
Journal of Thoracic and Cardiovascular Surgery 54: 622.
- Mohri, H., Hessel, E. A., Nelson, R. J., Matano, I., Anderson, H.N.,
Dillard, D. H. and Merendino, K. A. (1966a) Use of Rheomacrodex
and Hyperventilation in Prolonged circulatory arrest under
Deep Hypothermia Induced by Surface Cooling. A Method for
Open Heart Surgery in Infants. x
American Journal of Surgery, 112, 241.
- Mohri, H., Reichenbach, D. D., Barnes, R. W. and Merendino, K. A.
(1968b) Homologous aortic valve transplantation.
Alterations in viable and non-viable valves.
Journal of Thoracic and Cardiovascular Surgery 56: 767.
- Mohri, H., Reichenbach, D. D., Barnes, R. W., Nelson, R. J. and
Merendino, K. A. (1967b) Studies of antigenicity of the homologous
aortic valve. *Journal of Thoracic and Cardiovascular
Surgery* 54: 564.
- Mohri, H., Reichenbach, D. D., Nelson, R. J., Barnes, R. W. and
Merendino, K. A. (1968a) Preparation and preservation of aortic
valve grafts with special attention to problem areas.
Journal of Thoracic and Cardiovascular Surgery 56: 546.
- Murray, G., Roschlau, W. and Longhead, W. (1956) Homologous
aortic-valve-segment transplants as surgical treatment for
aortic and mitral insufficiency.
Angiology 7: 466.

Murray, G. (1960) Aortic Valve Transplants.
Angiology 11, 99.

Nelson, R. J., Mohri, H., Dillard, D. H., Wintercheid, L. C. and Merendino, K. A. (1967) Early clinical experience with homotransplantation of the aortic valve.
Circulation 35 - 36 (Suppl. 1) I - 3.

Oh, W., Somerville, J., Ross, D. N., Ross, J. K. and Emanuel, R., (1973)
Mitral valve replacement with preserved cadaveric aortic homografts.
Journal of Thoracic and Cardiovascular Surgery 65: 713.

Olsen, E. (1975) Personal communication.

Pacifico, A. D., Karp, R. B. and Kirklin, J. W. (1972)
Homografts for replacement of the aortic valve. Circulation 45, Suppl. 36 1972.

Paneth, M. and O'Brien, M. F. (1966) Transplantation of human homograft aortic valve.
Thorax 21: 115.

Pappas, G., Titus, J. L. and Ellis, F. M., (1967)
Homotransplantation of the mitral valve in dogs, treated with azathioprine.
Journal of Thoracic and Cardiovascular Surgery 54: 1.

Parker, D. J. (1975) Late Results of cardiac valve replacement with autologous fascia lata; in Current Status of Cardiac Surgery, p. 272.
Ed. D. B. Longmore, Medical and Technical Publishing Co. Ltd., Lancaster, 1975.

Paton, B. C., Kwong, K. H., Clark, D., Halseth, W. L. and Hill, R. B. (1967) Immunosuppressive therapy in the management of homo- and heterografted cardiac valves.
Transplantation 5: 909.

Peirce, E. C., Gross, R. E., Bill, A. H. and Merrill, K. (1949)
Tissue culture evaluation of the viability of blood vessels stored by refrigeration. Annals of Surgery, 129: 333.

- Peterkofsky, B. and Diegelmann, R. (1971) Use of a mixture of proteinase-free collagenases for the specific assay of radioactive collagen in the presence of other proteins. *Biochemistry* 10: 988.
- Pickering, B. N. (1966) The preparation and storage of aortic valve homografts. *Guy's Hospital Report* 115, 105.
- Pierce, W. S., Thompson, W. M., Kazama, S., and Waldhausen, J. A. (1971) Replacement of the pulmonary outflow tract and valve with a formalin-treated heterograft. *Journal of Thoracic and Cardiovascular Surgery* 61: 924.
- Pritchard, G. R., Wright, J. S. and Johnston, J. B. (1966) The effect of beta-propiolactone on the tensile properties of human pericardium. *Journal of Thoracic and Cardiovascular Surgery* 52: 232.
- Puig, L. B., Verginelli, G., Iryia, K., Kawabe, L., Bellotti, G. Sosa, E., Pilleggi, F., and Zarbini, E. J. (1975) Homologous dura mater cardiac valves: study of 533 surgical cases. *Journal of Thoracic and Cardiovascular Surgery* 70: 722.
- Rastelli, G. C., McGoon, D. C. and Wallace, R. B. (1969) Anatomic correction of transposition of the great arteries with ventricular septal defect and subpulmonary stenosis. *Journal of Thoracic and Cardiovascular Surgery* 58: 545.
- Rastelli, G. C., Titus, J. L. and McGoon, D. C. (1967) Homograft of ascending aorta and aortic valve as a right ventricular outflow - an experimental approach to the repair of truncus arteriosus. *Archives of Surgery* 95, 698.
- Rastelli, G. C., Wallace, R. B., Ongley, P. A., (1969) Complete repair of transposition of the great arteries with pulmonary stenosis: A review and report of a case corrected by using a new surgical technique. *Circulation* 39: 83.
- Reichenbach, D. D., Mohri, H., Sands, M. and Merendino, K. A. (1971) Viability of connective tissue cells following storage of aortic valve leaflets. *Journal of Thoracic and Cardiovascular Surgery* 62: 690.
- Reid, K. (1975) Design characteristics of heart valves; in *Current status of Cardiac Surgery* p. 123. Ed. D. B. Longmore, Medical and Technical Publishing Co. Ltd., Lancaster, 1975.

- Rob, C. (1968) The sterilisation and preservation of homologous arterial segments, with special reference to the heart valves. *Surgery*, 63: 875.
- Roitt, I. M. (1972) *Essential Immunology*. Blackwell Scientific Publications, Oxford.
- Ross, D. N. (1962) Homograft Replacement of the Aortic Valve. *Lancet* 2: 487.
- Ross, D. N. (1964) Homotransplantation of the aortic valve in the subcoronary position. *Journal of Thoracic and Cardiovascular Surgery* 47: 713.
- Ross, D. N. (1966) Aortic Valve Replacement. *Lancet* 2: 461.
- Ross, D. N. (1972) Biologic Valves. Their Performance and Prospects. *Circulation* 45, 1259.
- Ross, D. N. (1975a) Homograft and autograft replacement of the aortic valve. in *The Current Status of Cardiac Surgery*, p. 234 - 245 - ed. D. B. Longmore, Medical and Technical Publishing Co. Ltd., Lancaster, 1975.
- Ross, D. N. (1975b) The Need for homograft reconstruction of the right ventricular outflow in Fallot's tetralogy. In *The Current Status of Cardiac Surgery* p. 117 - 120. Ed. D. B. Longmore, Medical and Technical Publishing Co. Ltd., Lancaster, 1975.
- Ross, D. N. and Somerville, J. (1966) Correction of Pulmonary Atresia with a homograft aortic valve. *Lancet* 2, 1446.
- Ross, D. N. and Somerville, J. (1971) Fascia Lata reconstruction of the right ventricular outflow tract. *Lancet* 1, 941.
- Ross, D. N. and Somerville, J. (1973) Surgical correction of tricuspid atresia. *Lancet* 1, 845.
- Rubina vitz, M. J., Rowe, G. G., Young, W. P., Azen, E. A. and Clatanoff, (1970) Studies for haemodysis following aortic homograft surgery. *J. Thoracic and Cardiovascular Surgery*, 59: 668.

- Sands, M. P., Nelson, R. J., Mohri, H. and Merendino, K. A. (1967)
The procurement of aortic valve homografts. *Surgery* 62: 839.
- Seki, S., Rastelli, G. C., McGoon, D. C., Titus, J. C. (1970)
Replacement of the pulmonary artery with a pulmonary arterial
homograft.
Journal of Thoracic and Cardiovascular Surgery 60: 853.
- Senning, A. (1967) Fascia lata replacement of aortic valves.
Journal of Thoracic and Cardiovascular surgery 54: 465.
- Senning, A. (1975) Personal communication.
- Smith, J. C. (1967) The pathology of human aortic valve homografts.
Thorax 22: 114.
- Somerville, J. (1970) Management of pulmonary atresia.
British Heart Journal, 32: 641.
- Somerville, J. and Ross, D. N. (1972) Long-term results of
complete correction with homograft reconstruction in
pulmonary outflow tract atresia.
British Heart Journal 34: 29.
- Starr, A. (1975) The cage ball prosthesis - in Current Status
of Cardiac Surgery p. 144. Ed. D. B. Longmore, Medical and
Technical Publishing Co. Ltd., Lancaster, 1975.
- Starzl, T. E., Marchioro, T. L., Holme, J. H., Herman, G.,
Brittain, R. S., Stonington, O. H., Talmaze, D. W. and
Waddell, W. R. (1964) Renal homografts in patients with
major donor-recipient blood group incompatibilities.
Surgery 55: 195. (1964)
- Stinson, E. B., Angell, W. W., Iben, A. B. and Shumway, N. E.
(1968) Aortic valve replacement with the fresh valve
homograft. *American Journal of Surgery* 116: 204.
- Suzuki, A., Mackrell, J. and Kay, E. B. (1970) Mitral valve
replacement with transplant valves.
Journal of Thoracic and Cardiovascular Surgery, 60, 13.
- Tector, A. J., Boyd, W. C. and Kornis, M. E. (1971) Aortic valve
allograft rejection. *Journal of Thoracic and Cardiovascular
Surgery* 62: 592.

- Tjio, J. H. and Levan, A. (1956) *Hereditas* 42: 1.
- Trusler, G. A., Iyengar, S. R. and Mustard, W. T. (1973)
Reconstruction of the pulmonary valve and outflow tract.
A report of 25 cases.
Journal of Thoracic and Cardiovascular Surgery 65: 245.
- Van Vliet, P. D., Titus, J. L., Berghuis, J. and Ellis, F. M. (1965)
Morphologic features of homotransplanted canine mitral valves.
Journal of Thoracic and Cardiovascular Surgery 49: 504.
- Wallace, R. B., Guillani, E. R., Titus, J. L. (1971)
Use of aortic homografts for aortic valve replacement.
Circulation 43: 365.
- Wallace, R. B., Londe, S. P. and Titus, J. L. (1974) Aortic
valve replacement with preserved aortic valve homografts.
Journal of Thoracic and Cardiovascular Surgery 67: 44.
- Wallace, R. B., Rastelli, G. C., Ongley, P. A., Titus, J. L. and
McGoon, D. C. (1969) Complete repair of truncus arteriosus
defects. *Journal of Thoracic and Cardiovascular Surgery*, 57:
95.
- Waterworth, P. M., Lockey, E., Berry, E. M. and Pearce, H. M. (1974)
A critical investigation into the antibiotic sterilisation of
heart valve homografts. *Thorax*: 29: 432.
- Waldon, C. S. and Cameron, J. L. (1968) Correction of
persistent truncus arteriosus. *Journal of Cardiovascular
Surgery*, 9: 463.
- Wheatley, D. J., Prusty, S., Ross, D. N. (1974) Reconstruction
of right ventricular outflow with a valved homograft conduit.
Thorax 29: 617.
- Willman, V. L., Zafiracopoulos, P. and Hanlon, C. R. (1961)
Replacement of the mitral valve with homograft aortic valve.
in *Prosthetic Valves for Cardiac Surgery* p. 142, Ed.
K. A. Merendino; Charles, C. Thomas, Springfield 1961.
- Yacoub, M. H. and Kittle, C. F. (1970) Sterilisation of valve
homografts by antibiotic solutions.
Circulation, Supplement II to Vol. 41 and 42 II - 29.

Yacoub, M. H. (1975) Homograft replacement of the mitral valve.
In the Current Status of Cardiac Surgery p. 253 - 259.
Ed. D. B. Longmore, Medical and Technical Publishing Co. Ltd.,
Lancaster, 1975.

Yacoub, M. H. and Kittle, C. F. (1969) New technique for
replacement of the mitral valve by a semilunar valve homograft.
Journal of Thoracic and Cardiovascular Surgery, 58: 859.

Yacoub, M. H., Kothari, M., Keeling, D., Patterson, M. and
Ross, D. N. (1969) Red cell survival after homograft
replacement of the aortic valve. Thorax 24: 283.