

**Dr. Gary Dos Passos**

**Microvascular Free Tissue Transfer for Head and  
Neck Reconstruction in a Resource-Limited  
Setting**

**Division of Plastic, Reconstructive and  
Maxillofacial Surgery Department of Surgery  
University of Cape Town**

**Master of Medicine (MMed.) in Plastic and  
Reconstructive Surgery**

This research is based in independent work performed by the candidate. None of this work has been or is being submitted for any degree at any other university. This work has not been reported or published prior to registration of the above degree. It has been published in a peer-reviewed journal after registration of the above degree.

The copyright of this thesis vests in the author. No quotation from it or information derived from it is to be published without full acknowledgement of the source. The thesis is to be used for private study or non-commercial research purposes only.

Published by the University of Cape Town (UCT) in terms of the non-exclusive license granted to UCT by the author.

**Table of Contents:**

Declaration	Page 2
Acknowledgements	Page 2
Abstract	Page 3
Protocol	Page 4
Manuscript	Page 5
Published Article	Page 16

**DECLARATION**

I, Gary Des Passos, hereby declare that the work on which this dissertation/thesis is based is my original work (except where acknowledgements indicate otherwise) and that neither the whole work nor any part of it has been, is being, or is to be submitted for another degree in this or any other university.

I empower the university to reproduce for the purpose of research either the whole or any portion of the contents in any manner whatsoever.

Signature:

Signed by candidate

Date: 03/07/2016

**Acknowledgements:**

**Prof Donald A. Hudson:** Supervisor of research dissertation and guidance with writing and editing.

**Prof Johannes J. Fagan:** Extirpative surgeon for the study cases and guidance with writing and editing.

**Conrad H. Pienaar and Jacobus E. van Zyl:** Reconstructive surgeons for the study cases.

**Alan D. Rogers and Christopher E. Price:** Assistance with data collection and literature review.

## **Abstract:**

**Background:** Free tissue transfer has become the standard of care for the reconstruction of head and neck oncological defects. The Groote Schuur Hospital provides a microsurgical reconstructive service in a resource-limited setting, without access to venous couplers, invasive monitoring devices, modern microscopes or sophisticated pre-operative imaging. The reconstructive surgeons perform all anastomoses under x4.5 loupe magnification.

**Methods:** A retrospective chart review was undertaken of cases performed by the service over a 3-year period. Demographic factors, indications for flap cover, operative details (flap used, duration and lowest recorded temperature), intensive care and hospital length of stay, and other outcomes were recorded and evaluated (including flap and systemic complications, donor site morbidity, haematomas as well as returns to theatre).

**Results:** Over a 36-month period, 109 flaps for head and neck reconstruction were performed. The main indication for surgery was squamous cell carcinoma of the oral cavity. The mean operating time for resection and reconstruction was 6.02 h (range of 4 to 12 h). Virtually, all reconstructions were performed using one of either radial forearm, free fibula or anterolateral thigh flaps. We report a complete flap loss rate of 6%. All four successful salvages were undertaken in the early (less than 24 h) post-operative period. Hypothermia intra-operatively appears to correlate very closely with pejorative outcomes.

**Conclusions:** By restricting reconstructive options to three main 'workhorse' flaps and by utilising a simultaneous two-team approach for tumour ablation and flap elevation, success rates comparable to international standards have been achieved. Limited resources should not be regarded as an impassable barrier to providing a successful microvascular head and neck reconstructive service.

## **Protocol:**

### ***Aim:***

1. Determine the acute outcomes of free tissue transfer reconstruction for head and neck resection defects at Groote Schuur Hospital.
2. Compare these results with that of developed world units.
3. Determine if there is a need to adapt our reconstructive options, methods and free flap monitoring.

### ***Materials and Methods:***

Groote Schuur Hospital has a multidisciplinary head and neck service which has provided a free-flap reconstruction service for head and neck oncological defects for the last twenty years. The team includes oncologists, otorhinolaryngologists, who perform the extirpative surgery, and plastic surgeons, who perform the free-flap reconstruction. This unit performs a major head and neck tumour resection requiring free tissue transfer for reconstruction almost every week. All patients are assessed at the weekly multidisciplinary head and neck oncology clinic at which time the choice of reconstruction is made.

A retrospective audit is proposed of consecutive patients who underwent free tissue reconstruction for head and neck extirpative defects over a three-year period. This should yield about one hundred consecutive reconstructions. Variables to be assessed include: patient demographics (age and sex); pathological type and site of tumour; co-morbidities; primary reconstructive surgeon; free flap donor site(s); recipient artery and vein; operative time; additional procedures (e.g. tracheostomy and neck dissection); length of high care/intensive care stay; total hospital stay; flap viability (complete survival, partial loss, complete loss); flap and donor site complications; and additional surgical interventions required during the acute period.

A literature review of current international trends and outcomes in microvascular free tissue transfer for head and neck reconstruction following extirpative surgery will be conducted. This will allow comparison of our results to those of high volume first world international units. We hope to demonstrate comparable results despite the resource limited setting in which we work.

Resources limited in our setting include: intensive care bed availability; functional operating microscope; invasive flap monitoring devices; pre-operative radiological investigations; venous anastomotic devices; and dedicated nurses trained in free flap care & monitoring. The audit may highlight if any of these resource limitations have impacted negatively on our results and motivate for a change in our current practice.

# **Manuscript**

## **Introduction:**

Although the first free microvascular tissue transfer was reported as early as 1973 [1], there was limited enthusiasm for making use of free flaps to reconstruct head and neck defects until the late 1980s [2]. This reluctance stemmed from concerns relating to the reliability of a technique that was dependent on small-vessel anastomosis and concerns about complications and cost.

Free microvascular tissue transfer has proved to be extremely versatile and reliable, however, with several centers reporting very low flap failure rates, with acceptable donor site morbidity and perioperative complications. It has become the preferred method of reconstruction for the majority of major head and neck defects [3]. Furthermore, it may in fact have a cost-benefit over traditional pedicled flaps in selected patients [4]. Since the first described case by Panje in 1976, reported flap success rates have ranged between 90 and 99 % [5].

Groote Schuur Hospital has a multidisciplinary head and neck service, which has provided a free flap reconstruction service for head and neck oncological defects for more than 20 years. The team includes an oncologist, an otorhinolaryngologist, who performs the extirpative surgery, an anaesthetist, and plastic surgeons, who perform the free flap reconstruction.

The aims of the study were to:

1. Investigate acute outcomes of free tissue transfer reconstruction for head and neck resection defects at Groote Schuur Hospital.
2. Compare these results with those of developed world units.
3. Determine if there is a need to adapt our preferred reconstructive options, monitoring protocols and techniques.

## **Material and methods:**

This unit performs a major head and neck tumour resection requiring reconstruction with free tissue transfer every week. All patients are assessed at a multidisciplinary head and neck oncology clinic at which time the choice of reconstruction is made. Decisions regarding the primary pathology are corroborated with directed imaging modalities including panorex and CT scans.

Whenever possible, flaps with a long vascular pedicle and large diameter blood vessels are selected. With few exceptions, the free radial forearm (RF), free fibular (FF) or free

anterolateral thigh (ALT) flaps are used. The minimal bulk and pliability of the RF [6] makes it our first choice for the reconstruction of smaller defects and those requiring mobility. The ALT is chosen for larger defects and when bulk is required [7]. Thinning of the ALT to reduce bulk [8] was not performed in this series. The FF, providing unparalleled quantity and quality of bone [9], is chosen whenever a bone defect is to be reconstructed.

Resource restrictions limit the use of pre-operative investigations, and therefore, neither CT/MR angiography nor ultrasound doppler is routinely used to assess donor vessel patency. Donor vessels are assessed clinically. An Allen test is performed if a RF is planned even though it has questionable clinical validity [10] and should probably be supplemented with an ultrasound doppler assessment of collateral ulnar artery flow [11]. Angiography is only used when a FF is planned in patients with an abnormal clinical examination or if there is a history of claudication or significant lower limb trauma and was not required in this case series.

Resection of the primary tumour and elevation of the flap are performed simultaneously by the two surgical teams to reduce operative duration and exposure to hypothermia. Reconstruction plates are bent intra-operatively based on the extirpated defect. Pre-bent plates are not utilised. Ocular loupes (x4.5 magnification) are used for both flap elevation and microvascular anastomosis. All microvascular anastomoses are hand sutured. Vein grafts are avoided. Local rather than systemic intra-operative anticoagulation is used. All patients have thromboprophylactic stockings and intermittent pneumatic calf compression applied to lower limbs not required for flap elevation. Warming blankets are routinely utilised for regions of the body not operated. Closed suction drains are routinely utilised and are positioned and secured some distance away from the anastomoses, usually in the posterior triangle of the neck. Donor sites are closed primarily where possible, but are usually skin grafted, and dressed with negative pressure wound therapy, 'crouton dressings' or other types of tie-over dressings.

Post-operatively, all patients are monitored in an intensive care or post-anaesthetic high care unit (PAHCU) setting for the first night following surgery. Patients usually have a tracheostomy performed, but are seldom ventilated post-operatively. Variables closely monitored and corrected include haemodynamic status (including arterial catheter monitoring), urine output, temperature, pain control, output from suction drains, development of haematomas and the maintenance of a neutral head position. Drains are removed after drainage is less than 50 ml per 24-hour period. All patients received chlorhexidine mouthwash, perioperative broad-spectrum antibiotics and prophylaxis against thromboembolism.

Regular clinical assessment of patient and flap is carried out by the plastic surgery trainee who participated in the procedure, paying particular attention to flap colour, temperature, congestion and bleeding (speed and colour) after needle stick. Invasive flap monitoring (e.g. implantable doppler and tissue oximetry devices) is rarely used. Due to resource constraints, most patients return to the general ward the following day, where all invasive monitoring (arterial and central venous lines) is discontinued and flap monitoring is reduced to three times daily. Although there is a low threshold to return a patient to the operating theatre during the first 48-hour period (concern about flap perfusion or a haematoma), salvage

surgery is often delayed by other surgical emergencies competing for emergency theatre time.

A retrospective chart review was undertaken of all patients undergoing free tissue transfer reconstructions for head and neck resection defects at Groote Schuur Hospital over a 36-month period from July 2007 to June 2010. Data collected included patient demographics (age and sex), pathological type and site of tumour, comorbidities, primary reconstructive surgeon, free flap donor site(s), recipient artery and vein, operative time, lowest recorded intra-operative temperature, additional procedures (e.g. tracheostomy and neck dissection), length of high care/intensive care stay, total hospital stay, flap viability (complete survival, partial loss, complete loss), flap and donor site complications and additional surgical interventions required during the acute period.

## **Results:**

One hundred and nine free flap reconstructions (mean of 36 per year) were performed over the 36-month period, of which 100 records were available for analysis. Eight records were excluded, as they were incomplete or unavailable. One patient died on account of acute myocardial infarction and was excluded from further analysis. There were 65 males and 35 females with a mean age of 55 years (range 19 to 83 years).

The majority of patients had at least one known comorbidity, with smoking, hypertension and frequent alcohol use being the most common (Table 1).

Squamous cell carcinoma (SCC) was the most frequent histological diagnosis, affecting 80 of the 100 patients (Table 2). The oral cavity was involved in 87 patients. Specifically, the most commonly involved structures were the tongue and/or floor of the mouth and the mandible and/or lower alveolus (Table 3). Six patients had orbital involvement (four of the skin malignancies included in this series invaded the orbit). All tumour ablations and neck dissections were performed by or under supervision of Prof. Johan Fagan. Additional procedures at the time of tumour ablation are tabulated in Table 4.

<b>Co-morbidity</b>	<b>Number of patients</b>
None	18
Smoker	72
Hypertension	23
Frequent alcohol use	17
HIV infection	4
Epilepsy	3
Hypercholesterolemia	2
Diabetes mellitus	2
Atrial fibrillation	1
Hypothyroidism	1
Intravenous drug abuse	1

**Table 1: Patient Co-morbidities**

Histological Diagnosis	Number of patients
Squamous cell carcinoma	80
Sarcoma variants	7
Adenocarcinoma	5
Basal cell carcinoma	3
Ameloblastoma	2
Other	3

**Table 2: Histological Diagnosis of resected lesions**

Tumour Site	Number of patients
Tongue and/or floor of mouth	49
Lower alveolus and/or mandible	21
Primary skin malignancy	9
Upper alveolus and/or maxilla	8
Retromolar trigone	4
Buccal mucosa	3
Tonsil and/or soft palate	2
Orbital	2
Temporal	1
Hypopharynx	1

**Table 3: Tumour site**

Procedure	Number of patients
Panendoscopy	2
Panendoscopy, Tracheostomy	6
Panendoscopy, MRND	6
Panendoscopy, Tracheostomy, MRND	73
Panendoscopy, Tracheostomy, BMRND	9
Panendoscopy, Tracheostomy, SND	1
Panendoscopy, Superficial parotidectomy	1
Panendoscopy, Parotidectomy, MRND	2

**Table 4: Additional procedures at time of tumour ablation.** MRND = modified radical neck dissection; BMRND = bilateral modified radical neck dissection; SND = selective neck dissection.

Most reconstructive procedures were performed by one of two senior plastic surgeons with 50 by Conrad Pienaar and 49 by Jacobus van Zyl. The most commonly used free flaps were the FF, RF and the ALT (Table 5). Free jejunum was used for one hypopharyngeal reconstruction and one free vastus lateralis myocutaneous flap was used in a patient who was found to have inadequate perforators to use a classic ALT. The internal jugular vein (or branch thereof) was used for the recipient vein in all cases. A vein graft was used in only one case, to limit tension on the anastomosis in the case of a free fibula flap reconstruction of an

extensive mandibular defect. The facial artery was the most commonly used (87 patients) recipient artery (Table 6).

Free Flap	Number of patients
Free fibula flap	36
Free radial forearm flap	35
Anteriolateral thigh flap	26
Free vastus lateralis flap	1
Free iliac crest flap	1
Free jejunum	1

**Table 5: Free flaps used.**

Recipient Artery	Number of patients
Facial	86
Superior thyroid	7
Transverse cervical	2
Lingual	2
Occipital	1
Superficial temporal	1
External carotid	1

**Table 6: Recipient artery for free tissue transfer.**

The mean total operating time (combined resection and reconstruction) was 6.02 h, with a range of 4 to 12 hours. The mean time when FF, RF and ALT were used was 6.50, 5.46 and 6.13 hours, respectively. Nineteen patients were hypothermic during the procedure, registering core temperatures under 35 °C.

Early in-hospital complications occurred in 35 % of patients. Complications were significantly more prevalent in individuals who had been hypothermic intra-operatively. Five patients had to be returned to the operating theatre for drainage of haematoma. One of these patients had a compromised flap with unsuccessful salvage. Salvage was attempted in seven compromised flaps with four (57 %) successes. All four successful salvages were undertaken in the early (less than 24 hours) post-operative period. The three unsuccessful salvage attempts occurred during the late (more than 24 hours) post-operative period (Fig. 1).

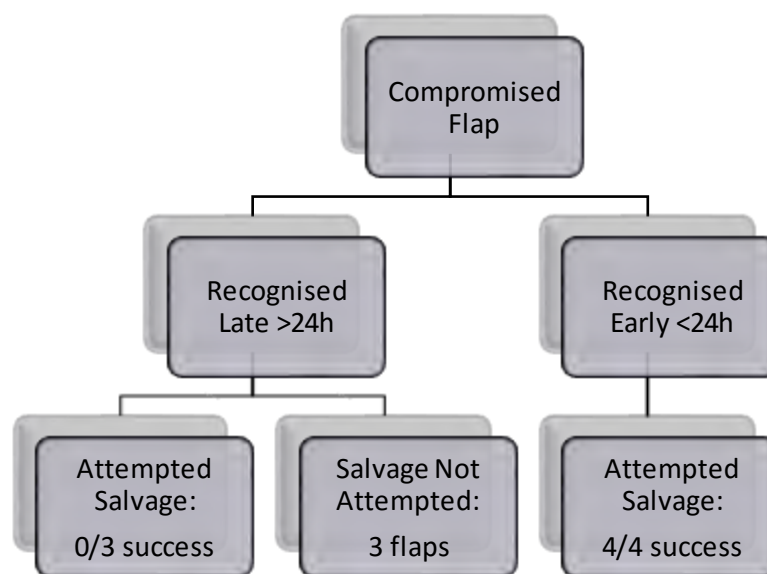
Partial flap loss occurred in five patients (5 %). None of these patients required a second flap. Two of them required debridement and secondary closure. The other three were managed conservatively (Table 7). Complete flap loss occurred in six patients (6 %). Three patients required additional flaps for closure (Table 8).

Flap dehiscence occurred in 10 patients (excluding the five patients with partial flap loss). Eight of these were minor and were treated conservatively. One patient required debridement and re-advancement with re-suturing of the flap. Another patient was treated with debridement, followed by dressings. Neck wound dehiscence occurred in nine patients. Five of these patients were treated conservatively with dressings. One patient required debridement and secondary closure. One patient required debridement and split skin

grafting. Two patients required debridement and pectoralis major flaps for closure of the neck.

One patient developed a chyle leak and lung atelectasis, which responded to conservative management. Two patients required debridement and repeat split skin grafting of their FF donor sites.

The mean intensive care or PAHCU stay was 1.14 days (range of 0 to 3 days). The mean hospital stay was 13.3 days (range of 5 to 108). Complete flap survival occurred in 89 patients. For completely viable flaps, the mean stay was 11.2 days (range of 5 to 34). This increased to 19 days (range of 12 to 27) when there was partial flap loss and to 39.7 days (range of 18 to 108) for complete loss (Fig. 2).



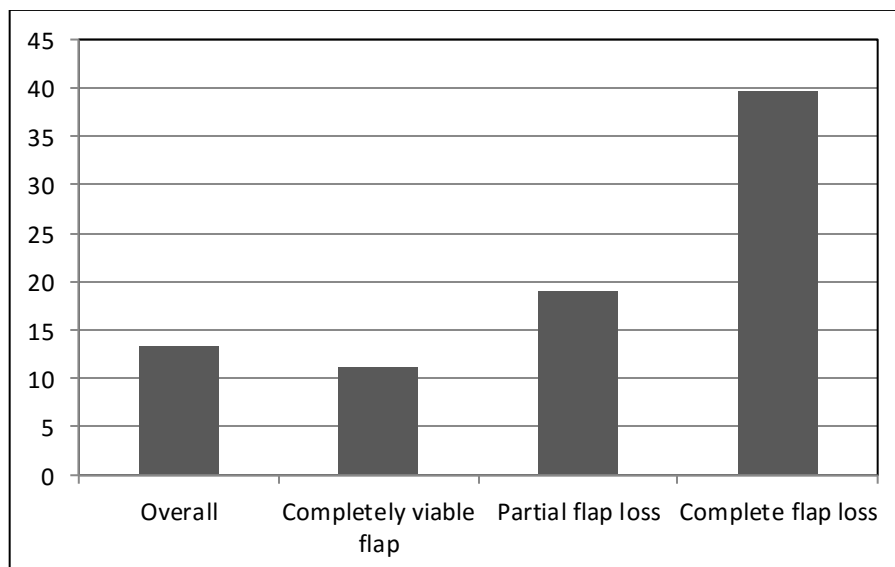
**Figure 1: Flap salvage outcomes.**

Patient	Details	Co-morbidities	Flap used	Complication	Treatment
1	69 male SCC alveolus/mandible	Hypertension Hypercholesterolemia	FFF	Necrosis of skin paddle	Debridement & secondary closure
2	76 female SCC floor of mouth	Hypertension Smoker	FFF	Partial skin paddle loss	Conservative
3	66 male SCC floor of mouth	Smoker	FFF	Partial skin paddle loss	Conservative
4	59 female SCC tongue & floor of mouth	Hypertension Smoker	FRFF	Partial loss	Conservative
5	67 male SCC cheek	None	ALTF	Partial loss	Debridement & secondary closure

**Table 7: Partial flap loss summary.**

Patient	Details	Co-morbidities	Flap used	Treatment
1	62 male SCC retromolar trigone	Atrial fibrillation Hypertension Smoker	FFF	Flap excised and secondary closure over recon plate.
2	60 female SCC floor of mouth	Smoker	FRFF	Failed salvage. Repeat FRFF: complete loss. Salvage with tongue flap.
3	63 male SCC floor of mouth	Hypertension Smoker Diabetic Frequent alcohol use	FFF	Repeat FFF: complete loss. Temporalis flap: failure. Repeat temporalis flap: failure. Healed by secondary intention. 108 days in hospital.
4	58 male SCC tongue & floor of mouth	Hypertension Smoker	FRFF	Healed by secondary intention.
5	49 male SCC tongue	Smoker	FRFF	Haematoma, failed salvage. Pectoralis major flap: loss of skin paddle, muscle viable. Split skin graft of muscle.
6	27 female SCC buccal mucosa	HIV infection	ALTF	Failed salvage. Flap excised and split skin graft.

**Table 8: Complete flap loss summary**



**Figure 2: Hospital stay (days) according to flap survival.**

## **Discussion:**

It is widely accepted that successful free flap reconstruction of the head and neck following tumour ablation is superior to alternative methods in terms of both function and aesthetics [12]. All patients undergoing free flap reconstruction in this study had advanced neoplastic disease on presentation, had at least one comorbid medical condition, and a large percentage were smokers or had received pre-operative radiotherapy. Limited operative time makes pre-operative evaluation and flap selection even more critical than it may be in a more developed environment.

Despite the wide variety of free flaps now available, it is evident from this study and others that reducing the variety of flaps utilised by the reconstructive team is important to decrease complication rates and time to adjuvant therapy [13, 14]. Numerous authors subscribe to this philosophy, provided that the reconstructive requirements of the defect are met [12, 13, 15, 16].

After reviewing 728 free flap head and neck reconstruction cases, Disa *et al* recommended the use of four free flaps, (RF, FF, rectus abdominus, and jejunal) [13]. Jones *et al* advocated the use of seven free flaps (RF, FF, rectus abdominus, jejunal, latissimus dorsi, scapular, and iliac crest) after reviewing their series of 305 reconstructions [15]. Gurtner and Evans preferred the combination of the RF, rectus abdominus, latissimus dorsi, and jejunal flaps [16].

These authors may differ with respect to their specific workhorse flaps, but the principle of limiting flap selection remains the same. We do not believe that limiting the selection of free flap reconstructions has in any way compromised the anatomico-functional outcomes. Kroll *et al* demonstrated that free flap selection may impact the likelihood of flap survival, as some donor sites appear to have higher inherent risk of failure than others [5].

This unit prefers the combination of flaps advocated by Lutz and Wei [12] for head and neck reconstruction (RF, FF and ALT). Table 9 summarises some of the motivations for selecting this combination of flaps. The surgical and nursing teams easily familiarise themselves with and can anticipate the requirements to streamline these procedures, and so limit operative time. The ALT flap in particular, has become increasingly more popular [17, 18], with numerous authors advocating its use as the frontline choice for head and neck reconstruction, when bone is not required. Thinning of the ALT flap allows it to be used instead of the RF flap when thin pliable tissue is needed, without the conspicuous donor site associated with the RF flap [19].

Flap choice has been influenced by the pre-requisite of having a simultaneous two-team approach for tumour excision and flap elevation. This decision has undoubtedly contributed to reduced operative time and probably also to fewer cases of intra-operative hypothermia, which has been shown to correlate with post-operative complications. The long vascular

pedicles of these flaps have usually avoided the use of vein grafts, which have also been correlated with an increased risk of free flap failure [20, 21].

Both senior reconstructive surgeons use x4.5 ocular loupe magnification for both flap elevation and anastomosis. Serletti *et al.* found that loupes are adequate for most anastomoses, but comfort with using an operating microscope is advocated when required [22]. It is this unit's preference to make use of the operating microscope for free flaps in children. Pieptu and Luchian have shown that loupe magnification is adequate for microanastomosis of vessels greater than 1.5 mm [23]. Loupe-only microsurgery can be justified on the grounds of cost-effectiveness, portability and improved operator freedom and extends the realm of microsurgery from the exclusive application in large academic hospitals to smaller facilities [24].

Most thrombotic complications occur within the first 24 to 48 hours after free tissue transfer, and haematomas generally present within the first 72 hours [25]. Early identification of flap-threatening complications allows for early surgical intervention and a greater likelihood of flap salvage [26]. There is no consensus regarding the ideal duration and frequency of free flap monitoring in an intensive care environment. Cornejo suggested one-to-two hourly free flap monitoring in an intensive care unit for the first 72 hours [25]. This is not feasible in our setting as resource limitations dictate that most of our patients are transferred to the general ward the morning after surgery.

Furthermore, our institution lacks nursing staff trained in free flap assessment, and thus, the plastic surgery resident is required to fulfill this role. As plastic surgery is a relatively understaffed division within the department of surgery, regular and frequent flap assessment logistically challenging. Initiatives to train nursing staff in flap physiology and monitoring have been advocated and may improve the early detection of compromised flaps. Invasive monitoring devices to corroborate clinical assessments were seldom used (4 out of 100 flaps). All of our successful salvage attempts occurred in the first 24 hours post-surgery.

Success rates between 90 and 99 % have been consistently reported for microvascular head and neck reconstruction. Suh *et al.* reported a complete flap loss rate of 0.8 % and a partial loss rate of 3 % in a series of 400 free flaps in 388 patients [27]. Disa *et al.* reported a complete flap loss rate of 1.4 % and a partial loss rate of 3 % in a series of 726 free flaps in 698 patients [13]. The complete loss rate in this series was 6 % and the partial loss rate was 5 %. None of the partial losses required a second flap. All three unsuccessful flap salvage attempts occurred after the first 24 hours. Increasing the post-operative intensive care/PAHCU stay to that of international standards and prioritising flap salvage surgery in the emergency operating room could potentially improve our flap salvage rate.

Numerous technologies have been developed with the aim of making microsurgical procedures safer, more reliable and with lower complication rates. The aim of this paper is not to suggest that these technologies are unjustified in their use. It is merely to highlight that a successful microvascular head and neck reconstructive service is possible in a resource-constrained environment.

## **Conclusion:**

Free flap reconstruction following head and neck extirpative surgery can be reliably undertaken in under-resourced settings. Limitations in the availability of pre-operative radiological investigations, invasive monitoring devices, anastomotic devices and intensive care are not barriers to providing a successful service. Limiting flap selection to reliable workhorse flaps with large caliber pedicles allows anastomosis under loupe magnification with low complete flap loss rates. A two-team approach facilitates shorter operating times, which may contribute to these results.

## **References:**

1. Daniel RK, Taylor GI (1973) Distant transfer of an island flap by microvascular anastomosis. *Plast Reconstr Surg* 52:111-117
2. Woods JE (1987) Reconstruction in head and neck cancer. *Ann Plast Surg* 18:209-211
3. Blackwell KE (1999) Unsurpassed reliability of free flap for head and neck reconstruction. *Arch Otolaryngol Head Neck Surg* 125: 295-299
4. Kroll SS, Evans GR, Goldberg D et al (1997) A comparison of resource costs for head and neck reconstruction with free and pectoralis major flaps. *Plast Reconstr Surg* 99: 1282-1286
5. Kroll SS, Schusterman MA, Reece GP (1996) Choice of flap and incidence of free flap success. *Plast Reconstr Surg* 98:459-463
6. Soutar DS, Scheker LR, Tanner NSB et al (1983) The radial forearm flap. A versatile method for intraoral reconstruction. *Br J Plast Surg* 36:1-8
7. Wei F-C, Jain V, Celik N et al (2002) Have we found the ideal soft tissue flap? An experience with 672 anterolateral thigh flaps. *Plast Reconstr Surg* 109:2219-2226
8. Koshima I, Fukuda H, Yamamoto H et al (1993) Free anterolateral thigh flaps for reconstruction of head and neck defects. *Plast Reconstr Surg* 92:412-418
9. Wong C-H, Wei F-C (2010) Microsurgical free flap in head and neck reconstruction. *Head Neck* 32:1236-1245
10. Jarvis MA, Jarvis CL, Jones PRM et al (2000) Reliability of Allen's test in selection of patients for radial artery harvest. *Ann Thorac Surg* 70:1362-1365
11. Abu-Omar Y, Mussa S, Anastasiadis K et al (2004) Duplex ultrasonography predicts safety of radial artery harvest in the presence of an abnormal Allen test. *Ann Thorac Surg* 77: 116-119
12. Lutz S, Wei F-C (2005) Microsurgical workhorse flaps in head and neck reconstruction. *Clin Plast Surg* 32:421-430
13. Disa JJ, Pusic AL, Hidalgo DH et al (2001) Simplifying microvascular head and neck reconstruction: a rational approach to donor site selection. *Ann Plast Surg* 47:385-389
14. Disa JJ, Hu QY, Hidalgo D (1997) Retrospective review of 400 consecutive free flap reconstructions for oncologic surgical defects. *Ann Surg Oncol* 4:663-669
15. Jones NF, Johnson JT, Shestak KC et al (1996) Microsurgical re- construction of the head and neck: interdisciplinary collaboration between head and neck surgeons and plastic surgeons in 305 cases. *Ann Plast Surg* 36:37-43

16. Gurtner GC, Evans GRD (2000) Advances in head and neck reconstruction. *Plast Reconstr Surg* 106:672-683
17. Wei FC, Jain V, Celik N et al (2002) Have we found an ideal soft tissue flap? An experience with 672 anteriolateral thigh flaps. *Plast Reconstr Surg* 109:2219-2226.
18. Ali RS, Bluebond-Langer, Rodriguez ED et al (2009) The versatility of the anteriolateral thigh flap. *Plast Reconstr Surg* 124:e395-407.
19. Huang CH, Chen HC, Huang YL et al (2004) Comparison of the radial forearm flap and the thinned anteriolateral thigh cutaneous flap for reconstruction of tongue defects: an evaluation of donor-site morbidity. *Plast Reconstr Surg* 114:1704-1710.
20. Jones NF, Johnson JT, Shestak KC et al (1996) Microsurgical reconstruction of the head and neck: interdisciplinary collaboration between head and neck surgeons and plastic surgeons in 305 cases. *Ann Plast Surg* 36:37-43
21. Schusterman MA, Miller MJ, Reece GP et al (1994) A single center's experience with 308 free flaps for repair of head and neck cancer defects. *Plast Reconstr Surg* 93:472-478
22. Serletti JM, Deuber MA, Guidera PM et al (1995) Comparison of the operating microscope and loupes for free microvascular tissue transfer. *Plast Reconstr Surg* 95:270-276
23. Pieptu G, Luchian S (2003) Loupes only microsurgery. *Microsurgery* 23:181-188
24. Shenaq S, Klebuc MJA, Vargo D (1995) Free-tissue transfer with the aid of loupe magnification: experience with 251 procedures. *Plast Reconstr Surg* 95:261-269
25. Cornejo A, Ivatury S, Crane CN et al (2013) Analysis of free flap complications and utilization of intensive care unit monitoring. *J Reconstr Microsurg* 29:473-479
26. Chen KT, Mardini S, Chuang DC et al (2007) Timing of the presentation of the first signs of vascular compromise dictates the salvage outcome of free flap transfers. *Plast Reconstr Surg* 120:187-195

## Loupe magnification for head and neck free flap reconstruction in a developing country

Gary dos Passos<sup>1</sup> · Alan D. Rogers<sup>1,2</sup> · Christopher E. Price<sup>1</sup> · Conrad H. Pienaar<sup>1</sup> · Jacobus E. van Zyl<sup>1</sup> · Johannes J. Fagan<sup>3</sup> · Donald A. Hudson<sup>1</sup>

Received: 5 February 2015 / Accepted: 6 May 2015 / Published online: 31 May 2015  
 © Springer-Verlag Berlin Heidelberg 2015

### Abstract

**Background** Free tissue transfer has become the standard of care for the reconstruction of head and neck oncological defects. The Grootte Schuur Hospital provides a microsurgical reconstructive service in a resource-limited setting, without access to venous couplers, invasive monitoring devices, modern microscopes or sophisticated pre-operative imaging. The reconstructive surgeons perform all anastomoses under ×4.5 loupe magnification.

**Methods** A retrospective chart review was undertaken of cases performed by the service over a 3-year period. Demographic factors, indications for flap cover, operative details (flap used, duration and lowest recorded temperature), intensive care and hospital length of stay, and other outcomes were recorded and evaluated (including flap and systemic complications, donor site morbidity, haematomas as well as returns to theatre).

**Results** Over a 36-month period, 109 flaps for head and neck reconstruction were performed. The main indication for surgery was squamous cell carcinoma of the oral cavity. The

mean operating time for resection and reconstruction was 6.02 h (range of 4 to 12 h). Virtually, all reconstructions were performed using one of either radial forearm, free fibula or anterolateral thigh flaps. We report a complete flap loss rate of 6 %. All four successful salvages were undertaken in the early (less than 24 h) post-operative period. Hypothermia intra-operatively appears to correlate very closely with pejorative outcomes.

**Conclusions** By restricting reconstructive options to three main 'workhorse' flaps and by utilising a simultaneous two-team approach for tumour ablation and flap elevation, success rates comparable to international standards have been achieved. Limited resources should not be regarded as an impassable barrier to providing a successful microvascular head and neck reconstructive service.

Level of Evidence: Level III, risk/prognostic study.

**Keywords** Head and neck reconstruction · Microvascular surgery · Microsurgery · Limited resources · Developing country · Loupe magnification · Free flap · Outcomes

✉ Alan D. Rogers  
 rogersadr@gmail.com

<sup>1</sup> Division of Plastic, Reconstructive and Maxillofacial Surgery, Department of Surgery, Grootte Schuur Hospital, University of Cape Town, Cape Town, South Africa

<sup>2</sup> Division of Plastic Surgery, Department of Surgery, Sunnybrook Health Sciences Centre, University of Toronto, Toronto, Canada

<sup>3</sup> Division of Otorhinolaryngology, Department of Surgery, Grootte Schuur Hospital, University of Cape Town, Cape Town, South Africa

### Introduction

Although the first free microvascular tissue transfer was reported as early as 1973 [1], there was limited enthusiasm for making use of free flaps to reconstruct head and neck defects until the late 1980s [2]. This reluctance stemmed from concerns relating to the reliability of a technique that was dependent on small-vessel anastomosis and concerns about complications and cost.

Free microvascular tissue transfer has proved to be extremely versatile and reliable, however, with several centres reporting

very low flap failure rates, with acceptable donor site morbidity and perioperative complications. It has become the preferred method of reconstruction for the majority of major head and neck defects [3]. Furthermore, it may in fact have a cost-benefit over traditional pedicled flaps in selected patients [4]. Since the first described case by Panje in 1976, reported flap success rates have ranged between 90 and 99 % [5].

Groote Schuur Hospital has a multidisciplinary head and neck service which has provided a free flap reconstruction service for head and neck oncological defects for more than 20 years. The team includes an oncologist, an otorhinolaryngologist, who performs the extirpative surgery, an anaesthetist, and plastic surgeons, who perform the free flap reconstruction.

The aims of the study were to:

1. Investigate acute outcomes of free tissue transfer reconstruction for head and neck resection defects at Groote Schuur Hospital
2. Compare these results with those of developed world units
3. Determine if there is a need to adapt our preferred reconstructive options, monitoring protocols and techniques

## Material and methods

This unit performs a major head and neck tumour resection requiring reconstruction with free tissue transfer every week. All patients are assessed at a multidisciplinary head and neck oncology clinic at which time the choice of reconstruction is made. Decisions regarding the primary pathology are corroborated with directed imaging modalities including panorex and CT scans.

Whenever possible, flaps with a long vascular pedicle and large diameter blood vessels are selected. With few exceptions, the free radial forearm (RF), free fibular (FF) or free anterolateral thigh (ALT) flaps are used. The minimal bulk and pliability of the RF [6] makes it our first choice for the reconstruction of smaller defects and those requiring mobility. The ALT is chosen for larger defects and when bulk is required [7]. Thinning of the ALT to reduce bulk [8] is not performed. The FF, providing unparalleled quantity and quality of bone [9], is chosen whenever a bone defect is to be reconstructed.

Resource restrictions limit the use of pre-operative investigations, and therefore, neither CT/MR angiography nor ultrasound Doppler is routinely used to assess donor vessel

**Table 1** Patient comorbidities

Comorbidity	Number of patients
None	18
Smoker	72
Hypertension	23
Frequent alcohol use	17
HIV infection	4
Epilepsy	3
Hypercholesterolemia	2
Diabetes mellitus	2
Atrial fibrillation	1
Hypothyroidism	1
Intravenous drug abuse	1

patency. Donor vessels are assessed clinically. An Allen test is performed if a RF is planned even though it has questionable clinical validity [10] and should probably be supplemented with an ultrasound Doppler assessment of collateral ulnar artery flow [11]. Angiography is only used when a FF is planned in patients with an abnormal clinical examination or if there is a history of claudication or significant lower limb trauma and was not required in this case series.

Resection of the primary tumour and elevation of the flap are performed simultaneously by the two surgical teams to reduce operative duration and exposure to hypothermia. Reconstruction plates are bent intra-operatively based on the extirpated defect. Pre-bent plates are not utilised. Ocular loupes ( $\times 4.5$  magnification) are used for both flap elevation and microvascular anastomosis. All microvascular anastomoses are hand sutured. Vein grafts are avoided. Local rather than systemic intra-operative anticoagulation is used. All patients have thromboprophylactic stockings and intermittent pneumatic calf compression applied to lower limbs not required for flap

**Table 2** Histological diagnosis of resected lesions

Histological diagnosis	Number of patients
Squamous cell carcinoma	80
Sarcoma variants	7
Adenocarcinoma	5
Basal cell carcinoma	3
Ameloblastoma	2
Other	3

**Table 3** Tumour site

Tumour site	Number of patients
Tongue and/or floor of the mouth	49
Lower alveolus and/or mandible	21
Primary skin malignancy	9
Upper alveolus and/or maxilla	8
Retromolar trigone	4
Buccal mucosa	3
Tonsil and/or soft palate	2
Orbital	2
Temporal	1
Hypopharynx	1

elevation. Warming blankets are routinely utilised for regions of the body not operated. Closed suction drains are routinely utilised and are positioned and secured some distance away from the anastomoses, usually in the posterior triangle of the neck. Donor sites are closed primarily where possible, but are usually skin grafted, and dressed with negative pressure wound therapy, 'crouton dressings' or other types of tie-over dressings.

Post-operatively, all patients are monitored in an intensive care or post-anaesthetic high care unit (PAHCU) setting for the first night following surgery. Patients usually have a tracheostomy performed, but are seldom ventilated post-operatively. Variables closely monitored and corrected include haemodynamic status (including arterial catheter monitoring), urine output, temperature, pain control, output from suction drains, development of haematomas and the maintenance of a neutral head position. Drains are removed after drainage is less than 50 ml

**Table 4** Additional procedures at time of tumour ablation

Procedure	Number of patients
Panendoscopy	2
Panendoscopy and tracheostomy	6
Panendoscopy and MRND	6
Panendoscopy, tracheostomy and MRND	73
Panendoscopy, tracheostomy and BMRND	9
Panendoscopy, tracheostomy and SND	1
Panendoscopy and superficial parotidectomy	1
Panendoscopy, parotidectomy and MRND	2

MRND modified radical neck dissection, BMRND bilateral modified radical neck dissection, SND selective neck dissection

**Table 5** Free flaps used

Free flap	Number of patients
Free fibula flap (FF)	36
Free radial forearm flap (RF)	35
Anterolateral thigh flap (ALT)	26
Free vastus lateralis flap	1
Free iliac crest flap	1
Free jejunum	1

per 24-h period. All patients received chlorhexidine mouthwash, perioperative broad spectrum antibiotics and prophylaxis against thromboembolism.

Regular clinical assessment of patient and flap is carried out by the plastic surgery trainee who participated in the procedure, paying particular attention to flap colour, temperature, congestion and bleeding (speed and colour) after needle stick. Invasive flap monitoring (e.g. implantable Doppler and tissue oximetry devices) is rarely used. Due to resource constraints, most patients return to the general ward the following day, where all invasive monitoring (arterial and central venous lines) is discontinued and flap monitoring is reduced to three times daily. Although there is a low threshold to return a patient to the operating theatre during the first 48-h period (concern about flap perfusion or a haematoma), salvage surgery is often delayed by other surgical emergencies competing for emergency theatre time.

A retrospective chart review was undertaken of all patients undergoing free tissue transfer reconstructions for head and neck resection defects at Grootte Schuur Hospital over a 36-month period from July 2007 to June 2010. Data collected included patient demographics (age and sex), pathological type and site of tumour, comorbidities, primary reconstructive surgeon, free flap donor site(s), recipient artery and vein,

**Table 6** Recipient artery for free tissue transfer

Recipient artery	Number of patients
Facial	86
Superior thyroid	7
Transverse cervical	2
Lingual	2
Occipital	1
Superficial temporal	1
External carotid	1

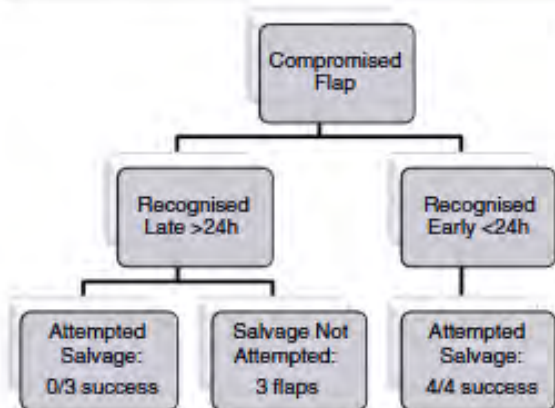


Fig. 1 Flap salvage outcomes

operative time, lowest recorded intra-operative temperature, additional procedures (e.g. tracheostomy and neck dissection), length of high care/intensive care stay, total hospital stay, flap viability (complete survival, partial loss, complete loss), flap and donor site complications and additional surgical interventions required during the acute period.

## Results

One hundred and nine free flap reconstructions (mean of 36 per year) were performed over the 36-month period, of which 100 records were available for analysis. Eight records were excluded as they were incomplete or unavailable. One patient died on account of acute myocardial infarction and was excluded from further analysis. There were 65 males and 35 females with a mean age of 55 years (range 19 to 83 years).

The majority of patients had at least one known comorbidity, with smoking, hypertension and frequent alcohol use being the most common (Table 1).

Squamous cell carcinoma (SCC) was the most frequent histological diagnosis, affecting 80 of the 100 patients (Table 2). The oral cavity was involved in 87 patients. Specifically, the most commonly involved structures were the tongue and/or floor of the mouth and the mandible and/or lower alveolus (Table 3). Six patients had orbital involvement (four of the skin malignancies included in this series invaded the orbit). All tumour ablations and neck dissections were performed by or under supervision of the sixth author (JJF). Additional procedures at the time of tumour ablation are tabulated in Table 4.

Most reconstructive procedures were performed by one of two senior plastic surgeons (fourth and fifth authors), with 50 by CHP and 49 by JEvZ. The most commonly used free flaps were the FF, RF and the ALT (Table 5). Free jejunum was used for one hypopharyngeal reconstruction and one free vastus lateralis myocutaneous flap was used in a patient who was found to have inadequate perforators to use a classic ALT. The internal jugular vein (or branch thereof) was used for the recipient vein in all cases. A vein graft was used in only one case, to limit tension on the anastomosis in the case of a free fibula flap reconstruction of an extensive mandibular defect. The facial artery was the most commonly used (87 patients) recipient artery (Table 6).

The mean total operating time (combined resection and reconstruction) was 6.02 h, with a range of 4 to 12 h. The mean time when FF, RF and ALT were used was 6.50, 5.46 and 6.13 h, respectively. Nineteen patients were hypothermic during the procedure, registering core temperatures under 35 °C.

Table 7 Partial flap loss summary

Patient	Details	Comorbidities	Flap used	Complication	Treatment
1	69, male SCC alveolus/mandible	Hypertension Hypercholesterolemia	FF	Necrosis of skin paddle	Debridement and secondary closure
2	76, female SCC floor of the mouth	Hypertension Smoker	FF	Partial skin paddle loss	Conservative
3	66, male SCC floor of the mouth	Smoker	FF	Partial skin paddle loss	Conservative
4	59, female SCC tongue and floor of the mouth	Hypertension Smoker	RF	Partial loss	Conservative
5	67, male SCC cheek	None	ALT	Partial loss	Debridement and secondary closure

**Table 8** Complete flap loss summary

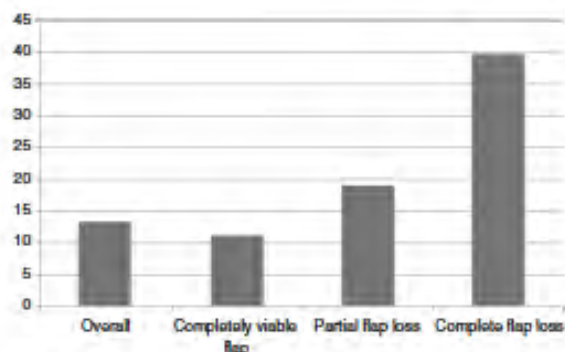
Patient	Details	Comorbidities	Flap used	Treatment
1	62, male SCC retromolar trigone	Atrial fibrillation Hypertension Smoker	FF	Flap excised and secondary closure over recon plate
2	60, female SCC floor of the mouth	Smoker	RF	Failed salvage Repeat FRFF: complete loss Salvage with tongue flap
3	63, male SCC floor of the mouth	Hypertension Smoker Diabetic Frequent alcohol use	FF	Repeat FFF: complete loss Temporalis flap: failure Repeat temporalis flap: failure Healed by secondary intention 108 days in hospital
4	58, male SCC tongue and floor of the mouth	Hypertension Smoker	RF	Healed by secondary intention
5	49, male SCC tongue	Smoker	RF	Haematoma, failed salvage Pectoralis major flap: loss of skin paddle, muscle viable Split skin graft of muscle
6	27, female SCC buccal mucosa	HIV infection	ALT	Failed salvage Flap excised and split skin graft

Early in-hospital complications occurred in 35 % of patients. Complications were significantly more prevalent in individuals who had been hypothermic intra-operatively. Five patients had to be returned to the operating theatre for drainage of haematoma. One of these patients had a compromised flap with unsuccessful salvage. Salvage was attempted in seven compromised flaps with four (57 %) successes. All four successful salvages were undertaken in the early (less than 24 h) post-operative period. The three unsuccessful salvage attempts occurred during the late (more than 24 h) post-operative period (Fig. 1).

Partial flap loss occurred in five patients (5 %). None of these patients required a second flap. Two of them required

debridement and secondary closure. The other three were managed conservatively (Table 7). Complete flap loss occurred in six patients (6 %). Three patients required additional flaps for closure (Table 8).

Flap dehiscence occurred in 10 patients (excluding the five patients with partial flap loss). Eight of these were minor and were treated conservatively. One patient required debridement and re-advancement with re-suturing of the flap. Another patient was treated with debridement, followed by dressings. Neck wound dehiscence occurred in nine patients. Five of these patients were treated conservatively with dressings. One patient required debridement and secondary closure. One patient required debridement and split skin grafting. Two

**Fig. 2** Hospital stay (days) according to flap survival**Table 9** Advantages of choosing RF, FF and ALT as workhorse flaps in head and neck reconstruction

Single patient position
Simultaneous ablation and flap harvest (two teams)
Harvest and anastomosis by loupe magnification
Long pedicles (avoiding vein grafts)
Large calibre vessels for anastomosis
Venability in design
Adequate volume
Consistent anatomy
Minimal donor site morbidity

patients required debridement and pectoralis major flaps for closure of the neck.

One patient developed a chyle leak and lung atelectasis which responded to conservative management. Two patients required debridement and repeat split skin grafting of their FF donor sites.

The mean intensive care or PAHCU stay was 1.14 days (range of 0 to 3 days). The mean hospital stay was 13.3 days (range of 5 to 108). Complete flap survival occurred in 89 patients. For completely viable flaps, the mean stay was 11.2 days (range of 5 to 34). This increased to 19 days (range of 12 to 27) when there was partial flap loss and to 39.7 days (range of 18 to 108) for complete loss (Fig. 2).

## Discussion

It is widely accepted that successful free flap reconstruction of the head and neck following tumour ablation is superior to alternative methods in terms of both function and aesthetics [12].

All patients undergoing free flap reconstruction in this study had significant and advanced neoplastic disease on presentation, had at least one comorbid medical condition, and a significant percentage were smokers or had received pre-operative radiotherapy. Limited operative time makes pre-operative evaluation and flap selection even more critical than it may be in a more developed environment.

Despite the wide variety of free flaps now available, it is evident from this study and others that reducing the variety of flaps utilised by the reconstructive team is important to decrease complication rates and time to adjuvant therapy [13, 14]. Numerous authors subscribe to this philosophy, provided that the reconstructive requirements of the defect are met [12, 13, 15, 16]. These authors may differ with respect to their specific workhorse flaps, but the principle of limiting flap selection remains the same. We do not believe that limiting the selection of free flap reconstructions has in any way compromised the anatomic-functional outcomes. Kroll et al. demonstrated that free flap selection may impact the likelihood of flap survival, as some donor sites appear to have higher inherent risk of failure than others [5].

This unit prefers the combination of flaps advocated by Lutz and Wei [12] for head and neck reconstruction (RF, FF and ALT). Table 9 summarises some of the motivations for selecting this combination of flaps. The surgical and nursing

teams easily familiarise themselves with and can anticipate the requirements to streamline these procedures, and so limit operative time.

Flap choice has been influenced by the pre-requisite of having a simultaneous two-team approach for tumour excision and flap elevation. This decision has undoubtedly contributed to reduced operative time and probably also to fewer cases of intra-operative hypothermia, which has been shown to correlate with post-operative complications. The long vascular pedicles of these flaps have usually avoided the use of vein grafts, which have also been correlated with an increased risk of free flap failure [17, 18].

Both senior reconstructive surgeons (CHP and JEvZ) use  $\times 4.5$  ocular loupe magnification for both flap elevation and anastomosis. Serletti et al. found that loupes are adequate for most anastomoses, but comfort with using an operating microscope is advocated when required [19]. It is this unit's preference to make use of the operating microscope for free flaps in children. Pieptu and Luchian have shown that loupe magnification is adequate for microanastomosis of vessels greater than 1.5 mm [20]. Loupe-only microsurgery can be justified on the grounds of cost-effectiveness, portability and improved operator freedom and extends the realm of microsurgery from the exclusive application in large academic hospitals to smaller facilities [21].

Most thrombotic complications occur within the first 24 to 48 h after free tissue transfer, and haematomas generally present within the first 72 h [22]. Early identification of flap-threatening complications allows for early surgical intervention and a greater likelihood of flap salvage [23]. There is no consensus regarding the ideal duration and frequency of free flap monitoring in an intensive care environment. Cornejo recently suggested one-to-two hourly free flap monitoring in an intensive care unit for the first 72 h [22]. This is not feasible in our setting as resource limitations dictate that most of our patients are transferred to the general ward the morning after surgery.

Furthermore, our institution lacks nursing staff trained in free flap assessment, and thus, the plastic surgery resident is required to fulfill this role. As plastic surgery is a relatively understaffed division within the department of surgery, regular and frequent flap assessment logistically challenging. Initiatives to train nursing staff in flap physiology and monitoring have been advocated and may improve the early detection of compromised flaps. Invasive monitoring devices to corroborate clinical assessments were seldom used (4 out of 100 flaps). All

of our successful salvage attempts occurred in the first 24 h post-surgery.

Success rates between 90 and 99 % have been consistently reported for microvascular head and neck reconstruction. Suh et al. reported a complete flap loss rate of 0.8 % and a partial loss rate of 3 % in a series of 400 free flaps in 388 patients [24]. Disa et al. reported a complete flap loss rate of 1.4 % and a partial loss rate of 3 % in a series of 726 free flaps in 698 patients [13]. The complete loss rate in this series was 6 % and the partial loss rate was 5 %. None of the partial losses required a second flap. All three unsuccessful flap salvage attempts occurred after the first 24 h. Increasing the post-operative intensive care/PAHCU stay to that of international standards and prioritising flap salvage surgery in the emergency operating room could potentially improve our flap salvage rate.

Numerous technologies have been developed with the aim of making microsurgical procedures safer, more reliable and with lower complication rates. The aim of this paper is not to suggest that these technologies are unjustified in their use. It is merely to highlight that a successful microvascular head and neck reconstructive service is possible in a resource-constrained environment.

## Conclusion

Free flap reconstruction following head and neck extirpative surgery can be reliably undertaken in under-resourced settings. Limitations in the availability of pre-operative radiological investigations, invasive monitoring devices, anastomotic devices and intensive care are not barriers to providing a successful service. Limiting flap selection to reliable workhorse flaps with large calibre pedicles allows anastomosis under loupe magnification with low complete flap loss rates. A two-team approach facilitates shorter operating times, which may contribute to these results.

**Ethical Standards** This retrospective study has been approved by the Groote Schuur Hospital and University of Cape Town ethics committee in accordance with the ethical standards set forth in the 1964 Declaration of Helsinki and its amendments. No details are included in the study that may be used to identify its subjects. All authors have approved of the study and consent to its submission for publication.

**Conflicts of Interest** Gary dos Passos, Alan D. Rogers, Christopher E. Price, Conrad H. Pienaar, Donald A. Hudson, Jacobus E. van Zyl, Johannes J. Fagan declare that they have no conflict of interest.

## References

1. Daniel RK, Taylor GI (1973) Distant transfer of an island flap by microvascular anastomosis. *Plast Reconstr Surg* 52:111–117
2. Woods JE (1987) Reconstruction in head and neck cancer. *Ann Plast Surg* 18:209–211
3. Blackwell KE (1999) Unsurpassed reliability of free flap for head and neck reconstruction. *Arch Otolaryngol Head Neck Surg* 125: 295–299
4. Kroll SS, Evans GR, Goldberg D et al (1997) A comparison of resource costs for head and neck reconstruction with free and pectoralis major flaps. *Plast Reconstr Surg* 99: 1282–1286
5. Kroll SS, Schusterman MA, Reece GP (1996) Choice of flap and incidence of free flap success. *Plast Reconstr Surg* 98:459–463
6. Soutar DS, Scheker LR, Tanner NSB et al (1983) The radial forearm flap. A versatile method for intra-oral reconstruction. *Br J Plast Surg* 36:1–8
7. Wei F-C, Jain V, Celik N et al (2002) Have we found the ideal soft tissue flap? An experience with 672 anterolateral thigh flaps. *Plast Reconstr Surg* 109:2219–2226
8. Koshima I, Fukuda H, Yamamoto H et al (1993) Free anterolateral thigh flaps for reconstruction of head and neck defects. *Plast Reconstr Surg* 92:412–418
9. Wong C-H, Wei F-C (2010) Microsurgical free flap in head and neck reconstruction. *Head Neck* 32:1236–1245
10. Jarvis MA, Jarvis CL, Jones PRM et al (2000) Reliability of Allen's test in selection of patients for radial artery harvest. *Ann Thorac Surg* 70:1362–1365
11. Abu-Omar Y, Mussa S, Anastasiadis K et al (2004) Duplex ultrasonography predicts safety of radial artery harvest in the presence of an abnormal Allen test. *Ann Thorac Surg* 77: 116–119
12. Lutz S, Wei F-C (2005) Microsurgical workhorse flaps in head and neck reconstruction. *Clin Plast Surg* 32:421–430
13. Disa JJ, Pusic AL, Hidalgo DH et al (2001) Simplifying microvascular head and neck reconstruction: a rational approach to donor site selection. *Ann Plast Surg* 47:385–389
14. Disa JJ, Hu QY, Hidalgo D (1997) Retrospective review of 400 consecutive free flap reconstructions for oncologic surgical defects. *Ann Surg Oncol* 4:663–669
15. Jones NF, Johnson JT, Shestak KC et al (1996) Microsurgical reconstruction of the head and neck: interdisciplinary collaboration between head and neck surgeons and plastic surgeons in 305 cases. *Ann Plast Surg* 36:37–43
16. Gartner GC, Evans GRD (2000) Advances in head and neck reconstruction. *Plast Reconstr Surg* 106:672–683
17. Jones NF, Johnson JT, Shestak KC et al (1996) Microsurgical reconstruction of the head and neck: interdisciplinary collaboration between head and neck surgeons and plastic surgeons in 305 cases. *Ann Plast Surg* 36:37–43
18. Schusterman MA, Miller MJ, Reece GP et al (1994) A single center's experience with 308 free flaps for repair of head and neck cancer defects. *Plast Reconstr Surg* 93:472–478
19. Serletti JM, Deuber MA, Guidara PM et al (1995) Comparison of the operating microscope and loupes for free microvascular tissue transfer. *Plast Reconstr Surg* 95:270–276
20. Pieptu G, Luchian S (2003) Loupes only microsurgery. *Microsurgery* 23:181–188
21. Shenaq S, Klebac MJA, Vargo D (1995) Free-tissue transfer with the aid of loupe magnification: experience with 251 procedures. *Plast Reconstr Surg* 95:261–269
22. Cornejo A, Ivatury S, Crane CN et al (2013) Analysis of free flap complications and utilization of intensive care unit monitoring. *J Reconstr Microsurg* 29:473–479

23. Chen KT, Mardini S, Chuang DC et al (2007) Timing of the presentation of the first signs of vascular compromise dictates the salvage outcome of free flap transfers. *Plast Reconstr Surg* 120:187–195
24. Suh JD, Sercarz JA, Abemayor E et al (2004) Analysis of outcome and complications in 400 cases of microvascular head and neck reconstruction. *Arch Otolaryngol Head Neck Surg* 130:962–966