

The copyright of this thesis vests in the author. No quotation from it or information derived from it is to be published without full acknowledgement of the source. The thesis is to be used for private study or non-commercial research purposes only.

Published by the University of Cape Town (UCT) in terms of the non-exclusive license granted to UCT by the author.

PERIPHERAL NEUROPATHIES OF CHILDHOOD:

Jo M Wilmshurst

MB BS (London), MRCP (London), FCP (SA)

Thesis presented for the Degree of

DOCTOR OF MEDICINE

Department of Paediatric Neurology

School of Child and Adolescent Health

Faculty of Health Sciences

UNIVERSITY OF CAPE TOWN



CONTENTS

| | PAGE |
|---|--------------|
| Title | 1 |
| Contents | 2-7 |
| Acknowledgements | 8 |
| Funding | 9 |
| Previous publications | 9 |
| Permissions / ethics | 9 |
| Declaration | 10 |
| Synopsis | 11-13 |
| Chapter 1: | 14-39 |
| <i>Introduction, literature review and diagnostic tables</i> | |
| Table 1.1: Summary of previous large studies of peripheral neuropathies in childhood | 18 |
| Table 1.2: Hereditary peripheral neuropathies | 19-29 |
| Figure 1.1: Transverse section of HNPP | 30 |
| Figure 1.2: Transverse section of CMT3 | 30 |
| Figure 1.3: Electron micrograph of CMTX | 31 |
| Table 1.3: Neurodegenerative disorders with peripheral neuropathy | 32-33 |
| Table 1.4: Specific protein deficiency or mutation | 34-39 |
| Chapter 2: | 40-67 |
| <i>The role of nerve biopsy</i> | |
| a. Introduction | 41-42 |
| b. Principles and technique | 42-54 |
| Figure 2.1: Transverse section of a patient with CMT1A | 45 |
| Figure 2.2: Transverse section of a patient with CMT | 45 |
| Figure 2.3: Teased fibre appearance of demyelination | 46 |
| Figure 2.4: Teased fibre appearance of axonal degeneration | 47 |
| Figure 2.5: Electron micrograph of neuroaxonal dystrophy. | 48 |
| Figure 2.6: Electron micrograph of a patient with P ₀ mutation | 49 |

| | |
|---|---------------|
| Figure 2.7: Electron micrograph active axonal degeneration. | 50 |
| Figure 2.8: Normal MF diameter changes with age. ⁴ | 54 |
| c. Biopsy findings in relevant diseases | 54-64 |
| Table 2.1: Inflammatory and infectious disorders | 56 |
| Table 2.2: Neurodegenerative and Metabolic disorders | 57-59 |
| Figure 2.9: Transverse section from a patient with Friedreich's ataxia | 59 |
| Figure 2.10: Electron micrograph from a patient with giant axonal neuropathy. | 60 |
| Figure 2.11: Electron micrograph of a patient with metachromatic leukodystrophy | 61 |
| Figure 2.12: Transverse section from a patient with Cockayne syndrome | 61 |
| Table 2.3: Toxic, nutritional deficiencies and miscellaneous | 62-63 |
| Figure 2.13: Transverse section from a patient with neurofibromatosis. | 64 |
| d. Conclusion | 64 |
| e. Case examples | 65-67 |
| Chapter 3: | 68-125 |
| <i>Chronic Peripheral Neuropathies Presenting In Childhood – 37 Years of Data from an Australian Population</i> | |
| a. Summary | 68-69 |
| b. Introduction | 70 |
| c. Methodology | 70-71 |
| d. Results | 72-115 |
| Figure 3.1: Summary of total group with peripheral neuropathies | 73 |
| Table 3.1: Summary of the motor sensory neuropathies with genetic correlation | 73-74 |
| Figure 3.2: Flow chart of patient breakdown leading to definitive genetic confirmation in the CMT group | 75 |

| | |
|--|---------------|
| 1. Hereditary neuropathies | 76-108 |
| Figure 3.3: Charcot Marie Tooth diseases broad categories | 76 |
| i. Demyelinating forms of CMT | 77-85 |
| Figure 3.4: Demyelinating group n=73 | 77 |
| Figure 3.4a: Teased fibre analysis of patient with CMT1A. | 78 |
| Figure 3.4b: Light microscopy study of a patient with CMT3 due to PMP22 mutation. | 81 |
| Figure 3.4c: Teased fibre analysis of a patient with CMT3 due to myelin protein zero mutation | 81 |
| Figure 3.4d: Transverse section of a CMT4B patient | 84 |
| Figure 3.4e: Transverse section of a patient with CMT4B due to fabrin mutation. | 85 |
| ii. Axonal forms of CMT | 86-96 |
| Figure 3.5: Axonal neuropathies n=81 | 86 |
| Figure 3.5a: Transverse section of a patient with EOHMSN due to mitofusin mutation. | 90 |
| Figure 3.5b: EM section of a patient with MFN2 mutation with reduced myelinated fibre density and an onion bulb formation | 91 |
| Figures 3.5c i and ii EM from a patient with confirmed MFN2 mutation | 91-92 |
| Figure 3.6: Hereditary sensory and autonomic neuropathies n=6 | 96 |
| iii. Mixed forms of CMT | 97-98 |
| Figure 3.7: Mixed axonal / demyelinating neuropathies n=7 | 97 |
| iv. Summary of genetic data from patients with CMT spectrum | 99-101 |

| | |
|--|----------------|
| Figure 3.8: Summary of patients who underwent genetic screens | 99 |
| Figure 3.9: Summary of the genetic mutations | 101 |
| Peripheral neuropathies associated with inherited disorders | 102-108 |
| v. Neurodegenerative and metabolic disorders | 102-107 |
| Figure 3.10: Neurodegenerative progressive and metabolic disorders with peripheral neuropathy | 102 |
| vi. Inherited structural disorders | 107-108 |
| 2. Acquired neuropathies | 109-115 |
| Figure 3.11: Acquired disorders and pathology types n=48 | 109 |
| Figure 3.11a: Teased fibre analysis of a patient with CIDP | 111 |
| Figure 3.11b: Transverse section of a patient with a vasculitic neuropathy. | 113 |
| Figure 3.11c: Transverse section 3 month old infant, vasculitis demonstrating recanalised vessel. | 114 |
| Figure 3.11d: Transverse section perineuroma | 114 |
| d. Discussion | 116-125 |
| Chapter 4: | 126-141 |
| <i>Peripheral Neuropathies presenting in Infancy from an Australian Population</i> | |
| a. Summary | 126 |
| b. Introduction | 127 |
| c. Method | 127 |
| d. Results | 128-136 |
| Table 4.1: Summary of the diagnostic categories of infantile-onset peripheral neuropathy | 128 |
| Figure 4.1: Sural nerve section electron micrography plate from a patient with myelin protein zero mutation CMT3. | 130 |
| Figure 4.2: Transverse section from the sural nerve of a patient with CMT with myelin-outfolding | 131 |

| | |
|---|----------------|
| e. Discussion | 137-140 |
| Algorithm 4.1: An approach through nerve conduction studies to Hereditary Motor and Sensory Neuropathies | 141 |
| Chapter 5: | 142-183 |
| <i>Children presenting with Chronic Peripheral neuropathy in a South African population</i> | |
| a. Summary | 142 |
| b. Introduction | 143-145 |
| c. Methods | 145-146 |
| d. Results | 146-178 |
| Figure 5.1: Summary of hereditary peripheral neuropathies | 146 |
| Figure 5.2: Patient with confirmed CMT1A. | 148 |
| Figure 5.3: Nerve biopsy of a patient with CMT1A | 149 |
| Figure 5.4: Affected CMT3 patient | 150 |
| Figure 5.5. Nerve biopsy of a patient with clinical phenotype of CMT3 | 151 |
| Figure 5.6. Electron microscopy onion bulb formation | 151 |
| Figure 5.7: Hands from father and son with CMT2. | 153 |
| Figure 5.8: Electron microscopy of patient with axonal neurophysiology but genetic diagnosis of CMT1A. | 154 |
| Figure 5.9: Clinical phenotype of patient with EOHMSN | 155 |
| Figure 5.10: (a & b). Clinical phenotype of patient with EOHMSN with extreme distal wasting. | 156 |
| Figures 5.11 Light microscopy from patient in Figure 5.9. | 156 |
| Figure 5.12 (a & b): Light microscopy patient with EOHMSN (Figure 5.10) | 157 |
| Figure 5.13: EM from the patient in Figure 5.10 | 158 |
| Figure 5.14 (a & b). Girl with miscellaneous axonal disease | 160 |
| Figure 5.15: Patient with SIANR | 162 |
| Figure 5.16: Patient with the juvenile form of SIANR | 162 |

| | |
|--|----------------|
| Figure 5.17: Chest X-ray patient with juvenile SIANR | 163 |
| Figure 5.18. Muscle biopsy patient with Vitamin E deficiency | 167. |
| Figure 5.19: Summary of acquired conditions | 170 |
| Figure 5.20a. Image of the hands from the eleven year old girl with HIV-1 infection | 172 |
| Figure 5.20b. The lower limbs of the patient in Figure 5.20a. | 173 |
| Table 5.1: Summary of the patients who underwent peripheral nerve biopsy | 174-178 |
| e. Discussion | 179-183 |
| Chapter 6: | 184-193 |
| <i>Conclusion and recommendations - guideline approach to investigations and diagnosis of Peripheral Neuropathies in childhood in resource-limited setting</i> | |
| Table 6.1: Summary of conditions commonly associated with specific clinical features. | 192 |
| Figure 6.1: Approach to the child with suspected peripheral neuropathy in a resource-limited setting | 193 |
| Figure 6.2: Approach to the HIV infected child with distal weakness / sensory disturbances. | 194 |
| References | 195-220 |

Acknowledgements

My husband Mark, and daughters Tabitha and Jasmine for their understanding and support.

My parents and friends for their support both with child care and patient interest in a topic they had never heard of. My father especially, for proof reading the text.

The neurology team at Red Cross Children's Hospital who covered my clinical duties for 3 months.

Dr Komala Pillay and her team for their assistance with the South African histopathology analysis and providing images of the biopsy samples.

My Supervisors,

Professor Robert Ouvrier, Head of the Institute for Neuromuscular Research at The Children's Hospital at Westmead in Sydney, Australia, for his great support and patience during the creation of this magnum opus.

Prof Colin Sinclair-Smith, Head of Histopathology, at Red Cross Children's Hospital, University of Cape Town, who sadly died in October 2008, for his enthusiasm and interest in such a specialized area.

Professor Heather Zar, who stepped in at short notice to cover Colin's place.

Dr Min Wang from the Institute of Nerve Research, University of Sydney for assisting me with access to the pathology and images from many of the patients.

The children and their carers described in the study.

The following specialists were all involved in parts of the study:

Prof John D Pollard, Consultant Neurologist, Nerve Research Laboratory, University of Sydney (assistance in data analysis).

Prof Garth Nicholson, Consultant in Medical Genetics, University of Sydney, Molecular Medicine Laboratory, NSW (assistance in collation of genetic data).

Dr Jayne Antony, Consultant Paediatric Neurologist, The Children's Hospital at Westmead (assistance in collation of relevant clinical data).

Prof Cai Fangchen (assistance in early establishment of database).

Dr Christopher Rittey, Consultant Paediatric Neurologist, Ryegate Children's Centre, Sheffield, UK (assistance in early establishment of database).

Funding

The time to write up the final thesis was funded in part by the Harry Crossly Fellowship, UCT, allowing a sabbatical to be taken and one trip to Sydney to meet with the thesis supervisor.

Previous publications

Chapters 2 and 4 were previously published, Chapter 2 as a book chapter and Chapter 4 in a peer reviewed journal. Permission has been granted by the publishers to include the data in this thesis.

Chapter 2: Nerve Biopsy. Jo M Wilmshurst, Robert A Ouvrier. Neuromuscular Disorders of Infancy, Childhood and Adolescence. A Clinician's Approach. Editors H. Royden Jones, Darryl De Vivo, Basil Darras, 2003, 91-109 ⁽¹⁾

Chapter 4: Wilmshurst JM, Pollard JD, Nicholson G, Antony J and Ouvrier R. Peripheral neuropathies presenting under one year of age. Dev Med Child Neurol 2003;45:408-414⁽²⁾

Permission:

Consent was obtained from the children (assent) and carers for inclusion of their images in this thesis.

Ethics approval was attained. REC REF: 026/2006

DECLARATION

I, Jo M Wilmshurst, hereby declare that the work on which this dissertation is based is my original work (except where acknowledgements indicate otherwise) and that neither the whole work nor any part of it has been, is being, or is to be submitted for another degree in this or any other university.

I empower the university to reproduce for the purpose of research either the whole or any portion of the contents in any manner whatsoever.

Signature:

Date:.....

University of Cape Town

SYNOPSIS

PERIPHERAL NEUROPATHIES OF CHILDHOOD

This thesis is divided into six chapters, the first of which is a summary of the literature assessing the available data on children presenting in childhood with chronic peripheral neuropathies (Table 1.1). Specific clinical, neurophysiological and histopathological markers are noted which may aid in diagnosing children in the setting where DNA testing is not available or affordable. These markers can also be used to assist more targeted genetic screens, thus allowing more direct investigations and avoiding more costly unnecessarily extensive studies. The terminology has become complex and the genetic labels (CMT1-4) have reverted to being the preferred terms for most conditions, further divided into multiple sub-groups. Tables 1.2-1.4 summarise the key data on the many sub-groups of conditions dominated by peripheral neuropathy, combining clinical, neurophysiological, histopathology and molecular genetic data for each condition – “endotyping”. The tables illustrate the heterogeneity of the various conditions and the frequent occurrence of different genotypes producing a given phenotype. The area is complex and such endotyping tables are essential for the clinician to attempt to maintain any level of confidence when categorising patients. Table 1.4 lists the known gene mutations and / or protein deficiencies with the current insight into their roles in nerve function. This data in Table 1.4 facilitates an understanding of how nerve damage arises from these mutations and how the same defect can manifest with either axonal or demyelinating pathology. Tables 1.2 and 1.4 also demonstrate how the categorisation of the previously rigid concepts of “axonal”, “demyelinating” and “mixed” categories can become unrealistic with some conditions, e.g. X-linked Charcot Marie Tooth (CMTX), and early onset neuronal hereditary motor sensory neuropathy (EOHMSN).

Chapter 2 examines the role of peripheral nerve biopsy. The chapter describes the technique used, the evolution and maturation of nerves in children and the information potentially gained from the investigation. A series of tables and images concentrate on conditions with particular features, some of which are diagnostic in isolation, others provide useful guides to direct further investigations.

Chapter 3 addresses a very large cohort (n=296) of Australian children presenting over a 37 year period with nerve biopsy-confirmed peripheral neuropathy. A study of this size

with the combined information on clinical, neurophysiological, neuropathological and, in many cases, molecular genetic peripheral nerve data is unlikely to be repeated again as the role of molecular genetics has resulted in fewer patients proceeding to nerve biopsy. Some of the patients who presented early in the study predated storage of DNA. A proportion of those from slightly more recently acquired definitive diagnoses with the combined data and subsequent molecular genetic analysis – often up to 20 years after data was originally collected: hence the importance of storage of DNA. The descriptions from Tables 1.2-1.4 were used to categorise the patients. Most molecular genetic studies were available for this group of patients but despite this a significant proportion of the database with a clear genetic aetiology remained without a molecular genetic diagnosis. This was most marked for the proportion of patients from the axonal / mixed group (15/37) compared to the demyelinating group (34/50). This data was important to illustrate the proportions of the more common conditions previously considered predominantly adult onset disorders (CMT1 and CMT2). Further, by nature of the large numbers of patients included in the study, otherwise rare mutations (e.g. *PRPS1* and *frabin* mutations) were also identified. The data also emphasised the importance of EOHMSN in the spectrum of childhood onset hereditary neuropathies, this group representing 22% of the axonal degenerative group.

Chapter 4 reviews in more detail a sub-group of children from the larger cohort, described in chapter 3, who presented under one year of age with symptoms of peripheral neuropathy (n=50). Similar findings were evident for the discrepancy in making definitive diagnoses in the axonal group compared to the demyelinating group. The range in pathology and heterogeneity was illustrated by groupings such as the representation of a number of infants with CMT1. The findings highlighted the condition severe infantile axonal neuropathy with respiratory failure (SIANR) (genetic category- *SMARD1*) – as an important and severe peripheral neuropathy presenting in infancy.

Chapter 5 reviews a smaller cohort of patients (n=123) managed in a dedicated paediatric neuromuscular service in South Africa. All patients with chronic peripheral neuropathy were included, although particular attention was placed on those who underwent peripheral nerve biopsy (n=15) and / or molecular genetics (n=22). Of the group, the proportion with acquired disorders dominated (n=79), mainly related to severe forms of acute

inflammatory demyelinating polyradiculoneuropathy (AIDP). Five patients with HIV disease were referred into the neuromuscular service with neuropathies related to the toxic effects of antiretroviral agents. It is suspected that the proportion of children with neuropathies related to HIV is higher but based on anecdotal experience these patients may remain sub-clinical or are managed in other services (infectious diseases). Investigations in these patients were useful, with 11 out of the 22 patients who had molecular genetic screens performed gaining a definitive diagnosis. Similarly, all the children who underwent peripheral nerve biopsies (n=15) had findings which were of diagnostic use. Variations from international figures were striking for the smaller number of patients with demyelinating forms of CMT – most markedly in the CMT1 group in which no patients of indigenous African ancestry were detected. The CMT1A gene does not appear to manifest as commonly in this population group. The study illustrated the limitations of incomplete genetic analyses and the need for comprehensive genetic screens to be available for the more relevant mutations in childhood, namely duplications and deletions at chromosome 17p11.2-12, *myelin protein zero*, *PMP22*, *connexin32*, *mitofusin* and *SMARD1* mutations.

Chapter 6 summarises the key points from the previous chapters in comparison with the available literature. The author proposes guidelines for the optimal investigation of children with chronic peripheral neuropathies, especially for those based in resource-limited settings.

CHAPTER 1

INTRODUCTION AND LITERATURE SUMMARY.

Peripheral nerve disease was described by Galen (AD 130-200) over a thousand years ago.⁽³⁾ Detailed anatomical illustrations were documented by Andreas Vesalius in his major work "De humani corporis fabrica" in 1543.⁽⁴⁾ Over the last two centuries an explosion in knowledge in the area has occurred, with a further exponential increase in the last 20 years mostly related to understandings in the field of molecular genetics.⁽⁵⁾ Although some degree of diagnostic closure was possible for a number of the hereditary peripheral neuropathies, this has not been the end point of knowledge but only the beginning. The diverse clinical presentations and molecular genetic heterogeneity of hereditary peripheral neuropathies are significant.

Acquired forms of peripheral neuropathy were described in the 1800's for diphtheria, epidemic polyneuritis, lead and arsenic intoxication, diabetes, alcoholism and beri-beri.⁽⁶⁻¹⁰⁾ Guillain and colleagues described the currently termed condition acute inflammatory polyradiculoneuropathy in 1916.⁽¹¹⁾ Although the clinical features of the condition were originally described by Octave Landry in 1859.⁽¹²⁾ Chronic inflammatory polyradiculopathy received recognition over the following years.⁽¹³⁻¹⁶⁾ Toxic neuropathies and neuropathy secondary to malignancy were also investigated further.^(17,18)

Of the neurodegenerative conditions associated with peripheral neuropathy, probably the most recognised is that described by Friedreich in 1863. This disorder, now referred to as Friedreich ataxia, required a nerve biopsy study to consolidate the diagnosis prior to a molecular genetic screen becoming available.⁽¹⁹⁾

According to available facilities early descriptions of hereditary peripheral neuropathies were based on clinical appearance, with recognition of subtypes evolving later.⁽²⁰⁻²²⁾ Electrophysiological data in the 1960s further enhanced understanding of disease processes, followed by more detailed pathological assessments.⁽²³⁻²⁶⁾ The categorisations of the hereditary peripheral neuropathies evolved further. Molecular genetics further sub-divided the major groups with to date over 44 mutations identified.⁽⁵⁾ However, most patients are limited to the original method of assessment – that of clinical assessment. The majority of the international paediatric population are based in countries where access to neurophysiological,

histopathology and molecular genetic screens are lacking. It remains important for centres with the capacity to perform all these studies to build a knowledge base which can be used to guide centres in resource-poor settings.

Peripheral neuropathies in childhood are underdescribed in the medical literature. There are few large studies reviewing the pattern of disease morphology.^(2,27-32) Table 1.1 summarises some of the larger studies with a breakdown of the types of neuropathy occurring in childhood. The peripheral neuropathies which occur in childhood differ from those in adults with a far greater number of inherited conditions. Early recognition of peripheral neuropathies enables accurate genetic advice and detection of pathology.

Charcot-Marie-Tooth disease is the commonest neuromuscular disorder based on adult prevalence studies or combined studies with paediatric figures integrated, with an estimated prevalence of 17-40:100,000.^(33,34) CMT1 is the commonest demyelinating disorder, representing 70% of all demyelinating CMT.⁽³⁵⁻³⁷⁾ Of the available paediatric studies this figure is closer to 50%.^(29,30) Most studies are from European and North American centres. In our Australian biopsy based study (chapter 3) the patients with CMT1 represented 37% of the demyelinating group, with 27% having CMT1A. The CMT1 group constituted 16.7% of the total inherited peripheral neuropathy group. This figure is an under representation of the prevalence since following identification of the 17p duplication defect in 1991, patients underwent molecular genetic assessment primarily and only proceeded to nerve biopsy if the result was not diagnostic.^(38,39)

Children present with more autosomal recessive forms related to point mutations. Lack of access to centres with the capacity to undertake these complex molecular genetic screens requires that clinicians base their diagnoses on a combination of clinical phenotype, neurophysiology and histopathology. As stated above, knowledge to interpret this information is hard to access.

As the spectrum of molecular genetic screens has expanded (<http://neuromuscular.wustl.edu/> and <http://194.167.35.195/>)⁽⁴⁰⁾ it has become evident that the heterogeneity in phenotypic presentations is wide with the same mutation resulting in different types of neuropathies and even overlapping myopathies and neuropathies.^(5,41,42) The previous broad categories of the "HMSN" group have required further subdivisions to cater for

the expanding number of mutations which can result in the same clinical phenotype.

Following on from this and with the exponential increase in the recognised mutations, the terminology has shifted back to use of the term “CMT” for most diagnostic labels instead of “HMSN”. CMT1 (HMSN type 1) is currently subdivided into subtypes 1A-F. Rather than reducing the need for histopathological analysis of peripheral nerve samples it remains necessary to combine the data in order to delineate disease categories with greater accuracy and understanding. For example confirming that a patient has a myelin protein zero mutation will not clarify to the clinician the type of neuropathy as this mutation is described in numerous forms of peripheral neuropathy including hypomyelinating, de- and re- myelinating as well as axonal degenerative forms.⁽⁴³⁾ This scenario requires *endotyping*, in which a diagnosis is established through combining information from various sources including the clinical phenotype, the neurophysiology findings, the peripheral nerve histology and if possible the molecular genetics.

The typical clinical phenotype of a patient with peripheral neuropathy consists of distal wasting and weakness, especially of the peroneal compartment, usually with some distal sensory impairment (to touch, pain and vibration, and occasional ataxia related to impaired joint position discrimination), skeletal deformities (pes cavus and hammer toes), contractures (scoliosis, claw hand “main en griffe”) and decreased or absent deep tendon reflexes.⁽⁴⁴⁾ As such many of the peripheral nerve diseases cannot be subdivided based on the clinical appearance alone. Specific phenotypes are evident for a few peripheral nerve diseases, but with inevitable overlap of other sub-types (Table 1.2).

Dysfunction in many of the proteins, even when they primarily affect the myelin, lead to eventual axonal degeneration⁽⁴⁵⁻⁴⁷⁾. It is the axonal degeneration which is suggested to lead to the clinical deterioration.⁽⁴⁶⁾

Table 1.2 summarises the primary hereditary motor and sensory disorders including their main clinical features, described neurophysiological and histopathological findings and the latest associated gene location. Table 1.3 summarises similar features for various neurodegenerative disorders with associated peripheral neuropathies. Table 1.4 summarises the known gene mutations and or protein deficiencies, describing their apparent role and

associated disorders. These tables form the basis for the diagnostic categories used later in the text.

The data was tabulated because the field has become complex; new findings are reported separately both in the clinical and genetic texts. As the field expands the information and correlation in the terminology have run the risk of pulling apart and functioning separately. There are cases of CMT sub-categories having conflicting protein mutations associated with them and likewise the same mutation labelled for several CMT sub-groups. The tables are an attempt to present the information in a comprehensive but accessible manner and to correlate the molecular genetic data with the the clinical, neurophysiological and histopathological findings.

In Chapter 3 we present our findings from patients who underwent nerve biopsy examination between 1969 and 2007 at The Nerve Research Laboratory, University of Sydney. Those who were symptomatic in the infantile period were reported in an earlier publication but still included in this study for completeness and are described in detail in Chapter 4.⁽²⁾ Tables 1.2-1.4 were used as guides to the diagnostic categories subsequently used in the study.

Table 1.1: Summary of previous large studies of peripheral neuropathies in childhood ^(2,27-32)

| Series | Total cases | Bx n=x | Acquired (e.g. AIDP, Toxins) | Inherited Metabolic | Inherited Neurodegenerative | Inherited Pure peripheral neuropathy | Other |
|--|--------------------|---------------|-------------------------------------|----------------------------|------------------------------------|---|--------------|
| Gamstorp(1968) ⁽²⁷⁾ | 43 | 3 | 13 | 4 | 13 | 13 | - |
| Evans (1979) ⁽²⁸⁾ | 61 | 0 | 25 | 4 | 16 | 12 | 4 |
| Hagberg & Lyon (1981) “hereditary neuropathies” ⁽²⁹⁾ | 287 | NA | 0 | 0 | 0 | 261 | 26 |
| Hagberg & Westerberg (1983) ⁽³⁰⁾ | 120 | 68 | 6 | 16 | 21 | 66 | 11 |
| Rossi <i>et al</i> (1983) pts with HMSN ⁽³¹⁾ | 24 | 11 | 0 | 0 | 0 | 24 | 0 |
| Ouvrier and Macleod (1988) ⁽³²⁾ | 125 | 125 | 16 | 15 | 27 | 62 | 5 |
| Wilmsurst <i>et al</i> (2003) ⁽²⁾ | 50 | 50 | - | 4 | 7 | 30 | 9 |

Table 1.2: Hereditary peripheral neuropathies⁽⁴⁸⁾ (<http://neuromuscular.wustl.edu/> and <http://194.167.35.195/>)

| Disorder(OMIM) | Clinical features | NCS | Biopsy findings | Genetic screen |
|--|---|---|--|---|
| CMT1 (Demyelinating) | | | | |
| CMT IA-F⁽⁴⁹⁾ (HMSN type I) | Autosomal dominant. Onset 1-4 th decade. Predominant distal weakness, decreased DTR, mild distal sensory loss, hypertrophy of nerves common | Delayed motor and sensory conduction studies. Motor studies typically <38m/s | Segmental demyelination and remyelination with onion bulb formations and axonal loss | |
| 1A (118220) | CMT1A: Commonest form recognised, seen in all ages (but more adults) | | | A <i>PMP22</i> , ⁽⁵⁰⁻⁵⁵⁾ |
| 1B (118200) | CMT1B: Approx 5% of CMT1 group | | | B <i>MPZ</i> ⁽⁵⁶⁻⁵⁹⁾ |
| 1C (601098) | CMT1C: Childhood onset, start with abnormal gait, then distal weakness and wasting, occasional nerve hypertrophy. Rarely early onset hearing loss | | | C <i>LITAF</i> ⁽⁶⁰⁾ |
| 1D (607678) | CMT1D: possible cranial nerve involvement. Late onset in childhood or early adulthood | | | D <i>EGR2</i> ^(61,62) |
| 1E (118300) | CMT1E associated with deafness (29-45%) | | | E <i>PMP22</i> ^(63,64) |
| 1F (607734) | | | CMT1F: Giant axons described. | F <i>NEFL</i> ⁽⁶⁵⁾ |
| Hereditary Neuropathy with liability to Pressure Palsies (Tomaculous neuropathy) (162500) | Autosomal dominant. Recurrent mononeuropathy simplex or multiplex frequently related to trauma. | Significant slowing of motor and sensory conduction velocity in clinically affected, but also in unaffected, nerves | Tomaculous or sausage like swellings of myelin sheaths, transnodal myelination and segmental demyelination. Figure 1.1 | <i>PMP 22</i> deletion ⁽⁶⁶⁻⁶⁸⁾ |
| Slowed nerve conduction velocities | Often Miscellaneous group. Incidentally detected with no clinical symptoms Autosomal dominant | Moderately slowed conduction velocities | Myelin thinning with no evidence of degeneration or regeneration. Static process. | <i>ARHGEF10</i> ^(69,70) |

| CMT2 (axonal) | | | | |
|---|---|---|--|--|
| CMT 2 A-L (HMSN type II) | Autosomal dominant (A,B,D,E,F,G,I) ⁽⁷²⁾ . Autosomal recessive (B1, B2, H and K) ^(73,74) Clinically similar to CMT type I, except for later onset, absence of peripheral nerve enlargement and less marked weakness. | Nerve conduction velocities are greater than HMSN type I (>38m/s), but are below the normal range occasionally. | Neuronal atrophy and degeneration of peripheral motor and sensory neurons. | |
| 2A1 (118210) 2A2 (609260) A2 (=HMSN VI) | CMT2A: proximal weakness also present in 60%, prominent distal weakness, Optic atrophy and central involvement reported. Main form related to MFN2 mutations ⁽⁷⁵⁻⁷⁷⁾ | | | A1 <i>KIF1B</i> (one family) ⁽⁷⁹⁾ , A2. <i>MFN2</i> ^(80,81) |
| 2B (600882) 2B1 (605588) | CMT2B: severe sensory loss, often complications with infections, arthropathy, amputations, foot ulcers, distal weakness | | | B <i>RAB7</i> ⁽⁸²⁻⁸⁴⁾ B1 <i>LMNA</i> ^(42,85-87) |
| 2B2 (605589) | CMT2B2: Average onset 34 years (Costa Rican family) | | | B2 ? <i>MED25</i> ^(88,89) |
| 2C (606071) | CMT2C: vocal cord, diaphragm and respiratory involvement, decreased longevity | | | Linked to C12q23-q24 ^(90,91) |
| 2D (601472) D (allelic to dSMA) | CMT2D: upper limb predominance | | | D <i>GARS</i> ^(92,93) |
| 2E (607684) E (allelic CMT 1F) | CMT 2E – 30% associated with deafness, early childhood onset with gait abnormalities, occasional hyperkeratosis, increased sensory involvement | CMT2E: intermediate / slow NCS | CMT2E – giant fibres – similar to <i>GAN</i> ^(65,78) . | E <i>NEFL</i> ⁽⁶⁵⁾ |
| 2F (606595) 2G (608591) | CMT2F: Trophic changes feet and knees CMT2G: Onset 9-76 years, average 20 years, large Spanish family. But also severe form with early onset | | | F <i>HSPB1 (HSP27)</i> ^(94,95) G 12q12-q13 ⁽⁹⁶⁾ |
| 2H (607731) H (allelic CMT4A) - | CMT2H: pyramidal involvement, vocal cord involvement | CMT2H: intermediate / slow NCS | | H. <i>GDAP1</i> ^(71,71) |

| | | | | |
|---|---|---|--|---|
| <p>CMT4C2 in original publication⁽⁷¹⁾</p> <p>2I (607677) 2J (607736)</p> <p>2K (607831)</p> <p>2L (608673)</p> | <p>CMT I and J – possible late onset, pupillary anomalies, pain, hearing loss, dysphagia</p> <p>CMT2K: vocal cord paralysis, more severe early onset form</p> <p>CMT2L: occasional proximal leg weakness (like dHMNI), large Chinese family, 15-33 years. Scoliosis</p> | | | <p>I <i>MPZ</i>;⁽⁹⁷⁾ J <i>MPZ</i>;⁽⁹⁸⁾</p> <p>K: <i>GDAP</i>^(99,100)1</p> <p>L <i>HSPB8</i>; (<i>HSP22</i>)12q24⁽¹⁰¹⁾</p> |
| <p>HMSN II with onset in early childhood (EOHMSN)^(102,103) Severe early-onset axonal neuropathy (SEOAN)⁽¹⁰⁴⁾</p> | <p>Autosomal recessive. Weakness within first 5 yrs, rapid progression of weakness, usually complete paralysis below elbows and knees by teens, absent DTR, moderate sensory changes in most cases. Normal CSF protein. Occasional optic atrophy</p> | <p>Axonal pattern with axonal-degenerative polyneuropathy. Absent SNAPs, No response to stimulation in the CP nerve, UL nerves normal or mildly slowed. EMG denervation</p> | <p>Neuronal atrophy with degeneration of peripheral motor and sensory neurons. Marked reduction in MF density, especially of large MF. No demyelination or active axonal degeneration, occasional cluster formations. Increased Schwann cell nuclei.</p> | <p><i>MFN2</i>⁽¹⁰⁵⁾</p> |
| <p>Spinal muscular atrophy with respiratory distress type 1 (SMARD1) / Severe infantile axonal neuropathy with respiratory failure (SIANR)^(106,107) allelic dHMN6 New term distal SMA type 1 (dSMA1)⁽¹⁰⁷⁾ (604320)</p> | <p>Autosomal recessive. Onset in infancy (3-6 months), respiratory failure, progressive distal weakness, eventual plateau. No recovery</p> | <p>Absent conduction in most cases</p> | <p>Decreased myelinated fibre, no onion bulb formations, active axonal degeneration or active evidence of regeneration. Increased Schwann cell nuclei. Thin MF.</p> | <p><i>IGHMBP2</i>⁽¹⁰⁸⁾</p> |

| | | | | |
|---|---|---|--|--|
| <p>Hereditary motor and sensory neuropathy (HMSN-P) (Okinowa type)</p> | <p>Adult onset (after 30 years). Autosomal dominant. Slowly progressive proximal dominant area of weakness. Fasciculations of extremities and trunk. Raised creatine kinase, hyperlipidaemia, diabetes mellitus, eventual loss of ambulation, absent DTR, sensory disturbances. Most patients described from Japan.</p> | <p>Motor and sensory axonal neuropathy. SNAP, CMAP, MNCV and SNCV reduced or absent. EMG: fasciculations, fibrillations and neuromyotonic picture early on.</p> | <p>Reduced anterior horn cells, reduced MF density in the posterior funiculus, cauda equine, roots, posterior tibial nerve. Sural nerve does not have onion bulb formations.</p> | <p>3q13^(109,110)</p> |
| CMT3 and 4 | | | | |
| <p>CMT 3 (Dejerine-Sottas Syndrome) (145900)</p> | <p>Onset first 2 yrs, overall disability less severe than CMT 4. Hypotonia, motor delay by 1st yr, poor coordination, ataxia, distal weakness (max lower limbs), short stature. By second decade proximal weakness and hand and feet deformities. Nerve hypertrophy. Moderate to severe sensory loss. Scoliosis. Common cranial nerve involvement, nystagmus, deafness and, mild bifacial weakness. Raised CSF protein</p> | <p>Motor CV usually <10m/s SAP absent EMG chronic denervation</p> | <p>Decreased MF density. Thin MF Multiple OB formations. Increased trans fascicular diameter due to OB formations, collagen and Schwann cell proliferation. Figure 1.2</p> | <p><i>PMP22</i>⁽¹¹¹⁾, <i>MPZ</i>⁽¹¹²⁾, <i>PRX</i>⁽¹¹³⁾ <i>EGR2</i>⁽¹¹⁴⁾</p> |
| <p>CMT 4 (A-J)⁽¹¹⁵⁾⁽¹¹⁶⁾ autosomal recessive</p> <hr/> <p>4A (214400)</p> <hr/> <p>4B1 (601382)</p> | <p>Similar or slightly more severe clinical picture to CMT1 form, increased ataxia, areflexia, scoliosis. Nerve hypertrophy rare.</p> <hr/> <p>A < 2yrs, (adult 2K) Tunisian and Moroccan families. Severe progressive. Less severe European phenotypes.</p> <hr/> <p>B1 Ophthalmoplegia, vocal cord paralysis, facial, bulbar weakness (all</p> | <p>Moderate slowing of NCS.</p> <hr/> <p>A: 25-35m/s</p> <hr/> <p>B1 9-20m/s</p> | <p>Marked reduction of myelinated fibre density, with some well myelinated fibres, segmental demyelination and a few classic onion bulbs. In a few subtypes a higher frequency of OB, consisting of single or double basal laminae</p> <hr/> <p>A demyelinating or axonal. Hypomyelination and onion bulbs</p> <hr/> <p>B1 myelin-outfolding, loss of MF</p> | <hr/> <p>A <i>GDAP1</i>⁽¹¹⁸⁻¹²⁰⁾</p> <hr/> <p>B1 <i>MTM2</i>⁽¹²¹⁻¹²³⁾, (<i>MPZ</i>⁽¹²⁴⁾),</p> |

| | | | | |
|-----------------------|--|----------------------------|---|--|
| | infrequent). Weakness below 5 yrs, proximal and distal weakness, absent DTR | | | |
| 4B2 (604563) | B2 Early onset glaucoma. 1 st decade. In Tunisia, Japan and Turkey | B2: 15-30m/s | B2: myelin-outfolding, loss of MF | B2 <i>SBF2, MTM13</i> , (125,126) |
| 4C (601596) | C early-onset scoliosis, Algerian pop, glaucoma and neutropenia. 1 st and 2 nd decade | C: 4-37m/s | C: Basal membrane onion bulbs | C <i>SH3TC2 (KIAA1985)</i> (127,128) |
| 4D (601455) | D Closed gypsy pedigree; Onset < 10 years. Deafness (by 2 nd -3 rd decade) Tongue atrophy (HMSN-Lom) | D 10-20m/s | D: Hypomyelination, onion bulbs, myelin decompaction, axonal inclusions, loss MF | D <i>NDRG1</i> ^(129,130) |
| 4E (605253) | E: Congenital hypotonia | E: 5-20m/s | E severe loss of myelinated and unmyelinated fibres, OB formations and focally folded myelin sheaths | E <i>ERG2/KROX 20</i> ⁽¹⁶²⁾ , <i>MPZ</i> ⁽¹³¹⁾ |
| 4F (145900) | F Severely affected at birth, or by 7 years, AMC common, respiratory and feeding difficulties, often die young | F <5m/s | F cong hypomyelination. Very little myelin and virtually absent OBs | F <i>PRX</i> ^{(113)(132,133)} |
| 4G (605285) | G: type Russe. Onset 8-16 years. Origin Bulgaria | G 30-35m/s | G: Hypomyelination, Regenerating clusters | G. 10q22 ^(134,135) |
| 4H (609311) | H. Increased in Lebanese / Turkish. Onset infancy – childhood (1-2 years). Delayed motor milestones. Occasional scoliosis, Increased distal weakness, usually absent DTR. | H: <10m/s or absent | H: Hypomyelination, small onion bulbs and sometimes myelin outfoldings | H <i>FDG4</i> ⁽¹³⁶⁻¹³⁸⁾ |
| 4J (611228) | J: onset by 5 years. Severe disorder. Similarities to motor neurone disease ⁽¹¹⁷⁾ | J: 2-7m/s | J: Profound axonal loss, thinly myelinated fibres, de- and re-myelination | J <i>FIG4</i> ⁽¹³⁹⁾ |
| CCFDN (604168) | CCFDN: Congenital cataract, microcornea, facial dysmorphism, mental retardation, distal motor peripheral neuropathy | CCFDN: 19-33m/s | CCFDN: Diffuse hypomyelination | CCFDN: <i>CTDP1</i> ^(129,140) |

| Mixed pathology (axonal and demyelinating) | | | | |
|---|---|---|--|--|
| CMT X ^(116,141) X1 (302800) | X1: X-linked dominant. Onset 1 st -2 nd decade. Progressive wasting and weakness of distal limb musculature, especially hands, more marked in affected males than carrier females. | X1: Median nerve motor conduction studies < 40m/s (but faster than CMT1A) Intermediate slowing less uniform along nerves with dispersion more pronounced | Figure 1.3 X1: Axonal degeneration and regeneration with some evidence of segmental demyelination. Variable findings with some patients having cluster formations, but also thin myelin and onion bulb formations | X1: <i>GJB1 / Connexin 32</i> ^(144,145) |
| X2 (302801) | X2: X-linked recessive. Rare infantile onset, intellectual disability, females very mildly affected | X2: Mixed demyelinating / axonal | X2: Mixed demyelinating / axonal | X2: Xp22.2 ⁽¹⁴⁶⁾ |
| X3 (302802) | X3: X-linked recessive. +/- Spasticity. Females unaffected | X3: Mixed demyelinating / axonal | X3: Mixed demyelinating / axonal | X3: Xq26 ⁽¹⁴⁷⁾ |
| X4 (310490) | X4: X-linked. Severe neuropathy, Females very mildly affected Isolated case reports. Onset birth- early childhood. Slowly progressive. Many develop deafness by 5 years. Mental retardation commonly seen Occasional also with optic atrophy. (Cowchock syndrome) ⁽¹⁴²⁾ | X4: Axonal neuropathy. Motor CV mild delay (33-56m/s). Sensory very abnormal EMG: Denervation, large MUP and fasciculation | X4: Axonal neuropathy. Axonal loss and "sprouting" with no segmental demyelination or onion bulb formations | X4: Xq24-26.1 |
| X5 (311070) | X5: X-linked. Mild-moderate neuropathy, deafness, late optic atrophy ⁽¹⁴³⁾ Allelic with Rosenberg-Chutorian (optico-acoustic) neuropathy. | X5: Axonal neuropathy – mild demyelinating changes | X5: Axonal neuropathy – mild demyelinating changes | X5: Xq21.32-q24 / <i>PRPS1</i> ^(143,148,149) |

| | | | | |
|--|---|--|---|--|
| <p>Intermediate forms of CMT⁽¹⁵⁰⁾</p> <p>B (606482)</p> <p>C (608323)</p> <p>D (607791)</p> <p>A – autosomal rec form (608340)</p> | <p>Patients with this condition have neurophysiological results which fall between the axonal and demyelinating range.</p> <p>DI-CMTA: Italian family:</p> <p>DI-CMTB : American family</p> <p>DI-CMTC</p> <p>DI-CMTD: MPZ</p> <p><i>Overlap conditions</i> Recessive CMT with GADP1 mutations: (CMT2K&4A) Spanish and Tunisian family – severe childhood form reported. Also called DI-CMTA autosomal recessive form⁽¹⁵¹⁾ CMT with NF-L: (CMT1F & 2E) CMTX1</p> | <p>“Intermediate values” 30-40m/s – most accurate from median motor nerves. Some forms have normal NCS (DI-CMTB)</p> | <p>Axonal and demyelinating pathology. Combination of Schwann cell and axonal changes</p> | <p>DI-CMTA:chr10⁽¹⁵²⁻¹⁵⁴⁾</p> <p>DI-CMTB: <i>DNM2</i>^(155,156)</p> <p>DI-CMTC: chr 1⁽¹⁵⁷⁾, <i>YARS</i>⁽¹⁵⁸⁾</p> <p>DI-CMTD: <i>MPZ</i>⁽¹⁵⁹⁾</p> <p><i>Overlap</i> <i>GJB1</i>⁽¹⁵⁵⁾ <i>NF-L</i>^(65,160) <i>GDAP1</i>^(100,119,120,151,161,162)</p> |
| <p>Other HMSN and HMN syndromes</p> | | | | |
| <p>HMSN V / Spastic paraplegia with HMSN type V / CMT5 (CMT with pyramidal signs) (600631)</p> | <p>Variable inheritance. Spasticity in the lower limbs causing difficulty walking and toe walking. Autosomal recessive form associated with MR. Lower limb marked spasticity with little weakness, increased DTR, ext plantars, pes cavus, often distal amyotrophy. Expanding field with multiple subforms n=37^(40,163). Not all</p> | <p>Small / absent SNAPs. Motor studies axonal type</p> | <p>Sural nerve biopsy mildly reduced MF density</p> | <p><i>SPG3A, SPAST, NIPA1, KIAA0196, KIF5A, HSPD1, BSCL2, REEP1, ZFYVE27, SPG7, SPG20, SPG21, ALDH3A2, ALS2, L1CAM, PLP1</i> CMT with pyramidal</p> |

| | | | | |
|---|--|--|--|---|
| | associated with peripheral neuropathy. CMT with pyramidal signs part of HMSN V but described without spasticity ⁽¹⁶⁴⁾ . | | | signs: <i>MFN2</i> ⁽¹⁶⁴⁾ |
| HMSN VI ⁽¹⁷¹⁾ (allelic CMT2A) | Visual impairment due to optic atrophy. Dominant and recessive forms. Onset in first decade. Distal weakness, often proximal involvement too. Less sensory involvement. Scoliosis. | No response or motor conduction around 45m/s. Sensory often cannot stimulate | Demyelinating ⁽¹⁶⁵⁾ or axonal ⁽¹⁶⁶⁾ forms described. Mitochondrial alternations described ⁽¹⁶⁷⁾ . | <i>MFN2</i> |
| HMSN VII | HMSN with retinitis pigmentosa. CSF protein raised. Usually adult onset condition. Rare entity described in a few families mainly of adult onset ⁽¹⁶⁸⁾ . | | Nil specific | |
| Distal Hereditary Motor Neuronopathies (dHMN) ⁽¹⁶⁹⁾ | | Normal NCS, occasional mild slowing. EMG neurogenic | Sural nerve mostly normal. Muscle mild neurogenic atrophy with small angular fibres and small group atrophy. | |
| dHMNI (182960) | dHMN type I: Autosomal dominant – juvenile onset, distal weakness and wasting ⁽¹⁷⁰⁾ | | | dHMN type I 7q34-q36 ⁽¹⁷¹⁾ |
| dHMNII (608634) dHMNIJuv(158590) | dHMN type II autosomal dominant adult onset, distal weakness and wasting juvenile form (allelic CMT2F, CMT2L) | | | dHMN type II <i>HSPB8</i> (<i>HSP22</i>) ^(163,172,173) dHMN type II adult juvenile <i>HSPB1</i> ⁽⁹⁴⁾ |
| dHMNIII (607088) | dHMN type III. Autosomal recessive, adult onset, slow progressive muscle wasting and weakness, no diaphragmatic paralysis | | | dHMN type III 11q13 ⁽¹⁷⁴⁾ |
| dHMNIIV (697088) | dHMN type IV: Autosomal recessive, juvenile onset, severe muscle wasting | | | dHMN type IV 11q13 ^(174,175) |

| | | | | |
|---|--|---------------------------------------|--|---|
| | and weakness and diaphragmatic paralysis | | | |
| dHMNV (600794) | dHMN type V: (allelic CMT2D) Autosomal dominant, upper limb predominance, occasional pyramidal features | | | dHMN type V: <i>GARS</i> (92,176) |
| Silver syndrome (606158) | dHMN type V: Silver syndrome: Autosomal dominant, prominent hand muscle weakness and wasting, and mild to severe spasticity of the lower limbs. | | | dHMN type V: Silver syndrome <i>BSCL2</i> ⁽¹⁷⁷⁾ |
| dHMNVI (604320) | dHMN type VI (allelic SMARD1): Autosomal recessive severe infantile form with respiratory distress. | | | dHMN type VI (allelic <i>SMARD1</i>): <i>IGHMP2</i> ⁽¹⁰⁸⁾ |
| dHMNVII (158580) | dHMN type VII: Autosomal onset with vocal cord paralysis | | | dHMN type VII: 2q14 (178,179) |
| dHMNVIIIB(607641) | dHMN type VIIIB: Autosomal onset with vocal cord paralysis and facial weakness | | | dHMN type VIIIB <i>DCTN1</i> ⁽¹⁷⁹⁾ |
| | X-linked dHMN: X-linked recessive, juvenile onset with distal wasting and weakness | | | X-linked dHMN: Xq13-q21 (180) |
| ALS4 (602433) | dHMN/ ALS4: Autosomal dominant, early onset with pyramidal tract signs | | | dHMN/ ALS4: <i>SETX</i> ⁽¹⁸¹⁻¹⁸³⁾ |
| | dHMN-J: Autosomal recessive onset with pyramidal features | | | dHMN-J: 9p21.1-p121 (184,185) |
| Congenital distal SMA (600175) | Congenital distal SMA: Autosomal dominant congenital non-progressive distal HMN with contractures | | | Congenital distal SMA: 12q23-q24 ⁽¹⁸⁶⁾ |
| Peripheral neuropathy with agenesis of corpus callosum (Charlevoix disease or Andermann) | Autosomal recessive. Increased in French Canadian populations. Progressive axonal neuropathy. CNS malformations – absence / hypoplasia of the corpus callosum, early onset, developmental delay, areflexia, dysmorphology. Later increased motor | EMG: Denervation Axonal neuropathy | Axonal degeneration with secondary demyelination | <i>SLC12A6 (KCC3)</i> ⁽¹⁸⁷⁻¹⁸⁹⁾ |

| | | | | |
|--|--|---|--|--|
| Syndrome) (218000) | disability, hallucinatory psychosis. Death by 3 rd decade. | | | |
| Hereditary neuralgic amyotrophy (brachial plexus neuropathy)⁽¹⁹⁰⁾ (162100) | Autosomal dominant. Episodes of paralysis and muscle weakness initiated by severe pain. Onset can be from birth or later childhood but usually adult onset. Outcome usually good but some left with residual dysfunction. Episodes often triggered by infections, immunizations and stress. Some pedigrees dysmorphic with hypotelorism ^(191,192) | Normal or mildly prolonged motor NCV distal to the affected brachial plexus ⁽¹⁹³⁾ | Axonal degeneration distal to the brachial plexus. Inflammatory response. ⁽¹⁹⁴⁾ | <i>SEPT9</i> ^(195,196) |
| Hereditary sensory and autonomic neuropathies⁽¹⁹⁷⁾ | | | | |
| HSN (HSAN) 1 (162400) | 1: Autosomal dominant, Onset 2 nd -5 th decade. Predominant loss of pain and temperature sensation, preservation of vibration sense, lancinating pain, variable distal motor involvement ^(198,199) . <i>CMT2B: see above – acro-mutilating complications</i> 1B: Autosomal dominant, predominantly sensory neuropathy with cough and gastroesophageal reflux, rarely foot ulcers. More adult onset. Often hearing abnormal. | Normal to low-normal motor CV, disturbance of sensory conduction of variable severity. ^(200,201) | Primary axonal nerve damage. Marked decrease of unmyelinated fibres, as well as small and large MF in sural nerves | 1: <i>SPTLC1</i> ⁽²⁰²⁻²⁰⁴⁾ <i>CMT2B:RAB7</i> ⁽¹⁹⁷⁾ 1B: 3p24-p22 ⁽²⁰⁵⁾ |
| HSN (HSAN) 2 (201300) | Autosomal recessive. Onset infancy / early childhood.- first two decades. Mutilating acropathy. Often unrecognised fractures. Marked sensory loss affecting all cutaneous modalities, most marked | Normal MCV, sensory nerve action potentials are absent | Marked or total loss of MF in sural nerve with preservation of unmyelinated fibres. | <i>HSN2</i> ⁽²⁰⁶⁾ |

| | | | | |
|---|---|--|---|-----------------------------------|
| | distally all limbs. Autonomic dysfunction less marked. Absent or decreased DTR. | | | |
| HSN (HSAN) 3 (Riley-Day Syndrome, Familial dysautonomia) (223900) | Autosomal recessive: History of neurological abnormality and of difficult feeding from birth. Failure to regularly produce tears. Absent or reduced DTR. Absent corneal reflexes, postural hypotension, emotional liability. Relative indifference to pain, absence of fungiform papillae on tongue, absence of flare with intradermal histamine. Normal intelligence ⁽²⁰⁷⁻²⁰⁹⁾ | Motor CV usually slightly below control values. Sensory conduction normal or decreased. | Sural nerve biopsy decreased in myelinated and unmyelinated fibres, small myelinated and <u>unmyelinated most affected</u> . Active degeneration or demyelination is rarely seen. | <i>IKBAP</i> ⁽²¹⁰⁻²¹²⁾ |
| HSN (HSAN) 4 (Congenital insensitivity to pain with anhidrosis)⁽²¹³⁾ (256800) | Autosomal recessive. Onset from infancy, often high fevers sec to truncal anhidrosis during hot weather, Painless injuries of extremities and oral structures, often self-mutilation. Lack of pain sensation, both peripheral and visceral, inability to distinguish hot and cold. Preservation of DTR. Mild mental retardation. Hyperactivity and emotional lability common ^(214,215) | NCS normal. But sympathetic skin responses are absent (histamine test). ^(199,216) | Marked reduction / absence in small myelinated and unmyelinated fibres in the sural nerve, <u>unmyelinated fibres the most affected</u> ^(217,218) | <i>NTRK1</i> ⁽²¹⁹⁻²²¹⁾ |
| HSN (HSAN) 5 (608654) | Autosomal recessive. Onset early life. Rare disorder. Painless injuries of the extremities. Lack of pain and thermal sensitivity in the limbs but preservation of response to tactile and mechanical stimuli. Preservation of muscle strength and DTR. Distal anhidrosis. Bone and joint fractures. Normal intelligence ⁽²²²⁾ | Normal motor and sensory NC | Selective loss of small myelinated fibres and moderate loss of thin myelinated fibres from the sural nerve | <i>NGFβ</i> ⁽²²³⁾ |




Figure 1.1: Transverse section of part of a nerve fascicle from a patient with hereditary neuropathy with liability to pressure palsy (light microscopy, toluidine blue, magnification x400). Several fibres are tomaculous (T) and others are thinly myelinated.

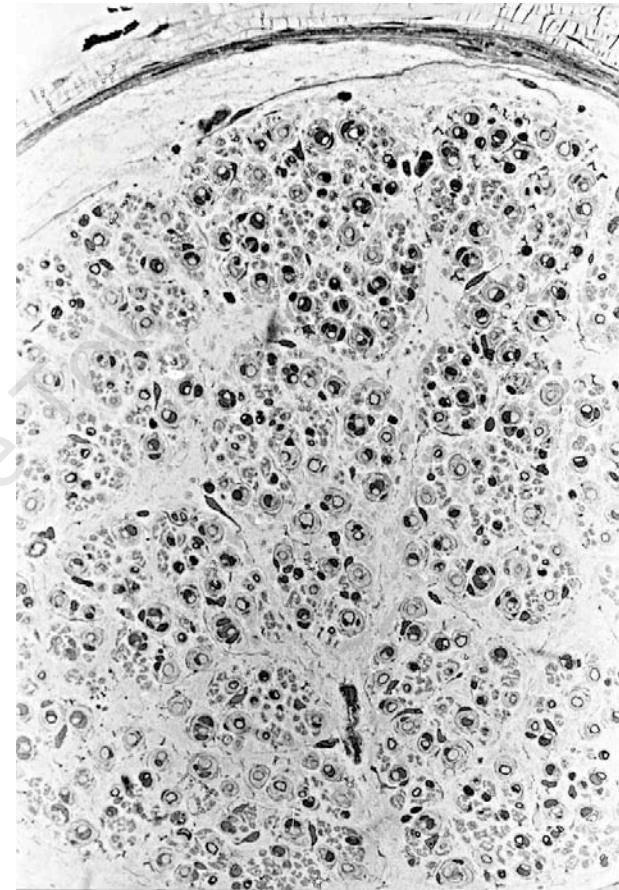


Figure 1.2 Transverse section of part of a nerve fascicle from a patient with CMT3 (LM, toluidine blue, magnification x200). The MF density is reduced; most fibres have thin or absent myelin and are surrounded by onion bulb formations.

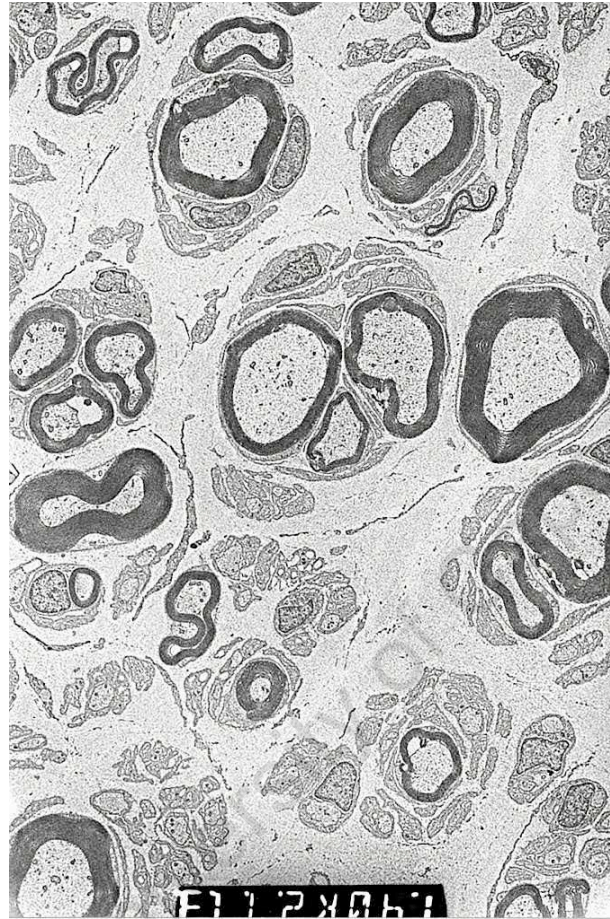


Figure 1.3 Electron micrograph of a patient with X-linked CMT. There is a reduction in myelinated fibre density, cluster formations and onion bulb formations. (Magnification estimated x3000).

Table 1.3 (see also table 2.2 page 57): Neurodegenerative disorders with peripheral neuropathy.

| Disorder (OMIM) | Clinical features | NCS | Biopsy findings | Genetic screen |
|--|--|--|--|--|
| Giant Axonal Neuropathy ^(224,225) (256850) | Onset first 7 yrs, usually delay in early milestones, progressive weakness, affecting LL first but spreading to affect all areas. Slurred speech, poor school performance – learning difficulties, small stature, Gen weakness, distal wasting, Absent DTR, impaired sensation especially proprioception and vibration, plantars often extensor, nystagmus, dysarthria, facial weakness. Tightly curled hair (“kinky”). Evolves into more spinocerebellar degeneration | Motor NCS normal / mildly decreased. SNAPS usually absent. Suggestive of axonal degeneration (similar to FA) | Numerous fusiform and sausage shaped axonal swellings with mod reduction in density of myelin and unmyelinated fibres. Myelin sheaths abnormally thin. OB around some fibres. Occasional Wallerian degeneration. EM axonal spheroids consist of tightly packed neurofilaments. | <i>GAN1</i> |
| Friedreich’s ataxia ^(226,227) (229300) | Ataxia earliest finding, onset 4-5 yrs. Insidious progression. Areflexia LL, dysarthria, post column signs LL, muscle weakness with or without hypotonia. Occasional pes cavus. Extensor plantars evolve with time. Nystagmus (20-50%). Kyphoscoliosis. Cardiomyopathy. | Normal or mild slowing of motor nerve conduction velocities, absent or very diminished SNAP. | Decreased density and total number of MF. Large MF affected. | <i>FRDA</i> |
| Ataxia with Vitamin E deficiency (AVED) ^(228,229) (277460) | Onset 3-13 yrs. Typically retinopathy, ophthalmoplegia or abnormal sensory conduction. Occasional extensor plantars, tremor, dystonic movements. Abnormal posterior column function. | Axonal pattern. ⁽²³⁰⁾ | Axonal features with large myelinated fibre involvement more marked than small myelinated fibres. Secondary demyelination occurs. ⁽²³⁰⁾ | Mapped to chromosome 8q13.1-13.3 |
| Spinocerebellar ataxia ⁽²³¹⁾ SCA1 (164400) SCA2 (183090) SCA3 (109150) SCA4 (600223) SCA7 (164500) SCA8 (608767) | Typically adult onset but childhood forms occur with anticipation | Axonal pattern compatible with a dying back axonopathy and / or a neuronopathy | Axonal or anterior horn cell features. | SCA1,2,3,4,7,8, 18,25 ^(232,233) |

| | | | | |
|---|--|--|--|---|
| SCA18 (607458) SCA25 (608703) | | | | |
| Metachromatic leukodystrophy ⁽²³⁴⁾ (250100) | Weakness and hypotonia lower limbs, progressive neurodeficit. Neuropathy subtle – depressed ankle reflexes. Abnormal arylsulphatase assays | Delayed conduction velocities consistent with demyelination | Reduced MF density, chronic demyelination. Onion bulb formations. Granular material in the perinuclear regions of the Schwann cell visible as metachromasia in cresyl violet or toluidine blue stains. Electron microscopy accumulations of myelin-like material as well as lipid-containing inclusions – zebra and ‘tuff-stone’ bodies. | Chr 22q, arylsulphatase A gene mutations ⁽²³⁵⁾ |
| Neuroaxonal dystrophy ⁽²³⁶⁾ (256600) | From second year with progressive gait difficulty and weakness, dementia, blindness and death occurs within a few years. | EMG denervation | Globular, ovoid or fusiform swellings along course of axons and patchy axonal degeneration. | <i>iPLA2β</i> gene, <i>PLA2G6</i> mutation ^(237,238) |
| Peroxisomal disorders ⁽²³⁹⁾ Zellwegers (214100) Neonatal adrenoleukodystrophy (202370) Infantile Refsums (266510) | Zellwegers, neonatal adrenoleukodystrophy ⁽²⁴⁰⁾ , infantile phytanic acid storage disorder | Often mixed motor and sensory impairment – severe demyelinating – mainly with phytanic acid disorder | Phytanic acid disorder - Nerve hypertrophy, demyelination | |
| Mitochondrial disorders ^(167,241-243) | Multifocal – Leigh’s disease main condition ⁽²⁴⁴⁾ | More axonal picture | Demyelination with patchy axonal loss | |
| | | | | |

Table 1.4: Specific protein deficiency or gene mutation^(245,246) (Abbreviations in key at end of table)

| Protein / mutation (OMIM) | Role | Disorders linked to | Comment |
|---|--|---|-------------------------------------|
| <i>DNM2</i>^(155,156) (602378) | DNM2 is part of the family of large GTPases and is involved in the cellular fusion-fission apparatus. In transiently transfected cell lines, DNM2 mutations reduced binding of DNM2 to membranes by altering the conformation of the beta3/beta4 loop of the pleckstrin homology domain | CNM DI-CMTB | DI-CMTB reported in American family |
| <i>EGR2 (Krox20)</i>^(62,114) (129010) | Acts as a zinc finger transcription factor. Regulates cellular proliferation Expression associated with myelination in peripheral nerve Plays role in PNS myelin development and maintenance Activated in Schwann cells before onset of myelination Disruption blocks Schwann cells at early stage of differentiation. Activates transcription of several myelin-associated genes Directly: PMP22, Cx32 & PRX Via EGR2/Sox10 synergy: MPZ; MAG | CMT 1D, DSS, Congenital hypomyelinating syndromes; CMT4E | |
| <i>FGD4</i>^(136,137,247) (611104) | FRABIN is a GDP/GTP nucleotide exchange factor (GEF), specific to Cdc42, a member of the Rho family of Rho GTPases, which play a key role in regulating signal-transduction pathways in eukaryotes. They are important in mediating actin cytoskeleton changes during cell migration, morphogenesis, polarization, and division. | CMT4H | Lebanese and Turkish populations |
| <i>FIG4</i>⁽¹³⁹⁾⁽¹¹⁷⁾ (609390) | FIG4 gene encodes a PI(3,5)P(2) 5-phosphatase. Mutations result in impaired trafficking of intracellular organelles due to obstruction by vacuoles. Based on plt mice - axonal degeneration in motor and sensory neurons, limited segmental demyelination, lack of TUNEL staining and lack of accumulation of ubiquitinated protein in vacuoles of motor and sensory neurons occurs. | CMT4J | |
| <i>GAN1</i>⁽²²⁴⁾ (605379) | Gigaxonin is composed of an amino-terminal BTB (for Broad-Complex, Tramtrack and Bric-a-brac) | GAN | |

| | | | |
|---|--|--------------------------------|--|
| | domain followed by six kelch repeats, predicted to adopt a beta-propeller shape. .Gigaxonin is a novel and distinct cytoskeletal protein affecting the neurofilament network. | | |
| GARS ^(92,96,179,248) (600287) | Mutations in the gene encoding glycyl-tRNA synthetase (GARS) impair function of tRNA-charging enzymes to play a key role in maintaining peripheral axons | DSMAV HMN V CMT2D | |
| GDAP1 ^(71,71,99,100,118-120,249) (606598) | GDAP1 expressed in the peripheral and central nervous system with high levels in Schwann cells and oligodendrocytes. Levels of GDAP1 increase during development. Participation in the mitochondrial fission process, mitochondrial swelling, aggregates, disruption of cristae in EM. | CMT4A, CMT 2H, CMT 2K | Described in Mediterranean, European and North African populations |
| GJB1 ^(114,144-146,250) (304040) | <i>GJB1</i> encodes the gap junction protein connexin 32 (Cx32).In myelinating Schwann cells, Cx32 probably forms "reflexive" gap junctions (between layers of the same cell) in non-compact myelin, found in paranodal loops and Schmidt–Lanterman incisures Cx32 mutants may disrupt the diffusion of small molecules and ions across the peripheral nervous system (PNS) myelin sheath. | DSS, CMTX1 | |
| HSPB1 ^(95,251) (602195) | Neuronal cells transfected with mutated HSPB1 less viable - Cotransfection of neurofilament light chain (NEFL) and mutant HSPB1 alters neurofilament assembly in cells devoid of cytoplasmic intermediate filaments. | CMT2F, dHMNII adult / juvenile | |
| HSPB8 ^(101,163,169,172,173) (608014) | Greater binding of HSPB8 mutants to the interacting partner HSPB1. Expression of mutant HSPB8 in cultured cells promotes formation of intracellular aggregates. | dHMNII CMT2L | CMT2L described in Chinese populations |
| IGHMBP2 ⁽¹⁰⁸⁾ (600502) | IGHMBP2 protein contains adenosine triphosphate binding, helices-like motifs and two nucleic acid-binding domains. Cellular pathomechanisms leading to SMARD phenotype are not known. | SMARD1 | |

| | | | |
|--|--|---|--|
| <i>IKBKAP</i> ⁽²¹⁰⁻²¹²⁾ (603722) | Component of the elongator complex and /or is a c-junction N-terminal kinase-associated protein | HSN 3 | |
| <i>KIF1B</i> ⁽⁷⁹⁾ (605995) | KIF1B is important for mitochondria transport. KIF1B heterozygotes have a defect in transporting synaptic vesicle precursors. | CMT2A1 | Described in one Japanese family – data not reproduced |
| <i>LITAF</i> ⁽⁶⁰⁾ (603795) | Stimulator of monocytes and macrophages. Causes secretion of tumour necrosis factor- α and other inflammatory mediators. May play a role in protein degradation pathways. | CMT1C | Location: Irish and English |
| <i>LMNA</i> ^(42,84-87) (150330) | Hypothesised that there are distinct functional domains in Lamin A/C which are essential for the maintenance and integrity of different cell lineages. There may be unique mutations in LMNA encoding Lamin A/C nuclear envelope proteins since mutations in LMNA lead to different phenotypes. The problem of the specificity of different domains of the protein and, conversely, of a possible common physiopathologic pathway is not understood. | CMD1A FPLD2 LGMD1B HGPS EDMD2 MADA restrictive dermopathy EDMD3 CMT2B1 | |
| <i>MFN2</i> ^(77,81,105,164,252) (608507) | <i>MFN2</i> is a large mitochondrial GTPase. It may function to tether mitochondria before fusion. Mitochondria undergo continued cycles of fission and fusion of their inner and outer membranes. The neuropathy may be due to a defect in mitochondrial fusion/fission which interferes with energy production and slows axonal transport. Many mutations are <i>de novo</i> . Mitochondrial aggregates and swelling onEM. | CMT2A2 HMSN V (CMT with pyramidal signs) CMT with deafness and white matter signal change on MRI EOHMSN | |
| <i>MPZ</i> mutation ^(58,59,97,98,112,131,159) (159440) | MPZ found in myelinating Schwann cells only. It is the most abundant protein in peripheral nerve myelin occupying 50% of total peripheral myelin protein. Within myelin it compacts myelin. Associated proteins: are PMP-22 & myelin basic protein. It is absent from CNS myelin. MPZ is necessary for normal myelin structure & function. It regulates Schwann cells. It is increased with axonal contact | CMT 1B: CMT 1E: CMT 2I: CMT 2J: CMT 4E, CMT 4B. CMT-DI3: Congenital hypomyelinating neuropathy: Dejerine-Sottas: Sometimes partial steroid responsive: Adult onset (Axonal) variant syndromes. | |

| | | | |
|--|--|------------------|-------------------|
| | and reduced by loss of axonal contact: It is turned off during Wallerian degeneration | | |
| MTMR2 ^(121,122,253) (603557) | MTMR2 is widely expressed and encodes a phosphatase (substrates include phosphoinositides). It is detected in all cytoplasmic compartments of myelin-forming and non-myelin-forming Schwann cells, and both sensory and motoneurons. In contrast, MTMR2 is detected in the nucleus of Schwann cells and motoneurons, but not in the nucleus of sensory neurons. As MTMR2 is diffusely present also within the nerve, a specific function could derive instead from nerve-specific interacting proteins. The neurofilament light chain protein (NEF-L) has been found to interact with MTMR2 in both Schwann cells and neurons. | CMT4B1 | |
| NDRG1 ⁽¹³⁰⁾ (605262) | NDRG1 is ubiquitously expressed and has been proposed to play a role in growth arrest and cell differentiation, possibly as a signalling protein shuttling between the cytoplasm and the nucleus. There are high levels expressed in the Schwann cell. NDRG1 may have a role in the peripheral nervous system, possibly in the Schwann-cell signalling necessary for axonal survival. | CMT4D HMSNL | Gypsy populations |
| NEFL ⁽⁶⁵⁾ (162280) | Required for organization of neurofilaments. Associated with radial axonal growth | CMT 1F CMT 2E | |
| NGFβ ⁽²²³⁾ (162030) | Mutations in the gene result in substitution of tryptophan for arginine – separates the effects of NGF involved in development central nervous system functions(e.g. mental abilities)from those involved in peripheral pain pathways | HSN5 | |
| NTRK1 ⁽²²⁰⁾ (191315) | TRKA protein is a receptor tyrosine kinase, phosphorylated in response to nerve growth factor | HSN4 | |

| | | | |
|--|--|--|--------------------------------------|
| PMP 22 ^(50-55,66,111) (601097) | Role in the initiation of myelin spirals, regulation of growth and differentiation of Schwann cells and control of thickness and stability of myelin sheaths. ⁽²⁵⁴⁾ | CMT1A, CMT1E, DSS, HNPP | |
| PRPS1 ^(148,149) (311850) | PRPS1 is an isoform of the PRPS gene family. It is ubiquitously expressed in human tissues, including cochlea. The enzyme mediates the biochemical step critical for purine metabolism and nucleotide biosynthesis. Decreased enzyme activity in affected patients. PRPS1 is the first CMT gene recognised to encode a metabolic enzyme. | CMTX5 | |
| PRX ^(113,132,133) (605725) | Periaxin proteins are important for normal Schwann cell function. | CMT4F, DSS (CMT3) | Lebanese populations |
| RAB7 ⁽⁸⁴⁾ (602298) | Rab GTPases localize to the cytosolic face of specific intracellular organelles, regulating distinct steps of membrane traffic. It has a fundamental role in growth factor-regulated cell nutrition and apoptosis. It is known to be involved in the control of retrograde axonal transport of neurotrophin receptors. Hypothesised that mutated Rab7 gene causes CMT2B disease by alteration of neurotrophin receptor trafficking | CMT2B (some clinical overlap with HSN1) | Increased in Costa Rican populations |
| SEPT9 ⁽¹⁹⁵⁾ (604061) | Implicated in formation of the cytoskeleton, cell division and tumour-genesis | Hereditary neuralgic amyotrophy | |
| SH3TC2 (KIAA1985) ⁽¹²⁸⁾ (608206) | KIAA1985 protein may acts as an adapter or docking molecule. The translated protein belongs to a so-far-unrecognized family of putative adapter proteins | CMT4C | Increased in Algerian populations |
| SLC12A6 (KCC3) ⁽¹⁸⁹⁾ (604878) | The gene encodes the K ⁺ -Cl ⁻ transporter KCC3 and maps within the ACCPN (peripheral neuropathy associated with agenesis of the corpus callosum) candidate region. It is suggested to play a critical role for SLC12A6 in the development and maintenance of the nervous system. | Andermann syndrome | French Canadian populations |

| | | | |
|---|---|---------|--|
| SPTLC1 ^(202,203) (605712) | Encodes serine palmitoyltransferase, long chain base subunit-1. The gene is located within the HSN1 locus, expressed in dorsal root ganglia (DRG) and mutated in HSN1. | HSN1 | |
| YARS ⁽¹⁵⁸⁾ (603623) | YARS localizes to axonal termini in differentiating primary motor neuron and neuroblastoma cultures. This specific distribution is significantly reduced in cells expressing mutant YARS proteins. It is the second aminoacyl-tRNA synthetase found to be involved in CMT, linking protein-synthesizing complexes with neurodegeneration. | DI-CMTC | |

Key:

Proteins / mutations

DNM2: dynamin 2

EGR2 (Krox20): Early Growth Response 2 protein

FGD4: actin-filament binding protein Frabin

FIG4: poly phosphoinositide phosphate activity

GARS: glycyl-tRNA synthetase

GAN1: gigaxonin

GJB1: gap junction protein, beta 1, 32kDa (connexin 32)

HSPB1: heat shock 27kDa protein 1

HSPB8: heat shock 27kDa protein 8

IGHMBP2: immunoglobulin mu binding protein 2

IKBKAP: IκB kinase complex-associated protein

LITAF; *SIMPLE*: Lipopolysaccharide-induced tumour necrosis factor-α factor

LMNA: Lamin A/C

MFN2: mitofusin 2

MPZ: Myelin protein zero

MTMR2: myotubularin-related protein 2

NEFL: Neurofilament light chain

NDRG1: N-myc downstream regulated gene 1

NGFβ: Nerve growth factor β gene

NTRK1: Neurotrophic tyrosine kinase receptor type 1

PMP 22: peripheral myelin protein 22

PRPS1: phosphoribosyl pyrophosphate synthetase 1

PRX: periaxin

RAB7: member RAS oncogene family

SEPT9: septin9

SH3TC2: *KIAA1985* protein

SLC12A6 (KCC3): solute carrier family 12, member 6

SPTLC1: serine palmitoyltransferase, long chain base subunit-1

YARS: tyrosyl-tRNA synthetase

Disorders:

1A -*CMD1A* :Cardiomyopathy, dilated,

CNM: Myopathy, centronuclear, autosomal dominant

DSMAV: Spinal muscular atrophy, distal, type V –

EDMD2:Emery-Dreifuss muscular dystrophy, autosomal dominant -

EDMD3:Emery-Dreifuss Autosomal recessive -

FPLD2:Lipodystrophy, familial partial, type 2 -

FPLD2:Lipodystrophy, familial partial, type 2 -

HGPS :Hutchinson-Gilford progeria syndrome -

HMN2:Neuropathy, distal hereditary motor, type II -

HMN V: Neuropathy, distal hereditary motor type V -

LGMD1B: Muscular dystrophy, limb-girdle, type 1B -

MADA: Mandibuloacral dysplasia with type a lipodystrophy -

CHAPTER 2

THE ROLE OF NERVE BIOPSY

This article "Nerve Biopsy" (Jo M Wilmshurst, Robert A Ouvrier) was published in
Neuromuscular Disorders of Infancy, Childhood and Adolescence. A Clinician's Approach.

Editors H. Royden Jones, Darryl De Vivo, Basil Darras, 2003, 91-109⁽¹⁾

Permission was obtained from the publishers to reproduce this chapter as part of this MD
thesis.

University of Cape Town

Introduction

Chapters 3, 4 and 5 will illustrate the usefulness of peripheral nerve biopsy in the clinical context. When electing to undertake this investigation on a child with a peripheral neuropathy the following text will aid to clarify the role, optimal methodology and interpretations of nerve biopsies.

Although the rapidly expanding area of molecular genetics has reduced the necessity of invasive investigations, peripheral nerve biopsy remains a valuable diagnostic aid when used appropriately. In many countries, access to comprehensive molecular genetic studies is limited. If centres have the capacity to analyse peripheral nerve biopsies, the results may aid diagnostic closure or support motivation for further investigations. There are specific DNA tests for many of the *demyelinating* hereditary motor sensory neuropathies (HMSN) or Charcot Marie Tooth (CMT) demyelinating disorders.⁽²⁵⁵⁾ In contrast many of the *axonopathies*, remain poorly understood and difficult to categorise diagnostically. Nerve biopsy is particularly useful in the evaluation of a child with an indeterminate peripheral neuropathy when clinical assessment, laboratory investigations, and EMG are unsuccessful in identifying an aetiologic mechanism for a neuropathy. The clinician needs to have clear indications and expectations for performing the nerve biopsy in a chronically affected sometimes debilitated patient where confirmatory data would aid prognostic, genetic and, ideally, therapeutic management.⁽²⁵⁶⁾ In the 1989 study of Argov and colleagues, forty- eight percent of children and adults, aged 12-78 years, with a peripheral neuropathy were diagnosed without proceeding to nerve biopsy. Biopsy contributed to diagnosis in 38% of the remaining patients and management was affected by the specific histological findings in half of these. The importance of careful patient selection was emphasized.⁽²⁵⁷⁾ Nerve biopsy also has an important role for excluding a number of devastating diseases such as infantile axonal neuropathy and giant axonal neuropathy.

Nerve biopsies need to be analysed in a centre skilled in the appropriate histopathological techniques, interpretation of both light and electron microscopic findings, and with the ability to perform quantitative analysis where appropriate. Peripheral nerves in the paediatric age group differ from those of adults. Between birth and age 5 years, significant peripheral nerve maturational changes occur in fibre density, and myelinated fibre size

including thickness. There is a gradual evolution in these parameters from early infancy until the mature adult histological pattern is approached in the pre-school years.⁽²⁵⁸⁾

Although peripheral electrophysiology is useful in identifying neuropathies, the findings are not always consistent. A patient with a suspected neuropathy, particularly one with a small fibre sensory neuropathy, may have normal conventional nerve conduction studies. Likewise, a patient with an axonopathy will sometimes have peripheral electrophysiological features suggesting a demyelinating condition.⁽²⁵⁹⁾ Without proceeding to nerve biopsy the exact nature of the neuropathy cannot always be reliably determined. See Case 2 below.

Although there is little in the literature discussing large group studies of nerve biopsies in childhood, four hundred and twenty six paediatric biopsies have been performed in children aged 1 month to 17 years during the last 37 years at the Nerve Research Laboratory of Sydney University. These biopsies confirmed and defined 296 peripheral neuropathies. The other 130 biopsies with normal findings were performed in children whose clinical features and/or nerve conduction studies suggested the possibility of a neuropathy (such as distal spinal muscular atrophy). In recent years, advances in molecular genetics have reduced the need for nerve biopsy in the investigation of many inborn errors of metabolism typically associated with a demyelinating polyneuropathy. In contrast, many of the paediatric axonal degenerative neuropathies remain poorly understood. Therefore peripheral nerve biopsy continues to provide an important means to aid these diagnostic efforts. The relative proportion of primary axonopathies studied has consequently increased as specific DNA testing is yet to be developed for most of these processes.

Nerve biopsy:

Principles and techniques:

The sural nerve is the usual source for most biopsy specimens. This primarily sensory nerve supplies the sensation to the lateral aspect of the foot. It is made up of both myelinated and unmyelinated fibres having both sensory and autonomic origin. Because of this nerve's distal location it is involved early in most generalized neuropathies. Its removal at biopsy typically results in minimal additional functional deficit particularly as these patients already

usually have a significant sensory loss in its distribution. A general anaesthetic is advisable in children although adults usually tolerate the procedure well under a local anaesthetic. In order to reduce the number of anaesthetic procedures that a child undergoes, if a muscle biopsy is also indicated, as part of the child's evaluation, it is best performed concomitantly with the nerve biopsy. This investigation is often useful in its own right and can complement nerve biopsy findings, such as by confirming the presence of a primary neurogenic atrophy secondary to chronic denervation.

Special care needs to be taken in the processing and handling of the nerve. One needs to avoid damage to the fascicles by over-zealous contact. Whole or fascicular sections are utilized depending on the nerve centre's experience. When one is specifically screening for certain pathologic conditions, such as chronic inflammatory demyelinating polyradiculoneuropathy (CIDP), sarcoidosis, and amyloidosis, it is advisable to obtain whole nerve sections.⁽²⁶⁰⁾ The peripheral nerve specimen is placed on a saline-moistened sponge that is then placed in an airtight container until arrival in the laboratory. In order to avoid artifacts, each biopsied nerve must be processed within 15 minutes of its removal. This urgency applies to autopsy samples, because of the rapid propensity to undergo spontaneous autolysis. Unless the samples are taken soon after death, there is a significant possibility that the findings will be impossible to interpret. Nevertheless, myelinated fibres can be reliably assessed up until 24 hours in rats if the cadaver is refrigerated.⁽²⁶¹⁾

Detailed descriptions of the various techniques used to assess nerve histology are published.⁽²⁶⁰⁾ The following technique is employed at the University of Sydney laboratory.⁽²⁶²⁾ It is advisable to store biopsy material in case further histopathological analysis becomes necessary.

Whole sural nerve biopsy is performed usually at the level of the lateral malleolus under general anaesthetic. The nerve is divided into three to five portions each 0.5-1cm in length. One piece of each nerve is fixed in picric acid, embedded in paraffin, and cut transversely and longitudinally into sections of 5µm thickness. Sections are stained with haematoxylin and eosin and with congo red.

A second piece is longitudinally cut into strips of about 1mm diameter which are fixed in 10% buffered formalin for at least 24 hours, stained overnight (for at least 5 hours) in 1%

aqueous osmic acid, transferred to a 2:1 mixture of glycerol and water for 12 hours and individually teased out under a dissecting microscope.

A third piece is fixed in 2.5% phosphate buffered glutaraldehyde overnight at 4°C followed by 2% osmium tetroxide for 90 minutes. The tissue is dehydrated in graded concentrations of ethanol, passed through acetone, and embedded in Spurr's resin. 0.25µm sections are cut transversely and stained with toluidine blue.

Portions of nerve are fixed for electron microscopy as indicated. When appropriate, pieces of nerve are frozen in liquid nitrogen and cryostat sections cut for immunohistochemical staining.

Light Microscopy Assessment: Certain stains are preferred in order to identify specific pathologic processes. One typically utilizes both transverse and longitudinal teased fibre sections.

Transverse sections

Haematoxylin and eosin (H & E) sections may identify perineurial oedema and signs of inflammation (as occurs in CIDP or vasculitis). Cuffing with lymphocytes around endoneurial vessels is a significant marker of inflammation that is well demonstrated with H&E sections.

Congo red stains are used to screen for amyloid infiltration, a test more relevant to adults.

Toluidine blue stains provide data on both demyelinating and axonal disorders. Demyelinating disorders are typically associated with reduced myelinated fibre density, increased Schwann cell and inflammatory cell numbers, reduced myelin thickness, evidence of myelin debris and onion bulb formations (Figure 4.1).

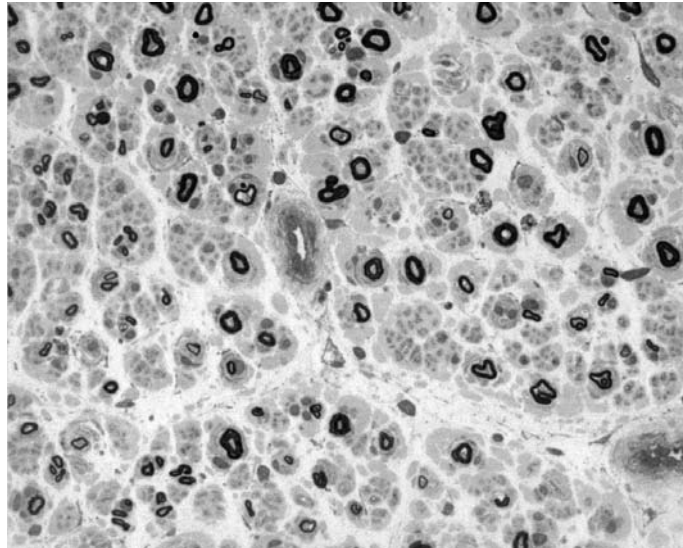


Figure 2.1: Transverse section of a nerve fascicle from a patient with CMT1A (LM, toluidine blue, magnification x400). Many fibres are surrounded by onion bulb formations. Some fibres are thinly myelinated and the MF density is reduced.

Axonopathies are typified by reduced myelinated fibre density, fibres undergoing active axonal degeneration and cluster formation when regeneration is occurring (Figure 2.2).

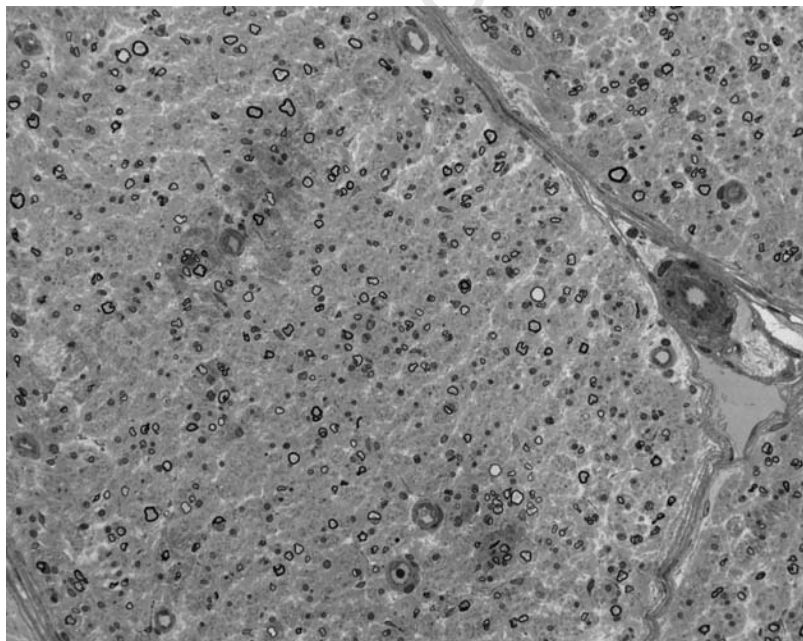


Figure 2.2: Transverse section of a nerve fascicle from a patient with CMT2 (LM, toluidine blue, magnification x200). The MF density is reduced. Remaining fibres are well myelinated.

Special histochemical stains are used to screen for conditions such as metachromatic leukodystrophy, where acid cresyl violet stain confirms the brown metachromatic granules.

Teased fibres.

Teased fibre studies, though time consuming to prepare, provide invaluable nerve pathology information. Ideally some 30 –100 fibres need to be separated out to give a reasonable selection of the nerve characteristics. This technique allows examination of myelinated fibre changes in a longitudinal axis that transverse sections may often not identify. It is possible to look for segmental demyelination, widening of the nodal gap with paranodal demyelination, segmental remyelination (often appearing as two or more short segments between normal length segments), and regenerated fibres where all internodal segments are short (0.2-0.6mm) and have disproportionately thick diameters (Figure 2.3). The finding of myelin ovoids suggests active axonal degeneration (Figure 2.4).

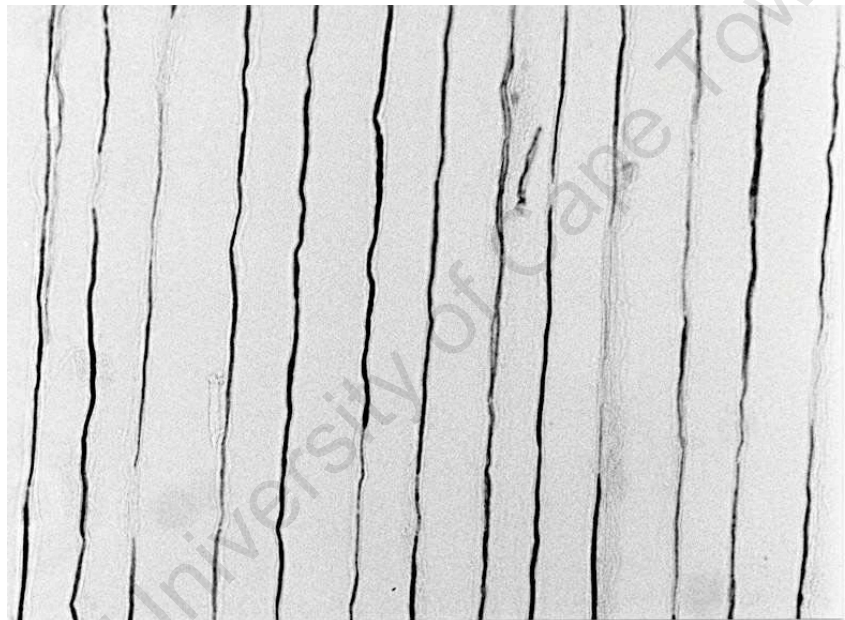


Figure 2.3: Teased fibre appearance of demyelination from a patient with CMT1 (magnification x200). Extensive thinning of myelin and patchy intra and segmental demyelination can be seen throughout the fibres.

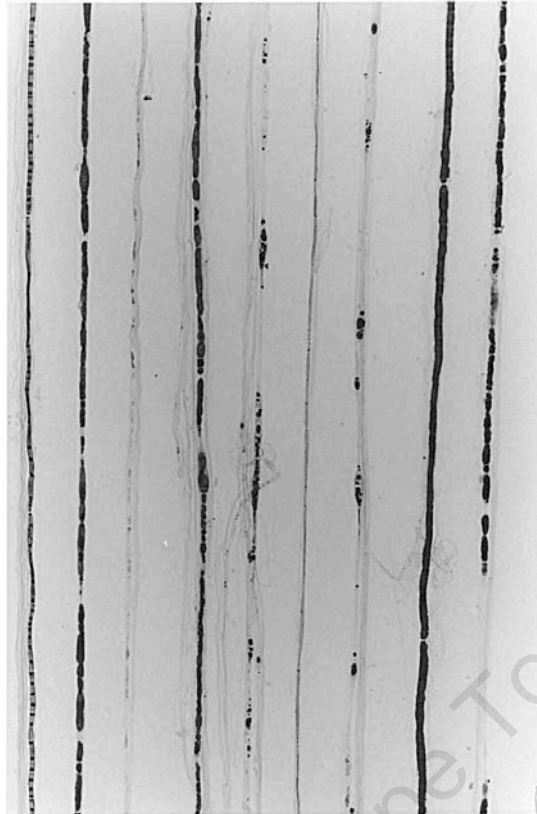


Figure 2.4: Teased fibre appearance of axonal degeneration demonstrating extensive myelin ovoids along the course of the fibres (magnification x200).

Teased fibre sections particularly aid in the differentiation of primary segmental demyelination from a secondary demyelinating process due to axonal disease. The finding of “clustering” of segmental demyelination along a single diseased axon, where many of the remaining axons appear well myelinated, suggests axonal degeneration as the primary process, whereas apparently random regions of segmental demyelination throughout many fibres are more likely compatible with a primary demyelinating process.⁽²⁶³⁾

Electron microscopy

Electron microscopy (EM) allows estimation of the presence and density of unmyelinated fibres. Additionally this is often the only means to confirm the presence of conditions such as neuroaxonal dystrophy, where the typical axonal spheroids are often only visible by this method (Figure 2.5).

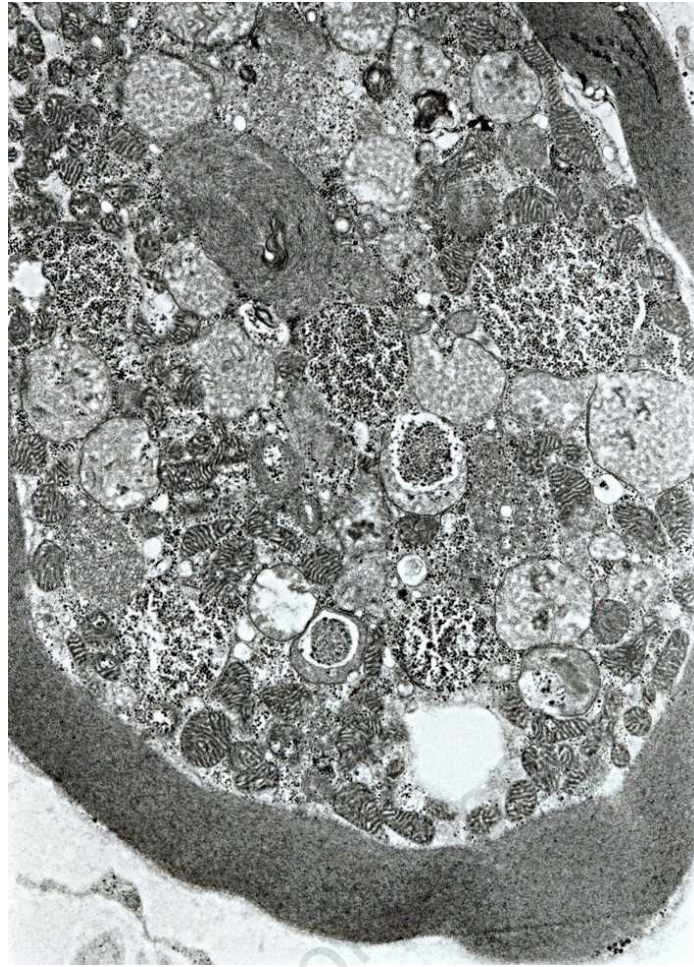


Figure 2.5: Electron micrograph from a patient with neuroaxonal dystrophy (magnification estimated x28000). The plate shows axonal degeneration with the axoplasm containing multiple mitochondria and the typical tubulogranular profiles of this condition.

Electron microscopy is primarily performed, subsequent to LM, in order to assess conditions where further information is needed for more precise diagnosis.

EM provides detailed pictures of the intrinsic nature of the fascicle with basement membrane configuration and continuity.

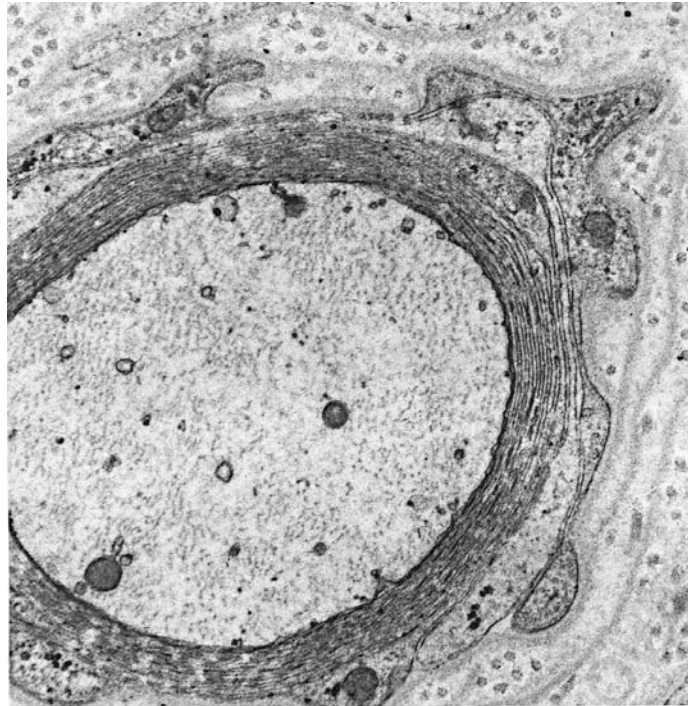

Figure 2.6: Electron micrograph of a single myelinated fibre, from a patient with P_0 mutation, demonstrating uncompact myelin round a thinly myelinated fibre. Concentric layers of Schwann cell cytoplasm and endoneurial elements, forming an "onion bulb" surround the fibre. (Magnification estimated x15000)

Further, electron microscopy may be the only way to detect evidence of Bands of Büngner (early regenerating large myelinated fibres) and Schwann cell subunits (where a single Schwann cell profile, or group of profiles, are enclosed by a continuous basal lamina, that may or may not include axons). Subtle changes in the myelin folds may suggest early demyelination or failure of compaction (Figure 2.6). In contrast early axoplasmal shrinkage, associated with degradation products, suggests axonal degeneration (Figure 2.7).

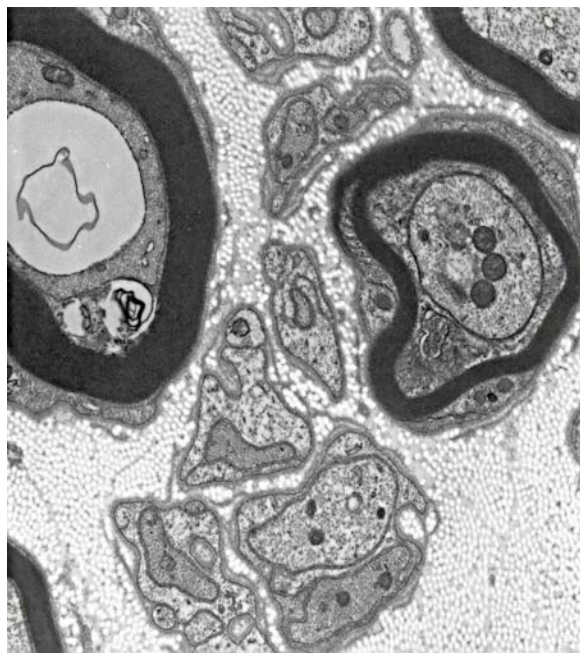


Figure 2.7: Electron micrograph of two nerve fibres, from an infant, undergoing active axonal degeneration. The fibres are well myelinated but active breakdown is evident within the axoplasm. (Magnification x7000)

Artifact is a frequent problem with even the most carefully prepared nerves. In such circumstances, EM frequently enables the nerve pathologist to differentiate between genuine disease pathology and artifactual changes.

Quantitative analysis

Myelinated fibre morphometric studies are performed utilising photomicrographic enlargements of toluidine blue stained sections. Electron micrographs also provide for the assessment of unmyelinated nerve fibres. Various computer-assisted methods are available to allow for the rapid assessment of larger numbers of fibres. Even the most sensitive programs require observer verification. This ensures that the fibre counts only include axons.

An alternative method utilises visual counts on electron micrographs or magnified LM fascicles. At least ten EM plates at a magnification of around x3500 magnitude are taken from random sections of the same fascicle. Myelinated fibres (MF) are counted and the density per mm^2 calculated from this figure and the area. Similarly the fibre diameters are assessed through the average of the maximum and minimum diameter or by conversion from the circumference of the fibre ($D=C/\pi$). From these values the equivalent number per mm^2 can be extrapolated and a histogram of fibre diameter distribution produced.

The histographic appearance of certain diseases is typical. For example, in Friedreich ataxia, there is a reduction in myelinated fibre density with predominant loss of the large MF.⁽²²⁷⁾

A similar process is used for unmyelinated fibres (unMF) though as the ratio of unmyelinated to myelinated fibres is often as much as 4:1 the numbers are clearly far greater. Generally, counting a total number per plate until a value over 80 is reached provides a reasonably accurate estimate of unMF density. The diameters are measured by the same method as for MF. Other useful measurements from EM include the numbers of Schwann cell nuclei, denervated Schwann cell subunits, and collagen pockets, the last two being indicators of unmyelinated fibre loss.

The ratio of axon diameter (d), excluding the myelin, to total MF diameter (D) provides an indication of the thickness of myelin around a specific fibre, the "d/D" or "g" ratio, allowing confirmation of the presence of excessively thin myelin, (*high d/D ratio*), as occurs with large numbers of regenerated or hypomyelinated fibres, or of excessively thick myelin (*low d/D ratio*), as is seen in the tomaculous neuropathies (particularly hereditary neuropathy with liability to pressure palsies).

Other biopsy sites:

Sural nerve biopsy is clearly relevant for the investigation of generalized sensorimotor polyneuropathies but obviously has no value when there is no sensory involvement. With certain exceptions, such as in the early stages of an axonal neuropathy, where many large diameter fibres are preserved, the lack of sensory nerve involvement may be clinically inferred. Supportive findings in the child include the presence of a normal sensory examination concomitant with nerve conduction studies (NCS) demonstrating preserved sensory nerve action potentials (SNAPs).⁽²⁶⁰⁾ Thus with each planned biopsy, if such studies are normal, it needs to be recognised that the yield from biopsy will be small.

Occasionally other sites are used when a specific localized neuropathy is suspected or if access to the sural nerve is not possible. The superficial radial, the superficial peroneal (after the motor component has branched off) or the deep peroneal nerves have been used. Similarly the saphenous nerve can be biopsied, although this is a difficult nerve to assess, as there are so many branches.⁽²⁶⁰⁾ The authors rarely employ these other sites.

If a nerve biopsy of a child with a pure or predominantly motor neuropathy is necessary, a motor nerve sample provides more diagnostic information than will a sural nerve biopsy. Motor nerves in general are not routinely sampled. However, prognostic information was gained from one study in a patient with severe Guillain-Barré syndrome.⁽²⁶⁴⁾ Biopsy of the terminal branch of the musculocutaneous nerve unequivocally confirmed that the pathological process was primary demyelination, not axonal degeneration, and provided more information than had previously been reported in such patients from sural nerve biopsies. Other motor nerves that may be considered include the lateral terminal branch of the deep peroneal nerve⁽²⁶⁵⁾ and the motor branch of the superficial peroneal nerve (although this is more often sampled from autopsy cases).⁽²⁶⁰⁾ The nerve to the gracilis muscle has also been used with little complication and useful information gained.⁽²⁶⁶⁾

Quantitative peripheral nerve analysis is also possible by performing a skin biopsy.⁽²⁶⁷⁾ It is particularly useful for assessment of small fibre neuropathies.⁽²⁶⁸⁾ In patients with Fabry's disease, a condition that results in severe distal burning pains with progressive loss of both small myelinated and unmyelinated fibres, the study produced convincing evidence that the quantification of small myelinated and unmyelinated fibres is as accurately calculated by skin biopsy as it was with a sural nerve biopsy.⁽²⁶⁹⁾ Another advantage is that skin biopsy sampling is less invasive, well tolerated, and easily repeated providing quantitative serial measurements of disease progression.⁽²⁶⁷⁾⁽²⁶⁹⁾ The application of these techniques may be particularly instructive in providing a better understanding of the hereditary sensory neuropathies.

Complications

In general, about 40 % of adult patients complain of pain or paraesthesiae persisting one year after nerve biopsy. The pain is moderate to severe in a quarter of these individuals. This discomfort is commonly described as being like a pinprick or a tight sensation during standing or walking.^(270,271) The outcome is not influenced whether the biopsy is whole nerve or fascicular.⁽²⁷²⁾ Prolonged follow up after 2 years suggests that there is a gradual improvement in symptoms with time.⁽²⁷³⁾ Most of these studies are derived from the adult age group; there is little comparative data from children. However, complaints following biopsy have not usually been significant among cases seen in the peripheral neuropathy clinics at The Children's Hospital at Westmead in Sydney. Only one case stands out, that of a boy who underwent

biopsy of the sural nerve and muscle at the mid-calf level. Subsequently he suffered discomfort in that region and this was felt to be secondary to adhesions around the nerve.

Sural nerve morphology varies with age:

During the first year of life the nerve morphology changes markedly with a more gradual evolution over the following years until the adult pattern is approached by 5 years of age.^(258,274,275) Similarly, nerve conduction parameters do not reach adult values until 3 – 5 years of age.^(276,277)

Myelination of peripheral nerve commences from 18 weeks gestation. By term, most of the fibres that are destined to become myelinated have started the process.⁽²⁷⁸⁾ The total number of MF per sural nerve increases from 4000 at birth to 7-12000 by “adulthood”. However, the density of MF per mm² follows the opposite trend. This is because the sural nerve endoneurial area is smaller at birth (0.2-0.5mm²) whilst the adult size increases to 0.6-1.2 mm². Densities at birth are as high as 12-20,000 MF/mm². This rapidly decreases to nearer 10,000 MF/mm² by one year of age. Adult levels are attained nearer to 10 years of age.

There is relative hypomyelination at birth, with “g”-ratios above 0.8 common.⁽²⁷⁹⁾ By 5 years of age the axons reach their adult size whilst final myelin thickness is really only evident by 10 years of age. The MF diameter histogram is unimodal at birth and evolves into a bimodal appearance towards the end of the first year as large myelinated fibres become established. Internode lengths are 200-300 microns at birth and increase to 200-1800 microns by “adulthood” (Figure 2.8).

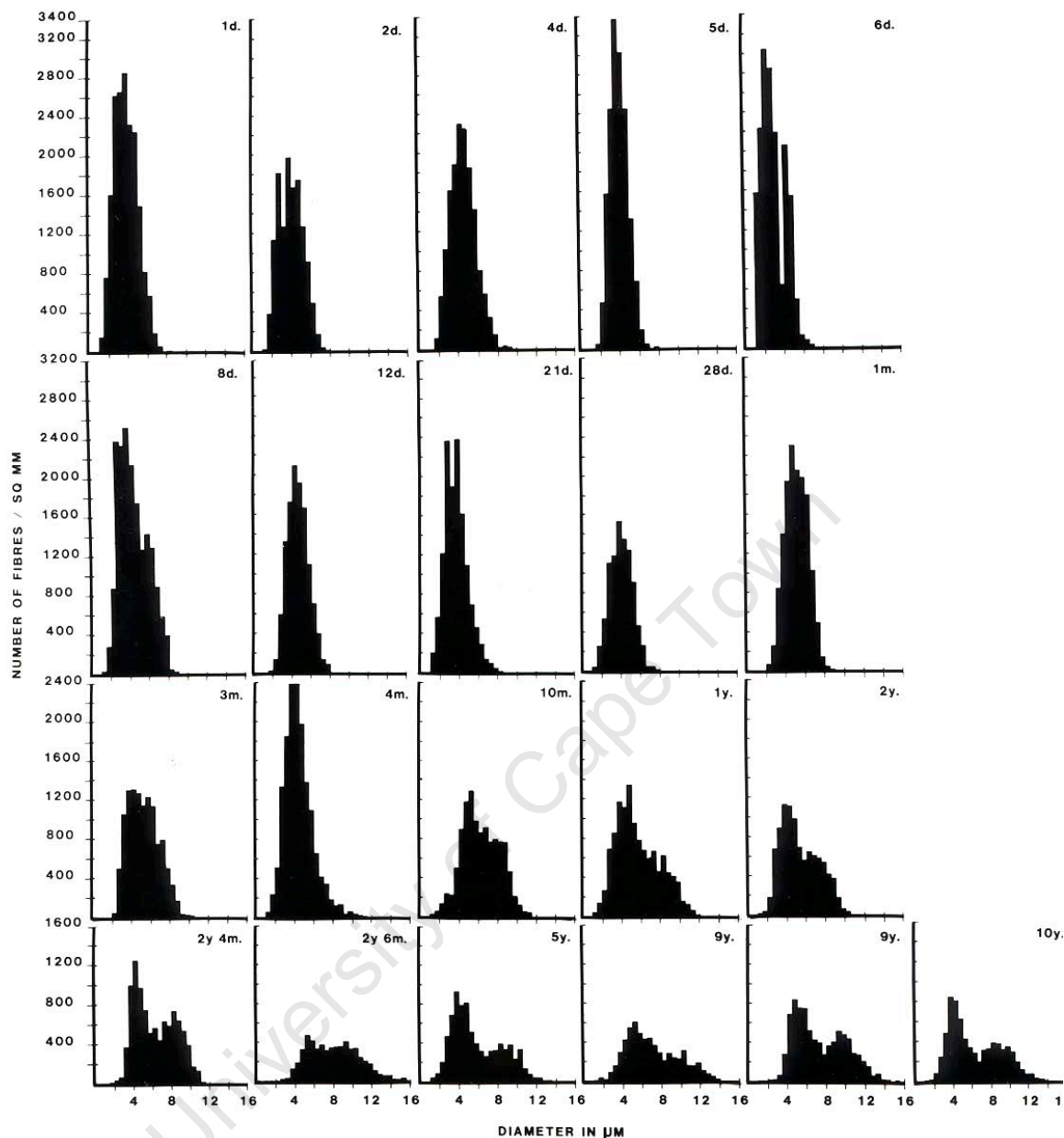


Figure 2.8: Normal MF diameter changes with age (0-10years).⁴ In early life the myelinated fibres are of small diameter (2-5microns) and the histograms are unimodal. By one year of age a bimodal trend appears as larger diameter fibres form (8-12 microns).⁽²⁵⁸⁾

Biopsy findings in relevant diseases:

Tables 1.2 (page 19), 1.3 (page 32), 2.1, 2.2 and 2.3 summarise the predominant nerve biopsy findings in the various childhood peripheral neuropathies. Tables 1.3 and 2.2 both describe various neurodegenerative diseases which involve the peripheral nerves, table 1.3 is shorter and represents the group of disorders where more molecular genetic diagnoses

are possible. Molecular DNA genetic testing easily confirms many of the hereditary demyelinating neuropathies. However, a substantial number of the axonal neurodegenerative disorders still require a nerve biopsy for diagnosis. The leukocyte (white cell) enzyme screen may confirm a leukodystrophy but as with the example of metachromatic leukodystrophy (MLD), borderline arylsulphatase A (ASA) levels can be misleading, sometimes leaving biopsy as the only firm diagnostic test available.⁽²³⁴⁾ Vasculitis may occur without systemic features. Thus, confirmation of this rare immunologically mediated neuropathy with a sural nerve biopsy could result in the institution of corticosteroid therapy.⁽²⁸⁰⁾

University of Cape Town

Table 2.1: Inflammatory and infectious disorders.

| Disease | Type of neuropathy | Biopsy findings | Comment |
|---|---------------------------------|---|---|
| CIDP ⁽²⁸¹⁾ | Mixed | Subperineurial oedema; macrophages; density ↓; clusters; thin myelin | Not routinely recommended as features can overlap the HMSNs and findings are not consistent. |
| Vasculitis ⁽²⁸²⁾ | Axonal | Acute axonal degeneration; vasculitis in endoneurium and perineurium | Rare in children – consider SLE, Sjögrens disease; RA; HIV |
| Leprosy ⁽²⁸³⁾ | Mixed with chronic inflammation | Segmental demyelination and axonopathy; macrophages and Schwann cells filled with organisms and debris (foamy cells); much of architecture preserved. | |
| Diphtheria ⁽²⁸⁴⁾ | Demyelinating | Minor focal segmental demyelination | |
| Lyme disease ⁽²⁸⁵⁾ | Axonal | Lymphocyte & plasma cell infiltration; thick pericapillary cuffs without necrosis of the vessel wall | |
| Human Immuno-deficiency Virus (HIV) – CMV neuritis ⁽²⁸⁶⁾ | Axonal | Active axonal degeneration with some segmental demyelination; necrotising endoneurial and epineurial vasculitis with prominent neutrophil infiltrate. On EM CMV virions seen in the endoneurial cells | Although neuropathy in HIV is rarely reported, it should be considered, especially in older children. NCS are often abnormal even in young children with HIV, biopsy data however is scarce. ⁽²⁸⁷⁾ |

Key: CIDP = chronic idiopathic demyelinating polyradiculoneuropathy; SLE = systemic lupus erythematosus; RA = rheumatoid arthritis; HIV = human immunodeficiency virus; MF = myelinated fibre; EM = electron microscopy; CMV = cytomegalovirus; NCS = nerve conduction studies

Table 2.2 (see also Table 1.3 page 32): Neurodegenerative and Metabolic disorders.

| Disease | Type of neuropathy | Biopsy findings | Comment |
|--|--------------------|---|---|
| Friedreich's ataxia ¹⁰ Figure 2.9 | Axonal | ↓ Density – selective loss of large MF; clusters rare | GAA triplet repeat test available ⁽²²⁶⁾ |
| Spinocerebellar ataxia ⁽²⁸⁸⁾ | Axonal | Mild axonal degeneration | |
| Infantile onset cerebellar ataxia with sensory neuropathy ⁽²⁸⁹⁾ | Axonal | Progressive loss of large MF, rare OB and clusters | IOSCA |
| Giant axonal neuropathy ⁽²²⁵⁾ Figure 2.10 | Axonal | Giant axons; ↓ density MF; axons filled with densely packed neurofilaments on EM | Diagnostic picture on biopsy. Mapped to the gene encoding gigaxonin. ⁽²²⁴⁾ |
| Neuroaxonal dystrophy ⁽²³⁶⁾ Figure 2.5 | Axonal | Globular, ovoid or fusiform swellings along the course of axons; axonal degeneration. Typical neurofilaments visible on EM sections | Diagnostic picture on biopsy – can also be diagnosed from other biopsy sites e.g. skin, conjunctiva. ⁽²⁹⁰⁾ |
| Fabry's disease ⁽²⁶⁹⁾ | Axonal | Selective loss of small and unMF; glycolipid granules in perineurial and endoneurial cells | Diagnostic picture on biopsy. Various mutations of the α -galactosidase A gene are described. ⁽²⁹¹⁾ |
| Niemann-Pick Disease Type A ⁽²⁹²⁾ | Demyelinating | Loss of MF; thin myelin sheaths; within Schwann cells numerous round or fusiform bodies | Infantile form |
| Farber disease ⁽²⁹³⁾ | Axonal | Loss of axons. Round membrane-bound clear inclusions in Schwann cells and histiocytes | |
| Leigh's disease ⁽²⁴⁴⁾ | Demyelinating | Hypomyelination and segmental demyelination | |
| Krabbe's disease ⁽²⁹⁴⁾ | Demyelinating | Density ↓; inclusions in Schwann cells; | Diagnostic picture on biopsy. Screening |

| | | | |
|---|--------------------------|--|---|
| | | macrophages | possible from white cell enzymes, but biopsy still has a role in atypical cases |
| Metachromatic leukodystrophy ⁽²³⁴⁾ Figure 2.11 | Demyelinating | Density ↓; OB; on acid cresyl violet stain metachromatic material; EM - macrophages, Schwann cells & occasional axons containing prismatic inclusions, tuffstones, zebra bodies and vacuoles | Diagnostic picture on biopsy. Biopsy is useful where white cells enzymes cannot exclude or confirm MLD. |
| Cockayne syndrome ⁽²⁹⁵⁾ Figure 2.12 | Demyelinating | Demyelinating fibres; Schwann cells containing granular inclusions | |
| Neonatal adrenoleukodystrophy ⁽²⁴⁰⁾ | Demyelinating | Demyelinating fibres with no Schwann cell inclusions | Peripheral neuropathy occurs in 30-50% of cases |
| Phytanic acid storage deficiency ⁽²⁹⁶⁾ | Demyelinating | ↓ density of MF; segmental demyelination; clusters; large OB. EM lipid inclusions | HMSN IV; Refsum's disease |
| Abetalipoproteinemia ⁽²⁹⁷⁾ | Axonal | ↓ large MF density; clusters; paranodal demyelination | |
| Tangier disease ⁽²⁹⁸⁾ | Demyelinating | Demyelinating and remyelinating pattern; multiple lipid vacuoles especially concentrated in Remak cells. | Mononeuropathy occurs in childhood; pseudosyringomyelic syndrome occurs after the second decade. |
| Chediak-Higashi Syndrome ⁽²⁹⁹⁾ | Axonal | Giant lysosomal inclusions in Schwann cells of peripheral nerves (and through the nervous system) | |
| Xeroderma Pigmentosa ^(300,301) | Axonal and Demyelinating | ↓ MF and unMF. Denervated Schwann cell subunits and ↑ collagen pockets | |

| | | | |
|--|--|--|---------------|
| Cerebrotendinous xanthomatosis | Axonal ⁽³⁰²⁾ and Demyelinating ⁽³⁰³⁾ | ↓ large MF Hypertrophic demyelinating neuropathy. Cholesterol deposits. Occasional lipid accumulation in the nerves. | Cholestanosis |
| Porphyria ⁽³⁰⁴⁾ | Axonal | Loss of large MF with active axonal degeneration | |
| Hereditary tyrosinaemia ⁽³⁰⁵⁾ | Axonal | Active axonal degeneration with secondary demyelination | |

Key: MF = myelinated fibre; EM = electron microscopy; OB = onion bulb formation; MLD = metachromatic leukodystrophy

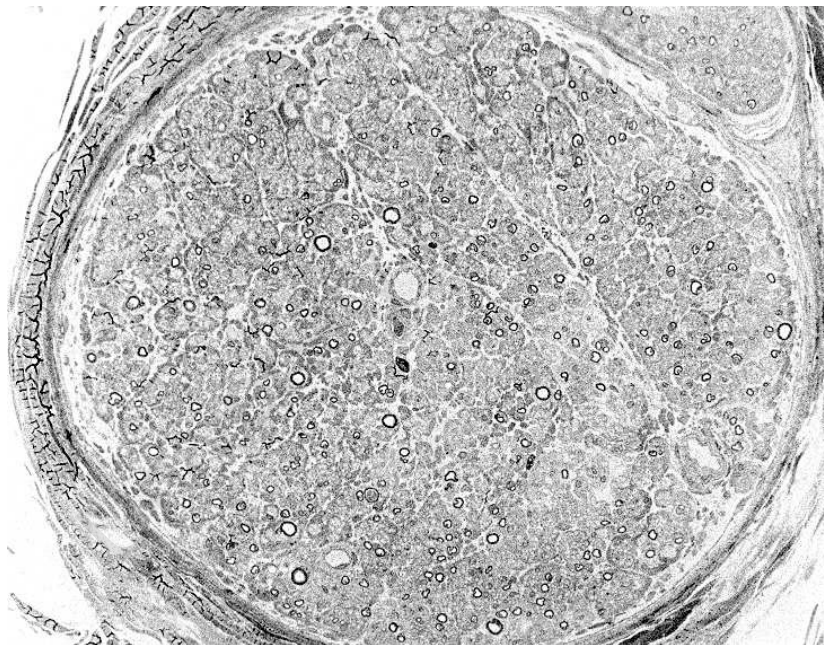


Figure 2.9: Transverse section of a nerve fascicle from a patient with Friedreich's ataxia (LM, toluidine blue, magnification x100). There is marked reduction in MF density, especially of the large MF.

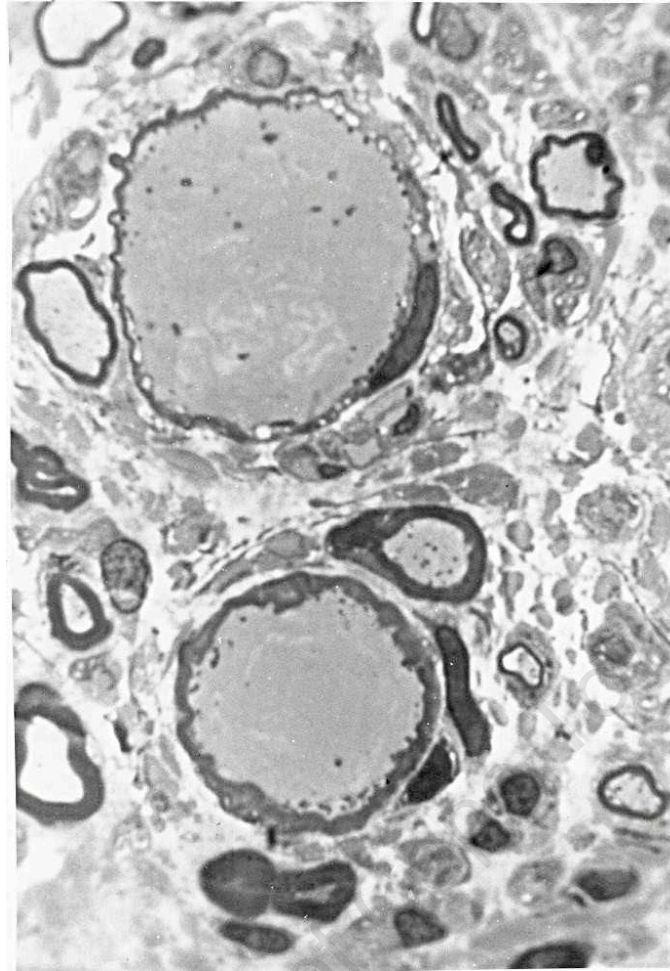


Figure 2.10: Electron micrograph from a patient with giant axonal neuropathy. Two abnormally large fibres are shown (>30 microns diameter), they are surrounded by thin myelin and the axons packed with neurofilaments. The fibres are surrounded by rudimentary onion bulbs. (Magnification estimated x12000)

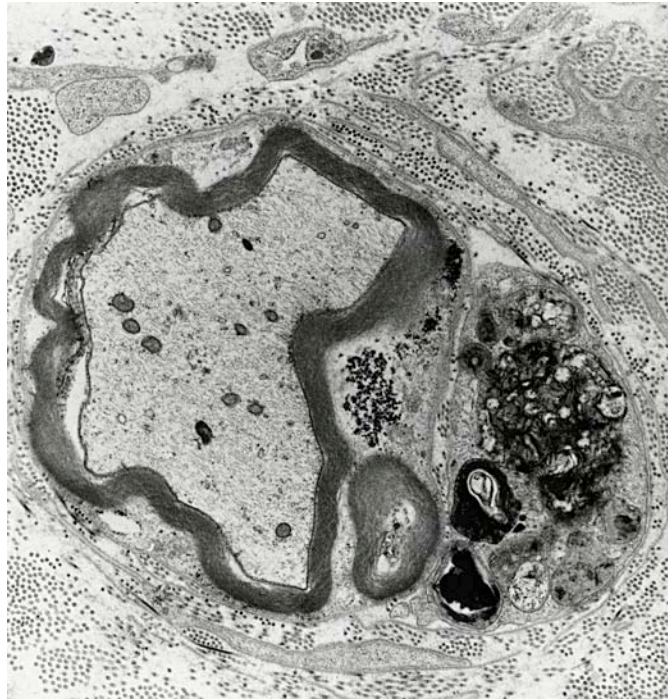


Figure 2.11: Electron micrograph of a patient with metachromatic leukodystrophy. Fibre is thinly myelinated. Tuff-stone bodies and zebra bodies are present within the Schwann cell cytoplasm. (Magnification estimated x20000)

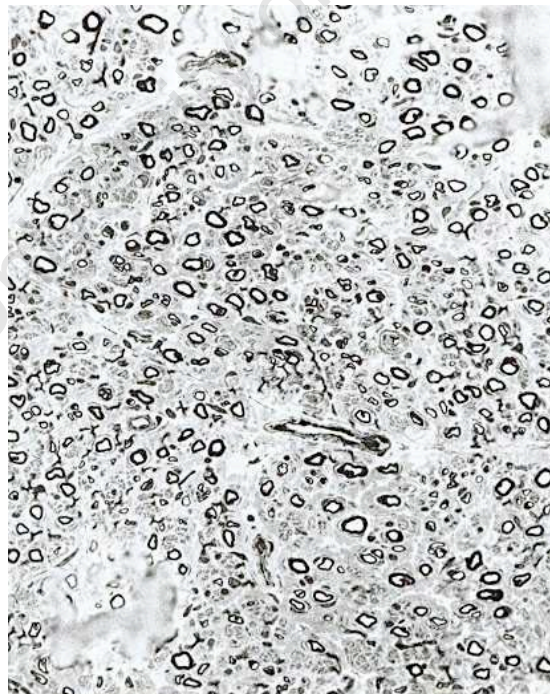


Figure 2.12: Transverse section of part of a nerve fascicle from a patient with Cockayne syndrome (LM, toluidine blue, magnification x200). Both onion bulbs and cluster formations are evident.

Table 2.3: Toxic, nutritional deficiencies and miscellaneous.

| Disease | Type of neuropathy | Biopsy findings | Comment |
|---|---|---|---|
| Glue – sniffing neuropathy ⁽³⁰⁶⁾ | Axonal | Swelling of the axons and thinning of the myelin. EM axonal swellings densely packed whorled masses of neurofilaments | Diagnostic picture on biopsy |
| Lead ⁽³⁰⁷⁾ | Axonal | Chronic and active axonal degeneration | |
| Chemotherapy (vincristine) ⁽³⁰⁸⁾ | Axonal | Axonal degeneration | |
| Ciguatera ⁽³⁰⁹⁾ | Axonal | Oedema of the adaxonal Schwann cell cytoplasm. | Poisoning from consuming toxins in fish from the tropics |
| Vitamin B ₁ deficiency ⁽³¹⁰⁾ | Axonal | Axonal degeneration with central peripheral distal (“dying back”) axonopathy | Thiamine |
| Vitamin B ₁₂ deficiency ⁽³¹¹⁾ | Axonal | Axonal degeneration | Cases described of infants affected after being breast fed by vegetarian mothers ⁽³¹²⁾ |
| Vitamin E deficiency ⁽²²⁸⁾ | Axonal | Loss of large MF and axonal degeneration. | Consider familial vitamin E deficiency (AVED) which can resemble Friedreich’s ataxia ⁽²²⁹⁾ |
| Neurofibromatosis Figure 2.13 | Axonal ⁽³¹³⁾ / Demyelinating ⁽³¹⁴⁾ | Damage due to neurofibromas in the nerve sheath ⁽³¹⁵⁾ with both demyelination and | An association with HMSN has been suggested ⁽³¹⁶⁾ |

| | | axonopathy described | |
|---|--------|---|---|
| Hereditary amyloid neuropathy ⁽³¹⁷⁾ | Axonal | Loss of MF, especially small MF. Positive birefringence of amyloid deposit with congo red stain | Very rare in childhood |
| Allgrove syndrome ⁽³¹⁸⁾ | Axonal | Axonal degeneration; minor loss MF | Alacrima, achalasia, adrenal insufficiency and autonomic dysfunction. Mutant WD-repeat protein is described. ⁽³¹⁹⁾ |
| Multiple endocrine neoplasia type 2B ⁽³²⁰⁾ | Axonal | Moderate loss MF | Characteristic adventitious plaque of tissue composed of hyperplastic, interlacing bands of Schwann cells and MFs overlaying the posterior columns of the spinal cord. Related to mutations in the RET proto-oncogene. ⁽³²¹⁾ |

Key: EM = electron microscopy; MF = myelinated fibre

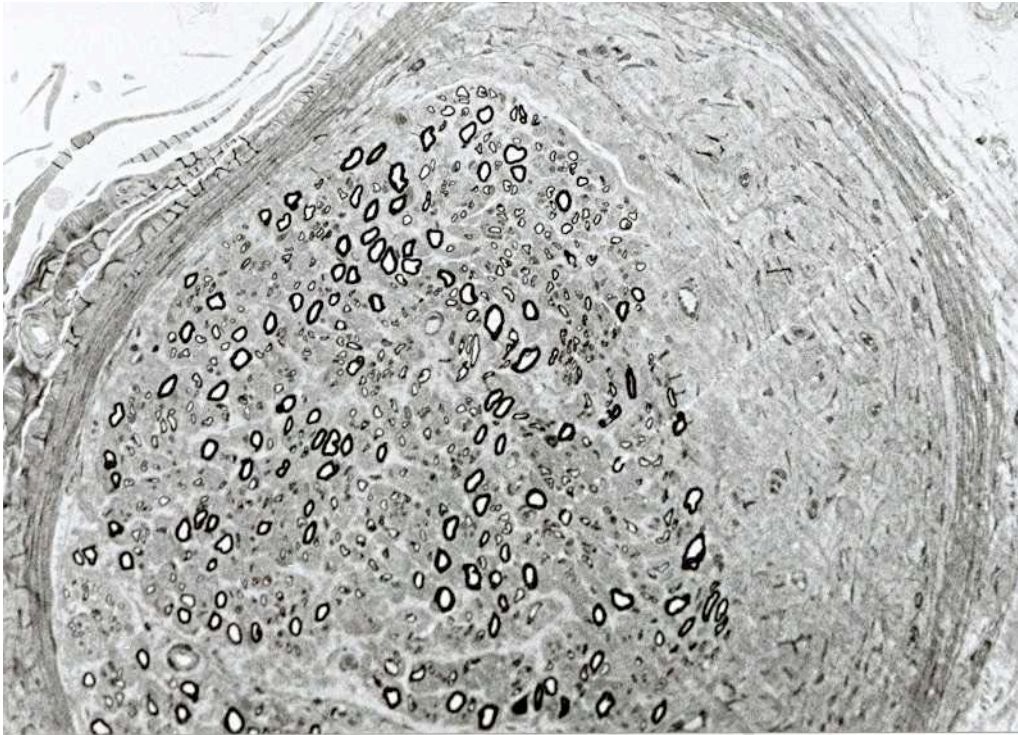


Figure 2.13: Transverse section of a nerve fascicle from a patient with neurofibromatosis type 1 (LM, toluidine blue, magnification x200). The subperineurial space is increased, containing neurofibromatous tissue.

Conclusion

Peripheral nerve biopsy is a valuable investigative modality when appropriately utilised and examined by a reliable laboratory. It is an invasive test and therefore must have well defined indications. This study should not be performed without good reason. The data derived can provide diagnostic information as well as both prognostic advice and patient management information. In the setting of a hereditary peripheral neuropathy, a sural nerve biopsy of just one affected member can sometimes provide helpful data for the entire family.

Vignettes.

Case 1:

This adopted full term male child was born to a thirteen year old mother in 1981 by Caesarean section. Her medical history was unremarkable. No details of the father were known. He had mild bilateral ptosis in infancy and hypotonia before his first birthday. He could sit if placed at six months but did not weight bear on his legs at 14 months. On neurological examination at age twenty months, he had mild bilateral ptosis, generalized hypotonia and mild weakness. All muscle stretch reflexes were absent.

He eventually walked independently at age three years. By age four years his clinical condition had stabilized however he was still not toilet trained. This boy appeared of normal or near normal intelligence. He was able to run a little in a waddling fashion. Although he appeared to feel pain normally, he seemed to have unpleasant sensations when his hands or body were rubbed, as with a towel. Both pupils reacted sluggishly to light. He was unable to converge and had bilateral ptosis. Mild bilateral facial weakness was present, more marked on the right. There was mild proximal and moderate distal weakness with bilateral foot drop. He could not lift his head from the bed or sit with the arms folded in the supine position. The Gowers' manoeuvre was utilized to arise from the floor. He had bilateral foot drop and bilateral pes planus. All muscle stretch reflexes were absent. The peripheral nerves were not palpably enlarged.

His strength was unchanged at age seven years. There was distal loss of vibratory and proprioceptive sensation. By twelve years, he had difficulty walking because of increasing weakness and ataxia. His pupils no longer reacted to light.

The following tests were normal: full blood count, serum electrolytes, serum calcium, magnesium and phosphorus, fasting blood glucose, serum uric acid, liver function tests, EEG, 3 day faecal fat estimation, serum lipid electrophoresis, urine metabolic screen, urinary excretion of lead and arsenic, free erythrocytic protoporphyrin level, serum phytanic acid, white cell aryl sulphatase level, and creatine phosphokinase. DNA testing for mutations of the PMP22 and MPZ proteins was negative. Cerebrospinal fluid protein was 20mg/dl. Fasting serum cholesterol was 5.3 mmol /litre (repeat 4.4 mmol / litre) (normal range 3.1 – 5.2 mmol / litre).

At age 20 months, sensory nerve action potentials (SNAPs) were absent on testing the left median and ulnar nerves. Motor nerve conduction velocities ranged between 24 to 19.5 m/s for the right median, left ulnar and left peroneal nerves. EMG of the left tibialis anterior muscle was unremarkable. Repeat nerve conduction studies were unchanged at 2.5 years.

Sural nerve biopsy (at age-20-months) confirmed the diagnosis of hereditary motor and sensory neuropathy with focally folded myelin sheaths (CMT 4B) (Figure 4.2).

Comment:

Three other similar, but sporadic, cases are recorded in the Sydney series of 260 biopsied children. About half of such cases have a mutation of the myotubularin gene. Currently, nerve biopsy is the only means to make the diagnosis of individual instances of CMT 4B when there is no record of other affected family members and DNA studies are negative.

Case 2:

After a normal pregnancy, this boy delivered at term weighing 3.3 kg. He was not a very active infant. His infantile period was complicated by severe reflux, asthma, recurrent ear infections, and tracheomalacia. There was no family history of neuropathy or other neurological abnormality. Although he walked at 14 months of age he was clumsy with an unusual gait. His feet tended to “flop” down with each step, resulting in frequent falls and unsteadiness. Speech dyspraxia was diagnosed at age 20 month. His was of normal intelligence.

At age three years he presented with a febrile illness. He was hypotonic and had absent muscle stretch reflexes. Initially Guillain-Barré syndrome was considered. He also had myoclonic jerks. Over the following year, he remained stable but appeared weaker after febrile illnesses. He tired after 10 minutes of walking.

At the age of four years he remained a small child with a head circumference of 51.5cm, weighing just 15 kg. His speech was difficult to follow but contained many words and some phrases. He was chronically constipated. His peripheral nerves were not thickened. Pupils and optic fundi were normal and there was no nystagmus. Apart from weak ankle dorsiflexors and peroneal groups, his muscle strength was normal. He was ataxic on tandem gait

and could not stand on one leg for more than two seconds. Vibration sense was reduced and he had a delayed response to pain. Muscle stretch reflexes continued to be absent.

Laboratory investigations demonstrated normal full blood count, serum lead, B12, folate, iron studies, phytanic acid, plasma lactate, vitamin E, lysosomal enzymes, lipoproteins and transferrin isoform pattern. Urinary amino acids, organic acids, mucopolysaccharides and oligosaccharides were also normal. CSF protein was 13 mg/dl. Magnetic resonance imaging of the brain was normal. Molecular genetic studies were negative for CMT type 1A and HNPP.

Nerve conduction studies (at four years of age) showed slow motor conduction velocities (median nerve 26 meter / second and ulnar nerve 22 meter / second) and absent sensory responses.

Sural nerve biopsy at the age of 4½ years showed a severe reduction in myelinated fibre density. The unmyelinated fibre density appeared normal. There were no demyelinated fibres or onion bulb formations. The teased fibre preparation showed predominantly small, thinly myelinated fibres with no segmental demyelination. The changes were consistent with a moderately severe axonal neuropathy of childhood.

Comment:

Clinically this boy was considered to have HMSN type III but his motor conduction velocities, though slow, were not as delayed as would be expected. The sural nerve biopsy confirmed that he had an axonopathy and not a demyelinating condition. Thus, he may well have HMSN of axonal type with early onset. ⁽¹⁰³⁾ From the Sydney series this condition is far commoner than recognized or reported in the literature. The nerve conduction velocities are sometimes in the demyelinating range in axonal degeneration presumably because of failure to develop, or loss of, large diameter fibres. Without proceeding to nerve biopsy in these patients the underlying nature of the pathology may be missed. This situation is particularly likely to be seen in patients whose neuropathy dates from birth or the first year or two of life.

CHAPTER 3

CHRONIC PERIPHERAL NEUROPATHIES PRESENTING IN CHILDHOOD

– 37 YEARS OF DATA FROM AN AUSTRALIAN POPULATION

SUMMARY

Over a 37 year period (1969-2007) 296 (153 female: 143 male) biopsy-proven peripheral neuropathies were identified from a total of 426 (205 female: 221 male) samples taken from patients less than 17 years of age. Biopsies came mainly from the two paediatric neurology units in Sydney. Samples were sent from a few patients from other centres and the clinical decision reasons for the biopsies were not the investigator's responsibility.

Of the group 169 had axonopathies, 107 had demyelinating neuropathies, 20 had a mixed picture and 130 were normal. Inherited aetiology was probable in 248, 161 of whom had primary or "pure" peripheral neuropathy disorders and 87 had peripheral neuropathy secondary to generalised (or metabolic) illnesses.

Within the inherited group 87 were pure axonal disorders and 56 secondary to generalised illnesses, whilst 73 were pure demyelinating disorders and 17 secondary to generalised illnesses. The remainder were mixed axonal and demyelinating (n=15). Of the patients where hereditary motor sensory neuropathies were the primary disorder, of those who underwent genetic analysis, confirmation was made in 34 out of 50 patients with demyelinating histopathological changes, 14 out of 33 patients with axonal degenerative changes and one of four patients with mixed axonal and demyelinating features. Fifteen out of 25 of the patients with Friedreich's ataxia and one out of 5 of the patients with spinocerebellar disease had genetic confirmation.

Acquired pathologies were definite or probable in 48 of the total group (axonal n=25, demyelinating n=17 and mixed picture n=6).

This study demonstrated that there is a role for peripheral nerve biopsy if molecular biological investigations are unavailable or inconclusive. With some conditions, e.g. HMSN with myelin out-folding, giant axonal neuropathy with normal hair, and certain sub-groups of metachromatic leukodystrophy, biopsy may be the only tool which clarifies the diagnosis. The results confirmed the much higher proportion of inherited as opposed to acquired pathologies found in the paediatric age group. Axonal degenerative processes in peripheral nerve are

common in childhood but their pathogenesis is poorly delineated in comparison to demyelinating conditions.

University of Cape Town

INTRODUCTION

Current research in the field of peripheral neuropathies in childhood is dominated by molecular genetics discoveries. This has reduced the input from histopathology. The following work is unlikely to be repeated again with such numbers of patients reviewed over many years and undergoing extensive complements of diagnostic screens. It is intended that the information in the following chapter will provide a comprehensive review of the demographics and epidemiology of chronic peripheral neuropathies which occur in childhood.

METHODOLOGY.

Four hundred and twenty-six patients underwent peripheral nerve biopsy as part of their investigation for suspected peripheral neuropathy.

Samples were from the sural nerve (mid-calf or lateral malleolus) or the superficial saphenous nerve. Samples were prepared by the technique as is standard practice in the Nerve Research Laboratory at the University of Sydney. This is described in detail in chapter 2 (The Role of Nerve Biopsy), page 44.

Data recorded from the light microscopy appearance and, where available, electron microscopy appearance of these peripheral nerve biopsies were reviewed and documented into a database. The principal investigator (JMW) identified biopsies prepared at the Nerve Research Laboratory, University of Sydney, which were performed on children under 17 years of age between 1969 and 2007. The histopathological appearances were examined by herself and assessments made of the pathological findings. She was blinded to the original reports but as part of identifying the samples occasional exposure to these results occurred. To reduce any possible bias from this, on separate occasions independent analyses were undertaken between the principal investigator (JMW) and the other investigators (RAO and JP). The latter two were reliably blinded to the pathology reports and the principal investigator's assessments. Based on these two assessments a consensus was reached as to the biopsy findings, categorising the results into axonal, demyelinating and mixed features, and additional features. Images of the significant pathological findings were taken by the principal investigator (JMW) and Dr Min Wang, histopathology specialist, at the Nerve Research Laboratory. These images were incorporated into a digital database used at the centre for educational purposes. Permission was gained to use the images in this thesis.

Additional data including the child's date of birth, age at time of biopsy, age at time of clinical presentation, clinical phenotype, biochemical investigations, molecular genetic results, nerve conduction study findings, and muscle biopsy findings were collated by the principal investigator to aid categorisation of the cohort. This data was accessed through the patient medical records, previous neurophysiological results and direct contact with the referring physician. Patients were broadly categorised as having hereditary neuropathies, neurodegenerative disorders with associated neuropathies, acquired neuropathies or as belonging to a miscellaneous group. Hereditary peripheral neuropathy groupings consisted of CMT1-5, CMTX, hypertrophic demyelinating, HMSN VII, atypical demyelinating, EOHMSN, SMARD1, atypical chronic axonal, and sporadic sensory neuropathy. These were referred to as the "pure" hereditary neuropathies. The neurodegenerative disorders included all conditions with evidence of central nervous or systemic metabolic dysfunction. A further group separate but linked to this category included hereditary conditions with structural defects such as neurofibromatosis and spinal muscular atrophy. The acquired peripheral neuropathies were related to post-infectious complications, autoimmune disorders and toxin exposure. Within each grouping, further subdivisions were made on the basis of the predominant neuropathological pattern, namely demyelinating, axonal degenerative or mixed. Demyelinating neuropathy was defined by the presence of a reduction in myelinated fibre density, with thinning or hypoplasia of the myelin sheaths, paranodal and/or segmental demyelination in teased fibre preparations and onion bulb formations. Axonal degenerative neuropathy was defined by reduction in the myelinated fibre density, with active or chronic axonal degeneration and cluster formations, with only rare evidence of demyelination. Mixed neuropathy had obvious features of both axonal degeneration and demyelination at the light microscopic level. Diagnostic labels followed the existing criteria in the literature and paralleled descriptions in Tables 1.2-1.4.⁽⁴⁴⁾

RESULTS.

A total of 426 peripheral nerve biopsies (205 females: 221 males) were reviewed, 130 were considered within normal limits. These normal studies were from patients with central nervous neurodegenerative disorders, hypotonia in infancy and patients with undefined conditions undergoing extensive diagnostic “work-ups”.

Of the remaining 296 (153 female: 143 male) peripheral nerve biopsies, 169 had axonal degenerative neuropathies, 107 demyelinating neuropathies and 20 had a mixed picture. The groups were further divided into diagnostic categories depending, in addition to the peripheral nerve biopsy findings, on the clinical phenotype, neurophysiology and molecular genetics findings.

One hundred and sixty-one patients had a hereditary peripheral neuropathy in isolation, 78 had a neurodegenerative or metabolic disorder, 9 had other inherited disorders (e.g. neurofibromatosis, SMA) and 48 had acquired disorders (Figure 3.1). Two hundred and forty-eight out of the total of 296 had a hereditary nature to their disorders. Diagnostic categories and molecular genetic findings are summarised in Table 3.1. Figure 3.2 summarises the overall patient breakdown from the total number assessed (n=426) to those who gain molecular genetic diagnoses.

All children had accepted clinical features of peripheral neuropathy, namely distal wasting (especially of their thenar/hypothenar eminences and extensor digitorum brevis muscles), distal weakness and absent or reduced deep tendon reflexes (except the HMSN V group).

Apart from one child with discomfort due to cicatricial traction at the posterior calf nerve biopsy site (a site which the study unit does not usually select), side effects in this cohort of patients from sural nerve biopsy were not an issue, which is supported by other studies, and children seem to tolerate the investigation better than adults.^(322,323)

**Figure 3.1: Summary of total group with peripheral neuropathies
n=296**

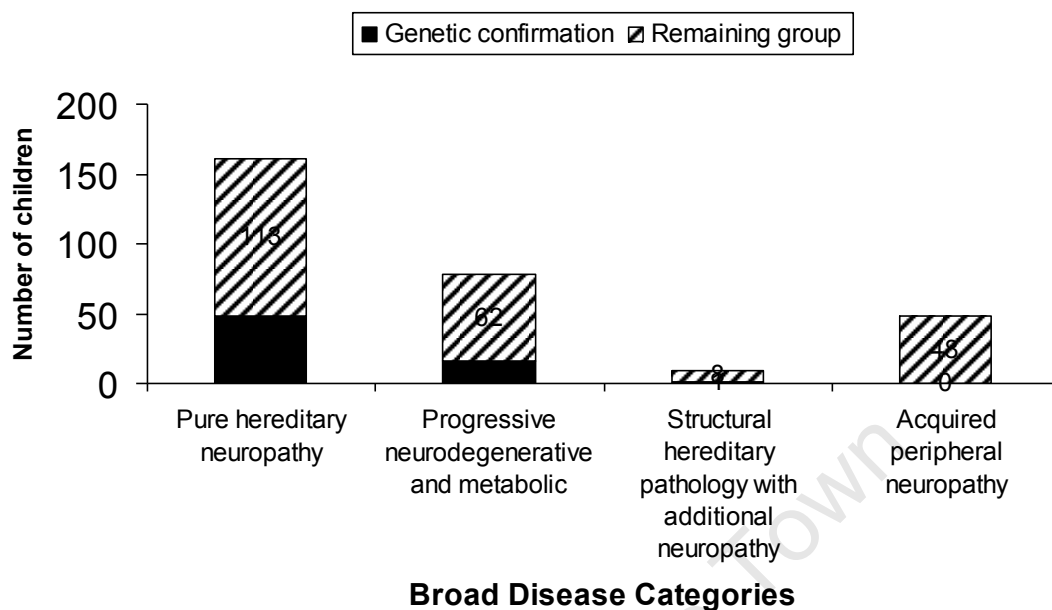
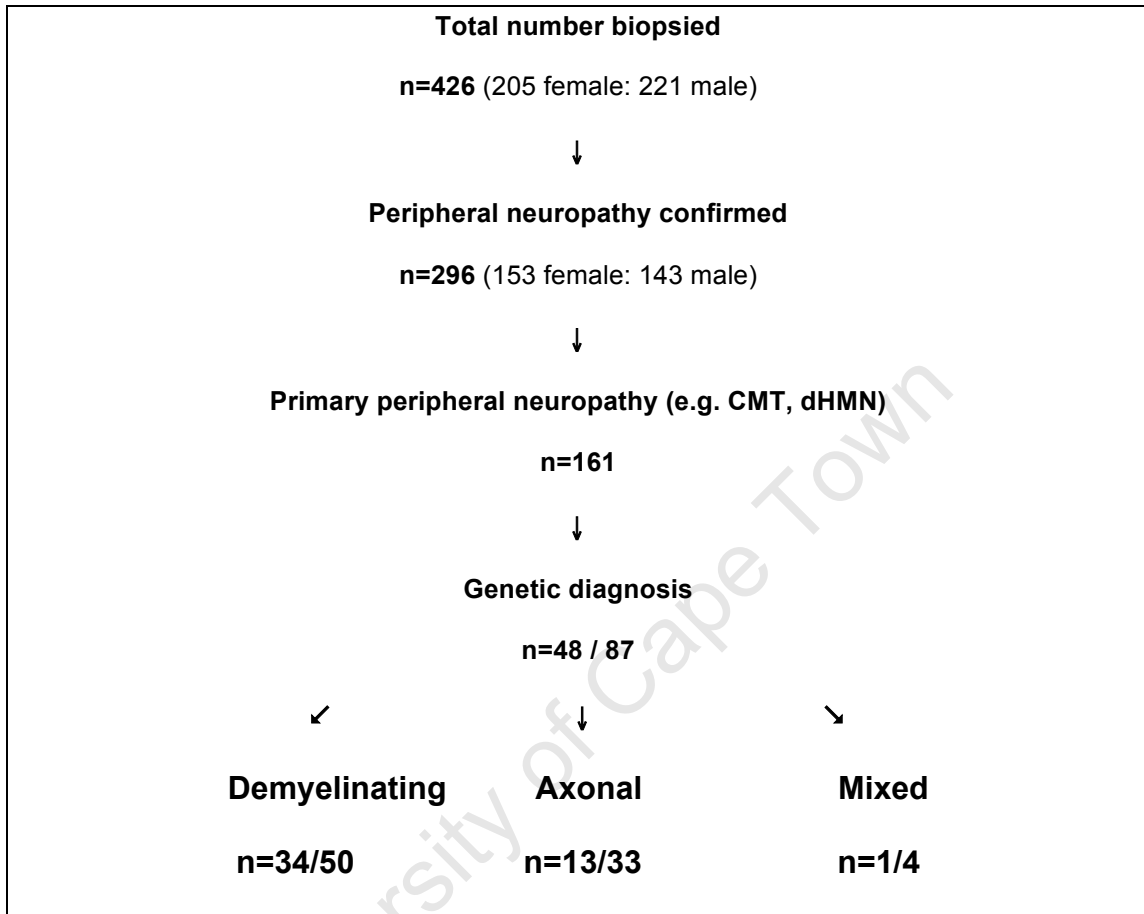


Table 3.1: Summary of the motor sensory neuropathies with genetic correlation

| Type | Sub-type | Genetics | Patients with genetic results (n) | Total |
|----------------------------------|----------|----------------------------|-----------------------------------|-----------|
| CMT1 | 1A | Duplication chr 17 | 20 | 20 |
| | | | | 1 |
| | 1A or B | | | 1 |
| | | Sporadic FH +ve | | 5 |
| | | | | 27 |
| CMT2 | | FH +ve / dominant | | 8 |
| | 2A | Mitofusin | 3 | 3 |
| | 2E | | | 1 |
| | | | | 12 |
| CMT3 | | P ₀ mutation | 6 | 6 |
| | | PMP ₂₂ mutation | 3 | 3 |
| | | Sporadic / FH | | 5 |
| | | | | 14 |
| CMT4 | 4B | P ₀ mutation | 1 | 1 |
| | | | | 4 |
| | 4H | Frabin | 1 | 1 |
| | | | | 6 |
| Remyelinating / demyelinating | | Sporadic / recessive | | 16 |

| | | | | |
|--|-------------------|----------------------|----|-----------|
| EOHMSN | | Mitofusin mutations | 5 | 5 |
| | | Sporadic / recessive | | 13 |
| | | | | 18 |
| HNPP | | 17 p duplication | 3 | 3 |
| CMTX | X1 | Connexin 32 mutation | 1 | 1 |
| | X1 | FH | | 3 |
| | X1 | Sporadic | | 1 |
| | X5 | PRPS1 mutation | 1 | 1 |
| | X5 | Sporadic | | 2 |
| X type unknown | | | | 1 |
| | | | | 9 |
| HMSN V (CMT5) | | Sporadic | | 2 |
| HMSN VII | | Sporadic | | 1 |
| Atypical demyelinating (Miscellaneous) | | | | 6 |
| SIANR / SMARD1 | | IGHMP1 | 5 | 5 |
| | | Sporadic / recessive | | 2 |
| | | | | 7 |
| Severe relapsing axonal | | Recessive | | 2 |
| Atypical chronic axonal and sensory neuropathy | | Sporadic / recessive | | 31 |
| Distal motor neuropathy | | Sporadic / recessive | | 1 |
| HSAN | Type 1 | | | 1 |
| | Type 4 | | | 2 |
| | Type 5 | | | 1 |
| | Miscellaneous | | | 2 |
| | | | | 6 |
| Friedreich's ataxia | | Triplicate repeat | 13 | 13 |
| | | Point mutation | 2 | 2 |
| | | Sporadic / recessive | | 10 |
| | | | | 25 |
| Spinocerebellar ataxia | SCA miscellaneous | | | 6 |
| | SCA7 | | 1 | 1 |
| | | | | 7 |

Figure 3.2: Flow chart of patient breakdown leading to definitive genetic confirmation

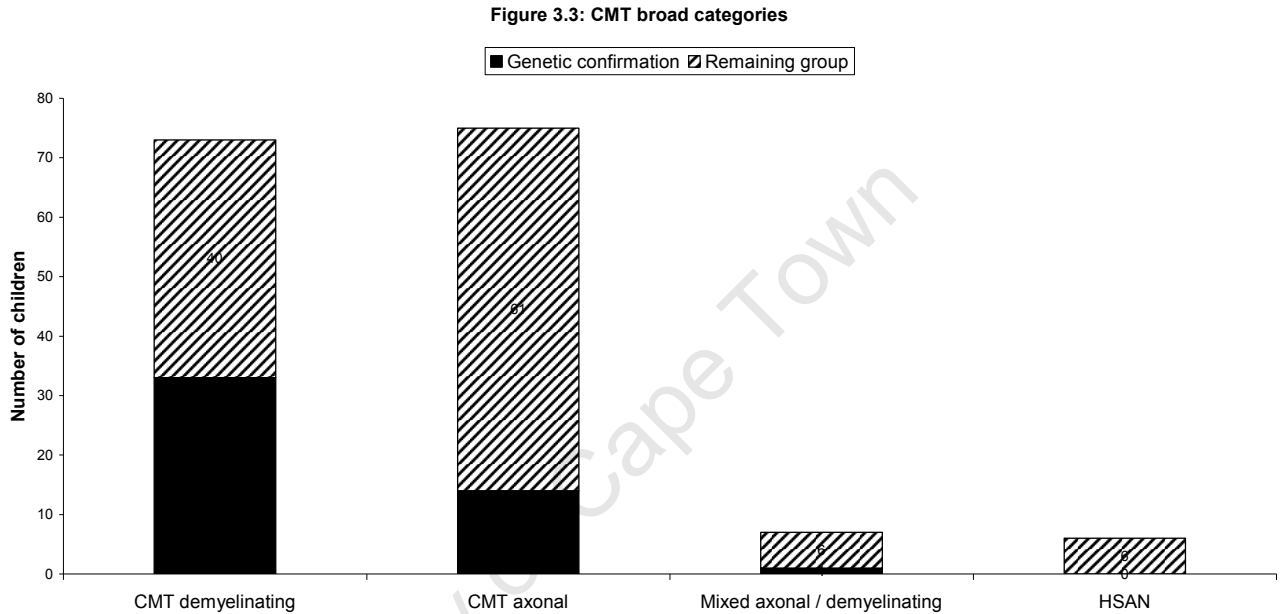


CHARCOT MARIE TOOTH GROUP (CMT)

Patients whose biopsies were categorised into the Charcot Marie Tooth group were divided into those with demyelinating, axonal and mixed features (Figure 3.3). Separate subsections described these groups in more detail (Figures 3.4-3.7).

(Hereditary motor sensory neuropathies)

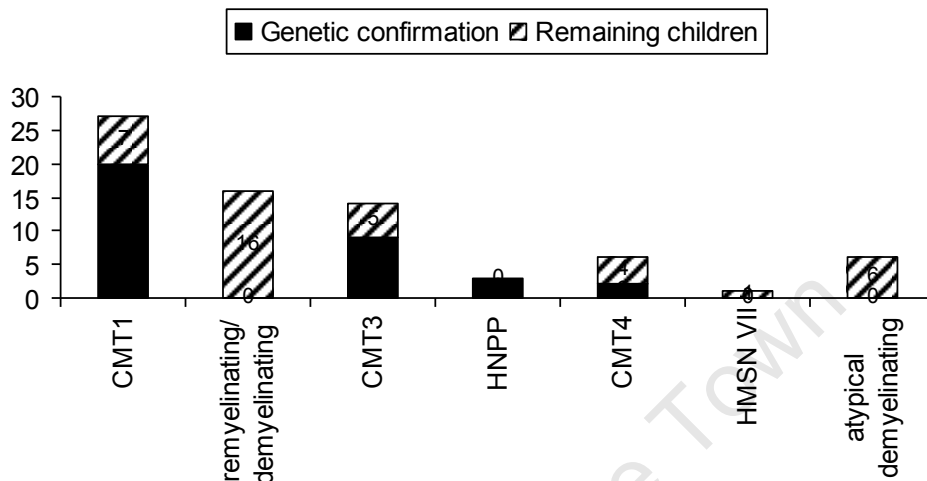
n= 161 (83 female: 78 male) (Figure 3.3)



DEMYELINATING NEUROPATHIES

n=73 (36 female: 37 male) (Figure 3.4)

Figure 3.4: Demyelinating group n=73



Twenty-seven patients (13 male: 14 female) had features consistent with **CMT1**.

Genetic studies confirmed type 1A with chromosome 17p duplication in 20 patients, five were family history positive, one had a clinical phenotype of type 1A or B and one was sporadic with no affected relatives. From the group with genetically confirmed CMT1A (11 female: 9 male), 13 patients had a positive family history and nine presented under 2 years of age. Clinical features included pes cavus (n=10), ataxia (n=5), enlarged nerves (n=7), sensory involvement (n=6), cranial nerve involvement (n=4) and nystagmus (n=2). One patient also had developmental delay; she had chromosome 17p trisomy and was previously described.⁽³²⁴⁾

Sensory nerve conduction studies were abnormal in fourteen of fifteen children tested. Motor NCS showed median *common peroneal* (n=12) and *median* (n=13) velocities of 16 m/s (range 5 – 45 m/s). Three patients had no potentials on stimulating their common peroneal nerves and one of these patients also had no response to stimulation of their median nerve. The patient with 17p trisomy had normal motor and sensory conduction studies. Median biopsy age was 8 years (range 1 –16.5 years). Sural nerve biopsies confirmed moderately or markedly reduced myelinated fibre density in all patients (n=26). Transverse section analysis showed active demyelination (n=17), axonal degeneration (n=1), onion bulb formations (n=15), no cluster formations and tomaculous myelin (n=1). Teased fibre analysis performed

in 16 showed segmental demyelination (n=16) (Figure 3.4a) and axonal ovoids (n=2). Electron microscopy performed in seven showed onion bulb formations (n=5) and no cluster formations. *In summary almost half the patients with CMT1 presented by 2 years of age, conduction studies were typically delayed in the region of 16 m/s and sural nerve biopsies showed consistent demyelinating features.*




Figure 3.4a: Teased fibre analysis (x 200 magnification) of patient with CMT1A demonstrating segmental demyelination over numerous fibres.

Sixteen patients (5 female: 11 male) were labelled **remyelinating / demyelinating** with sporadic or recessive disease. Negative molecular genetic screens were found for duplication of chromosome 17p (n=2), *MPZ* mutation (n=4), *PMP22* mutation (n=4), *connexin* 32 (n=3), *GDAP1* (n=1), *MTMR2* (n=1) and *mitofusin* (n=1). One male patient had a polymorphism in the *GDAP1* region c.421T>G but since this was not associated with a change in amino acids was not considered pathogenic. Four patients had a positive family history. Three children presented before one year of age and a further eight by 5 years of age. Clinical features included pes cavus (n=13), ataxia (n=3), enlarged nerves (n=7), sensory involvement (n=9), cranial nerve involvement (n=1) and nystagmus (n=3). One patient had developmental delay. Six children had kyphoscoliosis. Sensory conduction velocities were abnormal in all fifteen children tested. Motor conduction velocities showed median *ulnar* (n=10) and *median* (n=15) velocities of 17 m/s (range 0 – 39 m/s), and *common peroneal* velocities (n=15) of 0 m/s (range 0-39m/s) where testing failed to stimulate a potential in most of the nerves tested. EMG was performed in seven children, one was normal, one was described as myopathic and the remaining five recorded denervation changes. Median age at biopsy was seven years

(range 0-16 years). Sural nerve biopsies identified markedly or moderately reduced myelinated fibre density in 14 of the 16 patients. Light microscopy transverse sections detected active demyelination in twelve and secondary axonal degeneration in 2 patients. Onion bulb formations were seen in 14 and cluster formation in 2 patients. On teased fibre analysis (n=14), demyelination was seen in 12 and axonal changes in 2 patients. On electron microscopy (n=12) onion bulbs were seen in 10 patients and no cluster formations. *In summary over half the patients in this group presented by 5 years of age, a third developed kyphoscoliosis and the majority had distal weakness, pes cavus and abnormal reflexes. Neurophysiology revealed slower conduction velocities than the CMT 1 group. Sural nerve biopsy findings were similar with active demyelination, reduced myelinated fibre density and onion bulb formations. These patients are likely to have forms of CMT4 with mutations yet to be identified.*

Fourteen patients (8 female: 6 male) had **CMT3 (Dejerine Sottas Syndrome)**. Molecular genetic testing confirmed myelin protein zero point mutations in six and PMP22 point mutation in three. Of the positive group the exact mutations from the *myelin protein zero* mutation patients included one patient with a six base pair insertion (AGTTCT) in exon 3, resulting in a 2 amino acid insertion (Phe-Tyr) after aspartate 118, another with a C to G substitution at nucleotide 188, leading to a ser 63 cys substitution in the extracellular domain (exon 2), the third patient had a homozygous 3 base pair deletion in exon 3, resulting in the deletion of the Phe-64 (extracellular), two patients with a C to T substitution leading to arg 69 cys on exon 2 (extracellular) and one patient with 563_564insC Ala188. From the PMP 22 point mutation group one patient had a cytosine to adenine base change on exon 1 causing a histidine / glycine substitution at position 12 and two patients had cytosine changed to thymidine on exon 3, causing a serine/leucine substitution at position 12. Of the five patients without molecular genetic confirmation two predated screening, one was *mitofusin 2* mutation negative, one duplication of chromosome 17 negative and the other negative for mutations in *connexin 32*, *myelin protein zero* and *PMP 22*. Of the remaining group clinical features, nerve conduction studies and biopsy findings were consistent with the diagnosis of CMT3. Three children had clinical symptoms by 1 year of age and a further 7 by 2 years age and the remainder sought medical advice by five years of age. Clinical features included pes cavus (n=9), distal contractures (n=9), ataxia (n=7), weakness present in all (distal maximally n=6

and globally n=8), enlarged nerves (n=9), sensory involvement (n=10), cranial nerve involvement (n=5) and nystagmus (n=8). No patients had cognitive developmental delay. Four patients had kyphoscoliosis. Median CSF protein was 0.85g/l (range 0.20 – 1.8g/l). Sensory nerve conduction studies were abnormal in all 14 children. Motor conduction studies (n=13) failed to stimulate responses in 6 patients and in the remaining patients, four recorded median nerve conduction velocities below 10 metres / second, two below 24 metres / second and one 32 metres / second. These patients with faster conduction from the median nerve recorded values of below 10 meters / second over their common peroneal nerves. EMG was performed on two patients and detected denervation in both. Sural nerve biopsy was performed between 7 months and 14 years of age (median 4 years). Markedly or moderately reduced myelinated fibre density was evident in all patients. Light microscopy transverse sections detected myelinated fibre thinning consistent with demyelination in 14 patients, onion bulb formations in 14 (Figure 3.4b), and secondary axonal degeneration in one. One patient with a confirmed mutation of the myelin protein zero gene had a severe hypomyelinating appearance on the sural nerve biopsy but artefact precluded further interpretation. On teased fibre analysis (n=11), demyelination was seen in 9 (Figure 3.4c), and there were no patients with axonal degenerative changes. On electron microscopy (n=11) 11 patients had onion bulb formations. *In summary this group presented earlier than the other patients with a more severe neuropathy demonstrated both clinically, on NCS and on their sural nerve biopsies. The molecular genetics yield was high in this group.*




Figure 3.4b: Light microscopy toluidine blue immunohistochemical transverse section study of a patient with CMT3 due to a PMP22 gene mutation (x 400 magnification). Image demonstrates multiple onion bulb formations affecting every fibre.




Figure 3.4c: Teased fibre analysis of a patient with myelin protein zero mutation demonstrating marked segmental demyelination involving every fibre (x 200 magnification).

One male patient had **HMSN type VII (HMSN with retinitis pigmentosa)**. He presented before two years of age and had a positive family history with his mother affected. He did not have a duplication on chromosome 17p. He had distal weakness, sensory impairment, abnormal reflexes, developmental delay and retinitis pigmentosa. His neurophysiology revealed a mild motor axonal neuropathy. Sural nerve biopsy performed at the age of 12 years revealed a moderately reduced myelinated fibre density with thinning of myelin and a few onion bulb formations. Teased fibre analysis revealed segmental demyelination. Electron microscopy confirmed demyelinating fibres with a few onion bulb formations. Overall his biopsy was felt to be more consistent with a hypertrophic neuropathy from a primary demyelinating process. *This is a rare form of HMSN and reported cases are usually in adults.*⁽¹⁶⁸⁾

Three children (3 male) had **hereditary neuropathy with liability to pressure palsies (HNPP)**. Molecular genetics confirmed a deletion in the chromosome 17p region in all. All biopsies were performed at the age of 16 years, one child presented in his first decade and the other two in their second decade. None of the children had a positive family history. Patients presented with focal weakness, with variable improvement, in addition they had distal weakness (n=2), sensory changes (n=2), pes cavus (n=1) and abnormal reflexes (n=2). A typical presentation from one of the patients consisted of an 8 month history of weakness of his left upper limb not related to trauma and with a normal MRI of the region. Limited recovery occurred. Nerve conduction studies revealed abnormal sensory conduction in a patchy distribution (related to the focal areas of weakness) and mildly delayed motor conduction velocities also with a patchy distribution consistent with a mononeuritis multiplex picture. EMG was normal in one and showed denervation in the other two. Sural nerve biopsy detected markedly or moderately reduced myelinated fibre density on light microscopy transverse section; tomaculous fibres were evident in all, as well as additional thinly myelinated fibres. Axonal degeneration was also evident in one patient. Teased fibre analysis (n=3) detected axonal changes in one patient and demyelinating features in the other two. EM was not performed. *In summary these children presented in their second decade and were more likely to develop acute symptoms related to pressure palsies. Overall general clinical signs were*

more subtle than in the other groups. NCS were usually within the axonal range. However nerve biopsy detected features secondary to the tomaculous nerve pathology.

Six patients (4 female: 2 male) had **CMT4**. Molecular genetics confirmed a *myelin protein zero* mutation in one patient and a *frabin* mutation in another (CMT4H).⁽²⁴⁷⁾ The remainder were negative for a chromosome 17p duplication (n=3), or for point mutations of the *MPZ* (n=2), *mitofusin2* (n=2), and *MTMR2* (n=1) genes. The phenotype of five patients was suggestive of CMT 4B, including the patient with a *myelin protein zero* mutation. This patient with a *MPZ* mutation (exon 2, Thr65Ala, ACC>GCC) had a positive family history. Two children presented by one year of age, 3 by two years and one by five years of age. Clinical features consisted of distal contractures (n=3), nystagmus (n=1), ataxia (n=3), hypotonia (n=2), kyphoscoliosis (n=3), nerve enlargement (n=1), weakness (distal n=4, generalised n=2), areflexia (n=6), sensory abnormalities (n=4), pes cavus (n=2) and cranial nerve involvement (n=1). Nerve conduction studies were abnormal in all five children tested and motor conduction velocities were markedly slowed either less than 10 meters / second or between 10-24 meters / second. Sural nerve biopsy was performed between 2 and 6 years (median 4½ years). Examination of transverse sections under light microscopy detected marked to moderate reduction in myelinated fibre density and myelin out-folding in all, and thin myelin consistent with de- or hypo-myelination (n=3) (Figures 3.4d and e). One patient had some thickened myelinated fibres. Four patients had onion bulb formations. Teased fibre analysis (n=6) detected demyelinating features (n=5) and axonal degenerative features (n=2). *In summary six patients presented typically by two years of age with clinical features of a severe neuropathy; nerve biopsy was beneficial towards confirming the diagnosis as the clinical and neurophysiological data could not do this in isolation.*

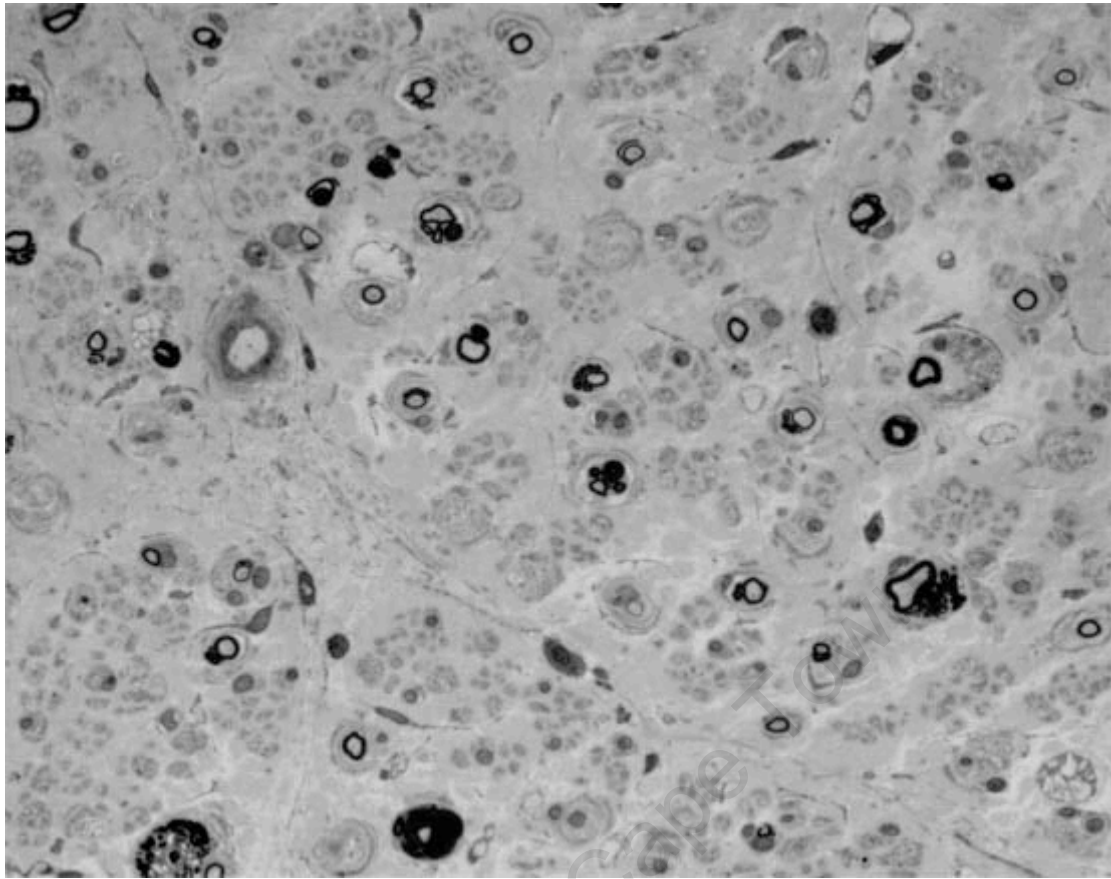


Figure 3.4d: Transverse section light microscopy toluidine blue immunohistochemical stain of a patient with CMT4B, demonstrating reduced myelinated fibre density, onion bulb formations and myelin-outfolding (Magnification x 400).

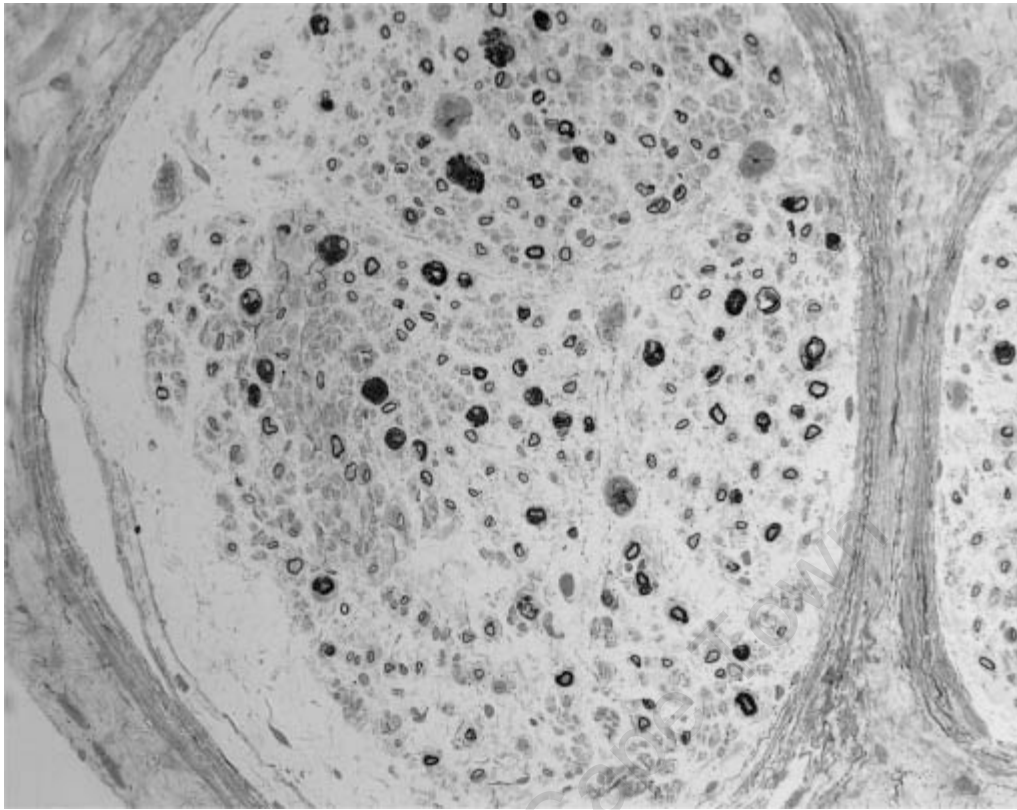


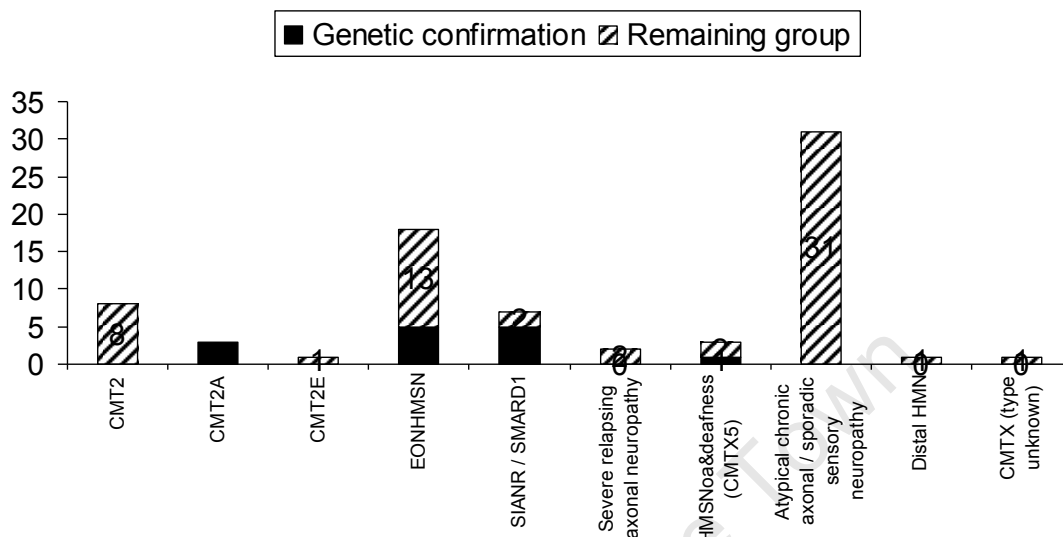
Figure 3.4e: Transverse section light microscopy toluidine blue immunohistochemical stain of a patient with CMT4H due to frabin mutation, demonstrating reduced myelinated fibre density, onion bulb formations and myelin-outfolding (Magnification x 100).

Six patients (5 female: 1male) could not be categorised into any of the recognised hereditary demyelinating neuropathy groups, these were labelled **atypical demyelinating**. These were patients, who despite strong evidence of demyelination on their nerve biopsies, had clinical or neurophysiological features which did not allow categorisation into any of the above groupings. Molecular genetic screening was negative for mutations in *GDAP1* (n=1), *MPZ* (n=2), *PMP22* (n=1). All presented by five years of age and three by one year. Two of the patients were sisters, and one of these sisters went on to have an affected child, suggesting autosomal dominant inheritance. Molecular genetic screening in this family proved negative for chromosome 17p duplication, *MPZ* and *PMP22* mutations. Exclusion criteria were related to a combination of atypical clinical features (n=4), neurophysiological results not in the demyelinating range (n=2) and typical biopsy findings of very mild demyelinating features (n=1).

AXONAL NEUROPATHIES

n=81 (47 female: 34 male) (Figure 3.5)

Figure 3.5: Axonal neuropathies



Eight patients (five female: three male) complied with a diagnosis of **CMT2** (sub-type undetermined). Molecular genetic studies were performed on 6 with absence of spinocerebellar ataxia (SCA) mutations in one, absence of SCA and Friedreich's ataxia (FA) mutations in two, absence of 17p duplication in two and one with an inconclusive result as only one allele was seen. This patient and one other were also connexin 32 negative. One patient was also *MPZ* mutation negative. Five out of the eight children had a positive family history. One child presented less than two years of age, and four were symptomatic by 5 years of age. Clinical features included pes cavus (n=5), absent or reduced deep tendon reflexes (n=8), ataxia (n=2), distal weakness (n=5), generalised weakness and hypotonia (n=1), sensory involvement (n=3), cranial nerve involvement (n=1) and nystagmus (n=1). One patient had mental retardation. Two patients had kyphoscoliosis. Sensory conduction velocities were abnormal in six out of seven children tested. Motor conduction velocities were normal in two patients and marginally slowed in the remainder. EMG, performed in three children, was normal in one and revealed denervation in two. Biopsy was performed between 2 years and 9 months and 16 years (median 13 years). Sural nerve biopsies revealed markedly or moderately reduced myelinated fibre density in 7 of the 8 patients. Light microscopy of transverse sections detected acute axonal degeneration in five patients and

cluster formations in four. On teased fibre analysis (n=7), demyelination was seen in 3 and axonal changes in 4 patients. On electron microscopy (n=1) no cluster formations or active axonal degeneration were detected. *In summary children with CMT2 presented nearer to 5 years or older, clinical signs were less severe and nerve conduction studies were either normal or consistent with an axonal picture. Nerve biopsy confirmed axonal degeneration with most information gained from the light microscopy and teased fibre analysis.*

Three patients were categorised as **CMT2A** (2 female: 1 male) (defined as an autosomal dominant axonal disorder usually associated with *mitofusin2* mutations). One female patient had a phenotype compatible with **CMT2A** but was found to have a homozygous (i.e recessive) *mitofusin2* mutation at c.647T>C. She presented at less than 5 years with localised weakness with a mildly progressive phenotype. There were no other clinically affected family members. Her peripheral nerve biopsy detected axonal degeneration with a moderate reduction in myelinated fibre density and thin myelinated fibres on teased fibre analysis. Nerve conduction studies recorded abnormal sensory studies, normal motor conduction and denervation on EMG. She could also be classified as a mild form of severe early onset axonal neuropathy (SEOAN) or early onset HMSN of neuronal type (EOHMSN).⁽¹⁰⁴⁾ Another female patient was confirmed to have a *mitofusin2* mutation c.640G>A(Asp214Asn). She subsequently had an affected son suggesting dominant inheritance. She had presented by 2 years of age ataxic with distal weakness and contractures. Both the mother and her son had intermediate nerve conduction velocities, the fastest being 33 m/sec. She was not clinically severe enough to be labelled EOHMSN. She had mixed pathology and was labelled **CMT2A**. One male patient presented after five years of age with features consistent with CMT2C (as defined by an axonal neuropathy with vocal cord, diaphragmatic and respiratory involvement, as well as decreased longevity). However his genetic screening confirmed a *mitofusin2* mutation, c.892G>A(Gly298Arg), categorising him as **CMT2A**. He had no affected relatives. He had distal weakness with contracture formation, kyphoscoliosis, and reduced deep tendon reflexes. In his second decade he developed tongue fasciculations and died of respiratory failure aged 16 years. Sensory conduction studies were abnormal, but the motor conduction velocities were within normal limits. Sural nerve biopsy, at the age of 16 years, showed, on light microscopy, active axonal degeneration and demyelination with markedly reduced myelinated fibre density and cluster

formations. Teased fibre analysis showed axonal and demyelinating changes. Electron microscopy confirmed the above findings.

One male patient was categorised as **CMT2E** based on his clinical, neurophysiological and histopathology findings. CMT2E was as defined by typically early childhood onset with gait abnormalities, occasional hyperkeratosis, and prominent sensory involvement with intermediate to slow NCS and on histopathology giant fibres similar to those seen in giant axonal neuropathy. This boy had symptoms from 3 years resulting in peripheral nerve biopsy aged 11 years. There was no family history. He was otherwise well with no evidence of toxin ingestion or metabolic derangements. His onset at 3 years was with foot deformities which progressed until he lost ambulation. He had several dramatic deteriorations from which he did not recover resulting in increased disability. His cranial nerves were normal. His feet were cold and ulcerated. His upper limbs had mild sensory reduction distally. He had no organomegaly. His cognition was normal. His peripheral nerve biopsy had a moderate reduction in his myelinated fibre density involving all fibres; he had giant axons - some with thin sheaths and others with no myelin. There were several onion bulb formations. He did not have teased fibre analysis. He was initially considered to have either giant axonal neuropathy or toxin exposure with glue sniffing most likely, but his clinical presentation did not correlate with these diagnoses. *Although it was not possible to perform NEFL screening on this patient his phenotype correlated with CMT2E.*

Eighteen patients (11 female: 7 male) had **early onset HMSN of neuronal type (EOHMSN)** as defined by a **severe early-onset axonal neuropathy (SEOAN)**.^(2,104,105) Molecular genetic screens confirmed *mitofusin2* mutations in five; namely c.310C>T n=2; c.640G>A + c.1168T>C n=1; c.292A>G (Lys98Glu i.e.K98E) n=1, c1085C>T + 817-2A>G n=1. Of the remainder, 4 underwent additional screens and were negative for duplications on chromosome 17p (n=2), *MPZ* mutation n=1, *mitofusin2* n=3, *Lamin A/C* (n=2) and *FA/SCA* (n=1). Family history following an autosomal recessive pattern of inheritance was positive in three. All children presented by 5 years of age, one before one year of age and a further nine by two years of age. Clinical features included pes cavus (n=5), distal contractures (n=14), hypotonia (n=9), kyphoscoliosis (n=2), reduced or absent deep tendon reflexes (n=17), weakness (distal n=16; generalised n=2), enlarged nerves (n=1), sensory involvement (n=10), optic atrophy (n=1) and nystagmus (n=2). Four patients also had learning difficulties.

Neurophysiological examination revealed that sensory conduction studies were abnormal in 13 out of 14 patients tested. Motor conduction studies detected *median* motor conduction velocities between 32-49 m/s (median 45 m/s) (the median nerves of two patients could not be stimulated), *ulnar* motor conduction velocities between 32-49 m/s (median 45 m/s) (the ulnar nerves of three patients could not be stimulated) and *common peroneal* motor velocities (n=11) which were normal in one, marginally slow in another and could not be stimulated in 9 patients. EMG (n=7) revealed denervation. Sural nerve biopsy was performed between 2 and 17 years of age (median 8 years). Light microscopic examination of transverse sections revealed axonal degeneration (n=4), thinning of the myelin (n=4), markedly or moderately reduced myelin fibre density (n=18), onion bulb formations (n=5) and cluster formations (n=5). Teased fibre analysis (n=15) revealed demyelinating features (n=6) and axonal ovoid formations (n=8). Electron microscopy (n=9) detected cluster formations (n=3) and onion bulb formations (n=1) The patients with *mitofusin2* mutations were found to have unusual cluster formations in some fibres with surrounding basement membrane appearances reminiscent of onion bulb formations i.e. a combination of features typically categorised axonal and demyelinating (Figures 3.5a-c). Many of the mitochondria were smaller than normal and had a rounded appearance, they tended to aggregate at the peripheries of the axons, the inner and outer mitochondrial membranes appeared irregular and the cristae were often disrupted Excessive numbers of Schwann cell nuclei were evident in some patients. A number of these patients and their findings have already been reported.⁽¹⁰⁵⁾ *In summary all patients presented by five years of age, symptomatology was severe and progressive with debilitating distal contractures and weakness. Nerve conduction studies tended to present the severe end of the disease spectrum with frequent failure to stimulate the common peroneal nerves and conduction velocities slower than commonly seen with axonal neuropathies, reflecting the loss of large diameter myelinated fibres involved in the disease.*

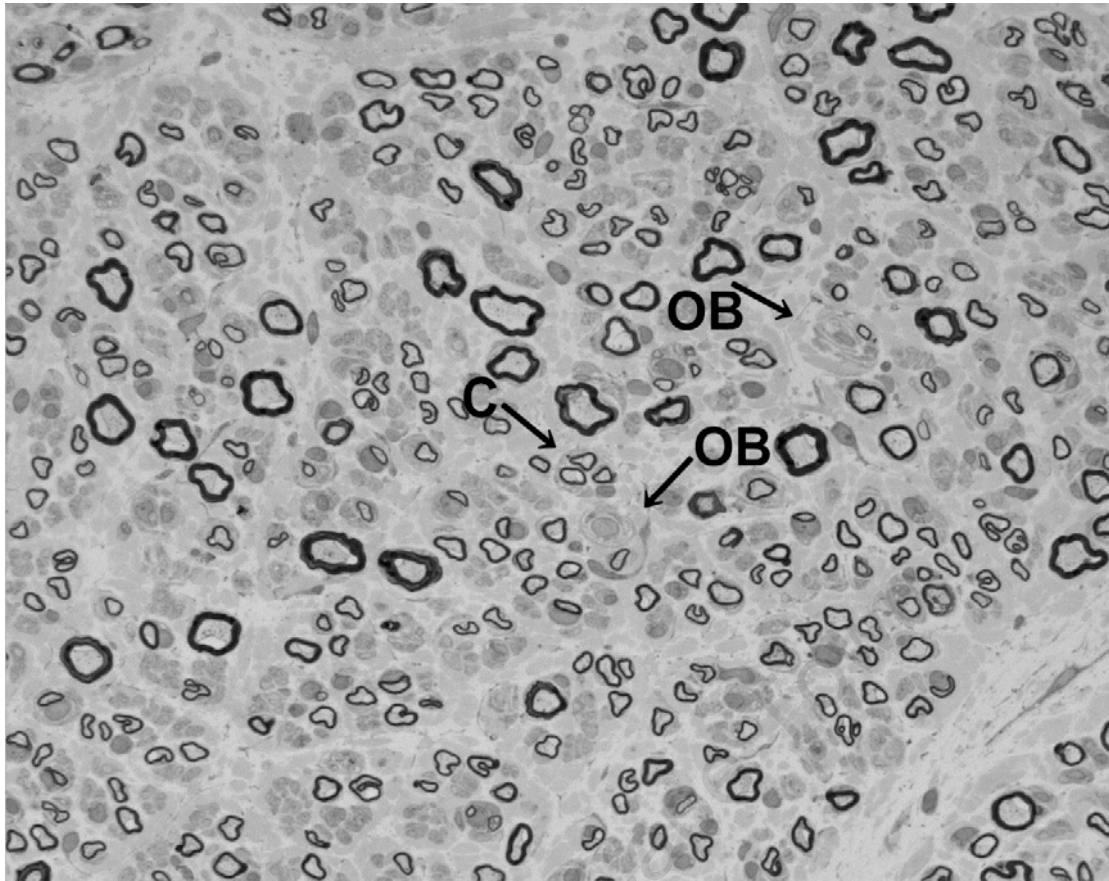


Figure 3.5a: Transverse section: light microscopy toluidine blue stain of a patient with EOHMSN due to mitofusin2 mutation (Magnification x 200). The section demonstrates reduced myelinated fibre density, especially of large diameter fibres, cluster formation (C) and onion bulb (OB) formation. Other sections demonstrated a degree of sub-perineurial oedema. The teased fibre preparations showed several fibres with segmental demyelination. This patient was considered to have mixed pathology with axonal degenerative and demyelinating changes, with the latter predominating. She was initially labelled CIDP but the diagnosis was revised based on her clinical course and molecular genetic findings.

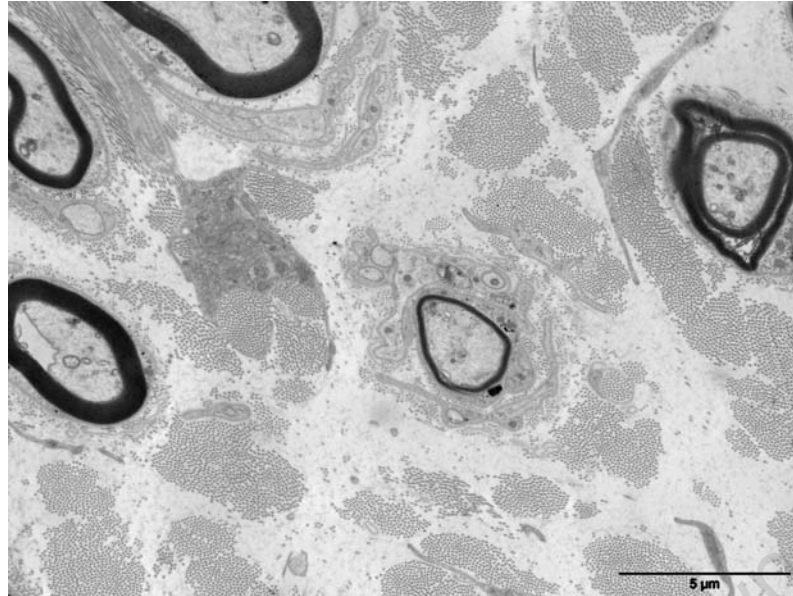


Figure 3.5b: Electron microscopy section of a patient with MFN2 mutation demonstrating reduced myelinated fibre density and an onion bulb formation (courtesy of Professor Vallat)

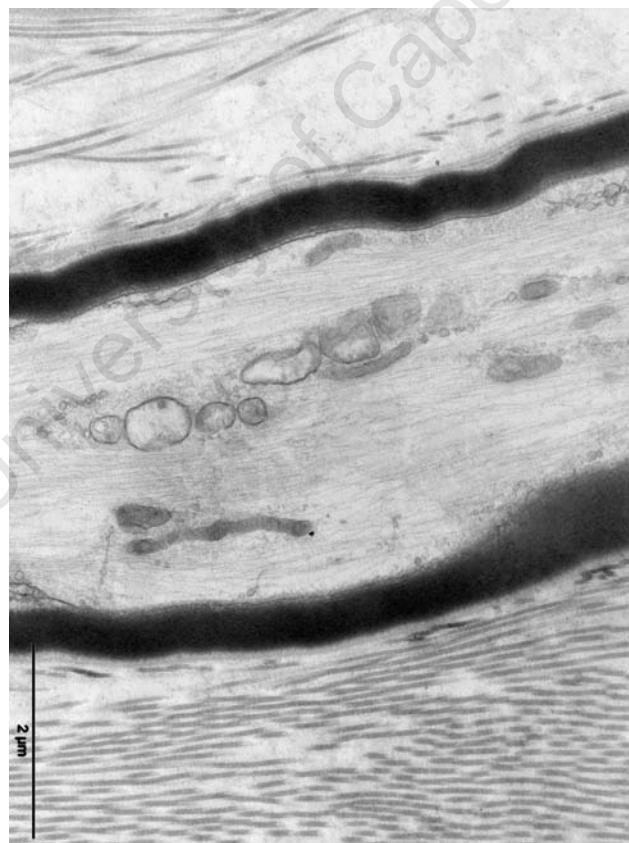


Figure 3.5c.i

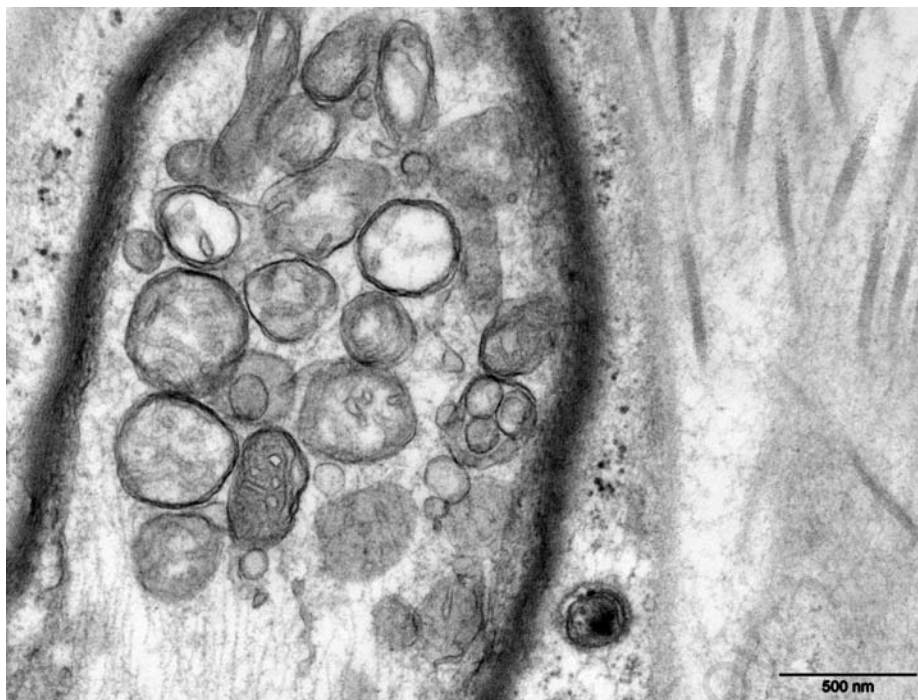

Figure 3.5c.ii:

Figures 3.5c i and ii. Electron micrograph from one of the patients with confirmed MFN2 mutation demonstrating abnormal aggregates of mitochondria. Note the abnormal inner and outer mitochondrial membranes, disrupted cristae in some and the accumulation of the abnormal mitochondria at the peripheries of the axon (courtesy of Professor Vallat)

Seven infants (5 male: 2 female) had **severe infantile axonal neuropathy with respiratory failure (SIANR) or spinal muscular atrophy with respiratory distress (SMARD1)**.^(2,106,108) They all had intrauterine growth retardation and presented at or shortly after birth with contractures, hypotonia, distal weakness and areflexia. Diaphragmatic weakness resulted in respiratory failure and eventual death in all. Two had a positive family history with previous siblings who had died. Nerve conduction velocities were either profoundly slowed or unrecordable. Nerve biopsy showed a marked reduction in MF density, apparent failure of regeneration and very little active degeneration, suggesting that the infants did not have the ability to recover from the resulting fibre loss. Five of the infants were screened and were confirmed to have mutations of the *IGHMBP₂* gene which as demonstrated can be associated with a generalised polyneuropathy (SIANR).⁽¹⁰⁶⁾

Two sisters had **severe relapsing axonal neuropathy**. One patient presented at 8 months with acute onset ataxia and weakness.⁽²⁾ After an almost complete recovery she relapsed at 21 months and died. Her sister was similarly affected and died aged 30 months.

Nerve conduction velocities were in the so-called “demyelinating range” (median nerve motor conduction velocity 15 meters/second; common peroneal nerve motor conduction velocity 8 meters/second) and there was denervation on EMG. Nerve biopsy confirmed axonal degeneration, occasional thin myelin sheaths, reduction in myelinated fibre density and an increased number of macrophages.

One patient presented in infancy with hypotonia, macrocephaly, poor head control and reduced spontaneous movements especially distally. He improved with time and had normal cognition. There was a strong family history on the maternal side. His mother had pes cavus and his maternal grandfather was clinically affected with a peripheral neuropathy as were two of his maternal uncles. Molecular genetic screens were negative for *connexin 32*, *MPZ* mutations and for mutations in the *CMTX2* region. Nerve conduction studies were in the demyelinating range but compatible with axonal loss and his EMG confirmed active reinnervation. His CSF protein was mildly raised. His sural nerve biopsy confirmed an adequate myelinated fibre density and myelin thickness with no cluster or onion bulb formations – there was one fibre undergoing active axonal degeneration. Combining his features he was suspected to have **CMTX2 or X4** but, in view of the lack of molecular genetic confirmation, he was categorised “CMTX type unknown”.

Three patients (2 female: 1 male) had **HMSN with optic atrophy and deafness** (Rosenberg-Chutorian syndrome or ARTS syndrome newly classified as **CMTX5**). The boy presented by 2 years of age and the girls by five years of age. The boy had a positive family history with two affected brothers. Molecular genetic screening confirmed *PRPS1* mutation in one of the latter.⁽³²⁵⁾ Screening for Friedreich’s ataxia disease was negative in another. Clinical features included in addition to the deafness and optic atrophy, nystagmus (n=1), kyphoscoliosis (n=1), generalised weakness (n=1), pes cavus (n=1), sensory alterations (n=1), hyporeflexia or areflexia (n=3) and developmental delay (n=1). Neurophysiological studies revealed abnormal sensory conduction in 2 out of 3 patients, whilst motor conduction was normal (n=1) or moderately delayed (range 25-40 m/s). EMG (n=1) was neuropathic. Sural nerve biopsy was performed between 2 and 6 years of age (median 3 years). Features included thinning of the myelin (n=1), markedly or moderately reduced MF density (n=3), cluster formation (n=1). On teased fibre analysis (n=2), thinning of the myelin was identified in

one. The features were felt to be consistent with an axonal neuropathy. *This condition is now categorised as **CMTX5***^(148,149).

Thirty-one children (18 female: 13 male) who did not conform with the recognised axonal neuropathy groups were labelled “**atypical**” **chronic axonal and sporadic sensory neuropathy**⁽³²⁶⁾. A number of them may well comply with the categories for autosomal recessive CMT2, but could not be defined further. Three children presented by 2 years of age and eight children presented before 5 years of age. Three had a family history of peripheral neuropathy. One patient presented with an aggressive progressive axonopathy from 2½ years of age with associated respiratory failure and eventual death despite medical and supportive interventions. Genetic and metabolic screens were negative; her phenotype was similar to a juvenile form of SMARD1.⁽³²⁷⁾ The older sister of this patient also developed a neurological disorder. However her onset of symptoms was later, from 7 years of age, and she had a milder course, with no respiratory compromise and she was deaf (she has not undergone a nerve biopsy to date). Two patients presented before one year of age with static sensory neuropathies with large myelinated fibre loss and associated scoliosis.⁽³²⁶⁾ Molecular genetics studies in the first patient were negative for SCA types 1, 2, 3, 6 and 7. Two patients were negative for FA and two for SCA 1,2,3,6 and 7. Molecular genetics studies were negative in eight other patients for chromosome 17p duplication (n=4), *GDAP1*(n=1), *MPZ* (n=2), *connexin32* (n=3), *lamin A/C* (n=1) and *mitofusin2* (n=1) mutations. All patients, except those with the sensory neuropathy, had neurophysiological and histopathological changes compatible with axonal disease but lacked specific features. *Without extensive molecular genetic testing these patients could not be categorised beyond having an axonal neuropathy, of possible autosomal recessive origin.*

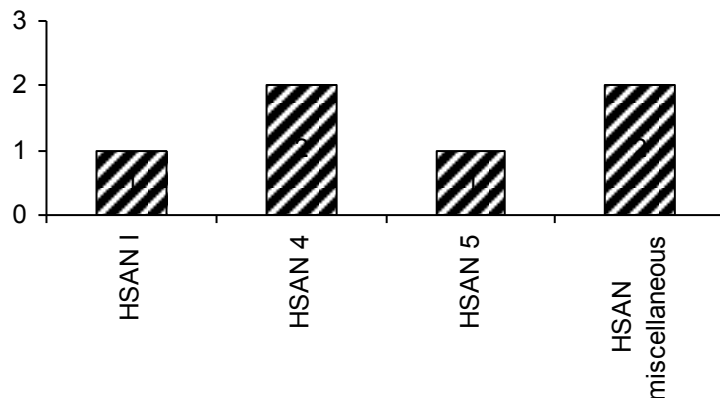
Of nine patients (3 female: 6 male) with a clinical and neurophysiological diagnosis of **distal hereditary motor neuropathy** only one male patient from the group had an abnormal sural nerve biopsy. This patient presented after five years of age and did not have a family history of neuropathy. He had distal weakness but retained deep tendon reflexes and no contractures. Neurophysiological studies confirmed normal sensory conduction and normal motor conduction but detected a prolonged distal latency from the right common peroneal study. His EMG was neuropathic. Sural nerve biopsy confirmed axonal degeneration and a moderate reduction in the myelinated fibre density. *In summary eight out of nine patients with*

spinal CMT had normal sural nerve biopsies but an axonal peripheral neuropathy was confirmed in one. A condition described as a pure motor neuropathy, would not be expected to have sensory involvement however as illustrated in Table 1.2 there are several sub-forms of dHMN with sensory involvement described. This is presumed secondary and follows a similar pathogenesis to that reported in anterior horn cell conditions such as SMA and ALS.^(183,328) This condition remains in the section for motor and sensory neuropathies as the clinician tends to work backward to the diagnosis i.e. starting with a clinical phenotype and a series of results – from these a diagnostic label is desired. Awareness that sensory involvement can occur in this primarily motor condition is important.

University of Cape Town

HEREDITARY SENSORY AUTONOMIC NEUROPATHY (n=6) (Figure 3.6)

Figure 3.6: Hereditary sensory and autonomic neuropathies n=6



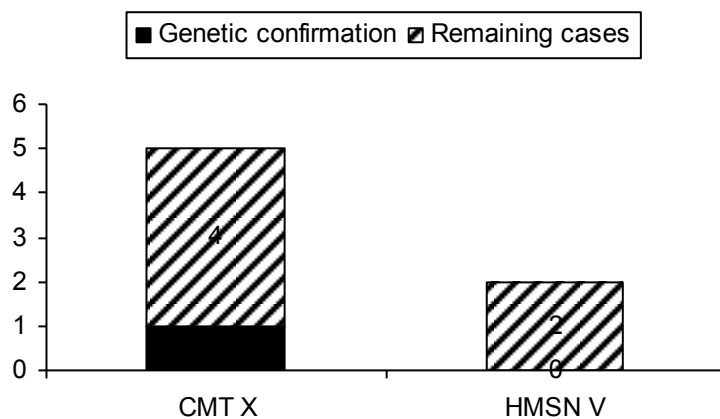
One male patient had **HSAN type 1**; he had a positive family history following an autosomal dominant pattern. He became symptomatic after five years of age with areflexia, altered sensibility, especially to pain, and pes cavus. Neurophysiological studies detected abnormal sensory conduction and normal motor studies. On sural nerve biopsy, he had markedly reduced myelinated fibre density and axonal degenerative changes.

The remaining patients were described and published in detail in the infantile series in chapter 4.⁽²⁾ Two female patients had **HSAN type 4**, they had a marked decrease of unmyelinated fibres and small myelinated fibres on nerve biopsy. One patient had **HSAN type 5**, she had a selective loss of small myelinated fibres.⁽³²⁹⁾ Two patients could not be categorised (**miscellaneous HSAN**) (1 female: 1 male). The boy presented in infancy.

MIXED PICTURE

(Axonal and demyelinating features) n= 7 (Figure 3.7)

Figure 3.7: Mixed axonal / demyelinating neuropathies



Five patients (5 male) had **CMT X**. Molecular genetics testing confirmed connexin 32 in one patient (CMTX1), was negative in another and *GDAP1* testing was negative in another. There was a positive family history in four. All patients presented after five years of age. Clinical features consisted of distal contractures (n=4), kyphoscoliosis (n=1), nystagmus (n=1), weakness (distal n=4, generalised n=1), nerve hypertrophy (n=1), abnormal reflexes (n=3), sensory changes (n=3), and pes cavus (n=5). Neurophysiological studies confirmed abnormal sensory conduction in four out of the five patients. Motor conduction velocities were slowed with median values of *median* 32 m/s (range 17-45m/s), *ulnar* 32 m/s (range 32-45 m/s) and *common peroneal* 45 m/s. EMG was not performed. Sural nerve biopsy performed between 13 and 17 years of age (median 13 years) detected markedly or moderately reduced myelinated fibre density in all patients. On light microscopic study of transverse sections, demyelination (n=3), axonal degeneration (n=1), onion bulb formations (n=4) and cluster formations (n=3) were seen. Teased fibre analysis (n=3) revealed demyelination in three patients. Electron microscopy (n=4) detected onion bulb formations (n=2) and cluster formation (n=1). The biopsy findings were consistent with a mixed picture of axonal and demyelinating degeneration. *In summary this group of boys presented in later childhood with a mixed axonal and demyelinating peripheral neuropathy.*

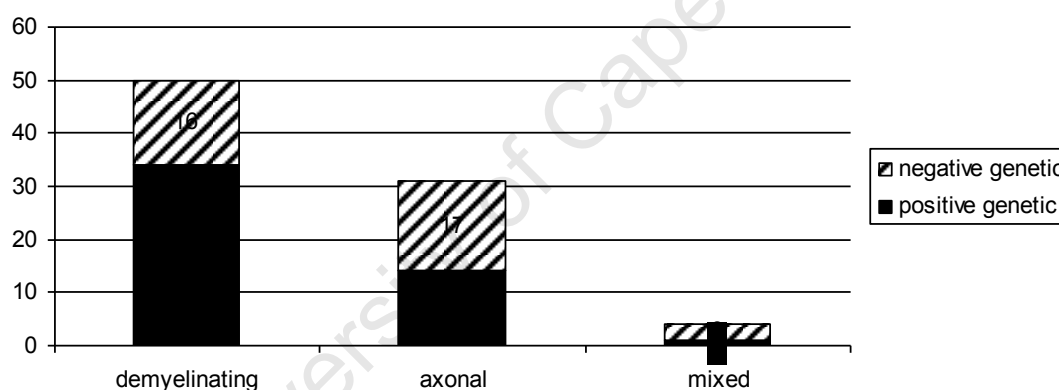
Two patients (1 female: 1 male) had **HMSN type V (HMSN with pyramidal signs or CMT5)**. One presented before five years of age and the other after five years of age. There

was no family history of neuropathies. Clinical findings including distal contractures (n=2), ataxia (n=1), distal weakness (n=2), sensory changes (n=1), increased deep tendon reflexes (n=1), and pes cavus (n=2). Both had long tract signs with exclusion of central pathology in addition to their clinical features of peripheral neuropathy. Neurophysiology revealed abnormal sensory conduction in one out of the two patients. Motor conduction was consistent with an axonal pattern in both. EMG was not performed. Sural nerve biopsies were performed at 6½ and 8½ years. Light microscopic examination of the transverse sections revealed moderately reduced myelinated fibre density in one and normal myelinated fibre density in the other patient with demyelination (n=1). Teased fibre analysis (n=2) detected axonal degeneration (n=1) and demyelination (n=1). EM was not performed. Based on the combined neurophysiological and histopathological results the features were felt to be consistent with a mild mixed axonal and demyelinating peripheral neuropathy. *In summary these two patients presented at around five years of age with a progressive peripheral neuropathy of mixed type and long tract signs.*

Summary of the Genetic data

Of the above patients (n=161) with hereditary peripheral neuropathies where the neuropathy was the primary disease, more than half had undergone genetic analyses (n=87). Autosomal dominant patterns of inheritance were evident in 53 patients of the total group and recessive or sporadic inheritance in the remaining 108. In most cases molecular genetic screens were directed by the clinical phenotype, neurophysiological results and histopathological findings. Forty-nine patients attained molecular genetic confirmation, 28 of whom had autosomal dominant patterns of inheritance and 21 followed autosomal recessive inheritance. The positive results were disproportionately skewed to the patients with demyelinating disease.

Figure 3.8: Summary of patients who underwent genetic screens



Demyelinating group: 34/50 patients who underwent genetic screens attained a definitive genetic diagnosis. These included duplication chromosome 17p11.2 (n=20 CMT1A patients), deletion in the chromosome 17p11.2 region (n=3 HNPP patients), *PMP22* point mutations (n=3 CMT3 patients), *frabin* mutation (n=1 CMT4H patient) and *MPZ* mutation (n=7, CMT3 n=6 and CMT4B n=1). Apart from *MPZ* mutations, which were expressed in patients with both CMT3 and CMT4, the individual mutations were associated with specific diseases. There was an extremely high confirmation rate for particular diseases, especially CMT1 (genetic confirmation in 20/21 screened) and CMT3 (genetic confirmation in 9/12 screened). Negative findings were most marked in the atypical demyelinating (n=3/6) and demyelinating / remyelinating sporadic groups (n=6/16) suggesting either incomplete genetic analysis or that they have mutations yet to be identified. The patients with CMT4B were also less likely to

attain a genetic confirmation with the rarer mutations associated such as *frabin* mutation.

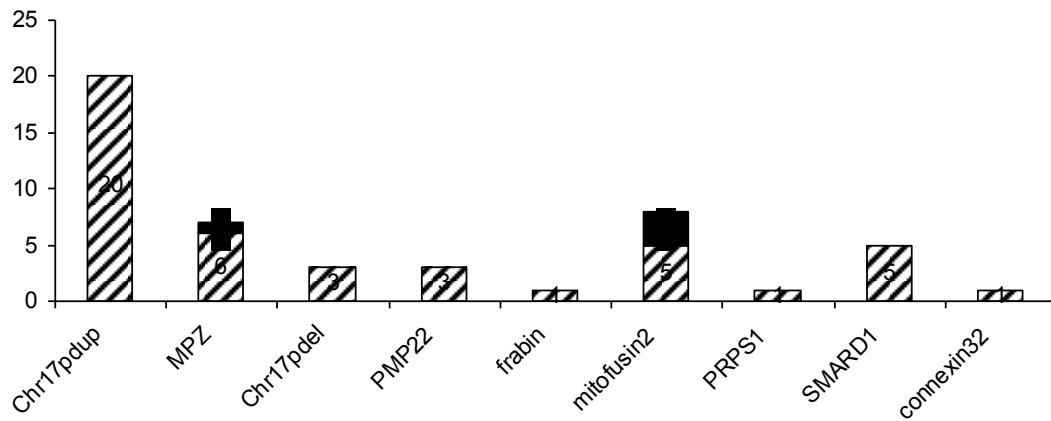
Three out of the five screened did not gain molecular genetic diagnoses.

Axonal group: 14/33 patients who underwent screening attained a genetic confirmation. This consisted of *mitofusin2* mutations (n=8; CMT2A n=3 and EOHMSN n=5), *PRPS1* mutation (n=1, CMTX5) and *SMARD1* mutations (n=5 all SIANR). Of this axonal degenerative group a further 4 patients were screened and found to be negative for *mitofusin2* mutations. Although the patients with axonal disease are most behind in gaining genetic confirmations the identification of *mitofusin2* mutations has started to reduce this disparity. Further the phenotypic variation in the range of diseases is evident here with the *MFN2* mutation being associated with both CMT2A and EOHMSN (SEOAN). Limited screening was evident in many of these patients suggesting suboptimal genetic analyses had occurred. Of the patients with atypical axonal disease who could not be categorised, only 7/31 had undergone various genetic analyses (with negative results). Similarly 6/12 of the patients with CMT2 were screened without gaining a genetic diagnosis. By far the highest efficacy in detection of a genetic screen was evident from the *mitofusin2* screens with seven negative results (EOHMSN n=4, atypical axonal n=1, CMT4B n=1, CMT3 n=1, demyelinating / remyelinating sporadic n=1) compared with the 8 diagnostic confirmatory results. Of note three of these negative screens were in patients with demyelinating disease. As *MFN2* mutations are not reported in this group the negative results were not surprising. The patients in whom it would be of most use to screen for *MFN2* mutations would be those with CMT2 and EOHMSN. Of the total group of EOHMSN patients (n=18), five attained genetic confirmation (*mitofusin2* mutations), a further three underwent various genetic screens which failed to lead to a genetic diagnosis. Of this last three one was negative for *mitofusin2* mutations i.e. of the six patients with EOHMSN who were screened for *mitofusin2* mutations five were confirmed to have *MFN2* mutations.

Mixed group: 1/4 patient attained genetic confirmation; the patient with *connexin 32* mutation who had CMTX1.

Overall genetic confirmation was possible in 49 out of the 87 patients who underwent targeted screening. But even from this group additional analyses would have been ideal.

Figure 3.9 Summary of genetic mutations



Key: Different shading identifies mutations occurring in more than one form of CMT e.g.

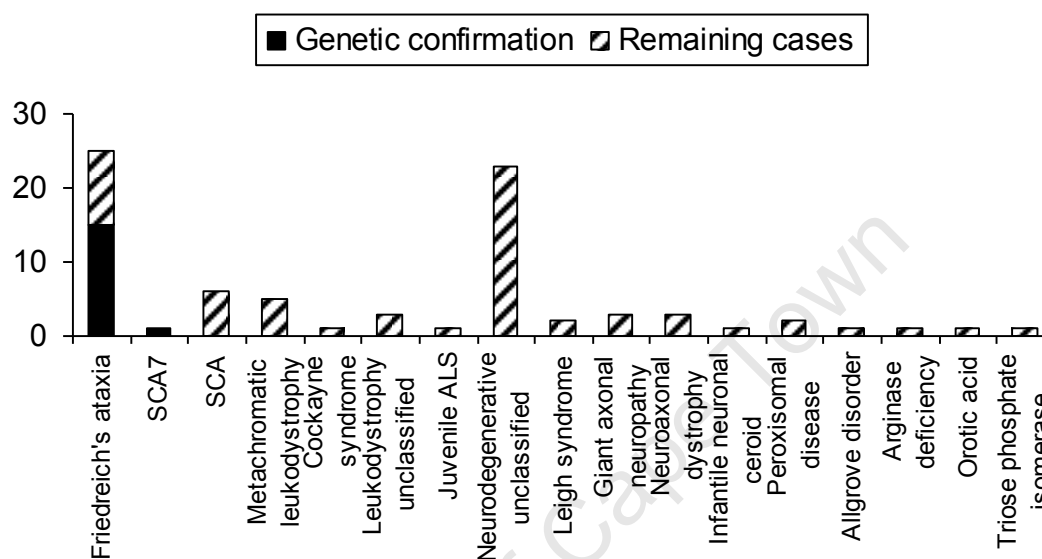
MFN2 mutations occurring in patients with CMT2A (n=3) and EOHMSN (n=5); *MPZ* occurring in patients with CMT3 (n=6) and CMT4 (n=1).

PERIPHERAL NEUROPATHIES ASSOCIATED WITH INHERITED DISORDERS

(n=87)

NEURODEGENERATIVE AND METABOLIC DISORDERS (n=78) (figure 3.10)

Figure 3.10: Neurodegenerative and metabolic disorders with peripheral neuropathy



Twenty-five patients (12 female: 13 male) had **Friedreich's ataxia (FA)** (Figure 2.9, page 59). Molecular genetics performed many years after the biopsies were performed in seventeen of this group confirmed expansions in 13 and identified point mutations in 2. The remainder were diagnosed based on clinical, neurophysiological and nerve biopsy findings. One pair of siblings was in the group and seven patients had a positive family history of FA. Six patients presented by two years of age and a further 9 by 5 years of age. Clinical features included sensory alteration (n=20), ataxia (n=21), abnormal deep tendon reflexes (n=25), kyphoscoliosis (n=11), weakness (distal n=12; generalised n=1), optic atrophy (n=14), pes cavus (n=17), nystagmus (n=6) and learning difficulties (n=3). Neurophysiology was abnormal in all 23 patients tested. Motor studies detected mildly delayed conduction velocities or normal (n=5) studies. Sural nerve biopsies were performed between 4 and 16 years of age (median 10.5 years of age). Light microscopic examination of transverse sections revealed selective reduction in the large myelinated fibres, thinning of the myelin (n=3), axonal degeneration (n=7), onion bulb formation (n=2) and cluster formations (n=6). Teased fibre analysis (n=24) identified thinning of the myelin (n=8) and axonal ovoids (n=8). Electron microscopy (n=8) identified cluster formations on one and mainly the reduced large myelinated fibres. *In*

summary 25 patients presented with FA. Nerve biopsy prior to molecular genetic advances was the main diagnostic aid used. Since identification of the molecular genetic mutation, biopsy remains useful when the molecular genetics fail to identify triplicate repeat mutations or a point mutation.

One patient had molecular genetic confirmation of **SCA 7**.⁽²³³⁾ She presented by 2 years of age with ataxia, hypotonia, generalised weakness, abnormal reflexes, abnormal eye movements with limited abduction, a pigmentary retinopathy and pale discs, and motor developmental delay. She had a progressive disorder. Her father subsequently became symptomatic with a milder form of the disease reflecting the anticipation which had occurred. Neurophysiological studies recorded abnormal sensory conduction studies, with normal to mild slowing in motor conduction in the upper limbs and more marked slowing in the lower limbs (in the region of 25-39 metres / second). Sural nerve biopsy was performed when she was 33 months old. This detected thinning of the myelin, axonal degeneration, marked reduction in myelinated fibre density and cluster formations. Teased fibre analysis identified thinning of the myelin and electron microscopy identified cluster formations.

Five children (4 female: 1 male) had forms of **spinocerebellar degeneration** with associated peripheral neuropathy which could not be classified. Molecular genetics failed to detect expansions in the FA or SCA regions in one and SCA regions in the others. Three patients presented by 2 years of age and a further 2 by five years of age. No patients had a positive family history. Clinical features, neurophysiological studies and sural nerve biopsy findings were consistent with undefined spinocerebellar degenerative syndromes. Neurophysiological studies recorded abnormal sensory conduction in two of the five children. Motor studies recorded conduction velocities in the axonal range in all five. Their peripheral nerve biopsies detected on light microscopy, axonal degeneration (n=2), moderate or borderline myelinated fibre densities (n=5), cluster formations (n=2). Teased fibre analysis (n=4) detected segmental demyelination (n=1) and ovoid formations (n=1). Electron microscopy examination (n=4) revealed cluster formations (n=2) and onion bulb formations (n=2). *Overall three of the children were considered to have axonal pathology and two mixed pathology. The nerve biopsy was useful to assist exclusion of FA and mitochondrial disease.*

Five children (4 female: 1 male) had **metachromatic leukodystrophy (MLD)** (**Figure 2.11, page 61**). All presented by 5 years of age and 3 before 2 years of age. Family history

was positive in one. Clinical features were consistent with the typical phenotypes of the disorder including long tract signs (n=3), nystagmus (n=1), ataxia (n=1), hypotonia (n=1), weakness (distal n=2; generalised n=3), abnormal reflexes (n=5), pes cavus (n=2), sensory changes (n=1), cranial nerve disorders (n=1), and cognitive decline (n=3). Neurophysiology revealed abnormal sensory conduction studies in all four patients tested. *Median* and *ulnar* motor conduction studies were delayed in the region between 17-32 m/s and common peroneal further slowed between 10-24m/s. Sural nerve biopsies were performed between 2 and 11 years of age (median 3 years). Transverse sections studied by light microscopy demonstrated thinning of the myelin (n=4), axonal degeneration (n=3), abnormal staining on cresyl violet immunohistochemistry (n=5), markedly reduced myelinated fibre density (n=5), onion bulb formations (n=2) and cluster formations (n=1). Teased fibre analysis (n=5) detected demyelination (n=4). Electron microscopy (n=5) detected accumulations of myelin-like material as well as onion bulb formations, zebra and “tuff-stone” bodies and prismatic inclusions. *In summary, five children had biopsy-proven metachromatic leukodystrophy. These biopsies were performed prior to aryl-sulphatase A levels and gene testing being available. There are still situations where biopsy can assist in the diagnosis of MLD – when gene testing is not available and where there are very low parental levels of aryl sulphatase, in cases with a pure neuropathic syndrome and in the AB variant where the sulphatase levels are normal.*

One boy had **Cockayne syndrome (Figure 2.12, page 61)**. He presented with short stature, developmental delay, ataxia, deafness, sensory alteration, and abnormal deep tendon reflexes. Nerve conduction studies recorded slow motor and sensory conduction velocities in the demyelinating range. Biopsy performed when 14 years of age confirmed features of demyelination, marked reduction in myelinated fibre density with onion bulb formations and occasional cluster formations. Teased fibre analysis detected segmental demyelination.

Three female children presented with **unclassifiable leukodystrophies**. Two presented in infancy with developmental delay and are described in detail in the infantile series publication (chapter 4).⁽²⁾ The third girl presented after 2 years of age with developmental delay, generalised weakness, abnormal reflexes and cranial nerve involvement. She had a positive family history. Sural nerve biopsy at 4³/₄ years revealed markedly reduced myelinated fibre density and cluster formation consistent with an axonal disorder.

Twenty-three patients (8 female: 15 male) had **undiagnosed neurodegenerative conditions** associated with demyelinating (n=5), axonal (n=16) and mixed (n=2) peripheral neuropathies. Nine presented in infancy (chapter 4).⁽²⁾ Two had demyelination and seven had axonal degeneration on sural nerve biopsy. Thirteen patients presented between 1 and 2 years of age. *In summary this study reflected large numbers of children with neurodegenerative disorders who, despite positive findings, did not have a definitive diagnosis. A proportion of these may have been diagnosed if put through all the biochemical screens now available.*

One patient had a clinical phenotype for **juvenile motor neurone disease**. She presented with short stature, microcephaly, expressive language delay, bulbar dysfunction and symmetrical distal weakness. Her feet had evidence of old injuries and she had globally reduced muscle bulk. She fell often, had difficulty walking with rapid deterioration and eventual loss of ambulation. Her intellect was retained. Screens for spinal muscular atrophy, white cell lysosomal enzymes and blood lactate were all within normal limits. Her neurophysiological studies confirmed a median nerve compound motor action potential (CMAP) amplitude of 2.8 microVolts (reduced), conduction velocity 57 metres /seconds (normal), ulnar nerve CMAP of 2.7 microVolts (reduced), conduction velocity 59 metres / second, common peroneal nerve CMAP of 6.8microVolts (normal), conduction velocity 28 metres / second (slowed) and posterior tibial nerve CMAP of 3.4 microVolts (reduced), conduction velocity 38 metres / second (delayed). Her sensory studies were within normal limits. Her EMG detected large polyphasic units. Her sural nerve biopsy performed aged 7 years detected very thinly myelinated fibres, moderate reduction in the myelinated fibre density and occasional very thinly myelinated fibres surrounded by onion bulb formations. The teased fibre sections revealed no ovoid formations but there was one area of segmental demyelination. The appearance was consistent with a demyelinating disorder.

Two children from the series with **Leigh syndrome** underwent peripheral nerve biopsy. One biopsy was normal. One female who presented in infancy had an abnormal nerve biopsy which was more suggestive of an axonopathy with reduced MF density than the recognised demyelination which occurs with Leigh disease.⁽²⁾

Three patients had **giant axonal neuropathy** (1 female: 2 male) (**Figure 2.10, page 60**). The first boy presented in infancy and is described in more detail in chapter 4.⁽²⁾ The girl

had a similar picture to this boy but presented slightly older. She had motor delay, “woolly” hair, nystagmus, generalised weakness, areflexia, ataxia and absent vibration and proprioceptive sensibility. The characteristic giant axons with thin myelin sheaths which confirmed the diagnosis were evident on her nerve biopsy. The other boy had a positive family history and presented by 2 years of age with developmental delay, generalised weakness and abnormal reflexes as well as the typical “woolly” hair. Nerve conduction studies failed to stimulate any sensory responses but the motor responses were only marginally slowed. Peripheral nerve biopsy confirmed thin myelinated fibres of abnormally large size with cluster and onion bulb formations. The large myelinated fibres were packed with abnormal neurofilaments most evident on electron microscopy.

Three children had **neuroaxonal dystrophy** (NAD) (2 female: 1 male). All presented by 2 years of age and the female patient was related to one of the male patients. The children presented with gait difficulty and weakness. They initially developed hypotonia but later spasticity was evident. In this group the deep tendon reflexes were depressed. The children evolved progressive cognitive neuroregression and blindness related to optic atrophy. Neurophysiology confirmed normal sensory conduction (n=2) and normal motor conduction in two patients but mild slowing in the other. EMG detected denervation in all. Sural nerve biopsies performed at the age of 2½ (n=2) and 3 years of age, detected axonal degeneration and abnormal neurofilaments with cluster formations (n=1) and markedly reduced MF density in one, borderline reduction in one and normal density in the other. EM detected cluster formations (n=1) and abnormal axonal spheroids consisting of storage neurofilamentous material in all (**Figure 2.5, page 48**). The biopsies were diagnostic of NAD with an axonal picture.

One boy presented by two years of age with **infantile neuronal ceroid lipofuscinosis** (INCL), confirmed on rectal biopsy. Clinical features included neuroregression, ataxia, abnormal deep tendon reflexes, cranial nerve involvement, central disease and developmental delay. His neurophysiology studies were normal. His sural nerve biopsy performed aged 6 years revealed normal myelinated fibre density and ovoid formations on teased fibre analysis. The changes were consistent with a mild axonal peripheral neuropathy. This was an unusual finding as neuronal ceroid lipofuscinosis is not typically associated with peripheral neuropathies.

Four children with **peroxisomal disorders** underwent peripheral nerve biopsies. No neuropathy was found in two. The other two male infants, who presented at birth, were first cousins (their mothers were sisters).⁽²⁾ Their nerve biopsies confirmed a demyelinating disorder in one and axonal degeneration in the other with glycogen accumulation in the Schwann cells.

Four boys had different metabolic disorders associated with peripheral neuropathy; namely **Allgrove syndrome (Tripe A, alacramia, achalasia, adrenal insufficiency)** (biopsy: axonal degenerative), **arginase deficiency** (biopsy: mixed picture), **orotic aciduria** (biopsy: mixed picture) and **triosephosphate isomerase deficiency (TPI)** (biopsy: axonal degeneration).⁽³³⁰⁾

OTHER HEREDITARY DISORDERS WITH ASSOCIATED PERIPHERAL NEUROPATHIES (n=9)

Two patients (1 female: 1 male) had **neurofibromatosis type 1 (NF1)**. One presented by 5 years and the other after 5, neither had a positive family history. Both complied with international inclusion criteria for NF1.⁽³³¹⁾ Clinical features included limb deformities (n=1), kyphoscoliosis (n=1), distal weakness (n=2), pes cavus (n=1) and developmental delay (n=1). Neurophysiology was abnormal in one and motor studies were not performed in the other. EMG (n=1) demonstrated a neuropathic process. Sural nerve biopsy performed aged 11 and 12 years, demonstrated borderline to moderately reduced MF density, with axonal degeneration (n=1) and abnormal loosely packed tissue in the subperineurial region composed of interlacing bundles of collagen, containing fibroblasts, Schwann cells and a few mast cells (**Figure 2.13, page 64**). Features were felt to be consistent with an axonal peripheral neuropathy and were typical of neurofibromatous neuropathy, a recognised entity.

Sixteen patients, who had nerve biopsies, were subsequently found to have **spinal muscular atrophy**. Of this group five (1 female: 4 male) had features of axonal degeneration on sural nerve biopsy. These five infants presented at birth with severe weakness.⁽²⁾ Two had contractures and these bore similarities to the cases described by Korinthenberg et al 1997.⁽³²⁸⁾

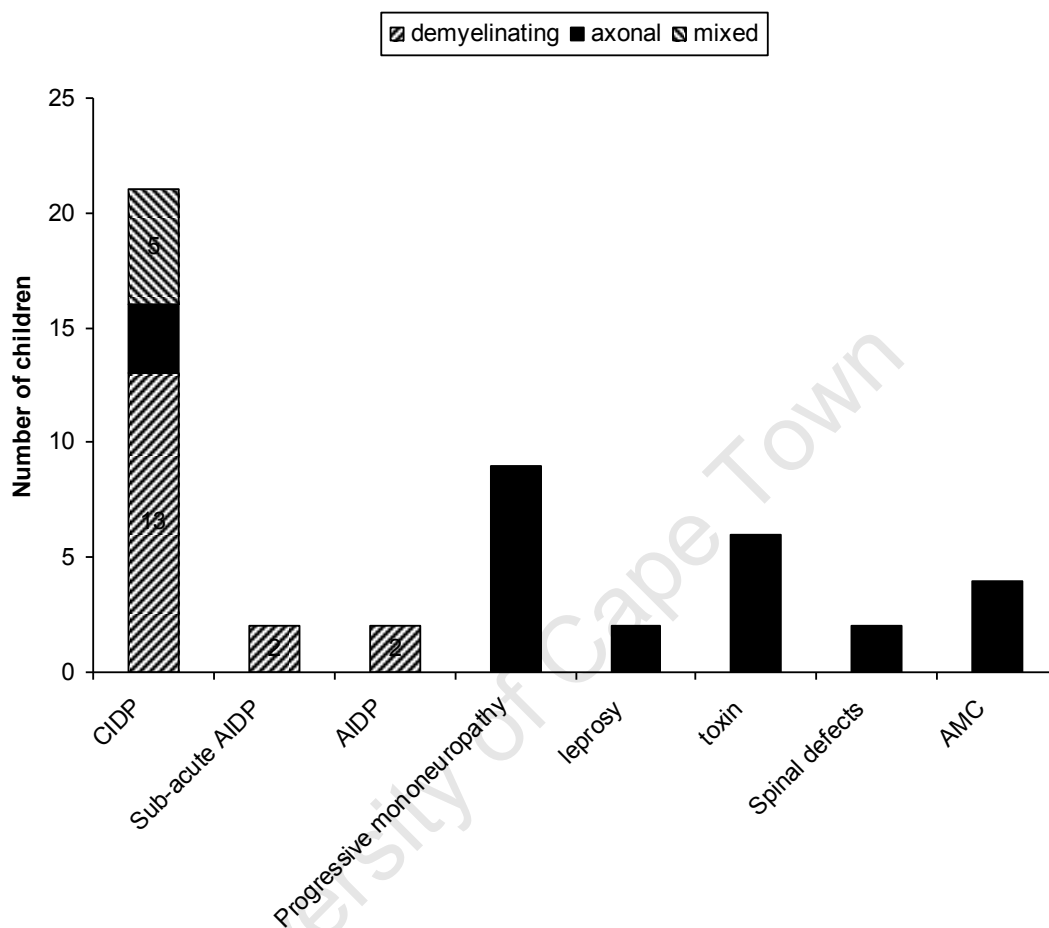
One patient had **nemaline myopathy but with an associated HMSN type 1 phenotype**.⁽²⁾

One patient (female) had a connective tissue disorder consistent with **Ehlers Danlos syndrome**. She had a positive family history with onset by 2 years of age. Clinical features included limb deformities, hypotonia, kyphoscoliosis, generalised weakness and developmental delay. Her neurophysiological tests were normal. Nerve biopsy performed at the age of five years detected features consistent with demyelination on teased fibre analysis. She was felt to have a demyelinating peripheral neuropathy as part of her Ehlers Danlos syndrome.

University of Cape Town

ACQUIRED DISORDERS n=48 (figure 3.11)

Figure 3.11: Acquired disorders and pathology types



Twenty-one (15 female: 6 male) had **chronic inflammatory demyelinating polyradiculoneuropathy**. Fifteen of the group were described in a previous publication.⁽³³²⁾ The inclusion criteria consisted of patients with a clinical history of progressive weakness and hyporeflexia, or multiple relapses, over a period of at least 2 months. Patients had generalised slowing of motor nerve conduction velocity to less than 60% of normal values, the presence of dispersion of the compound muscle action potential and / or conduction block, prolonged distal latencies and absent or prolonged F-wave latencies. Pathologic criteria included an abnormal percentage of teased fibres affected by segmental demyelination or electron microscopic evidence of demyelination and electron-microscopic or immunohistochemical evidence of inflammatory cell infiltrates.^(333,334) No patients had a positive family history. One patient presented by 2 years and four by five years. Clinical features included ataxia (n=1), hypotonia

(n=4), weakness (distal n=15; generalised n=6), nerve hypertrophy (n=2), reduced or absent deep tendon reflexes (n=18), sensory impairment (n=9) and cranial nerve involvement (n=6). CSF protein levels were between 0.045-9mmol/l (median 1.135mmol/l). Neurophysiological sensory studies (n=19) were abnormal in 18. Median motor nerve conduction velocities ranged between 5 –45 metres / second (median 17 metres / second); ulnar: 17-49 metres / second (median 32 metres /second) and common peroneal 17-49metres /second (median 32 metres / second). The median and common peroneal nerves of one patient and the common peroneal nerves of two other patients could not be stimulated. EMG was neuropathic in 4 and normal in one. Nerve biopsies detected on transverse section thinning of myelin (n=12), axonal degeneration (n=10), infiltration with macrophages and inflammatory cells (n=8), reduction in the myelinated fibre density (marked (n=4), moderate (n=8) and borderline (n=4)), onion bulb formations (n=6) and cluster formation (n=3). Teased fibre analysis (n=20) revealed demyelinating changes (n=19) and axonal degeneration (n=11) (Figure 3.11a). EM (n=8) detected onion bulb formation (n=1), cluster formations (n=1) and macrophage and inflammatory cell infiltration (n=3). *Overall the biopsies were felt to be of mixed pathology in five, axonal in three and demyelinating in the remaining 13. Of the neurophysiology in comparison the mixed pathologies all had conduction velocities in the range 25-39metres / second range, whilst the demyelinating neuropathies typically had velocities in the 10-24 metres / second range, but also recorded rates above and below this.*

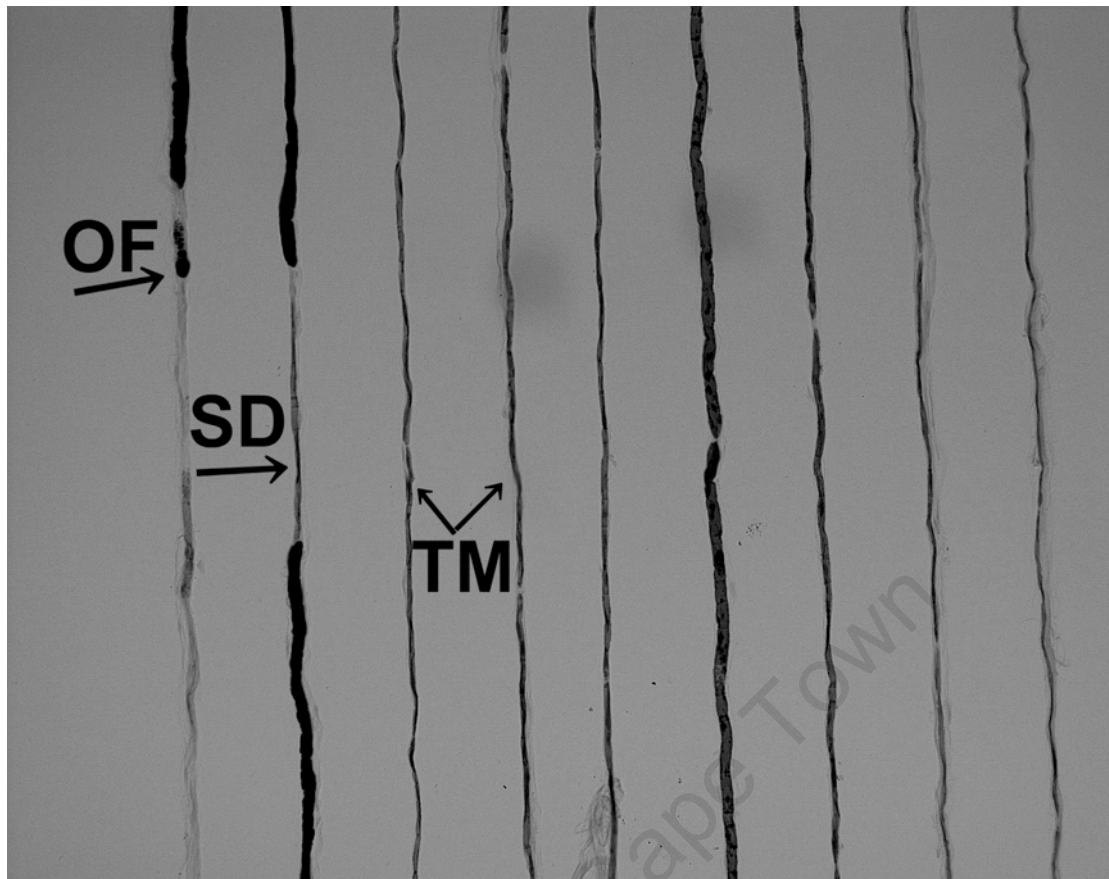


Figure 3.11a: Teased fibre analysis of a patient with CIDP demonstrating ovoid formations (OF), segmental demyelination (SD) and thinly myelinated (TM) fibres (Magnification x200).

Two patients (1 female: 1 male) had **sub-acute inflammatory demyelinating polyradiculoneuropathy**. The male patient presented aged 3 years and died 6 weeks into his illness with respiratory compromise. Clinical features included ataxia (n=1), hypotonia (n=2), distal weakness (n=2), reduced reflexes (n=2), sensory impairment (n=1), cranial nerve involvement (n=2). CSF protein was 0.2 and 3.6g/l (range 0.2-1.8g/l). Neurophysiology revealed abnormal sensory studies in the one patient tested and median nerve conduction velocities of 10 metres / second. Sural nerve biopsies were performed at the age of three and 13 years. Light microscopic examination of transverse sections revealed macrophage infiltration and moderate reduction in the myelinated fibre density. Teased fibre analysis (n=1) revealed demyelination. EM (n=1) demonstrated macrophage infiltration. The changes were felt to be demyelinating in nature.

Two patients (2 female) had **acute inflammatory demyelinating polyradiculoneuropathy**. There was no family history. Clinical features included hypotonia (n=2), distal weakness (n=2), reduced reflexes (n=1) and sensory impairment (n=2). CSF

protein was 0.41 and 1.04g/l. Neurophysiology revealed abnormal sensory conduction studies (n=2), median nerve potentials could not be evoked in one, and were < 10 metres / second in the other, and common peroneal conduction velocities were >40 metres / second. Nerve biopsy performed at the age of eight years for both girls revealed moderate reduction in the myelinated fibre density, with myelin thinning (n=1) and macrophage infiltration (n=2). Teased fibre analysis (n=1) detected demyelination. EM detected macrophage infiltration. The findings were in keeping with a demyelinating disorder.

Nine patients (5 female: 4 male) had **progressive mononeuropathy**. The left sciatic nerve was clinically involved in five, the right sciatic nerve in one and two patients had mononeuritis multiplex secondary to vasculitis. The ninth patient was a three month old infant with distal weakness thought to be related to a vasculitic process. There was no family history for any of the patients. Of the five with left sciatic nerve involvement one patient was confirmed to have a perineurioma and another had localised hypertrophy of the sciatic nerve. One patient with the right foot drop presented with a livedo reticularis rash at the age of 14 years and a history of right retinal artery occlusion one year previously. He was thought to have a vasculitic neuropathy. One female patient presented with distal wasting and weakness with reduced reflexes. Her neurophysiology studies and nerve biopsy findings of an axonal polyneuropathy with cellular infiltrates around the blood vessel (figure 3.11b), were suggestive of an immunological disorder. Clinical features of the group included localised weakness (n=8), reduced reflexes (n=5), sensory impairment (n=3) and pes cavus (n=1). The patient with mononeuritis multiplex had learning difficulties. Neurophysiological sensory studies were abnormal in 5 out of seven patients tested. Motor studies revealed a range of changes over the affected common peroneal nerve with a *median* conduction velocity of 40m/s (range 32-43 m/s) (n=4), absent stimulation response of the common peroneal in two patients, and a normal result in two patients. Nerve biopsy was performed in eight of the patients between 8 and 15 years (median 11 years) from the left sciatic nerve (n=2), common peroneal nerve (n=1) and sural nerve (n=5). Sural nerve biopsy was taken from the infant aged 3 months. Light microscopic examination of transverse sections revealed axonal degeneration (n=6), thinly myelinated fibres (n=4), reduced MF density in seven out of the nine biopsies (marked n=3, moderate n=3; mild n=1), cluster formations (n=7) and onion bulb formations (n=1). The patients with vasculitic neuropathy underwent sural nerve biopsy in the boy at 14 years and

the girl at 8 years of age. The biopsy from the boy revealed macrophage and inflammatory infiltrates around the blood vessels. The biopsy from the girl revealed inflammatory lymphocytic infiltrates around one endoneurial vessel on TS and normal density of MF (Figure 3.11b), with axonal degeneration on the teased fibre analysis demonstrated by ovoid formation on one fibre. The infant had evidence of a medium sized recanalising vessel with lymphocytic infiltrates and minute blood vessels scattered around it consistent with a past healed vasculitic process (Figure 3.11c). The patient with a perineuroma (Figure 3.11d) had severe reduction in myelinated fibre density, with remaining fibres surrounded by “pseudo-onion bulb” formations, consisting of arrays of cells with the morphology of perineurial cells occasionally surrounding two or three central MF and some unmyelinated fibres. The immunohistochemical staining with vimentin and epithelial membrane antigen supported the diagnosis of a perineurioma, a benign but rare tumour. Teased fibre analysis (n=8) revealed thinning of the myelin (n=4) and ovoid formations (n=3). *The changes were felt to be consistent with an axonal degenerative peripheral neuropathy. The peripheral nerve biopsies were an aid to diagnostic direction for most patients either confirming vasculitis (n=3), or identifying a hypertrophic process predominantly affecting the sciatic nerve (n=6).*

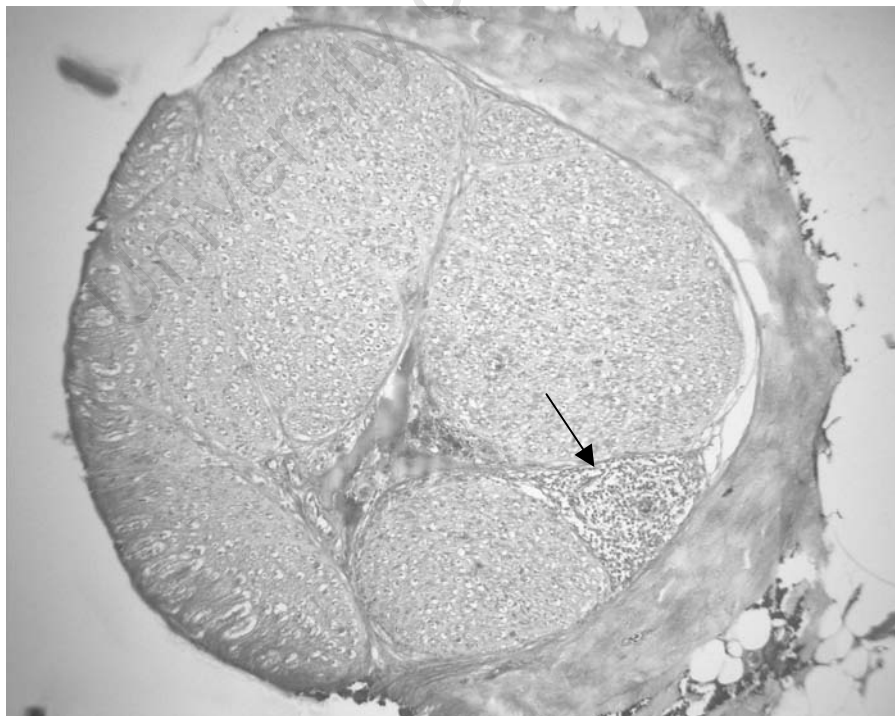


Figure 3.11b: Transverse section of the sural nerve biopsy from the eight year old girl with a vasculitic neuropathy (magnification x60, haematoxylin and eosin stain). Demonstrating lymphocytic inflammatory infiltration around an endoneurial vessel (arrow)

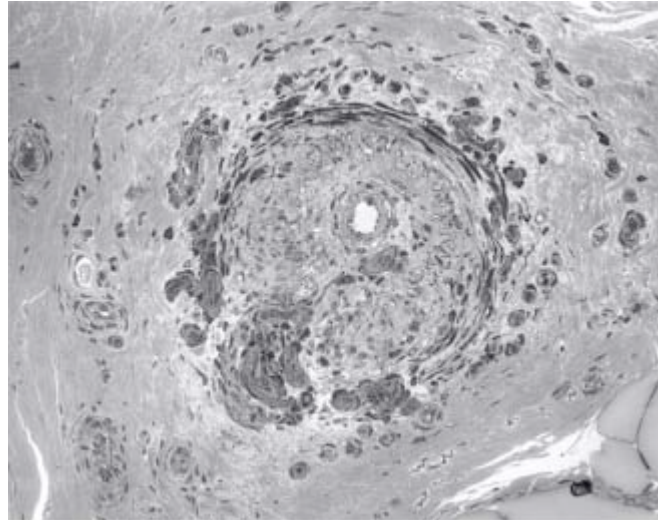


Figure 3.11c: Transverse section from the 3 month old infant with a vasculitic process, (toluidine blue stain, magnification x200). The infant had evidence of a medium sized recanalising vessel with lymphocytic infiltrates and minute blood vessels scattered around it consistent with a past healed vasculitis.

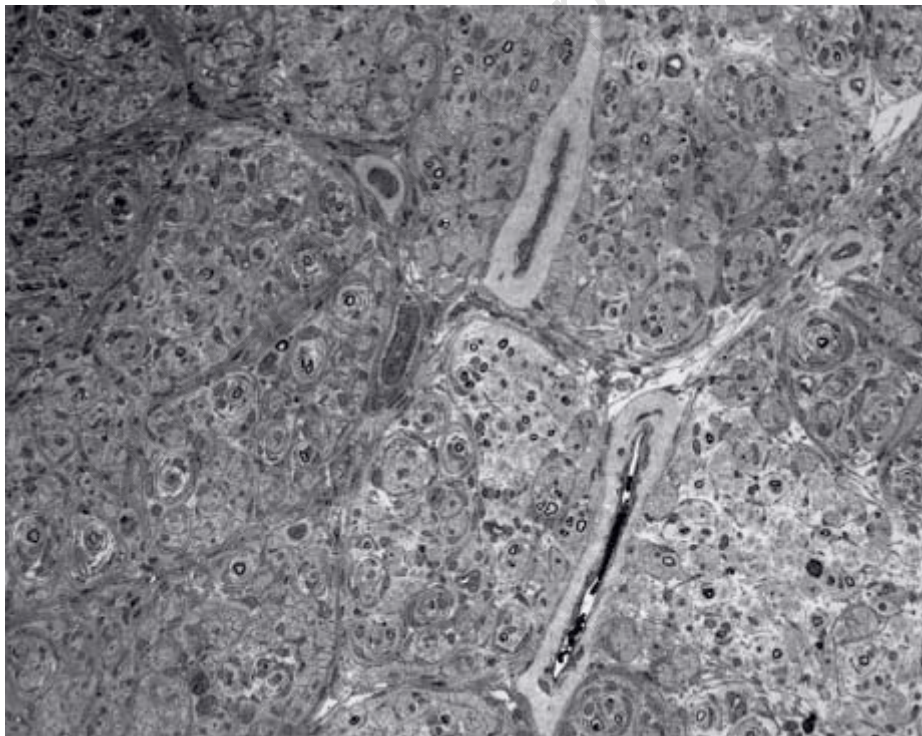


Figure 3.11d Transverse section light microscopy (toluidine blue stain, magnification x400) of patient with perineurioma demonstrating atypical onion bulb formations and reduced myelinated fibre density from the sciatic nerve sample.

Two patients (male) had peripheral neuropathies in relation to **leprosy**. Nerve biopsies revealed a granulomatous destructive process with lymphocytic infiltration.

Six patients (4 female: 2 male) presented with **toxin exposure** related to glue sniffing (n=1), farm pesticides (n=1), ciguatera poisoning (n=1), chemotherapy for a medulloblastoma (n=1) and unidentified agents (n=2). All patients were over five years at the time of presentation and none had a positive family history. Clinical features were consistent with a chronic peripheral neuropathy. Two patients had central involvement. Sensory studies (n=6) were abnormal in all six patients. Motor studies were within the axonal range. Sural nerve biopsies were performed between 9 and 16 years of age (median 12 years). Transverse section light microscopy detected axonal degeneration (n=5), myelin thinning and fibre diameter expansion ("giant axons") (n=1), with reduction in the MF density (markedly n=2, moderately n=3) and onion bulb formations (n=1). Teased fibre analysis (n=6) detected myelin thinning (n=2), axonal ovoid formations (n=3). EM (n=4) detected expanded MF diameters (n=1) with myelin thinning. *The picture was consistent with an axonal peripheral neuropathy in all patients screened. The patients with "giant axons" identified on biopsy had further diagnostic clarity where toxin exposure with glue sniffing was suspected.*

Two patients (1 female: 1 male) had **spinal defects** (spina bifida and spinal dysraphism). They did not have a family history and one presented with clinical neuropathy features by two years of age whilst the other was older. Neurophysiology was normal in one child but consistent with an axonal peripheral neuropathy in the other with mild to moderate slowing of the conduction velocities and a neuropathic EMG. Nerve biopsy performed at the ages of 13 and 14 years revealed moderate reduction of MF density (n=1), fibre myelin thinning in teased fibre preparations (n=1) and cluster formations on EM (n=1). The patients were both considered to have axonal peripheral neuropathies.

Four male infants had **arthrogryposis multiplex congenita**. All presented from infancy and had nerve biopsy features of axonal pathology.⁽²⁾

DISCUSSION.

Over a 37 year period 296 patients were identified with peripheral neuropathies confirmed by nerve biopsy. This group with chronic peripheral neuropathies was dominated by hereditary pathologies both in the “pure” hereditary motor sensory neuropathy group, but also those associated with central / neurodegenerative disorders. The original group consisted of 426 nerve biopsies, of these 130 were normal. These patients with normal nerve biopsies were dominated by infants and children with neurodegenerative disorders and infants with severe hypotonia. Many samples were performed prior to specific molecular genetic and neurometabolic screens becoming accessible.

Charcot-Marie-Tooth disease is the commonest neuromuscular disorder. This data is based on adult prevalence studies or combined studies with paediatric figures integrated.⁽³³⁾ CMT1 is the commonest demyelinating disorder occurring in 1:2500 of the population and representing 70% of all demyelinating CMT.⁽³⁵⁻³⁷⁾ Of the available paediatric studies this figure is closer to 50%.^(29,30) Most studies are from European and North American centres. In our Australian based study the patients with CMT1 represented 37% of the demyelinating group, with 27% having CMT1A. The CMT1 group were 16.7% of the total inherited peripheral neuropathy group. This figure is an under representation of the prevalence since the availability of 17p duplication genetic screening is one of the few tests readily available to most centres following confirmation of the defect in 1991.^(38,39) Hence many patients presenting with demyelinating disease since 1991 would have undergone genetic screens first and only proceeded to biopsy if results were negative or the screening was unavailable. The cohort described in this study at the time of their biopsy predated the discovery of the mutation and were gene tested at a later stage. Despite this, our number of patients with CMT1 was high confirming that this condition does indeed occur in childhood. There is literature to suggest that anticipation could occur in some patients with CMT1A whereby the severity of the disorder is more marked in subsequent generations.⁽³³⁵⁾ The cause for this is not known but would explain in some of the familial cases the increased incidence at younger ages with each generation.

From the **demyelinating group** despite the extensive range of sub-divisions for CMT1 (A-F) most patients (n=20) were part of the 1A group, one was suspected to have A or B (his *MPZ* screen was not available) and another patient could not be categorised beyond

CMT1 (she was negative for chromosome 17 duplication and *MPZ* mutation). Beyond this, five patients had a dominant pattern of inheritance and a phenotype compatible (based on clinical, neurophysiological and histopathological data) with CMT1. But despite the key pointers highlighted in Table 1.2 they could not be categorised further.

Fourteen patients complied with the phenotype for CMT3; 9 of them had genetic confirmation. The detection rate of point mutations in this group was very high. Despite extensive screening of three of the remaining five patients without genetic delineation, none have to date been found to have other mutations described in the DSS category, namely periaxin, and *EGR2*. This may reflect that these three patients did not have ancestries from the populations who typically carry those other mutations, such as periaxin mutation in the Lebanese population.^(58,111-114,336)

Six patients had CMT4; this is a relatively new term. It has defined a number of previously unidentified phenotypes and assisted to clarify some of the confusion surrounding the hypomyelinating syndromes.⁽³³⁷⁾ From our cohort the patients who were labelled with autosomal recessive demyelinating and remyelinating / demyelinating neuropathies were reanalysed for features of CMT4. Typically patients are of infantile onset with delayed motor milestones and eventual loss of ambulation is not unusual.⁽¹¹⁵⁾ Extensive peripheral nerve involvement occurs and additional vocal cord paresis, bulbar, facial, diaphragmatic weakness and sensorineural deafness are often described. This group was already separated from the CMT3 category predominantly based on their histopathological data (including myelin-outfolding CMT4B, CMT4F and CMT4H). With the combined information and definitive genetic screens in two of the patients (*MPZ* mutation and *frabin* mutation), all patients were categorised (CMT4B n=5 and CMT4H n=1).^(115,116) Rare forms would be CMT4H related to *frabin* mutations which was identified in one patient from the cohort. Phenotypically this patient had no features to differentiate her from a severe demyelinating neuropathy, her peripheral nerve biopsy demonstrated the typical myelin-outfolding but without the molecular genetic diagnosis she could not be categorised further. Of the remaining group in whom myelin-outfolding was common, mutations in the *MTMR2* region would be expected. However only one patient was screened and the results are outstanding.

One patient was labelled HMSNVII – his phenotype complied with the original description.^(159,168) There is little in the literature on this rare disorder.

Of the 73 patients with demyelinating peripheral neuropathy, 34 (47%) attained a molecular genetic diagnosis. But when the group who underwent genetic screening were assessed the figure increased to 78%. Twenty-two patients (30%) could not be categorised. Many of these patients without categories predated the current molecular screens and did not have DNA material available for analysis.

The patients allocated to the remyelinating / demyelinating group (n=16) did not belong in any clear category falling between features of CMT1 and CMT4. Their nerve conduction velocities were too slow for CMT1, but they lacked key pointers to sub-divide them further. They appeared to have sporadic or recessive patterns of inheritance; most were of onset in the first decade and the incidence of scoliosis was high (a third). They may eventually be delineated into CMT4 sub-groups once their mutations are identified. Since only six of this group had undergone extensive but negative genetic screening this group may still attain diagnostic closure.

Similarly the six patients in the atypical demyelinating group fitted no known category due to combinations of atypical clinical features, neurophysiology and histopathology. Three of them had undergone genetic screening without identifying a mutation.

Eighty-one of the patients had **axonal neuropathies**. Twelve were in the category autosomal dominant CMT2. Of this group it was possible to sub-categorise 4 patients based on clinical phenotype and molecular genetics (CMT2A n=3, CMT2E n=1). The finding of CMT2A (due to MFN2 mutations) in three of the patients could represent a proportion of a larger cohort, yet to be defined, the *mitofusin2* mutation is considered the commonest to occur and its identification should allow categorisation of many of the patients with hereditary axonal forms of CMT.^(75,77,252) The patient with CMT2E was initially labelled with either "toxin exposure" or giant axonal neuropathy based on his biopsy appearance of giant axonal fibres. However he presented early, with no history of toxin exposure and was cognitively intact. The combination of his phenotype including his sensory complications complied with the diagnosis CMT2E.^(65,78)

Eighteen patients (22%) of the axonal group complied with the category for EOHMSN or SEOAN. This entity was the commonest single group of the axonal neuropathy patients. This disease is a severe and clearly common form of CMT which occurs in early childhood with major disability.^(102,103) The identification of *mitofusin2* mutations in 5 of the patients to

date reinforces the relevance of this severe form and the need to investigate these children thoroughly.⁽¹⁰⁴⁾ Of the eight children with the condition screened for the *mitofusin2* mutation only one has not had the mutation identified. Affected patients are at risk of significant disability with contracture formation, scoliosis, loss of ambulation and occasional optic atrophy.^(102,103) EOHMSN does not appear to have been categorised as an entity in itself in many reviews of sub-forms of CMT, but the size of this cohort should confirm the need to recognise it as a specific sub-category of severe childhood onset axonal CMT. It has been suggested that EOHMSN should be recognised under the term SEOAN (severe early onset axonal neuropathy) and that the condition should be placed in a CMT2B sub-category for autosomal recessive disease (personal communication Professor S Scherer).

Seven patients (8.5% of axonal group) had SIANR (genetic mutation SMARD1). The mutation was identified in all those who underwent genetic screening (n=5). This condition is probably more frequent than previously recognised with many more patients now being reported.⁽¹⁰⁶⁻¹⁰⁸⁾ The range in recognised phenotypes of the condition has also widened.⁽³³⁸⁾ It was originally reported as a peripheral neuropathy involving motor and sensory nerves with secondary anterior and posterior horn cell fall-out.⁽¹⁰⁶⁾ When the genetic marker was identified the condition was described as a primary condition of the anterior horn cells.⁽¹⁰⁸⁾ It is evident that both anterior and posterior horns are affected, with heterogeneity in the regions maximally affected in patients with the SMARD1 mutation.⁽³³⁹⁾ Diverse ethnicities are affected by this devastating condition; prenatal diagnosis is possible and there is ethical debate about the level of appropriate intervention.⁽³⁴⁰⁻³⁴⁸⁾

Two female siblings presented with a severe relapsing axonal neuropathy. Both died without a definitive diagnosis. The hereditary nature was assumed as both siblings were affected and the parents were normal (presumed autosomal recessive). The older sibling was originally considered to have CIDP but this was thought less likely when the second sibling became affected. Severe cases of axonal "CIDP" are described with debate about the term itself and the inclusion criteria.⁽³⁴⁹⁾ No children with hereditary forms of CIDP were identified in published reports. Of the few with a hereditary nature, all were linked to other conditions.⁽³⁵⁰⁻³⁵²⁾ One patient reported had a similar phenotype with young onset and relapsing pattern resulting in death from respiratory failure.⁽³⁵³⁾ Although reported as CIDP following publication another female sibling was born with an identical phenotype (personal communication Dr B

Anlar). The patient was considered to have demyelinating pathology but with macrophage infiltration.

Thirty-one patients were labelled “atypical axonal and sporadic sensory neuropathy”. This interesting mix of patients all had different phenotypes – some may conform to the autosomal recessive CMT2 categories.

Nine patients underwent peripheral nerve biopsies to screen for neuropathies associated with distal hereditary motor neuropathy: of this group only one was affected. This condition is proposed to be an exclusive motor neuropathy, and has been referred to as a neuronopathy based on the concept that the primary disease is in cell body of the anterior horn cells and not the axons. However reports of minor sensory abnormalities identified in neurophysiological and neuropathological studies, as occurred in one patient from this study, have contended this concept.^(169,184)

Nine patients were categorised in the CMTX group – one patient had a *connexin 32* mutation (CMTX1).^(116,141) Another patient presented very young with a strong family history – his phenotype was more in keeping with CMTX2 or X4 but his genetic screens were negative.⁽³⁵⁴⁾ Three patients complied with the category for CMTX5 with optic atrophy and deafness. Two of the group were female, they presenting later than the affected male patient. Genetic screening in the one male patient confirmed a *PRPS1* mutation.^(143,148,149) These last four patients were described in the section for axonal disease. The fact that they complied with CMTX illustrated the overlap and inevitable difficulties in trying to place the patients into fixed “axonal”, “demyelinating” and “mixed” categories. The patients with EOHMSN typically have primarily an axonal disorder but manifest on histology with additional features of demyelination with onion bulb formations.⁽¹⁰⁵⁾ Secondary demyelination may occur as a consequence of axonal disease⁽³⁵⁵⁾ and axonal degeneration is common as part of severe demyelinating disease. This axonal damage is thought to be the determinant of the severity of the clinical course in patients with CMT1.⁽⁴⁶⁾

The HSAN group was relatively small. Clinical features often directed the disease categorisation but the biopsy was helpful to further define the condition. One of the group had clinical features but normal NCS. His biopsy confirmed axonal neuropathy. This highlighted an important scenario occasionally seen where there is clinical suspicion of neuropathy which is not supported by the surface electrode studies.^(259,330) This may be because the specific

disorder affects the small MF and unmyelinated MF which are not the determinants of the NCV in conventional surface electrode studies.⁽²⁵⁶⁾

Two patients had CMT5 – this is a complex group and important to recognise. Many patients are labelled with forms of cerebral palsy before the progressive nature of their disorder is recognised.^(356,357)

Of the eighty-eight patients with hereditary axonal and mixed disease 15 (17%) gained molecular genetic diagnoses. However of the group only 37 patients underwent genetic screening and 38% of them attained a genetic diagnosis. Thirty-three (37%) of the group could not be categorised.

Genetic correlation: The one hundred and sixty-one patients described with hereditary peripheral neuropathies as their primary disorder most typically followed a recessive or sporadic pattern of inheritance (n=108), with dominant inheritance less common (n=53). Forty-nine patients attained definitive molecular genetic diagnoses, twenty-eight of whom had autosomal dominant patterns of inheritance and 21 autosomal recessive. The disparity in these figures, where a larger number of patients had autosomal dominant patterns of inheritance was due to the diagnoses of patients with CMT1A (n=20). Screening for patients with autosomal recessive disorders tends to be more specialized as mutations are more likely point mutations.

Seventy-eight patients underwent peripheral nerve biopsy as part of their **neurodegenerative** screens. Many of them preceded genetic screens being available (e.g. Friedreich's ataxia). Some had conditions for which peripheral nerve biopsy remains useful either diagnostically or to direct screens e.g. neuroaxonal dystrophy, giant axonal neuropathy, some forms of metachromatic leukodystrophy.⁽²⁹⁰⁾ In patients undergoing extensive neurometabolic screens the nerve biopsy data may direct investigations more effectively.

Neuronal ceroid lipofuscinosis is rarely described with an associated peripheral neuropathy.⁽³⁵⁸⁻³⁶¹⁾ Sural nerve biopsy is not routinely performed and most reported cases are based on nerve conduction study findings.⁽³⁵⁹⁾ The involvement however is logical with inclusions in Schwann cells and the neuraxis reported.⁽³⁶²⁾ Of the published reports the heterogeneity of the disease manifestations within the same family is noted whereby not all have associated peripheral neuropathy.^(360,361)

Two patients with **neurofibromatosis type 1 (NF)** had biopsy-confirmed peripheral nerve disease. Localised nerve involvement is well described but a more generalised involvement occasionally occurs although there is debate as to whether two pathological entities may have arisen co-incidentally.⁽³¹³⁻³¹⁶⁾ Most reports are based on NF type 2 patients.^(314,363,364) The role of reduced *merlin* gene dosage is believed to be relevant in the manifestation of peripheral neuropathy in NF type 2.⁽³⁶⁵⁾ Although reports of NF type 1 associated sensorimotor neuropathy are less frequent, there is a suggestion that this complication is more common than is realised and may be sub-clinical in most patients. As such, peripheral neuropathy in patients with NF1 should be monitored for since the complications can be severe.^(315,364) Based on histological confirmation, supported in our series, there is direct involvement of the peripheral nerves in NF1.^(315,364)

Five out of the sixteen patients with **spinal muscular atrophy (SMA)** had evidence of peripheral neuropathy on sural nerve biopsy. Studies have suggested that this is related to the more severe type 1 phenotype and reflects immobility.^(328,366-369) However SMA is a multisystem disease with studies suggesting fatty acid metabolism and mitochondrial dysfunction.⁽³⁷⁰⁻³⁷³⁾ Most reports suggest the neuropathy is secondary but full understanding of the disease mechanism is still not complete⁽³⁷⁴⁾ and direct pathological involvement of the peripheral nerves is likely.^(328,369)

Forty-eight patients had **acquired pathologies**, some were screened for CIDP and the biopsy assisted in differentiating them from the CMT group.^(352,375) Some of these patients have already been reported in a separate paper.⁽³³²⁾ At times, however, the biopsy appearance led to treatment for CIDP before a diagnosis of a hereditary polyneuropathy was established. This occurred with one of the patients with *MFN2* mutation.^(352,375)

Nine patients had mononeuropathy predominantly involving the sciatic nerve (n=6). This is a relatively rare entity.⁽³⁷⁶⁾ Vasculitic processes are the major cause described, especially related to systemic lupus erythematosus, followed by vascular insults and isolated lesions in the nerve itself such as perineuriomas.^(377,378) Nerve biopsy has been promoted as a useful diagnostic aid in this clinical setting.⁽³⁷⁹⁾

The need for “**endotyping**”: Modern technology has advanced such that there are over 44 gene locations mapped for various peripheral neuropathies.⁽⁵⁾ However this technology has opened up new understandings that the clinical picture and prognosis cannot

always be concluded from the molecular genetic result in isolation. It is often necessary to combine the information on the clinical phenotype, neurophysiological and histopathological results with the molecular genetics findings in the patients presenting in childhood to gain an understanding of the underlying process. This study has attempted to use this system to advance understanding of the numerous forms of peripheral neuropathy presenting in childhood and to define the prevalence of these in a large population.

Even this may be an over simplification as the role of the various gene products continues to expand with different disease manifestations seen with the same protein deficiency. This is illustrated in Table 1.4. *Myelin protein zero* mutations can result in demyelinating and axonal disorders.^(58,59,97,98,112,131,159) Some patients present in infancy, others in middle age.⁽³⁸⁰⁾ Some mutations are specifically associated with Holmes-Adie pupils^(381,382). Some appear to cause remittent neuropathy.⁽³⁸³⁾ The action of myelin protein zero in the compaction of the myelin as part of Schwann cell function and regeneration explains some of this process.^(112,384) The same apparent condition (phenotype) can result from different mutations.^(111,112,114,336,385)

Many centres worldwide managing children with clinically diagnosed peripheral neuropathies cannot perform molecular genetic analysis or are limited to the most standard duplication or deletion screen of chromosome 17p. Similarly the technique of performing nerve conduction studies in children is specialised and requires skilled operators and specialists trained to interpret the values normally recorded in childhood. Peripheral nerve biopsy analysis should only be analysed in centres confident with the technique and analysis. Thus three out of the four main requirements used for “endotyping” these patients are lacking in most parts of the world. One could debate whether it matters if the management is the same for all patients. However in reality there are factors which differ from type to type including prognosis, levels of intervention (surgery, splints, frequency of physiotherapy etc), and especially genetic advice. Accordingly this data should be used as a guide to key markers which may aid diagnosis, subsequent therapy and genetic advice. Vitamin C therapy for patients with CMT1A may become a recommended intervention in the near future – thus precisely identifying these patients is important.⁽³⁸⁶⁻³⁸⁸⁾

Many of the patients studied had samples taken prior to molecular genetics being available and as such did not have DNA analysis. Some patients attained a genetic diagnosis some 30 years after initially being studied.

Even in the context of a facility with the ability to screen patients for many of the recently identified gene loci a significant proportion of the database with clear genetic aetiology remained without a molecular genetic diagnosis. This was most marked for the axonal / mixed group (15/37) compared to the demyelinating group (34/50). This is the case in all centres.

Allocating specific sub-categories was possible for many of the patients but a proportion remained in various miscellaneous categories (remyelinating / demyelinating, atypical axonal, atypical demyelinating) even with the capabilities available to a centre specialising in paediatric neuromuscular disorders with access to DNA research laboratories. Particular mutations have had a significant impact on categorising many of the paediatric onset conditions. *Mitofusin2* mutations are found predominantly in axonal disorders and to date have been identified in 8 patients of the group. It is expected to delineate a large proportion of the patients with axonal disease, especially those with EOHMSN.⁽¹⁰⁴⁾

Of the miscellaneous groups, many of those patients are likely to be part of the CMT2 recessive and the CMT4 categories with mutations yet to be identified. Rare protein mutations are often located to specific gene pools.

By nature of its invasiveness as an investigation peripheral **nerve biopsy** is often left at the end of a list of other studies. The expanding field of molecular genetics has further lessened the need for biopsy, which was often used to confirm a diagnosis of CMT1. However there are many conditions which may remain dependent on biopsy to confirm the diagnosis. This includes not just the group with characteristic disease-specific findings evident on biopsy alone but also the group whereby the nerve conduction studies may suggest a demyelinating process but the biopsy identifies an axonopathy, for example the EOHMSN group.⁽¹⁰⁵⁾ Patients with intermediate NCS are often diagnostic dilemmas and nerve biopsy can help define the most likely genetic categories to look for. For example *mitofusin2* mutations have striking mitochondrial abnormalities as well as additional features to the axonal degeneration, such as onion bulb formations.⁽¹⁰⁵⁾ Patients with CMT2E may have giant axonal fibres. The patient from our series was categorised to have this, based on a typical clinical phenotype not

compatible with giant axonal neuropathy or toxin (glue sniffing) exposure – ideally he should have NEFL screen but his DNA was not available at this time.^(65,78) This case illustrated the usefulness of the nerve biopsy. Patients with giant axonal neuropathy are reported without the “woolly” hair. In centres where DNA analysis is not available, these biopsy findings can assist diagnostic dilemmas.^(389,390) Similarly identifying a patient with myelin-outfolding will direct investigations towards forms of CMT4 (B,F and H).⁽¹¹⁵⁾

The degree of nerve involvement will also correlate with disease severity as can be seen in patients with Friedreich’s ataxia.⁽²²⁶⁾

Conclusion: This study highlights the extensive range of peripheral neuropathies found in childhood emphasising the high level of inherited disorders as opposed to acquired disorders.

Many conditions were identified in patients of a far younger age than normally expected to be susceptible to specific peripheral neuropathies.

Nerve biopsy should remain as an essential part of the diagnostic screen for affected patients who lack clear delineation despite genetic screening or where there is lack of access to molecular genetics.

CHAPTER 4

PERIPHERAL NEUROPATHIES OF INFANCY.

Published in *Developmental Medicine and Child Neurology*⁽²⁾

Wilmshurst JM, Pollard JD, Nicholson G, Antony J and Ouvrier R. Peripheral neuropathies presenting under one year of age. Dev Med Child Neurol 2003;45:408-414

(Publishers granted permission for inclusion in thesis)

SUMMARY

Over a 30 year period 260 New South Wales patients aged less than 17 years, who had peripheral neuropathies confirmed by nerve biopsy, were studied. Of these, 50 infants presented with symptoms or signs of neuropathy less than one year of age. The group included 24 demyelinating and 21 axonal cases (22 male: 23 female). A further 5 patients had spinal muscular atrophy with associated secondary sensory axonopathy (4 male: 1 female). Nineteen infants had hereditary motor sensory neuropathy, of whom 13 had myelin protein mutations confirmed by molecular genetic studies. Peripheral neuropathy is not an unusual diagnosis in infancy. Awareness of this association will aid early diagnosis and prognosis as well as facilitate interventional patient management.

INTRODUCTION.

There are few studies specifically describing peripheral neuropathies presenting clinically in infancy. The majority of these concentrate on the hereditary types. ^(29,31,391) The European multicentre study identified 287 children with "pure" peripheral neuropathy. ⁽²⁹⁾ Of these, 20 presented less than 1 year of age. The majority were congenital and the authors emphasised that CMT1 (HMSN I) could occur in this age group. At the time of the study molecular genetic analysis was not available and biopsies were not performed in all.

In a further study reviewing genetic neuropathies in Swedish children (0-15 years) over an eight year period, 103 children were identified. ⁽³⁰⁾ The study divided the group into motor / sensory neuropathies (n=63), sensory neuropathies (n=3) and central nervous system (CNS) disorders with peripheral neuropathy (n=37). Those with infantile onset were not separately analysed.

The following study describes a large series of children with biopsy-confirmed peripheral neuropathy who presented with symptoms in infancy.

METHOD.

From 1969 to 1999, 362 children (0-17 years of age) had sural nerve biopsies analysed at the Nerve Research Laboratory University of Sydney. Two hundred and sixty of these had a peripheral neuropathy. Fifty children were symptomatic in infancy (less than one year of age). Frequent clinical features were hypotonia, weakness, sensory alteration, areflexia, ataxia, contractures and wasting. The diagnostic categories were allocated through a combination of recognised clinical features, neurophysiology results and biopsy findings. ⁽⁴⁴⁾ As sural nerve biopsy was often one of the last studies to be performed, many patients were older than one year at the time of sampling. Median age at nerve biopsy was 2 years (inter-quartile ranges 1-3.8 years; total range 8 days to 8 years). Since 1993, many of the patients have had DNA studies for clinically appropriate diagnostic entities. In all 17 have had such studies and when performed the results have been described in the text.

RESULTS.

Of the 50 children, there were 24 with demyelinating neuropathies, 21 with axonal neuropathies (22 male: 23 female) and 5 cases of spinal muscular atrophy with sensory axonal degeneration (4 male: 1 female). The group diagnoses are summarised in Table 1. No patients had known complications during or following peripheral nerve biopsy.

Table 4.1: Summary of infantile-onset peripheral neuropathy diagnostic categories

| | |
|------------------------------------|---|
| 24 demyelinating disorder:- | |
| CMT1 | 7 |
| Hypertrophic sporadic / recessive | 2 |
| CMT3 | 7 |
| CMT4B | 2 |
| HMSN Miscellaneous | 1 |
| Peroxisomal disorder | 1 |
| Leukodystrophy-unclassified | 2 |
| Neurodegenerative disease | 2 |
| 21 axonal disorders:- | |
| HSAN IV | 2 |
| HSAN V | 1 |
| HSAN Miscellaneous | 1 |
| Sporadic sensory neuropathy | 1 |
| Chronic axonal - miscellaneous | 1 |
| Early onset HMSN of axonal type | 1 |
| Severe infantile axonal neuropathy | 3 |
| + respiratory failure | |
| Severe relapsing axonal neuropathy | 1 |
| Peroxisomal disorder | 1 |
| Giant axonal neuropathy | 1 |
| Leigh Disease | 1 |
| Neurodegenerative disease | 3 |
| Arthrogryposis multiplex | 4 |
| Secondary axonopathy: | |
| SMA 1 | 5 |

Hereditary motor sensory neuropathies of demyelinating and remyelinating type.

Charcot Marie Tooth (CMT) (n=19)

Of seven patients with dominantly inherited **CMT1**, five had chromosome 17p11.2-12 duplications (**CMT1A**), one had partial trisomy of chromosome 17p and one had a positive family history (her father was affected). The patient with partial trisomy of chromosome 17p had the typical phenotype of seizures, global delay and dysmorphism in addition to the neuropathy.⁽³²⁴⁾

Two patients had **remyelinating / demyelinating neuropathies**. Clinically they presented with a combination of early contractures, hypotonia and areflexia with subsequent delay in walking. One of the two had a positive family history with her mother clinically affected, but she was negative for the chromosome 17p11.2-12 duplication, *myelin protein zero mutation*, *PMP22 mutation* and *ERG2 mutation*. The apparently autosomal dominant pattern of inheritance was compatible with CMT1 but the negative Chr17dup and *MPZ* screen precluded type 1A and 1B. The other case was sporadic.

Nerve conduction velocities were abnormal in all those tested (n=8/9) with common peroneal MCV ranging from 0-22 metres/second (mean value 10 metres/sec) and median MCV ranging from 6-31 metres /second (mean 18 metres/second). The patient with trisomy did not have nerve conduction studies. Of the four EMG studies three were normal (from the CMT1 group) and one showed evidence of denervation.

Nerve biopsies confirmed prominent demyelination with onion bulbs in many myelinated fibres. Density was significantly reduced in six of the nine patients. The extent of demyelination on teased fibres varied from 20-70%. One patient had secondary axonal changes in 5% of teased fibres. The severity of biopsy changes did not correlate reliably with nerve conduction studies or clinical disability.

Seven patients had **CMT3**. Four had *myelin protein zero* mutations, two had *PMP22* point mutations and one did not have molecular genetic studies. The patients with *myelin protein zero* mutations had a six base pair insertion (AGTTCT) in exon 3, resulting in a two amino acid insertion (phenylalanine to tyrosine) after aspartate 118 in one case, a cytosine to guanine substitution at nucleotide 188, leading to a serine 63 cystine substitution in the extracellular domain (exon2) in another and the remaining two patients had a cytosine to thymine substitution giving an arginine 69 cystine substitution on exon 2 (extracellular). Of the

patients with *PMP22* point mutations one had a cytosine to adenosine base change on exon 1 causing a histidine/glycine substitution at position 22, the other had a cytosine to thymine change on exon 3, causing a serine/leucine substitution at position 22. Five of the seven presented between 6 and 10 months of age with motor delay and hypotonia. One patient in this group, with a *myelin protein zero* mutation, died at 11 months being severely weak, with bulbar and respiratory dysfunction.⁽³⁹²⁾ His features were similar to the cases described by Felice et al.⁽³⁹³⁾ Of the remaining two patients one presented at birth and the other at 6 weeks of age with hypotonia. Motor conduction velocities were profoundly slowed, mostly below 10 metres/second. Nerve biopsies revealed significant reduction in the density of myelinated fibres with hypomyelination and / or demyelination and extensive onion bulb formations (Figure 4.1).

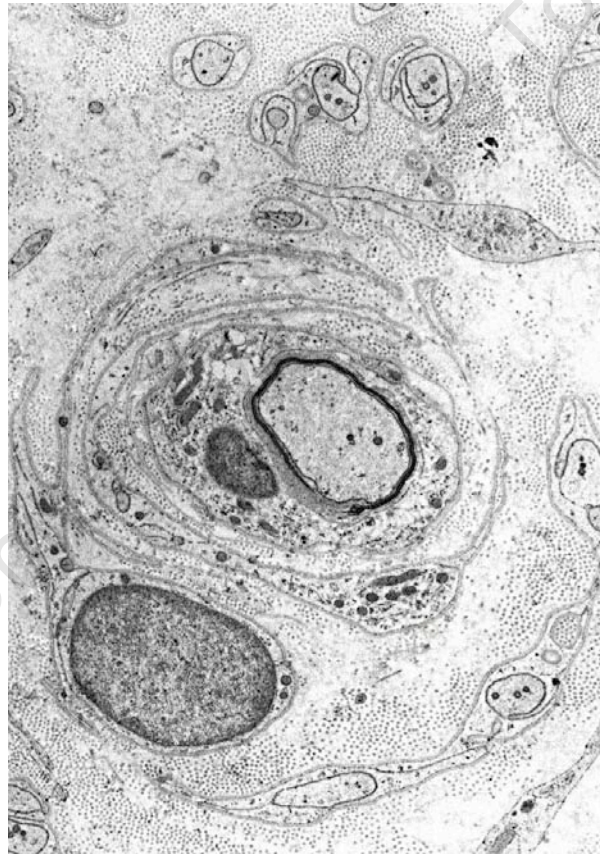

Figure 4.1: Sural nerve section electron micrography plate (magnification x20 000) from a patient with myelin protein zero mutation CMT3, showing a thinly myelinated fibre surrounded by an onion bulb formation and a Schwann cell nucleus.

Two patients who were hypotonic at birth, had HMSN with excessive myelin unfolding (**CMT4B**)⁽³⁹⁴⁾ on sural biopsy (Figure 4.2). One had bilateral ptosis, motor delay, areflexia and progressive weakness. Without biopsy this diagnosis could not have been confirmed at the

time of these patients' presentations. One of these patients has subsequently been confirmed to have a *myelin protein zero* mutation (AGC > GCC on exon 2 causing a Thr 65 Ala substitution).

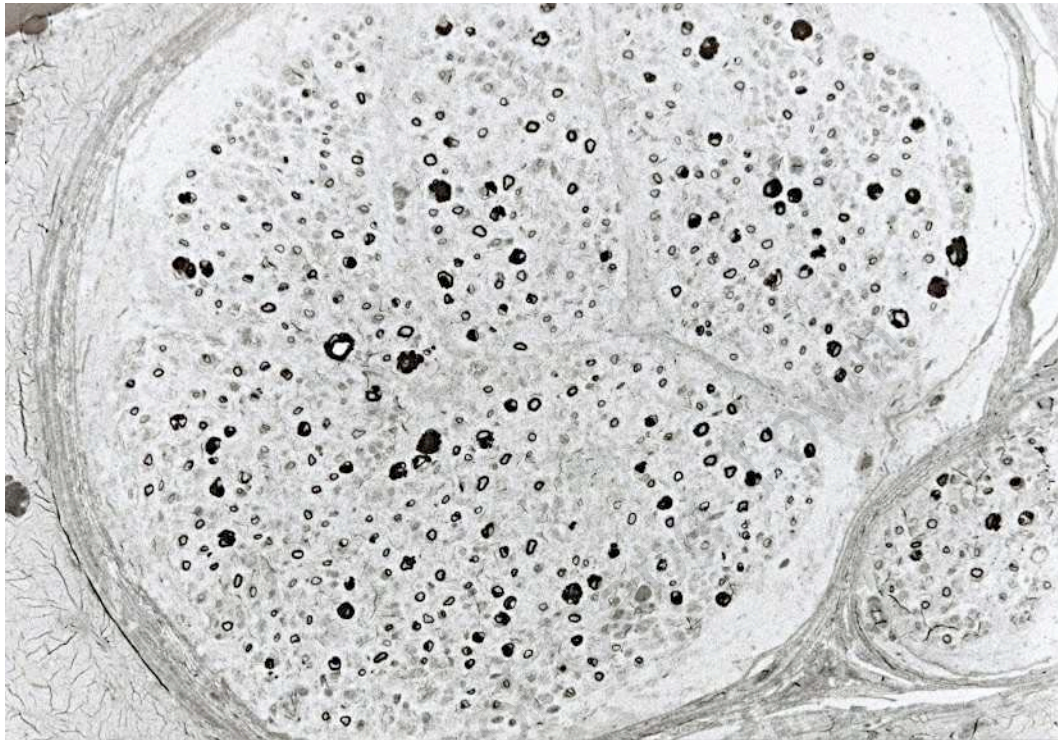


Figure 4.2: Transverse section from the sural nerve of a patient with CMT with myelin-outfolding, showing a reduction in myelinated fibre density and myelin outfolding in many of the fibres. (Light microscopy, toluidine blue stain, magnification x100)

One patient did not have the criteria for any of the recognised demyelinating CMT subtypes (**miscellaneous CMT**) She presented at 10 months of age with motor delay, distal weakness, clumsiness with a family history of an affected sister (who was negative for chromosome 17 duplication, *myelin protein zero* mutation, *PMP22* mutation and *ERG2* mutation). On NCS her motor conduction velocities were below 10 metres/second and sensory potentials were abnormal. Her nerve biopsy at the age of 4 years, confirmed demyelination with onion bulbs and 40% reduction in fibre density. Studies for *myelin protein zero* mutation was negative. She ultimately went on to have an affected child.

Of the total CMT group thirteen had diagnostic molecular genetic results with the greatest detection rate from the CMT1A (n=6/7) and CMT3 (n=6/7) patients.

Hereditary sensory autonomic neuropathy. (HSAN) (n=4) Two patients had **HSAN type 4**. They presented at 3 and 4 months of age with insensitivity to pain, autonomic dysfunction and failure to thrive. Sensory potentials studies, performed in one patient at 8 months of age, revealed normal median and ulnar responses, whilst the sural action potential, was reduced at 2 microvolts. Motor conduction studies (median, ulnar, peroneal and tibial) were normal in both. There was a marked decrease of unmyelinated fibres and small myelinated fibres on nerve biopsy. One patient had **HSAN type 5**. She presented aged 7 months with no response to pain, ulcers distally of the limbs and a fractured tibia. Her motor and sensory nerve conduction studies were normal. On nerve biopsy a selective loss of small myelinated fibres was found.⁽³²⁹⁾ . One patient could not be categorised (**miscellaneous HSAN**). He presented with a history of insensitivity to pain from birth, associated with tongue biting. At 11 months it was also evident that he had language and social delay. He had steady clinical improvement but was lost to follow up early in his course. Axonal degeneration was found on nerve biopsy and nerve conduction studies were normal.

Sporadic sensory neuropathy / Chronic axonal miscellaneous (n=2)⁽³²⁶⁾ Two patients had sporadic atypical sensory neuropathies with large diameter myelinated fibre loss and without significant disturbance of pain or temperature sensibility or of strength. One presented with motor delay, possibly related to impaired proprioception and the other also had motor delay associated with ataxia and scoliosis. Neither patient has progressed (aged 10 and 15 years) and the scoliosis in the second has improved. Sensory action potentials were abnormal in both and motor studies were slightly slowed in the first patient. Nerve biopsies identified axonal degeneration in both, with marked reduction in myelinated fibre density. Molecular genetics studies in the first patient were negative for SCA (spinocerebellar atrophy) types 1, 2, 3, 6 and 7.

Early onset HMSN of neuronal type (Severe early onset axonal neuropathy). **(n=1)**⁽¹⁰³⁾ This patient presented at 11 months, with motor and speech delay. Her biopsy at 2 years of age showed reduced MF density and axonal degeneration. Denervation was evident on EMG but nerve conduction studies were normal.

Severe infantile axonal neuropathy with respiratory failure (SIANR). **(n=3)**⁽¹⁰⁶⁾ Three patients all of whom had intrauterine growth retardation presented at or shortly after birth with contractures, hypotonia, distal weakness and areflexia. Diaphragmatic weakness

resulted in respiratory dysfunction and eventual death in all. Nerve conduction studies were either profoundly slowed or unrecordable. Nerve biopsy showed marked reduction in MF density, apparent failure of regeneration and very little active degeneration, suggesting that the infants were affected by a previous intrauterine insult and did not have the ability to recover from the resulting fibre loss. One of the three infants was tested for a mutation of the *IGHMBP₂* gene and was found to have the mutation responsible for a form of spinal muscular atrophy with diaphragmatic involvement (SMARD1)⁽¹⁰⁸⁾ which we have shown to be sometimes associated with a generalised polyneuropathy (SIANR).⁽¹⁰⁶⁾

Severe relapsing axonal neuropathy (n=1) One patient presented at 8 months with acute-onset ataxia and weakness. After an almost complete recovery she relapsed at 21 months and died. Her sister was similarly affected. Nerve conduction velocities were in the so-called “demyelinating range” (median nerve motor conduction velocity 15 meters/second; common peroneal nerve motor conduction velocity 8 meters/second) and there was denervation on EMG. Nerve biopsy confirmed axonal degeneration, occasional thin myelin sheaths, reduction in myelinated fibre density and an increased number of macrophages.

Peroxisomal disorders (n=2) Two infants who presented at birth were first cousins (their mothers were sisters). One was generally weak, with nystagmus and areflexia and later developed pes cavus. His mother was mildly affected. His very long chain fatty acids were abnormal (C26:C22 ratio 0.075 (normal <0.035) C24:C22 ratio 1.2 (normal 0.55-1.15)) and his phytanic acid level was 0.1 mmol/l (normal range <0.5 mmol/l). His nerve conduction velocities, both sensory and motor, were slow (median nerve MCV 22 metres / second and common peroneal nerve MCV 10 metres / second). Nerve biopsy at the age of 2 years showed demyelination, thin myelin sheaths, reduction in myelinated fibre density by approximately 40%, onion bulb formation and increased macrophages. The other patient, who was floppy at birth, was subsequently found to have mental retardation and motor delay with areflexia. He had abnormally elevated phytanic acid levels. His nerve conduction velocities were slow (delayed sensory conduction; median nerve MCV 19 metres / second; posterior tibial nerve MCV 18 metres / second). Nerve biopsy showed a mixed picture. On transverse section, there was demyelination and reduced myelinated fibre density but myelin ovoids on teased fibre studies. On electron microscopy there was demyelination with glycogen accumulation in the Schwann cells.

Giant axonal neuropathy (n=1) This patient presented in infancy with motor delay, “woolly” hair, dry skin, pes cavus, and subsequently developed nystagmus, generalised weakness, areflexia, ataxia and absent vibration and proprioception sensitivity. Nerve conduction studies were mildly abnormal with borderline motor and sensory changes. The characteristic giant axons with thin myelin sheaths confirmed the diagnosis when a nerve biopsy was performed at 4 years. On teased fibre analysis there was a variation in myelin thickness and segmental demyelination.

Leigh disease (n=1) This infant presented at 3 months of age with developmental delay, seizures, generalised weakness, abnormal reflexes and cranial nerve palsies. Sensory studies were normal and motor nerve conduction studies were marginally slow (median nerve MCV 35 metres / second; ulnar nerve MCV 28 meters/second; common peroneal nerve MCV 31metres / second). EMG suggested denervation. Nerve biopsy at 1 year of age was more suggestive of an axonopathy with reduced myelinated fibre density than the recognised demyelination which occurs with Leigh disease.

Leukodystrophy – unclassifiable (n=2) Two infants presented with developmental delay from birth. The first had failure to thrive, seizures, hypotonia and microcephaly. Nerve conduction studies were slow (median nerve MCV 17 metres / second; ulnar nerve MCV 20 metres / second; common peroneal nerve MCV 15 metres / second) and sensory potentials could not be elicited. Demyelination and sudanophilic deposits suggestive of leukodystrophy were seen on nerve biopsy. The second was floppy from birth with developmental delay, ataxia, ophthalmoplegia and Hirschsprung disease. Conduction studies were also slow (median nerve MCV 25.5 metres / second; absent sensory action potential amplitudes). Lysosomal enzyme analysis for metachromatic and Krabbe leukodystrophies were negative in this patient. There was a markedly reduced density of myelinated fibre, with demyelination and onion bulb formations. The clinical and histological features of this patient were similar to a recently described case with a *SOX10* mutation⁽³⁹⁵⁾ or POLIP syndrome (polyneuropathy, ophthalmoplegia, leukoencephalopathy, intestinal pseudo-obstruction)⁽³⁹⁶⁾. The mutation analysis was not available for this patient.

Neurodegenerative disorders (n=5) Five patients had undiagnosed neurodegenerative conditions. Two had demyelination and three had axonal degeneration on sural nerve biopsy. One of the two patients with demyelination presented in infancy with

developmental delay and infantile spasms. Nerve conduction studies were normal apart from marginal slowing of the median motor nerve conduction velocity (43 metres / second). Nerve biopsy at 7 years of age identified demyelination on transverse section and onion bulb formations and clusters on electron microscopy. His muscle biopsy was normal. The second patient had a similar picture but was felt to have an underlying disorder of mitochondrial function. This patient's nerve conduction studies were also slow (median nerve MCV 30 metres / second; common peroneal nerve 28 metres / second) with normal sensory studies and EMG. Demyelination was most evident on teased fibre analysis on nerve biopsy at one year of age. The patients with axonal pathology on biopsy included a boy who presented at 3 months of age with developmental delay, regression and hypotonia. He was diagnosed at a time when white cell enzyme studies were not available. Hence, although his clinical picture appeared consistent with Krabbe disease, there were several discrepancies, in particular an axonopathy on sural nerve biopsy. The other two patients presented at birth. One was hypotonic, irritable, had recurrent vomiting, respiratory dysfunction, motor delay and apparent absence of peripheral sensation evident by three months. The other patient was floppy with developmental delay, dystonia, bulbar dysfunction, failure to thrive and optic atrophy evident by four months. Again these patients were managed very early in the study before detailed molecular and mitochondrial studies were available.

Arthrogryposis multiplex congenita (n=4) All four of these male infants had nerve biopsy features of axonal pathology. One, who had biopsy findings of a marked decrease in MF density with cluster formations, was static clinically. The other three had progressive conditions with central nervous system involvement.

Spinal muscular atrophy (n=5) Sixteen patients, who had nerve biopsies, were subsequently found to have spinal muscular atrophy. Of this group five had features of axonal degeneration on sural nerve biopsy. These five infants presented at birth with severe weakness. Two had contractures and these bear similarities to the cases described by Korinthenberg et al.⁽³²⁸⁾ Nerve conduction studies were performed in one, confirming abnormal sensory action potentials with median nerve motor conduction between 10-24 metres / second and absent common peroneal nerve conduction velocity. Denervation was found in the two who underwent electromyography. All had biopsies performed under 4 months of age and all had an axonopathy, most evident on teased fibre analysis. Some decrease in fibre density

was evident in 4 out of 5. DNA analysis, performed in one patient, confirmed a deletion of the SMN gene on chromosome 5. Most of these patients presented prior to the time genetic studies became available.

University of Cape Town

DISCUSSION

Peripheral neuropathy in infancy is an uncommon entity. In this series a similar incidence of axonal and demyelinating pathologies occurred. Inherited rather than acquired causes predominated.

Charcot Marie Tooth type 1 (CMT1), more commonly recognised in the older population, may also have its onset in infancy.^(29,31) Seven infants from our series were affected, six of whom had confirmation on molecular genetic testing.

Seven of our patients had clinical features of CMT3 with six of them confirmed to have *myelin protein zero (PO)* or *PMP22* point mutations. It is striking how high the genetic yield is for these patients with early infantile presentation. A review of hereditary demyelinating neuropathy in infancy described nine patients with clinical features consistent with CMT3.⁽³⁹¹⁾ There was molecular genetic confirmation in six. In the present study peripheral nerve biopsy identified 2 of the nineteen infants as having HMSN with myelin out-folding (CMT 4B). In approximately half of such patients mutations of the myotubularin gene have recently been identified⁽¹²³⁾, while other scattered cases have been associated with *MPZ* mutations. In the remainder this diagnosis can only be made on nerve biopsy. One of our patients was found to have an *MPZ* mutation. The other has not yet been tested.

Respiratory dysfunction secondary to phrenic nerve involvement is described in a number of neuropathies including CMT3^(392,393), HMSN with myelin out-folding (CMT4B)⁽³⁹¹⁾ and severe infantile axonal neuropathy with respiratory failure⁽¹⁰⁶⁾ or SMA with respiratory distress.⁽¹⁰⁸⁾ Biopsy may be the only way to differentiate these neuropathies if all molecular genetic studies are negative.

Four of the infants with arthrogryposis multiplex congenita (AMC) had axonal degenerative features on nerve biopsy. Most cases of AMC do not have associated neuropathies but small groups have been described who have nerve pathology attributed to in-utero insults.⁽³⁹⁷⁾

Axonal degeneration involving sensory nerves is described in spinal muscular atrophy.⁽³⁹⁸⁾ Theories as to why there is sensory involvement in a motor condition include SMA being a more generalised condition than previously accepted or the loss and degeneration of sensory fibres occurring secondary to immobility.⁽³⁹⁸⁾ Sensory nerve changes were detected in five of sixteen patients in our total group with SMA type 1. Axonal degeneration and

myelinated fibre loss were seen on biopsy. These patients bear similarities with the described condition SMA with congenital contractures.⁽³²⁸⁾ Sensory nerve axonal degeneration was described in patients with the most severe form of SMA (type 1) and not type 2 or 3.⁽³⁷⁰⁾

Our patients with pure demyelination and / or hypomyelination were more likely to conclude with a definitive diagnosis, often confirmed through molecular genetics. When investigating these patients nerve biopsy is rarely indicated unless the molecular genetic, metabolic and neurodegenerative screens are negative. However the classification and inheritance of axonal neuropathies in infancy and childhood remain less well delineated.

Recommended investigations for peripheral neuropathy with onset in infancy or childhood have become more sophisticated and extensive with time⁽²⁵⁶⁾. Compared to earlier practices peripheral nerve biopsy (as an invasive procedure) needs to be performed less often with the availability of molecular genetics. Patients in our series with undiagnosable neurodegenerative disorders would almost certainly be diagnosed today, especially with increased recognition of mitochondrial disorders, availability of white cell enzyme screens and fibroblast cultures.

An approach to the infant with suspected peripheral neuropathy would be based initially on clinical and electrophysiological evidence (Algorithm 4.1). A combination of hypotonia, areflexia, distal contractures and muscle weakness more marked distally, especially with inappropriate response to pain, would be suggestive of peripheral neuropathy. A positive family history should be sought. Peripheral electrophysiology must be performed in a centre skilled in infantile studies and in the interpretation of the results. Performing motor / sensory studies in infants can be distressing. In our laboratory, they are performed with nitrous oxide inhalation for analgesia. Placement of electrodes should be accurate and is often problematic in unco-operative patients. The interpretation must be made with caution as the normal ranges vary significantly until five years of age when the nerve conduction velocity approaches adult levels.⁽²⁷⁶⁾ In some infants with axonal degeneration and a paucity of large diameter fibres, nerve conduction velocity may be in the so-called "demyelinating range" leading to fruitless exploration for myelin protein mutations. Further, axonal pathology does not always result in measurable abnormality in nerve conduction e.g. in small fibre neuropathies such as HSN types 4 and 5. Thus if the clinician has sufficient clinical evidence this should guide the management (this situation is more likely to lead to a nerve biopsy).

Once peripheral neuropathy is confirmed an underlying cause can be sought. Patients should be divided into those with and without central involvement for the infantile range. The group without central pathology will be dominated by the hereditary motor sensory neuropathies. A smaller number, not seen in our study may have acquired causes (Guillain-Barré syndrome, toxic, infectious (diphtheria) and nutritional deficiency states (vitamin B₁₂, thiamine and vitamin E). Molecular genetic studies usually identify a diagnosis for the demyelinating CMT patients. The axonal pathologies are less likely at the present time to have diagnoses which can be confirmed by molecular genetic studies, resulting in more nerve biopsies either to confirm the diagnosis of a polyneuropathy in the situation of normal NCS or to delineate the nature of nerve pathology (such as with toxin induced neuropathy, giant axonal neuropathy and some neurodegenerative disorders; infantile neuroaxonal dystrophy).

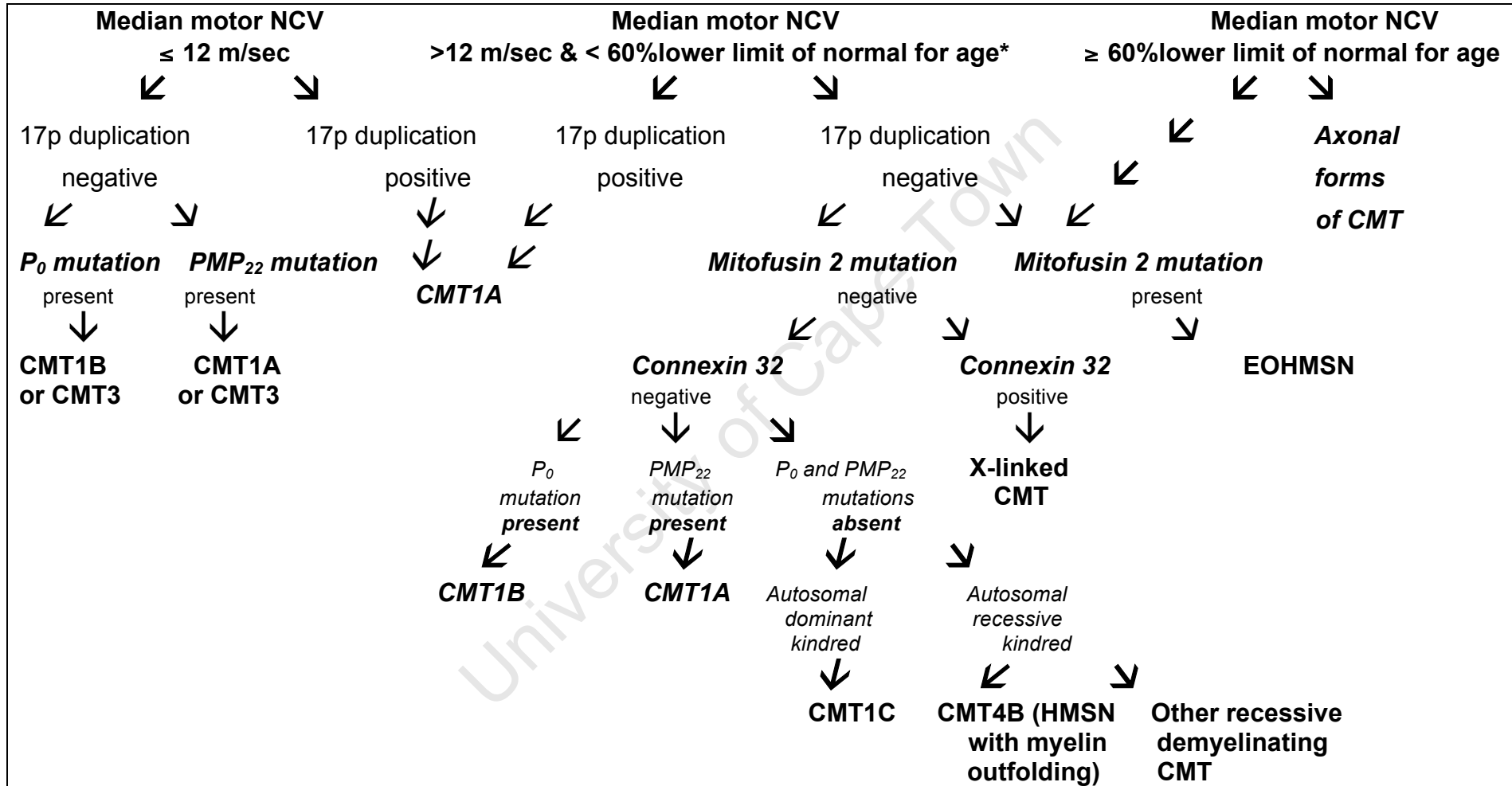
Patients with central involvement should be further subdivided into those with predominantly white and grey matter disease. White matter disorders will be dominated by the leukodystrophies, especially metachromatic leukodystrophy. Lysosomal enzyme studies generally confirm the diagnosis. Proceeding to nerve biopsy may only be necessary in patients with pseudodeficiency of arylsulphatase. Grey matter diseases include mitochondrial disorders (Leigh disease), neuroaxonal dystrophy and giant axonal neuropathy. Extensive screening investigations fail to achieve a clear diagnosis in some infants. Proceeding to nerve biopsy in these cases may provide the answer (e.g. giant axonal neuropathy without curly hair and neuroaxonal dystrophy). A number of patients with neurodegenerative conditions of unknown cause are found in most units. For the patients with additional central disease there is the potential for more information and the clinician should consider the role of skin, muscle and nerve biopsy in such patients already committed to a general anaesthetic to ensure the maximum information is collected. Storing histopathological material in these patients is essential as science advances and new diagnostic tests become available.

The role of muscle biopsy of patients with peripheral neuropathy is debatable. Generally the additional information for the pure peripheral neuropathies of axonal type is limited. Most of these patients will have a denervation pattern of grouped fibre atrophy. It is possible that the tempo of the disease progression could be more easily predictable on the basis of the muscle histopathology.

With the rapid progression of molecular genetics and available enzyme studies the need for peripheral nerve biopsy has steadily decreased. There are patients however, who will remain undiagnosed without this investigation. In the correct context peripheral nerve biopsy still has a role in both diagnosis and prognosis. That role includes:-

- i. The confirmation of small fibre neuropathies such as HSAN types 4 and 5, where conventional nerve conduction studies are normal.
- ii. The delineation of specific diagnostic pathologies in conditions where DNA analysis is unavailable or unhelpful such as certain autosomal recessive forms of CMT, some cases of CMT with myelin unfolding, giant axonal neuropathy with normal hair and neuroaxonal dystrophy.
- iii. The proof that the degenerative process is in fact demyelinating or axonal when nerve conduction studies are misleading, as occurs more frequently in infants than in older children and adults.

Algorithm 4.1: An approach through nerve conduction studies to Charcot Marie Tooth diseases (Hereditary Motor and Sensory Neuropathies).



* In some axonal neuropathies where large diameter fibres are greatly reduced, nerve conduction studies may be in the so-called “demyelinating range”.

CHAPTER 5

Review of Patients managed at Red Cross Children's Hospital

Neuromuscular service with Peripheral Neuropathies

SUMMARY

There is paucity of data relating to the occurrence of peripheral neuropathy in children from South Africa. Over a nine year period 123 children were managed in a dedicated paediatric neuromuscular service. Forty-four of them had hereditary causes and seventy-nine had neuropathies related to acquired causes. Most of the children with acquired causes had acute inflammatory demyelinating polyradiculoneuropathy (n=54) with a high incidence following *Campylobacter* or *Mycoplasma* infections. Five children from the group were referred with peripheral neuropathy related to the toxic side-effects of antiretroviral therapy for human immunodeficiency virus infection. Of the children with hereditary causes very few had CMT1A (n=4), whilst the majority had axonal forms of neuropathy (n=36), mostly from the CMT2 group (n=10). Sural nerve biopsies were performed on 15 children and were of use in all, either confirming the diagnosis or reinforcing the category suspected from the clinical and neurophysiological findings. Molecular genetic screens were performed in 22 of the children and resulted in a diagnostic label in 11. In two patients there were conflicting results where the molecular genetic results did not correlate with the patient's phenotype. The study confirmed that peripheral neuropathies do occur in the paediatric South African population; the predominance of acquired causes illustrated the multitude of infectious triggers prevalent in the country. The hereditary causes reflected the common groups of CMT but differed in the proportion of children with axonal forms compared to the demyelinating group – specifically CMT1A.

INTRODUCTION

The previous chapters illustrate the range of peripheral neuropathy prevalent in a setting where extensive investigations are possible (chapters 1, 3 and 4). Chapter 2 summarised the optimal method to obtain successful results when performing a nerve biopsy. The following chapter aims to use the preceding information to support analysing a cohort of patients from a relatively resource-limited setting and in different ethnicities from the Australian patients discussed in chapters three and four. In addition inclusion of all patients in this study with chronic peripheral neuropathy, whether they have undergone a nerve biopsy or not, may give more comparable results of the demographics of childhood neuropathies which occur in this setting.

There is no data to clarify the prevalence of peripheral neuropathy, especially chronic cases in the South African context. There is a need to identify primarily which neuropathies are commonly managed, and to establish whether a comparable range of hereditary conditions occur or, if as occurs with other conditions in South Africa, the acquired conditions dominate. This reflects the poor socioeconomic setting where many children have limited access to health facilities, poor nutrition, and frequent infections (e.g. tuberculosis, human immunodeficiency virus and streptococcal infections).

Similarly there are few studies from other parts of Sub-Saharan Africa addressing peripheral neuropathies and none dedicated to hereditary neuropathies in children. A study from Libya reviewed their cohort of patients with neuromuscular disorders and identified that the largest group had forms of CMT followed by AIDP.⁽³⁹⁹⁾ They estimated a population CMT prevalence of 7.9 per 100,000, with CMT1 at 6.4 and CMT2 at 1.5. This study combined paediatric and adult data. A study from Senegal in adults between 20-40 years described “tropical neuropathies” as responsible for half their cases, followed by toxic neuropathies (ethanol and isoniazide), then CMT and finally diabetes.⁽⁴⁰⁰⁾ Another study from the same group quoted that 8.16% of their neurology referrals were related to peripheral neuropathies. The age range screened was 3-80 years, so a proportion of the group were children.⁽⁴⁰¹⁾

Molecular genetic analyses for peripheral neuropathies are limited in South Africa (SA) to screening for CMT1A and hereditary neuropathy with liability to pressure palsies (HNPP). This testing is based in a single centre. Patients from the private sector have the

capacity to send samples abroad but those from the government sector cannot undertake this activity because of the cost implications. Fewer and fewer centres internationally are offering support to resource-limited centres for molecular genetic screens which are viewed as a routine service overseas. Countries such as South Africa are at risk of falling behind in the diagnostic wave of genetic screens identified over the last 10 years alone. There are treatment and management implications necessitating the correct identification of the specific mutations which patients carry.

Neurophysiological studies are limited to a few centres that may not be skilled in performing and interpreting studies on children – this challenges the interpretation of such results.

Pathological samples are rarely assessed further reflecting the limited resources for analysis and interpretations.

The Red Cross Children's Hospital, located in Cape Town, South Africa, is the tertiary paediatric referral hospital for the Western Cape Province (population 5.26 million total; 1.5 million children 0-14 years of age).⁽⁴⁰²⁾ It is the paediatric teaching hospital of the University of Cape Town. The hospital functions as a national referral centre for complex paediatric neurological disorders (population 48 million total; 15.7 million children 0-14 years of age)⁽⁴⁰²⁾ and receives referrals from other countries in Sub-Saharan Africa. The neuromuscular service is supported by competent histopathology and neurophysiology departments. Molecular genetic screens remain limited to CMT1A and HNPP within SA but the service has been supported over the years by other international centres allowing government patients a wider access than would otherwise have been available elsewhere in the country for some of the essential screens. The principal investigator (JMW) operates the neuromuscular service through a weekly clinic. Since the author commenced as head of the paediatric neurology service at the Red Cross Children's Hospital in 2000, all patients have been assessed and followed up by her. The clinic staff include a paediatric neurology consultant, a physiotherapist and a neurology trainee (senior registrar).

Based on patient data collated over the last 9 years (2000-2009), this study plans to review the types of peripheral neuropathies managed in our service, to summarise the forms and sub-forms and to identify key diagnostic markers based on those identified in chapter 1

(tables 1.2 and 1.3) to see how specific a diagnosis the clinician with limited resources can attain.

METHODOLOGY

As part of standard practice a database of all patients managed through the neurology service has been recorded since 2000 by the author (n=3581). This data has provided essential information mainly related to service needs and administrative statistical data to ensure services are not cut. Patients are aware that a short summary of their clinical diagnoses is recorded and this database is invaluable in emergency settings when medical folders are unavailable. Use of this database for the purposes of this study was passed by the ethics committee of the University of Cape Town. From this database, patients with neuromuscular disorders were selected. From this group, a subgroup of patients with chronic peripheral neuropathies was selected. This group was defined by patients with chronic symptomatology requiring regular outpatient follow-up. Patients with acute neuromuscular disorders were not included. These included patients with typical forms of acute inflammatory polyradiculoneuropathy who may have required only one outpatient assessment before deemed fully recovered.

Demographic data were recorded including sex, ancestry (indigenous African, European and *mixed), age, clinical features (degree of disability), interventions, neurophysiological findings, molecular genetic screens and histopathology if performed. Other investigations relevant to the patient were recorded.

Based on these findings patients were divided into two groups – hereditary and acquired, using the diagnostic data in Tables 1.2 and 1.3 as a guide. Peripheral neuropathies were defined according to standard guidelines.^(44,260,278) Particular attention was placed on the findings of two main areas:

1. The sub-divisions of the hereditary group leading to possible or definitive diagnoses
2. The frequency of children with human immunodeficiency type 1 (HIV-1) - related neuropathies, as this condition has such relevance in our context.

Carers gave permission and children assent, for inclusion of their images in the study.

****Mixed** ancestry includes people of predominantly Asian or indigenous Khoi-San descent, who have diverse but not necessarily mixed African / European ancestry*

RESULTS:

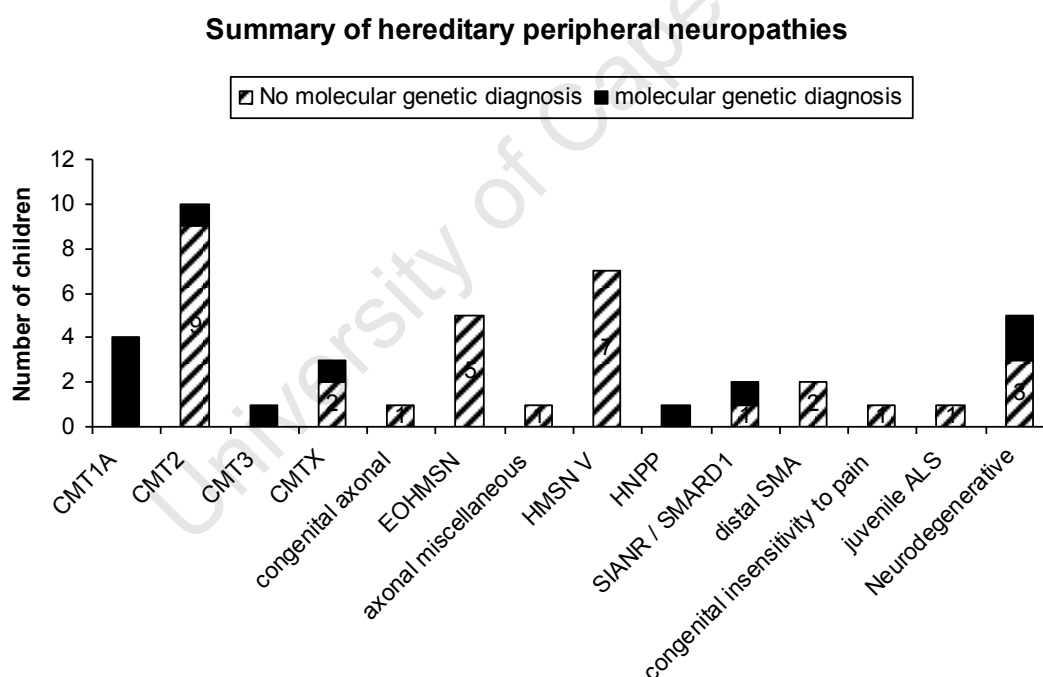
From a database of 3581 children managed in the neurology service between 2000 and 2009, 371 attended the neuromuscular service; of this group 123 carried a diagnosis of peripheral neuropathy. Forty-four children (36%) had hereditary causes for their peripheral neuropathy (Figure 5.1) and 79 were considered to have acquired disorders.

HEREDITARY DISORDERS (n=44)

(25 female: 19 male)

Indigenous African n=10; European descent n=19; mixed n=15)

Figure 5.1



Of the total group, thirty-six patients had axonal pathology; seven demyelinating and one could not be defined. This last patient was categorised in the axonal group based on his clinical presentation. Median age for symptoms to arise was three and a half years of age with a range from 0-10 years. Fifteen children underwent peripheral nerve biopsy – this was either specifically requested as part of their diagnostic screens or performed as an additional investigation whilst undergoing an anaesthetic for other medical purposes (e.g. achilles

tendon releases) (Table 5.1). Fourteen of the fifteen peripheral nerve biopsies identified pathology. Twenty-two children had molecular genetic screens sent for analysis with diagnostic results returned in eleven.

Demyelinating CMT sub-groups n=6

CMT1A (n=4) (3 female: 1 male). Median age at presentation with symptoms was 72 months (range 36-120 months). Two were of European descent and the others were of mixed ancestry. There were no patients of indigenous African origin. Three had a positive family history. All had distal weakness, distal contractures and depressed or abnormal deep tendon reflexes (DTR) (Figure 5.2). One had scoliosis, two had pes cavus and three had sensory alteration. One patient had bilateral hip dysplasia. This complication was considered related to her underlying CMT1A and is described in other children with CMT1A.⁽⁴⁰³⁻⁴⁰⁵⁾ Nerve conduction studies confirmed a demyelinating neuropathy in all based on the motor studies. The sensory nerves could not be stimulated. Median values for motor conduction were median 12.9 metres / second (range 10-18.6 metres / second), ulnar 13.1 metres / second (range 12.6-13.7 metres / second) and common peroneal 8 metres / second. One patient underwent sural nerve biopsy whilst undergoing an anaesthetic for lengthening of her achilles tendon – she had typical features with reduction in her MF density, onion bulb formations and thin myelin (Figure 5.3). Another girl had a nerve biopsy from her index finger digital nerve taken whilst undergoing hand surgery. Her biopsy confirmed reduced myelinated fibre density, thin myelin, a few tomaculous myelinated fibres and multiple onion bulb formations. All patients were genetically confirmed to have CMT1A.

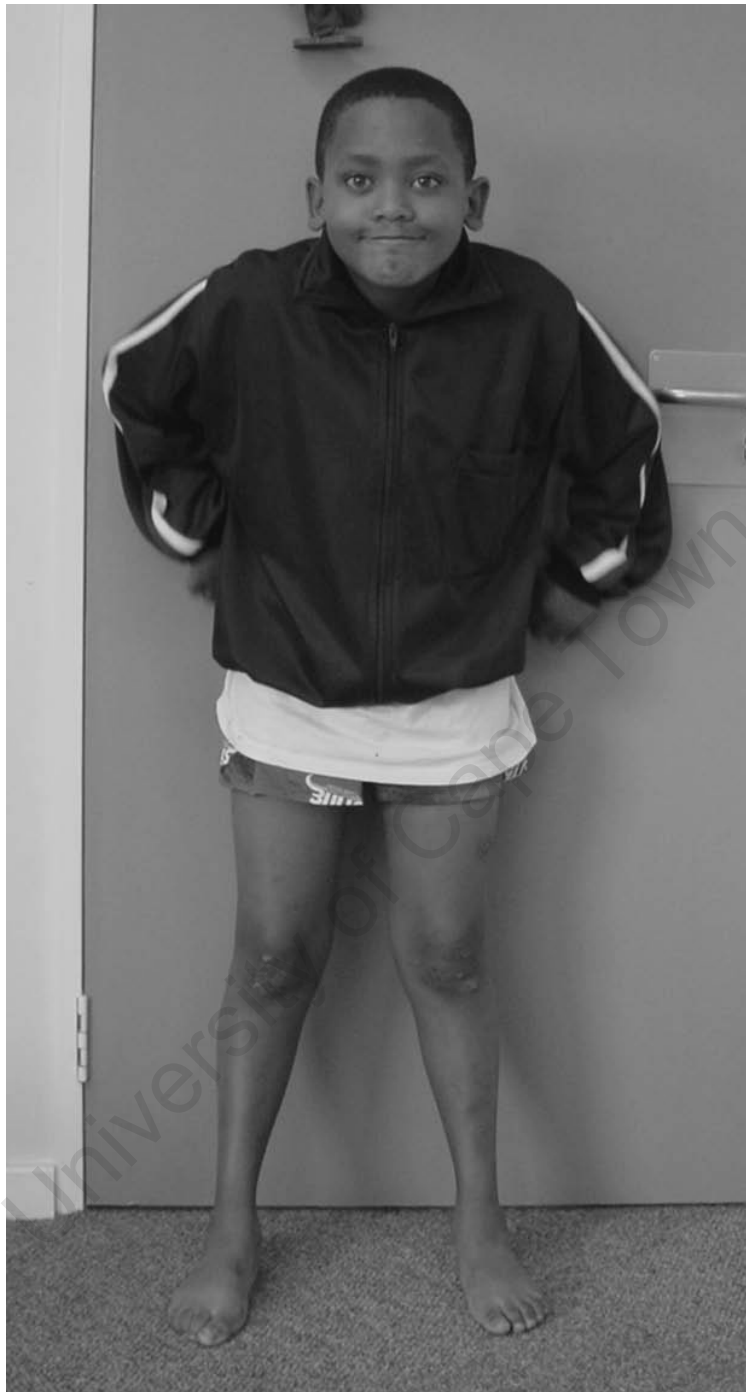

Figure 5.2: Patient with confirmed CMT1A. He has an affected father. Note the typically tapered distal limbs and pes planus.

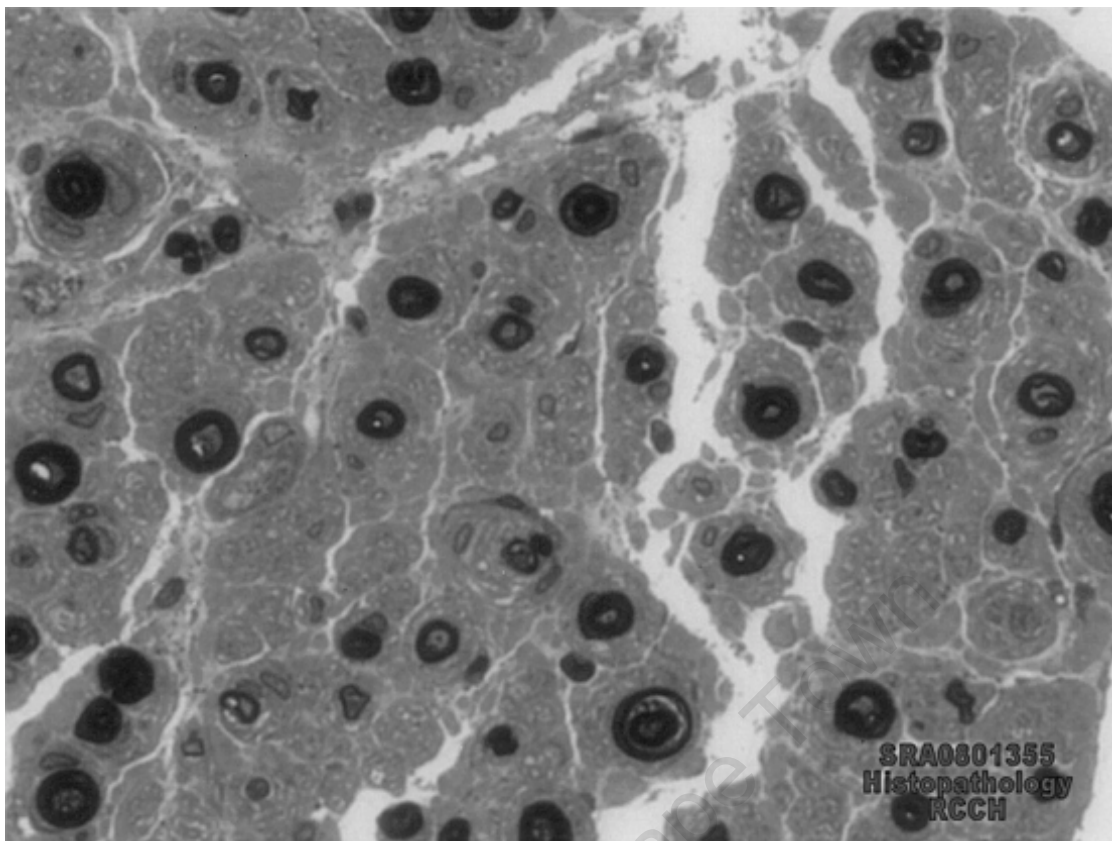


Figure 5.3: Light microscopy toluidine blue stain of the sural nerve from a female patient with confirmed CMT1A (magnification x400). The sample confirmed reduced myelin fibre density, both thinly as well as excessively thick myelinated fibres and occasional onion bulb formations.

CMT3: One female patient (mixed ancestry) presented from birth with profound distal weakness and hypotonia. She developed multiple complications from her disorder with recurrent chest infections, scoliosis and lost ambulation at a young age (Figure 5.4). She underwent several orthopaedic interventions. Despite multiple siblings there were no other affected family members. Her nerve conduction studies failed to stimulate any responses in her motor or sensory nerves. Light microscopy and electron microscopy of her sural nerve biopsy at the age of two years detected multiple onion bulb formations involving every myelinated fibre; her MF density was reduced and there was thinning of her myelin (Figure 5.5). Her teased fibre analysis detected ovoid formations consistent with secondary axonal degeneration. Her electron microscopy examination confirmed multiple onion bulb formations (Figure 5.6). Her muscle biopsy was consistent with denervation. Her molecular genetic

studies suggested CMT1A, but as this result was conflicting with her phenotype, she was categorised CMT3 based on her clinical, neurophysiological and histopathological findings.

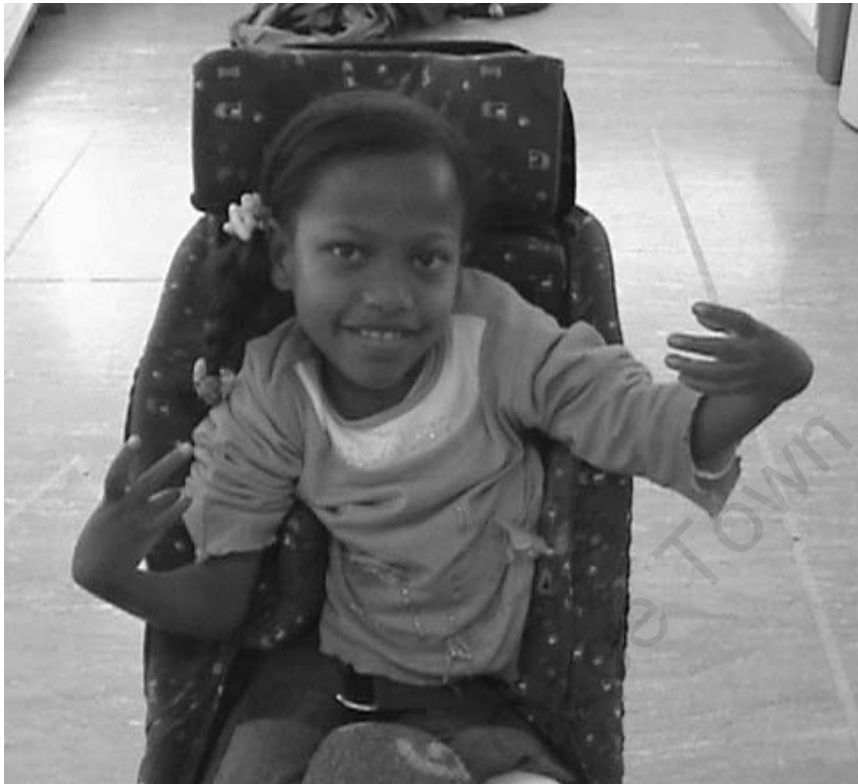

Figure 5.4. Affected patient with CMT3 phenotype at the age of eight years demonstrating her non-ambulant state and the severe distal involvement with ulnar deviation and clawed hands as well as a scoliosis.

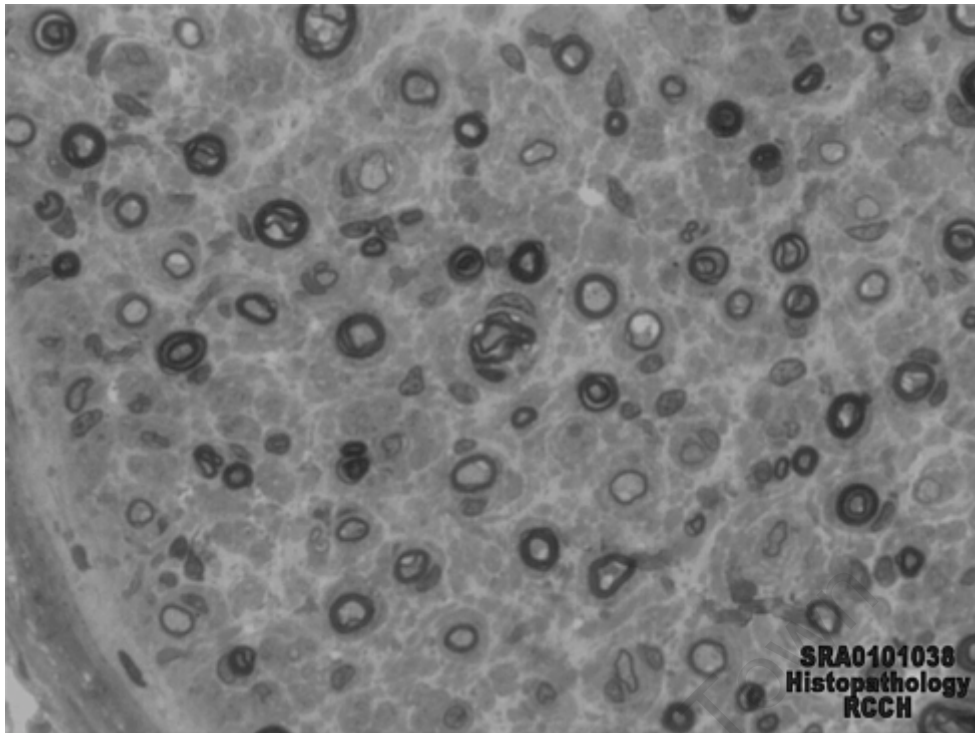


Figure 5.5: Light microscopy toluidine blue stain of the sural nerve from the patient with clinical phenotype of CMT3 but molecular genetic diagnosis of CMT1A. The sample confirmed a moderate reduction in myelinated fibre density, many thinly myelinated fibres and multiple onion bulb formations. (Magnification x400)

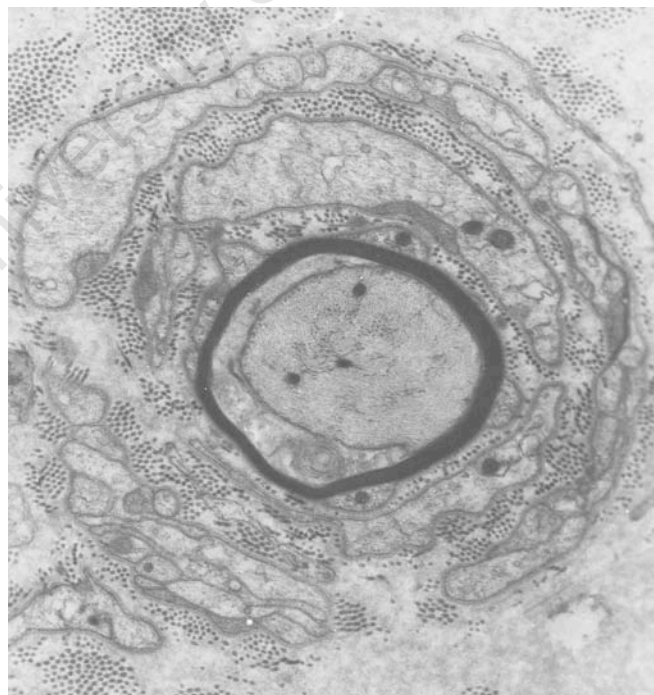


Figure 5.6. Electron microscopy appearance from the same patient with CMT3 demonstrating an onion bulb formation. (Magnification x20000)

Hereditary neuropathy with liability to pressure palsies (HNPP) (n=1) One female patient of indigenous African descent presented aged 2 years with frequent falls and proximal weakness. She had wasting of her thenar and hypothenar eminences, contractures of her achilles tendons, sensory loss, and depressed DTR. She did not have a history of intermittent palsies. She did not have any other affected family members. Due to her proximal weakness she was suspected to have a myopathy, although her creatine kinase was normal and her genetic screen for Spinal Muscular Atrophy was negative. She underwent a muscle biopsy which suggested neurogenic disease with evidence of denervation. Her nerve conduction studies confirmed absent sensory potentials and very delayed median distal latency and conduction velocity. Similarly, the common peroneal velocity was very slow with a reduced amplitude and her posterior tibial response was absent. Repeat study 5 years later detected a median conduction velocity of 13.9 metres / second. Her molecular genetic screens were negative for CMT1A but confirmed the deletion in the region consistent with HNPP. Her clinical phenotype is a little unusual but without a nerve biopsy, which might have shown tomaculous changes, confirmation of the genetic diagnosis could not be taken further. The family were hesitant to proceed to biopsy as it would not alter her direct management.

Axonal CMT sub-types n=32

CMT2: (n=10) (5 female: 5 male). Median age at onset of symptoms was 60 months (range 0-120 months). Five were of mixed ancestry and five of European descent. Family history was positive in six patients and correlated with an autosomal dominant pattern of inheritance. All presented with distal weakness, in addition to distal contractures (n=8), hypotonia (n=1), scoliosis (n=2), sensory loss (n=6), pes cavus (n=3) and depressed or absent DTR (n=5) (Figure 5.7). Unusual features included learning difficulties (n=2) and congenital equinus foot deformities (n=1). Nerve conduction studies were consistent with axonal pathology in all with reduced amplitudes and normal (n=6) or mildly slowed common peroneal conduction velocities (n=4 range 32.2-36.8 metres / second), sensory studies were abnormal in four patients. Two patients underwent sural nerve biopsy. One sural nerve biopsy was within normal limits in a patient with a clinical phenotype consistent with a peripheral neuropathy and abnormal nerve conduction studies. The other biopsy was from a male patient

who was symptomatic from 5 years of age; his father was affected with the same condition. His sensory studies were abnormal. His motor studies confirmed reduced amplitudes and prolonged distal latencies with conduction velocities of 39.7m/s for the median nerve and 36.8m/s for the common peroneal nerve. His sural nerve biopsy detected major axonal degeneration involving both myelinated fibres and unmyelinated fibres, with Bands of Büngner typical of an axonal degenerative and regenerative process; there were no onion bulb formations or abnormally thinned myelinated fibres (Figure 5.8). His molecular genetic screen detected CMT1A, and was duplicated on his repeat study in the same laboratory. In the light of his phenotype not concurring with this genetic diagnosis there remains some conflict as to his correct category.



Figure 5.7: Appearance of hands from affected father and son with CMT2. Note the progression with the father's phenotype more marked than his 12 year old son.

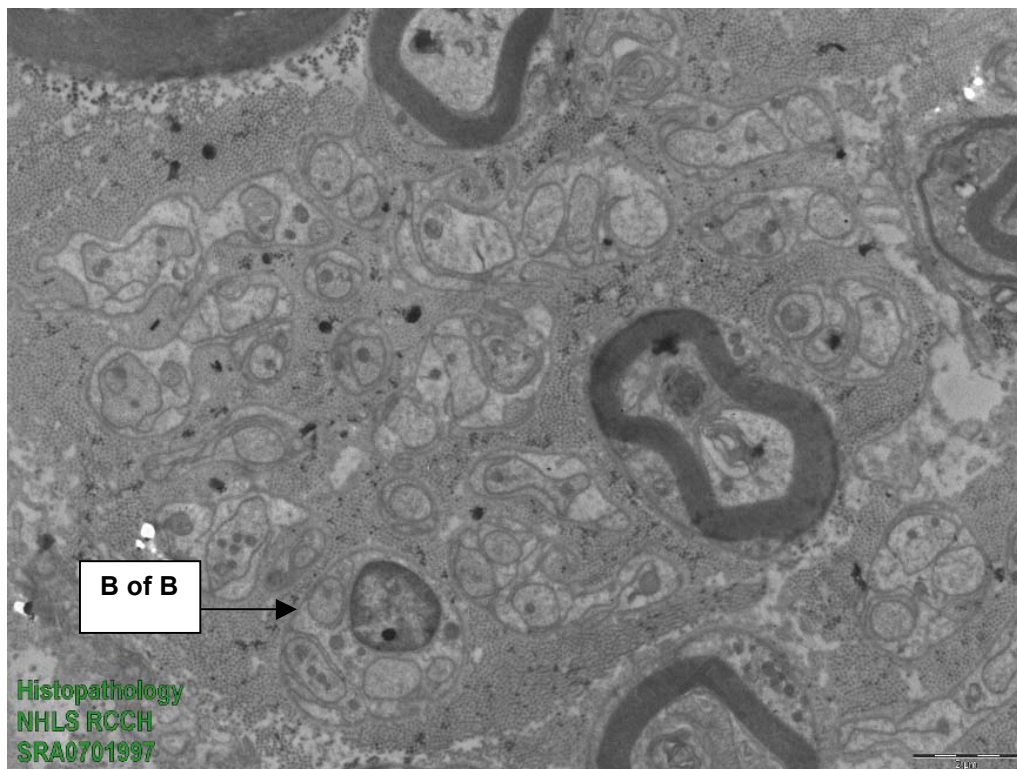


Figure 5.8: Electron microscopy appearance from the patient with neurophysiological findings consistent with an axonal process but with a molecular genetic diagnosis of CMT1A. (Magnification x3000) The sample demonstrates reduced myelinated fibre density, adequate myelin thickness in the remaining fibres, axonal degeneration and numerous unmyelinated fibres, of which one group associated with a Schwann cell nucleus would be consistent with a Band of Büngner (B of B).

Early onset neuronal hereditary motor sensory neuropathy (EOHMSN) (n=5). All children were female: two were of indigenous African descent, two were of mixed ancestry and one was of European ancestry. They presented between two and five and a half years of age (median three years) with severe progressive disability. One underwent ten orthopaedic surgical interventions (Figure 5.9). They required significant support at school as they were limited for independent functions and in their activities of daily living. Clinical features consisted of distal contractures (n=5), ataxia (n=1), hypotonia (n=3), scoliosis (n=2), distal weakness (n=5), additional proximal weakness (n=2), sensory loss (n=4), pes cavus (n=2) and absent DTR (n=3) (Figure 5.10 a and b). The child who presented from 2 years of age

had additional cognitive learning disabilities. She had a rapidly progressive course and aged 13 years was wheel-chair dependent with marked limitations in her activities of daily living. Their nerve conduction studies revealed abnormal sensory studies (n=4) and markedly reduced amplitudes and distal latencies with conduction velocities in the demyelinating (n=2), axonal (n=1) and normal (n=1) range. One patient had absent responses. Sural nerve biopsy performed in four confirmed active axonal degeneration, reduction in the myelinated fibre density and one patient in addition had onion bulb formations detected (Figures 5.11, 5.12a and b). Abnormal mitochondrial aggregations were detected in one of the patients (Figure 5.13). One family considered mitofusin analysis but the cost was too great for them and the child's DNA remains stored. Another child was negative for CMT1A mutation.

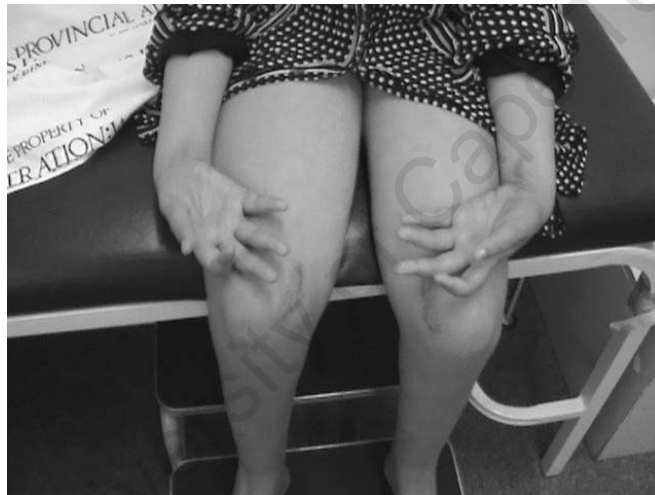
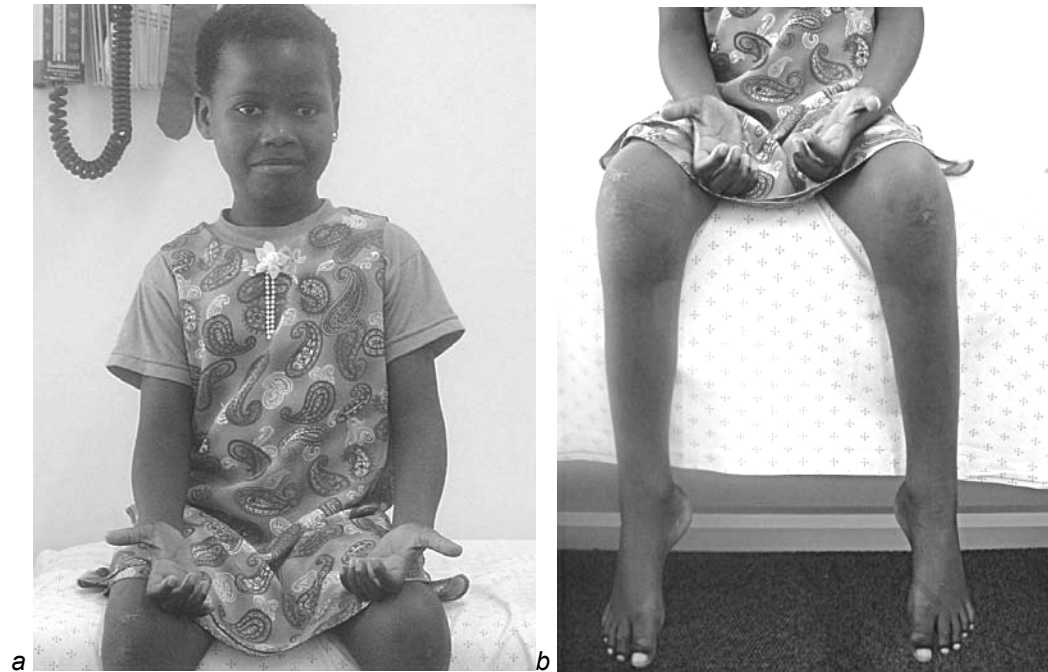
Figure 5.9: Clinical phenotype of patient with EOHMSN. Distal wasting is evident as well as contracture formations and evidence of multiple surgical interventions.



Figures 5.10 (a and b). Clinical phenotype of the other patient with EOHMSN with extreme distal wasting.

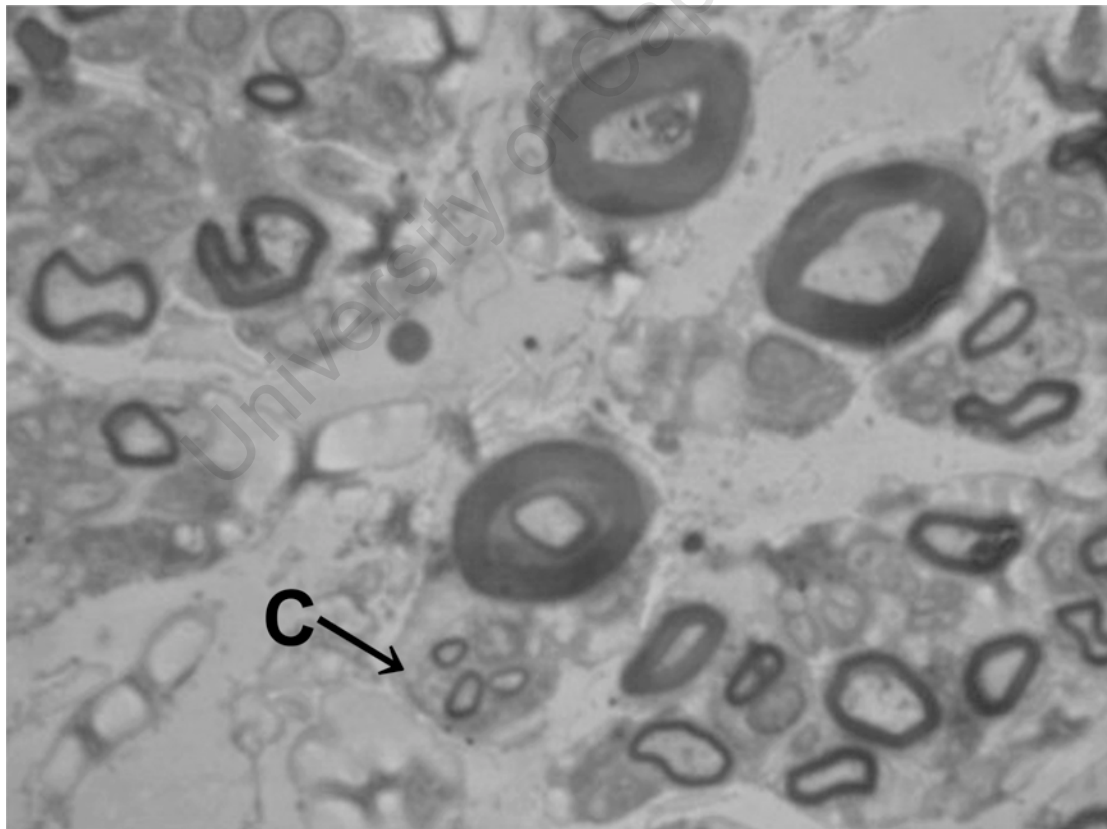


Figure 5.11: Light microscopy appearance (toluidine blue stain, magnification x400) from the patient in Figure 5.9, demonstrating reduced myelinated fibre density and cluster formation (C).

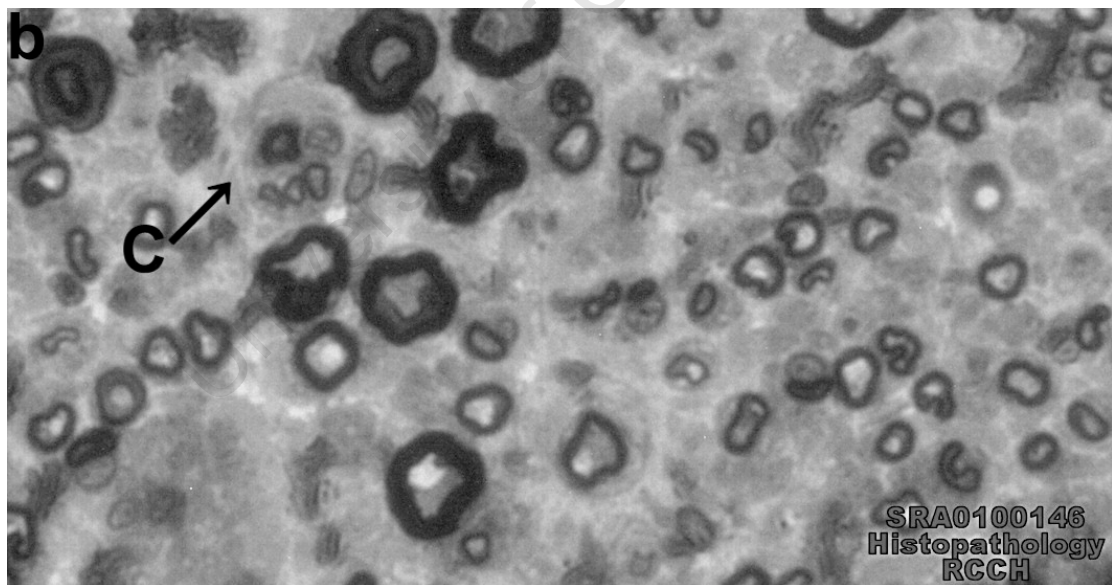
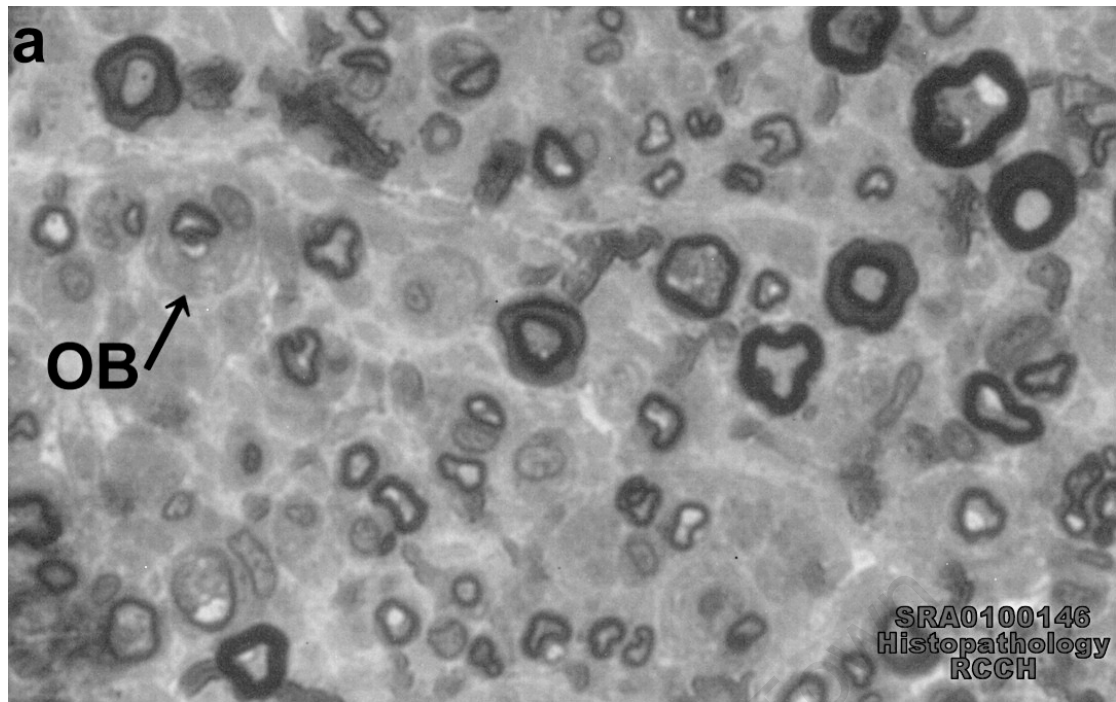


Figure 5.12 (parts a and b): Light microscopy of appearance of the sural nerve from the second patient (Figure 5.10) demonstrating reduced myelinated fibre density, onion bulb formation (OB) (figure 5.12a) and cluster formation (C) (Figure 5.12b, (magnification x400).

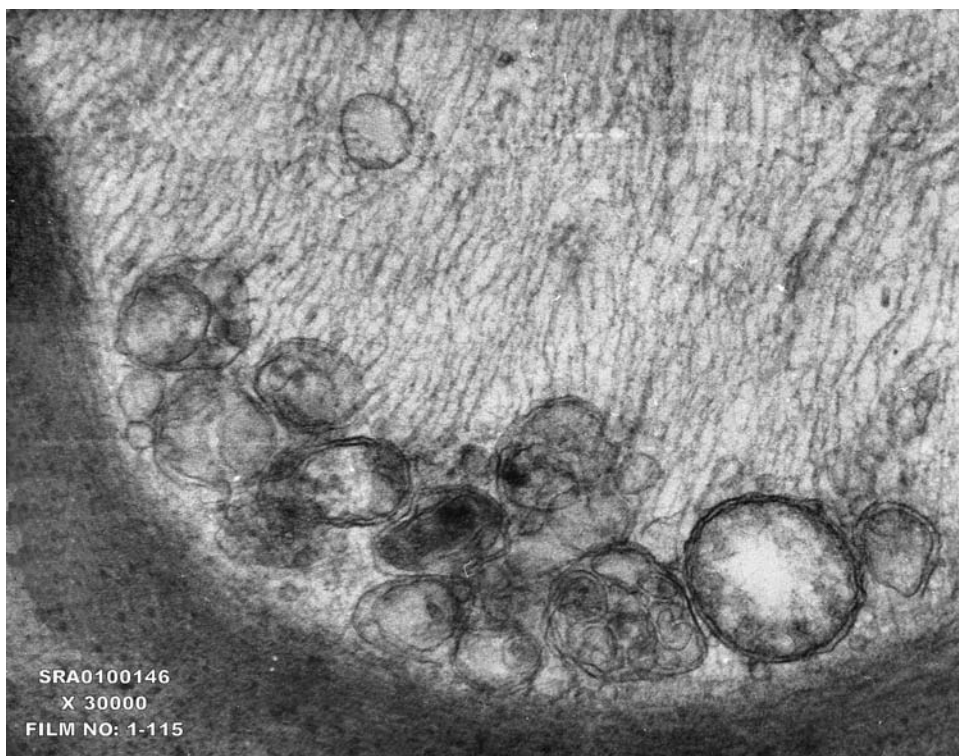


Figure 5.13: Electron microscopy from the patient in Figure 5.10 demonstrating abnormal mitochondrial aggregations at the periphery of the axon. (Magnification x30000)

Congenital axonal neuropathy (n=1) This female child of mixed ancestry was born to well parents with extreme hypotonia evident from birth. She had some respiratory compromise but did not require ventilation and had no diaphragmatic involvement. She had dislocated hips at birth. She stabilised and gradually appeared to improve; she clearly had marked distal weakness in addition to her generalised condition. By 17 months of age she was standing and climbing, she remained of very small build, with her mouth open and drooling. Her nerve conduction studies aged one year revealed normal sensory ulnar studies and absent sural responses. Her common peroneal distal latency was delayed, with a reduced amplitude of 0.5mv, and normal conduction velocity, her posterior tibial conduction velocity was 24 metres / second, amplitude 4mV, distal latency mildly delayed at 2.88ms. Her ulnar responses were normal. These findings were considered consistent with an axonal process. Her phenotype is similar to the patients with arthrogyrosis multiplex congenital (AMC) who improved with time, although those patients had hypomyelinating disorders.^(406,407) Patients with axonal disease associated with AMC are described.^(2,408,409)

Axonal miscellaneous: One girl of European descent presented in her first decade with scoliosis (Figure 5.14 a and b). Her family had noted an altered gait since she was 13 months of age. Despite this she had functioned well participating in school sports and only became limited when she developed her scoliosis. This was aggressive and of rapid onset. The curvature became so marked that within 2 years she had developed a respiratory restrictive defect and was hypoventilating. Magnetic resonance imaging (MRI) of her spine identified a tethered cord. This was released but the scoliosis persisted. Spinal rods were inserted with excellent results allowing her to return to her previous level of functioning with limited and slow progression over the last 2 years. Her clinical phenotype has remained a challenge to categorise. She had distal contractures, distal weakness, sensory alteration, depressed DTR, pes cavus, and swallowing difficulties. She also had a tendency to bleed and bruise easily but an extended screen of her bleeding function was normal. Her nerve conduction studies detected normal sensory values. Her motor studies recorded delayed motor conduction (44.3 metres / second common peroneal), reduced amplitudes and distal latencies suggestive of axonal disease. Muscle biopsy identified evidence of a neurogenic process on the muscle screen. Her sural nerve biopsy was normal. This girl appears to have an axonal process predominantly affecting her motor nerves. The combination with scoliosis and swallowing difficulties overlap CMT2C and distal hereditary motor neuropathy type VII

(dHMN)^(91,178,179,410,411).

Figure 5.14a

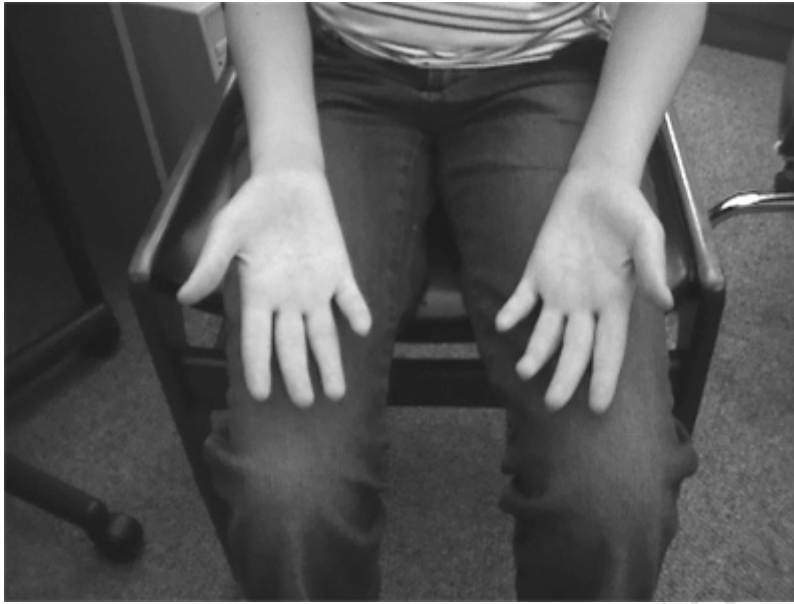

Figure 5.14b



Figure 5.14 parts a and b. Appearance of the girl with miscellaneous axonal disease. She had wasting of her thenar and hypothenar eminences (a) as well as high arches and wasted extensor digitorum brevis (b).

SIANR (severe infantile axonal neuropathy with respiratory failure) / SMARD1

(spinal muscular atrophy with respiratory distress type 1) (n=2) One male infant of European descent presented aged 3 months with a typical phenotype of SIANR (Figure 5.15).⁽¹⁰⁶⁾ His genetic testing confirmed the *IGHMBP2* mutation.⁽¹⁰⁸⁾ He had a paralysed diaphragm, no movement in his lower limbs and marked weakness distally in his upper limbs. He had features of autonomic dysfunction. He was discharged on a home ventilation programme. Aged 4 years he was cognitively intact and his family were planning his school placement. The second child was a female of mixed ancestry who presented aged 3 years with a paretic hemidiaphragm which was initially managed with a Nissen's fundoplication intervention (Figure 5.16 and 5.17). When her respiratory dysfunction persisted, she was referred to a respiratory specialist who noted diaphragmatic dysfunction and in addition distal weakness and a myopathic facies. Her respiratory compromise increased such that she started nocturnal ventilation from 5 years of age. Her clinical state slowly deteriorated with ongoing distal weakness limiting (but not stopping) ambulation. She developed a marked scoliosis but did well following spinal surgery. Aged 13 years she continues to perform well at school and remains ambulant (except for long distances) and dependent on intermittent ventilation. Her nerve conduction studies recorded normal sensory potentials and delayed motor conduction velocities (common peroneal 43 metres / second) with reduced amplitudes (1.5mv). Her sural nerve biopsy detected axonal degeneration with preservation of the myelinated fibre density. Her phenotype is similar to that described in a juvenile form of SMARD1⁽³²⁷⁾ but her genetic screens did not detect the typical *IGHMBP2* mutation. Extended screens from her and her family for possible point mutations are being analysed, courtesy of Professor Christof Hübner, in Germany. Other conditions with such diaphragmatic involvement and axonal disease would include distal HMN type IV.^(169,174,175)



Figure 5.15: Patient with SIANR genetically confirmed to have SMARD1 mutation aged 9 months. He had limited head control and shoulder movements and no voluntary movements in his distal upper limbs or lower limbs. He was completely ventilator dependent.



Figure 5.16: Patient with the juvenile form of SIANR demonstrating her distal wasting. She was ventilator dependent intermittently in the day and during sleep.

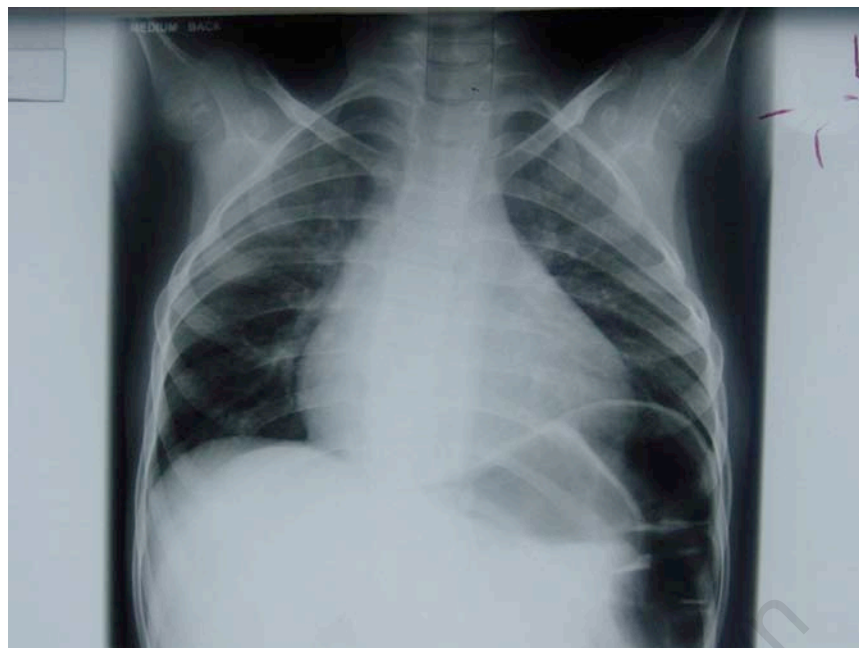


Figure 5.17: Chest X-ray from the patient with juvenile SIANR demonstrating an elevated left hemidiaphragm.

Distal SMA / Hereditary Motor Neuropathy (HMN) (n=2). Twin boys of Indigenous African ancestry presented aged four years with progressively abnormal gaits. They had distal weakness, contractures and reduced DTR. They had learning difficulties from the onset but appeared to have cognitive regression with time. Their greatest complaint was progressive deterioration in their vision associated with optic atrophy. They were both non-ambulant by 15 years of age. Metabolic and mitochondrial screens were unremarkable, magnetic resonance imaging of one of their brains was normal. Nerve conduction studies detected normal sensory potentials, but the motor responses could not be stimulated, EMG detected fibrillations suggestive of denervation. A predominantly motor axonal process was suspected. Their VEP was abnormal, but ERG was within normal limits. Sural nerve biopsy detected axonal degeneration with no abnormal storage material. These boys had a neurodegenerative disorder but their major disability related to their peripheral neuropathy and optic atrophy. Conditions with these aspects and the cognitive involvement would include CMTX5 (deafness has not been excluded in them)^(143,148,149), CMT2A / HMSN VI (this would not explain their cognitive decline but the associated mitofusin mutation linked with mitochondrial dysfunction

could be relevant)^(75,77,252) and CMTX4 (but the lack of clinical sensory involvement limits this)⁽¹⁴²⁾.

CMT5 (n=7) Four female and three male children had the clinical phenotype of CMT5, five were of European ancestry, one was of mixed descent and one was of indigenous African ancestry. Onset was from birth in two who had increased tone and abnormal foot posture. The remainder presented between nine months and seven years of age (median five years). The seven year old child had long standing “odd feet” noted by her parents before she started to complain of pain in her feet and was investigated. One of the children with symptoms from birth was labelled “spastic quadriplegic cerebral palsy”. She was non-ambulant and attending a special school for children with motor and cognitive deficits. She was always considered cognitively intact in comparison to her motor disability. Her mother became concerned when she realised her daughter’s disability was progressive. Following confirmation of the diagnosis CMT5 her mother transferred her to mainstream education where she is doing well with some special support. All children had distal weakness, associated in some cases with distal contractures (n=5), brisk DTR (n=6), scoliosis (n=1), hypotonia (n=1), sensory alteration (n=3), pes cavus (n=2), and more generalised weakness (n=1). Six children were cognitively intact and one had mild learning difficulties. One had a positive family history of autosomal dominant inheritance pattern. Nerve conduction studies detected abnormal sensory conduction (n=2) and moderately delayed conduction velocities with a median common peroneal value of 36.9 metres / second (range 34.0-39.1 metres / second) with reduced CMAP amplitudes and delayed distal latencies. The picture was axonal though approaching the **intermediate range** suggestive of a possible mixed picture.⁽¹⁵⁰⁾ None of the children underwent sural nerve biopsy and molecular genetic testing was not available.

CMTX: (n=3) Three male children presented with features compatible with forms of CMTX, two were of European descent and one was of mixed ancestry. They developed symptoms when aged 18 months, 5 years and 10 years. All had a positive family history with mildly affected mothers and clinically affected male relatives through the maternal side. Clinical features consisted of distal weakness (n=3), additional generalised weakness in one (n=1), distal contractures (n=2), hypotonia (n=2), scoliosis (n=1), sensory alteration (n=2), and depressed DTR (n=2). The youngest patient to present at 18 months had a relatively mild

course with dysmorphic features and in addition some learning difficulties. He failed to attend for further investigations or follow up but may have complied with the **CMTX2** sub-group.⁽¹⁴⁶⁾ The absence of neurophysiological and nerve biopsy data limited categorising him, however his clinical phenotype complied with an axonal or mixed disorder (CMTX). The oldest boy who presented at 10 years of age complained of gait disability. His maternal uncle was examined and had a typical phenotype of a peripheral neuropathy for which he had undergone multiple orthopaedic interventions. His nephew had mild distal weakness and abnormal nerve conduction studies compatible with an axonal process. However his predominant complication was dystonia which progressed and eventually rendered him non-ambulant. Molecular genetic screen confirmed a *DYT1* mutation. The last boy who presented aged 5 years had typical features of CMT, with an extensive affected family tree. His nerve conduction studies recorded conduction velocities of 28.9 metres / second from the common peroneal nerve and 32.1 metres / second from the median nerve with reduced CMAP amplitudes. His picture was compatible with intermediate conduction velocities and if he had undergone a biopsy a mixed picture may have been seen. He and his family underwent molecular genetic screening overseas and were found to be negative for *MPZ*, *connexin 32* mutation, *PMP22* duplication and deletion as well as point mutations.

Congenital insensitivity to pain (n=1). One male child of indigenous African descent presented with symptoms from birth of apparent lack of pain awareness. He was dysmorphic with mental retardation; he was not weak but did have multiple scars from old injuries. He was unaware of pain or temperature. He did not appear to have autonomic dysfunction with normal blood pressure, sweating, salivation and tear production. His mother could only discipline him through throwing water at him. His nerve conduction studies were normal. Genetic screening was negative for Smith Magenis syndrome. He defaulted before sural nerve biopsy could be taken – a small unmyelinated fibre disorder could not be excluded without biopsy material and his phenotype could be compatible with **hereditary sensory neuropathy type 2**.⁽²¹³⁾ Another child, of mixed ancestry, presented with a similar phenotype of apparent insensitivity to pain at 2 years of age. His parents related his lack of response to numerous painful stimuli including being bitten by the family dog. He apparently felt no pain but bit the dog back. His power was normal, he had retained DTRs and he could sweat

normally. He had old injuries mainly from burns on his hands and a scar from the dog bite on his face. His nerve conduction studies were normal. His sural nerve biopsy was normal both on light microscopy examination of his small and large myelinated fibres and electron microscopy screening of his unmyelinated fibres. In addition his skin and muscle biopsies were unremarkable. He improved with time becoming conscious of noxious stimuli such as burns. By 10 years of age had mild learning difficulties and attention deficit hyperactivity disorder.

Neurodegenerative disorders (n=6)

One female patient of indigenous African descent was managed long term for liver cirrhosis of unknown origin (she was jaundiced from birth). She required a liver transplant but her social circumstances precluded this. Aged 6 years she developed altered vision (especially at night) and gait impairment (foot drop). She had progressive learning difficulties, external ophthalmoplegia, ptosis, depressed DTR and night blindness. She lost ambulation aged 10 years. Her vitamin E levels were extremely low at 0.17mg/l (normal range 4.22-16.8 mg/l) but replacement therapy did not improve her clinical state. Her nerve conduction studies detected normal sural potentials and common peroneal values delayed at 41.9m/s suggestive of an axonal process. Her muscle biopsy detected atypical clustering of mitochondria, grouping of type 1 fibres, hypertrophy of type 2, with some degeneration and necrosis; these findings were consistent with vitamin e deficiency. Her mitochondrial screens were unremarkable. Her muscle biopsy was thought compatible with **AVED (familial vitamin E deficiency)** but her phenotype was clearly more complex and likely to be part of another neurodegenerative disorder.^(228,229)

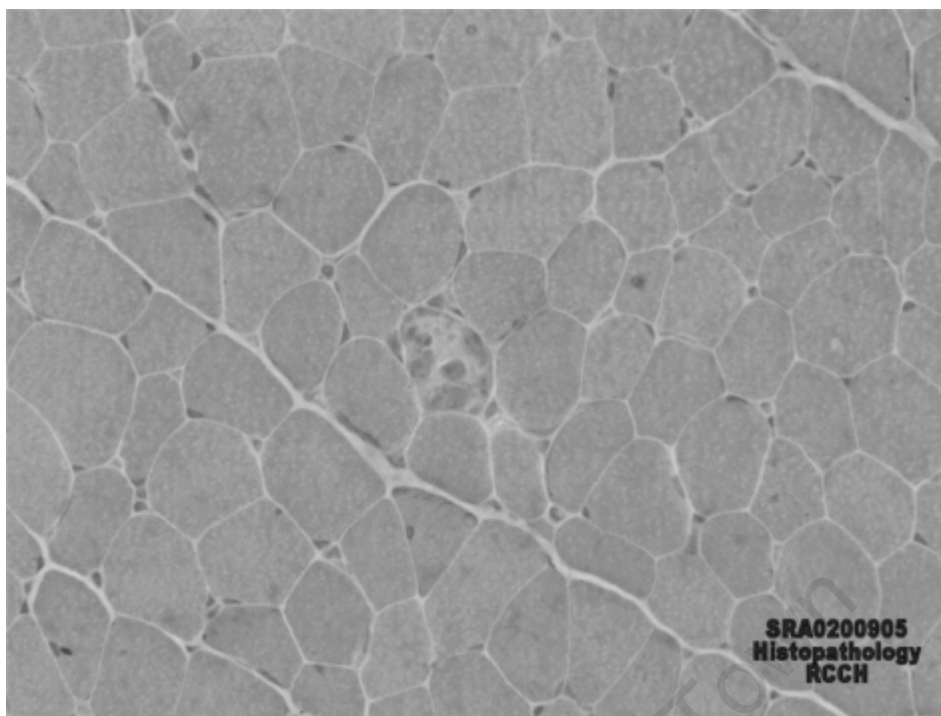


Figure 5.18. Muscle biopsy Gomori immunohistochemical stain from the patient with Vitamin E deficiency demonstrating atypical clustering of mitochondria. (Magnification x200)

A male patient of indigenous African ancestry presented at six months of age with a slowly progressive degenerative disorder. He had mental retardation, was ataxic and had optic atrophy. His power was globally reduced and his DTRs were brisk. He evolved dystonic posturing and by 14 years of age was noted to have distal contractures and was weak in his distal regions. His nerve conduction studies were previously normal. They were repeated and revealed common peroneal conduction velocities of 49.5 metres / second, with his amplitude reduced at 1.8 mV and distal latencies of 2.6 ms and absent posterior tibial responses. His sensory studies remained normal. His findings were consistent with an axonal degenerative process. His CSF protein was normal, but his CSF lactate on two separate occasions was raised at 15.6 and 15.8 mmol/l. Magnetic resonance imaging of his brain detected a leucoencephalopathy. His mitochondrial screens were negative for MELAS (A8344G, A3243G and T3271C), Leigh (T8993G and T9176C) and NARP (T3993C). Despite these negative results he was considered most likely to have an underlying **mitochondrial disorder**.

Another male patient of European descent was known to have hypotonia and developmental delay evident from birth. He was initially considered to have hypotonic cerebral palsy but with time his distal weakness became marked with contractures managed with

botulinum injections and surgical intervention. He had failure to thrive, short stature, ataxia, retinitis pigmentosa, scoliosis, depressed DTR, pes cavus, sensory alteration and wizened facies. He developed a corneal pannus. His BSAER, VEP and ERG were abnormal. His nerve conduction studies recorded normal sensory potentials, whilst his motor studies recorded common peroneal conduction velocities of 10m/s, with an amplitude of 1.5mV; median conduction velocity of 13m/s, amplitude 3.8mV and ulnar conduction velocity 19m/s and amplitude 1.3mV, consistent with a demyelinating process. His genetic studies confirmed **Cockayne syndrome.**⁽²⁹⁵⁾

The next male patient of indigenous African descent had hypotonia from birth. His sibling died some years previously and was described as having an identical phenotype to him. Aged 2 years he was dysmorphic with tapered fingers, triangular facies, small build. He held his mouth open drooling, had intermittent strabismus, and woolly hair. He had distal weakness and depressed DTR. His nerve conduction studies detected borderline low sensory potentials, whilst his motor studies recorded common peroneal amplitude reduced at 1.83mV, distal latency delayed at 3.52ms, and delayed conduction velocities of 42.7m/s; his median amplitude was normal but his distal latency was delayed at 2.62ms with conduction velocity of 46.4m/s. His EMG recorded occasional positive waves. He was thought to have a neurodegenerative axonal disorder and his phenotype was similar to **Giant Axonal Neuropathy (GAN).**^(224,225)

A female patient of mixed ancestry presented at four years of age with a rapidly progressive ataxic disorder compromising her activities of daily living. She was hypotonic, with distal weakness, absent knee DTRs and extensor plantar responses. She developed a marked scoliosis requiring intervention with spinal rod surgery at 10 years of age. Magnetic resonance imaging of her brain was normal, as were her cardiac and ophthalmological examinations. Her sensory and motor neurophysiology studies were abnormal. Her common peroneal motor conduction velocity was 25.2 metres / second, the amplitude 4.83 mV and the distal latency 6.88 ms. Her posterior tibial conduction velocity was 36.6 metres / second, amplitude 7.83 mV and distal latency 6.3 ms, and her median conduction velocity was 49.2 metres / second, amplitude 12.8 mV and distal latency 3.44ms. Molecular genetic

investigations confirmed a large triplicate repeat consistent with a diagnosis of **Friedreich ataxia (FA)**. She remains relatively stable on maintenance idebenone therapy.

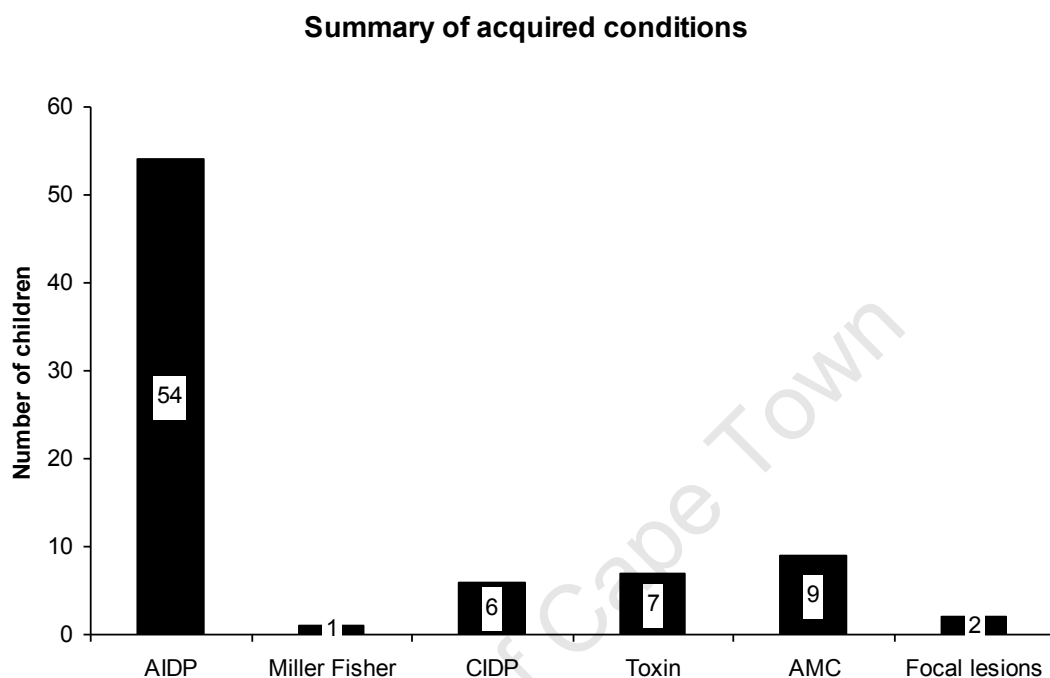
The last male patient of European descent (Portuguese parents) had a history of craniosynostosis which was corrected surgically in infancy. He re-presented aged 10 years complaining initially of having difficulties controlling his left foot whilst playing football. This seemed to stabilise but was followed by rapid asymmetrical upper limb weakness. He had extreme loss of power initially distally then with proximal progression and winging of his scapulae became evident. Five years into his illness his speech became nasal and he had evidence of tongue fibrillations. His DTR were initially depressed, became brisk in the lower limbs and then, seven years into his illness, became depressed again. His cognition was preserved throughout. Eight years into his illness he had more involvement of his lower limbs though his predominant site of weakness was in his upper limbs. MRI of his brain and spine detected hydromyelia from T5-9, and mild cerebral and cerebellar atrophy. The spinal pathology would not explain his marked upper limb involvement. His nerve conduction studies detected normal sensory potentials, whilst his motor studies revealed absent common peroneal responses. His posterior tibial conduction velocities were normal at 47m/s with amplitudes of 5.33 mV and distal latency of 3.72ms. His EMG recorded denervation. His sural nerve biopsy at 10 years of age confirmed axonal degeneration with relatively preservation of myelinated fibres. His muscle biopsy detected denervation. His diagnosis is not finalised, his molecular genetic screens were negative for *MPZ* mutation and *SMN* deletion, with his *SOD1* mutation outstanding but considered unlikely to be diagnostic. Testing for *senataxin* mutations was not available.^(412,413) He clinically complies with a sub-type of **amyotrophic lateral sclerosis – ALS4** (allelic to dHMN).^(181-183,183,414) He was originally considered to have Hirayama's syndrome but his lower limb involvement made this unlikely. However this condition does have overlap with motor neurone disease described.⁽⁴¹⁵⁻⁴¹⁹⁾ Other differential diagnoses considered were CMT2D which has predominantly upper limb involvement^(92,93), CMT2H since it has pyramidal involvement described⁽⁷¹⁾ and CMT2K which has vocal cord involvement with a severe early onset^(99,100). These forms of CMT cannot be completely excluded but his combined features remain more consistent with ALS4.

ACQUIRED (n=79)

(34 female: 45 male)

(40 indigenous Africa; 6 European; 33 mixed ancestries)

Figure 5.19



This group was dominated by patients with **AIDP** (n=54), axonal forms predominated and were often secondary to *Mycoplasma* or *Campylobacter* infections. Median age of presentation was 40 months (range 8 months – 12 years) and duration of admission was 30 days (range 2 – 220 days). A proportion of the children were admitted for several months with their monophasic illness requiring ventilation support and tracheostomy (n=18). All eventually weaned off their tracheostomies with full respiratory recovery but minimal foot drop was typically seen up to a year post presentation. One patient had a phenotype of Miller Fisher syndrome. In six patients the features were compatible with CIDP with relapsing pattern of illness.

Nine patients had forms of **arthrogryposis multiplex congenita**, most were syndromic with multiple pathologies, three were described previously for their unusual focal amyoplasia in the context of normal intelligence, lack of progression and apparent perinatally acquired pathology.⁽⁴²⁰⁾ Peripheral nerve involvement was suspected in these patients based on their clinical phenotype of hypotonia, weakness and contracture, but additional mixed

pathologies with muscle and anterior horn cell involvement could not be excluded. Further since definitive diagnoses were lacking in these patients with congenital disorders, a hereditary cause could not be completely excluded. The lack of a positive family history was one of the supporting factors towards acquired causes.

Seven children had **toxin** related neuropathies, five children related to HAART medication for HIV-1 infection, one related to dapsone therapy and one to vincristine therapy. The last child was a girl of European descent who was being treated for acute lymphocytic leukaemia. At 6 years of age she developed significant hypersensitivity symptoms affecting her palmar hand surfaces and the plantar surfaces of her feet. Her sensory neurophysiological studies were normal. Her median conduction velocities were 51.4 metres / second, amplitude 2.33 mV and distal latency 3.88ms; her common peroneal conduction velocity was 57 metres / second, amplitude reduced at 1.67 mV and distal latency delayed at 5.52 ms. Her results were consistent with an axonal degenerative disorder. Her vincristine dosage was reduced and she clinically improved.

Five children with HIV-1 infection developed peripheral neuropathies (3 female :2 male, all were of indigenous African ancestry). Median age of presentation was 5 years (range 42-139 months). All children were receiving HAART (highly active antiretroviral therapy) medication which included stavudine (d4T) in their regimens. Conversion to zidovudine or abacavir resulted in clinical improvement (n=4). One patient spontaneously improved. Additional therapy with gabapentin was administered in three. Children presented with distal wasting (n=5), distal weakness (n=5), ataxia (n=1) and severe distal pain (n=3) (Figure 5.20a and b). All children were under weight for age with a globally wasted appearance. This tended to mask the degree to which the neuropathy was clinically evident. Two of the children also had evidence of lipodystrophy / lipoatrophy syndrome with transiently raised plasma lactate levels. One child had prior co-infection with tuberculous meningitis; she was treated with 9 months of standard therapy including isoniazid. She had not received pyridoxine prophylaxis. Another child was covered with isoniazid prophylaxis which included pyridoxine therapy. Nerve conduction studies were normal in one, could not be stimulated in another and revealed an axonal degenerative process in three whose common peroneal conduction velocities were between 36.9 and 44.2 metres / second.

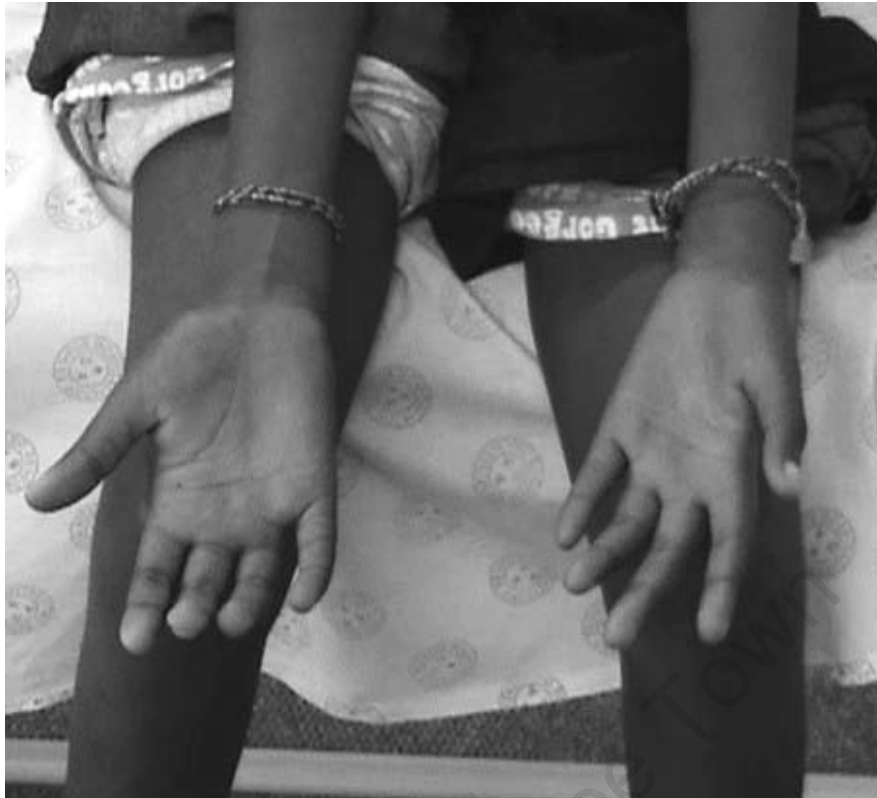

Figure 5.20a. Image of the hands from the eleven year old girl with HIV-1 infection and previous tuberculous meningitis, demonstrating atrophy of her thenar and hypothenar eminences. She had severe hypersensitivity to pain in her distal palmar and plantar surfaces. She responded well after her stavudine was converted to abacavir and she received symptomatic relief with gabapentin therapy.

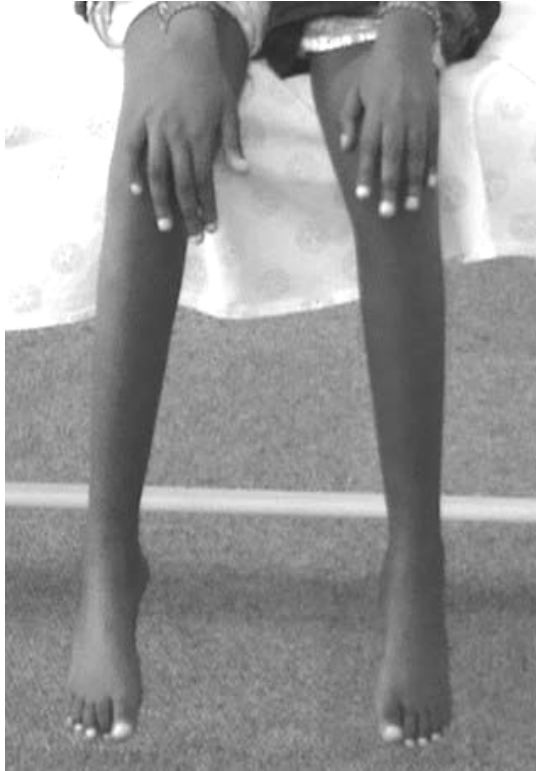

Figure 5.20b. The lower limbs of the patient in Figure 5.20a demonstrating her tapered appearance with distal wasting.

Two boys had focal signs of neuropathy related to isolated lesions in the common peroneal region. One had a biopsy-confirmed hamartoma in his left calf causing compression of the common peroneal and the other had no clear explanation for his pathology.

Table 5.1: Summary of the patients who underwent peripheral nerve biopsy

| Pt | Diagnosis | Clinical | NCS | Genetics | Biopsy | Comment |
|-----------|------------------|--|---|-----------------|---|---|
| 1 | CMT1A | Onset 8 years. Distal weakness, pes cavus and absent DTR. | Ulnar conduction velocity 13.7m/s | CMT1A | Moderate reduction in MF density, onion bulb formations, thin myelin and tomaculous myelin fibres (Figure 5.3) | This biopsy confirmed the suspected diagnosis based on the clinical, NCS and molecular genetic results. The conduction velocities were very slow but the biopsy concurred with the diagnosis CMT1A |
| 2 | CMT1A | Onset 3 years. Distal weakness, scoliosis, pes cavus, absent DTR, and bilateral hip dysplasia. Mother also affected. | Median distal latency 7.08ms (slow), amplitude 2.29mV (reduced), CV 18.6m/s (slow). Ulnar distal latency 6.24ms, amplitude 2.9mV, CV 12.6m/s; Posterior tibial and common peroneal no response to stimulation | CMT1A | Moderate reduction in MF density | This biopsy confirmed the suspected diagnosis based on the clinical, NCS and molecular genetic results. The conduction velocities were very slow but the biopsy concurred with the diagnosis CMT1A. |
| 3 | CMT3 | Onset from birth, severe global hypotonia and weakness, scoliosis and distal contractures. Recurrent lower respiratory tract infections (Figure 5.4) | No response to stimulation in motor or sensory nerves | CMT1A | Multiple OB, MF density markedly reduced, TF axonal degeneration. (Muscle biopsy showed denervation) (Figure 5.5 and 5.6) | This biopsy was useful in that it reinforced the clinicians concern that the molecular genetic result did not correlate well with the patients clinical presentation |

| | | | | | | |
|---|--------|--|--|-------|--|--|
| 4 | CMT 2 | Onset 5 years of age with distal weakness, sensory alteration, pes cavus and absent DTRs. No family history. | Normal sensory study. Common peroneal conduction velocity 41.6 m/s, amplitude 3.33mV, distal latency 4.08ms, median conduction velocity 42 m/s, amplitude 9.17mV, distal latency 2.36ms. | - | Normal myelinated fibre density, no active axonal degeneration or regeneration. Basically normal study. | The biopsy was performed on this child whilst she was undergoing corrective surgery for her foot deformity. It was useful to illustrate that she did not have marked disease involvement detected in her sensory nerve fibres. |
| 5 | CMT2 | Onset 5 years of age with distal weakness, scoliosis and mild concentration problems. Father affected. | Abnormal sensory studies. Median CV 39.7m/s; common peroneal 36.8 m/s with prolonged distal latency and reduced amplitude | CMT1A | Marked axonal degeneration involving both myelinated and unmyelinated fibres, with Bands of Büngner (Figure 5.7) | The clinical features could not differentiate the type of CMT, but the NCS suggested an axonal process. The molecular genetic diagnosis did not correlate with this. The biopsy findings were consistent with axonal disease supporting the neurophysiological data. |
| 6 | EOHMSN | Onset 3 years. Pes cavus, mild sensory impairment, generalised weakness (distal > proximal) and scoliosis. Multiple surgical interventions | Normal CV, amplitudes median 1.67mV, common peroneal 1mV | - | Axonal degeneration with reduced myelinated fibre density | Extended reviews of these samples failed to identify the associated mitochondrial abnormalities described with MFN2 mutations |

| | | | | | | |
|---|--------|---|---|---|--|--|
| 7 | EOHMSN | Onset 4 years. Hypotonia, generalised weakness (distal > proximal), absent DTR and impairment of sensory awareness. | Ulnar 41m/s slow, amplitude 0.83mV; median amplitude 1.83mV, conduction velocity normal, common peroneal amplitude 1.5mV low, conduction velocity normal. EMG denervation | - | Myelinated fibre density reduced, axonal degeneration. | Extended reviews of these samples failed to identify the mitochondrial abnormalities described with MFN2 mutations |
| 8 | EOHMSN | Onset 6.5 years. Distal weakness, pes cavus, multiple surgical interventions, absent DTR, scoliosis and altered sensory awareness (Figure 5.9) | Absent sensory conduction. Reduced motor amplitude and distal latencies | - | Severe axonal degeneration with reduced myelinated fibre density and regeneration with cluster formation (Figure 5.11) | Extended reviews of these samples failed to identify the mitochondrial abnormalities described with MFN2 mutations |
| 9 | EOHMSN | Onset 3 years of age, initially lower limb distal weakness, by 5 years of age upper limb involvement and eventual clawing of the hands. Ataxia, hypotonia and severe distal weakness. (Figure 5.10 a and b) | Absent sensory responses. Normal upper limb motor responses. Absent lower limb motor responses | - | Severe axonal degeneration with reduced myelinated fibre density and regeneration with cluster formation. Also some fibres with features similar to onion bulb | Confirming the appearances typical of the MFN2 mutation suggested a more definitive diagnosis for this patient. |

| | | | | | | |
|----|--|--|--|--|--|---|
| | | | | | formations. (Figures 5.12 a and b) Electron microscopy appearance confirmed abnormal mitochondrial aggregations (Figure 5.13) | |
| 10 | Axonal miscellaneous | Onset 13 months of age with an abnormal gait. From 10 years of age rapid and severe scoliosis. Distal contractures, distal weakness, sensory alteration, depressed DTR, pes cavus and swallowing difficulties. (Figure 5.14 a and b) | Normal sensory studies. Motor common peroneal CV 44.3m/s, reduced amplitudes and distal latencies. | - | Normal sural nerve biopsy | This girl remains without a diagnosis. A motor axonal nerve disorder is suggested. |
| 11 | Severe infantile axonal neuropathy with respiratory failure / SMARD1 | Onset 3 months. Diaphragmatic paralysis, distal weakness and generalised hypotonia. Reduced sensory awareness. Scoliosis. Absent DTR. Home ventilation. Normal cognition. (Figure 5.15) | Not performed | <i>IGMBP2</i> mutation | Moderate reduction in MF density. Predominance of small diameter fibres. Large fibres undergoing active axonal degeneration. Bands of Büngner. | This biopsy result was obtained early in the infant's course (prior to the genetic result). The result assisted in the early counselling and management plans for the patient. |
| 12 | Juvenile severe infantile axonal neuropathy with respiratory failure | Onset 3 years of age with a paretic hemidiaphragm, distal weakness and scoliosis. She required BIPAP support. (Figures 5.16 and 5.17) | Normal sensory studies. Delayed motor CV common peroneal 43m/s and reduced amplitude | SMARD1 negative Extended further screens pending. | Axonal degeneration. Normal myelinated fibre density | The combined information from this child has allowed collaboration with a centre overseas to undertake further extended molecular genetic screens of the SMARD mutation region. |

| | | | | | | |
|----|----------------------------------|---|---|------------------------------|--|--|
| | | | 1.5mV | | | |
| 13 | Hereditary motor neuropathy | Twins. Onset 4 years of age with abnormal gait, distal weakness, contractures and reduced DTR. Learning difficulties and some further cognitive decline. Optic atrophy. | Normal sensory studies. Motor responses could not be stimulated. | - | Axonal degeneration. No abnormal storage material | A neurodegenerative disorder was suspected. The absence of abnormal storage material or neurofilaments reduced the likelihood of a number of differential diagnoses. |
| 14 | ALS4 | Onset 10 years of age. Portuguese ancestry. Upper and lower motor neurone signs, cognition preserved, bulbar dysfunction, tongue fasciculations. | Normal sensory studies. Common peroneal – no response to stimulation. EMG denervation | MPZ negative SMN negative | Axonal degeneration. Normal myelinated fibre density | The biopsy confirmed the suspicion of a more global condition. This boy's clinical course has also guided his subsequent diagnostic label. |
| 15 | Congenital insensitivity to pain | Presented at 2 years of age with apparent insensitivity to pain. He was bitten by the family dog, he felt no pain but bit the dog back. Head banging. Hyperactive. Mild developmental delay. Normal sweating. Old burn marks on fingers. Did feel cold (shivers). Normal examination with retained DTR. | Normal sensory and motor studies | - | Normal biopsy on light microscopy and electron microscopy examination. Additional skin and muscle biopsy were also normal. | Finding no evidence of nerve disease directed the therapy towards behavioural interventions for this boy. |

DISCUSSION.

Children with peripheral neuropathies represented a third of the patients seen in the neuromuscular service and 3% of the total group attending the service with neurological conditions. The neuromuscular service at Red Cross Children's Hospital is a tertiary referral centre and as such children are referred nationally and from other countries bordering South Africa as well as from all sectors (government and private). This would have affected the ancestry groupings where typically government patients seen at Red Cross would be dominated by the Indigenous African and so-called "mixed" ancestries. This was evident in the "acquired" group where six children were of European descent.

AIDP typically occurs after infections and many of our cohort had proven triggers (*Campylobacter* and *Mycoplasma*) – this has already been described as well as the more severe course.^(421,422) Our centre has access to intensive care, high care support, intravenous immunoglobulin for relevant cases, and ancillary services so the management of these patients if they can access the tertiary setting is similar to that of international centres.

The disparity of the larger size of the acquired group compared to the children with hereditary disorders could be explained by the increased number of trigger factors (poor nutrition, exposure to toxins and infections) but is more likely related to this study reviewing all patients with peripheral neuropathy whether sural nerve biopsy was performed or not. None the less both groups were of significant size and clinical impact. A review from Oman found similar results.⁽⁴²³⁾ The authors identified 82 children with peripheral neuropathies of whom 45 were related to acquired causes, mostly AIDP, and 37 related to hereditary causes. Seventeen patients (20%) from this group had forms of CMT. In another study of 74 children from Turkey 73% had acquired pathologies and 27% were considered hereditary.⁽⁴²⁴⁾ A study from the Netherlands of 82 children with chronic peripheral neuropathies had the reverse evident with 68% of their cohort related to hereditary neuropathies and remaining 32% acquired.⁽⁴²⁵⁾ The relevance of this study originating from a "resource equipped" country without the same levels of socioeconomic challenges cannot be ignored. Interestingly a three year audit of all children with peripheral neuropathies seen at a Sydney centre found that 40% were related to hereditary causes, 45% acquired and the remainder considered

miscellaneous (personal communication Prof R Ouvrier). No cases of HIV-related neuropathy were identified in childhood.

Five patients were managed with peripheral neuropathy symptoms related to HIV-1. These children became clinically symptomatic in relation to their antiretroviral medication and required adjustment of their treatment regimen. Peripheral neuropathy developing in relation to ARVs is a well described complication, commonly related to nucleoside reverse transcriptase inhibitors, especially stavudine (d4T).⁽⁴²⁶⁾ Other described causes of peripheral neuropathy are distal symmetrical polyneuropathy (DSP), mononeuritis multiplex, inflammatory demyelinating polyneuropathy and progressive polyneuropathy.⁽⁴²⁷⁾ Most of these conditions, especially DSP, are more recognised in adult patients with HIV-1 infection. In our centre the infectious diseases service routinely manages children with HIV-1 infection and discusses patients who may have neuropathy. Since this study related to patients managed within the neuromuscular services the number of children affected could have been underestimated. One patient was previously reported with AIDP at the time of seroconversion as part of a case series from our centre.⁽⁴²⁸⁾ This patient was managed acutely but continued his long-term follow-up in the infectious diseases service at another centre. The signs of peripheral neuropathy in a chronically sick and malnourished child can be subtle and not be detected unless specifically looked for. In a prospective study of 80 children with HIV-1 managed in the infectious disease service at Red Cross Children's Hospital, five had evidence of unsuspected peripheral neuropathy (unpublished data R Govender, J Wilmshurst et al). Four were considered related to ARV toxicity and one secondary to *Cytomegalovirus* infection. The "layering" effect of HIV-1 infection results in multiple potential causes for a clinical phenotype. Children infected with HIV-1 are at increased risk of malnutrition, poor mobility, drug toxicity and additional infections. This was evident in the patient who had completed treatment for tuberculous meningitis. Her regimen included isoniazid and she did not receive prophylactic pyridoxine. Increased incidence of peripheral neuropathy is described with co-infection of HIV-1 and tuberculosis.⁽⁴²⁹⁾

Acquired conditions seen in other parts of Africa but not seen in our cohort included sickle cell related sensory neuropathy⁽⁴³⁰⁾, leprosy related neuropathy⁽⁴³¹⁾ and an ataxic polyneuropathy from Nigeria⁽⁴³²⁾.

Forty-four children had features of hereditary forms of peripheral neuropathy. CMT1A is described as the commonest sub-form even in childhood^(29,30,33,35-37) – this was not the case in our group with only four patients confirmed genetically and no patients were of indigenous African descent. Our numbers were small but the trend would imply that this sub-form is not expressed in the same proportions in our population compared to other international centres. There is little data describing incidence of CMT1A in indigenous African populations. A study from Brazil reported that 13% of their cohort with CMT1A were of African descent (n=6).⁽⁴³³⁾ This finding differed from a report from Nigeria where only 3 patients were identified with CMT from an extended audit of 2.1 million patients.⁽⁴³⁴⁾ In the SA series the group was dominated by children with axonal forms of CMT. Genetic analysis of this group remains a challenge even for international centres and the group remains with the lowest molecular genetic mutation detection rate. Screening the cohort of patients with CMT2, the patients with EOHMSN and the twins with dHMN for *mitofusin* mutations would be of great interest as this molecular genetic error is described in all these forms.^(77,81,105,164,252) CMT2A could not be excluded in the twins as they had optic atrophy.

Sural nerve biopsy was performed in 14 of the 44 children; this proved a useful intervention in our setting (table 5.1). Samples either reinforced the diagnostic category for the patient or strengthened diagnostic concerns arising from conflicting molecular genetic and neurophysiological results. The histopathology laboratory at Red Cross Children's Hospital is skilled in the preparation and analysis of muscle and nerve samples. Concentrating this service in the one centre, though not ideal for patients from further afield, has allowed a level of expertise to develop and the technical staff to perform high quality screens. Clinicians are encouraged to refer patients to the centre for counselling and for the studies to be performed on site to reduce artefact damage. A fifteenth biopsy was performed on the child with congenital insensitivity to pain, the normal result reinforced the belief that the child's condition was of central origin and directed his interventions towards more behavioural therapy.

Within South Africa the screening for hereditary forms of CMT is limited to testing for CMT1A and HNPP and no point mutations are analysed. The conflicting results in the study are of great concern. The infant whose molecular genetic screen detected a duplication of *PMP22* consistent with CMT1A, presented with severe demyelinating disease. CMT1A can

occur in infancy ⁽²⁾, but the extreme severity of this patient's disease and her marked involvement on sural nerve biopsy did not correlate with this result and she was recategorised CMT3.⁽⁴³⁵⁾ Similarly the boy with a dominant family history who had axonal changes on his neurophysiology and histopathology studies had a positive result for CMT1A (twice). Some of the described mutations can present with either axonal or demyelinating pathology (*MPZ*, *GDAP1*) but this is not the case for *PMP22* mutations. *PMP22* duplications result in primarily demyelinating conditions only (CMT1A). The axonal disease in our patient appeared the primary process and he had no biopsy evidence of demyelination. When diagnostic challenges and conflicting results such as this arise sourcing other centres to perform repeat and extended screens is ideal. However the cost implications are beyond the government facilities' and most parents' finances. What is basically a clinical screen would be dubious to place in a research category – especially when so many of these screens are readily available overseas. There are huge implications from the lack of extensive genetic analysis in these patients as to drawing finite conclusions and reaching a level of diagnosis for the requirements of most peer reviewed journals would require the genetic screens to be equivalent to other studies. Resource-limited countries are falling behind with regard to this as, although large cohorts of patients are recruited in the small dedicated centres, genetic diagnostic closure is often not possible and accordingly these patients cannot be published. The genetic screens, beyond CMT1A and HNPP, performed from this group were all undertaken by individually sourced centres from the United Kingdom, Germany and Australia. Most provided the services at no cost. The *DYT1* screen was performed at a research unit in Cape Town.

A number of the patients were lost to follow-up. Unfortunately this is not an infrequent occurrence in SA. Families are driven by their daily living needs which often override the health needs of their children – especially where at the current time the investigations are unlikely to alter their child's management. Children often move across different parts of South Africa according to who the main carer is or in pursuit of parental employment. It is not unusual for a child to be lost to follow-up for several years and then reappear when school placement must be arranged. Communication between primary health care centres is limited and children may be managed there without their diagnosis being known. Ancillary support is

usually good in most government centres but must be coordinated, otherwise the child is left without intervention and surgery becomes inevitable.

The day to day care of children with peripheral neuropathies can and should be managed at the nearest centre to the child. The diagnostic “work-up” should occur at specialised centres with an interest in the pathology to allow comprehensive counselling and management plans to be drawn. Dedicated centres must be in place with the capacity to undertake and interpret accurately neurophysiological and histopathological screens in children. Molecular genetic services need to be drastically expanded to keep up with the international trends.

Even with limited access to genetic facilities and not all the patients undergoing peripheral nerve biopsy, reasonable categorisation was possible for many of them based on combined data describing the clinical CMT sub-groups (Table 1.2). It was often necessary however to have at least two aspects of the investigations available (clinical, neurophysiological and ideally histopathological). For centres with limited resources children can be assessed with at least the first two in most tertiary facilities in South Africa. Complex patients can be and often are referred to Red Cross Children’s Hospital, Cape Town. Definitive diagnoses are likely to become of increasing import as studies progress looking at therapeutic interventions based on specific genetic mutations. A prime example would be the intervention with Vitamin C for children with CMT1A.⁽³⁸⁶⁻³⁸⁸⁾

CHAPTER 6

CONCLUSIONS

The preceding chapters have provided an overview of peripheral neuropathy occurring in children and infants. They have described the recognised categories (chapter 1, tables 1.2-1.4), the role of nerve biopsy (chapter 2), the spectrum of infantile and childhood peripheral neuropathies prevalent in a developed world setting (chapters 3 and 4) and in a resource-limited setting (chapter 5).

The differences between adults with peripheral neuropathies and children are illustrated in chapter 3. Unlike adults, children have more hereditary aetiologies for their chronic neuropathy than acquired causes. More autosomal recessive conditions occur in children than adults. Despite this, CMT1 is prevalent in both groups – although still more frequent in adults. Children are more likely to have undefined aetiologies than adults. Part of the explanation for this lies in the greater incidence of axonal degenerative peripheral neuropathies which occur in children (n=169 axonal versus n=107 demyelinating, chapter 3). Patients with axonal degenerative peripheral neuropathies are less likely to achieve a definitive molecular genetic diagnosis. As demonstrated in the Australian study (chapter 3), children with neurodegenerative disorders and infants with generalised hypotonia are more likely to undergo a peripheral nerve biopsy and have a normal result. This reflects some of the diagnostic challenges of investigating a hypotonic infant, as well as the screening undertaken when performing a neurodegenerative assessment or “work-up”. A normal result in this setting, for children, can be equally beneficial as it may exclude a number of serious differential diagnoses. The progress in molecular genetic and biochemical screens has resulted in this situation being less common in children analysed more recently.

Children and infants suffer a similar spectrum of conditions (chapters 3 and 4), with a predominance of hereditary causes even more evident in the infantile group. A wide range of conditions is described in the group presenting in infancy (chapter 4), conditions which previously were more recognised in children and adults (e.g.CMT1). Although the number of infants with axonal disease equalled those with demyelinating disease, those with axonal disease were less likely to achieve a definitive diagnosis. For the whole group presenting with

peripheral neuropathy in the infantile period, apart from those with CMT3, a molecular genetic diagnosis was unusual.

This study is of use for its large collection of affected patients enabling both a perspective of the groupings of the more “common” forms of chronic peripheral neuropathy in childhood and the identification of the rarer disorders. The disorders commonly under-recognised in the adult-dominated literature would be EOHMSN and SMARD1 / SIANR.^(103,106,108) Rarer disorders in this population would be conditions such as CMTX5 (*PRPS1* mutation) and CMT4H (*frabin* mutation).^(136,137,148,149,247) Although the data from the patients from Australia span 37 years (chapter 3) it remains, in part, a prospective study with on-going diagnoses emerging on many of the historical cases as each new mutation is identified. Important genetic screens which at the very least should be available to most populations include chromosome 17p duplications and deletions, *MPZ*, *connexin 32*, *mitofusin2* and SMARD1.

Despite the explosion in molecular genetics from the Sydney series, molecular genetic diagnoses were made in 34/50 (78%) of the demyelinating CMT group but in only 13/31 (42%) of the axonal degenerative group of the patients who underwent genetic screening. A study from the Netherlands found that a causative gene was identified in 17% of their patients with axonal disease.⁽⁴³⁶⁾ Most studies support the need however for extensive molecular genetic screens to fully delineate and understand large cohorts of patients with chronic peripheral neuropathy. This remains a great challenge in the resource-limited setting.⁽⁶⁴⁾

The groups which dominated the axonal cases were the patients with EOHSMN (22% of the axonal group) and the patients with *SMARD1* mutations. Both conditions are severe disorders. Prenatal screening for *SMARD1* mutations should be available as the implications for a family and child affected with this condition are devastating.⁽³⁴⁸⁾

Comparing the Australian patients to the patients from South Africa (SA), there were several parallels but some interesting differences. The lack of patients with CMT1A cannot be assumed due to selective screening as the SA patients were included with or without nerve biopsy and as such the proportion of CMT1 cases should have been greater. The number of patients from the SA study was small but the trend would suggest that demyelinating forms of

CMT are not as prevalent as the axonal forms. This is supported by a study from Nigeria but there are few other studies to allow comparison.⁽⁴³⁴⁾ Adult SA data suggests that under 10% of the indigenous African neuropathy population seen in a government hospital have CMT1 (personal communication J Heckman, Dissertation MMed (UCT) 1994; Inherited Neuropathies at Groote Schuur Hospital).

In settings where access to molecular genetics is limited, screening using all possible tools is essential to attain a diagnostic label. Even when molecular genetic studies are available, the genetic confirmation alone may not correlate with a clinical diagnosis without supporting information from the combined findings of the clinical phenotype, neurophysiology and histopathology (“endotyping”).

Based on this information the following specific diagnostic indicators could be used to focus the differential diagnoses of children presenting with peripheral neuropathy

Clinical markers are summarised in table 6.1 with the relevant references. The table identifies recognised peripheral neuropathy sub-types linked to these clinical clues, namely those hereditary peripheral neuropathies with onset in early childhood, some of which have severe evolution. We have previously demonstrated that there is heterogeneity in the presentations of many of the hereditary neuropathies, as demonstrated by the patients with CMT1 who became symptomatic in infancy.⁽²⁾ Additional clues are those conditions particularly associated with scoliosis, marked sensory involvement, respiratory involvement with diaphragmatic and or vocal cord impairment, predominantly upper limb involvement, additional proximal weakness, glaucoma, optic atrophy, deafness, pyramidal tract involvement, central involvement with white matter MRI abnormalities, and mental retardation.

Useful neurophysiological markers other than the typical demyelinating and axonal ranges described in CMT1 and CMT2, are the extreme slowing evident in CMT3 (usually <10m/s motor conduction velocity) and most forms of CMT4, as well as the intermediate values seen in patients with DI-CMT and CMTX.^(48,150) The patients with EOHMSN often have values in the borderline axonal / demyelinating range.⁽¹⁰³⁾ Patients with SMARD1 typically have no nerve responsive to stimulation.^(2,106)

Most guidelines discussing investigation of peripheral neuropathies recommend consideration of peripheral nerve biopsy, especially if other routes have failed to confirm an

underlying diagnosis.^(256,322,424,437,438) Peripheral nerve biopsy is a safe investigation which if performed and analysed in an appropriate setting can enhance the diagnostic yield of complex patients.⁽³²³⁾ Most guidelines, however, are adult based and few exist with paediatric emphasis.^(2,424)

Specific features on histology would include the giant axons of GAN and CMT2E,⁽⁷⁸⁾ the myelin-outfolding of CMT4B⁽¹¹⁶⁾ the unusual Schwann cell cytoplasmic chains of CMT4C, the extreme paucity of fibres in some cases of *lamin A* mutations and the mixed ultrastructural demyelinating/ axonal degenerative picture of EOHMSN associated with abnormal mitochondria⁽¹⁰⁵⁾.

Other tools yet to be explored include the role of neuroimaging – MRI has identified specific muscle groups affected in particular subgroups of CMT.^(439,440) Additional studies have looked at the role of lumbosacral root and sciatic nerve imaging to assess disease severity and progression.⁽⁴⁴¹⁻⁴⁴³⁾

The combined data in Tables 1.2-4 should aid the clinician to try and subcategorise patients as specifically as possible using an “endotyping” approach.

Confirming a diagnosis for patients is important for directing therapy towards specific complications (e.g. scoliosis, respiratory failure), for diagnostic closure for a family with information on subsequent risks for future pregnancies and potentially for therapies in the future (e.g. CMT1A and Vitamin C).

An approach in a resource-limited setting.

As stated, the main tool used consistently in most resource-limited centres is that of clinical assessment. As a result the majority of children, unless they demonstrate one or more of the key markers described above and in table 6.1, will lack a more definitive diagnosis beyond the label “peripheral neuropathy”. Clinical history should assist differentiating between acquired and hereditary neuropathies.

In the context the author works in, the following management priorities are addressed and summarised in figure 6.1. Once clinical confirmation of a peripheral neuropathy is established, as described in the introduction of the text, basic interventions can be implemented, commencing with whether the condition is acquired or hereditary.

Clues to support an acquired condition would include an acute onset, a monophasic illness in a previously well child, often with a prior history of infection or initiation of a potentially neurotoxic therapy (ARVs, isoniazid); also, the child with a chronic but relapsing course. The most prevalent peripheral neuropathy, as occurs internationally, remains AIDP. It may not be possible to perform nerve conduction studies but access to analysis of CSF, demonstrating an acellular response and a raised protein in the second week of clinical onset, should be available in most centres; also analysis of potential trigger factors – especially prior *Campylobacter* and *Mycoplasma* infections. Poliomyelitis remains a notifiable condition which is still prevalent in parts of Africa. Screening for enteroviruses in any child with flaccid paralysis remains essential.

Few centres in South Africa, or other parts of Africa, have access to intensive care support and the management of the child with progressive weakness and airway compromise is challenging. Recommendations are that centres with access to intravenous immunoglobulin administer the agent to any child suspected of having AIDP, who has respiratory compromise or loss of ambulation.

The other significant cause of peripheral neuropathy which is increasingly presenting is that related to HIV, either as part of direct disease involvement or secondary to the complications of ARVs. The neuropathy which arises has a similar clinical phenotype to distal symmetrical polyneuropathy (DSP) described more in adults with HIV.⁽⁴²⁷⁾ Affected children may have severe sensory features of intense distal burning affecting the hands and the feet, as well as distal weakness.⁽⁴²⁷⁾ This occurs as an adverse side effect of therapy with the nucleoside reverse-transcriptase inhibitors, stavudine and to a lesser extent didanosine. Stavudine remains part of the first line recommended regimen from the WHO guidelines. If peripheral neuropathy occurs conversion to zidovudine or abacavir is recommended.^(426,444) Symptomatic relief is described with gabapentin, if it is available, otherwise amitriptyline can be used.⁽⁴²⁷⁾ Adult based trials have assessed the role of acetyl-L-carnitine which may benefit some patients.⁽⁴⁴⁵⁾ Peripheral neuropathy in children with HIV has not been extensively studied but is also described in the form of AIDP at the time of seroconversion or as an immune reconstitution phenomenon, and in relation to secondary infection with *Cytomegalovirus*.^(428,446-448) The author has managed children with these complications. The

author believes that the incidence of peripheral neuropathy in children with HIV-1 infection is underestimated. From the cohort of HIV-infected patients attending the infectious diseases service (n=80) prospectively reviewed at Red Cross Children's Hospital 6% had peripheral neuropathies (R Govender, JM Wilmshurst unpublished data). Another study identified abnormal nerve conduction studies in 12 out of 50 children clinically suspected to have neuropathies.⁽²⁸⁷⁾ A study from Rio de Janeiro quoted a 34% prevalence of peripheral neuropathy in their paediatric patients with HIV-1 infection.⁽⁴⁴⁹⁾ The approach used specifically for patients with HIV-1 and peripheral neuropathy in the author's centre is summarised in figure 6.2.

The other toxic neuropathy seen infrequently is related to isoniazid therapy though with increased frequency when there is co-infection with HIV.⁽⁴²⁶⁾ Prophylaxis with pyridoxine can reverse this.⁽⁴⁵⁰⁾ Seen less frequently are the nutritional deficiency neuropathies, especially vitamin B12 deficiency, either in isolation or associated with the HIV infected patient.^(451,452) These seem to be rare in South Africa but are described elsewhere in the continent.⁽⁴⁵³⁾

A positive family history and a chronic progressive clinical course would support a hereditary nature in a child with peripheral neuropathy. Establishing if there is evidence of neuroregression would further direct the search for possible causes. Neuroregressive disorders with distinct clinical appearances include Friedreich ataxia, rare childhood forms of spinocerebellar ataxia, various metabolic disorders, mitochondrial disorders, leukodystrophies, giant axonal neuropathy, and Cockayne syndrome. Centres with the capacity should perform diagnostic neuroimaging and biochemical screens (e.g. CSF lactate, urinary organic and amino acids, mitochondrial screens). Frustratingly most suspected diagnoses require additional support from neurophysiology, molecular genetics and or histopathology.

The management of both acquired and hereditary peripheral neuropathies should concentrate on the optimal outcome of the child. This requires supportive care, such as pain relief (gabapentin), therapeutic interventions where indicated (e.g. immunoglobulins) and ancillary input. Most children present to a primary health care centre and are managed by a primary health care worker who may be a nurse practitioner or a medical officer. Limited

training in the recognition of the clinical signs of peripheral neuropathy may result in some of these children being misdiagnosed. There is a need to train these service providers in the key clinical diagnostic features of peripheral neuropathy and to establish viable management guidelines for affected children. Commencing regular physiotherapy and occupational therapy early in the child's illness is essential and should be available at most secondary and tertiary centres. As a result inevitably these children need to be referred on to a secondary or tertiary level facility. Across Africa there is significant limitation in paediatric specialist services, and paediatric neurologists are scarce in countries between South Africa and the Northern African countries. As a result the burden of care falls on the primary health care workers.

Carers can be taught a home programme for avoidance of contracture formation. The child and carer should be educated of the increased need to avoid damage to the joints and distal regions due to sensory impairment. Many children in South Africa live in households where paraffin fires are the main heating and cooking devices. These are rarely protected and burns are frequent complications, all the more likely to occur to the child with altered sensory awareness. Orthotic devices are important and also should be available in most referral centres. Access to speech therapy and dieticians is also important. Support from other specialists, such as orthopaedic surgeons to undertake surgical interventions to promote mobility is ideal but often lacking. Regular assessments are necessary to avoid secondary complications such as contractures, scoliosis and respiratory tract infections occurring. Where available, prophylactic intervention with influenza and pneumococcal vaccinations should be given to those children who are considered to be at risk of chest infections.

The centre where the author works has access to neurophysiology, histopathology and limited molecular genetics. Most other centres have only clinical assessment for diagnosis with the ancillary input often consisting of a community physiotherapist.

In summary the basic aims of care for a child with a peripheral neuropathy include:-

1. Accurate diagnosis of a peripheral neuropathy, typically via clinical assessment.
2. Where available referral to a specialist centre (there may be only one per country, or none, requiring referral to another country).
3. Education of the carers in the safety aspects required when a child has a peripheral neuropathy.

4. Counselling on the potential genetic implications (based on suspected aetiology).
5. Involvement of any available ancillary services and access to orthotic and orthopaedic facilities.

These points would be the minimum standards of care when based in a resource-limited setting.

University of Cape Town

Table 6.1. Summary of conditions commonly associated with specific clinical features

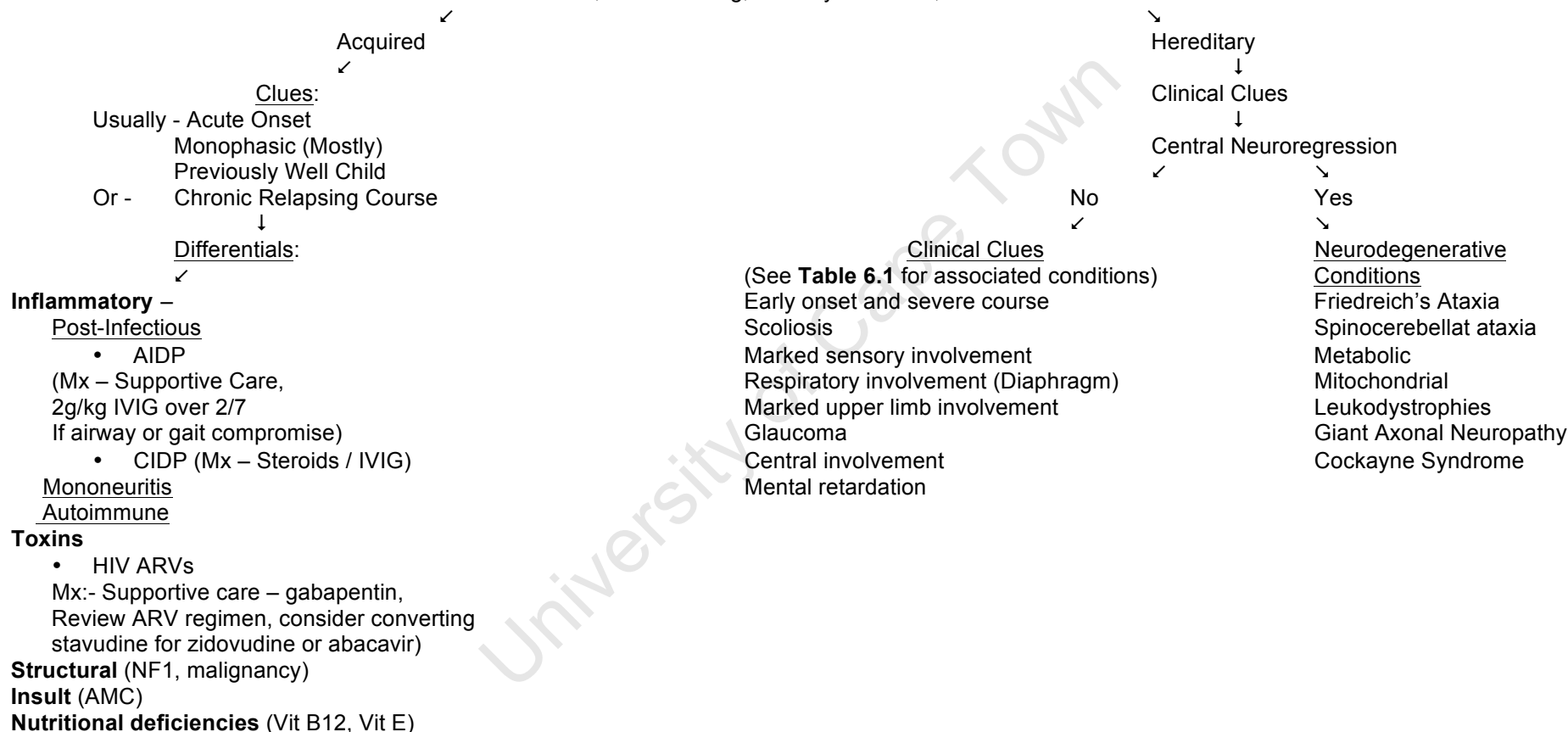
| Clinical Feature | Associated conditions | Clinical Feature | Associated conditions |
|--|--|--|---|
| Early onset (some severe) | CMT1A ⁽²⁾ CMT1B ⁽²⁾ CMT1C ⁽⁶⁰⁾ CMT2C ^(91,410) CMT2G ⁽⁹⁶⁾ CMT2K ^(99,100) Autosomal recessive forms of CMT2 ⁽²⁾ Giant axonal neuropathy ⁽²⁾ EOHMSN ^(102,103) SMARD1 ^(106,108) CMT3 ⁽¹¹⁶⁾ CMT4 ⁽¹¹⁶⁾ CMTX ⁽¹⁴¹⁾ HSAN2-5 ^(197,198) Congenital distal SMA ⁽¹⁸⁶⁾ Most metabolic neuropathies | Predominantly upper limb involvement | CMT2D ^(92,93) dHMNV ⁽¹⁷⁶⁾ additional proximal weakness with CMT2L ⁽¹⁰¹⁾ |
| Scoliosis | CMT2L ⁽¹⁰¹⁾ CMT3 ⁽¹¹⁶⁾ CMT4 ⁽¹¹⁶⁾ | Glaucoma | CMT4B2 ^(125,126) CMT4C ^(127,128) |
| Sensory involvement marked | CMT2B ⁽⁸²⁻⁸⁴⁾ CMT2E ⁽⁶⁵⁾ CMT2F ^(94,95) HSAN ^(197,198) | Optic atrophy | CMT2A ⁽⁷⁷⁾ EOHMSN ⁽¹⁰³⁾ CMTX4 ⁽¹⁴²⁾ CMTX5 ⁽¹⁴³⁾ |
| Respiratory involvement (diaphragm and or vocal cord) | CMT2C ^(91,410) CMT2H ⁽⁷¹⁾ CMT2K ⁽¹⁰⁰⁾ SMARD1 ^(106,108) EOHMSN in later life ^(121,122,253) CMT4B1 ^(113,132,133,336) CMT4F ^(174,175) dHMNV ⁽¹⁰⁸⁾ dHMNV ⁽¹⁰⁸⁾ dHMNVII ^(178,179) | Deafness | <i>MPZ mutations</i> ^(454,455) <i>PMP22 mutations</i> ⁽⁴⁵⁶⁾ CMT2E ⁽⁶⁵⁾ CMT4D ^(129,130) CMTX1 ⁽⁴⁵⁷⁾ CMTX4 ⁽¹⁴²⁾ CMTX5 ⁽¹⁴⁸⁾ |
| Pyramidal tract involvement | CMT2H ⁽⁷¹⁾ CMTX3 ⁽¹⁴⁷⁾ HMSNV ⁽¹⁶⁴⁾ dHMNV ^(92,176) ALS4 (dHMN) ⁽¹⁸¹⁻¹⁸³⁾ d-HMN-J ^(184,185) | Central involvement with white matter MRI abnormalities | CMT2A, particularly with mitofusin mutations ^(252,458) CMTX ⁽⁴⁵⁹⁻⁴⁶¹⁾ |
| Mental retardation | CMTX2 ⁽¹⁴⁶⁾ CMTX4 ⁽¹⁴²⁾ Andermann syndrome ⁽¹⁸⁷⁾ HSAN 4 ⁽²¹⁹⁻²²¹⁾ | | |
| | | | |

Figure 6.1 Approach to the child with suspected peripheral neuropathy in a Resource-Limited Setting

Peripheral Neuropathy typical clinical phenotype:

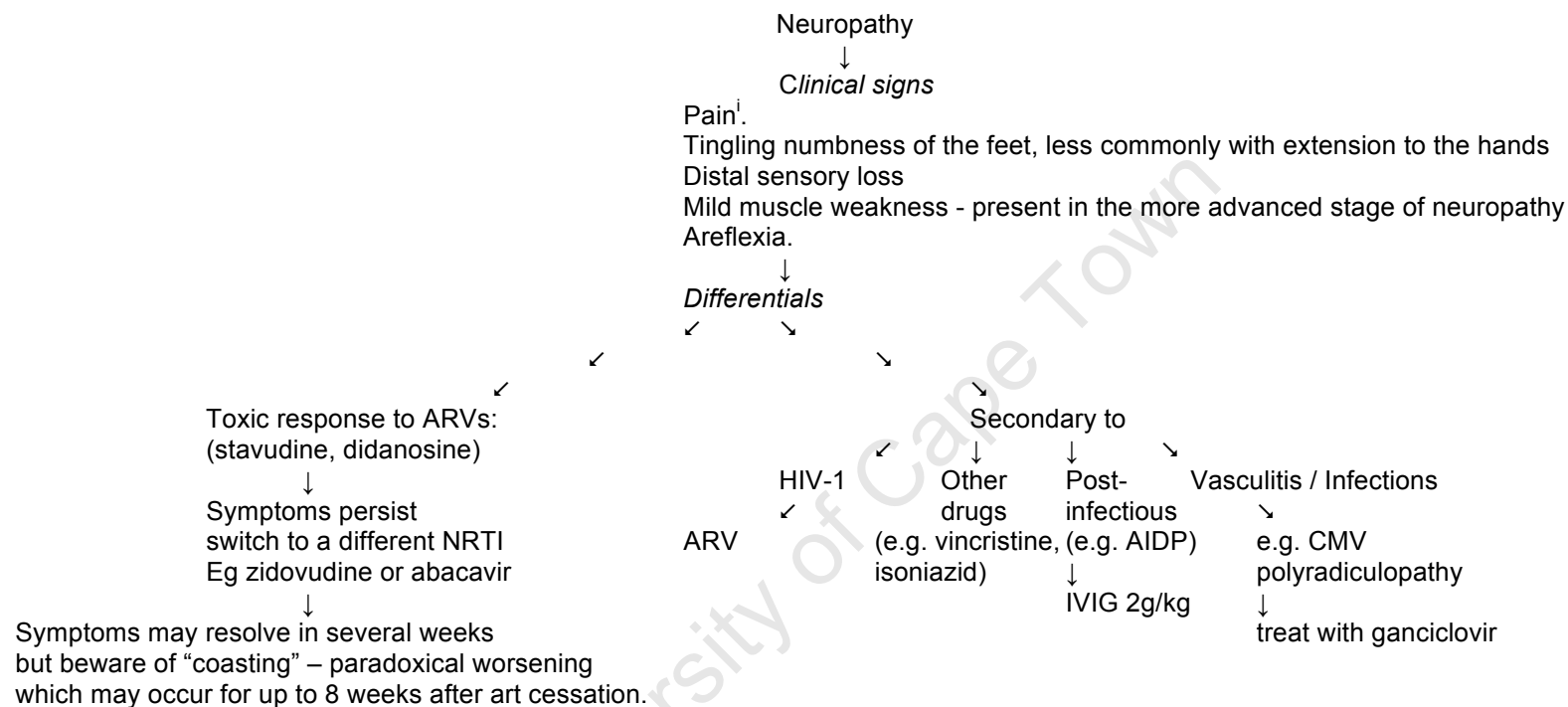
Key features:

Distal Weakness, distal wasting, sensory alteration, reduced / absent DTR.



Key: AIDP = acute inflammatory demyelinating polyradiculoneuropathy; AMC = arthrogyrosis multiplex congenita; ARV= antiretroviral therapy; CIDP= chronic inflammatory demyelinating polyradiculoneuropathy; IVIG=intravenous immunoglobulins; HIV = human immunodeficiency virus; NF1 = neurofibromatosis type 1;

Figure 6.2 Approach to the HIV infected child with distal weakness / sensory disturbances



i. Consider using analgesics, amitriptyline, gabapentin; avoid carbamazepine

Key: AIDP = acute inflammatory demyelinating polyradiculoneuropathy; CMV = cytomegalovirus; IVIG = intravenous immunoglobulin

References

- (1) Wilmshurst JM, Ouvrier RA. Nerve Biopsy. In: Royden Jones H, De Vivo DC, Darras BT, editors. *Neuromuscular Disorders of Infancy, Childhood, and Adolescence. A Clinician's Approach*. Philadelphia: Butterworth Heinemann; 2003. p. 91-109.
- (2) Wilmshurst JM, Pollard JD, Nicholson G, Antony J, Ouvrier R. Peripheral neuropathies of infancy. *Dev.Med.Child Neurol.* 2003 Jun;45(6):408-414.
- (3) Viale GL. The spinal cord and its roots according to Galen. *Neurosurgery* 2004 Jun;54(6):1490-5; discussion 1495-6.
- (4) Spillane JD. *The Doctrine of the Nerves* Oxford: Oxford University Press; 1981. p. 35-52.
- (5) Donaghy M. Genes for peripheral neuropathy and their relevance to clinical practice. *J.Neurol.Neurosurg.Psychiatry.* 2004 Oct;75(10):1371-1372.
- (6) Chomel AF. De l'epidemic actuellement regante Paris. *J Hebdomadaire Med* 1828;1:333.
- (7) Remak E. Zur Pathogenese der Bleilahmungen. *Arch.Psychiatr.Nervenkr* 1875;6:1-56.
- (8) V. P. A. Maingault. De la paralysie diphtherique, recherches cliniques sur les causes, la nature et la traitement de cette affection. University of Paris: ; 1860.
- (9) Meyer P. Anatomische Untersuchungen über diphtheritische Lahmung. *Virchow Arch (A)* 1881;85:181-226.
- (10) Gombault A. Contribution à l'étude anatomique de la névrite parenchymateuse subaiguë et chronique: Névrite segmentaire peri-axile. *Arch.Neurol.* 1880-1881;1:117-190.
- (11) Guillain G, Barré JA, Strohl A. Sur un syndrome de radiculonévrite avec hyperalbuminose du liquide céphalorachidien sans réaction cellulaire. *Bull.Soc.Med.de l'Hopital de Paris* 1916;40:1462-1470.
- (12) Brody AJ, Sternbach G, Varon J. Octave Landry: Guillain-Barre syndrome. *J.Emerg.Med.* 1994 Nov-Dec;12(6):833-837.
- (13) De Jong RN. The Guillain-Barré syndrome. Polyradiculoneuritis with albinocytologic dissociation. *Arch.Neurol.Psychiatry* 1940;44:1044-1068.
- (14) Dyck PJ. Inherited neuronal degeneration and atrophy affecting peripheral motor, sensory and autonomic neurons. In: Dyck PJ, Thomas PK, Lambert EH, Bunge R, editors. *Peripheral Neuropathy* Philadelphia: WB Saunders; 1975. p. 825-867.
- (15) Austin JH. Observations on the syndrome of hypertrophic neuritis (the hypertrophic interstitial radiculoneuropathies). *Medicine* 1956;35:187-237.
- (16) Thomas PK, Lascelles RG, Hallpike JF, Hewer RL. Recurrent and chronic relapsing Guillain-Barré polyneuritis. *Brain* 1969;92:589-606.
- (17) Spencer P, Schaumburg HH. *Experimental and Clinical Neurotoxicology*. Baltimore: Williams & Wilkins; 1980.
- (18) McLeod JG. Carcinomatous neuropathy. In: Dyck PJ, Thomas PK, Lambert EH, Bunge R, editors. *Peripheral Neuropathy*. 2nd ed. Philadelphia: WB Saunders; 1984. p. 2180-2191.
- (19) Friedreich N. Über degenerative Atrophie der spinalen Hinterstränge. *Virchow Arch (A)* 1863;27:1-26.
- (20) Charcot JM, Marie P. Sue une forme particulière d'atrophie musculaire progressive souvent familial debutant par les pieds et les jambes et atteignant plus tard les mains. *Rev. Med. (Paris)* 1886;6:97-138.

- (21) Tooth HH. The peroneal type of progressive muscular atrophy. : London H.K. Lewis & Co, Ltd; 1886.
- (22) Déjerine J, Sottas J. Sur la nevrite: interstitial, hypertrophique et progressive de l'enfance. C.R.Soc.Biol. (Paris) 1893;45:63-96.
- (23) Gilliat RW, Thomas PK. Extreme slowing of nerve conduction in peroneal muscular atrophy. Ann.Phys.Med. 1957;4:104-106.
- (24) Dyck PJ, Lambert EH. Lower motor and primary sensory neuron diseases with peroneal muscular atrophy. II. Neurologic, genetic, and electrophysiologic findings in various neuronal degenerations. Arch.Neurol. 1968 Jun;18(6):619-625.
- (25) Dyck PJ, Lambert EH. Lower motor and primary sensory neuron diseases with peroneal muscular atrophy. I. Neurologic, genetic, and electrophysiologic findings in hereditary polyneuropathies. Arch.Neurol. 1968 Jun;18(6):603-618.
- (26) Harding AE, Thomas PK. The clinical features of hereditary motor and sensory neuropathy types I and II. Brain 1980 Jun;103(2):259-280.
- (27) Gamstorp I. Polyneuropathy in childhood. Acta Paediatr Scand 1968;57:230-238.
- (28) Evans OB. Polyneuropathy in childhood. Pediatrics 1979 Jul;64(1):96-105.
- (29) Hagberg B, Lyon G. Pooled European series of hereditary peripheral neuropathies in infancy and childhood. A "correspondence work shop" report of the European Federation of Child Neurology Societies (EFCNS). Neuropediatrics 1981 Feb;12(1):9-17.
- (30) Hagberg B, Westerberg B. The nosology of genetic peripheral neuropathies in Swedish children. Dev.Med.Child Neurol. 1983 Feb;25(1):3-18.
- (31) Rossi LN, Lutschg J, Meier C, Vassella F. Hereditary motor sensory neuropathies in childhood. Dev.Med.Child Neurol. 1983 Feb;25(1):19-31.
- (32) Ouvrier RA, McLeod JG. Chronic peripheral neuropathy in childhood: an overview. Aust.Paediatr.J. 1988;24 Suppl 1:80-82.
- (33) Emery AE. Population frequencies of inherited neuromuscular diseases--a world survey. Neuromuscul.Disord. 1991;1(1):19-29.
- (34) Martyn CN, Hughes RA. Epidemiology of peripheral neuropathy. J.Neurol.Neurosurg.Psychiatry. 1997 Apr;62(4):310-318.
- (35) Holmberg BH, Holmgren G, Nelis E, van Broeckhoven C, Westerberg B. Charcot-Marie-Tooth disease in northern Sweden: pedigree analysis and the presence of the duplication in chromosome 17p11.2. J.Med.Genet. 1994 Jun;31(6):435-441.
- (36) Nelis E, Van Broeckhoven C, De Jonghe P, Lofgren A, Vandenberghe A, Latour P, et al. Estimation of the mutation frequencies in Charcot-Marie-Tooth disease type 1 and hereditary neuropathy with liability to pressure palsies: a European collaborative study. Eur.J.Hum.Genet. 1996;4(1):25-33.
- (37) Skre H. Genetic and clinical aspects of Charcot-Marie-Tooth's disease. Clin.Genet. 1974;6(2):98-118.
- (38) Lupski JR, de Oca-Luna RM, Slaugenhaupt S, Pentao L, Guzzetta V, Trask BJ, et al. DNA duplication associated with Charcot-Marie-Tooth disease type 1A. Cell 1991 Jul 26;66(2):219-232.
- (39) Raeymaekers P, Timmerman V, Nelis E, De Jonghe P, Hoogendijk JE, Baas F, et al. Duplication in chromosome 17p11.2 in Charcot-Marie-Tooth neuropathy type 1a (CMT 1a). The HMSN Collaborative Research Group. Neuromuscul.Disord. 1991;1(2):93-97.

- (40) Gene table of monogenic neuromuscular disorders (nuclear genome only) Vol. 18 No. 1, January 2008. *Neuromuscul.Disord.* 2008 Jan;18(1):101-129.
- (41) Kuhlensbaumer G, Young P, Hunermund G, Ringelstein B, Stogbauer F. Clinical features and molecular genetics of hereditary peripheral neuropathies. *J.Neurol.* 2002 Dec;249(12):1629-1650.
- (42) Chaouch M, Allal Y, De Sandre-Giovannoli A, Vallat JM, Amer-el-Khedoud A, Kassouri N, et al. The phenotypic manifestations of autosomal recessive axonal Charcot-Marie-Tooth due to a mutation in Lamin A/C gene. *Neuromuscul.Disord.* 2003 Jan;13(1):60-67.
- (43) Chapon F, Latour P, Diraison P, Schaeffer S, Vandenberghe A. Axonal phenotype of Charcot-Marie-Tooth disease associated with a mutation in the myelin protein zero gene. *J.Neurol.Neurosurg.Psychiatry.* 1999 Jun;66(6):779-782.
- (44) Ouvrier RA, McLeod JG, Pollard JD. The peroneal atrophy syndrome. In: Procopis P, editor. *Peripheral Neuropathy in Childhood.* 2nd ed. London: MacKeith Press; 1999. p. 67-135.
- (45) Scherer S. Axonal pathology in demyelinating diseases. *Ann.Neurol.* 1999 Jan;45(1):6-7.
- (46) Krajewski KM, Lewis RA, Fuerst DR, Turansky C, Hinderer SR, Garbern J, et al. Neurological dysfunction and axonal degeneration in Charcot-Marie-Tooth disease type 1A. *Brain* 2000 Jul;123 (Pt 7)(Pt 7):1516-1527.
- (47) Kamholz J, Menichella D, Jani A, Garbern J, Lewis RA, Krajewski KM, et al. Charcot-Marie-Tooth disease type 1: molecular pathogenesis to gene therapy. *Brain* 2000 Feb;123 (Pt 2)(Pt 2):222-233.
- (48) Pareyson D, Scaiola V, Laura M. Clinical and electrophysiological aspects of Charcot-Marie-Tooth disease. *Neuromolecular Med.* 2006;8(1-2):3-22.
- (49) Houlden H, Reilly MM. Molecular genetics of autosomal-dominant demyelinating Charcot-Marie-Tooth disease. *Neuromolecular Med.* 2006;8(1-2):43-62.
- (50) Vance JM, Nicholson GA, Yamaoka LH, Stajich J, Stewart CS, Speer MC, et al. Linkage of Charcot-Marie-Tooth neuropathy type 1a to chromosome 17. *Exp.Neurol.* 1989 May;104(2):186-189.
- (51) Patel PI, Roa BB, Welcher AA, Schoener-Scott R, Trask BJ, Pentao L, et al. The gene for the peripheral myelin protein PMP-22 is a candidate for Charcot-Marie-Tooth disease type 1A. *Nat.Genet.* 1992 Jun;1(3):159-165.
- (52) Matsunami N, Smith B, Ballard L, Lensch MW, Robertson M, Albertsen H, et al. Peripheral myelin protein-22 gene maps in the duplication in chromosome 17p11.2 associated with Charcot-Marie-Tooth 1A. *Nat.Genet.* 1992 Jun;1(3):176-179.
- (53) Timmerman V, Nelis E, Van Hul W, Nieuwenhuijsen BW, Chen KL, Wang S, et al. The peripheral myelin protein gene PMP-22 is contained within the Charcot-Marie-Tooth disease type 1A duplication. *Nat.Genet.* 1992 Jun;1(3):171-175.
- (54) Valentijn LJ, Bolhuis PA, Zorn I, Hoogendijk JE, van den Bosch N, Hensels GW, et al. The peripheral myelin gene PMP-22/GAS-3 is duplicated in Charcot-Marie-Tooth disease type 1A. *Nat.Genet.* 1992 Jun;1(3):166-170.
- (55) Roa BB, Lupski JR. Molecular basis of Charcot-Marie-Tooth disease type 1A: gene dosage as a novel mechanism for a common autosomal dominant condition. *Am.J.Med.Sci.* 1993 Sep;306(3):177-184.
- (56) Bird TD, Ott J, Giblett ER. Evidence for linkage of Charcot-Marie-Tooth neuropathy to the Duffy locus on chromosome 1. *Am.J.Hum.Genet.* 1982 May;34(3):388-394.
- (57) Guiloff RJ, Thomas PK, Contreras M, Armitage S, Schwarz G, Sedgwick EM. Evidence for linkage of type I hereditary motor and sensory neuropathy to the Duffy locus on chromosome 1. *Ann.Hum.Genet.* 1982 Jan 1;46(Pt 1):25-27.

- (58) Hayasaka K, Himoro M, Sato W, Takada G, Uyemura K, Shimizu N, et al. Charcot-Marie-Tooth neuropathy type 1B is associated with mutations of the myelin P0 gene. *Nat.Genet.* 1993 Sep;5(1):31-34.
- (59) Kulkens T, Bolhuis PA, Wolterman RA, Kemp S, te Nijenhuis S, Valentijn LJ, et al. Deletion of the serine 34 codon from the major peripheral myelin protein P0 gene in Charcot-Marie-Tooth disease type 1B. *Nat.Genet.* 1993 Sep;5(1):35-39.
- (60) Street VA, Bennett CL, Goldy JD, Shirk AJ, Kleopa KA, Tempel BL, et al. Mutation of a putative protein degradation gene LITAF/SIMPLE in Charcot-Marie-Tooth disease 1C. *Neurology* 2003 Jan 14;60(1):22-26.
- (61) Street VA, Bennett CL, Bird TD, Chance PF. New gene for CMT. *J.Peripher.Nerv.Syst.* 2003 Dec;8(4):206.
- (62) Warner LE, Mancias P, Butler IJ, McDonald CM, Keppen L, Koob KG, et al. Mutations in the early growth response 2 (EGR2) gene are associated with hereditary myelinopathies. *Nat.Genet.* 1998 Apr;18(4):382-384.
- (63) Kovach MJ, Lin JP, Boyadjiev S, Campbell K, Mazzeo L, Herman K, et al. A unique point mutation in the PMP22 gene is associated with Charcot-Marie-Tooth disease and deafness. *Am.J.Hum.Genet.* 1999 Jun;64(6):1580-1593.
- (64) Boerkoel CF, Takashima H, Garcia CA, Olney RK, Johnson J, Berry K, et al. Charcot-Marie-Tooth disease and related neuropathies: mutation distribution and genotype-phenotype correlation. *Ann.Neurol.* 2002 Feb;51(2):190-201.
- (65) Jordanova A, De Jonghe P, Boerkoel CF, Takashima H, De Vriendt E, Ceuterick C, et al. Mutations in the neurofilament light chain gene (NEFL) cause early onset severe Charcot-Marie-Tooth disease. *Brain* 2003 Mar;126(Pt 3):590-597.
- (66) Chance PF, Alderson MK, Leppig KA, Lensch MW, Matsunami N, Smith B, et al. DNA deletion associated with hereditary neuropathy with liability to pressure palsies. *Cell* 1993 Jan 15;72(1):143-151.
- (67) Nicholson GA, Valentijn LJ, Cherryson AK, Kennerson ML, Bragg TL, DeKroon RM, et al. A frame shift mutation in the PMP22 gene in hereditary neuropathy with liability to pressure palsies. *Nat.Genet.* 1994 Mar;6(3):263-266.
- (68) Mariman EC, Gabreels-Festen AA, van Beersum SE, Jongen PJ, van de Looij E, Baas F, et al. Evidence for genetic heterogeneity underlying hereditary neuropathy with liability to pressure palsies. *Hum.Genet.* 1994 Feb;93(2):151-156.
- (69) Verhoeven K, De Jonghe P, Van de Putte T, Nelis E, Zwijsen A, Verpoorten N, et al. Slowed conduction and thin myelination of peripheral nerves associated with mutant rho Guanine-nucleotide exchange factor 10. *Am.J.Hum.Genet.* 2003 Oct;73(4):926-932.
- (70) De Jonghe P, Timmerman V, Nelis E, De Vriendt E, Lofgren A, Ceuterick C, et al. A novel type of hereditary motor and sensory neuropathy characterized by a mild phenotype. *Arch.Neurol.* 1999 Oct;56(10):1283-1288.
- (71) Barhoumi C, Amouri R, Ben Hamida C, Ben Hamida M, Machghoul S, Gueddiche M, et al. Linkage of a new locus for autosomal recessive axonal form of Charcot-Marie-Tooth disease to chromosome 8q21.3. *Neuromuscul.Disord.* 2001 Jan;11(1):27-34.
- (72) Zuchner S, Vance JM. Molecular genetics of autosomal-dominant axonal Charcot-Marie-Tooth disease. *Neuromolecular Med.* 2006;8(1-2):63-74.
- (73) Bernard R, De Sandre-Giovannoli A, Delague V, Levy N. Molecular genetics of autosomal-recessive axonal Charcot-Marie-Tooth neuropathies. *Neuromolecular Med.* 2006;8(1-2):87-106.

- (74) Kabzinska D, Hausmanowa-Petrusewicz I, Kochanski A. Charcot-Marie-Tooth disorders with an autosomal recessive mode of inheritance. *Clin.Neuropathol.* 2008 Jan-Feb;27(1):1-12.
- (75) Banchs I, Casasnovas C, Montero J, Martinez-Matos JA, Volpini V. Two spanish families with Charcot-Marie-Tooth type 2A: Clinical, electrophysiological and molecular findings. *Neuromuscul.Disord.* 2008 Nov 7.
- (76) Brockmann K, Dreha-Kulaczewski S, Dechent P, Bonnemann C, Helms G, Kyllerman M, et al. Cerebral involvement in axonal Charcot-Marie-Tooth neuropathy caused by mitofusin2 mutations. *J.Neurol.* 2008 Jul;255(7):1049-1058.
- (77) Zuchner S, De Jonghe P, Jordanova A, Claeys KG, Guergueltcheva V, Cherninkova S, et al. Axonal neuropathy with optic atrophy is caused by mutations in mitofusin 2. *Ann.Neurol.* 2006 Feb;59(2):276-281.
- (78) Fabrizi GM, Cavallaro T, Angiari C, Bertolasi L, Cabrini I, Ferrarini M, et al. Giant axon and neurofilament accumulation in Charcot-Marie-Tooth disease type 2E. *Neurology* 2004 Apr 27;62(8):1429-1431.
- (79) Zhao C, Takita J, Tanaka Y, Setou M, Nakagawa T, Takeda S, et al. Charcot-Marie-Tooth disease type 2A caused by mutation in a microtubule motor KIF1Bbeta. *Cell* 2001 Jun 1;105(5):587-597.
- (80) Ben Othmane K, Middleton LT, Loprest LJ, Wilkinson KM, Lennon F, Rozeau MP, et al. Localization of a gene (CMT2A) for autosomal dominant Charcot-Marie-Tooth disease type 2 to chromosome 1p and evidence of genetic heterogeneity. *Genomics* 1993 Aug;17(2):370-375.
- (81) Zuchner S, Mersiyanova IV, Muglia M, Bissar-Tadmouri N, Rochelle J, Dadali EL, et al. Mutations in the mitochondrial GTPase mitofusin 2 cause Charcot-Marie-Tooth neuropathy type 2A. *Nat.Genet.* 2004 May;36(5):449-451.
- (82) Kwon JM, Elliott JL, Yee WC, Ivanovich J, Scavarda NJ, Moolsintong PJ, et al. Assignment of a second Charcot-Marie-Tooth type II locus to chromosome 3q. *Am.J.Hum.Genet.* 1995 Oct;57(4):853-858.
- (83) Pericak-Vance MA, Speer MC, Lennon F, West SG, Menold MM, Stajich JM, et al. Confirmation of a second locus for CMT2 and evidence for additional genetic heterogeneity. *Neurogenetics* 1997 Sep;1(2):89-93.
- (84) Spinosa MR, Progida C, De Luca A, Colucci AM, Alifano P, Bucci C. Functional characterization of Rab7 mutant proteins associated with Charcot-Marie-Tooth type 2B disease. *J.Neurosci.* 2008 Feb 13;28(7):1640-1648.
- (85) Bouhouche A, Birouk N, Azzedine H, Benomar A, Durosier G, Ente D, et al. Autosomal recessive axonal Charcot-Marie-Tooth disease (ARCMT2): phenotype-genotype correlations in 13 Moroccan families. *Brain* 2007 Apr;130(Pt 4):1062-1075.
- (86) De Sandre-Giovannoli A, Chaouch M, Kozlov S, Vallat JM, Tazir M, Kassouri N, et al. Homozygous defects in LMNA, encoding lamin A/C nuclear-envelope proteins, cause autosomal recessive axonal neuropathy in human (Charcot-Marie-Tooth disorder type 2) and mouse. *Am.J.Hum.Genet.* 2002 Mar;70(3):726-736.
- (87) Worman HJ, Bonne G. "Laminopathies": a wide spectrum of human diseases. *Exp.Cell Res.* 2007 Jun 10;313(10):2121-2133.
- (88) Leal A, Morera B, Del Valle G, Heuss D, Kayser C, Berghoff M, et al. A second locus for an axonal form of autosomal recessive Charcot-Marie-Tooth disease maps to chromosome 19q13.3. *Am.J.Hum.Genet.* 2001 Jan;68(1):269-274.
- (89) Berghoff C, Berghoff M, Leal A, Morera B, Barrantes R, Reis A, et al. Clinical and electrophysiological characteristics of autosomal recessive axonal Charcot-Marie-Tooth disease (ARCMT2B) that maps to chromosome 19q13.3. *Neuromuscul.Disord.* 2004 May;14(5):301-306.

- (90) Klein CJ, Cunningham JM, Atkinson EJ, Schaid DJ, Hebbring SJ, Anderson SA, et al. The gene for HMSN2C maps to 12q23-24: a region of neuromuscular disorders. *Neurology* 2003 Apr 8;60(7):1151-1156.
- (91) McEntagart ME, Reid SL, Irrthum A, Douglas JB, Eyre KE, Donaghy MJ, et al. Confirmation of a hereditary motor and sensory neuropathy IIC locus at chromosome 12q23-q24. *Ann.Neurol.* 2005 Feb;57(2):293-297.
- (92) Antonellis A, Ellsworth RE, Sambuughin N, Puls I, Abel A, Lee-Lin SQ, et al. Glycyl tRNA synthetase mutations in Charcot-Marie-Tooth disease type 2D and distal spinal muscular atrophy type V. *Am.J.Hum.Genet.* 2003 May;72(5):1293-1299.
- (93) Ionasescu V, Searby C, Sheffield VC, Roklina T, Nishimura D, Ionasescu R. Autosomal dominant Charcot-Marie-Tooth axonal neuropathy mapped on chromosome 7p (CMT2D). *Hum.Mol.Genet.* 1996 Sep;5(9):1373-1375.
- (94) Evgrafov OV, Mersiyanova I, Irobi J, Van Den Bosch L, Dierick I, Leung CL, et al. Mutant small heat-shock protein 27 causes axonal Charcot-Marie-Tooth disease and distal hereditary motor neuropathy. *Nat.Genet.* 2004 Jun;36(6):602-606.
- (95) Ismailov SM, Fedotov VP, Dadali EL, Polyakov AV, Van Broeckhoven C, Ivanov VI, et al. A new locus for autosomal dominant Charcot-Marie-Tooth disease type 2 (CMT2F) maps to chromosome 7q11-q21. *Eur.J.Hum.Genet.* 2001 Aug;9(8):646-650.
- (96) Nelis E, Berciano J, Verpoorten N, Coen K, Dierick I, Van Gerwen V, et al. Autosomal dominant axonal Charcot-Marie-Tooth disease type 2 (CMT2G) maps to chromosome 12q12-q13.3. *J.Med.Genet.* 2004 Mar;41(3):193-197.
- (97) Auer-Grumbach M, Strasser-Fuchs S, Robl T, Windpassinger C, Wagner K. Late onset Charcot-Marie-Tooth 2 syndrome caused by two novel mutations in the MPZ gene. *Neurology* 2003 Nov 25;61(10):1435-1437.
- (98) De Jonghe P, Timmerman V, Ceuterick C, Nelis E, De Vriendt E, Lofgren A, et al. The Thr124Met mutation in the peripheral myelin protein zero (MPZ) gene is associated with a clinically distinct Charcot-Marie-Tooth phenotype. *Brain* 1999 Feb;122 (Pt 2)(Pt 2):281-290.
- (99) Claramunt R, Pedrola L, Sevilla T, Lopez de Munain A, Berciano J, Cuesta A, et al. Genetics of Charcot-Marie-Tooth disease type 4A: mutations, inheritance, phenotypic variability, and founder effect. *J.Med.Genet.* 2005 Apr;42(4):358-365.
- (100) Birouk N, Azzedine H, Dubourg O, Muriel MP, Benomar A, Hamadouche T, et al. Phenotypical features of a Moroccan family with autosomal recessive Charcot-Marie-Tooth disease associated with the S194X mutation in the GDAP1 gene. *Arch.Neurol.* 2003 Apr;60(4):598-604.
- (101) Tang BS, Luo W, Xia K, Xiao JF, Jiang H, Shen L, et al. A new locus for autosomal dominant Charcot-Marie-Tooth disease type 2 (CMT2L) maps to chromosome 12q24. *Hum.Genet.* 2004 May;114(6):527-533.
- (102) Gabreels-Festen AA, Joosten EM, Gabreels FJ, Jennekens FG, Gooskens RH, Stegeman DF. Hereditary motor and sensory neuropathy of neuronal type with onset in early childhood. *Brain* 1991 Aug;114 (Pt 4)(Pt 4):1855-1870.
- (103) Ouvrier RA, McLeod JG, Morgan GJ, Wise GA, Conchin TE. Hereditary motor and sensory neuropathy of neuronal type with onset in early childhood. *J.Neurol.Sci.* 1981 Aug;51(2):181-197.
- (104) Nicholson GA, Magdelaine C, Zhu D, Grew S, Ryan MM, Sturtz F, et al. Severe early-onset axonal neuropathy with homozygous and compound heterozygous MFN2 mutations. *Neurology* 2008 May 6;70(19):1678-1681.
- (105) Vallat JM, Ouvrier RA, Pollard JD, Magdelaine C, Zhu D, Nicholson GA, et al. Histopathological Findings in Hereditary Motor and Sensory Neuropathy of Axonal Type With Onset

in Early Childhood Associated With Mitofusin 2 Mutations. *J.Neuropathol.Exp.Neurol.* 2008 Nov;67(11):1097-1102.

(106) Wilmshurst JM, Bye A, Rittey C, Adams C, Hahn AF, Ramsay D, et al. Severe infantile axonal neuropathy with respiratory failure. *Muscle Nerve* 2001 Jun;24(6):760-768.

(107) Kaindl AM, Guenther UP, Rudnik-Schoneborn S, Varon R, Zerres K, Schuelke M, et al. Spinal muscular atrophy with respiratory distress type 1 (SMARD1). *J.Child Neurol.* 2008 Feb;23(2):199-204.

(108) Grohmann K, Schuelke M, Diers A, Hoffmann K, Lucke B, Adams C, et al. Mutations in the gene encoding immunoglobulin mu-binding protein 2 cause spinal muscular atrophy with respiratory distress type 1. *Nat.Genet.* 2001 Sep;29(1):75-77.

(109) Takashima H, Nakagawa M, Suehara M, Saito M, Saito A, Kanzato N, et al. Gene for hereditary motor and sensory neuropathy (proximal dominant form) mapped to 3q13.1. *Neuromuscul.Disord.* 1999 Oct;9(6-7):368-371.

(110) Takashima H, Nakagawa M, Nakahara K, Suehara M, Matsuzaki T, Higuchi I, et al. A new type of hereditary motor and sensory neuropathy linked to chromosome 3. *Ann.Neurol.* 1997 Jun;41(6):771-780.

(111) Roa BB, Dyck PJ, Marks HG, Chance PF, Lupski JR. Dejerine-Sottas syndrome associated with point mutation in the peripheral myelin protein 22 (PMP22) gene. *Nat.Genet.* 1993 Nov;5(3):269-273.

(112) Hayasaka K, Himoro M, Wang Y, Takata M, Minoshima S, Shimizu N, et al. Structure and chromosomal localization of the gene encoding the human myelin protein zero (MPZ). *Genomics* 1993 Sep;17(3):755-758.

(113) Boerkoel CF, Takashima H, Stankiewicz P, Garcia CA, Leber SM, Rhee-Morris L, et al. Periaxin mutations cause recessive Dejerine-Sottas neuropathy. *Am.J.Hum.Genet.* 2001 Feb;68(2):325-333.

(114) Chung KW, Sunwoo IN, Kim SM, Park KD, Kim WK, Kim TS, et al. Two missense mutations of EGR2 R359W and GJB1 V136A in a Charcot-Marie-Tooth disease family. *Neurogenetics* 2005 Sep;6(3):159-163.

(115) Dubourg O, Azzedine H, Verny C, Durosier G, Birouk N, Gouider R, et al. Autosomal-recessive forms of demyelinating Charcot-Marie-Tooth disease. *Neuromolecular Med.* 2006;8(1-2):75-86.

(116) Ouvrier R, Geevasingha N, Ryan MM. Autosomal-recessive and X-linked forms of hereditary motor and sensory neuropathy in childhood. *Muscle Nerve* 2007 Aug;36(2):131-143.

(117) Zhang X, Chow CY, Sahenk Z, Shy ME, Meisler MH, Li J. Mutation of FIG4 causes a rapidly progressive, asymmetric neuronal degeneration. *Brain* 2008 Aug;131(Pt 8):1990-2001.

(118) Ben Othmane K, Hentati F, Lennon F, Ben Hamida C, Blel S, Roses AD, et al. Linkage of a locus (CMT4A) for autosomal recessive Charcot-Marie-Tooth disease to chromosome 8q. *Hum.Mol.Genet.* 1993 Oct;2(10):1625-1628.

(119) Baxter RV, Ben Othmane K, Rochelle JM, Stajich JE, Hulette C, Dew-Knight S, et al. Ganglioside-induced differentiation-associated protein-1 is mutant in Charcot-Marie-Tooth disease type 4A/8q21. *Nat.Genet.* 2002 Jan;30(1):21-22.

(120) Cuesta A, Pedrola L, Sevilla T, Garcia-Planells J, Chumillas MJ, Mayordomo F, et al. The gene encoding ganglioside-induced differentiation-associated protein 1 is mutated in axonal Charcot-Marie-Tooth type 4A disease. *Nat.Genet.* 2002 Jan;30(1):22-25.

(121) Bolino A, Brancolini V, Bono F, Bruni A, Gambardella A, Romeo G, et al. Localization of a gene responsible for autosomal recessive demyelinating neuropathy with focally folded myelin sheaths to chromosome 11q23 by homozygosity mapping and haplotype sharing. *Hum.Mol.Genet.* 1996 Jul;5(7):1051-1054.

(122) Previtali SC, Zerega B, Sherman DL, Brophy PJ, Dina G, King RH, et al. Myotubularin-related 2 protein phosphatase and neurofilament light chain protein, both mutated in CMT neuropathies, interact in peripheral nerve. *Hum.Mol.Genet.* 2003 Jul 15;12(14):1713-1723.

(123) Bolino A, Muglia M, Conforti FL, LeGuern E, Salih MA, Georgiou DM, et al. Charcot-Marie-Tooth type 4B is caused by mutations in the gene encoding myotubularin-related protein-2. *Nat.Genet.* 2000 May;25(1):17-19.

(124) Gabreels-Festen AA, Hoogendijk JE, Meijerink PH, Gabreels FJ, Bolhuis PA, van Beersum S, et al. Two divergent types of nerve pathology in patients with different P0 mutations in Charcot-Marie-Tooth disease. *Neurology* 1996 Sep;47(3):761-765.

(125) Azzedine H, Bolino A, Taieb T, Birouk N, Di Duca M, Bouhouche A, et al. Mutations in MTMR13, a new pseudophosphatase homologue of MTMR2 and Sbf1, in two families with an autosomal recessive demyelinating form of Charcot-Marie-Tooth disease associated with early-onset glaucoma. *Am.J.Hum.Genet.* 2003 May;72(5):1141-1153.

(126) Senderek J, Bergmann C, Weber S, Ketelsen UP, Schorle H, Rudnik-Schoneborn S, et al. Mutation of the SBF2 gene, encoding a novel member of the myotubularin family, in Charcot-Marie-Tooth neuropathy type 4B2/11p15. *Hum.Mol.Genet.* 2003 Feb 1;12(3):349-356.

(127) LeGuern E, Guilbot A, Kessali M, Ravise N, Tassin J, Maisonobe T, et al. Homozygosity mapping of an autosomal recessive form of demyelinating Charcot-Marie-Tooth disease to chromosome 5q23-q33. *Hum.Mol.Genet.* 1996 Oct;5(10):1685-1688.

(128) Senderek J, Bergmann C, Stendel C, Kirfel J, Verpoorten N, De Jonghe P, et al. Mutations in a gene encoding a novel SH3/TPR domain protein cause autosomal recessive Charcot-Marie-Tooth type 4C neuropathy. *Am.J.Hum.Genet.* 2003 Nov;73(5):1106-1119.

(129) Angelicheva D, Turnev I, Dye D, Chandler D, Thomas PK, Kalaydjieva L. Congenital cataracts facial dysmorphism neuropathy (CCFDN) syndrome: a novel developmental disorder in Gypsies maps to 18qter. *Eur.J.Hum.Genet.* 1999 Jul;7(5):560-566.

(130) Kalaydjieva L, Gresham D, Gooding R, Heather L, Baas F, de Jonge R, et al. N-myc downstream-regulated gene 1 is mutated in hereditary motor and sensory neuropathy-Lom. *Am.J.Hum.Genet.* 2000 Jul;67(1):47-58.

(131) Warner LE, Hilz MJ, Appel SH, Killian JM, Kolodry EH, Karpati G, et al. Clinical phenotypes of different MPZ (P0) mutations may include Charcot-Marie-Tooth type 1B, Dejerine-Sottas, and congenital hypomyelination. *Neuron* 1996 Sep;17(3):451-460.

(132) Delague V, Bareil C, Tuffery S, Bouvagnet P, Chouery E, Koussa S, et al. Mapping of a new locus for autosomal recessive demyelinating Charcot-Marie-Tooth disease to 19q13.1-13.3 in a large consanguineous Lebanese family: exclusion of MAG as a candidate gene. *Am.J.Hum.Genet.* 2000 Jul;67(1):236-243.

(133) Guilbot A, Williams A, Ravise N, Verny C, Brice A, Sherman DL, et al. A mutation in periaxin is responsible for CMT4F, an autosomal recessive form of Charcot-Marie-Tooth disease. *Hum.Mol.Genet.* 2001 Feb 15;10(4):415-421.

(134) Thomas PK, Kalaydjieva L, Youl B, Rogers T, Angelicheva D, King RH, et al. Hereditary motor and sensory neuropathy-russe: new autosomal recessive neuropathy in Balkan Gypsies. *Ann.Neurol.* 2001 Oct;50(4):452-457.

(135) Rogers T, Chandler D, Angelicheva D, Thomas PK, Youl B, Tournev I, et al. A novel locus for autosomal recessive peripheral neuropathy in the EGR2 region on 10q23. *Am.J.Hum.Genet.* 2000 Sep;67(3):664-671.

(136) De Sandre-Giovannoli A, Delague V, Hamadouche T, Chaouch M, Krahn M, Boccaccio I, et al. Homozygosity mapping of autosomal recessive demyelinating Charcot-Marie-Tooth neuropathy (CMT4H) to a novel locus on chromosome 12p11.21-q13.11. *J.Med.Genet.* 2005 Mar;42(3):260-265.

- (137) Delague V, Jacquier A, Hamadouche T, Poitelon Y, Baudot C, Boccaccio I, et al. Mutations in FGD4 encoding the Rho GDP/GTP exchange factor FRABIN cause autosomal recessive Charcot-Marie-Tooth type 4H. *Am.J.Hum.Genet.* 2007 Jul;81(1):1-16.
- (138) Stendel C, Roos A, Deconinck T, Pereira J, Castagner F, Niemann A, et al. Peripheral nerve demyelination caused by a mutant Rho GTPase guanine nucleotide exchange factor, frabin/FGD4. *Am.J.Hum.Genet.* 2007 Jul;81(1):158-164.
- (139) Chow CY, Zhang Y, Dowling JJ, Jin N, Adamska M, Shiga K, et al. Mutation of FIG4 causes neurodegeneration in the pale tremor mouse and patients with CMT4J. *Nature* 2007 Jul 5;448(7149):68-72.
- (140) Varon R, Gooding R, Steglich C, Marns L, Tang H, Angelicheva D, et al. Partial deficiency of the C-terminal-domain phosphatase of RNA polymerase II is associated with congenital cataracts facial dysmorphism neuropathy syndrome. *Nat.Genet.* 2003 Oct;35(2):185-189.
- (141) Kleopa KA, Scherer SS. Molecular genetics of X-linked Charcot-Marie-Tooth disease. *Neuromolecular Med.* 2006;8(1-2):107-122.
- (142) Priest JM, Fischbeck KH, Nouri N, Keats BJ. A locus for axonal motor-sensory neuropathy with deafness and mental retardation maps to Xq24-q26. *Genomics* 1995 Sep 20;29(2):409-412.
- (143) Rosenberg RN, Chutorian A. Familial opticoacoustic nerve degeneration and polyneuropathy. *Neurology* 1967 Sep;17(9):827-832.
- (144) Bergoffen J, Trofatter J, Pericak-Vance MA, Haines JL, Chance PF, Fischbeck KH. Linkage localization of X-linked Charcot-Marie-Tooth disease. *Am.J.Hum.Genet.* 1993 Feb;52(2):312-318.
- (145) Bone LJ, Dahl N, Lensch MW, Chance PF, Kelly T, Le Guern E, et al. New connexin32 mutations associated with X-linked Charcot-Marie-Tooth disease. *Neurology* 1995 Oct;45(10):1863-1866.
- (146) Ionasescu VV. Charcot-Marie-Tooth neuropathies: from clinical description to molecular genetics. *Muscle Nerve* 1995 Mar;18(3):267-275.
- (147) Brewer M, Changi F, Antonellis A, Fischbeck K, Polly P, Nicholson G, et al. Evidence of a founder haplotype refines the X-linked Charcot-Marie-Tooth (CMTX3) locus to a 2.5 Mb region. *Neurogenetics* 2008 Jul;9(3):191-195.
- (148) Kim HJ, Hong SH, Ki CS, Kim BJ, Shim JS, Cho SH, et al. A novel locus for X-linked recessive CMT with deafness and optic neuropathy maps to Xq21.32-q24. *Neurology* 2005 Jun 14;64(11):1964-1967.
- (149) Kim HJ, Sohn KM, Shy ME, Krajewski KM, Hwang M, Park JH, et al. Mutations in PRPS1, which encodes the phosphoribosyl pyrophosphate synthetase enzyme critical for nucleotide biosynthesis, cause hereditary peripheral neuropathy with hearing loss and optic neuropathy (cmtx5). *Am.J.Hum.Genet.* 2007 Sep;81(3):552-558.
- (150) Nicholson G, Myers S. Intermediate forms of Charcot-Marie-Tooth neuropathy: a review. *Neuromolecular Med.* 2006;8(1-2):123-130.
- (151) Senderek J, Bergmann C, Ramaekers VT, Nelis E, Bernert G, Makowski A, et al. Mutations in the ganglioside-induced differentiation-associated protein-1 (GDAP1) gene in intermediate type autosomal recessive Charcot-Marie-Tooth neuropathy. *Brain* 2003 Mar;126(Pt 3):642-649.
- (152) Rossi A, Paradiso C, Cioni R, Rizzuto N, Guazzi G. Charcot-Marie-Tooth disease: study of a large kinship with an intermediate form. *J.Neurol.* 1985;232(2):91-98.
- (153) Villanova M, Timmerman V, De Jonghe P, Malandrini A, Rizzuto N, Van Broeckhoven C, et al. Charcot-Marie-Tooth disease: an intermediate form. *Neuromuscul.Disord.* 1998 Aug;8(6):392-393.

- (154) Verhoeven K, Villanova M, Rossi A, Malandrini A, De Jonghe P, Timmerman V. Localization of the gene for the intermediate form of Charcot-Marie-Tooth to chromosome 10q24.1-q25.1. *Am.J.Hum.Genet.* 2001 Oct;69(4):889-894.
- (155) Rouger H, LeGuern E, Birouk N, Gouider R, Tardieu S, Plassart E, et al. Charcot-Marie-Tooth disease with intermediate motor nerve conduction velocities: characterization of 14 Cx32 mutations in 35 families. *Hum.Mutat.* 1997;10(6):443-452.
- (156) Zuchner S, Noureddine M, Kennerson M, Verhoeven K, Claeys K, De Jonghe P, et al. Mutations in the pleckstrin homology domain of dynamin 2 cause dominant intermediate Charcot-Marie-Tooth disease. *Nat.Genet.* 2005 Mar;37(3):289-294.
- (157) Jordanova A, Thomas FP, Guergueltcheva V, Tournev I, Gondim FA, Ishpekova B, et al. Dominant intermediate Charcot-Marie-Tooth type C maps to chromosome 1p34-p35. *Am.J.Hum.Genet.* 2003 Dec;73(6):1423-1430.
- (158) Jordanova A, Irobi J, Thomas FP, Van Dijk P, Meerschaert K, Dewil M, et al. Disrupted function and axonal distribution of mutant tyrosyl-tRNA synthetase in dominant intermediate Charcot-Marie-Tooth neuropathy. *Nat.Genet.* 2006 Feb;38(2):197-202.
- (159) Mastaglia FL, Nowak KJ, Stell R, Phillips BA, Edmondston JE, Dorosz SM, et al. Novel mutation in the myelin protein zero gene in a family with intermediate hereditary motor and sensory neuropathy. *J.Neurol.Neurosurg.Psychiatry.* 1999 Aug;67(2):174-179.
- (160) Mersyanova IV, Perepelov AV, Polyakov AV, Sitnikov VF, Dadali EL, Oparin RB, et al. A new variant of Charcot-Marie-Tooth disease type 2 is probably the result of a mutation in the neurofilament-light gene. *Am.J.Hum.Genet.* 2000 Jul;67(1):37-46.
- (161) Nelis E, Erdem S, Van Den Bergh PY, Belpaire-Dethiou MC, Ceuterick C, Van Gerwen V, et al. Mutations in GDAP1: autosomal recessive CMT with demyelination and axonopathy. *Neurology* 2002 Dec 24;59(12):1865-1872.
- (162) Sevilla T, Cuesta A, Chumillas MJ, Mayordomo F, Pedrola L, Palau F, et al. Clinical, electrophysiological and morphological findings of Charcot-Marie-Tooth neuropathy with vocal cord palsy and mutations in the GDAP1 gene. *Brain* 2003 Sep;126(Pt 9):2023-2033.
- (163) Irobi J, De Jonghe P, Timmerman V. Molecular genetics of distal hereditary motor neuropathies. *Hum.Mol.Genet.* 2004 Oct 1;13 Spec No 2:R195-202.
- (164) Zhu D, Kennerson ML, Walizada G, Zuchner S, Vance JM, Nicholson GA. Charcot-Marie-Tooth with pyramidal signs is genetically heterogeneous: families with and without MFN2 mutations. *Neurology* 2005 Aug 9;65(3):496-497.
- (165) Barreira AA, Junior EC, Junior WM, Herrera RF. Hereditary sensorimotor neuropathy associated with optic atrophy (type VI HMSN). *J.Neurol.Sci.* 1990;98 9suppl):366 (abstract).
- (166) Sommer C, Schroder JM. Hereditary motor and sensory neuropathy with optic atrophy. Ultrastructural and morphometric observations on nerve fibers, mitochondria, and dense-cored vesicles. *Arch.Neurol.* 1989 Sep;46(9):973-977.
- (167) Schroder JM, Sommer C. Mitochondrial abnormalities in human sural nerves: fine structural evaluation of cases with mitochondrial myopathy, hereditary and non-hereditary neuropathies, and review of the literature. *Acta Neuropathol.* 1991;82(6):471-482.
- (168) Massion-Verniory, L, Dumont, E, Potvin, AM. Retinite pigmentaire familiale compliquée d'une amyotrophie neurale. *Rev.Neurol.(Paris)* 1946;78:561-571.
- (169) Irobi J, Dierick I, Jordanova A, Claeys KG, De Jonghe P, Timmerman V. Unraveling the genetics of distal hereditary motor neuropathies. *Neuromolecular Med.* 2006;8(1-2):131-146.

- (170) Harding AE. Inherited neuronal atrophy and degeneration predominantly of lower motor neurons. In: Dyck PJ, Thomas PK, Low PA, Poduslo JF, editors. *Peripheral Neuropathy Philadelphia: W.B.Saunders Company; 1993. p. 1051-1064.*
- (171) Gopinath S, Blair IP, Kennerson ML, Durnall JC, Nicholson GA. A novel locus for distal motor neuron degeneration maps to chromosome 7q34-q36. *Hum.Genet.* 2007 Jun;121(5):559-564.
- (172) Timmerman V, De Jonghe P, Simokovic S, Lofgren A, Beuten J, Nelis E, et al. Distal hereditary motor neuropathy type II (distal HMN II): mapping of a locus to chromosome 12q24. *Hum.Mol.Genet.* 1996 Jul;5(7):1065-1069.
- (173) Irobi J, Van Impe K, Seeman P, Jordanova A, Dierick I, Verpoorten N, et al. Hot-spot residue in small heat-shock protein 22 causes distal motor neuropathy. *Nat.Genet.* 2004 Jun;36(6):597-601.
- (174) Viollet L, Barois A, Rebeiz JG, Rifai Z, Burlet P, Zarhrate M, et al. Mapping of autosomal recessive chronic distal spinal muscular atrophy to chromosome 11q13. *Ann.Neurol.* 2002 May;51(5):585-592.
- (175) Viollet L, Zarhrate M, Maystadt I, Estournet-Mathiaut B, Barois A, Desguerre I, et al. Refined genetic mapping of autosomal recessive chronic distal spinal muscular atrophy to chromosome 11q13.3 and evidence of linkage disequilibrium in European families. *Eur.J.Hum.Genet.* 2004 Jun;12(6):483-488.
- (176) Christodoulou K, Kyriakides T, Hristova AH, Georgiou DM, Kalaydjieva L, Yshpekova B, et al. Mapping of a distal form of spinal muscular atrophy with upper limb predominance to chromosome 7p. *Hum.Mol.Genet.* 1995 Sep;4(9):1629-1632.
- (177) Windpassinger C, Auer-Grumbach M, Irobi J, Patel H, Petek E, Horl G, et al. Heterozygous missense mutations in BSCL2 are associated with distal hereditary motor neuropathy and Silver syndrome. *Nat.Genet.* 2004 Mar;36(3):271-276.
- (178) McEntagart M, Norton N, Williams H, Teare MD, Dunstan M, Baker P, et al. Localization of the gene for distal hereditary motor neuropathy VII (dHMN-VII) to chromosome 2q14. *Am.J.Hum.Genet.* 2001 May;68(5):1270-1276.
- (179) Puls I, Jonnakuty C, LaMonte BH, Holzbaur EL, Tokito M, Mann E, et al. Mutant dynactin in motor neuron disease. *Nat.Genet.* 2003 Apr;33(4):455-456.
- (180) Takata RI, Speck Martins CE, Passosbueno MR, Abe KT, Nishimura AL, Da Silva MD, et al. A new locus for recessive distal spinal muscular atrophy at Xq13.1-q21. *J.Med.Genet.* 2004 Mar;41(3):224-229.
- (181) Chance PF, Rabin BA, Ryan SG, Ding Y, Scavina M, Crain B, et al. Linkage of the gene for an autosomal dominant form of juvenile amyotrophic lateral sclerosis to chromosome 9q34. *Am.J.Hum.Genet.* 1998 Mar;62(3):633-640.
- (182) Chen YZ, Bennett CL, Huynh HM, Blair IP, Puls I, Irobi J, et al. DNA/RNA helicase gene mutations in a form of juvenile amyotrophic lateral sclerosis (ALS4). *Am.J.Hum.Genet.* 2004 Jun;74(6):1128-1135.
- (183) De Jonghe P, Auer-Grumbach M, Irobi J, Wagner K, Plecko B, Kennerson M, et al. Autosomal dominant juvenile amyotrophic lateral sclerosis and distal hereditary motor neuropathy with pyramidal tract signs: synonyms for the same disorder? *Brain* 2002 Jun;125(Pt 6):1320-1325.
- (184) Christodoulou K, Zamba E, Tsingis M, Mubaidin A, Horani K, Abu-Sheik S, et al. A novel form of distal hereditary motor neuropathy maps to chromosome 9p21.1-p12. *Ann.Neurol.* 2000 Dec;48(6):877-884.
- (185) Middleton LT, Christodoulou K, Mubaidin A, Zamba E, Tsingis M, Kyriacou K, et al. Distal hereditary motor neuropathy of the Jerash type. *Ann.N.Y.Acad.Sci.* 1999 Sep 14;883:439-442.

- (186) van der Vleuten AJ, van Ravenswaaij-Arts CM, Frijns CJ, Smits AP, Hageman G, Padberg GW, et al. Localisation of the gene for a dominant congenital spinal muscular atrophy predominantly affecting the lower limbs to chromosome 12q23-q24. *Eur.J.Hum.Genet.* 1998 Jul-Aug;6(4):376-382.
- (187) Casaubon LK, Melanson M, Lopes-Cendes I, Marineau C, Andermann E, Andermann F, et al. The gene responsible for a severe form of peripheral neuropathy and agenesis of the corpus callosum maps to chromosome 15q. *Am.J.Hum.Genet.* 1996 Jan;58(1):28-34.
- (188) Howard HC, Dube MP, Prevost C, Bouchard JP, Mathieu J, Rouleau GA. Fine mapping the candidate region for peripheral neuropathy with or without agenesis of the corpus callosum in the French Canadian population. *Eur.J.Hum.Genet.* 2002 Jul;10(7):406-412.
- (189) Howard HC, Mount DB, Rochefort D, Byun N, Dupre N, Lu J, et al. The K-C1 cotransporter KCC3 is mutant in a severe peripheral neuropathy associated with agenesis of the corpus callosum. *Nat.Genet.* 2002 Nov;32(3):384-392.
- (190) Chance PF. Inherited focal, episodic neuropathies: hereditary neuropathy with liability to pressure palsies and hereditary neuralgic amyotrophy. *Neuromolecular Med.* 2006;8(1-2):159-174.
- (191) Airaksinen EM, Iivanainen M, Karli P, Sainio K, Haltia M. Hereditary recurrent brachial plexus neuropathy with dysmorphic features. *Acta Neurol.Scand.* 1985 Apr;71(4):309-316.
- (192) Klein CJ, Windebank AJ. Hereditary brachial plexus neuropathy. In: Dyck PJ, Thomas PK, editors. *Peripheral Neuropathy*. 4th ed. Philadelphia: W.B.Saunders; 2005.
- (193) Tsairis P, Dyck PJ, Mulder DW. Natural history of brachial plexus neuropathy. Report on 99 patients. *Arch.Neurol.* 1972 Aug;27(2):109-117.
- (194) Klein CJ, Dyck PJ, Friedenberg SM, Burns TM, Windebank AJ, Dyck PJ. Inflammation and neuropathic attacks in hereditary brachial plexus neuropathy. *J.Neurol.Neurosurg.Psychiatry.* 2002 Jul;73(1):45-50.
- (195) Kuhlenbaumer G, Hannibal MC, Nelis E, Schirmacher A, Verpoorten N, Meuleman J, et al. Mutations in SEPT9 cause hereditary neuralgic amyotrophy. *Nat.Genet.* 2005 Oct;37(10):1044-1046.
- (196) Pellegrino JE, Rebbeck TR, Brown MJ, Bird TD, Chance PF. Mapping of hereditary neuralgic amyotrophy (familial brachial plexus neuropathy) to distal chromosome 17q. *Neurology* 1996 Apr;46(4):1128-1132.
- (197) Auer-Grumbach M, Mauko B, Auer-Grumbach P, Pieber TR. Molecular genetics of hereditary sensory neuropathies. *Neuromolecular Med.* 2006;8(1-2):147-158.
- (198) Auer-Grumbach M, De Jonghe P, Verhoeven K, Timmerman V, Wagner K, Hartung HP, et al. Autosomal dominant inherited neuropathies with prominent sensory loss and mutilations: a review. *Arch.Neurol.* 2003 Mar;60(3):329-334.
- (199) Houlden H, Blake J, Reilly MM. Hereditary sensory neuropathies. *Curr.Opin.Neurol.* 2004 Oct;17(5):569-577.
- (200) Dubourg O, Barhoumi C, Azzedine H, Birouk N, Brice A, Bouche P, et al. Phenotypic and genetic study of a family with hereditary sensory neuropathy and prominent weakness. *Muscle Nerve* 2000 Oct;23(10):1508-1514.
- (201) Whitaker JN, Falchuck ZM, Engel WK, Blaese RM, Strober W. Hereditary sensory neuropathy. Association with increased synthesis of immunoglobulin A. *Arch.Neurol.* 1974 May;30(5):359-371.
- (202) Bejaoui K, Wu C, Scheffler MD, Haan G, Ashby P, Wu L, et al. SPTLC1 is mutated in hereditary sensory neuropathy, type 1. *Nat.Genet.* 2001 Mar;27(3):261-262.
- (203) Dawkins JL, Hulme DJ, Brahmabhatt SB, Auer-Grumbach M, Nicholson GA. Mutations in SPTLC1, encoding serine palmitoyltransferase, long chain base subunit-1, cause hereditary sensory neuropathy type I. *Nat.Genet.* 2001 Mar;27(3):309-312.

- (204) Nicholson GA, Dawkins JL, Blair IP, Kennerson ML, Gordon MJ, Cherryson AK, et al. The gene for hereditary sensory neuropathy type I (HSN-I) maps to chromosome 9q22.1-q22.3. *Nat.Genet.* 1996 May;13(1):101-104.
- (205) Spring PJ, Kok C, Nicholson GA, Ing AJ, Spies JM, Bassett ML, et al. Autosomal dominant hereditary sensory neuropathy with chronic cough and gastro-oesophageal reflux: clinical features in two families linked to chromosome 3p22-p24. *Brain* 2005 Dec;128(Pt 12):2797-2810.
- (206) Lafreniere RG, MacDonald ML, Dube MP, MacFarlane J, O'Driscoll M, Brais B, et al. Identification of a novel gene (HSN2) causing hereditary sensory and autonomic neuropathy type II through the Study of Canadian Genetic Isolates. *Am.J.Hum.Genet.* 2004 May;74(5):1064-1073.
- (207) RILEY CM, DAY RL. Central autonomic dysfunction with defective lacrimation; report of five cases. *Pediatrics* 1949 Apr;3(4):468-478.
- (208) Slaugenhaupt SA, Blumenfeld A, Gill SP, Leyne M, Mull J, Cuajungco MP, et al. Tissue-specific expression of a splicing mutation in the IKBKAP gene causes familial dysautonomia. *Am.J.Hum.Genet.* 2001 Mar;68(3):598-605.
- (209) Anderson SL, Coli R, Daly IW, Kichula EA, Rork MJ, Volpi SA, et al. Familial dysautonomia is caused by mutations of the IKAP gene. *Am.J.Hum.Genet.* 2001 Mar;68(3):753-758.
- (210) Hawkes NA, Otero G, Winkler GS, Marshall N, Dahmus ME, Krappmann D, et al. Purification and characterization of the human elongator complex. *J.Biol.Chem.* 2002 Jan 25;277(4):3047-3052.
- (211) Holmberg C, Katz S, Lerdrup M, Herdegen T, Jaattela M, Aronheim A, et al. A novel specific role for I kappa B kinase complex-associated protein in cytosolic stress signaling. *J.Biol.Chem.* 2002 Aug 30;277(35):31918-31928.
- (212) Otero G, Fellows J, Li Y, de Bizemont T, Dirac AM, Gustafsson CM, et al. Elongator, a multisubunit component of a novel RNA polymerase II holoenzyme for transcriptional elongation. *Mol.Cell* 1999 Jan;3(1):109-118.
- (213) Indo Y, Tsuruta M, Hayashida Y, Karim MA, Ohta K, Kawano T, et al. Mutations in the TRKA/NGF receptor gene in patients with congenital insensitivity to pain with anhidrosis. *Nat.Genet.* 1996 Aug;13(4):485-488.
- (214) Axelrod FB, Hilz MJ. Inherited autonomic neuropathies. *Semin.Neurol.* 2003 Dec;23(4):381-390.
- (215) Pinsky L, DiGeorge AM. Congenital familial sensory neuropathy with anhidrosis. *J.Pediatr.* 1966 Jan;68(1):1-13.
- (216) Bonkowsky JL, Johnson J, Carey JC, Smith AG, Swoboda KJ. An infant with primary tooth loss and palmar hyperkeratosis: a novel mutation in the NTRK1 gene causing congenital insensitivity to pain with anhidrosis. *Pediatrics* 2003 Sep;112(3 Pt 1):e237-41.
- (217) Matsuo M, Kurokawa T, Goya N, Ohta M. Congenital insensitivity to pain with anhidrosis in a 2-month-old boy. *Neurology* 1981 Sep;31(9):1190-1192.
- (218) Rafel E, Alberca R, Bautista J, Navarrete M, Lazo J. Congenital insensitivity to pain with anhidrosis. *Muscle Nerve* 1980 May-Jun;3(3):216-220.
- (219) Levi-Montalcini R. The nerve growth factor: thirty-five years later. *Biosci.Rep.* 1987 Sep;7(9):681-699.
- (220) Weier HU, Rhein AP, Shadravan F, Collins C, Polikoff D. Rapid physical mapping of the human trk protooncogene (NTRK1) to human chromosome 1q21-q22 by P1 clone selection, fluorescence in situ hybridization (FISH), and computer-assisted microscopy. *Genomics* 1995 Mar 20;26(2):390-393.
- (221) Greco A, Villa R, Pierotti MA. Genomic organization of the human NTRK1 gene. *Oncogene* 1996 Dec 5;13(11):2463-2466.

- (222) Minde J, Toolanen G, Andersson T, Nennesmo I, Remahl IN, Svensson O, et al. Familial insensitivity to pain (HSAN V) and a mutation in the NGFB gene. A neurophysiological and pathological study. *Muscle Nerve* 2004 Dec;30(6):752-760.
- (223) Einarsdottir E, Carlsson A, Minde J, Toolanen G, Svensson O, Solders G, et al. A mutation in the nerve growth factor beta gene (NGFB) causes loss of pain perception. *Hum.Mol.Genet.* 2004 Apr 15;13(8):799-805.
- (224) Bomont P, Cavalier L, Blondeau F, Ben Hamida C, Belal S, Tazir M, et al. The gene encoding gigaxonin, a new member of the cytoskeletal BTB/kelch repeat family, is mutated in giant axonal neuropathy. *Nat.Genet.* 2000 Nov;26(3):370-374.
- (225) Flanigan KM, Crawford TO, Griffin JW, Goebel HH, Kohlschutter A, Ranells J, et al. Localization of the giant axonal neuropathy gene to chromosome 16q24. *Ann.Neurol.* 1998 Jan;43(1):143-148.
- (226) Santoro L, De Michele G, Perretti A, Crisci C, Coccozza S, Cavalcanti F, et al. Relation between trinucleotide GAA repeat length and sensory neuropathy in Friedreich's ataxia. *J.Neurol.Neurosurg.Psychiatry.* 1999 Jan;66(1):93-96.
- (227) Said G, Marion MH, Selva J, Jamet C. Hypotrophic and dying-back nerve fibers in Friedreich's ataxia. *Neurology* 1986 Oct;36(10):1292-1299.
- (228) Burck U, Goebel HH, Kuhlendahl HD, Meier C, Goebel KM. Neuromyopathy and vitamin E deficiency in man. *Neuropediatrics* 1981 Aug;12(3):267-278.
- (229) Hentati A, Deng HX, Hung WY, Nayer M, Ahmed MS, He X, et al. Human alpha-tocopherol transfer protein: gene structure and mutations in familial vitamin E deficiency. *Ann.Neurol.* 1996 Mar;39(3):295-300.
- (230) Muller DP, Goss-Sampson MA. Neurochemical, neurophysiological, and neuropathological studies in vitamin E deficiency. *Crit.Rev.Neurobiol.* 1990;5(3):239-263.
- (231) Soong BW, Paulson HL. Spinocerebellar ataxias: an update. *Curr.Opin.Neurol.* 2007 Aug;20(4):438-446.
- (232) Manto MU. The wide spectrum of spinocerebellar ataxias (SCAs). *Cerebellum* 2005;4(1):2-6.
- (233) Grattan-Smith PJ, Healey S, Grigg JR, Christodoulou J. Spinocerebellar ataxia type 7: a distinctive form of autosomal dominant cerebellar ataxia with retinopathy and marked genetic anticipation. *J.Paediatr.Child Health* 2001 Feb;37(1):81-84.
- (234) Vos AJ, Joosten EM, Gabreels-Festen AA, Gabreels FJ, Notermans SL, Lamers KJ. The diagnostic value of sural nerve biopsy in metachromatic leucodystrophy and other conditions with low leucocyte arylsulphatase A activities. *Neuropediatrics* 1982 Feb;13(1):42-46.
- (235) Biffi A, Cesani M, Fumagalli F, Del Carro U, Baldoli C, Canale S, et al. Metachromatic leukodystrophy - mutation analysis provides further evidence of genotype-phenotype correlation. *Clin.Genet.* 2008 Oct;74(4):349-357.
- (236) Duncan C, Strub R, McGarry P, Duncan D. Peripheral nerve biopsy as an aid to diagnosis in infantile neuroaxonal dystrophy. *Neurology* 1970 Oct;20(10):1024-1032.
- (237) Khateeb S, Flusser H, Ofir R, Shelef I, Narkis G, Vardi G, et al. PLA2G6 mutation underlies infantile neuroaxonal dystrophy. *Am.J.Hum.Genet.* 2006 Nov;79(5):942-948.
- (238) Shinzawa K, Sumi H, Ikawa M, Matsuoka Y, Okabe M, Sakoda S, et al. Neuroaxonal dystrophy caused by group VIA phospholipase A2 deficiency in mice: a model of human neurodegenerative disease. *J.Neurosci.* 2008 Feb 27;28(9):2212-2220.
- (239) Moser HW. Molecular genetics of peroxisomal disorders. *Front.Biosci.* 2000 Mar 1;5:D298-306.

- (240) Aubourg P, Scotto J, Rocchiccioli F, Feldmann-Paukrat D, Robain O. Neonatal adrenoleukodystrophy. *J.Neurol.Neurosurg.Psychiatry*. 1986 Jan;49(1):77-86.
- (241) Yiannikas C, McLeod JG, Pollard JD, Baverstock J. Peripheral neuropathy associated with mitochondrial myopathy. *Ann.Neurol*. 1986 Aug;20(2):249-257.
- (242) Holt II, Harding AE, Petty RK, Morgan-Hughes JA. A new mitochondrial disease associated with mitochondrial DNA heteroplasmy. *Am.J.Hum.Genet*. 1990 Mar;46(3):428-433.
- (243) Hart PE, De Vivo DC, Schapira AH. Clinical features of the Mitochondrial Encephalopathies. In: Schapira AH, DiMauro S, editors. *Mitochondrial Disorders in Neurology 2* Boston: Butterworth Heinemann; 2002. p. 35-68.
- (244) Jacobs JM, Harding BN, Lake BD, Payan J, Wilson J. Peripheral neuropathy in Leigh's disease. *Brain* 1990 Apr;113 (Pt 2)(Pt 2):447-462.
- (245) Szigeti K, Nelis E, Lupski JR. Molecular diagnostics of Charcot-Marie-Tooth disease and related peripheral neuropathies. *Neuromolecular Med*. 2006;8(1-2):243-254.
- (246) Niemann A, Berger P, Suter U. Pathomechanisms of mutant proteins in Charcot-Marie-Tooth disease. *Neuromolecular Med*. 2006;8(1-2):217-242.
- (247) Stendel C, Roos A, Deconinck T, Pereira J, Castagner F, Niemann A, et al. Peripheral nerve demyelination caused by a mutant Rho GTPase guanine nucleotide exchange factor, frabin/FGD4. *Am.J.Hum.Genet*. 2007 Jul;81(1):158-164.
- (248) Antonellis A, Lee-Lin SQ, Wasterlain A, Leo P, Quezado M, Goldfarb LG, et al. Functional analyses of glycyl-tRNA synthetase mutations suggest a key role for tRNA-charging enzymes in peripheral axons. *J.Neurosci*. 2006 Oct 11;26(41):10397-10406.
- (249) Ammar N, Nelis E, Merlini L, Barisic N, Amouri R, Ceuterick C, et al. Identification of novel GDAP1 mutations causing autosomal recessive Charcot-Marie-Tooth disease. *Neuromuscul.Disord*. 2003 Nov;13(9):720-728.
- (250) Shy ME, Siskind C, Swan ER, Krajewski KM, Doherty T, Fuerst DR, et al. CMT1X phenotypes represent loss of GJB1 gene function. *Neurology* 2007 Mar 13;68(11):849-855.
- (251) Evgrafov OV, Mersyanova I, Irobi J, Van Den Bosch L, Dierick I, Leung CL, et al. Mutant small heat-shock protein 27 causes axonal Charcot-Marie-Tooth disease and distal hereditary motor neuropathy. *Nat.Genet*. 2004 Jun;36(6):602-606.
- (252) Brockmann K, Dreha-Kulaczewski S, Dechent P, Bonnemann C, Helms G, Kyllerman M, et al. Cerebral involvement in axonal Charcot-Marie-Tooth neuropathy caused by mitofusin2 mutations. *J.Neurol*. 2008 Jul;255(7):1049-1058.
- (253) Bolino A, Muglia M, Conforti FL, LeGuern E, Salih MA, Georgiou DM, et al. Charcot-Marie-Tooth type 4B is caused by mutations in the gene encoding myotubularin-related protein-2. *Nat.Genet*. 2000 May;25(1):17-19.
- (254) Vallat JM. Dominantly inherited peripheral neuropathies. *J.Neuropathol.Exp.Neurol*. 2003 Jul;62(7):699-714.
- (255) Chance PF. Molecular genetics of hereditary neuropathies. *J.Child Neurol*. 1999 Jan;14(1):43-52.
- (256) McLeod JG. Investigation of peripheral neuropathy. *J.Neurol.Neurosurg.Psychiatry*. 1995 Mar;58(3):274-283.
- (257) Argov Z, Steiner I, Soffer D. The yield of sural nerve biopsy in the evaluation of peripheral neuropathies. *Acta Neurol.Scand*. 1989 Mar;79(3):243-245.
- (258) Ouvrier RA, McLeod JG, Conchin T. Morphometric studies of sural nerve in childhood. *Muscle Nerve* 1987 Jan;10(1):47-53.

- (259) Behse F, Buchthal. Sensory action potentials and biopsy of the sural nerve in neuropathy. *Brain* 1978 Sep;101(3):473-493.
- (260) Dyck PJ, Karnes J, Lais AC, Lofgren EP, Clarke Stevens J. Pathologic alterations of the peripheral nervous system in humans. In: Dyck PJ, Thomas PK, Lambert EH, Bunge R, editors. *Peripheral neuropathies Philadelphia: WB Saunders; 1984. p. 760-870.*
- (261) R. A. Ouvrier. *Chronic peripheral neuropathy in childhood University of Sydney; 1985.*
- (262) Ouvrier RA, McLeod JG, Pollard JD. Investigation of peripheral neuropathy. *Peripheral Neuropathy in Childhood London: MacKeith Press; 1999. p. 29-41.*
- (263) Dyck PJ, Lais AC, Karnes JL, Sparks M, Hunder H, Low PA, et al. Permanent axotomy, a model of axonal atrophy and secondary segmental demyelination and remyelination. *Ann.Neurol.* 1981 Jun;9(6):575-583.
- (264) Hall SM, Hughes RA, Atkinson PF, McColl I, Gale A. Motor nerve biopsy in severe Guillain-Barre syndrome. *Ann.Neurol.* 1992 Apr;31(4):441-444.
- (265) Massaro ME, Rodriguez EC, Pocięcha J, Arroyo HA, Sacolitti M, Taratuto AL, et al. Nerve biopsy in children with severe Guillain-Barre syndrome and inexcitable motor nerves. *Neurology* 1998 Aug;51(2):394-398.
- (266) Abouzahr MK, Lange DJ, Latov N, Olarte M, Rowland LP, Hays AP, et al. Diagnostic biopsy of the motor nerve to the gracilis muscle. Technical note. *J.Neurosurg.* 1997 Jul;87(1):122-124.
- (267) McArthur JC, Stocks EA, Hauer P, Cornblath DR, Griffin JW. Epidermal nerve fiber density: normative reference range and diagnostic efficiency. *Arch.Neurol.* 1998 Dec;55(12):1513-1520.
- (268) Holland NR, Crawford TO, Hauer P, Cornblath DR, Griffin JW, McArthur JC. Small-fiber sensory neuropathies: clinical course and neuropathology of idiopathic cases. *Ann.Neurol.* 1998 Jul;44(1):47-59.
- (269) Scott LJ, Griffin JW, Luciano C, Barton NW, Banerjee T, Crawford T, et al. Quantitative analysis of epidermal innervation in Fabry disease. *Neurology* 1999 Apr 12;52(6):1249-1254.
- (270) Solders G. Discomfort after fascicular sural nerve biopsy. *Acta Neurol.Scand.* 1988 Jun;77(6):503-504.
- (271) Rappaport WD, Valente J, Hunter GC, Rance NE, Lick S, Lewis T, et al. Clinical utilization and complications of sural nerve biopsy. *Am.J.Surg.* 1993 Sep;166(3):252-256.
- (272) Pollock M, Nukada H, Taylor P, Donaldson I, Carroll G. Comparison between fascicular and whole sural nerve biopsy. *Ann.Neurol.* 1983 Jan;13(1):65-68.
- (273) Flachenecker P, Janka M, Goldbrunner R, Toyka KV. Clinical outcome of sural nerve biopsy: a retrospective study. *J.Neurol.* 1999 Feb;246(2):93-96.
- (274) Gutrecht JA, Dyck PJ. Quantitative teased-fiber and histologic studies of human sural nerve during postnatal development. *J.Comp.Neurol.* 1970 Jan;138(1):117-129.
- (275) Jacobs JM, Love S. Qualitative and quantitative morphology of human sural nerve at different ages. *Brain* 1985 Dec;108 (Pt 4)(Pt 4):897-924.
- (276) Miller RG, Kuntz NL. Nerve conduction studies in infants and children. *J.Child Neurol.* 1986 Jan;1(1):19-26.
- (277) THOMAS JE, LAMBERT EH. Ulnar nerve conduction velocity and H-reflex in infants and children. *J.Appl.Physiol.* 1960 Jan;15:1-9.
- (278) Dyck PJ, Karnes J, Lais AC, Lofgren EP, Clarke Stevens J. Development of peripheral nerve fibres. In: Dyck PJ, Thomas PK, Lambert EH, Bunge R, editors. *Peripheral neuropathies Philadelphia: WB Saunders; 1984. p. 329-359.*

- (279) Ferriere G, Deneff JF, Rodriguez J, Guzzetta F. Morphometric studies of normal sural nerves in children. *Muscle Nerve* 1985 Oct;8(8):697-704.
- (280) Dyck PJ, Benstead TJ, Conn DL, Stevens JC, Windebank AJ, Low PA. Nonsystemic vasculitic neuropathy. *Brain* 1987 Aug;110 (Pt 4)(Pt 4):843-853.
- (281) Molenaar DS, Vermeulen M, de Haan R. Diagnostic value of sural nerve biopsy in chronic inflammatory demyelinating polyneuropathy. *J.Neurol.Neurosurg.Psychiatry*. 1998 Jan;64(1):84-89.
- (282) Hawke SH, Davies L, Pamphlett R, Guo YP, Pollard JD, McLeod JG. Vasculitic neuropathy. A clinical and pathological study. *Brain* 1991 Oct;114 (Pt 5)(Pt 5):2175-2190.
- (283) Job CK. Pathology of peripheral nerve lesions in lepromatous leprosy--a light and electron microscopic study. *Int.J.Lepr.Other Mycobact.Dis*. 1971 Apr-Jun;39(2):251-268.
- (284) FISHER CM, ADAMS RD. Diphtheritic polyneuritis; a pathological study. *J.Neuropathol.Exp.Neurol*. 1956 Jul;15(3):243-268.
- (285) Vallat JM, Hugon J, Lubeau M, Leboutet MJ, Dumas M, Desproges-Gotteron R. Tick-bite meningoradiculoneuritis: clinical, electrophysiologic, and histologic findings in 10 cases. *Neurology* 1987 May;37(5):749-753.
- (286) Budzilovich GN, Avitabile A, Niedt G, Aleksic SN, Rosenblum MK. Polyradiculopathy and sensory ganglionitis due to cytomegalovirus in acquired immune deficiency syndrome (AIDS). *Prog.AIDS Pathol*. 1989;1:143-157.
- (287) Floeter MK, Civitello LA, Everett CR, Dambrosia J, Luciano CA. Peripheral neuropathy in children with HIV infection. *Neurology* 1997 Jul;49(1):207-212.
- (288) Rossi A, Ciacci G, Federico A, Mondelli M, Rizzuto N. Sensory and motor peripheral neuropathy in olivopontocerebellar atrophy. *Acta Neurol.Scand*. 1986 Apr;73(4):363-371.
- (289) Koskinen T, Sainio K, Rapola J, Pihko H, Paetau A. Sensory neuropathy in infantile onset spinocerebellar ataxia (IOSCA). *Muscle Nerve* 1994 May;17(5):509-515.
- (290) Goebel HH. Neurodegenerative diseases: Biopsy diagnosis in children. *Neuropathology. Diagnostic Approach* St Louis: Mosby; 1997. p. 581-635.
- (291) Altarescu GM, Goldfarb LG, Park KY, Kaneski C, Jeffries N, Litvak S, et al. Identification of fifteen novel mutations and genotype-phenotype relationship in Fabry disease. *Clin.Genet*. 2001 Jul;60(1):46-51.
- (292) Gumbinas M, Larsen M, Mei Liu H. Peripheral neuropathy in classic Niemann-Pick disease: ultrastructure of nerves and skeletal muscles. *Neurology* 1975 Feb;25(2):107-113.
- (293) Pellissier JF, Berard-Badier M, Pinsard N. Farber's disease in two siblings, sural nerve and subcutaneous biopsies by light and electron microscopy. *Acta Neuropathol*. 1986;72(2):178-188.
- (294) Bischoff A, Ulrich J. Peripheral neuropathy in globoid cell leukodystrophy (Krabbe's disease). Ultrastructural and histochemical findings. *Brain* 1969;92(4):861-870.
- (295) Vos A, Gabreels-Festen A, Joosten E, Gabreels F, Renier W, Mullaart R. The neuropathy of Cockayne syndrome. *Acta Neuropathol*. 1983;61(2):153-156.
- (296) Thomas PK, Landon DN, King RH. Diseases of the peripheral nerves. In: Adams JH, Corsellis JAN, Duchon LW, editors. *Greenfield's Neuropathology*. 4th Edition ed. London: Edward Arnold; 1984. p. 873-874.
- (297) Wichman A, Buchthal F, Pezeshkpour GH, Gregg RE. Peripheral neuropathy in abetalipoproteinemia. *Neurology* 1985 Sep;35(9):1279-1289.
- (298) Pollock M, Nukada H, Frith RW, Simcock JP, Allpress S. Peripheral neuropathy in Tangier disease. *Brain* 1983 Dec;106 (Pt 4)(Pt 4):911-928.

- (299) Sung JH, Meyers JP, Stadlan EM, Cowen D, Wolf A. Neuropathological changes in Chediak-Higashi disease. *J.Neuropathol.Exp.Neurol.* 1969 Jan;28(1):86-118.
- (300) Origuchi Y, Eda I, Matsumoto S, Furuse A. Quantitative histologic study of sural nerves in xeroderma pigmentosum. *Pediatr.Neurol.* 1987 Nov-Dec;3(6):356-359.
- (301) Thrush DC, Holti G, Bradley WG, Campbell MJ, Walton JN. Neurological manifestations of xeroderma pigmentosum in two siblings. *J.Neurol.Sci.* 1974 May;22(1):91-104.
- (302) Soffer D, Benharroch D, Berginer V. The neuropathology of cerebrotendinous xanthomatosis revisited: a case report and review of the literature. *Acta Neuropathol.* 1995;90(2):213-220.
- (303) Ohnishi A, Yamashita Y, Goto I, Kuroiwa Y, Murakami S, Ikeda M. De- and remyelination and onion bulb in cerebrotendinous xanthomatosis. *Acta Neuropathol.* 1979 Jan 12;45(1):43-45.
- (304) CAVANAGH JB, MELLICK RS. On the Nature of the Peripheral Nerve Lesions Associated with Acute Intermittent Porphyria. *J.Neurol.Neurosurg.Psychiatry.* 1965 Aug;28:320-327.
- (305) Mitchell G, Larochelle J, Lambert M, Michaud J, Grenier A, Ogier H, et al. Neurologic crises in hereditary tyrosinemia. *N.Engl.J.Med.* 1990 Feb 15;322(7):432-437.
- (306) Korobkin R, Asbury AK, Sumner AJ, Nielsen SL. Glue-sniffing neuropathy. *Arch.Neurol.* 1975 Mar;32(3):158-162.
- (307) Windebank AJ. Metal neuropathy. In: Dyck PJ, Griffen JW, editors. *Peripheral neuropathies.* 3rd Edition ed. Philadelphia: WB Saunders; 1993. p. 1569-1570.
- (308) McLeod JG, Penny R. Vincristine neuropathy: an electrophysiological and histological study. *J.Neurol.Neurosurg.Psychiatry.* 1969 Aug;32(4):297-304.
- (309) Allsop JL, Martini L, Lebris H, Pollard J, Walsh J, Hodgkinson S. Neurologic manifestations of ciguatera. 3 cases with a neurophysiologic study and examination of one nerve biopsy. *Rev.Neurol.(Paris)* 1986;142(6-7):590-597.
- (310) Victor M. Polyneuropathy due to nutritional deficiency and alcoholism. In: Dyck PJ, Thomas PK, Lambert EH, Bunge R, editors. *Peripheral neuropathy.* 2nd Edition ed. Philadelphia: WB Saunders; 1984. p. 1899-1940.
- (311) McCombe PA, McLeod JG. The peripheral neuropathy of vitamin B12 deficiency. *J.Neurol.Sci.* 1984 Oct;66(1):117-126.
- (312) Renault F, Verstichel P, Ploussard JP, Costil J. Neuropathy in two cobalamin-deficient breast-fed infants of vegetarian mothers. *Muscle Nerve* 1999 Feb;22(2):252-254.
- (313) Bosch EP, Murphy MJ, Cancilla PA. Peripheral neurofibromatosis and peroneal muscular atrophy. *Neurology* 1981 Nov;31(11):1408-1414.
- (314) Iwata A, Kunitomo M, Inoue K. Schwann cell proliferation as the cause of peripheral neuropathy in neurofibromatosis-2. *J.Neurol.Sci.* 1998 Apr 1;156(2):201-204.
- (315) Thomas PK, King RH, Chiang TR, Scaravilli F, Sharma AK, Downie AW. Neurofibromatous neuropathy. *Muscle Nerve* 1990 Feb;13(2):93-101.
- (316) Roos KL, Pascuzzi RM, Dunn DW. Neurofibromatosis, Charcot-Marie-Tooth disease, or both? *Neurofibromatosis* 1989;2(4):238-243.
- (317) Thomas PK, King RH. Peripheral nerve changes in amyloid neuropathy. *Brain* 1974 Jun;97(2):395-406.
- (318) Moore PS, Couch RM, Perry YS, Shuckett EP, Winter JS. Allgrove syndrome: an autosomal recessive syndrome of ACTH insensitivity, achalasia and alacrima. *Clin.Endocrinol.(Oxf)* 1991 Feb;34(2):107-114.

- (319) Tullio-Pelet A, Salomon R, Hadj-Rabia S, Mugnier C, de Laet MH, Chaouachi B, et al. Mutant WD-repeat protein in triple-A syndrome. *Nat.Genet.* 2000 Nov;26(3):332-335.
- (320) Dyck PJ, Carney JA, Sizemore GW, Okazaki H, Brimijoin WS, Lambert EH. Multiple endocrine neoplasia, type 2b: phenotype recognition; neurological features and their pathological basis. *Ann.Neurol.* 1979 Oct;6(4):302-314.
- (321) Iwashita T, Murakami H, Kurokawa K, Kawai K, Miyauchi A, Futami H, et al. A two-hit model for development of multiple endocrine neoplasia type 2B by RET mutations. *Biochem.Biophys.Res.Commun.* 2000 Feb 24;268(3):804-808.
- (322) Chang XZ, Zhou JY, Yuan Y, Wu Y, Li YX, Zhang W, et al. Diagnostic value of muscle, sural nerve and skin biopsies in childhood neuromuscular disorders. *Zhonghua Er Ke Za Zhi* 2006 Dec;44(12):909-912.
- (323) Hilton DA, Jacob J, Househam L, Tengah C. Complications following sural and peroneal nerve biopsies. *J.Neurol.Neurosurg.Psychiatry.* 2007 Nov;78(11):1271-1272.
- (324) Docherty Z, Hulten MA, Honeyman MM. De novo tandem duplication 17p11 leads to cen. *J.Med.Genet.* 1983 Apr;20(2):138-142.
- (325) de Brouwer AP, Williams KL, Duley JA, van Kuilenburg AB, Nabuurs SB, Egmont-Petersen M, et al. Arts syndrome is caused by loss-of-function mutations in PRPS1. *Am.J.Hum.Genet.* 2007 Sep;81(3):507-518.
- (326) Bye AM, Baker WD, Pollard J, Wise G. Hereditary sensory neuropathy type II without trophic changes. *Dev.Med.Child Neurol.* 1990 Feb;32(2):164-171.
- (327) Guenther UP, Schuelke M, Bertini E, D'Amico A, Goemans N, Grohmann K, et al. Genomic rearrangements at the IGHMBP2 gene locus in two patients with SMARD1. *Hum.Genet.* 2004 Sep;115(4):319-326.
- (328) Korinthenberg R, Sauer M, Ketelsen UP, Hanemann CO, Stoll G, Graf M, et al. Congenital axonal neuropathy caused by deletions in the spinal muscular atrophy region. *Ann.Neurol.* 1997 Sep;42(3):364-368.
- (329) Low PA, Burke WJ, McLeod JG. Congenital sensory neuropathy with selective loss of small myelinated fibers. *Ann.Neurol.* 1978 Feb;3(2):179-182.
- (330) Wilmshurst JM, Wise GA, Pollard JD, Ouvrier RA. Chronic axonal neuropathy with triosephosphate isomerase deficiency. *Pediatr.Neurol.* 2004 Feb;30(2):146-148.
- (331) Neurofibromatosis. Conference statement. National Institutes of Health Consensus Development Conference. *Arch.Neurol.* 1988 May;45(5):575-578.
- (332) Ryan MM, Grattan-Smith PJ, Procopis PG, Morgan G, Ouvrier RA. Childhood chronic inflammatory demyelinating polyneuropathy: clinical course and long-term outcome. *Neuromuscul.Disord.* 2000 Aug;10(6):398-406.
- (333) Nevo Y. Childhood chronic inflammatory demyelinating polyneuropathy. *Eur.J.Paediatr.Neurol.* 1998;2(4):169-177.
- (334) Research criteria for diagnosis of chronic inflammatory demyelinating polyneuropathy (CIDP). Report from an Ad Hoc Subcommittee of the American Academy of Neurology AIDS Task Force. *Neurology* 1991 May;41(5):617-618.
- (335) Steiner I, Gotkine M, Steiner-Birmanns B, Biran I, Silverstein S, Abeliovich D, et al. Increased severity over generations of Charcot-Marie-Tooth disease type 1A. *J.Neurol.* 2008 Jun;255(6):813-819.
- (336) Boerkoel CF, Takashima H, Bacino CA, Daentl D, Lupski JR. EGR2 mutation R359W causes a spectrum of Dejerine-Sottas neuropathy. *Neurogenetics* 2001 Jul;3(3):153-157.

- (337) Ouvrier RA. The hypomyelinating neuropathies of mice and men. *Rev.Neurol.(Paris)* 1998 Jul;154(6-7):481-487.
- (338) Guenther UP, Varon R, Schlicke M, Dutrannoy V, Volk A, Hubner C, et al. Clinical and mutational profile in spinal muscular atrophy with respiratory distress (SMARD): defining novel phenotypes through hierarchical cluster analysis. *Hum.Mutat.* 2007 Aug;28(8):808-815.
- (339) Diers A, Kaczinski M, Grohmann K, Hubner C, Stoltenburg-Didinger G. The ultrastructure of peripheral nerve, motor end-plate and skeletal muscle in patients suffering from spinal muscular atrophy with respiratory distress type 1 (SMARD1). *Acta Neuropathol.* 2005 Sep;110(3):289-297.
- (340) Grohmann K, Varon R, Stolz P, Schuelke M, Janetzki C, Bertini E, et al. Infantile spinal muscular atrophy with respiratory distress type 1 (SMARD1). *Ann.Neurol.* 2003 Dec;54(6):719-724.
- (341) Giannini A, Pinto AM, Rossetti G, Prandi E, Tiziano D, Brahe C, et al. Respiratory failure in infants due to spinal muscular atrophy with respiratory distress type 1. *Intensive Care Med.* 2006 Nov;32(11):1851-1855.
- (342) Appleton RE, Hubner C, Grohmann K, Varon R. 'Congenital peripheral neuropathy presenting as apnoea and respiratory insufficiency: spinal muscular atrophy with respiratory distress type 1 (SMARD1)'. *Dev.Med.Child Neurol.* 2004 Aug;46(8):576.
- (343) Maystadt I, Zarhrate M, Landrieu P, Boespflug-Tanguy O, Sukno S, Collignon P, et al. Allelic heterogeneity of SMARD1 at the IGHMBP2 locus. *Hum.Mutat.* 2004 May;23(5):525-526.
- (344) Pitt M, Houlden H, Jacobs J, Mok Q, Harding B, Reilly M, et al. Severe infantile neuropathy with diaphragmatic weakness and its relationship to SMARD1. *Brain* 2003 Dec;126(Pt 12):2682-2692.
- (345) Rudnik-Schoneborn S, Stolz P, Varon R, Grohmann K, Schachtele M, Ketelsen UP, et al. Long-term observations of patients with infantile spinal muscular atrophy with respiratory distress type 1 (SMARD1). *Neuropediatrics* 2004 Jun;35(3):174-182.
- (346) Sangiuolo F, Filareto A, Giardina E, Nardone AM, Pilu G, Pietropolli A, et al. Prenatal diagnosis of spinal muscular atrophy with respiratory distress (SMARD1) in a twin pregnancy. *Prenat.Diagn.* 2004 Oct;24(10):839-841.
- (347) Wong VC, Chung BH, Li S, Goh W, Lee SL. Mutation of gene in spinal muscular atrophy respiratory distress type I. *Pediatr.Neurol.* 2006 Jun;34(6):474-477.
- (348) Bush A. Spinal muscular atrophy with respiratory disease (SMARD): an ethical dilemma. *Intensive Care Med.* 2006 Nov;32(11):1691-1693.
- (349) Uncini A, Sabatelli M, Mignogna T, Lugaesi A, Liguori R, Montagna P. Chronic progressive steroid responsive axonal polyneuropathy: a CIDP variant or a primary axonal disorder? *Muscle Nerve* 1996 Mar;19(3):365-371.
- (350) Echaniz-Laguna A, Degos B, Mohr M, Kessler R, Urban-Kraemer E, Tranchant C. A study of three patients with amyotrophic lateral sclerosis and a polyneuropathy resembling CIDP. *Muscle Nerve* 2006 Mar;33(3):356-362.
- (351) Korn-Lubetzki I, Argov Z, Raas-Rothschild A, Wirguin I, Steiner I. Family with inflammatory demyelinating polyneuropathy and the HNPP 17p12 deletion. *Am.J.Med.Genet.* 2002 Dec 1;113(3):275-278.
- (352) Pareyson D. Differential diagnosis of Charcot-Marie-Tooth disease and related neuropathies. *Neurol.Sci.* 2004 Jun;25(2):72-82.
- (353) Anlar B, Deda G, Erdem S, Tan E, Korkusuz P. Chronic acquired polyneuropathy in infancy. *J.Neurol.* 2002 Oct;249(10):1469-1471.
- (354) Ionasescu VV, Trofatter J, Haines JL, Summers AM, Ionasescu R, Searby C. Heterogeneity in X-linked recessive Charcot-Marie-Tooth neuropathy. *Am.J.Hum.Genet.* 1991 Jun;48(6):1075-1083.

- (355) Dyck PJ, Nukada H, Lais AC, Karnes JL. Permanent axotomy: a model of chronic neuronal degeneration preceded by axonal atrophy, myelin remodeling, and degeneration. In: Dyck PJ, Thomas PK, et al, editors. *Peripheral Neuropathy*. 2nd ed. Philadelphia: W.B.Saunders; 1984. p. 666-690.
- (356) Rainier S, Sher C, Reish O, Thomas D, Fink JK. De novo occurrence of novel SPG3A/atlastin mutation presenting as cerebral palsy. *Arch.Neurol.* 2006 Mar;63(3):445-447.
- (357) Nimityongskul P, Anderson LD, Sri P. Hereditary spastic paraplegia. *Orthop.Rev.* 1992 May;21(5):643-646.
- (358) Joosten E, Gabreels F, Stadhouders A, Bolmers D, Gabreels-Festen A. Involvement of sural nerve in neuronal ceroid-lipofuscinoses: report of two cases. *Neuropadiatrie* 1973 Jan;4(1):98-110.
- (359) Lyon BB. Peripheral nerve involvement in Batten-Spielmeyer-Vogt's disease. *J.Neurol.Neurosurg.Psychiatry.* 1975 Feb;38(2):175-179.
- (360) Goebel HH, Gullotta F, Bajanowski T, Hansen FJ, Braak H. Pigment variant of neuronal ceroid-lipofuscinosis. *Am.J.Med.Genet.* 1995 Jun 5;57(2):155-159.
- (361) Wisniewski KE, Madrid RE, Dambaska M, Rapin I, Pullarkat R, Sklower S. Spino-cerebellar degeneration with polyneuropathy associated with ceroid lipofuscinosis in one family. *J.Child Neurol.* 1988 Jan;3(1):33-41.
- (362) Badurska B, Fidzianska A, Jedrzejowska H. A dominant form of neuronal ceroid-lipofuscinosis. An ultrastructural study of sural nerve and peripheral lymphocytes. *J.Neurol.* 1981;226(3):205-212.
- (363) Ferner RE. Neurofibromatosis 1 and neurofibromatosis 2: a twenty first century perspective. *Lancet Neurol.* 2007 Apr;6(4):340-351.
- (364) Drouet A, Creange A. Polyneuropathy associated with neurofibromatosis. *Rev.Neurol.(Paris)* 2005 Mar;161(3):275-283.
- (365) Hanemann CO, Diebold R, Kaufmann D. Role of NF2 haploinsufficiency in NF2-associated polyneuropathy. *Brain Pathol.* 2007 Oct;17(4):371-376.
- (366) Anagnostou E, Miller SP, Guiot MC, Karpati G, Simard L, Dilenge ME, et al. Type I spinal muscular atrophy can mimic sensory-motor axonal neuropathy. *J.Child Neurol.* 2005 Feb;20(2):147-150.
- (367) Chien YY, Nonaka I. Peripheral nerve involvement in Werdnig-Hoffmann disease. *Brain Dev.* 1989;11(4):221-229.
- (368) Imai T, Minami R, Nagaoka M, Ishikawa Y, Kameda K, Okabe M, et al. Proximal and distal motor nerve conduction velocities in Werdnig-Hoffmann disease. *Pediatr.Neurol.* 1990 Mar-Apr;6(2):82-86.
- (369) Omran H, Ketelsen UP, Heinen F, Sauer M, Rudnik-Schoneborn S, Wirth B, et al. Axonal neuropathy and predominance of type II myofibers in infantile spinal muscular atrophy. *J.Child Neurol.* 1998 Jul;13(7):327-331.
- (370) Rudnik-Schoneborn S, Goebel HH, Schlote W, Molaian S, Omran H, Ketelsen U, et al. Classical infantile spinal muscular atrophy with SMN deficiency causes sensory neuronopathy. *Neurology* 2003 Mar 25;60(6):983-987.
- (371) Tein I, Sloane AE, Donner EJ, Lehotay DC, Millington DS, Kelley RI. Fatty acid oxidation abnormalities in childhood-onset spinal muscular atrophy: primary or secondary defect(s)? *Pediatr.Neurol.* 1995 Jan;12(1):21-30.
- (372) Jongpipitvanich S, Sueblinvong T, Norapucsunton T. Mitochondrial respiratory chain dysfunction in various neuromuscular diseases. *J.Clin.Neurosci.* 2005 May;12(4):426-428.
- (373) Crawford TO, Sladky JT, Hurko O, Besner-Johnston A, Kelley RI. Abnormal fatty acid metabolism in childhood spinal muscular atrophy. *Ann.Neurol.* 1999 Mar;45(3):337-343.

- (374) Kernochan LE, Russo ML, Woodling NS, Huynh TN, Avila AM, Fischbeck KH, et al. The role of histone acetylation in SMN gene expression. *Hum.Mol.Genet.* 2005 May 1;14(9):1171-1182.
- (375) Ryan MM, Jones HR,Jr. CMTX mimicking childhood chronic inflammatory demyelinating neuropathy with tremor. *Muscle Nerve* 2005 Apr;31(4):528-530.
- (376) Ryan MM, Tilton A, De Girolami U, Darras BT, Jones HR,Jr. Paediatric mononeuritis multiplex: a report of three cases and review of the literature. *Neuromuscul.Disord.* 2003 Nov;13(9):751-756.
- (377) Scheller C, Richter HP, Scheuerle A, Kretschmer T, Konig RW, Antoniadis G. Intraaneural perineuriomas; a rare entity. Clinical, surgical and neuropathological details in the management of these lesions. *Zentralbl.Neurochir.* 2008 Aug;69(3):134-138.
- (378) Srinivasan J, Escolar D, Ryan M, Darras B, Jones HR. Pediatric sciatic neuropathies due to unusual vascular causes. *J.Child Neurol.* 2008 Jul;23(7):738-741.
- (379) Bennett DL, Groves M, Blake J, Holton JL, King RH, Orrell RW, et al. The use of nerve and muscle biopsy in the diagnosis of vasculitis: a 5 year retrospective study. *J.Neurol.Neurosurg.Psychiatry.* 2008 Dec;79(12):1376-1381.
- (380) Szabo A, Zuchner S, Siska E, Mechler F, Molnar MJ. Marked phenotypic variation in a family with a new myelin protein zero mutation. *Neuromuscul.Disord.* 2005 Nov;15(11):760-763.
- (381) Baloh RH, Jen JC, Kim G, Baloh RW. Chronic cough due to Thr124Met mutation in the peripheral myelin protein zero (MPZ gene). *Neurology* 2004 May 25;62(10):1905-1906.
- (382) Misu K, Yoshihara T, Yamamoto M, Hattori N, Nagamatu M, Mukai E, et al. Two families of Charcot-Marie-Tooth disease with Adie's pupil, axonal neuropathy and the Thr124Met mutation in the peripheral myelin protein zero gene. *Rinsho Shinkeigaku* 2000 Feb;40(2):149-154.
- (383) Hisama FM. Familial periodic paralysis and Charcot-Marie-Tooth disease in a 7-generation family. *Arch.Neurol.* 2005 Jan;62(1):135-138.
- (384) Sander S, Ouvrier RA, McLeod JG, Nicholson GA, Pollard JD. Clinical syndromes associated with tomacula or myelin swellings in sural nerve biopsies. *J.Neurol.Neurosurg.Psychiatry.* 2000 Apr;68(4):483-488.
- (385) Boerkoel CF, Takashima H, Stankiewicz P, Garcia CA, Leber SM, Rhee-Morris L, et al. Periaxin mutations cause recessive Dejerine-Sottas neuropathy. *Am.J.Hum.Genet.* 2001 Feb;68(2):325-333.
- (386) Kaya F, Belin S, Bourgeois P, Micaleff J, Blin O, Fontes M. Ascorbic acid inhibits PMP22 expression by reducing cAMP levels. *Neuromuscul.Disord.* 2007 Mar;17(3):248-253.
- (387) Kaya F, Belin S, Micallef J, Blin O, Fontes M. Analysis of the benefits of vitamin cocktails in treating Charcot-Marie-Tooth disease type 1A. *Muscle Nerve* 2008 Aug;38(2):1052-1054.
- (388) Pareyson D, Schenone A, Fabrizi GM, Santoro L, Padua L, Quattrone A, et al. A multicenter, randomized, double-blind, placebo-controlled trial of long-term ascorbic acid treatment in Charcot-Marie-Tooth disease type 1A (CMT-TRIAAL): the study protocol [EudraCT no.: 2006-000032-27]. *Pharmacol.Res.* 2006 Dec;54(6):436-441.
- (389) Boltshauser E, Bischoff A, Isler W. Giant axonal neuropathy. Report of a case with normal hair. *J.Neurol.Sci.* 1977 Mar;31(2):269-278.
- (390) Jedrzejowska H, Drac H. Infantile chronic peripheral neuropathy with giant axons. Report of a case. *Acta Neuropathol.* 1977 Mar 31;37(3):213-217.
- (391) Tyson J, Ellis D, Fairbrother U, King RH, Muntoni F, Jacobs J, et al. Hereditary demyelinating neuropathy of infancy. A genetically complex syndrome. *Brain* 1997 Jan;120 (Pt 1)(Pt 1):47-63.
- (392) Ikegami T, Nicholson G, Ikeda H, Ishida A, Johnston H, Wise G, et al. A novel homozygous mutation of the myelin Po gene producing Dejerine-Sottas disease (hereditary motor and sensory neuropathy type III). *Biochem.Biophys.Res.Commun.* 1996 May 6;222(1):107-110.

- (393) Felice KJ, Fratkin JD, Feldman EL, Sima AA. Phrenic nerve involvement in Dejerine-Sottas disease: a clinicopathological case study. *Pediatr.Pathol.* 1994 Nov-Dec;14(6):905-911.
- (394) Quattrone A, Gambardella A, Bono F, Aguglia U, Bolino A, Bruni AC, et al. Autosomal recessive hereditary motor and sensory neuropathy with focally folded myelin sheaths: clinical, electrophysiologic, and genetic aspects of a large family. *Neurology* 1996 May;46(5):1318-1324.
- (395) Inoue K, Tanabe Y, Lupski JR. Myelin deficiencies in both the central and the peripheral nervous systems associated with a SOX10 mutation. *Ann.Neurol.* 1999 Sep;46(3):313-318.
- (396) Simon LT, Horoupian DS, Dorfman LJ, Marks M, Herrick MK, Wasserstein P, et al. Polyneuropathy, ophthalmoplegia, leukoencephalopathy, and intestinal pseudo-obstruction: POLIP syndrome. *Ann.Neurol.* 1990 Sep;28(3):349-360.
- (397) Yuill GM, Lynch PG. Congenital non-progressive peripheral neuropathy with arthrogyrosis multiplex. *J.Neurol.Neurosurg.Psychiatry.* 1974 Mar;37(3):316-323.
- (398) Carpenter S, Karpati G, Rothman S, Watters G, Andermann F. Pathological involvement of primary sensory neurons in Werdnig-Hoffmann disease. *Acta Neuropathol.* 1978 May 24;42(2):91-97.
- (399) Radhakrishnan K, el-Mangoush MA, Gerryo SE. Descriptive epidemiology of selected neuromuscular disorders in Benghazi, Libya. *Acta Neurol.Scand.* 1987 Feb;75(2):95-100.
- (400) Ndiaye IP, Ndiaye MM, Mauferon JB, Diagne M, Diop AG. Etiological aspects of polyneuritis in Senegal. *Dakar Med.* 1989;34(1-4):68-71.
- (401) Thiam A, Sene-Diouf F, Diallo AK, Diagne M, Ndiaye MM, Ndao AK, et al. Aetiological aspects of neurological diseases in Dakar: follow-up after 10 years (1986-1995). *Dakar Med.* 2000;45(2):167-172.
- (402) Statistical release P0302. Mid-year population estimates 2008. <http://www.statssa.gov.za/publications/populationstats.asp>. 2008; .
- (403) Chan G, Bowen JR, Kumar SJ. Evaluation and treatment of hip dysplasia in Charcot-Marie-Tooth disease. *Orthop.Clin.North Am.* 2006 Apr;37(2):203-9, vii.
- (404) Bamford NS, White KK, Robinett SA, Otto RK, Gospe SM,Jr. Neuromuscular hip dysplasia in Charcot-Marie-Tooth disease type 1A. *Dev.Med.Child Neurol.* 2009 May;51(5):408-411.
- (405) Kumar SJ, Marks HG, Bowen JR, MacEwen GD. Hip dysplasia associated with Charcot-Marie-Tooth disease in the older child and adolescent. *J.Pediatr.Orthop.* 1985 Sep-Oct;5(5):511-514.
- (406) Ghamdi M, Armstrong DL, Miller G. Congenital hypomyelinating neuropathy: a reversible case. *Pediatr.Neurol.* 1997 Jan;16(1):71-73.
- (407) Levy BK, Fenton GA, Loaiza S, Hayat GR. Unexpected recovery in a newborn with severe hypomyelinating neuropathy. *Pediatr.Neurol.* 1997 Apr;16(3):245-248.
- (408) Guzzetta F, Ferriere G. Congenital neuropathy with prevailing axonal changes. A clinical and histological report. *Acta Neuropathol.* 1985;68(3):185-190.
- (409) Hooshmand H, Martinez AJ, Rosenblum WI. Arthrogyrosis multiplex congenita. Simultaneous involvement of peripheral nerve and skeletal muscle. *Arch.Neurol.* 1971 Jun;24(6):561-572.
- (410) Klein CJ, Cunningham JM, Atkinson EJ, Schaid DJ, Hebbring SJ, Anderson SA, et al. The gene for HMSN2C maps to 12q23-24: a region of neuromuscular disorders. *Neurology* 2003 Apr 8;60(7):1151-1156.
- (411) Dyck PJ, Litchy WJ, Minnerath S, Bird TD, Chance PF, Schaid DJ, et al. Hereditary motor and sensory neuropathy with diaphragm and vocal cord paresis. *Ann.Neurol.* 1994 May;35(5):608-615.
- (412) Bassuk AG, Chen YZ, Batish SD, Nagan N, Opal P, Chance PF, et al. In cis autosomal dominant mutation of Senataxin associated with tremor/ataxia syndrome. *Neurogenetics* 2007 Jan;8(1):45-49.

- (413) Schols L, Arning L, Schule R, Epplen JT, Timmann D. "Pseudodominant inheritance" of ataxia with ocular apraxia type 2 (AOA2). *J.Neurol.* 2008 Apr;255(4):495-501.
- (414) Orban P, Devon RS, Hayden MR, Leavitt BR. Chapter 15 Juvenile amyotrophic lateral sclerosis. *Handb.Clin.Neurol.* 2007;82:301-312.
- (415) Hirayama K. Juvenile muscular atrophy of unilateral upper extremity (Hirayama disease)--half-century progress and establishment since its discovery. *Brain Nerve* 2008 Jan;60(1):17-29.
- (416) Hirayama K, Tomonaga M, Kitano K, Yamada T, Kojima S, Arai K. Focal cervical poliopathy causing juvenile muscular atrophy of distal upper extremity: a pathological study. *J.Neurol.Neurosurg.Psychiatry.* 1987 Mar;50(3):285-290.
- (417) Kira J, Ochi H. Juvenile muscular atrophy of the distal upper limb (Hirayama disease) associated with atopy. *J.Neurol.Neurosurg.Psychiatry.* 2001 Jun;70(6):798-801.
- (418) Rowland LP. Diagnosis of amyotrophic lateral sclerosis. *J.Neurol.Sci.* 1998 Oct;160 Suppl 1:S6-24.
- (419) Tashiro K, Kikuchi S, Itoyama Y, Tokumaru Y, Sobue G, Mukai E, et al. Nationwide survey of juvenile muscular atrophy of distal upper extremity (Hirayama disease) in Japan. *Amyotroph Lateral Scler.* 2006 Mar;7(1):38-45.
- (420) Govender R, Wieselthaler NA, Ramanjam V, Ndong A, Wilmshurst JM. Congenital cervical spinal cord lesions: pathogenesis, management, and outcome. *J.Child Neurol.* 2007 Jul;22(7):874-879.
- (421) Lastovica AJ, Goddard EA, Argent AC. Guillain-Barre syndrome in South Africa associated with *Campylobacter jejuni* O:41 strains. *J.Infect.Dis.* 1997 Dec;176 Suppl 2:S139-43.
- (422) London L, Bourne D, Sayed R, Eastman R. Guillain-Barre syndrome in a rural farming district in South Africa: a possible relationship to environmental organophosphate exposure. *Arch.Environ.Health* 2004 Nov;59(11):575-580.
- (423) Koul R, Chacko A, Javed H, Al-Hinai K, Zachariah M, Bulusu S, et al. A profile of childhood neuropathies at a university hospital in Oman. *Saudi Med.J.* 2002 Apr;23(4):450-456.
- (424) Polat M, Tekgul H, Kilincer A, Tosun A, Terlemez S, Serdaroglu G, et al. Electrodiagnostic pattern approach for childhood polyneuropathies. *Pediatr.Neurol.* 2006 Jul;35(1):11-17.
- (425) Shabo G, Paskan JW, van Alfen N, Willemsen MA. The spectrum of polyneuropathies in childhood detected with electromyography. *Pediatr.Neurol.* 2007 Jun;36(6):393-396.
- (426) Van Dyke RB, Wang L, Williams PL, Pediatric AIDS Clinical Trials Group 219C Team. Toxicities associated with dual nucleoside reverse-transcriptase inhibitor regimens in HIV-infected children. *J.Infect.Dis.* 2008 Dec 1;198(11):1599-1608.
- (427) Verma S, Simpson D. Peripheral neuropathy in HIV infection. In: Portegies P, Berger J, editors. *HIV/AIDS AND THE NERVOUS SYSTEM* Edinburgh: Elsevier; 2007. p. 129-137.
- (428) Wilmshurst JM, Burgess J, Hartley P, Eley B. Specific neurologic complications of human immunodeficiency virus type 1 (HIV-1) infection in children. *J.Child Neurol.* 2006 Sep;21(9):788-794.
- (429) Marks DJ, Dheda K, Dawson R, Ainslie G, Miller RF. Adverse events to antituberculosis therapy: influence of HIV and antiretroviral drugs. *Int.J.STD AIDS* 2009 May;20(5):339-345.
- (430) Kehinde MO, Temiye EO, Danesi MA. Neurological complications of sickle cell anemia in Nigerian Africans--a case-control study. *J.Natl.Med.Assoc.* 2008 Apr;100(4):394-399.
- (431) Saunderson P, Gebre S, Desta K, Byass P, Lockwood DN. The pattern of leprosy-related neuropathy in the AMFES patients in Ethiopia: definitions, incidence, risk factors and outcome. *Lepr.Rev.* 2000 Sep;71(3):285-308.

- (432) Oluwole OS, Onabolu AO. High mortality of subjects with endemic ataxic polyneuropathy in Nigeria. *Acta Neurol.Scand.* 2004 Aug;110(2):94-99.
- (433) Marques W,Jr, Freitas MR, Nascimento OJ, Oliveira AB, Calia L, Melo A, et al. 17p duplicated Charcot-Marie-Tooth 1A: characteristics of a new population. *J.Neurol.* 2005 Aug;252(8):972-979.
- (434) Aiyesimoju AB, Osuntokun BO, Bademosi O, Adeuja AO. Hereditary neurodegenerative disorders in Nigerian Africans. *Neurology* 1984 Mar;34(3):361-362.
- (435) Ouvrier RA, McLeod JG, Conchin TE. The hypertrophic forms of hereditary motor and sensory neuropathy. A study of hypertrophic Charcot-Marie-Tooth disease (HMSN type I) and Dejerine-Sottas disease (HMSN type III) in childhood. *Brain* 1987 Feb;110 (Pt 1)(Pt 1):121-148.
- (436) Bienfait HM, Baas F, Koelman JH, de Haan RJ, van Engelen BG, Gabreels-Festen AA, et al. Phenotype of Charcot-Marie-Tooth disease Type 2. *Neurology* 2007 May 15;68(20):1658-1667.
- (437) Vrancken AF, Kalmijn S, Buskens E, Franssen H, Vermeulen M, Wokke JH, et al. Feasibility and cost efficiency of a diagnostic guideline for chronic polyneuropathy: a prospective implementation study. *J.Neurol.Neurosurg.Psychiatry.* 2006 Mar;77(3):397-401.
- (438) Willison HJ, Winer JB. Clinical evaluation and investigation of neuropathy. *J.Neurol.Neurosurg.Psychiatry.* 2003 Jun;74 Suppl 2:ii3-ii8.
- (439) Chung KW, Kim SB, Cho SY, Hwang SJ, Park SW, Kang SH, et al. Distal hereditary motor neuropathy in Korean patients with a small heat shock protein 27 mutation. *Exp.Mol.Med.* 2008 Jun 30;40(3):304-312.
- (440) Chung KW, Suh BC, Shy ME, Cho SY, Yoo JH, Park SW, et al. Different clinical and magnetic resonance imaging features between Charcot-Marie-Tooth disease type 1A and 2A. *Neuromuscul.Disord.* 2008 Aug;18(8):610-618.
- (441) Cellerini M, Salti S, Desideri V, Marconi G. MR imaging of the cauda equina in hereditary motor sensory neuropathies: correlations with sural nerve biopsy. *AJNR Am.J.Neuroradiol.* 2000 Nov-Dec;21(10):1793-1798.
- (442) Ellegala DB, Monteith SJ, Haynor D, Bird TD, Goodkin R, Kliot M. Characterization of genetically defined types of Charcot-Marie-Tooth neuropathies by using magnetic resonance neurography. *J.Neurosurg.* 2005 Feb;102(2):242-245.
- (443) Liao JP, Waclawik AJ. Nerve root hypertrophy in CMT type 1A. *Neurology* 2004 Mar 9;62(5):783.
- (444) Beadles WI, Jahn A, Weigel R, Clutterbuck D. Peripheral neuropathy in HIV-positive patients at an antiretroviral clinic in Lilongwe, Malawi. *Trop.Doct.* 2009 Apr;39(2):78-80.
- (445) Youle M. Acetyl-L-carnitine in HIV-associated antiretroviral toxic neuropathy. *CNS Drugs* 2007;21 Suppl 1:25-30; discussion 45-6.
- (446) Sohal A, Riordan A, Mallewa M, Solomon T, Kneen R. Successful treatment of cytomegalovirus polyradiculopathy in a 9-year-old child with congenital human immunodeficiency virus infection. *J.Child Neurol.* 2009 Feb;24(2):215-218.
- (447) Brannagan TH,3rd, Zhou Y. HIV-associated Guillain-Barre syndrome. *J.Neurol.Sci.* 2003 Apr 15;208(1-2):39-42.
- (448) Puthanakit T, Oberdorfer P, Akarathum N, Wannarit P, Sirisanthana T, Sirisanthana V. Immune reconstitution syndrome after highly active antiretroviral therapy in human immunodeficiency virus-infected thai children. *Pediatr.Infect.Dis.J.* 2006 Jan;25(1):53-58.
- (449) Araujo AP, Nascimento OJ, Garcia OS. Distal sensory polyneuropathy in a cohort of HIV-infected children over five years of age. *Pediatrics* 2000 Sep;106(3):E35.

- (450) Steichen O, Martinez-Almoyna L, De Broucker T. Isoniazid induced neuropathy: consider prevention. *Rev.Mal.Respir.* 2006 Apr;23(2 Pt 1):157-160.
- (451) Coodley G. Update on vitamins, minerals, and the carotenoids. *J.Physicians Assoc.AIDS Care* 1995 Jan;2(1):24-29.
- (452) Tagliati M, Grinnell J, Godbold J, Simpson DM. Peripheral nerve function in HIV infection: clinical, electrophysiologic, and laboratory findings. *Arch.Neurol.* 1999 Jan;56(1):84-89.
- (453) Bademosi O, Osuntokun BO. Diseases of peripheral nerves as seen in the Nigerian African. *Afr.J.Med.Med.Sci.* 1981 Mar-Jun;10(1-2):33-38.
- (454) Kabzinska D, Korwin-Piotrowska T, Drechsler H, Drac H, Hausmanowa-Petrusewicz I, Kochanski A. Late-onset Charcot-Marie-Tooth type 2 disease with hearing impairment associated with a novel Pro105Thr mutation in the MPZ gene. *Am.J.Med.Genet.A.* 2007 Sep 15;143A(18):2196-2199.
- (455) Seeman P, Mazanec R, Huehne K, Suslikova P, Keller O, Rautenstrauss B. Hearing loss as the first feature of late-onset axonal CMT disease due to a novel P0 mutation. *Neurology* 2004 Aug 24;63(4):733-735.
- (456) Huehne K, Benes V, Thiel C, Kraus C, Kress W, Hoeltzenbein M, et al. Novel mutations in the Charcot-Marie-Tooth disease genes PMP22, MPZ, and GJB1. *Hum.Mutat.* 2003 Jan;21(1):100.
- (457) Stojkovic T, Latour P, Vandenberghe A, Hurtevent JF, Vermersch P. Sensorineural deafness in X-linked Charcot-Marie-Tooth disease with connexin 32 mutation (R142Q). *Neurology* 1999 Mar 23;52(5):1010-1014.
- (458) Chung KW, Kim SB, Park KD, Choi KG, Lee JH, Eun HW, et al. Early onset severe and late-onset mild Charcot-Marie-Tooth disease with mitofusin 2 (MFN2) mutations. *Brain* 2006 Aug;129(Pt 8):2103-2118.
- (459) Basri R, Yabe I, Soma H, Matsushima M, Tsuji S, Sasaki H. X-linked Charcot-Marie-Tooth disease (CMTX) in a severely affected female patient with scattered lesions in cerebral white matter. *Intern.Med.* 2007;46(13):1023-1027.
- (460) Mazzeo A, Di Leo R, Toscano A, Muglia M, Patitucci A, Messina C, et al. Charcot-Marie-Tooth type X: unusual phenotype of a novel CX32 mutation. *Eur.J.Neurol.* 2008 Oct;15(10):1140-1142.
- (461) Sugie M, Ishihara K, Simizu Y, Oono H, Kawamura M. Case report of transient splenium abnormality in Charcot-Marie-Tooth disease. *Rinsho Shinkeigaku* 2008 May;48(5):359-362.