

**Post Transplant Lymphoproliferative Disorders in
Liver Transplant Recipients**

**Cases at Red Cross Children's Hospital
Cape Town**

By

John Quail Davies MBBCh (Wits) FCPATH (SA)

Dissertation submitted in fulfilment of Part II of the requirements for the degree of:

**Master of Philosophy (Paediatric Pathology) at the
University of Cape Town**

May 2002

The copyright of this thesis vests in the author. No quotation from it or information derived from it is to be published without full acknowledgement of the source. The thesis is to be used for private study or non-commercial research purposes only.

Published by the University of Cape Town (UCT) in terms of the non-exclusive license granted to UCT by the author.

To Lana

University of Cape Town

DECLARATION

I, John Quail Davies, hereby declare that the work on which this thesis is based is original work (except where acknowledgements indicate otherwise), and that neither the whole work nor part of it has been, or is being, or is submitted for a degree in this or any other University.

I empower the University to reproduce for the purpose of research either the whole or any portion of the contents in any manner whatsoever.

A handwritten signature in black ink, appearing to read 'J. Quail Davies', written in a cursive style.

Signed

2002-05-12

ACKNOWLEDGEMENTS

I wish to express my sincere thanks and appreciation to the following persons:

Professor's R.O.C. Kaschula and C.C. Sinclair-Smith, my supervisors

Professor C. C. Sinclair-Smith, for the opportunity to undertake this study in his department

The Department of Paediatric Surgery at Red Cross Children's Hospital, Cape Town and Professor A.J.W. Millar for providing funding to perform the immunohistochemistry and *in-situ* hybridisation

Dr W Spearman and Dr M McCoulough for providing the valuable clinical information

Mr Mark Engel for his technical expertise and for performing the *in-situ* hybridisation

Dr H Wainwright for introducing me to the discipline of Paediatric Pathology and for all her enthusiasm during my registrar training

TABLE OF CONTENTS

	Page numbers
Abbreviations	8
List of tables	10
List of figures	11
Abstract	12
Chapter One: Introduction	14
Chapter Two: Epstein Barr Virus	
2.1 Introduction	16
2.2 Biology of EBV infection	18
2.3 Biology of EBV infection in PT-LPD	22

Chapter Six:	Discussion	
6.1	General	53
6.2	Pathology of cases at Red Cross Children's Hospital	55
6.3	Current guidelines in diagnosis of PT-LPD	58
6.4	EBV negative PT-LPD	61
6.5	Host vs. donor PT-LPD	61
6.6	EBV-associated leiomyosarcomas in PT-LPD	61
6.7	Recurrent PT-LPD	62
Chapter Seven	Recommendations for pathologists	
7.1	General	63
7.2	Diagnostic reporting	63
Appendix		65
1.	Suggested minimum data set for reporting	66
2.	Photomicrographs	68
References		71

ABBREVIATIONS

ATG	Anti-thymocyte globulin
BMT	Bone marrow transplantation
CMV	Cytomegalovirus
CT	Computerised tomography
CTL	Cytotoxic T lymphocyte
CSF	Cerebrospinal fluid
DNA	Deoxyribonucleic acid
EBNA	EBV Nuclear antigen
EBER	EBV-encoded RNA
EBV	Epstein-Barr Virus
GIT	Gastrointestinal tract
IFN α	Interferon alpha
IL	Interleukin
IVI	Intravenous infusion
IVIG	Intravenous gamma globulin
LAK cells	Lymphokine activated killer cells
LMP	Latent membrane protein
LP	Leader protein
ML	Malignant lymphoma
MM	Multiple myeloma
OLT X	Orthotopic liver transplant

PBCH	Polymorphic B-cell hyperplasia
PBCL	Polymorphic B-cell lymphoma
PCP	Pneumocystis carinii pneumonia
PLD	Polymorphic lymphoproliferative disorder
PT-LPD	Post transplant lymphoproliferative disorder
REAL	Revised European-American Lymphoma
RXH	Red Cross Children's Hospital
SCID	Severe combined immunodeficiency
TNF	Tumour necrosis factor
UCT	University of Cape Town
WHO	World Health Organisation
ZEBRA	Bam Z Epstein-Barr replication activator

LIST OF TABLES

	Page numbers
Table 1: Overview of EBV-associated malignancies	16
Table 2: Cytokines expressed by EBV-immortalized B-cells and during PT-LPD	23
Table 3: Incidence of paediatric PT-LPD according to organ transplanted	27
Table 4: Incidence of PT-LPD (all ages) in various types of transplants	27
Table 5: PT-LPD classification (Knowles et al)	29
Table 6: Prognosis of paediatric PT-LPD according to organ transplanted	36
Table 7: Patient profiles of paediatric PT-LPD (n=6), Red Cross Children's Hospital	51
Table 8: Pathology: correlation with morphology, clonality and EBV-ISH	52
Table 9: Categories of post-transplant lymphoproliferative disorders	59

LIST OF FIGURES

	Page numbers
Figure 1: EBV gene expression in EBV infected cells <i>in vivo and in vitro.</i>	19
Figure 2: Interactions between immunosuppressive drugs, Epstein-Barr virus, and cytokines	24
Figure 3a: Plasmacytic hyperplasia, lymph node	30
3b: Sinusoidal expansion by plasma cells	
Figure 4a: Polymorphic PT-LPD, tonsil	32
4b: Polymorphic PT-LPD, tonsil	
Figure 5: Polymorphic PT-LPD, tonsil (Reed Sternberg-like giant cells)	32
Figure 6: High grade B cell lymphoma; small bowel	34
Figure 7: CD20 immunohistochemistry, polymorphic PT-LPD	39
Figure 8: PCR: Monoclonal immunoglobulin heavy chain rearrangement	44
Figure 9: High grade B-cell PT-LPD, <i>in-situ</i> hybridisation for EBERs	45
Figure 10a: Malignant myeloma, small bowel	56
b: <i>In-situ</i> hybridization, malignant myeloma, small bowel	

ABSTRACT

Between 1985 and 2000, 43 children (age range 6 months-13 years) underwent liver transplantation at Red Cross Children's Hospital. In 46% of these cases, viral infections resulted in considerable morbidity and mortality. Included in this group were: *de novo* hepatitis B (5 patients, 2 deaths), EBV-related post-transplantation lymphoproliferative disease (6 patients, 4 deaths) and CMV disease (9 patients, 4 deaths).

Of the six children (age range 10-30 months) who developed PT-LPD, the mean time to the development of PT-LPD after transplantation was 9.2 months (range 3-30 months). The most common mode of presentation was adeno-tonsillar enlargement and associated upper airway obstruction (4 out of 6 children). The sites of involvement included: the tonsil (5 patients), mediastinum (2 patients), gastrointestinal tract (2 patients) and CNS (2 patients). Half of the cases that developed PT-LPD were EBV positive at the time of transplant.

Histological classification from seven tissue biopsies showed: polymorphic PT-LPD (4 cases), immunoblastic lymphoma (1 case), malignant myeloma (1 case) and plasmacytic hyperplasia (1 case). All were B-cell proliferations. There were five monoclonal and two polyclonal lymphoid proliferations. EBV RNA was detected by *in-situ* hybridisation in histological sections from five of the six patients.

Four patients died (67% mortality rate). The two survivors responded to a reduction in immunosuppression. Aggressive systemic chemotherapy was unsuccessful in two patients with disseminated disease.

An incidence of PT-LPD of 14% at Red Cross Children's Hospital is of concern, particularly as this was the direct or indirect cause of death in 9% of all paediatric liver transplant recipients treated in Cape Town. The development of

PT-LPD was associated with EBV driven disease in all instances. High immunosuppression dosages were an additional risk factor.

University of Cape Town

CHAPTER ONE:

INTRODUCTION

Organ transplantation is used increasingly to treat a variety of paediatric diseases. The success of transplantation depends on effective immunosuppression. Although this promotes acceptance of the allograft by the recipient, it impairs the host's ability to resist various infections.

In transplant patients, either primary Epstein-Barr Virus (EBV) infection or reactivation of latent EBV infection may promote the proliferation, and in some cases the malignant transformation of lymphoid tissue [1]. This results in a spectrum of diseases known as the Post Transplant Lymphoproliferative Disorders (PT-LPD).

PT-LPD has been recognised for the last thirty years as a discrete clinicopathological entity because of several constant characteristics: it occurs following transplantation of any organ, it is associated with EBV infection and lesions regress after reduction of immunosuppression in some cases [2].

In South Africa, liver transplantation has been available for infants and children for more than a decade. Since 1985, 43 orthotopic liver transplants (OLT) have been performed involving Red Cross Children's Hospital (RXH) patients [3]. In 46% of these cases, viral infections resulted in considerable late morbidity and significant mortality. Included in this group were: *de novo* hepatitis B (5 patients, 2 deaths), EBV-related post-transplantation lymphoproliferative disease (6 patients, 4 deaths) and cytomegalovirus (CMV) disease (9 patients, 4 deaths) [3]. EBV infection and its complications therefore proved to be a considerable management problem in this relatively small group of patients treated at RXH.

In this thesis, the group of PT-LPD patients was closely examined in order to document and determine the importance of clinical features, histological appearance, clonality and EBV status.

University of Cape Town

CHAPTER TWO:

EPSTEIN BARR VIRUS

2.1 Introduction

EBV is an enveloped herpes virus with a 172 kb double stranded DNA genome [4]. The tumours associated with Epstein-Barr Virus (EBV) in congenital and acquired immunodeficiency states reflect an imbalance in the normal control of EBV infection and are in the vast majority of cases B cell lymphoproliferations [5]. The virus is also linked to a subset of Hodgkin's disease and T cell lymphomas in apparently immunocompetent individuals [6,7,8].

Other EBV associated tumours include Burkitt's and Aids-related lymphoma in equatorial Africa as well as nasopharyngeal carcinoma in South East Asia [4].

Table 1. Overview of EBV-associated malignancies [4]

Tumour	Subtype	Typical latent period	EBV positivity
Burkitt's Lymphoma	Endemic	3-8 years post-EBV	100%
	Sporadic	3-8 years post-EBV	15-85%
	AIDS associated	3-8 years post-HIV	30-40%
Nasopharyngeal Carcinoma	Poorly/Non-differentiated	>30 years post-EBV	100%
Hodgkin's disease	MC/LD	>30 years post-EBV	80-90%
	NS	>10 years post-EBV	30%

T -cell lymphoma	VAHS/Fatal IM	<6 months post-EBV [^]	?100%
	Nasal	>30 years post-EBV	100%
	AILD/Pleomorphic	>30 years post-EBV	?40%
Immunoblastic lymphoma	Fatal IM	<6 months post-EBV [^]	100%
	TX-associated	<6 months post-TX [^]	100%
	TX-associated	> 1 year post-tr	100%
	AIDS-associated	5-10 years post-HIV	70-80%

[^]Tumours arising mainly in the context of primary rather than persistent EBV infection

MC/LD mixed cellularity/lymphocyte depleted

NS: nodular sclerosing

VAHS: Viral associated haemophagocytic syndrome

AILD: Angioimmunoblastic lymphadenopathy

IM: Infectious mononucleosis

TX: transplant

2.2 Biology of EBV infection

EBV targets B-lymphocytes through the CD21 receptor where it establishes a latent infection both *in vivo* and *in vitro* [5]. Following entry of the virus into the cell, the linear virion DNA circularizes to form an episome [9]. The viral genome remains as an episome (a genetic element that can exist and replicate either independently, or after integration into the host cell's genome) for many cell divisions before integrating into the cells DNA. Some cell lines maintain both integrated and episomal EBV DNA [4].

EBV infection in vitro

In vitro infection of B-lymphocytes with EBV results in the establishment of an immortalized B lymphoblastoid cell line. The majority of cells contain a non-replicating episomal form of the EBV genome. Only a small proportion of cells contain replicating virus [5]. The pattern of EBV expression in B cells varies depending on the type of latency established. Three latency states, termed latent-cycle type I, II and III have been characterized by the expression of EBV encoded latent antigens [9].

These antigens comprise of:

- six EBV nuclear antigens (EBNAs)
- two EBV-encoded RNA's (EBERs)
- three latent membrane antigens (LMFs).

In PT-LPD, EBV typically exhibits type III latency which is characterized by the expression of EBERs 1 and 2, EBNAs 1, 2, 3A, 3B, 3C, leader protein (LP) and LMP 1, 2A, 2B [9,10] (see figure 1). EBNAs 2, 3A, 3C and LMP1 are essential for B-cell immortalisation, while EBNA-1 and LMP2 are critical for maintenance of the EBV episome and the latent state, respectively [4,11,12]. EBNA LP is encoded by the leader of each EBNA mRNA and may play a role in EBV RNA transcription or processing [4].

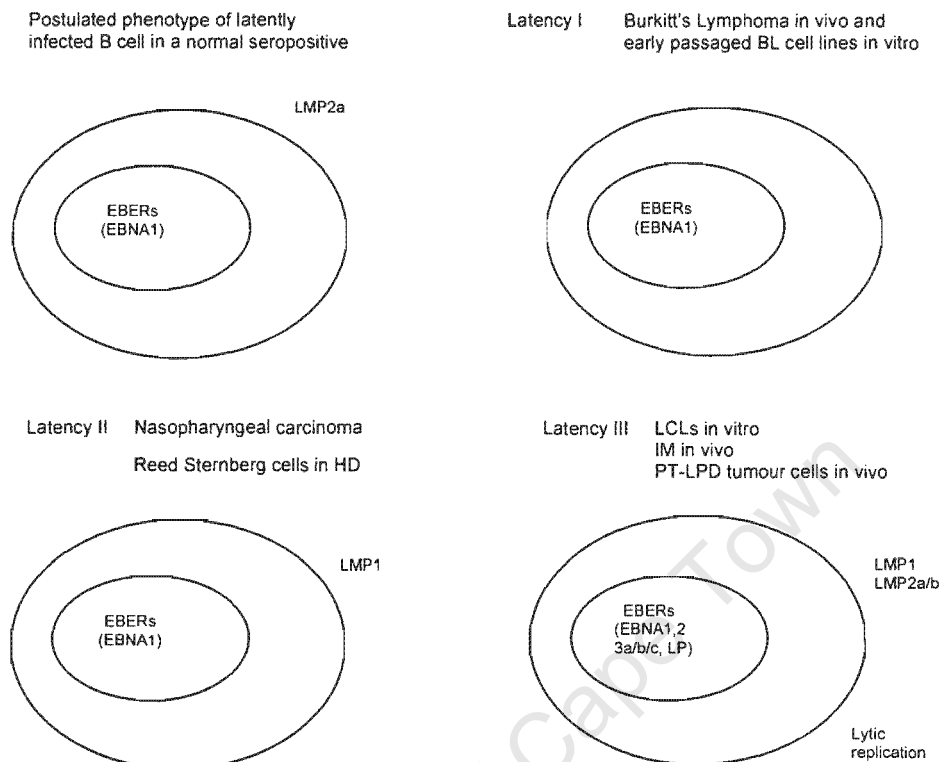


Figure 1. EBV gene expression in EBV infected cells *in vivo* and *in vitro* [from 5].

EBERs, EBV encoded small RNAs; EBNA, EBV nuclear antigen; IM, infectious mononucleosis; LCL, lymphoblastoid cell line; LMP, latent membrane protein; LP, leader protein; PTLD, post-transplant lymphoproliferative disease.

EBERs are small non-polyadenylated RNAs that are strongly expressed in EBV-infected tissue. They do not appear to be essential for B-cell immortalisation [13-15]. Although their function is uncertain, EBERs may be involved in blocking the effects of gamma-interferon within newly infected B-lymphocytes, thereby promoting the immortalisation process [16-19].

In summary, EBV transformed lymphoblastoid cell lines resemble normal proliferating B-lymphocytes, albeit immortalised and with the expression of EBV encoded proteins. This is in contrast to cells infected with other DNA tumour viruses such as SV40 or adenovirus, which alter cell growth by interaction with cellular oncogenes or tumour suppressor genes [5].

EBV infection in vivo

This can be divided into: early infection, persistent infection and the lymphoproliferative diseases [5].

1. Early infection

More than 95% of the adult population worldwide is infected with EBV [20]. Initial infection usually occurs in childhood following transmission of virus through salivary exchange to B-lymphocytes in pharyngeal lymphoid tissues. In general, primary infection of young healthy individuals is not accompanied by disease. However, should infection be delayed until adolescence, 50% of individuals will suffer infectious mononucleosis [21].

The symptoms and signs of infectious mononucleosis (fever, sore throat, myalgia, fatigue, lymphadenopathy, hepatosplenomegaly) are immunopathological in nature [22]. Antibodies develop early in infectious mononucleosis and include: the viral capsid antigen complex and the membrane antigen complex (gp350) [20]. IgG antibodies to EBNA1 and less consistently to EBNA2, -3A, -3B, -3C and LP develop late during infectious mononucleosis. In addition, non-specific serum heterophile antibodies can be detected in about 85% of cases of acute infectious mononucleosis. This forms the basis of the diagnostic Paul-Bunnell and monospot tests [22].

During this time, a large number of atypical mononuclear cells are seen in peripheral blood and infiltrating tissues. These are predominantly EBV-specific CD8⁺ HLA class

I restricted cytotoxic T lymphocytes (CTL) directed against latent and lytic cycle antigens [23].

2. Persistent infection

After recovery from primary infection, a healthy EBV carrier state is established. Here IgG antibodies against viral capsid antigen, membrane antigen complex gp350, and EBNA1 can usually be detected [20]. This suggests that EBV infected cells, during this stage of disease, are able to undergo lytic replication with transient expression of the full panel of latent antigens. Infected cells are able to evade the immune system and maintain a low level of persistent infection for a considerable time period [24].

Immune recognition follows and elimination of the infection occurs in the majority of cases [5]. EBV specific memory T cells in normal EBV seropositive individuals are present for life [25].

3. EBV in post-transplant lymphoproliferative disease (PT-LPD)

With immunosuppression, loss of CTL activity probably allows infected cells expressing a latency III phenotype to persist. This leads to the accumulation of EBV infected B cells in the body. There is also enhanced virus replication [26]. These changes mirror the loss of CTL activity and will return to normal when the level of immunosuppression is reduced [27,28]. This clinical scenario is sometimes called “reactivated” EBV infection. In most cases no disease will ensue [5].

Uncontrolled EBV driven B cell proliferation can occur in a minority of patients. This leads to clinically apparent post-transplant lymphoproliferative disease [5]. Why this should occur is unclear at this time.

2.3 Biology of EBV in PT-LPD

Most tumour cells in PT-LPD express the latency III pattern of EBV gene expression. A small proportion of cells undergo lytic replication [29,30]. The pattern of viral gene expression within a particular tumour may also vary between individual cells [31] and occasionally latency type I and/or II patterns have also been detected in PT-LPD biopsies [29,31,32]. In these cases, additional genetic or epigenetic changes are probably required for tumour development [5]. Specific antibodies detecting the early and late lytic-cycle antigens ZEBRA (BamZ Epstein–Barr replication activator) and virion glycoprotein gp350 have shown that up to 80% of these tumours have evidence of EBV early lytic cycle reactivation. This has also been confirmed using oligonucleotide probes that measure viral DNA. In addition, 30-40% of cases contain EBV late antigens or replicative DNA [33-35].

In tumour biopsy material, EBV positive cells often make up only a modest proportion of the tumour mass, with an extensive EBV negative lymphoid infiltrate comprising predominantly of CD4+ T lymphocytes [36]. *In vivo* experiments in severe combined immunodeficient (SCID) mice, where PT-LPD-like tumours can be generated following injection of human peripheral blood mononuclear cells, show that T cells are necessary for establishment of these tumours [37]. This suggests that the non-tumour element in PT-LPD is needed, possibly in supplying essential growth factors. Studies of SCID generated tumours have shown that the tumour cells produce cytokines that stimulate B cell growth in an autocrine fashion [38].

These cytokines are thought to contribute to B-cell growth and chemotaxis. Induction of many of these cytokines can be attributed to individual EBV genes, most notably LMP1 [9]. This is thought to be due to the ability of LMP1 to interact with the tumour necrosis factor (TNF) signaling pathway, inducing NF κ B and AP-1 - two transcription factors which control the expression of many

cytokines [39-43]. A summary of the cytokines expressed by EBV-immortalized cells *in vitro* and during PT-LPD can be seen in Table 2.

Table 2 Cytokines expressed by EBV-immortalized B cells and during PT-LPD [9]

Cytokine ¹	EBV Inducer	Immune action(s)
IL-1 α / β		↑ B cell growth, MF influx
IL-2		↑ NK activity, T cell differentiation
IL-4		↑ B cell growth
IL-5		↑ B cell growth
IL-6	LMP1, gp350	↑ B cell growth, ↓ NK activity
IL-8	LMP1	↑ T and MF influx, ↑ Selectins
IL-10	LMP1	↓ CTL, APC
IL-12	LMP1	↑ NK activity
IL-13		↑ B cell growth
TNF α	LMP1, gp350	↑ B cell growth, ↓ T cell activity
TNF β /lymphotoxin	LMP1	↑ B cell growth
TGF- β 1	ZEBRA	↑ B cell efflux
IFN- γ		↑ T, NK activity

¹ Boldtype indicates that cytokine is increased during PT-LPD.

MF, macrophage; CTL, cytotoxic T lymphocyte; APC, antigen-presenting cell; ZEBRA, BamZ Epstein-Barr replication activator.

Progression of PT-LPD from polyclonal to more aggressive monoclonal lesions regularly occurs in untreated cases or in recurrent lesions [44] and probably involves additional cellular genetic changes. Some studies have shown changes in the tumour suppressor gene p53 and oncogenes c-myc and N-ras in some cases [45,46]. These genetic changes may abolish the need for the expression of growth transforming EBV antigens, as in the case of rare EBNA2 and LMP1 negative tumours [29,30].

It has also recently been suggested that immunosuppressive agents CsA, FK506 and anti-CD3 antibodies may contribute to the pathogenesis of PT-LPD. In addition to inhibiting T cell function, these agents have also been shown to promote the EBV lytic cycle, to increase EBV growth and to increase resistance to immune killing by promoting expression of anti-apoptotic factors [9] (see figure 2).

The occurrence of PT-LPD in the transplanted organ may be due to the complex immunological interactions taking place during graft rejection or dysfunction that results in enhanced cytokine production [47,48].

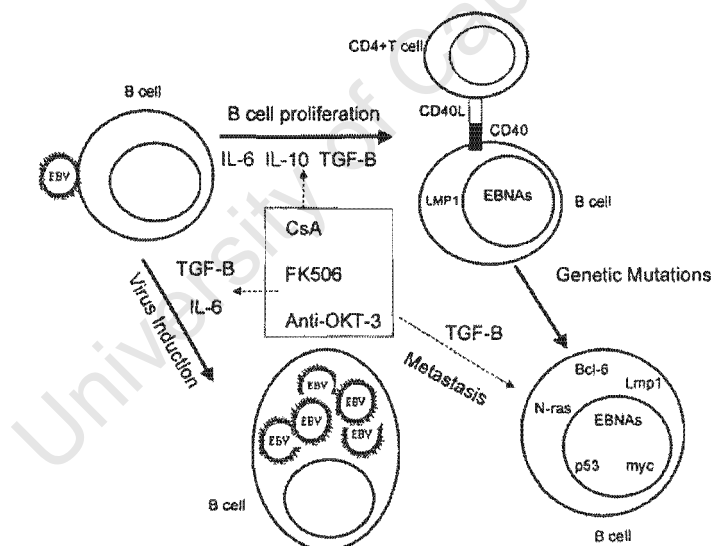


Fig 2. A schematic diagram of the interactions between immunosuppressive drugs, Epstein-Barr virus, and cytokines for the genesis of post-transplant lymphoproliferative disease [9]

The immunology and pathogenesis of PT-LPD is complex, the etiology of which is due to an interplay of several factors. These factors include the blocking of T-cell activity by immunosuppressive drugs, the expansion of EBV infected B-cells, the production of cytokines and mutations of oncogenes or tumour suppressor genes.

A better understanding of these mechanisms in the future may provide new information so that improved preventative and therapeutic strategies can be developed.

University of Cape Town

CHAPTER THREE:

POST TRANSPLANT LYMPHOPROLIFERATIVE DISORDERS IN CHILDREN

3.1 Epidemiology of Paediatric PT-LPD

PT-LPD was first described in renal transplant patients in the late 1960s [49], and is currently estimated to occur in 2% of all patients who receive an organ transplant [50].

One of the largest databases of tumours occurring in pediatric transplant patients is contained in the Cincinnati Transplant Tumor Registry [1]. Five hundred and twenty-seven tumours in 512 pediatric transplant recipients have been reported from around the world to this Registry [6]. Fifty-two per cent of these paediatric tumours were PT-LPDs. In comparison, PT-LPD made up only 15% of tumours reported in adult transplant recipients.

In this series, 47% of the paediatric patients with PT-LPD died. Sixteen per cent of these cases were diagnosed only at autopsy, emphasizing the importance of the paediatric pathologist.

The incidence of PT-LPD varies widely between transplant groups in the paediatric setting (see table 3). Different levels of immunosuppression between the groups may contribute to this finding [50].

Table 3. Incidence of paediatric PT-LPD according to organ transplanted

Organ transplanted	Incidence of PT-LPD
Liver	6.8-13.1% [51,52,53]
Heart	10% [54]
Heart & lungs	3.8-11.7% [55,56]
Kidneys	2.6-9% [57-60]
Bone marrow (adults included)	1-30% [61,62]

These figures can be compared to larger series, incorporating predominantly adult patients (see Table 4) where a generally lower incidence of PT-LPD is present.

Table 4. Incidence of PT-LPD (all ages) in various types of transplants [63]

Kidney	1%
Liver	2.2%
Heart	3.4%
Lung	1.8-7.9%
Heart-lung	9.4%
Intestinal	7-11%
Multivisceral	13-33%
Bone Marrow	<1%

In a study confined to liver transplant recipients, 19% of children developed symptomatic EBV infection compared to 2.7% of adults. Twenty-two percent of children under the age of five years developed EBV infection, compared to

10.8% of older children [52]. All cases of paediatric PT-LPD in that series occurred in children under five years of age [52].

Most young children are EBV-naive at the time of transplant. EBV seronegativity at the time of transplant appears to partly account for the higher incidence of PT-LPD in children [2,52,56,63-66]. Paediatric patients with higher EBV burdens in the peripheral blood have also been shown to be at greater risk for developing PT-LPD [67].

There is mounting evidence to suggest that infection with cytomegalovirus (CMV) is also an additional important risk factor for the development of PT-LPD [63]. Mismatching for CMV, where a seronegative recipient receives an organ from a seropositive donor, has been associated with a several-fold increased risk of PT-LPD in recipients of non-renal solid organ transplants [68]. This finding has been confirmed in other studies [59,69] and may be due to the combined loss of immune control for CMV and EBV due to high dose immunosuppression. It is also possible that reactivation of CMV has profound effects on the immune system by inducing cytokine production, thereby directly transactivating EBV genes [70].

It has been reported that Hepatitis C virus (HCV) may also be associated with the development of PT-LPD in patients with HCV-associated cirrhosis [71]. Verification of this finding does however require further study.

In summary therefore, it is generally accepted that PT-LPD is more common in the paediatric age group, it is more likely to occur in certain types of organ transplants and is more likely to occur in patients who are seronegative for EBV, as well as CMV at the time of transplant.

3.2 Pathology of PT-LPD

Over the last 15 years three major PT-LPD classifications have been published by *Frizzera et al* [72], *Nalesnik et al* [73], and *Knowles et al* [45]. Modifications of these schemes have also been reported [74-76] indicating the difficulties encountered in establishing reproducible and/or clinically relevant classifications.

A comprehensive review of the above classifications is beyond the scope of this thesis (see *Seminars in Diagnostic Pathology 1997;14: 2-7* [77]). Currently, the classification according to *Knowles et al* appears to be the easiest to interpret and has been used recently at Red Cross Children's Hospital. This scheme has the distinct advantage of correlating morphology with molecular genetics. A recent modification of this system will be discussed (see Chapter 6.3).

Three broad groups of PT-LPD are present in this classification, with the B cell lymphoproliferations subdivided into three further categories (Table 5)

Table 5. PT-LPD classification (Knowles et al. [45])

-
1. Probably benign
 2. B cell PT-LPD
 - i. plasmacytic hyperplasia
 - ii. polymorphic lymphoproliferative disorder
 - iii. malignant lymphoma/multiple myeloma
 3. T cell PT-LPD
-

A brief pathological description of the latter two categories follows:

Plasmacytic hyperplasia

There is retention of the underlying architecture of the lymph node or tissue of origin in these lesions. In nodal disease there is an expansion of the interfollicular zone by small lymphocytes, plasmacytoid lymphocytes and plasma cells. Scanty immunoblasts may be present and there is little or no cytological atypia [45,73].

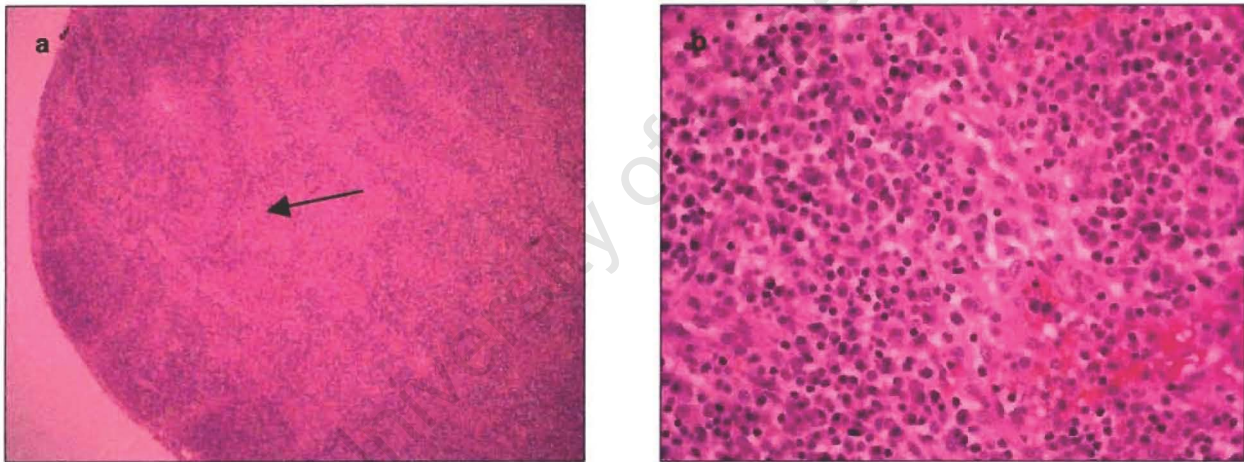


Fig 3a: Plasmacytic hyperplasia. Note the expansion of the sinusoids.
(Case 3; Frozen section, H&E x 4)

Fig 3b: Sinusoids expanded by numerous plasma cells.
(Case 3; H&E: x 400)

Generally these lesions are composed of mixed B and T lymphocytes, there are no clonal immunoglobulin light/heavy-chain or T cell receptor gene rearrangements and there are no structural abnormalities of proto-oncogenes or tumour suppressor genes (including *bcl-1*, *bcl-2*, *c-myc*, *H-ras*, *K-ras*, *N-ras*, and *p-53* [45,74]. Most, but not all of these lesions contain evidence of EBV infection [45,74] which may be a polyclonal, oligoclonal or monoclonal as determined by Southern Blot hybridisation using a probe to the EBV terminal repeat region [45].

Lesions usually develop early after transplantation (4 months on average) and often occur in Waldeyer's ring or lymph nodes. Virtually all these lesions regress after reducing the immunosuppression [45,73,78]. Only in very rare occasions will recurrent disease develop. The clinical course of these patients depends on the morphological and molecular features of the recurrent lesion [45].

Polymorphic Lymphoproliferative Disorder

In these lesions there is obliteration of the architecture of the tissue by a polymorphic lymphoid proliferation [45,72,78,79]. Tumours range in appearance from small plasmacytoid lymphoid cells and immunoblasts without significant cytological atypia, to lesions lacking plasmacytoid differentiation and containing highly atypical immunoblasts. This category is therefore a spectrum of morphological characteristics, combining the polymorphic B-cell hyperplasia (PBCH) and polymorphic B-cell lymphoma (PBCL) categories described in the classification according to *Frizzera et al* [72].

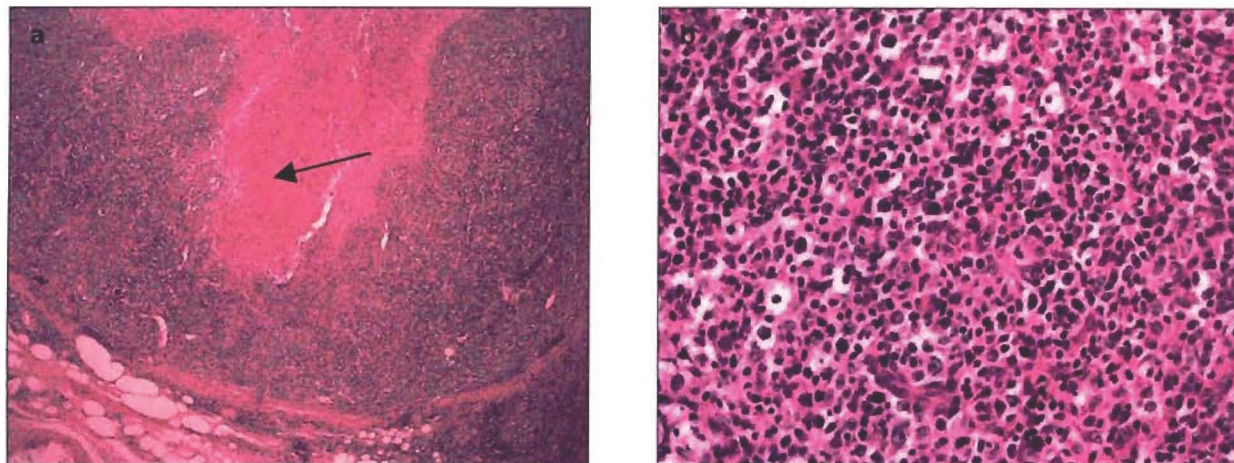


Fig 4a: Polymorphic PT-LPD involving the tonsil. Note the loss of normal architecture and large area of necrosis. (Case 5; H&E x 4)

Fig 4b: Polymorphic PT-LPD. Note the polymorphic population of lymphocytes, some of which are atypical. (Case 5; H&E x 400)

Additional histological features include areas of necrosis, 'squiggle' cells (accompanying T cells) and immunoblasts, which may resemble Reed-Sternberg cells [45,72,79,80].

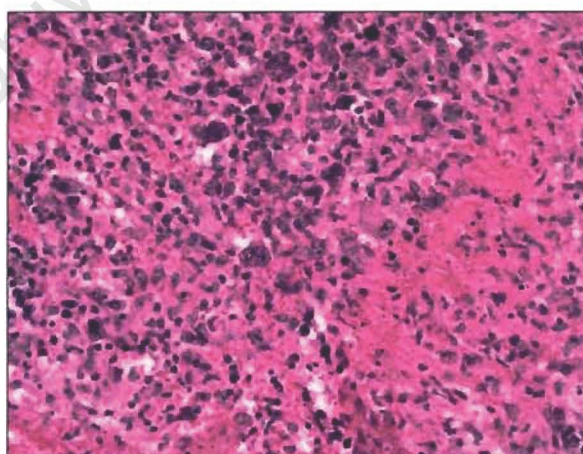


Fig 5: Polymorphic PT-LPD, tonsil. Note the Reed Sternberg-like giant cells and foci of necrosis. (Case 5; H&E x 400)

Polymorphic lymphoproliferative disorders (PLD) show clonal rearrangements of the immunoglobulin heavy-chain gene and have clonal evidence of EBV infection. There is no evidence of abnormalities in proto-oncogenes or tumour suppressor genes [45,74].

PLDs occur frequently in extranodal sites such as the gastrointestinal tract and lung [79,81] and develop 5 to 96 months after transplantation (median, 11 months) [78]. The clinical course in this group is variable, with some cases regressing after reducing immunosuppression and others requiring chemotherapy or radiotherapy. In general the prognosis in this group is said to be favourable, with a median survival of 21 months [78].

Malignant lymphoma / Multiple myeloma

Histologically these lesions are similar to cases of malignant lymphoma (ML) and multiple myeloma (MM) occurring in immunocompetent individuals [45,82-84]. Most of the cases in this group would be classified as diffuse large B-cell lymphomas in the Revised European-American Lymphoma (REAL) or WHO classifications [85,86]. Occasionally, cases resemble Burkitt lymphomas or High Grade B-cell lymphomas of the Burkitt-like subcategory [84,87].

These neoplasms usually show evidence of clonal EBV infection and are monoclonal based on immunoglobulin gene rearrangements [45,83,84,88]. They are unique, in comparison to the other B cell derived PT-LPD disorders, in that they consistently contain structural aberrations in proto-oncogenes or tumour suppressor genes such as *c-myc*, *p53* and *N-ras* [47,74].

Patients usually present with widespread disease (Stage III or IV) and despite optimal therapy there is usually a poor clinical outcome. In addition, cases of

MM may occasionally result in a monoclonal gammopathy with lytic bone disease [78,82,84,87].

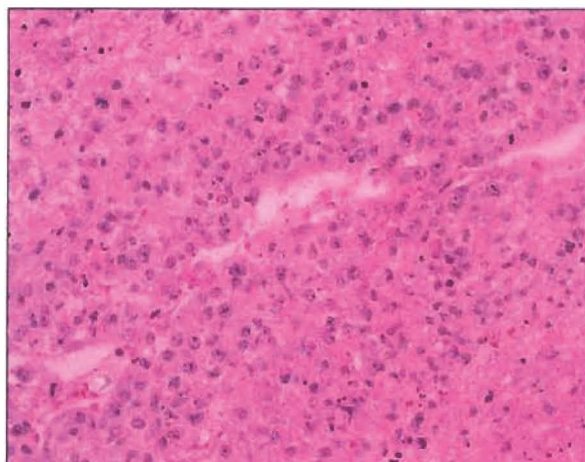


Fig 6: High-grade B cell lymphoma; PT-LPD small bowel. Note the numerous immunoblasts and high mitotic rate. (Case 4; H&E x 400)

T-Cell PT-LPDs

These lesions are relatively rare in the post-transplant setting and less than twenty cases have been reported in the literature [46]. They tend to occur late after transplantation (median time of 5 years) and are less strongly associated with EBV infection (approximately 50% of cases positive) [46,73,78]. The existence of T-cell PT-LPD therefore remains controversial [46].

The examples include cases of lymphoblastic lymphoma, peripheral T-cell lymphoma and anaplastic large cell lymphoma [46].

In general, PT-LPD often develops in sites that are unusual in the context of other lymphomas [5]. This is particularly prominent in EBV seropositive individuals with late onset disease [89]. These tumours are often localised and extranodal, commonly occurring in the gastrointestinal tract, central nervous

system, or grafted organ [30,90,91]. Tumours developing in the transplanted organ are most common in lung transplant recipients [92], the reasons for which are unknown.

University of Cape Town

3.3 Prognosis in paediatric PT-LPD

Mortality from PT-LPD is high and is estimated to be 60-70% [2,93,94]. This depends on a number of factors: including the type of transplant, the length of time to onset of disease and whether EBV seroconversion occurs.

The mortality from PT-LPD is highest in paediatric bone marrow transplant recipients and appears to be lowest in heart transplant recipients (see Table 6).

Table 6 Prognosis of paediatric PT-LPD according to organ transplanted

Organ transplanted	Mortality
Bone marrow	96-100% [1,95]
Liver	44-66% [1,53]
Kidneys	48% [59]
Thoracic	36% [56]
Heart	0-25% [1,56]

The length of time from transplant to the development of PT-LPD may predict prognosis better than the type of organ transplanted [1]. Most paediatric liver transplant patients who die with PT-LPD, present less than six months following transplantation. Those who survive usually became symptomatic more than six months after transplant [1,53]. A similar pattern is thought to be present in other transplanted organs, however larger studies are required in children to confirm this finding [1].

PT-LPD histology, as well as clonality does not correlate consistently with outcome, making patient management problematic. Monomorphous lesions are generally resistant to treatment in the majority of cases, however regression with reduced immunosuppression as the only treatment has been reported [73,96].

Conversely, lesions with bland histology may pursue an aggressive clinical course [93].

It is interesting that the histology and clonality in PT-LPD may change over time within the same patient [76,93]. The pathologist's analysis of surgical material may therefore not be representative of the most aggressive PT-LPD clone. It has been shown that even within an individual tumour, polyclonal proliferations can coexist with clonal populations [45].

Structural alterations in tumour suppressor genes and/or oncogenes are invariably associated with aggressive disease requiring intensive treatment and a poor prognosis [46,97]. Every attempt should therefore be made to obtain fresh tissue so that these investigations can be performed.

University of Cape Town

3.4 Management in paediatric PT-LPD

Drawing conclusions from the available paediatric literature is difficult, as the studies are generally small, anecdotal, and complicated by diversity in the presentation and histological features of PT-LPD [5]. It is generally accepted that the first line of therapy is reduction or withdrawal of immune suppression. This allows the host to recover natural immune surveillance [98]. Regression of lesions will occur in 23-86% of patients, the wide variation probably explained by differences in the definition of PT-LPD in the major centers [2,99]. Most cases that respond to this treatment do so within 2-4 weeks [98]. There are however isolated examples of children having a belated response after several months of reduced immunosuppression alone [100,101].

Apart from the reduction of immunosuppression, optimal management of PT-LPD in both paediatric and adult patients is controversial [98]. The use of acyclovir or gancyclovir has become routine [2,56,99,102] based on the *in vitro* activity of these agents, as they inhibit the lytic phase of EBV deoxyribonucleic acid (DNA) [103,104]. Gancyclovir is favored as it is approximately ten times more potent than acyclovir *in vitro* [103] and also has activity against CMV co-infection [98]. Many have questioned the efficacy of this therapy as no prospective, comparative clinical trials have been conducted using these drugs. In addition, most of the EBV infected cells in PT-LPD are transformed B cells that are not undergoing lytic infection [45,74,105]. Neither acyclovir nor gancyclovir suppress EBV-driven proliferation of B cells *in vitro* or B cells that are latently infected with EBV [103,104]. It has been said that the only reason to give these agents is to prevent a small number of lytically infected cells within PT-LPD lesions from spreading EBV to new clones of previously uninfected B cells [98].

Interferon (IFN α) alpha has been used in many anecdotal instances with uncertain efficacy [56,98,99,106-109]. IFN α may function as a pro-

inflammatory mediator as well as a natural antiviral agent. Its precise mode of action however is uncertain [108]. In the largest reported study using this therapy, a high relapse rate occurred with an added complication of rejection and infection in half of the cases [110,111].

Immunotherapy using intravenous gammaglobulin (IVIg) or anti-B cell monoclonal antibodies are agents used in some centers with theoretical therapeutic value [45,106,107,109]. Promising results for polyclonal disease with anti-CD 21 and anti-CD 24 monoclonal antibodies have been reported in the treatment of PT-LPD in recipients of both bone marrow and solid organs [112-114]. Although these drugs are no longer in use, a new drug approved for the treatment of certain CD20-positive B cell-non-Hodgkin's lymphomas called rituximab [115] (an anti-CD20 monoclonal antibody), may certainly be of benefit.

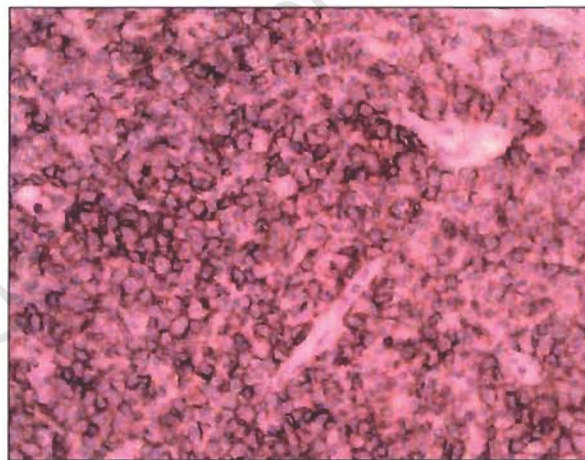


Fig 7: Polymorphic PT-LPD, tonsil. Strong membrane staining for CD20.
(Case 6; CD20 immunohistochemistry x 400)

It is important therefore that the pathologist prove strong CD20 immunoreactivity within the tumour to be treated, before such therapy is considered [98]. Reports of patients with PT-LPD treated with this agent appear

to be promising [92,116-118]. In a multicentre study, there was a 65% response rate to rituximab in 26 solid organ associated PT-LPDs. Eleven of these patients were long term survivors [117].

Recently, because interleukin-6 (IL-6) has been described as a growth factor for EBV-infected B cells, anti-IL-6 monoclonal antibody therapy has been tested in a phase I-II clinical trial with encouraging preliminary results [119]. Complete remission, as judged by complete clinical and radiological disappearance of all tumours, was achieved in 5 cases out of 12. No relapses occurred in these patients, with a follow-up from 15 to 27 months [119].

One of the most exciting areas in the treatment of EBV disease and PT-LPD is the use of cellular therapies involving T lymphocytes. EBV-specific cytotoxic T lymphocytes (CTL) have been used in the management of PT-LPD in bone marrow transplant (BMT) recipients [120,121].

This therapy is relatively straightforward in BMT as the proliferating lymphoid tissue is generally of donor cell origin [5]. CTLs obtained from the original donor can therefore be infused, as they will recognise and destroy the EBV-infected B cells in the recipient. This is in contrast to PT-LPD occurring in solid organ transplants where the lesions are typically of recipient, not donor origin. [122-124]. EBV-specific CTLs from the recipient are therefore needed for a comparable strategy to be effective.

This is further complicated, particularly in the paediatric population, as recipients are often EBV-naïve at the time of transplant. In these cases autologous CTLs must be grown *in vitro* from T cells obtained before transplantation. In addition these cells may need to be 'stimulated' or immunised against EBV [5,98]. An alternative approach is to obtain an HLA-identical donor so that CTL can be grown from this source and infused into patients with PT-LPD [125,126].

Interleukin-2 stimulated lymphokine-activated killer (LAK) cells of recipient origin have been used as an alternative to EBV-stimulated CTLs [127]. This therapy avoids *ex vivo* immunization of recipient cells, but is non-specific and also results in the additional possibility of organ rejection. More clinical experience is required in this form of therapy [98].

Finally, it is generally accepted that the use of radiation therapy and surgery should be restricted to the management of local complications (such as bowel obstruction) as PT-LPD is a systemic disease [98]. Uniform guidelines concerning the use of chemotherapy in children are not available at the present time. Some centers are strongly in favour of this treatment, whereas others advocate a more cautious approach suggesting initial withdrawal of immunosuppression and the commencement of antiviral therapy [98,128].

Patients with an obviously malignant tumour containing tumour suppressor or proto-oncogene abnormalities (e.g. Burkitt lymphoma) should be immediate candidates for chemotherapy [98].

There is however no current consensus on which PT-LPD lesions are truly 'malignant'. Some centers use the term 'lymphoma' for tumours that are still likely to be immune responsive [129]. As with all rare malignancies a uniform international pathological classification, incorporating all the available molecular technology, should be used to stratify patients so that uniform guidelines can be established.

CHAPTER FOUR

AIM, MATERIALS AND METHODS

4.1 Aim

To document the experience of PT-LPD in 43 paediatric liver transplant recipients seen at Red Cross Children's Hospital in order to document and determine the importance of clinical features, histological appearance, clonality and EBV status.

4.2 Materials And Methods

Study population: Between November 1991 and December 2000, 43 children (age range 6 months-13 years) underwent liver transplantation at Red Cross Children's Hospital. The indications for transplantation were biliary atresia (25 patients), inborn errors of metabolism (6 patients), fulminant liver failure (8 patients), autoimmune hepatitis (2 patients) and cryptogenic cirrhosis (2 patients). Transplanted allografts consisted of full-size livers in 19 cases and reduced-sized cadaver livers in 24 cases.

Immunosuppression: The standard immunosuppressive regimen at RXH is cyclosporin-based triple drug therapy, as outlined below:

Cyclosporin was administered at a dosage sufficient to achieve whole blood trough levels of approximately 300ng/ml in the first month, thereafter progressively decreasing the trough levels to a level of 150ng/ml.

Corticosteroids were administered intravenously at an initial dose of 10mg/kg/day on postoperative day one, gradually decreasing to 1mg/kg/day by day five and 0.2 - 0.5mg/kg/day by one month.

Azathioprine was administered at 0.5-1mg/kg/day, aiming at a white cell count of $4-6 \times 10^9/l$. Azathioprine was discontinued at six months with most patients being maintained on cyclosporin and low dose steroids.

No induction therapy with OKT3 or ATG was used.

Rejection episodes were managed with pulsed Medrol 5-10mg/kg/day for three days. If there was continued evidence of rejection after three days of intravenous (IVI) Medrol, patients were converted to tacrolimus aiming for a level of 10-14ng/ml initially until stable, gradually decreasing to a level of 6-8ng/ml.

Anti-viral therapy: Prior to 1996 all patients received prophylactic acyclovir, initially IVI and then orally. Since 1996, all CMV seronegative patients of allografts from seropositive donors received IVI gancyclovir (5mg/kg/day bd) for the first 2 weeks post-transplant. They were also covered with IVI gancyclovir if they received pulsed medrol for control of rejection. Immune globulin preparations in the form of cymovene (CMV hyper immune globulin) or polygam were also used.

EBV status: EBV status as determined by measuring EBNA serology was assessed before transplantation and at the time of diagnosis of PT-LPD.

Diagnosis of PT-LPD: The diagnosis of PT-LPD was suspected in patients presenting with pyrexia of unknown origin, failure to thrive, lymphadenopathy, adeno-tonsillar enlargement with airway obstruction and unexplained GIT symptoms. The diagnosis was confirmed histologically on biopsy of lymph nodes, tonsils and intra-abdominal masses. Where indicated, bone marrow and cerebrospinal fluid was examined.

Tumour morphology was determined by light microscopy on paraffin-embedded tissue. All slides were re-cut, stained with haematoxylin and eosin and classified according to the system of Knowles et al [45] by one pathologist (JD) at a single sitting. Immunohistochemistry using the monoclonal antibodies CD20 and CD3 was also performed.

Clonality was assessed by immunoglobulin heavy-chain gene rearrangement as previously described [130]. High molecular weight DNA was isolated from formalin-fixed paraffin-embedded tissue samples, according to standard proteinase K digestion and organic extraction procedures. PCR amplification was performed in a Perkin Elmer GeneAmp PCR System 9600 using consensus primers VH5' CTG TCG ACA CGG CCG TGT ATT ACT G 3' and JH5' AAC TGC AGA GGA GAC GGT GAC C 3', (Oligos, Etc., Portland, Oregon, USA).



Fig 8: Monoclonal immunoglobulin heavy chain rearrangement detected by PCR.
Test case (T), negative control (-), positive control (+).
(Case 4)

Detection of EBV: Epstein-Barr virus RNA in-situ hybridisation studies were performed using an oligonucleotide probe targeting EBV-encoded small RNAs, which are actively transcribed (up to 107 copies per cell), in latently infected cells [131]. Briefly, 5 µm paraffin sections of formalin-fixed tissues were mounted on slides coated with 3-aminopropyltriethoxysilane, deparaffinised, dehydrated, pre-digested with proteinase K, and then hybridised for 2 hours at the manufacturer's concentration of probe. RNAase-free precautions were observed to minimise contamination with RNAase throughout the procedure until the hybridisation stage. After washing, hybridisation was detected using avidin-alkaline phosphatase conjugate followed by development of the signal with fuchsin substrate; haematoxylin was used as a counter stain. A positive result was indicated by a red or magenta colour in the nucleus. A known EBV-positive Hodgkin's lymphoma section was used as the external control.

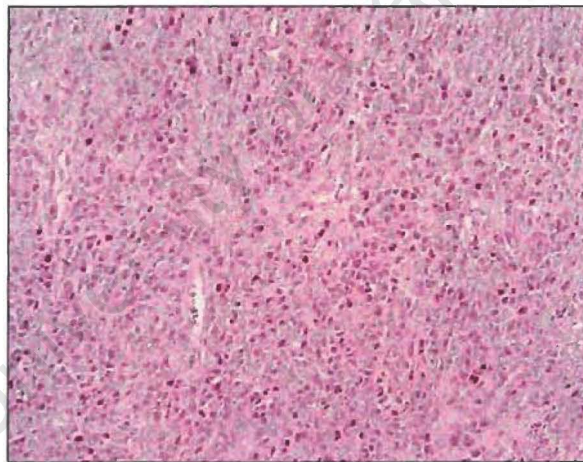


Fig 9: High grade B cell PT-LPD, small bowel. *In-situ* hybridisation showing strong nuclear EBER staining.
(Case 4; x 200)

CHAPTER FIVE

RESULTS

5.1 Incidence and location of PT-LPD:

Six of 43 children (age range 10-30 months) developed PT-LPD. All had been transplanted for biliary atresia following a failed Kasai procedure. The mean time to the development of PT-LPD was 9.2 months (range 3-30 months) post transplantation. There were four males and two females. Three of the patients were white, two were of mixed racial origin and one was black.

Sites of involvement: tonsillar (5 cases), mediastinum (2 cases), gastrointestinal tract (2 cases) and CNS (2 cases).

5.2 Patient Profiles:

Case 1: Aged 14 months (W, F), was EBV EBNA positive at time of transplant. She developed steroid-resistant rejection requiring pulsed medrol, conversion to tacrolimus and high dose maintenance steroids (2mg/kg/day). Attempts to decrease steroids and tacrolimus levels <12ng/ml were associated with deteriorating liver function. She presented four months post transplant with upper airway obstruction and underwent tonsillectomy and adenoidectomy.

Histology: The lymphoid tissue from both the tonsil and adenoid showed an infiltrating lymphoid population, distorting the normal architecture. The cells ranged in shape and morphology. Centroblasts and centrocytes were prominent.

Numerous, non-malignant T-lymphocytes were identified on CD3 staining. The features were therefore those of a typical polymorphic B-cell PT-LPD.

B-cell gene rearrangement: Monoclonal.

Management: Immunosuppression was withdrawn, the PT-LPD resolved but she developed chronic ductopaenic rejection requiring re-transplantation.

Outcome: Patient is disease free, 4 years after initial diagnosis.

Case 2: Aged 10 months (C, M), was EBV EBNA negative at time of transplant. Four months post transplant, he presented with adeno-tonsillar enlargement and upper airway obstruction; becoming EBV EBNA positive. Tonsillectomy and adenoidectomy were performed.

Histology: Confirmed a polymorphic B cell PT-LPD with features similar to case 1. Areas of necrosis were also seen.

B-cell gene rearrangement: Oligoclonal.

Management: Immunosuppression was reduced (Azathioprine stopped, medrol decreased to alternate days and cyclosporin trough levels maintained between 50-80mg/ml). IVI gancyclovir was administered.

Outcome: PT-LPD resolved and the patient remains disease free, 16 months after diagnosis.

Case 3: Aged 2.5 years (C, M), was EBV EBNA positive at time of transplant. Compliance was poor with erratic attendance at clinic. He developed steroid-resistant rejection and was converted to tacrolimus. Two and a half years post transplant, he presented with recurrent chest infections and failure to thrive, associated with bone marrow suppression. He also developed mediastinal lymphadenopathy with superior vena cava obstruction and recurrent pericardial effusions.

Histology: A frozen section was performed intra-operatively, showing lymphoid tissue, 'not obviously malignant'. Examination of the paraffin fixed tissue

showed a reactive lymph node with preservation of the architecture and subcapsular sinus. Large numbers of normal plasma cells expanded the interfollicular areas, compatible with a diagnosis of plasmacytic hyperplasia.

B-cell gene rearrangement: Oligoclonal.

Management: Attempts at decreasing immunosuppression were associated with deteriorating liver function. He was given IVI gancyclovir, polygam and one cycle of chemotherapy (vincristine, cyclophosphamide, low dose prednisone). His course was complicated by development of PCP pneumonitis, disseminated aspergillosis and adenoviral pneumonitis.

Outcome: The patient died seven weeks after diagnosis with no evidence of residual tumour. This was confirmed by post mortem examination.

Case 4: Aged 17 months (W, M), was EBV EBNA negative at time of transplant. Follow-up was erratic with frequently documented high cyclosporin levels. Five months post transplant, he presented with failure to thrive, an abdominal mass and a gastrointestinal (GIT) bleed. He underwent exploratory laparotomy where necrotic small bowel was resected. Resection lines were not free of tumour.

Histology: Showed a malignant B-cell lymphoma infiltrating all layers of bowel, mesentery and adipose tissue. There were large areas of tumour necrosis and a 'starry sky' appearance was seen in areas. The cells were predominantly large, with prominent, often red nucleoli in keeping with immunoblastic cytology. Bone marrow and cerebrospinal fluid (CSF) were clear.

B-cell gene rearrangement: Monoclonal

Management: Immunosuppression was withdrawn, IVI gancyclovir was administered and chemotherapy commenced. This consisted of a modified COP regimen: One cycle of vincristine, cyclophosphamide and prednisone followed by a second cycle of vincristine and prednisone. This was followed by COPADM (vincristine, cyclophosphamide, prednisone, methotrexate, adriamycin and intrathecal triple therapy).

Outcome: Despite intensive chemotherapy, the patient developed CSF involvement within three weeks. A computerised tomogram (CT) scan of the abdomen showed only a minor reduction in abdominal mass size. Treatment was discontinued and the patient died 10 weeks after diagnosis.

Case 5: Aged 2 years, 3 months (W, M) was EBV EBNA positive at time of transplant. He developed steroid-resistant rejection requiring pulsed medrol and conversion to tacrolimus. He presented 3 months post transplant with adenotonsillar enlargement and upper airway obstruction. Tonsillectomy and adenoidectomy were performed.

Histology: Showed a polymorphic B cell lymphoma of the tonsil. Cells ranged from small centrocytes to larger centroblasts. There were large, sometimes confluent areas of necrosis. Bone marrow and CSF were clear.

B-cell gene rearrangement: Monoclonal.

Management: Immunosuppression was reduced. IVI gancyclovir and polygam were administered and chemotherapy was commenced. Chemotherapy consisted of COP- one cycle of vincristine, low dose of cyclophosphamide and prednisone and a second cycle of vincristine, high dose cyclophosphamide and prednisone.

Whilst on chemotherapy, he developed abdominal pain and a GIT bleed. Exploratory laparotomy revealed tumour involvement of the small bowel with a perforation.

Histology: The whole bowel wall was infiltrated by a malignant lymphoma with plasmacytoid cytology (malignant myeloma). The atypical plasma cells were large and often binucleated. Tumour necrosis was not apparent. Resection lines were not free of tumour.

B-cell gene rearrangement: Monoclonal

Outcome: Three weeks after diagnosis, he developed CSF involvement, was given intra-theal methotrexate, but died three days later, 10 weeks after the diagnosis was made.

Case 6: Aged 2 years 3 months (B, F) was EBV EBNA negative at time of transplant. She developed steroid-resistant rejection, requiring pulsed Medrol and conversion to tacrolimus. Four months post transplant, she presented with upper airways obstruction and was EBV EBNA positive. Tonsillectomy and adenoidectomy were performed.

Histology: Showed the tonsil to be replaced by a polymorphic lymphoid infiltrate. There was loss of the underlying normal architecture. The larger, more atypical lymphocytes were positive for CD20 on immunohistochemistry. The features were those of a polymorphic B cell PT-LPD.

B-cell gene rearrangement: Monoclonal.

Management: Gallium scan revealed extensive mediastinal uptake, compatible with lymphadenopathy. Immunosuppression was reduced and IVI gancyclovir was commenced.

Outcome: She died eight days after tonsillectomy.

A summary of the clinical findings, therapy and outcome can be seen in table 7.

Table 7 Patient profiles of Paediatric Post-transplant lymphoproliferative disorders (n=6), Red Cross Children's Hospital

Case	Age*	EBV†	Interval‡	Site	Immunosuppression	Therapy	Outcome
1	14	+	4	Tonsil	Withdrawn		Regression, Rejection, ReTx, Alive
2	10	-	4	Tonsil	Reduced	Gan	Regression, Alive, FOD
3	30	+	30	Mediastinum	Reduced	Gan, Pol, Cmt	Died, FOD
4	17	-	5	Ileum, CNS	Withdrawn	Gan, Cmt	Died of disease
5	27	+	3	Tonsil, Ileum, CNS	Reduced	Gan, Pol, Cmt	Died of disease
6	27	-	4	Tonsil, mediastinum	Reduced	Gan, Pol	Died with disease

Ts, tonsil; Gan, gancyclovir; Pol, polygam; Cmt, chemotherapy; FOD, free of disease; ReTx, re-transplant.

*Age in months.

†EBV status at transplant.

‡Time from transplant to PT-LPD diagnosis (months).

5.3 EBV expression by *in situ* hybridisation

Results of the EBV investigation are indicated in table 8. The EBER-ISH technique gave clear results with positive cells identifiable confidently and with minimal background staining. EBV RNA was detected in the nuclei of eight out of nine histological sections studied. EBERs were not detectable in areas of necrosis.

Table 8 Pathology: correlation with morphology, clonality and EBV-ISH

Case	Site	Morphology	Clonality	EBV-ISH
1	Tonsil	Polymorphic PT-LPD	Monoclonal	+
2	Tonsil	Polymorphic PT-LPD	Oligoclonal	+
3	Mediastinum	Plasmacytic hyperplasia	Oligoclonal	-
4	Ileum	Immunoblastic lymphoma	Monoclonal	+
5	Tonsil	Polymorphic PT-LPD	Monoclonal	+
	Ileum	Malignant myeloma	Monoclonal	+
6	Tonsil	Polymorphic PT-LPD	Monoclonal	+

CHAPTER SIX

DISCUSSION

6.1 General:

Of the 43 liver transplant recipients treated at Red Cross Children's Hospital, six developed a post transplant lymphoproliferative disorder.

Although this represents an incidence of PT-LPD of 14%, any statistical analysis and comparison with the reported literature should be viewed with caution in view of the very small sample size. Nevertheless, other centres report a comparable incidence of 6.8-13.1% in a similar age group of patients [1,2].

There appears to be a relatively high incidence of this complication at RXH, which is of some concern, particularly as PT-LPD was the direct or indirect cause of death in 9% of all paediatric liver transplant recipients treated in Cape Town.

Several factors are known to greatly increase the risk of developing PT-LPD in the early post-transplant period. Pre-transplant EBV seronegativity increases the incidence of PT-LPD 10- to 75-fold over that of EBV seropositive recipients [63]. Other risk factors in PT-LPD include very young recipient age, cytomegalovirus infection or mismatching (donor positive-recipient negative) and aggressive immunosuppression with conventional biologic agents [132]. The increased risk of PT-LPD seen in the very young patient is largely due to their predisposition toward primary infections with EBV and CMV early in the post-transplant course [69].

Half of the Red Cross Hospital patients who developed PT-LPD were EBV positive at the time of transplant. All 6 children with PT-LPD were less than 3 years of age (mean age 20.8 months) at the time of transplant. None of the children at Red Cross had the additional risk factor of concurrent CMV infection.

The development of PT-LPD at RXH was also associated with increased immunosuppression dosages. In four of the patients conversion from cyclosporin to tacrolimus was necessary for control of steroid-resistant rejection. In two patients there was erratic compliance and attendance at follow up clinics, preventing an earlier reduction in immunosuppression.

The average time to development of PT-LPD, diagnosed by tissue biopsy was 8.3 months (range 3-30 months). No cases of PT-LPD in the late transplant period were encountered. It has been suggested that cases seen during the late transplant period are not at risk from the type of immunosuppressive agents employed, but rather by the duration the immunosuppression [63]. The role of EBV in late PT-LPD is also less certain as the incidence of EBV in this group of patients (not confined to children though) is much lower than in the early transplant period. Other factors may be playing a role in these patients.

The most common mode of presentation was adeno-tonsillar enlargement and associated upper airway obstruction (4 out of 6 children). Aggressive disease involving the GIT was seen in two patients.

Of the six cases, only two survived (67% mortality rate). This is comparable to the 50-70% quoted in other series [1,2,52].

In the RXH series chemotherapy was unsuccessful. In two of these patients there was disseminated disease with CNS and extensive GIT involvement. In both cases debulking surgery was performed without complete tumour resection.

6.2 Pathology of cases at Red Cross Children's Hospital series:

In all cases the morphology, immunohistochemistry and clonality were correlated. All cases were B-cell proliferations. Only two of the six patients had oligoclonal lymphoid proliferations according to immunoglobulin heavy-chain gene rearrangement studies. The biopsies from these patients revealed one case of plasma cell hyperplasia and one case of a polymorphic PT-LPD (see Table 7 for details).

EBV RNA was identified in all cases but one (Case 3). The biopsy from this patient was a reactive lymph node with expansion of the interfollicular areas by plasmacytoid cells. Unfortunately the tissue had been frozen before formaldehyde fixation in order to give an intraoperative frozen section opinion. Retrospectively this specimen proved to be problematic in two aspects: (1) the cellular morphology was difficult to interpret and (2) we were not able to detect EBV RNA by the *in situ* method in any of the available archived material. This was despite the fact that this child had serological evidence of primary EBV infection soon after transplant. In view of this finding, it does not therefore seem unreasonable to assume that this patient did in fact have a B-cell proliferation due to EBV.

Of further interest was that the patients with aggressive disease involving the GIT had lymphomas with monoclonal morphology. One patient had a high grade B-cell lymphoma (immunoblastic cytology) and the other had the cytological features of a malignant myeloma. Unfortunately, no serum protein electrophoresis was performed in the latter case in order to identify a paraprotein peak. Multiple myeloma and plasmacytoma-like PT-LPD may be EBV positive or negative [133]. In some cases the PT-LPD may present as an extramedullary

plasmacytoma and later manifest as multiple myeloma [134]. In other cases it may present as an ascites-type tumour [135]. A post-transplant extramedullary plasmacytoma has been reported to present as an aural polyp [136].

The single case seen in the Red Cross series is extremely unusual and possibly unique (no prior reported cases identified on Medline). This patient presented with adeno-tonsillar PT-LPD but soon developed clinical complications due to an aggressive infiltrating malignancy of the small bowel wall, a site commonly seen in African children with Burkitt's lymphoma. The malignant lymphocytes were highly atypical plasma cells, strongly expressing EBNA RNA. This strongly implicated EBV in the aetiology of this unusual case.

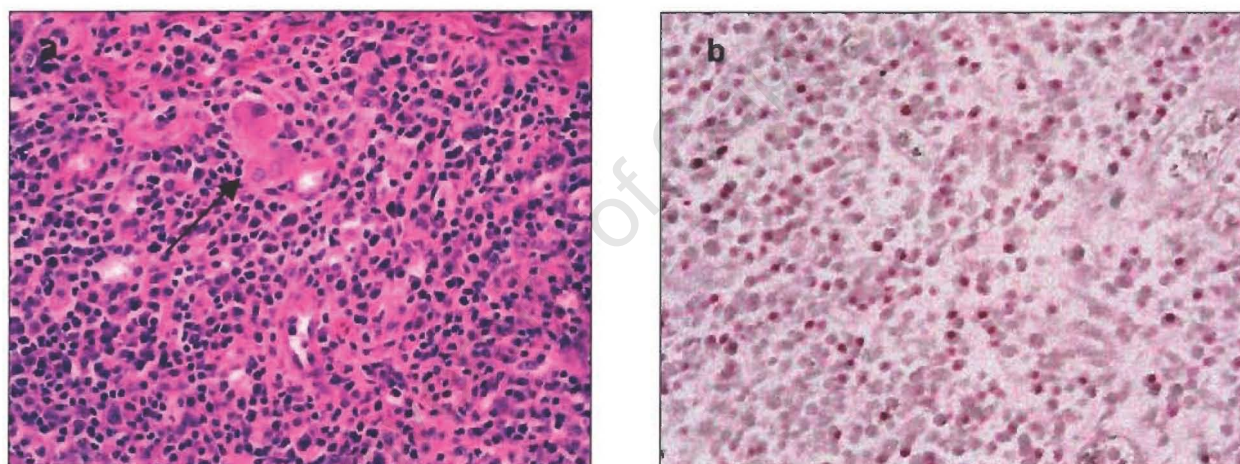


Fig 10a: Malignant myeloma, small bowel. Note occasional atypical (binucleate) plasma cells. Neighbouring ganglia present (arrow). (Case 5; H&E x 400)

Fig 10b: *In-situ* hybridisation PT-LPD, malignant myeloma. Positive EBV nuclear staining. (Case 5; x 400)

Although PT-LPDs may have plasmacytoid differentiation, terminal differentiation to plasma cells secreting immunoglobulins is very rare [137]. After organ transplantation, immunosuppressed patients have a 30% incidence of

monoclonal gammopathy of unknown significance. The M-proteins are usually IgM and are detected 1-25 weeks after transplantation [138]. Whether persistence of M protein predicts development of PT-LPDs is not known.

The role of this virus in the pathogenesis of MM is not well understood. EBV DNA has been demonstrated in some cases of post-transplantation extramedullary plasmacytoma [139, 140] and has only been reported in three cases of post-transplant MM, two demonstrated by Southern blot and one by *in-situ* hybridisation [137, 141].

All cases occurring in the tonsil were classified as polymorphic PT-LPDs according to the classification of *Frizzera et al* [72]. Most were of the atypical polymorphic category, with a large proportion of the B cells having the cytological features of atypical immunoblasts. Distinguishing atypical, infiltrating lymphocytes from reactive follicle-centre centroblasts, was a problem encountered in many cases [JD, personal observation]. The use of reticulin staining and CD-21 immunohistochemistry, to outline the normal follicle centre architecture, was an important investigation in these cases.

6.3 Current guidelines in diagnosis of PT-LPD

In order to unify the many classification systems previously discussed, in 1996 the Society of Haematopathology (SH) convened a meeting to review a collected series of PT-LPD cases [142].

Their system recognized three major categories in this family of disorders:

- a) lymphoid hyperplasias, or 'early' lesions,
- b) polymorphic PTLDs, and
- c) lymphomatous or monomorphic PT-LPDs.

They also included an 'other' category to descriptively include some of the more recently described variants of lymphoid neoplasm observed in transplant patients [142].

A modified, more complete classification system based on this classification follows overleaf:

Table 9 Categories of post-transplant lymphoproliferative disorders [136]

Hyperplastic PT-LPD ('early lesions')
Reactive plasmacytic hyperplasia
Infectious mononucleosis
Atypical lymphoid hyperplasia with architectural retention
Polymorphic PT-LPD
Lymphomatous PT-LPD ('monomorphic PT-LPD')
B cell lymphoma
Diffuse large B-cell lymphoma (immunoblastic, centroblastic, anaplastic)
Burkitt/Burkitt-like lymphoma
MALToma
T-cell lymphoma
Peripheral T-cell lymphoma, unspecified type (usually large cell type)
Anaplastic large-cell lymphoma (T or Null cell)
Hepatosplenic gamma-delta T-cell lymphoma
Other (e.g. T-NK)
Other
Plasmacytoma
Myeloma
T-cell rich/ Hodgkin's disease-like large B-cell lymphoma

Diagnostic line should incorporate histological appearance, cell phenotype, clonal and EB viral status

It is important to realise that early lesions in this classification system often regress following reduction of immunosuppression. However, like infectious mononucleosis itself, these lesions may on occasion act in an aggressive fashion and lead to the death of the patient.

This is an extremely important point. Many of these lesions are rapidly growing proliferations that require some form of intervention for control. The fact that a

particular PT-LPD may prove to be 'benign' in a pathological sense does not imply that it will not progress if left untreated [136].

The term monomorphic was retained and used for PT-LPDs that morphologically resembled non-Hodgkin's lymphomas. The SH group recommended using standard lymphoma nomenclature (i.e., the Revised European American Lymphoma system [85]) to categorize such lesions, while including the term 'PT-LPD' in the diagnosis.

In this classification, the existence of post-transplant T-cell lymphomas were also recognized and placed within the category of monomorphic PT-LPD. Lesions that resembled Hodgkin's disease or B-cell lymphomas with a large number of T cells were placed in the 'other' category, as were post-transplant plasma cell neoplasms such as plasmacytoma or multiple myeloma.

6.4 EBV-negative PT-LPD

It is thought that approximately 10% of PT-LPD cases are EBV negative [136]. Some of these cases could well be spontaneous lymphomas unrelated to the hosts' immunosuppressed state. These cases would be considered to be a PT-LPD according to the latest classification, as any lymphoma that occurs in the post-transplant patient population is by definition considered to be a variant of PT-LPD [142]. This certainly highlights a current limitation in knowledge of this disease. Nevertheless, none of the Red Cross Hospital cases should be regarded as EBV-unrelated.

6.5 Host versus donor origin PT-LPD

It is thought that at least 90% of PT-LPD occurring in solid organ transplant patients arises from recipient cells. The opposite applies in the case of bone marrow transplantation [87]. Donor-derived PT-LPD in organ transplant patients may have a predilection for the allograft [122]. No such cases were seen in the Red Cross Hospital series.

6.6 EBV-associated leiomyosarcomas in PT-LPD

EBV-positive sarcomas in several paediatric transplant patients were first described in 1995 [143]. They have been shown to be leiomyosarcomas by immunohistochemical analysis. Similar tumours have been described in AIDS patients [144]. It has been shown that low levels of the EBV receptor CD21 and lytic EB viral proteins are present in these tumour cells, confirming active intracellular EBV infection [145].

In several cases EBV-associated leiomyosarcomas have arisen in the setting of prior PT-LPD [146]. Precise histological diagnosis of all mass lesions in the transplant patient is therefore necessary to implement appropriate treatment [147].

6.7 Recurrent PT-LPD

Clinical recurrence of PT-LPD has been estimated to occur in approximately 5% of cases [76]. In some cases, the recurrence was morphologically and clonally identical to the original tumour. In several cases, the PT-LPD recurred in a more aggressive form. In one case, as noted above, a recurrent 'PT-LPD' was found on biopsy to actually be post-transplant leiomyosarcoma [146]. For this reason histological confirmation of recurrent masses in these patients is also indicated.

CHAPTER SEVEN

RECOMMENDATIONS FOR PATHOLOGISTS

7.1 General

The diagnosis of PT-LPD is best made on tissue biopsy [136]. As PT-LPD is often multifocal, the surgeon should be encouraged to sample the largest lesion. Needle biopsies should be avoided, as there are often large areas of necrosis. If possible, the tissue should be examined fresh and using sterile techniques. Should the sample be large enough, a frozen section is useful in two regards:

- (1) to confirm the presence of viable tumour, and
- (2) to store for future molecular studies/ *in-situ* studies.

Imprints should be taken from the freshly cut surface so that cytological detail can be best appreciated. The remaining tissue should be sent for routine fixation in buffered formaldehyde as well as a fixative such as B5 (in that order).

7.2 Diagnostic reporting

The pathologist should attempt to classify the lesion according to the latest morphological system (see Table 9). The infiltrating cells should be characterised phenotypically. CD20 is recommended as a B-cell marker [136] as it can be used routinely in paraffin embedded tissue. In addition, this marker is invaluable should rituximab therapy be contemplated.

Clonality studies of immunoglobulin genes are extremely useful to support the diagnosis of PT-LPD. In some cases it may provide the evidence needed to distinguish hyperplastic (early) PT-LPD from more advanced forms of the

disease [136]. It must, however, be remembered that both polymorphic and monomorphic cases of PT-LPD are nearly always monoclonal [45,46] and that clonality *per se* does not predict tumour behaviour in response to treatment [136].

Every attempt should be made to identify EBV within the PT-LPD routinely [136]. *In-situ* hybridisation has the added benefit of demonstrating EBV integration within tumour cells, and is therefore preferred to other molecular methods of detection. It is also a reassuring investigation should CTL therapy directed against virus-infected tumour cells be considered.

The routine molecular analysis of oncogenes and tumour suppressor genes is not well established in the First World [136] and should therefore not be offered routinely in South Africa at this time. In the future, micro-array technology may prove to be extremely useful.

For the time being however, it is certainly worthwhile storing frozen tissue for future retrospective molecular studies.

APPENDIX

- 1. Suggested minimum data set for pathological reporting of PT-LPD specimens**
- 2. Photomicrographs**

University of Cape Town

Pathology Report: PT-LPD

Patient name:

Hospital number:

Pathology number:

Age:

Sex:

Organ transplanted:

Time after transplant: (months)

Site of biopsy:

Macroscopic description:

Microscopic evaluation:

Immunohistochemistry:

B cell lineage:

Other:

Gene rearrangement study:

Polyclonal

Monoclonal

EBV *in situ*: Positive

Negative

Inconclusive/unsatisfactory

CONCLUSION AND S.H. CLASSIFICATION (see below):

SNOMED CODES:

Society of Haematology: Categories of post-transplant lymphoproliferative disorders [1]

Hyperplastic PT-LPD ('early lesions')

- Reactive plasmacytic hyperplasia
- Infectious mononucleosis
- Atypical lymphoid hyperplasia with architectural retention

Polymorphic PT-LPD

Lymphomatous PT-LPD ('monomorphic PT-LPD')

- B cell lymphoma
 - Diffuse large B-cell lymphoma (immunoblastic, centroblastic, anaplastic)
 - Burkitt/Burkitt-like lymphoma
 - MALToma

T-cell lymphoma

- Peripheral T-cell lymphoma, unspecified type (usually large cell type)
- Anaplastic large-cell lymphoma (T or Null cell)
- Hepatosplenic gamma-delta T-cell lymphoma
- Other (e.g. T-NK)

Other

- Plasmacytoma
 - Myeloma
 - T-cell rich/ Hodgkin's disease-like large B-cell lymphoma
-

[1] Nalesnik M.A. The diverse pathology of post-transplant lymphoproliferative disorders: the importance of a standardized approach. *Transplant Infectious Disease* 2001;3(2),88-96

PHOTOMICROGRAPHS

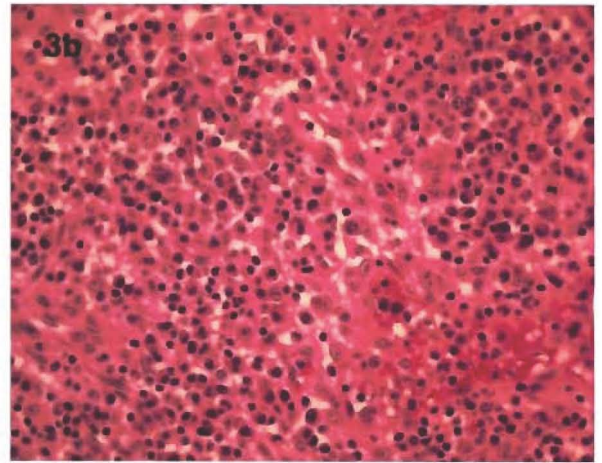
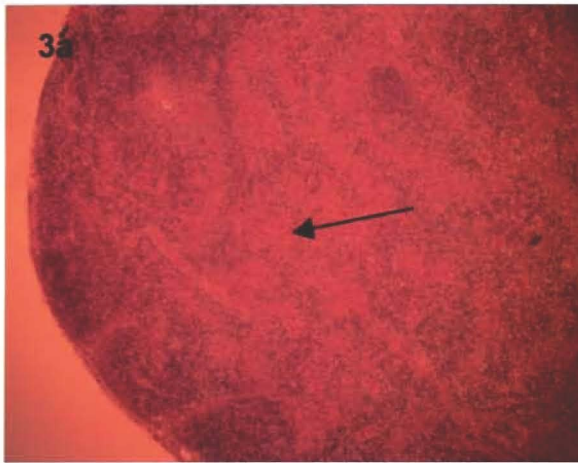


Fig 3a: Plasmacytic hyperplasia. Note the expansion of the sinusoids (arrow).
(Case 3; Frozen section, H&E x 4)

Fig 3b: Sinusoids expanded by numerous plasma cells.
(Case 3; H&E: x 400)

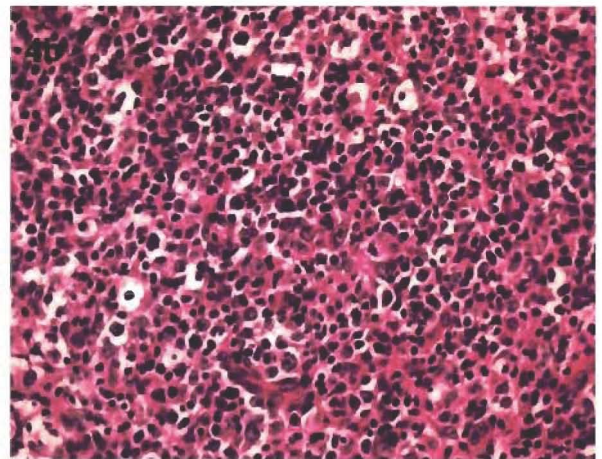
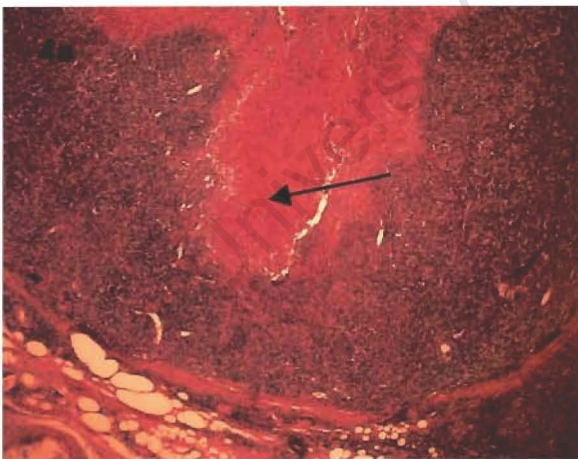


Fig 4a: Polymorphic PT-LPD involving the tonsil. Note the loss of normal architecture and large area of necrosis (arrow). (Case 5; H&E x 4)

Fig 4b: Polymorphic PT-LPD. Note the polymorphic population of lymphocytes, some of which are atypical. (Case 5; H&E x 400)

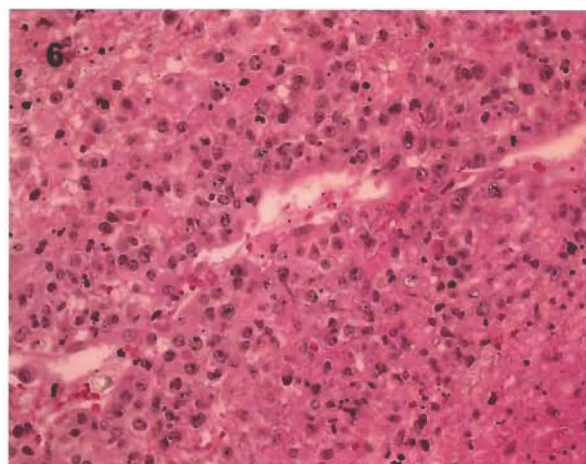
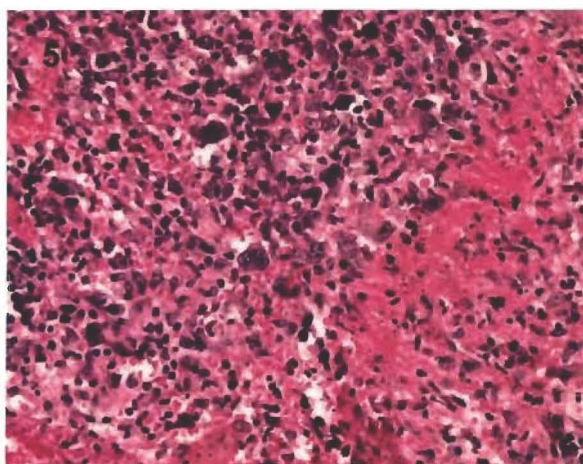


Fig 5: Polymorphic PT-LPD, tonsil. Note the Reed Sternberg-like giant cells and foci of necrosis. (Case 5; H&E x 400)

Fig 6: High-grade B cell lymphoma PT-LPD, small bowel. Note the numerous immunoblasts and high mitotic rate. (Case 4; H&E x 400)



Fig 7: Polymorphic PT-LPD, tonsil. Strong membrane staining for CD20. (Case 6; CD20 immunohistochemistry x 400)

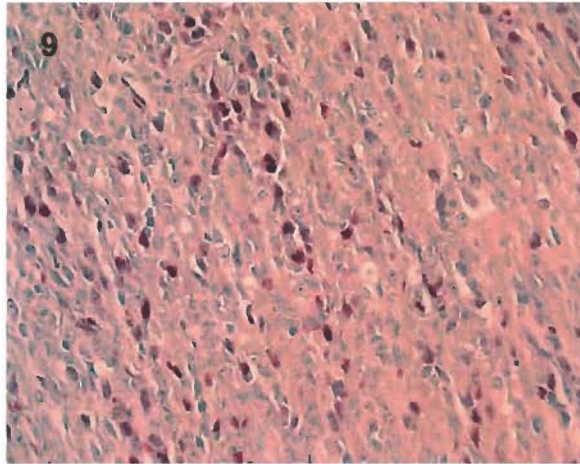


Fig 9: High grade B-cell PT-LPD, small bowel. *In-situ* hybridisation showing strong nuclear EBER staining. (Case 4; x 200)

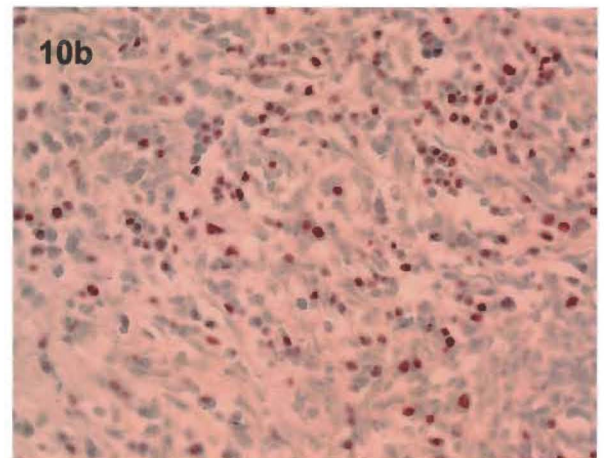
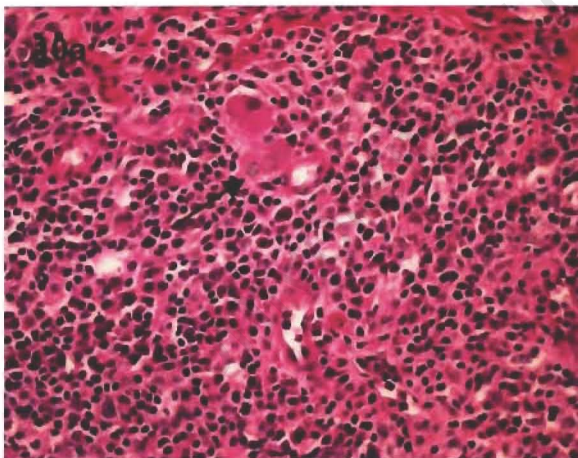


Fig 10a: Malignant myeloma, small bowel. Note occasional atypical (binucleate) plasma cells. Neighbouring ganglia present (arrow). (Case 5; H&E x 400)

Fig 10b: *In-situ* hybridisation PT-LPD, malignant myeloma. Positive EBER nuclear staining. (Case 5; x 200)

REFERENCES

1. Collins MH, Montone KT, Leahey AM, et al. Post-transplant lymphoproliferative disease in children. *Pediatr Transplant*. 2001;5:250-7.
2. Newell KA, Alonso EM, Whittington PF, et al. Posttransplant lymphoproliferative disease in pediatric liver transplantation. Interplay between Epstein-Barr virus infection and immunosuppression. *Transplantation* 1996;62:370-375.
3. Millar AJ, Spearman CW, McCulloch M et al. Liver transplantation in children--the Red Cross War Memorial Children's Hospital experience. *S Afr J Surg* 2000;38:91-7.
4. Rickinson AB, Kieff E. Epstein Barr virus. In: Fields BN, Knipe DM, Howley PM, eds. *Fields Virology*, 3rd ed. Philadelphia: Lippincott-Raven, 1996:2397-446.
5. Hopwood P, Crawford DH. The role of EBV in post-transplant malignancies: a review. *J Clin Pathol* 2000;53:248-254.
6. Pallessen G, Hamilton-Dutoit SJ, Rowe M, et al. Expression of Epstein-Barr virus latent gene products in tumour cells of Hodgkin's disease. *Lancet* 1991;337:320-2.
7. Weiss LM, Movahed LA, Warnke RA, et al. Detection of Epstein-Barr viral genomes in Reed-Sternberg cells of Hodgkin's disease. *N Engl J Med* 1989;320:502-6.
8. Ott G, Ott MM, Feller AC, et al. Prevalence of Epstein-Barr virus DNA in different T-cell lymphoma entities in a European population. *Int J Cancer* 1992;51:562-7.
9. Tanner, J.E. & Alfieri, C. The Epstein-Barr virus and post-transplant lymphoproliferative disease: interplay of immunosuppression, EBV, and the immune system in disease pathogenesis. *Transplant Infectious Disease* 2001;3:60-69.

19. Sharp TV, Raine DA, Gewert DR, et al. Activation of the interferon-inducible (2'-5') oligoadenylate synthetase by the Epstein-Barr virus RNA, EBER-1. *Virology* 1999;257:303-313.
20. Henle G, Henle W. Seroepidemiology of the virus. In: Epstein MA, Achong BG, eds. *The Epstein-Barr virus*. Berlin: Springer-Verlag, 1979,297-320.
21. Sawyer RN, Evans AS, Neiderman JC, et al. Prospective study of a group of Yale University freshman: occurrence of infectious mononucleosis. *J Infect Dis* 1971;123:263-70.
22. Epstein MA, Crawford DH. Gammaherpesviruses: Epstein-Barr virus. In: Mahy BWJ, Collier L, eds. *Microbiology and microbial infections*, vol 1. London: Arnold,1998:351-66.
23. Callan MFC, Steven N, Krausa P, et al. Large clonal expansion of CD8+ve T-cells in acute mononucleosis. *Nature Med* 1996;2:906-10.
24. Lewin N, Aman P, Masucci MG, et al. Characterisation of Epstein-Barr virus carrying B-cell populations in healthy seropositive individuals with regard to density, release of transforming virus and spontaneous outgrowth. *Int J Cancer* 1987;39:472-6.
25. Steven N, Leese AM, Annels NE, et al. Epitope focussing in the primary cytotoxic T-cell response to Epstein-Barr virus and its relationship to T-cell memory. *J Exp Med* 1996;184:1801-6.
26. Cen H, Breining MC, Atchison RW, et al. Epstein-Barr virus transmission via donor organs. *J Virol* 1991;65:976-80.
27. Crawford DH, Edwards JMB, Sweeny P, et al. Studies on long-term T-cell mediated immunity to Epstein-Barr virus in immunosuppressed renal allograft recipients. *Int J Cancer* 1981;28:705-9.
28. Haque T, Thomas JA, Parratt R, et al. A prospective study in heart and lung transplant recipients correlating persistent EBV infection with clinical events. *Transplantation* 1997;64:1028-34.
29. Rea D, Fourcade C, Leblond V, et al. Patterns of Epstein-Barr virus latent and replicative gene expression in Epstein-Barr virus B cell

- lymphoproliferative disorders after organ transplantation. *Transplantation* 1994;58:317–24.
30. Thomas JA, Hotchin NA, Allday MJ, et al. Immunohistology of Epstein-Barr virus associated antigens in B cell disorders from immunocompromised individuals. *Transplantation* 1990;49:944–53.
 31. Hunt BJ, Thomas JA, Burke M. Epstein-Barr virus associated Burkitt's lymphoma in a heart transplant recipient. *Transplantation* 1996;62:869–72.
 32. Oudjens JJ, Jiwa M, van den Brule AJC, et al. Detection of heterogenous Epstein-Barr virus gene expression within individual post-transplant lymphoproliferative disease. *Am J Pathol* 1995;147:923–33.
 33. Montone KT, Hodinka RL, Salhany KE, et al. Identification of Epstein-Barr virus lytic activity in post-transplantation lymphoproliferative disease. *Mod Pathol* 1996;9:621-630.
 34. Hornef MW, Bein G, Fricke L, et al. Coincidence of Epstein-Barr virus reactivation, cytomegalovirus infection, and rejection episodes in renal transplant recipients. *Transplantation* 1995;60:474-480.
 35. Rea D, Fourcade C, Leblond V, et al. Patterns of Epstein-Barr virus latent and replicative gene expression in Epstein-Barr virus B cell lymphoproliferative disorders after organ transplantation. *Transplantation* 1994;58:317-324.
 36. Perera SM, Thomas JA, Burke M, et al. Analysis of the T-cell microenvironment in Epstein-Barr virus-related posttransplantation B-lymphoproliferative disease. *J Pathol* 1998;184:177–84.
 37. Veronese ML, Veronesi A, D'Anrea E, et al. Lymphoproliferative disease in human peripheral blood mononuclear cell-injected SCID mice. T lymphocyte requirement of B-cell tumour generation. *J Exp Med* 1992; 196:1763–7.
 38. Johannessen I, Crawford DH. In vivo models for Epstein-Barr virus associated B-cell lymphoproliferative disease. *Rev Med Virol* 1999;9:263-77.

39. Izumi K & Kieff E. The Epstein-Barr virus oncogene product latent membrane protein 1 engages the tumor necrosis factor associated death domain protein to mediate B lymphocyte growth transformation and NFkB activation. *Proc Natl Acad Sci USA* 1997;94:12592-12597.
40. Kieser A, Kilger E, Gires O, et al. Epstein-Barr virus latent membrane protein-1 triggers AP-1 activity via the c-Jun N-terminal kinase cascade. *EMBO J* 1997;16:6478-6485.
41. Faro A. Interferon-alpha and its effects on post-transplant lymphoproliferative disorders. *Semin Immunopathol* 1998;20:425-436.
42. Wajant H, Grell M, Scheurich P. TNF receptor associated factors in cytokine signaling. *Growth Factor Rev* 1999;10:15-26.
43. Liebowitz D. Epstein-Barr virus and a cellular signaling pathway in lymphomas from immunosuppressed patients. *New Engl J Med* 1998;338:1413-1421.
44. Nalesnik MA. Clinical and pathological features of posttransplant lymphoproliferative disorders (PTLD). *Semin Immunopathol* 1998;29:325-42.
45. Knowles DM, Cesarman E, Chadburn A, et al. Correlative morphologic and molecular genetic analysis demonstrates three distinct categories of post transplantation lymphoproliferative disorders. *Blood* 1995;85:552-565.
46. Chadburn A, Cesarman E, Knowles D. Molecular pathology of Posttransplant lymphoproliferative Disorders. *Seminars in Diagnostic Pathology* 1997;14:15-26.
47. Wakasugi H, Rimsky L, Mahe Y, et al. Epstein-Barr virus containing B-cell line produces an interleukin 1 that it uses as a growth factor. *Proc Natl Acad Sci USA* 1987;84:804-8.
48. Tosato G, Jones K, Breinig MK, et al. Interleukin 6 production in posttransplant lymphoproliferative disease. *J Clin Invest* 1993;91:2806-14.

49. Murray JE, Wilson RE, Tilney NL, et al. Five years experience in renal transplantation with immunosuppressive drugs: survival, function, complications and the role of lymphocyte depletion by thoracic duct fistula. *Ann Surg* 1968;168:416-435.
50. Nalesnik MA. Clinicopathologic features of posttransplant lymphoproliferative disorders. *Ann Transpl* 1997;2:33-40.
51. Reyes J, Jain A, Mazariegos G, et al. Long-term results after conversion from cyclosporine to tacrolimus in pediatric liver transplantation for acute and chronic rejection. *Transplantation* 2000;69:2573-2580.
52. Cox KL, Lawrence-Miyasaki LS, Garcia-Kennedy R, et al. An increased incidence of Epstein-Barr virus infection and lymphoproliferative disorder in young children on FK506 after liver transplantation. *Transplantation* 1995;59:524-529.
53. Lattyak B, Rosenthal P, Mudge C, et al. Posttransplant lymphoproliferative disorder presenting in the head and neck. *Laryngoscope* 1998;108:1195-1198.
54. Bernstein D, Baum C, Berry G, et al. Neoplastic Disorders After Pediatric Heart Transplantation. *Circulation* 1993;88:230-237.
55. Harwood JS, Gould FK, McMaster A, et al. Significance of Epstein-Barr virus status and post-transplant lymphoproliferative disease in pediatric thoracic transplantation. *Pediatr Transpl* 1999;3:100-103.
56. Boyle GJ, Michaels MG, Webber SA, et al. Posttransplantation lymphoproliferative disorders in pediatric thoracic organ recipients. *J Pediatr* 1997;131:309-313.
57. Wingen AM, Wiesel M, Mohring K, et al. Malignancies in children with renal replacement therapy. *Transplant Proc* 1994;26:5-6.
58. Srivastava T, Zwick D, Rothberg PG, Warady BA. Posttransplant lymphoproliferative disorder in pediatric renal transplantation. *Pediatr Nephrol* 1999;13:748-754.
59. Hebert D, Sullivan EK. Malignancy and posttransplant lymphoproliferative disorder (PTLD) in pediatric renal transplant

- recipients: a report of the North American Pediatric Renal Transplant Cooperative Study (NAPRTCS). *Pediatr Transpl* 1998;2(Suppl.1):57(Abstract).
60. Shapiro R, Scantlebury VP, Jordan ML, et al. Pediatric renal transplantation under tacrolimus-based immunosuppression. *Transplantation* 1999;67:299-303.
61. Bhatia S, Ramsay NKC, Steinbuch M, et al. Malignant neoplasms following bone marrow transplantation. *Blood* 1996;87:3633-3639.
62. Smith CA, Ng CY, Heslop HE, et al. Production of genetically modified Epstein-Barr virus-specific cytotoxic T cells for adoptive transfer to patients at high risk of EBV-associated lymphoproliferative disease. *J Hematother* 1995;4:73-79.
63. Cockfield, S.M. Identifying the patient at risk for post-transplant lymphoproliferative disorder. *Transplant Infectious Disease* 2001;3:70-78.
64. Ho M, Jaffe R, Miller G, et al. The frequency of Epstein-Barr virus infection and associated lymphoproliferative syndrome after transplantation and its manifestation in children. *Transplantation* 1988;45:719-727.
65. Breinig MK, Zitelli B, Starzl TE, Ho M. Epstein-Barr virus, Cytomegalovirus, and other viral infections in children after liver transplantation. *J Infect Dis* 1987;156:273-279.
66. Basgoz N, Preiksaitis JK. Post-Transplant Lymphoproliferative Disorder. *Infect Dis Clin North Am* 1995;9:901-923.
67. Wingen A-M, Wiesel M, Mohring K, et al. Malignancies in children with renal replacement therapy. *Transplant Proc* 1994;26:5-6.
68. Walker RC, Marshall WF, Strickler JG, et al. Pretransplantation assessment of the risk of lymphoproliferative disorder. *Clin Infect Dis* 1995;20:1346-1353.

69. Manez R, Breinig MC, Linden P, et al. Posttransplant lymphoproliferative disease in primary Epstein-Barr virus infection after liver transplantation: the role of CMV disease. *J Infect Dis* 1997;176:1462-1467.
70. Aalto SM, Linnavuori K, Peltola H, et al. Immunoreactivation of Epstein-Barr virus due to cytomegalovirus primary infection. *J Med Virol* 1998;56:186-91.
71. Hezode C, Duvoux C, Germanidis G, et al. Role of hepatitis C virus in lymphoproliferative disorders after liver transplantation. *Hepatology* 1999;30:775-778.
72. Frizzera G, Hanto OW, Gajl-Peczalska KJ, et al. Polymorphic diffuse B-cell hyperplasias and lymphomas in renal transplant recipients. *Cancer Res* 1981;41:4262-4279.
73. Nalesnik MA, Jaffe R, Starzl TE, et al. The pathology of post transplant lymphoproliferative disorders occurring in the setting of cyclosporine A-prednisone immunosuppression. *Am J Pathol* 1988;133:173-192.
74. Locker J, Nalesnik M. Molecular genetic analysis of lymphoid tumors arising after organ transplantation. *Am J Pathol* 1989;135:977-987.
75. Shapiro RS, McClain K, Frizzera G, et al. Epstein-Barr virus associated B cell lymphoproliferative disorders following bone marrow transplantation. *Blood* 1988;71:1234-1243.
76. Wu TT, Swerdlow SH, Locker J, et al. Recurrent Epstein-Barr virus associated lesions in organ transplant recipients. *Hum Pathol* 1996;27:157-164.
77. Swerdlow SH. Classification of posttransplant lymphoproliferative disorders: from the past to the present. *Seminars in Diagnostic Pathology* 1997;14:2-7.
78. Chadburn A, Frizzera G, Chen I, et al. Clinicopathologic analysis of 28 post-transplantation lymphoproliferative disorders (PT-LPDs). *Lab Invest* 1994;70:104A.

79. Frizzera G. Atypical lymphoproliferative disorders, in Knowles DM (ed): Neoplastic Hematopathology. Baltimore, MD, Williams & Wilkins, 1992, pp 459-495.
80. Osterhage DA, Steele PE, Witte D, et al. T cells in posttransplant lymphoproliferative disorders (PTLD): An immunophenotypic and genotypic investigation. *Modern Pathol* 1995;8:107A.
81. Hanto DW, Gajl-Peczalska KJ, Frizzera G, et al. Epstein-Barr virus (EBV) induced polyclonal and monoclonal B-cell lymphoproliferative diseases occurring after renal transplantation: Clinical, pathologic, and virologic findings and implications for therapy. *Ann Surg* 1983;198:356-369.
82. Ferry JA, Jacobson JO, Conti D, et al. Lymphoproliferative disorders and hematologic malignancies following organ transplantation. *Modern Pathol* 1989;2:583-592.
83. Cleary ML, Warnke R, Sklar J. Monoclonality of lymphoproliferative lesions in cardiac-transplant recipients: Clonal analysis based on immunoglobulin-gene rearrangements. *N Engl J Med* 1984;310:477-482.
84. Kaplan MA, Ferry JA, Harris NL, et al. Clonal analysis of posttransplant lymphoproliferative disorders, using both episomal Epstein-Barr virus and immunoglobulin genes as markers. *Am J Clin Pathol* 1994;10:590-596.
85. Harris NE, Jaffe ES, Stein H, et al. A Revised European-American Classification of lymphoid neoplasms: A proposal from the international lymphoma study group. *Blood* 1994;84:1361-1392.
86. Harris NL, Jaffe ES, Diebold J, et al. World Health Organization Classification of Neoplastic Diseases of the Hematopoietic and Lymphoid Tissues: Report of the Clinical Advisory Committee Meeting-Airlie House, Virginia, November 1997. *J Clin Oncol* 1999;17:3835-3849.
87. Weissmann DJ, Ferry JA, Harris NL, et al. Posttransplantation lymphoproliferative disorders in solid organ recipients are predominantly aggressive tumors of host origin. *Am J Clin Pathol* 1995;103:748-755.

88. Cleary ML, Nalesnik MA, Shearer WT, et al: Clonal analysis of transplant-associated lymphoproliferations based on the structure of the genomic termini of the Epstein-Barr virus. *Blood* 1988;72:349-352.
89. Penn I. The problem of cancer in organ transplant recipients: an overview. *Transplant Sci* 1994;4:23-32.
90. Nalesnik MA, Deetris AJ, Fung JJ, et al. Lymphoproliferative diseases arising under immunosuppression with FK506: initial observations in a large transplant population. *Transplant Proc* 1991;23:1108-10.
91. Penn I, Porat G. Central nervous system lymphomas in organ allograft recipients. *Transplantation* 1995;59:240-4.
92. Garnier JL, Stevenson G, Blanc-Brunat N, et al. Treatment of post-transplant lymphomas with anti-B-cell monoclonal antibodies. *Recent Results Cancer Res* 2002;159:113-22.
93. Cohen JI. Epstein-Barr virus lymphoproliferative disease associated with acquired immunodeficiency. *Medicine* 1991;70:137-160.
94. Benkerrou M, Durandy A, Fischer A. Therapy for transplant related lymphoproliferative disease. *Hematol Oncol Clin North Am* 1993;7:467-475.
95. Lones MA, Lopez-Terrada D, Shintaku P, et al. Posttransplant lymphoproliferative disorder in pediatric bone marrow transplant recipients: disseminated disease of donor origin demonstrated by fluorescence in situ hybridization. *Arch Pathol Lab Med* 1998;122:708-714.
96. Starzl TE, Nalesnik MA, Porter KA, et al. Reversibility of lymphomas and lymphoproliferative lesions developing under cyclosporin-steroid therapy. *Lancet* 1984;1:583-587.
97. Chadburn A, Cesarman E, Liu YF, et al. Molecular genetic analysis demonstrates that multiple post transplantation lymphoproliferative disorders occurring in one anatomic site in a single patient represent distinct primary lymphoid neoplasms. *Cancer* 1995;75:2747-2756.

98. Green M, Michaels MG, Rowe D, Reyes J. The management of Epstein-Barr virus associated post-transplant lymphoproliferative disorders in pediatric solid-organ transplant recipients. *Pediatric Transplantation* 1999;3:271-281.
99. Cacciarelli TV, Green M, Jaffe R, et al. Management of post-transplant lymphoproliferative disease in pediatric liver transplant recipients receiving primary tacrolimus (FK 506) therapy. *Transplantation* 1998;66:1047-1052.
100. Webber SA, Rowe D, Boyle GJ, et al. Natural history of Epstein-Barr virus load in pediatric thoracic transplant recipients with post-transplant lymphoproliferative disorders and other primary EBV infections. Program and Abstracts of the annual meeting of the American Society of Transplantation 1999. Chicago: Lippincott, Williams & Wilkins. *Transplantation* 1999; 67 (Suppl.): S215.
101. Green M, Cacciarelli TV, Mazareigos GV, et al. Serial measurement of Epstein-Barr viral load in peripheral blood in pediatric liver transplant recipients during treatment for posttransplant lymphoproliferative disease. *Transplantation* 1998;66:1641-1644.
102. Hanto DW, Frizzera G, Gajl-Peczalska KJ, et al. Acyclovir therapy of Epstein-Barr Virus-induced posttransplant lymphoproliferative diseases. *Transplant Proc* 1985;17:89-92.
103. Lin JC, Smith MC, Pagano JS. Prolonged inhibitory effect of 9-(1,3-Dihydroxy-2-Propoxymethyl) Guanine against replication of Epstein-Barr Virus. *J Virol* 1984;50:50-55.
104. Davis CL. The antiviral prophylaxis of post-transplant lymphoproliferative disorder. *Semin Immunopathol* 1998;20:437-453.
105. Randhawa PS, Jaffe R, Demetri AJ, et al. Expression of Epstein-Barr Virus-encoded small RNA (by the EBER-1 probe) in liver specimens from transplant recipients with posttransplant lymphoproliferative disorders. *N Engl J Med* 1992;327:1710-1714.

106. Shapiro RS, Chauvenet A, McGuire W, et al. Treatment of B-cell lymphoproliferative disorders with interferon alpha and intravenous gamma globulin. *N Engl J Med* 1988;318:1334.
107. Ippoliti G, Martinelli L, Loernzutti F, et al. Posttransplant lymphoproliferative disease after heart transplantation on sandimmune therapy: treatment with interferon-alpha 2b and intravenous immunoglobulin. *Transplant Proc* 1995;26:2660-2661.
108. Faro A, Kurland G, Michaels MG, et al. Interferon alpha affects the immune response in post-transplant lymphoproliferative Disorder. *Am J Respir Crit Care Med* 1996;153:1442-1447.
109. Taguchi Y, Purtillo Dt, Okano M. The effect of intravenous immunoglobulin and interferon-alpha on Epstein-Barr Virus-induced lymphoproliferative disorder in a liver transplant recipient. *Transplantation* 1994;57:1813-1815.
110. Demario M, Liebowitz D. Lymphomas in the immunocompromised patient. *Seminars in Oncology* 1998;25(4):492-502.
111. Liebowitz D, Anastasi J, Hagos F, et al. Post-Transplant Lymphoproliferative Disorders (PTLD): Clinicopathological characterization and response to immunomodulatory therapy with interferon alpha. *Ann Oncol* 1996;7(28).
112. Fisher A, Blanche S, Le Bidois J, et al. Anti-B-cell monoclonal antibodies in the treatment of severe B-cell lymphoproliferative syndrome following bone marrow and organ transplantation. *N Engl J Med* 1991;324:1451-1456.
113. Lazarovits AI, Tibbles LA, Grant DR, et al. Anti-B cell antibodies for the treatment of monoclonal Epstein-Barr virus induced lymphoproliferative syndrome after multivisceral transplantation. *Clin Invest Med* 1994;176:621-625.
114. Benkerrou M, Durandy A, Fischer A. Therapy for transplant-related lymphoproliferative diseases. *Hematol Oncol Clin North Am* 1993;7:467-475.

115. Mclaughlin P, Grillo-Lopez AJ, Link BK, et al. Rituximab chimeric anti-CD20 monoclonal antibody therapy for relapsed indolent lymphoma: half of patients respond to a four dose treatment program. *J Clin Oncol* 1998;16:2825-2833.
116. Verschuuren EA, Stevens SJ, van Imhoff GW, et al. Treatment of posttransplant lymphoproliferative disease with Rituximab: the remission, the relapse, and the complication. *Transplantation* 2002;73:100-4.
117. Milpied N, Vasseur B, Parquet N, et al. Humanized anti-CD20 monoclonal antibody (Rituximab) in post transplant B-lymphoproliferative disorder: a retrospective analysis on 32 patients. *Ann Oncol* 2000;11 Suppl 1:113-6.
118. Fischer A, Blanche S, Le Bidois, et al. Anti-B cell monoclonal antibodies in the treatment of severe B-cell lymphoproliferative syndrome following bone marrow and organ transplantation. *N Engl J Med* 1991;324:1451-1456.
119. Durandy A. Anti-B cell and anti-cytokine therapy for the treatment of post-transplant lymphoproliferative disorder: past, present, and future. *Transpl Infect Dis* 2001;3:104-7.
120. Rooney CM, Smith CA, Ng CYC, et al. Use of genetically modified virus-specific T lymphocytes to control Epstein-Barr virus related lymphoproliferation. *Lancet* 1995;345:9-13.
121. Papadopoulos EB, Ladanyi M, Emanuel D, et al. Infusions of donor leukocytes to treat Epstein-Barr virus associated lymphoproliferative disorders after allogeneic bone marrow transplantation. *N Engl J Med* 1994;330:1185-1191.
122. Strazzabosco M, Corneo B, Iemmolo RM, et al. Epstein-Barr virus-associated post-transplant lymphoproliferative disease of donor origin in liver transplant recipients. *J Hepatol* 1997;26:926-934.
123. Chadburn A, Suci-Foca N, Cesarman E, et al. Post-Transplantation lymphoproliferative disorders arising in solid organ

- transplant recipients are usually of recipient origin. *Am J Pathol* 1995;147:1862-1870.
124. Weissman DJ, Ferry JA, Harris NL, et al. Posttransplantation lymphoproliferative disorders in solid organ recipients are predominantly aggressive tumors of host origin. *Am J Clin Pathol* 1995;103:748-755.
125. Emanuel DJ, Lucas KG, Mallory GB, et al. Treatment of posttransplant lymphoproliferative disease in the central nervous system of a lung transplant recipient using allogeneic leukocytes. *Transplantation* 1997;63:1691-1694.
126. Haque T, Crawford DH. Role of adoptive immunotherapy in the prevention and treatment of lymphoproliferative disease following transplantation. *Br J Haematol* 1999;106:309-16.
127. Nalesnik MA, Rao AS, Furukawa H, et al. Autologous lymphokine-activated killer cell therapy of Epstein-Barr virus positive and negative lymphoproliferative disorders arising in organ transplant recipients. *Transplantation* 1997;63:1200-205.
128. Swinnen LJ, Mullen GM, Carr TJ, et al. Aggressive treatment for postcardiac transplant lymphoproliferation. *Blood* 1995;86:3333-340.
129. Paya CV, Fung JJ, Nalesnik MA, et al. Epstein-Barr virus-induced posttransplant lymphoproliferative disorders. ASTS/ASTP EBV-PTLD Task Force and The Mayo Clinic Organized International Consensus Development Meeting. *Transplantation* 1999;68:1517-25.
130. Essop MF, Blakolmer K, Close PM, Manuel YE, Cornelius S. Analysis of low and high grade B-cell lymphoma subtypes using semi-nested PCR and two primer sets. *Eur J Haematol* 1997;59:136-141
131. Hamilton-Dutoit SJ, Pallesen G. Detection of Epstein-Barr Virus small RNAs in routine paraffin sections using non-isotopic RNA/RNA in-situ hybridization. *Histopathology* 1994;25:101-111.
132. Shapiro R, Nalesnik MA, McCauley J, et al. Posttransplant lymphoproliferative disorders in adult and pediatric renal transplant

- patients receiving tacrolimus-based immunosuppression. *Transplantation* 1999;68:1851-1854.
133. Chucrallah AE, Crow MK, Rice LE, Rajagopalan S, Hudnall SD. Multiple myeloma after cardiac transplantation: an unusual form of post-transplant lymphoproliferative disorder. *Hum Pathol* 1994;25:541-545.
134. Leigh BR, Larkin EC, Doggett RL. Solitary extramedullary plasmacytoma five years after successful cardiac transplantation: case report and review of the literature. *Am J Clin Oncol* 1997;20:467-470.
135. Chan BK, Ranheim E, Jeffrey RbJr. Disseminated peritoneal plasmacytoma following cardiac transplantation. *Abdom Imaging* 1999;24:508-510.
136. Nalesnik M.A. The diverse pathology of post-transplant lymphoproliferative disorders: the importance of a standardized approach. *Transplant Infectious Disease* 2001;3:88-96.
137. Ancin I, Sarra J, Peris J, et al. Demonstration of Epstein-Barr virus in a case of multiple myeloma after renal transplantation. *Haematologica*. 2000 Jul;85:773-4.
138. Peest D, Schaper B, Nashan B, et al. High incidence of monoclonal immunoglobulin in patients after liver or heart transplantation. *Transplantation* 1988;46:389-93.
139. Ho M, Miller G, Atchison RW, et al. Epstein-Barr virus infections and DNA hybridization studies in posttransplantation lymphoma and lymphoproliferative lesions: the role of primary infection. *J Infect Dis* 1985;152:876-86.
140. Dunphy CH, Galambos C, Polski JM, et al. Extranodal posttransplant plasmacytic hyperplasia with subsequent posttransplant plasmacytic malignancy: six-year interval case report and review of the literature. *Arch Pathol Lab Med* 2002;126:351-6.
141. Joseph G, Barker RL, Yuan B, et al. Post-transplantation plasma cell dyscrasias. *Cancer* 1994;74:1959-64.

142. Harris NL, Ferry JA, Swerdlow SH. Post-transplant lymphoproliferative disorders (PTLD): Summary of Society for Hematopathology Workshop. *Semin Diagnostic Pathol* 1997;14:8-14.
143. Lee ES, Locker J, Nalesnik M, Reyes J, et al. The association of Epstein-Barr virus with smooth-muscle tumors occurring after organ transplantation [see comments]. *N Engl J Med* 1995;332:19-25.
144. McClain KL, Leach CT, Jenson HB, et al. Association of Epstein-Barr virus with leiomyosarcomas in children with AIDS. *N Engl J Med* 1995;332:12-18.
145. Jenson HB, Montalvo EA, McClain KL, et al. Characterization of natural Epstein-Barr virus infection and replication in smooth muscle cells from a leiomyosarcoma. *J Med Virol* 1999;57:36-46.
146. Kingma DW, Shad A, Tsokos M, et al. Epstein-Barr virus (EBV)-associated smooth-muscle tumor arising in a post-transplant patient treated successfully for two PT-EBV-associated large-cell lymphomas. *Am J Surg Pathol* 1996;20:1511-1519.
147. Brichard B, Smets F, Sokal E, Clapuyt, P, et al. Unusual evolution of an Epstein-Barr virus-associated leiomyosarcoma occurring after liver transplantation. *Pediatric Transplantation* 2001;5:365-369.