

# The clinical and pathological features of hereditary mixed polyposis syndrome: Report on a South African family

S. B. IBIROGBA, M.B. B.S., F.C.S. (S.A.)

U. ALGAR, M.SC. (NURSING)

P. A. GOLDBERG, M.B. CH.B., F.C.S. (S.A.), M.MED. (SURG.)

Colorectal Unit, Department of Surgery, Groote Schuur Hospital and University of Cape Town

M. DUFFIELD, M.B. CH.B., L.R.C.P., M.R.C. (PATH.), F.S. (EDIN/GLASGOW), M.MED. (ANAT. PATH.)

Division of Anatomical Pathology, Groote Schuur Hospital and University of Cape Town

A. VORSTER, M.SC.

R. RAMESAR, PH.D.

Division of Human Genetics, Groote Schuur Hospital and University of Cape Town

## Summary

**Background.** Hereditary mixed polyposis syndrome is characterised by multiple large-bowel polyps of differing histological types including a mixture of atypical juvenile polyps, hyperplastic polyps and adenomas. Affected individuals are thought to have an increased risk of malignancy, possibly via the juvenile polyposis pathway.

**Methods.** A 51-year-old woman (with a history of a colectomy for polyps during childhood) presented with rectal bleeding. Endoscopy demonstrated small rectal polyps which were hyperplastic on histology. A family tree was drawn up and the three children of the proband underwent flexible sigmoidoscopy.

**Results.** Endoscopic surveillance of the three children revealed one who had a similar phenotype to the mother. This child underwent colectomy and ileorectal anastomosis. The pathological specimen revealed more than 70 polyps, with a combination of juvenile retention, hyperplastic, adenomatous and inflammatory polyps. A second child had multiple small hyperplastic polyps, and the third had a normal colon. Although the gene locus for the disorder has been mapped, neither the gene nor the disease-causing mutation has been defined.

**Conclusion.** A rare inherited polyposis syndrome has been identified in a South African family. Where clinical suspicion of a possible inherited condition exists, investigating at-risk first-degree relatives confirms the inherited nature of the disease. It is possible to use genetic haplotyping (i.e. with a range of markers in the area of the gene) to provide statistical risk to immediate relatives and therefore those at highest risk.

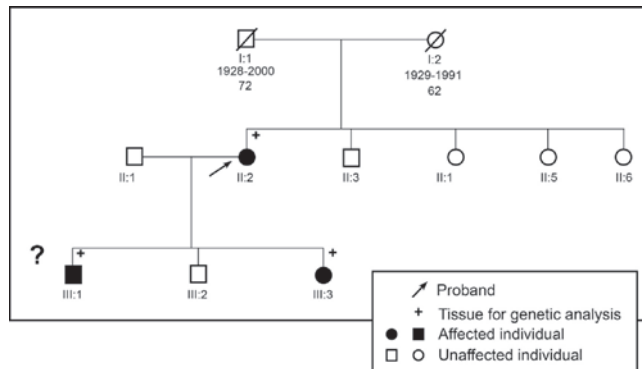
Hereditary mixed polyposis syndrome (HMPS) is characterised by multiple large-bowel polyps. The polyps are unusual because individual polyps contain a mixture of juvenile retention, hyperplastic and adenomatous features.<sup>1</sup> This condition has been reported internationally in three different parts of the world (UK, Israel and Singapore) and, although the causative genetic defect has not been defined, the disorder has been mapped to chromosomes 15 and 10, reflecting genetic heterogeneity. Affected individuals are thought to have an increased risk of malignancy, possibly via the juvenile polyposis pathway.<sup>1,2</sup>

We report the clinical and pathological features of a South African family with HMPS affecting two individuals in two generations.

## Family case report

A 51-year-old woman (the proband) presented in 2002 with rectal bleeding. She had had a colectomy and ileorectal anastomosis in 1966 (at age 11 years) for severe anaemia due to multiple colonic polyps. She was told that she had familial adenomatous polyposis (FAP), counselled and entered into a follow-up programme. However, she was lost to follow-up for many years. Flexible sigmoidoscopy in 2002 demonstrated multiple small rectal polyps which were hyperplastic on histological examination. A family pedigree was drawn up (Fig. 1) and it was suggested that her children should be screened. The family decided to delay clinical investigation.

In 2005, her 17-year-old daughter presented with rectal bleeding and iron deficiency anaemia. Colonoscopy revealed multiple colonic polyps. Histological examination of a polyp demonstrated a low-grade dysplastic adenoma with some hyperplastic elements. A diagnosis of FAP was made, based on the family history and the presence of adenomas at a young age. A total colectomy and ileorectal anastomosis was



**Fig. 1. Pedigree of the HMPS family in South Africa. There are 2 affected individuals in 2 generations.**

performed. Histological examination of the colectomy specimen, however, demonstrated mixed juvenile and adenomatous polyps unlike that expected for FAP.

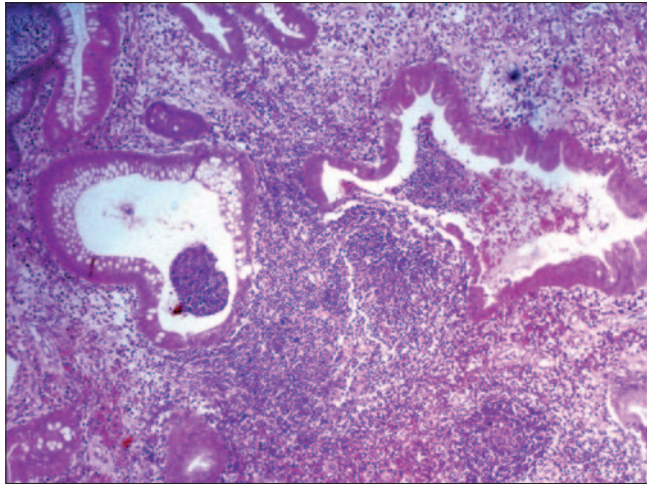
The pathological report from the proband's colectomy specimen of 1966 was obtained from the institution where she had been operated on. The report documented a large number of polyps with both adenomatous and juvenile features. The histological results had been reviewed by Dr Morson at St Mark's Hospital, London. No clear diagnosis was made, and the condition was thought to be either juvenile polyposis or FAP. We were able to find the original 1966 paraffin blocks. Recut sections of these blocks confirmed features of mixed juvenile and adenomatous polyps (Fig. 2) similar to those seen in the specimen from the daughter.

Both sons have undergone colonoscopy. One had a normal colon and the other displayed multiple hyperplastic polyps. Histological review of the colectomy specimen (Fig. 3) from the 17-year-old showed approximately 70 sessile and pedunculated polyps ranging in size from 3 to 25 mm in diameter. There were features of juvenile retention, hyperplastic and adenomatous polyps with no more than low-grade dysplasia in the latter (Fig. 4). Intermediate forms of the polyp types appeared to be present, although juvenile retention polyps were most numerous.

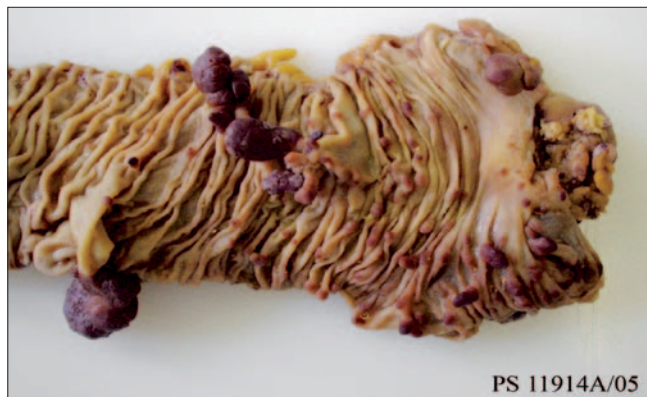The two causative genes found in families internationally have yet to be identified in this family. Preliminary investigations by allele segregation and recombination data suggest that the gene in the South African family is excluded from the chromosome 10 locus; it cannot be excluded from the chromosome 15 locus.

## Discussion

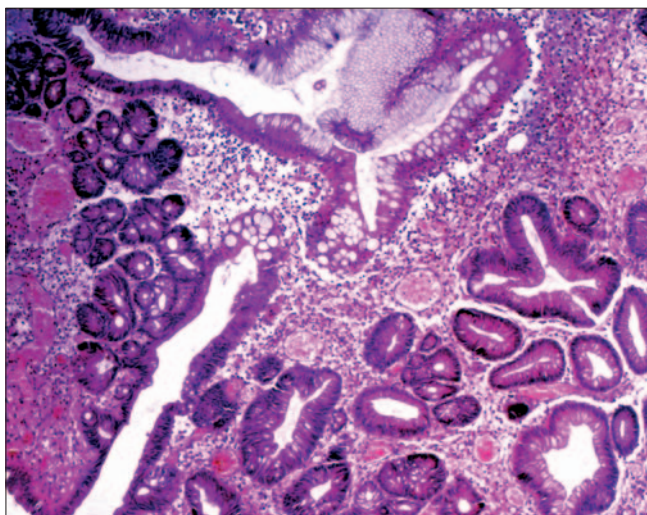
We have documented two family members over two generations who developed multiple colonic polyps and presented with rectal bleeding and anaemia. The condition appears to be inherited, yet the polyps are not the usual adenomas seen in FAP, nor are they characteristic of juvenile polyposis; they appear to be of a mixed type. In 1989, Murday and Slack<sup>2</sup> described a family with mixed large-bowel polyps. In 1997, Whitelaw *et al.*<sup>1</sup> identified the autosomal dominant nature of the mixed polyposis syndrome. A single large family in the UK and one in Israel with a similar condition have undergone linkage analysis that suggests localisation of a mutation to chromosome 15q 13-14.<sup>3,5</sup> Investigation of another two families in Singapore suggests genetic heterogeneity,<sup>4,6</sup> and their mutation was localised to chromosome 10q23.



**Fig. 2. Overview of a polyp in the mother (Proband, ii-2 on pedigree) which shows a juvenile retention polyp with hyperplastic features (haematoxylin and eosin stain).**



**Fig. 3. Colectomy specimen from the daughter. There are numerous sessile and pedunculated polyps of varying size.**



**Fig. 4. An overview of a polyp in the daughter (iii-3 on pedigree) which shows a zone typical of a juvenile retention polyp with transition into an adenomatous polyp (haematoxylin and eosin stain).**

Expression of malignancy has been found in six members of the two families from Singapore. The syndrome may therefore be associated with an increased risk of cancer.<sup>6</sup> The 17-year-old daughter underwent a total colectomy and ileorectal

anastomosis because she was thought to have FAP, and the operation was performed to reduce the risk of colonic malignancy. Although the final diagnosis was not FAP, and the risk of malignancy is not as clearly defined for mixed polyposis syndromes as for FAP, the operation was still appropriate because the large number of colonic polyps resulted in bleeding and iron deficiency anaemia. Endoscopic control of these polyps would not have been possible.

## Conclusion

Mixed polyposis syndrome is a rare inherited disorder that has been identified in a South African family. Investigating at-risk first-degree relatives confirms the inherited nature of the disease. It is worth while to put effort into identifying the causative genetic defect to: (i) provide accurate risk assessment in those individuals at highest risk, and release from follow-up those individuals who do not carry the genetic defect; and (ii) identify additional/new components of carcinogenic

pathways in order to more fully understand the endogenous factors involved in carcinogenesis, and possibly to identify novel modes of treatment and intervention.

## REFERENCES

1. Whitelaw SC, Murday VA, Tomlinson IPM, *et al.* Clinical and molecular features of the hereditary mixed polyposis syndrome. *Gastroenterology* 1997; 112: 327-334.
2. Murday V, Slack J. Inherited disorders associated with colorectal cancer. *Cancer Surv* 1989; 8: 139-157.
3. Jaeger EEM, Woodford-Richins KL, Lockett M, *et al.* Ancestry Ashkenazi haplotype at the HMPS/CRAC I Locus on 15q 13-q 14 is associated with hereditary mixed polyposis syndrome. *Am J Human Genet* 2003; 72: 1261-1267.
4. Peng H, Cao X, Li HH, *et al.* Haplotype and linkage analysis in Chinese hereditary mixed polyposis syndrome. *Zhonghua Wei Chang Wai Ke Za Zhi* 2005; 8(4): 312-315.
5. Tomlinson I, Nazneen R, Ian F, *et al.* Inherited susceptibility to colorectal adenomas and carcinomas. Evidence for new predisposition gene on 15q14-q22. *Gastroenterology* 1999; 116: 789-795.
6. X Cao, Kw Eu, Kumarasinghe MP, *et al.* Mapping of hereditary mixed polyposis syndrome (HMPS) to chromosome 10q23 by genome-wide high density single nucleotide polymorphism (SNP) SCAN and identification of BMPRIA loss of function. *J Med Genet* 2006; 43(3): e13.