



Master of Medicine (MMed) in Plastic and Reconstructive Surgery

Submitted to:

**University of Cape Town
Faculty of Health Sciences**

Anthropometric Changes in a Prospective Study of 100 Patents Requesting Breast Reduction

Submitted by:

Ngoato Bruce Lelala

Student number: LLLNG0002

Supervisor:

Professor Donald A. Hudson

September 2019

The copyright of this thesis vests in the author. No quotation from it or information derived from it is to be published without full acknowledgement of the source. The thesis is to be used for private study or non-commercial research purposes only.

Published by the University of Cape Town (UCT) in terms of the non-exclusive license granted to UCT by the author.

Table of contents

1. Part A: Plagiarism Declaration	page 3
2. Part B: Final Abstract	page 4
References	page 5
3. Part D: Acknowledgements	page 6
4. Part F: List of Appendices	page 7
5. Part G: Journal Article	page 8
6. Part I: Appendices	page 14

Part A: Plagiarism Declaration

I, *Ngoato Bruce Lelala*, hereby declare that the work on which this dissertation/thesis is based is my original work (except where acknowledgements indicate otherwise) and that neither the whole work nor any part of it has been, is being, or is to be submitted for another degree in this or any other university.

I empower the university to reproduce for the purpose of research either the whole or any portion of the contents in any manner whatsoever.

Signed by candidate

Dr Ngoato B. Lelala

12 August 2019

Part B: Final Abstract

Anthropometric Changes in a Prospective Study of 100 Patients Requesting Breast Reduction

Background

The anthropometry of the “ideal” breast is well described, but changes that occur with enlarged breasts are not. The aim of this study was to assess the prevalence of nipple asymmetry in the horizontal plane and changes in the inframammary fold (IMF) in patients presenting with macromastia (defined as excessive development of the mammary gland by Merriam-Webster dictionary).

Methods

One hundred patients (200 breasts) presenting to the Plastic Surgery Clinic for bilateral breast reduction were enrolled in this study. Patient’s characteristics captured for this study included age, body mass index (BMI), and breast anthropometric measurements, such as suprasternal notch to nipple, nipple to IMF, IMF projected to cubital fossa, midhumeral point, and nipple measurement from meridian. Basic univariate statistical analysis were performed to evaluate the impact of nipple asymmetry.

Results

The average age was 37 years (SD 12 years), and the median BMI was 33 (IQR 28-37). More patients presented with nipple asymmetry, of whom 45% were classified as lateral to meridian, 19% were classified as medial to the meridian, and 36% were classified as central to the meridian. Patients with lateral asymmetry and medial asymmetry has a significantly higher BMI (median BMI 35) compared with patients with central positioning (median 30). Increasing breast size was positively associated with nipple asymmetry, whereas BMI ($R = -0.30$, $P = 0.003$) and macromastia correlated negatively with IMF position ($R = -0.38$, $P = 0.0001$).

Conclusion

In macromastia, nipple displacement from breast meridian, especially lateral displacement, is common and is aggravated by an increase in BMI. The IMF also descends, and this is also common in patients with a raised BMI. These changes have clinical implications.

References:

1. Rohrich, R.J., et al. Incidence of Breast and Chest Wall Asymmetry in Breast Augmentation: A Retrospective Analysis of 100 Patients. *Journal of Plastic & Reconstructive Surgery*, 2006. 118 (Suppl): p. 7s-13s
2. Lewin, R., et al., *The Aesthetically Ideal Position of the Nipple-Areolar Complex on the Breast*. *Journal of Aesthetic Plastic Surgery*, 2016. 40: p.724-732
3. Mallucci, P., Branford, O.A., *Concept in aesthetic breast dimensions: Analysis of the ideal breast*. *Journal of Plastic, Reconstructive & Aesthetic Surgery*, 2012. 65: p. 8-16
4. Mallucci, P., Branford, O.A., *Population Analysis of the Perfect Breast: A Morphometric Analysis*, *Journal of Plastic & Reconstructive Surgery*, 2014. 134: p. 436-447
5. Hall-Findlay, E.J., Shestak, K.C., *Breast Reduction*, *Journal of Plastic & Reconstructive Surgery*, 2015. 136: p. 531-544
6. Barbosa, M.V.J., et al., *Keyhole pattern for preoperative marking for reduction mammaplasty*, *Canadian Journal of Plastic Surgery*, 2010. 18: p. 130-134
7. Cheema, M.H., Singh, S., *Modified Pitanguy Technique for intraoperative Symmetrical localization of Nipple-Areola Complex*, *Journal of Aesthetic Plastic Surgery*, 2008. 32: p. 920-922

Part C: Acknowledgements

I would like to thank the following individuals for their support and assistance in this project:

1. Professor Donald Hudson, my chief supervisor, for his support, motivation, guidance and valuable input into completing our research and writing this thesis.
2. Dr Franscas Malherbe for referring some of the patients from his Breast clinic to our Plastic Surgery OPD for evaluation
3. Mr Shameem Jaumdally for assistance with the statistical analysis
4. The Division of Plastic & Reconstructive Surgery OPD for allowing me to conduct my study.

Part D: List of appendices

1.1. UCT HREC approval letter	page	14
2.2 Literature review	page	16
1.3. Prof Donald Hudson Letter	page	22

Part E: Journal Article

OPEN



ORIGINAL ARTICLE

Breast

Anthropometric Changes in a Prospective Study of 100 Patients Requesting Breast Reduction

Donald A. Hudson, MMed, FRCS (Ed), FCS (SA), FACS
Ngoato B. Lelala, BSc, MBChB, DA

Background: The anthropometry of the “ideal” breast is well described, but changes that occur with enlarged breasts are not. The aim of this study was to assess the prevalence of nipple asymmetry in the horizontal plane and changes in the inframammary fold (IMF) in patients presenting with macromastia (defined as excessive development of the mammary glands by Merriam-Webster dictionary). **Methods:** One hundred patients (200 breasts) presenting to the Plastic Surgery Clinic for bilateral breast reduction were enrolled in this study. Patients’ characteristics captured for this study included age, body mass index (BMI), and breast anthropometric measurements, such as suprasternal notch to nipple, nipple to IMF, IMF projected to cubital fossa, midhumeral point, and nipple measurement from meridian. Basic univariate statistical analyses were performed to evaluate the impact of nipple asymmetry.

Results: The average age was 37 years (SD 12 years), and the median BMI was 33 (IQR 28–37). More patients presented with nipple asymmetry, of whom 45% were classified as lateral to the meridian, 19% were classified as medial to the meridian, and 36% were classified as central to the meridian. Patients with lateral asymmetry and medial asymmetry had a significantly higher BMI (median BMI 35) compared with patients with central positioning (median BMI 30). Increasing breast size was positively associated with nipple asymmetry, whereas BMI ($R = -0.30$, $P = 0.003$) and macromastia correlated negatively with IMF position ($R = -0.38$, $P = 0.0001$).

Conclusion: In macromastia, nipple displacement from the breast meridian, especially lateral displacement, is common and is aggravated by an increase in BMI. The IMF also descends, and this is also more common in patients with a raised BMI. These changes have clinical implications. (*Plast Reconstr Surg Glob Open* 2019;7:e2150; doi: 10.1097/GOX.0000000000002150; Published online 24 May 2019.)

INTRODUCTION

The breast has been described as the most changeable organ in the body, altering with puberty, pregnancy, weight gain, hormonal changes, and aging.¹ Breast asymmetry is well documented in patients presenting for breast augmentation.^{2,3} However, the implications are different for patients with macromastia requesting a breast reduction.

Although anthropometric studies have been performed to investigate the ideal breast,^{4–8} the changes that

occur with enlarged breasts have not been defined: how does the footplate change with enlargement and does the breast retain its proportions? The changes that occur to the inframammary fold (IMF) are also not well documented. Furthermore, few studies have focused on the position of the nipple relative to the breast meridian (ie, medial–lateral plane/ x plane). The surgeon, by understanding the changes that occurs, can reverse them and, in so doing, optimize the aesthetic result of breast reduction.

This study reports on the anthropometric data of 100 consecutive patients presenting to a tertiary hospital for bilateral breast reduction. The clinical implications are discussed.

METHODS

A prospective cohort of 100 patients who presented to the Plastic Surgery Outpatient Department at Groot-

From the Department of Plastic and Reconstructive Surgery, University of Cape Town, Cape Town, South Africa

Received for publication August 30, 2018; accepted December 19, 2018.

Copyright © 2019 The Authors. Published by Wolters Kluwer Health, Inc. on behalf of The American Society of Plastic Surgeons. This is an open-access article distributed under the terms of the Creative Commons Attribution-Non Commercial-No Derivatives License 4.0 (CCBY-NC-ND), where it is permissible to download and share the work provided it is properly cited. The work cannot be changed in any way or used commercially without permission from the journal.

DOI: 10.1097/GOX.0000000000002150

Disclosure: The authors have no financial interest to declare in relation to the content of this article.

Schuur Hospital between July 1, 2017, and November 31, 2017, with clinical macromastia (defined as excessive development of the mammary glands by Merriam-Webster dictionary) and requesting bilateral breast reduction were assessed for nipple displacement relative to the breast meridian and IMF position relative to the midhumeral point.

Inclusion criteria included participants above the age of 18 years and presenting to our OPD requesting bilateral breast reduction. Exclusion criteria included participants requesting other forms of breast surgery, or those who had previous breast surgery.

Patient's height and weight were measured, and their body mass index (BMI) was calculated. All patients were marked in an upright position.

The distance from suprasternal notch to nipple (SN-N) and the distance from nipple to IMF (N-IMF) were measured in centimeters and recorded. These are standard measurements.

Three vertical lines were drawn on the patient's chest wall (Figs. 1, 2) to mark the vertical breast meridian for each breast: the first line passes down the chest midline through the center of the sternum (long green line) and the second line is drawn along the anterior axillary line (short green line).

To ensure that the breast meridian was situated in the middle of the breast, additional markings and calculations were performed; ie 2 cm was subtracted from the sternal midline on the horizontal plane at the fourth intercostal space, to mark the medial aspect of the breast. Then, the breast meridian (red dotted line) was marked at the midpoint between this point and the anterior axillary line (Figs. 1, 2).

The nipple position was measured relative to the breast meridian and categorized into 3 groups, namely: (1) nipple situated on the breast meridian, (2) nipple situated 2 cm or more medial to the meridian, and (3) nipple situated 2 cm or more lateral to meridian.

The length of humerus was measured from the inferior aspect of the acromioclavicular joint to the cubital fossa. The midhumeral point (ie, half way between the acromioclavicular joint and cubital fossa) was marked on the upper arm.

A ruler was placed along the center of the IMF, and the point where this projected onto the upper arm (humerus) was marked as the IMF point (Fig. 1B).

Finally, the distance between the IMF point (when projected on the upper arm) and the cubital fossa of the elbow was measured.

All the measurements were performed by the second author (NBL). All patients signed written consent. Ethical approval was obtained from the Human Research Ethics Committee (077/2017).

Anthropometric Breast Measurement: Statistical Analysis

Shapiro-Wilk test for normality was performed to determine the distribution of variables within the dataset. The Spearman's rank test was applied to test for correlation between nonparametric data. Statistical inferences on binary sets of data were performed using the Fisher's exact test, and odds ratios were calculated. Nonparametric assessments of variation between groups were carried out through the Kruskal-Wallis analysis of variance, with Dunn's post-test being applied to test for the effect of multiple comparisons. Statistical analyses were performed using

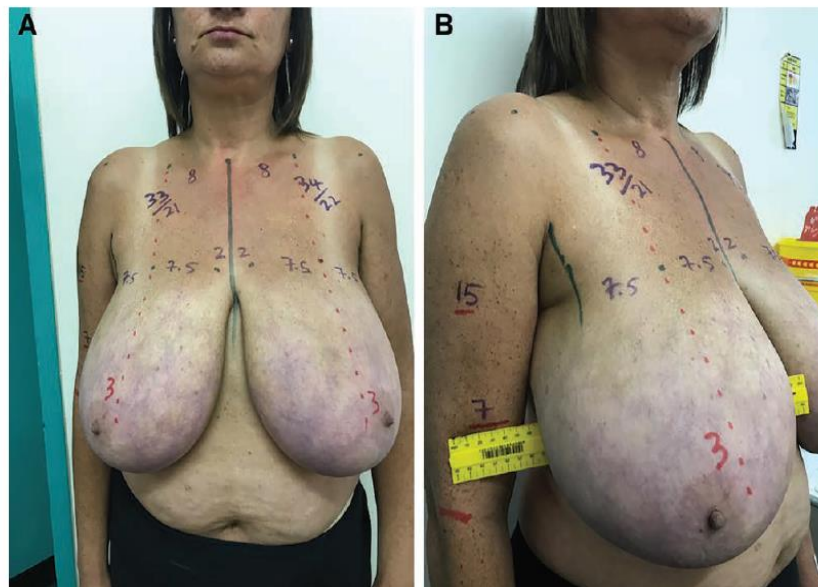


Fig. 1. Anthropometric markings in 38-year-old patient with a BMI of 31, presenting with macromastia. (A) Anterior view (B) Oblique view. The ruler rests on the IMF, the level of the IMF is projected on the upper arm, and this point is marked. The length of the humerus is measured and midpoint is calculated (15 cm in this patient). Also, the distance from the cubital fossa to the projected IMF is recorded. In this patient, the IMF is 7 cm above the antecubital fossa.

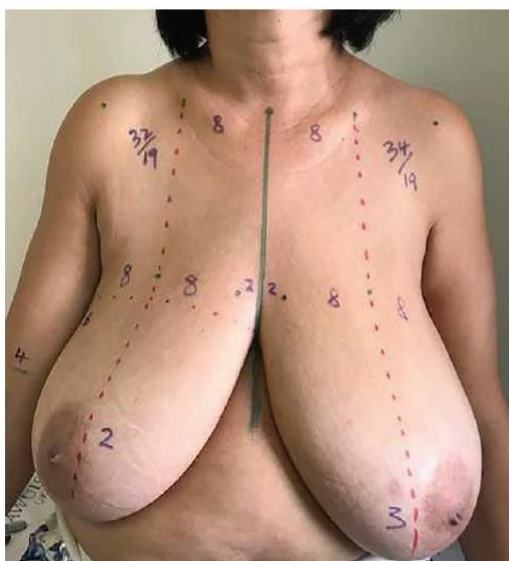

Fig. 2. In this patient, the nipple is lateral to the breast meridian. The IMF projected onto the upper arm is only 4 cm from the cubital fossa. The length of the humerus is 30 cm.

the GraphPad Prism version 5.0 for Windows (GraphPad Software, San Diego, CA). All tests were 2-tailed, and *P* values ≤ 0.05 were considered statistically significant.

RESULTS

A total of 100 participants were enrolled for the study (Figs. 1, 2). They had an average age of 37 years (range 18–69 years). Regarding BMI, 22% were classified as overweight, 54% were classified as obese, and 14% were classified as extremely obese (BMI >40). Only 10% of participants classified as normal weight per BMI (Table 1).

The mean measurement from SN-N was 33 cm (range 18–50 cm). The mean distance from N-IMF was 17 cm (range 6–29 cm).

Nipple position was classified as central to the breast meridian in 36% of breasts examined, 45% were recorded as laterally positioned relative to the meridian, and 19% were classified as medial to the breast meridian. In 45 patients (36 lateral and 9 medial), the NAC was displaced 2 cm or more from the meridian of the breast (Table 1).

Table 1. Characteristics of Participants

Characteristics	
N	100
Mean age (y) (SD)	37 (12)
Median BMI (IQR)	33 (28–37)
Mean notch to nipple (cm) (SD)	33 (7)
Position of nipple, n (%)	
Central	73 (36)
Lateral	89 (45)
Medial	38 (19)
Median IMF position Average (cm) (IQR)	5 (4–7)
Midhumerus point (cm) (IQR)	15 (14–15)

IQR, interquartile ration.

The mean length of the humerus was 30 cm (range 18–34 cm). The mean midpoint of the humerus was 15 cm. The average distance of the IMF (when projected onto the arm) below the middle of the humerus was 8.5 cm. The median distance between the IMF point (when extended and projected onto the upper arm) and the cubital fossa was 5 cm (range 2–14 cm) (Table 1).

Statistical Analysis

1. Patients with increasing BMI were more likely to have nipple positions medial or lateral to the breast meridian ($P = 0.0005$, Fisher's exact test; Fig. 3).
2. As the nipple-to-notch distance increases, the IMF descends closer to the cubital fossa ($R = -0.38$, $P = 0.0001$, Spearman's rank test; Fig. 4) Note: *y*-axis marks IMF position relative to cubital fossa.
3. As the BMI increases, the position of the IMF descends ($R = -0.30$, $P = 0.003$, Spearman's rank test; Fig. 5).
4. As age increases, the IMF descends ($R = -0.06$, $P = 0.54$, Spearman's rank test; Fig. 6), but this was a trend did not reach statistical significance.

DISCUSSION

The breast is a subcutaneous structure situated between the second and sixth ribs.^{4,6,7} The ideal breast is not ptotic, and its shape is maintained by taut Cooper's ligaments. The ideal nipple position needs to be defined in 2 planes. In the *y*-axis or vertical plane, it should be in the middle of the breast or just lateral to the midline.⁴ In the *x*-axis or horizontal plane, it should be level with the midpoint of the humerus, or marginally (1.5 mm) below.^{4,5} The curve of the IMF should form a semicircle,⁴ and its inferior most point should be situated at the level of the sixth rib.^{4,8} Westreich⁴ in his study of the "perfect" breast did not find a correlation between body length (patient height) and nipple position, which was always situated at the level of the midhumerus.

As the breast enlarges, the nipple position deviates from the breast meridian (Figs. 1–3). This is more pronounced in patients with a raised BMI (Fig. 3). This nipple displacement may be explained by changes in the ligamentous anatomy.^{9,10} Matousek et al⁹ reported that the breast is globally surrounded by taut ligaments. The medial breast ligaments are short and taut compared with the lateral ligaments, and hence, in some patients, as the breast enlarges, the nipple is displaced medially from the breast meridian. This occurred in 19% (19 patients; 38 breasts) of patients (Table 1) in this study. In contrast, the ligaments forming the inferior-lateral breast base are more tenuous and appear to stretch more easily, resulting in inferolateral displacement of the nipple. In this study, the nipple position was found to be displaced laterally to the breast meridian in 45% of cases (45 patients; 90 breasts; Fig. 3). Clinically, extrapolating the data from this study suggests that if the preoperative nipple position is used to mark the breast midline (thus, nipple position after breast reduction), the new nipple position would be situated either too far

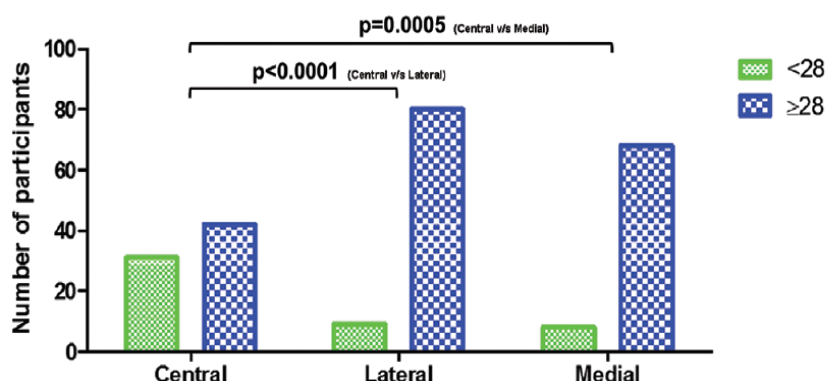


Fig. 3. BMI vs nipple position. As the BMI increases, the nipple shifts from the breast meridian (lateral $P < 0.0001$ and medial $P = 0.0005$, Fisher's exact test).

medially and/or laterally in 64% of cases, marring the aesthetic results.

This study also shows that, as the breast enlarges, the position of the IMF also descends (Fig. 4). Again, this is aggravated in patients as the BMI increases (Fig. 5). This implies that as the breast enlarges globally, the base/foot-plate also increases in surface area. This descent of the IMF is also probably due to attenuation of the superficial ligaments constituting the IMF. There was a tendency for patients with increasing age to also have a lower situated IMF, but this did not reach statistical significance ($P = 0.54$; Fig. 6).

The position of the IMF was never ever at the midpoint of the humerus—the ideal aesthetic point⁴ in any patients in this study. In fact, more commonly, the projected IMF position was, on average, only 5 cm above

the cubital fossa, indicating the extend of its descent. Hence, it is suggested that the position of the IMF in breast reduction be fixed to prevent further descent.^{11,12} This is achieved by anchoring the IMF to both rib periosteum and pectoralis fascia. Additionally, this maneuver splints the IMF, which reduces tension at the angle of sorrow.¹¹ Interestingly, IMF fixation is well described in breast augmentation^{3,13,14} to prevent inferior migration of the prosthesis.

The lower position of the IMF has other clinical implications: in most techniques of breast reduction, the new nipple position is marked relative to the position of the IMF (Pitanguy's point). If Pitanguy's point is used to mark the new nipple position at breast reduction, the new nipple position would be situated much lower than middle of the length of the humerus. In fact, patients in this study would have the new nipple position (on average)

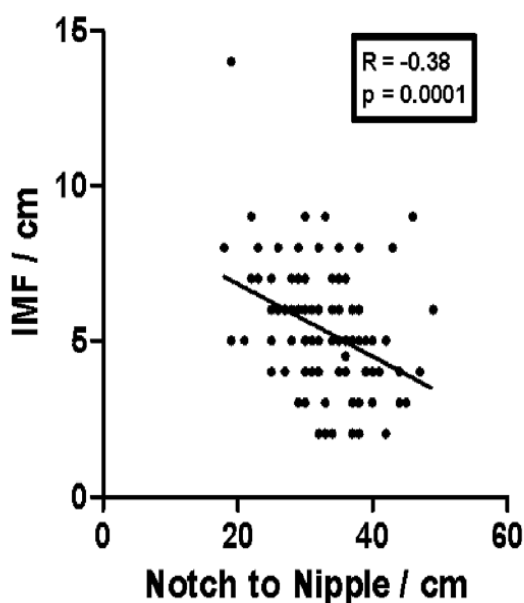


Fig. 4. As the nipple–notch distance increases, the IMF descends ($R = -0.38$, $P = 0.0001$, Spearman's rank correlation).

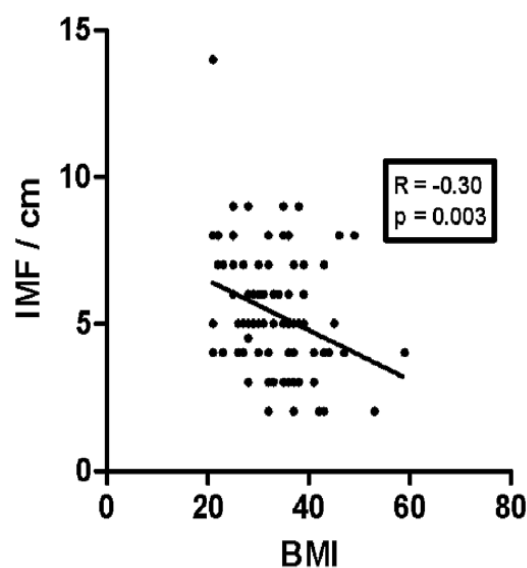


Fig. 5. BMI vs IMF position. ($R = -0.30$, $P = 0.003$, Spearman's rank correlation).

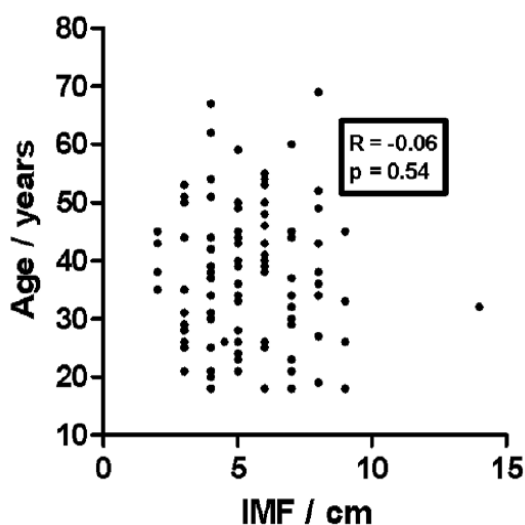


Fig. 6. IMF vs age ($R = -0.06$, $P = 0.54$, Spearman's rank correlation).

positioned approximately three quarters down the length of the humerus. In contrast, if the midhumeral point was used, the new nipple position would be situated too high after breast reduction.

It is also our policy to mark the new nipple position at the level of the IMF. (Pitanguy's point). The descent of the IMF implies that the new nipple position is marked a longer distance from the suprasternal notch than if the midhumeral point is used. To maintain the aesthetic ratio of SN-N:N-IMF, the distance from N-IMF (vertical limbs in keyhole/inverted T pattern) also needs to be made longer. In patients having a vertical mammoplasty, the new nipple is marked even lower than the position of the IMF projected onto the breast, with the obvious implications. Extrapolating these data suggests that patients may need to be advised of a longer, flatter upper pole, which is likely to occur after reduction.

The superomedial pedicle is becoming more popular in breast reduction due to its robust and reliable vascularity.¹⁴ When the NAC is displaced laterally relative to the breast meridian, rotation and inset of the pedicle are enhanced. However, when the NAC is displaced medially, a conventionally designed keyhole pattern would impede pedicle rotation, even if a back cut is performed. Iorio et al¹⁵ reported lengthening the vertical limb of the keyhole to address the medially deviated nipple areola complex.

There are some shortcomings to this study. Macromastia is a clinical diagnosis of enlarged breasts, and all the patients who presented had clinical symptoms of backache and shoulder pain, rather than aesthetic concerns. No patients with ideal breasts were seen, so the comparison of macromastia with the ideal breast was derived from the literature. All the patients were measured in the standing position. Furthermore, there were no cases of gross chest asymmetry, but minor chest wall asymmetry may have been missed. Additionally, this study is not addressing the outcome of these patients after breast reduction but

rather investigated anthropometric changes that occur in patients presenting with enlarged breasts.

This is the first study to report on changes occurring in 100 consecutive patients presenting for breast reduction. As the breast enlarges, there is displacement of the nipple areolar complex, either laterally (45%) or medially (19%) from the breast meridian. This nipple displacement is more common in patients as the BMI increases. Hence, using the (preoperative, but displaced) nipple position to mark the breast midline may result in a new nipple position that is not on the breast meridian. This study also shows that the IMF descends in patients with breast hypertrophy, again these changes are aggravated as the BMI increases. Hence, if Pitanguy's point is used to mark the new nipple position after breast reduction, this will result in the new nipple being situated in a lower position than in the middle of the humerus.

Donald A. Hudson, MMed, FRCS (Ed), FCS (SA), FACS
Department of Plastic and Reconstructive Surgery
University of Cape Town
Groote Schuur Hospital
H53 OMB
Observatory
7925 Cape Town, South Africa
E-mail: donald.hudson@uct.ac.za

ACKNOWLEDGMENT

We wish to acknowledge Shameem Jaumdally for assistance with the statistical analysis.

REFERENCES

1. Brody G. The perfect breast: is it attainable? Does it exist? *Plast Reconstr Surg* 2009;113:1500-1503
2. Rohrich RJ, Hartley W, Brown S. Incidence of breast and chest wall asymmetry: a retrospective analysis of 100 patients. *Plast Reconstr Surg* 2003;118:7S-13S.
3. Yeslev M, Braun SA, Maxwell GP. Asymmetry of inframammary folds in patients undergoing augmentation mammoplasty. *Aesthet Surg J*. 2016;36:156-166.
4. Westreich M. Anthropomorphic breast measurement: protocol and results in 50 women with aesthetically perfect breasts and clinical application. *Plast Reconstr Surg*. 1997;100:468-479.
5. Lewin R, Amoroso M, Plate N, et al. The aesthetically ideal position of the nipple-areola complex on the breast. *Aesthetic Plast Surg*. 2016;40:724-732.
6. Liu YJ, Thomson JG. Ideal anthropomorphic values of the female breast: correlation of pluralistic aesthetic evaluations with objective measurements. *Ann Plast Surg*. 2011;67:7-11.
7. Mallucci P, Branford OA. Concepts in aesthetic breast dimensions: analysis of the ideal breast. *J Plast Reconstr Aesthet Surg*. 2012;65:8-16.
8. Penn J. Breast reduction. *Br J Plast Surg*. 1955;7:357-371.
9. Matousek SA, Corlett RJ, Ashton MW. Understanding the fascial supporting network of the breast: key ligamentous structures in breast augmentation and a proposed system of nomenclature. *Plast Reconstr Surg*. 2014;133: 273:2081
10. Steele TN, Pribaz J, Lau FH. The sternum nipple distance is double the nipple-inframammary fold distance in macromastia. *Ann Plast Surg*. 2017;78:S347-350
11. Hudson DA, Moodley S. Breast reduction: decreasing complications and improving long-term aesthetic results with parenchymal sutures. *Plast Reconstr Surg Glob Open*. 2017;5:e1470.

12. Hammond DC. Techniques in breast reduction. Paper presented at: Association of Plastic and Reconstructive Surgeons of Southern Africa Annual Congress; September 14–17, 2018; Arabella, Western Cape.
13. Montemurro P, Awedimento S, Hedén P, et al. A four-layer wound closure technique with barbed sutures for stable reset of the inframammary fold in breast augmentation. *Aesthet Surg J*. 2016;36:966–971.
14. Davison SP, Mesbahi AN, Ducic I, et al. The versatility of the superomedial pedicle with various skin reduction patterns. *Plast Reconstr Surg*. 2007;120:1466–1476.
15. Iorio ML, Endara M, Ducic I. Reduction mammoplasty in patients with a medialized nipple-areola complex: modification of the superomedial dermoglandular pedicle and skin pattern. *Plast Reconstr Surg*. 2013;131:302e–303e.

Part F: Appendices

Appendix 1:

1.1. UCT HREC approval



UNIVERSITY OF CAPE TOWN
Faculty of Health Sciences
Human Research Ethics Committee



Room E53-46 Old Main Building
Groote Schuur Hospital
Observatory 7925
Telephone [021] 406 6492
Email: sunayah.arnold@uct.ac.za
Website: www.health.uct.ac.za/fhs/research/humanethics/forms

26 September 2017

HREC REF:579/2017

Prof D Hudson
Division of Plastic & Reconstructive Surgery
H53, Room 69
OMS

Dear Prof Hudson

PROJECT TITLE: ANTHROPOMETRIC CHANGES IN A PROSPECTIVE STUDY OF 100 PATIENTS REQUESTING BREAST REDUCTION (MMed-candidate-Dr N Lelela)

Thank you for your response letter dated 21 September 2017, addressing the issues raised by the Human Research Ethics Committee (HREC).

It is a pleasure to inform you that the HREC has **formally approved** the above-mentioned study, subject to explaining in lay language some of the terms in the informed consent document e.g. asymmetries meridian.

Approval is granted for one year until the 30 September 2018.

Please submit a progress form, using the standardised Annual Report Form if the study continues beyond the approval period. Please submit a Standard Closure form if the study is completed within the approval period.

(Forms can be found on our website: www.health.uct.ac.za/fhs/research/humanethics/forms)

We acknowledge that the student: Dr N Lelela will also be involved in this study.

Please quote the HREC REF in all your correspondence.

Please note that the ongoing ethical conduct of the study remains the responsibility of the principal investigator.

Please note that for all studies approved by the HREC, the principal investigator **must** obtain appropriate institutional approval, where necessary, before the research may occur.

Yours sincerely

Signature Removed

PROFESSOR M. BLOCKMAN
CHAIRPERSON, FHS HUMAN RESEARCH ETHICS COMMITTEE

Federal Wide Assurance Number: FWA00001637.

Institutional Review Board (IRB) number: IRB00001938

This serves to confirm that the University of Cape Town Human Research Ethics Committee complies to the Ethics Standards for Clinical Research with a new drug in patients, based on the Medical Research Council (MRC-SA), Food and Drug Administration (FDA-USA), International Convention on Harmonisation Good Clinical Practice (ICH GCP), South African Good Clinical Practice Guidelines (DoH 2006), based on the Association of the British Pharmaceutical Industry Guidelines (ABPI), and Declaration of Helsinki (2013) guidelines.

The Human Research Ethics Committee granting this approval is in compliance with the ICH Harmonised Tripartite Guidelines E6: Note for Guidance on Good Clinical Practice (CPMP/ICH/135/95) and FDA Code Federal Regulation Part 50, 56 and 312.

Appendix 2:

1.2. Literature review

List of Contents of Literature review:

1. Objectives	page 17
2. Literature search methods	page 17
3. Interpretation of literature	page 18
3.1. Introduction	page 18
3.2. The ideal breast	page 18
3.3. The NAC	page 19
3.4. The IMF	page 19
3.5. Conclusion	page 20
4. References	page 21

1. Objectives:

The study objective is to determine the relationship between:

- a. Macromastia and breast nipple asymmetries
- b. Body Mass Index (BMI) and breast asymmetry

2. Literature Search Methods:

- Search engines used to acquire the relevant journal articles: PubMed, Medline and Google Scholar.
- Search words and phrases used:
 - Breast
 - Macromastia
 - Ideal breast
 - Breast reduction
 - Gigantomastia
 - Breast meridian
 - Inframammary fold (IMF)
 - Nipple areola complex (NAC)
 - Breast anthropometrics
 - Aesthetically perfect breast
 - Perfect breast
 - Breast asymmetry
 - Female breast
 - Breast dimensions
 - Augmentation
 - Mammoplasty

- Related citations suggested by the search engine were used.
- References cited in journal articles obtained were used to further broaden the search.
- Only articles cited in the English language were used.

3. Interpretation of the Literature

3.1. Introduction

The breast is the most changeable organ in the body, altering with puberty, weight gain and loss, hormonal balance, pregnancy, lactation, menopause, and with aging (1). It is an organ with varied volume, width, height, projection, tissue density, composition, shape, and position on the chest wall; this makes the female breast one of the most difficult organs to assess objectively (10). In breast surgery whether augmentation, reduction, or reconstruction, the goal in any breast-contouring procedure should be to create a symmetrical and aesthetically pleasing breast (2). Breast reduction is one of the most common procedures performed by plastic surgeons and the benefits have been extensively documented and include pain relief, improved posture, improved quality of life, and an increase in quality-adjusted life years as well as improve body self-image (3,12). Although there has been a lot of literature concerning the anthropometry of the ideal breast, changes that occur with macromastia and the clinical implications have not been described.

3.2 The ideal breast

In the past, investigators have attempted to define standards for anthropomorphic measurement both subjectively and quantitatively, as well as identifying an objective description of the aesthetically ideal breast, but they have all suffered in their reliability due to several intrinsic limitations (4, 5). Surgery of the breast is a broad field of plastic surgery, and regardless of the nature of the procedure, whether reconstruction or cosmetic, the main goal is always to create a natural appearance and symmetric breast to meet the patient's expectations (1, 5). Multiple authors agree that this entails creating a breast that is proportional to the body with no ptosis, and have a nipple at the most anteriorly projecting portion of the breast that is conical to teardrop in shape (2, 10).

Penn in his 1955 landmark paper measured the breasts of 150 healthy volunteers, and among these, he personally judged the breasts of 20 volunteers to be aesthetically perfect, and his anthropomorphic measurements have been used as "normal" values (4, 6). In Smith's article, 66 women were studied, he differed from Penn by including patients with marked breast hypertrophy, ptosis, or both, and compared his results with the concept of the "ideal nipple position" (10, 11). Westreich's study on the perfect breast found values of 18.59cm from suprasternal notch-to- nipple distance, Nipple-to-IMF distance was 6.95cm, and the true nipple plane 1,5mm below the midhumeral point with IMF 4.18cm lower to the midhumeral point (10).

In 2011 Mallucci & Banford's observational study defined critical ideals of breast beauty and identified a recurring pattern in four key parameters that included: an upper pole-to-lower pole ratio of 45:55 percent, an upward pointing nipple with mean angle of 20 degrees, a straight or mildly concave upper pole slope,

and a smooth lower pole convexity (7, 8). The objective landmarks for assessment of an aesthetically pleasing breast include volume of the breast, position of the inframammary fold (IMF), base diameter, and size and position of the nipple-areola complex (NAC) (9).

3.3 The NAC

The ideal nipple plane is defined as a line level to the midpoint on the shaft of the humerus and was considered by Maliniac as the ideal level for the nipple (10). However Penn found that in his 20 perfect subjects the true nipple plane was 3.75cm beneath the midhumeral point, and Westreich found this plane to be only 1.5mm lower to the midhumeral point (6, 10). Rohrich *et al.* observed that nearly 88 percent of women had natural asymmetries when critically examined, 24.5% had asymmetry in at least two parameters, while another 24.5% had asymmetry of one parameter (2, 9). The NAC placement is preferred to be at a ratio of 04:60 *x* and 50:50 *y*, which means that it is best situated in the middle of the breast gland vertically and slightly lateral to the midpoint horizontally (5). A displacement of the NAC by 0.5 – 1.5 cm in the vertical direction is considered to be less aesthetically acceptable as compared with similar displacement in the horizontal plane (9). A women's NAC undergoes dynamic positional changes throughout morphogenesis, and tend to descend with normal aging, as glandular ptosis develops (17). The NAC position changes that occurs with high BMI, macromastia and advancing age are not well documented in literature.

3.4 The IMF

The inframammary fold fibers form attachment between the chest wall and the dermis, however it has been subject to several conflicting descriptions (13, 16). The ideal IMF is at or above the sixth rib, but this is quite variable from person to person (13). It is recognized that the IMF descends with age and in patients with a raised BMI (14, 15). The sternum to nipple distance has been found to be double the distance from nipple to IMF in patients with macromastia (12). According to Yeslev *et al.* the breast volume, IMF location, and NAC location, are part of a complex and inter-related structural system present within the female, where disproportion in one parameter can cause morphologic changes in the others (17).

The IMF is a zone of adherence and prevents descent of the breast caused by gravity, but can be lowered if the fibers are stretched as seen in patients with macromastia or in massive weight loss patients where the fold drops towards the abdomen (13).

3.5 Conclusion

The female breast is noted for its diverse physiognomy, making accurate, reproducible measurements very difficult, therefore identification of pre-existing breast asymmetry in a patients undergoing breast surgery aids the surgeon in developing a precise operative plan, which accounts for these differences in order to optimize symmetry and obtain an ideal surgical outcome (10, 17).

However there is a lack of studies examining the breast changes that occurs with macromastia and the clinical applications of these changes, which makes our study unique and insightful in this regards

4. References

1. Brody G. The Perfect Breast: Is It Attainable? Does It Exist? *Plast Reconstr Surg* 2009; 113: 1500 – 1503
2. Rohrich RJ, Hartley W, Brown S. Incidence of Breast and Chest wall Asymmetry in Breast Augmentation: A Retrospective Analysis of 100 Patients. *Plast Reconstr Surg* 2003; 118: 7S – 13S
3. Nahai FR, Nahai F. Breast Reduction. *Plast Reconstr Surg* 2008; 121: 1-13
4. Liu YJ, Thomson JG. Ideal Anthropomorphic Values of the Female Breast: Correlation of Pluralistic Aesthetic Evaluation with Objective Measurements. *Ann Plast Surg* 2011; 67:7-11
5. Lewin R, Amoroso M, Plate N, et al. The Aesthetically Ideal Position of the Nipple-Areola Complex on the Breast. *Aesthetic Plast Surg* 2016; 40: 724-732
6. Penn J. Breast Reduction. *Br J Plast Surg* 1955;7: 357-371
7. Mallucci P, Branford OA. Concepts in aesthetic breast dimensions: Analysis of the ideal breast. *J Plast Reconstr Aesthet Surg* 2012; 65: 8-16
8. Malluci P, Branford OA. Population Analysis of the Perfect Breast: A Morphometric Analysis. *Plast Reconstr Surg* 2014; 134: 436-447
9. Cheema MH, Singh S. Modified Pitanguy Technique for Intraoperative Symmetrical Localization of Nipple-Areola Complex. *J Aesth Plast Surg* 2008; 32: 920-922
10. Westreich M. Anthropomorphic Breast Measurement: Protocol and Results in 50 Women with Aesthetically Perfect Breast and Clinical Application. *Plast Reconstr Surg* 1997; 100: 468-479
11. Smith DJ, Palin WE, Katch VL, et al. Breast volume and anthropomorphic measurements: Normal values. *Plast Reconstr Surg* 1986; 78: 331- 335
12. Steele TN, Pribaz JJ, Lau FH. The Sternum-Nipple Distance is Double the Nipple-Inframammary Fold Distance in Macromastia. *Ann Plast Surg* 2017; 78: S345- S350
13. Hall-Findlay EJ. The Three Dimensions: Analysis and Effecting Change. *Plast Reconstr Surg* 2010; 125: 1632-1642
14. Hudson DA, Moodley S. Breast Reduction: Decreasing Complications and Improving Long-Term Aesthetic Results with Parenchymal Sutures. *Plast Reconstr Surg Glob Open* 2017;5: e1470
15. Hammond DC. *Atlas of Aesth Breast Surg*. New York: Elsevier; 2009
16. Matousek SA, Corlett RJ, Ashton MW. Understanding the Fascial Supporting Network of the Breast: Key Ligamentous Structures in Breast Augmentation and a Proposed System of Nomenclature. *Plast Reconstr Surg* 2014; 133: 273-281
17. Yeslev M, Braun SA, Maxwell P. Asymmetry of Inframammary Folds in Patients undergoing Augmentation Mammoplasty. *Aesthet Surg J* 2016; 36:156-166

Appendix 3: 1.3. Prof Hudson's Letter

UNIVERSITY OF CAPE TOWN



Department of Plastic, Reconstructive and Maxillo-Facial Surgery

Medical School · Observatory 7925 · Cape Town · South Africa

Departmental Office · Room H53/69 · O.M.B. · Groote Schuur Hospital

Telephone: (021) 404-3426/406-6415

Fax: (021) 406-6649

Email: Donald.Hudson@uct.ac.za

Head of Dept.: Professor DA Hudson MB ChB, FCS (SA), FRCS (Ed), MMed (UCT) FACS

PR No 0360003601331

Professional Masters Committee of faculty of Health Science

RE : MMed of Dr NB Lelala

Dr Lelala should have been joint first author of our publication "Anthropometric Changes in a Prospective Study of 100 Patients Requesting Breast Reduction published in Plastic and Reconstructive Surgery Global Open 2019;7:e2150=which forms part of his thesis

Signature Removed

Prof DA Hudson