

**Transorbital Endoscopic Surgery for Sphenoid Wing Meningioma: Long-term
Outcomes & Surgical Technique**

Masters of Medicine in Otorhinolaryngology

University of Cape Town

Dr Nicholas Goncalves

[*drnicgoncalves@gmail.com*](mailto:drnicgoncalves@gmail.com)

University of Cape Town

The copyright of this thesis vests in the author. No quotation from it or information derived from it is to be published without full acknowledgement of the source. The thesis is to be used for private study or non-commercial research purposes only.

Published by the University of Cape Town (UCT) in terms of the non-exclusive license granted to UCT by the author.

Table Of Contents

Title Page	1
Declaration page	3
Acknowledgments.....	4
Chapter 1 (Introduction & Literature Review)....	5
Chapter 2 (Publication Manuscript).....	15
References.....	34
List of Tables & Figures.....	36
Appendix.....	44

DECLARATION

I, *Nicholas Goncalves*, hereby declare that the work on which this dissertation/thesis is based is my original work (except where acknowledgements indicate otherwise) and that neither the whole work nor any part of it has been, is being, or is to be submitted for another degree in this or any other university.

I empower the university to reproduce for the purpose of research either the whole or any portion of the contents in any manner whatsoever.

Signature:

Signed by candidate

Date:29 January 2020

Acknowledgements & Contributions

Nicholas Goncalves

Protocol, ethics application, data collection, data interpretation, write up, manuscript author and assistant surgeon

Associate Professor Darlene Lubbe

Project supervisor, principle investigator, write up editor, manuscript author and principle surgeon

Mark Webb and Duncan Brett for Statistical analysis, Research LampPost, Cape Town

Statistical support

Chapter 1

Introduction & Literature Review

Meningiomas are the most common benign tumors of the central nervous system, comprising between 12 and 15% of all intracranial neoplasms (1-4). They are of mesenchymal origin and arise from arachnoid cells of neurovascular structures in close proximity to cranial sutures (3). Sphenoid wing meningiomas are the most frequently occurring tumor of the sphenoid wing making up approximately 18% of all meningiomas (2, 4). Cushing and Eisenhardt were the first to classify sphenoid wing meningiomas into globoid, nodular and *en plaque* subtypes (2). The more common globoid entity has been sub-classified according to the anatomical location of the lesser sphenoid wing i.e. medial, middle and lateral. The medial third comprises the projection of bone from posterior to anterior most closely adjacent to the anterior clinoid process. The middle third lies immediately lateral to the middle third and the lateral third comprises the most lateral portion of bone before it joins the squamous portion of the temporal bone (2). This classification was further modified into medial third and lateral two thirds by Fohanno and Bitar, as the medial third corresponds to the posterior margin of the lesser wing and the lateral two thirds corresponds to the posterior margin of the greater wing (4, 5).

En plaque meningiomas are rare and make up 2-9% of all meningiomas. They mostly occur in the sphenoid wing and are 3 – 6 times more common in females (6). Spheno-orbital meningiomas have been shown to occur almost exclusively in females (94%) (7). In the literature *en plaque* meningiomas are also referred to as pterional tumors of the sphenoid, hyperostosing tumors and spheno-orbital meningiomas. This subtype is characterized by a small volume, thin layer of tumor (meningeal component), which is out of proportion to a

relatively large bony hyperostosis. The hyperostosis is thought to result from direct tumor spread into the bone via the Haversian canal system. The bony hyperostosis identified on computed tomography (CT) scan must be differentiated from other conditions such as Paget's disease, fibrous dysplasia and malignancy (6). These tumors are distinctly difficult to manage due to the extensive dural component, making complete surgical excision challenging and resulting in high recurrence rates. Sphenoid wing meningiomas may spread secondarily into the orbit, superior orbital fissure, cavernous sinus and intracranially (6).

Studies reporting the natural history of spheno-orbital meningiomas have shown that these tumours are generally slow growing with an annual growth rate of 0.3cm³ per year (7).

The average size of tumors measured on CT scan at presentation has been reported to be 3.4cm (8). Although tumor growth is unpredictable various factors have been shown to be associated with increased growth rates i.e. younger age at presentation and a large soft tissue component compared to bony involvement (7).

Sphenoid wing meningiomas commonly occur between the ages of 36 and 70 years. They occur more frequently in females with a female to male ratio of 2.8:1 (4, 9). Patients with neurofibromatosis type 2 (NF-2) and multiple endocrine neoplasia type 1 (MEN-1) are at a greater risk of developing meningiomas (10). Meningiomas occur in NF-2 patients due to a mutation of the tumour suppressor gene located on chromosome 22. They have a 75% lifetime risk of developing meningioma (11). Other risk factors for meningioma include exposure to ionizing radiation, hormonal factors, breast cancer, increased body mass index (BMI) and head trauma (12-15).

Meningioma tumor growth has been postulated to be influenced by female sex hormones (16).

The higher incidence of meningiomas in females, an increased tumor growth rate during

pregnancy and a possible association between breast cancer and meningioma may support tumor hormone responsiveness (16). It is well established that most meningiomas express progesterone receptors and generally lack estrogen receptors (16). It has been demonstrated that the presence of progesterone receptors is a good prognostic tumor indicator and is associated with improved progression free survival (16). Meningiomas that show negative progesterone expression are more likely to be malignant and have a high mitotic index (16). There is no correlation between estrogen receptors and prognostic outcomes (16).

Interestingly, sphenoidal meningiomas have been reported to have a greater female predominance and recurrence risk compared to meningiomas in other sites (7). The identification of progesterone receptor expression in meningioma has led to the use of hormonal therapy as part of the medical management. Mifepristone, an anti-progesterone agent, has been used in the treatment of meningioma and was found to be of benefit in diffuse meningiomatosis (17). However mifepristone has not been shown to reduce tumor size and provide symptom relief in patients with meningioma (17).

Sphenoidal meningiomas may be associated with hyperostosis of the sphenoid wing, a phenomenon well characterized occurring in 25 to 49% of cases (9, 18). Hyperostosis is thought to occur as a result of direct invasion of the tumor into bone via the Haversian canals and commonly occurs in the lateral third of the sphenoid; however, the exact cause of hyperostosis remains unclear (3, 4, 18). The hyperostotic bone is typically large and out of proportion compared to the relatively adjacent small tumor.

The presenting symptoms of patients with sphenoid wing meningiomas are largely determined by the location of the tumor on the sphenoid wing and tumor spread (2). Bony

tumor growth may involve the optic canal, superior orbital fissure, roof of the orbit and anterior clinoid process. Lateral third tumors commonly present with proptosis and medially situated tumors are more likely to present with visual disturbances due to the close proximity to the optic nerve (2). Proptosis is the most common presenting symptom in sphenoid orbital meningioma ranging from 33-95% of cases and may occur in isolation (7, 19-21). Progressive proptosis may result in cosmetic deformity. Even if proptosis is not reported clinically it is further detected on CT scan with an average of 5.5mm at presentation (22). Proptosis is likely attributed to a number of causes including periorbital tumor invasion, intraorbital tumor spread, ophthalmic vein thrombosis and hyperostotic bony change of the sphenoid & orbital bones (7, 18, 23). Visual loss, occurring in 40-60% of cases, is related to tumor infiltration into the optic canal and compression of the optic nerve resulting in a compressive optic neuropathy rather than intraorbital tumor spread (23). Patients may also present with diplopia, ptosis and orbital pain, all of which may impact quality of life (18).

The management of sphenoid wing meningioma includes observation, surgery and radiation therapy (10). It has been reported that small incidental tumors that are asymptomatic may be observed due to their slow growing benign nature. Saeed *et al*, reported that 35% of patients with sphenoid orbital meningioma did not have further deterioration in vision with active observation (7). The disadvantages of conservative management are that tumor progression is unpredictable and age of presentation (4th decade) allows time for further tumor growth. Due to the advancement in imaging and surgical expertise surgical excision has become the mainstay of treatment (10).

In patients undergoing surgery for sphenoid meningioma the standard of care has been complete tumor resection (10). However due to the nature of tumor spread and close

proximity to the optic nerve, superior orbital fissure, cavernous sinus and dura, complete resection is not always possible and is often associated with significant morbidity (10). Champagne et al, showed that gross total resection is less likely with large meningiomas of more than 6cm and involving major cerebral blood vessels. The study showed that total resection via an open approach was only achieved in a minority of cases and was associated with a higher recurrence rate (24). Therefore, the paradigm of meningioma surgical resection has evolved with time due to the understanding of the biology of the tumor. Although benign, they are locally invasive into surrounding bone and dura. Thus, complete surgical resection is challenging, associated with an increased risk of post-operative complications, high residual tumor and recurrence rates post-surgery (25). Tumors that partly encase or invade multiple cerebral vessels are not resectable and have an increased risk of postoperative cerebrovascular accident (24). In addition, tumors that invade the superior orbital fissure (SOF) or cavernous sinus are treated via subtotal resection due to the high risk of ophthalmalgia (26). Therefore, the aim of treatment is to address the symptoms, minimize the risk of morbidity and attain acceptable functional and cosmetic outcomes (26). The Simpson grading system is typically used as the standard for grading tumor resection (27). This grading system is used to predict the recurrence rates as it correlates directly with the extent of the tumor resection (27). Grades I to V range from gross total resection (I) to simple decompression (V). The rates of recurrence for grades I, II, III, IV are 9%, 16%, 29% and 39% respectively (27).

Magnetic resonance imaging is used to assess sphenoid wing meningiomas prior to treatment to determine the extent of the tumour and the degree of attachment to surrounding brain parenchyma (2). CT scan may be used to assess the degree of hyperostotic bone and aid in

pre-operative planning (9). Standard open surgical approaches include variations of the frontotemporal (pterional) approach, lateral orbitotomy and open extradural optic nerve decompression followed by orbital reconstruction using autologous split calvarial bone grafts, titanium mesh or non-metallic orbital prostheses (4, 21). Open craniotomy has been shown to improve proptosis in up to 96% of cases and is dependent on the extent of tumor resection (26). Freeman *et al* showed a reduction in proptosis in 86% of cases (26). Scarone *et al*, reported an initial improvement in proptosis in 90% of cases, however over time there was a worsening of proptosis in 50% of cases (22). Shrivastava *et al*, reported a remarkable reduction in proptosis in a large number of patients. Nevertheless visual acuity only improved in 28% of patients and remained unchanged in 72% of cases (21). Reports of improvement in vision in the literature are varied i.e. from 21–74% improvement. Although there is a lack of objectively reported data (26). Postoperative resolution of ophthalmoplegia has been reported in 68% of cases in a series of 25 patients (21). However open surgical approaches are associated with significant morbidity, new onset cranial nerve neuropathy and a recurrence rate of up to 10% (4). Major complications reported include CSF leak, epilepsy, trigeminal neuralgia & new onset ophthalmoplegia (28).

Gross total resection may not always be possible due to the intimate anatomical relationship to underlying neurovascular structures necessitating subtotal resection (2). It is interesting to note that tumor recurrence has been shown to be unlikely in cases where subtotal resection has been performed despite the presence of an aggressive histological tumor grade and in the absence of additional therapy (2). This has led to the hypothesis that it is possible that tumor remnants may remain dormant and cease to grow. Nonetheless, further research is necessary to determine the key factors and molecular mechanisms involved in the process (2). It has

been demonstrated that adequate control, defined as an 80% control rate over a period of 8 years post-operatively, can be achieved of residual tumor using adjuvant radiotherapy or radiosurgery, supporting the efficacy of a more conservative subtotal resection (2). Adjuvant radiotherapy for the treatment of meningioma has shown to reduce disease progression. Radiation therapy has been used to treat residual meningioma post subtotal resection where vital neurovascular structures are intimately involved. There is currently no consensus on the timing of adjuvant radiotherapy (26, 29). Some authors advocate immediate post-operative radiation therapy and have shown to improve progression free survival compared to patients who did not receive post-operative radiotherapy (29). Others promote a conservative approach and commence radiation when recurrence is evident (26).

In 2010 Moe *et al*, popularized the use of transorbital neuroendoscopic surgery (TONES). This approach allows for multiportal endoscopic access around the eye to access skull base pathology i.e. lateral based tumours, repair of CSF leak and optic nerve decompression (30). Using this approach, a novel minimally invasive endoscopic surgical approach for sphenoid wing meningiomas has recently been described and shown to improve visual acuity and reduce proptosis (31, 32). Vision improved with a 2.7 line increase on Snellen chart and proptosis was reduced on average by 3.5mm at 6 weeks postoperatively (32). The above procedure addresses the most common symptoms namely, proptosis, visual loss and pain. Proptosis is addressed by using an extended superior eyelid approach to access the lateral tumor component and to remove hyperostotic bone. Furthermore, stabilization of vision is achieved by early decompression of the optic canal via a medial optic canal decompression. The surgery involves a combined method utilizing both an endo-orbital as well as an endonasal transsphenoidal approach (31, 32). Recently Dallan *et al*, reported the safety and

feasibility of using an endoscopic transorbital approach for the treatment of sphenoid-orbital meningioma (25).

Although transorbital endoscopic resection of sphenoid wing meningioma have shown promising results to improve vision and reduce proptosis, there is a lack of published data on the long-term outcomes. Therefore, the aim of this study was to retrospectively determine the long-term outcomes of vision and proptosis at one year, using an endoscopic transorbital approach in patients routinely undergoing subtotal endoscopic resection of sphenoid wing meningioma and to describe the surgical approach.

References

1. Inamura A, Ideguchi M, Sadahiro H, Suzuki M. Sphenoid ridge meningioma with increased intracranial pressure caused by venous congestion. *Acta Neurochir (Wien)*. 2012;154(10):1945-6.
2. Sughrue ME, Rutkowski MJ, Chen CJ, Shangari G, Kane AJ, Parsa AT, et al. Modern surgical outcomes following surgery for sphenoid wing meningiomas. *J Neurosurg*. 2013;119(1):86-93.
3. Luetjens G, Krauss JK, Brandis A, Nakamura M. Bilateral sphenoorbital hyperostotic meningiomas with proptosis and visual impairment: a therapeutic challenge. Report of three patients and review of the literature. *Clin Neurol Neurosurg*. 2011;113(10):859-63.
4. Honig S, Trantakis C, Frerich B, Sterker I, Schober R, Meixensberger J. Sphenoid-orbital meningiomas: outcome after microsurgical treatment: a clinical review of 30 cases. *Neurol Res*. 2010;32(3):314-25.
5. Fohanno D, Bitar A. Sphenoidal ridge meningioma. *Adv Tech Stand Neurosurg*. 1986;14:137-74.
6. Simas NM, Farias JP. Sphenoid Wing en plaque meningiomas: Surgical results and recurrence rates. *Surg Neurol Int*. 2013;4:86.
7. Saeed P, van Furth WR, Tanck M, Kooremans F, Freling N, Streekstra GI, et al. Natural history of sphenoid-orbital meningiomas. *Acta Neurochir (Wien)*. 2011;153(2):395-402.
8. Chaichana KL, Jackson C, Patel A, Miller NR, Subramanian P, Lim M, et al. Predictors of visual outcome following surgical resection of medial sphenoid wing meningiomas. *J Neurol Surg B Skull Base*. 2012;73(5):321-6.

9. Bikmaz K, Mrak R, Al-Mefty O. Management of bone-invasive, hyperostotic sphenoid wing meningiomas. *J Neurosurg.* 2007;107(5):905-12.
10. Rogers L, Barani I, Chamberlain M, Kaley TJ, McDermott M, Raizer J, et al. Meningiomas: knowledge base, treatment outcomes, and uncertainties. A RANO review. *J Neurosurg.* 2015;122(1):4-23.
11. Evans DG, Huson SM, Donnai D, Neary W, Blair V, Newton V, et al. A clinical study of type 2 neurofibromatosis. *Q J Med.* 1992;84(304):603-18.
12. Umansky F, Shoshan Y, Rosenthal G, Fraifeld S, Spektor S. Radiation-induced meningioma. *Neurosurg Focus.* 2008;24(5):E7.
13. Carroll RS, Zhang J, Dashner K, Sar M, Wilson EM, Black PM. Androgen receptor expression in meningiomas. *J Neurosurg.* 1995;82(3):453-60.
14. Wiemels J, Wrensch M, Claus EB. Epidemiology and etiology of meningioma. *J Neurooncol.* 2010;99(3):307-14.
15. Jhawar BS, Fuchs CS, Colditz GA, Stampfer MJ. Sex steroid hormone exposures and risk for meningioma. *J Neurosurg.* 2003;99(5):848-53.
16. Hsu DW, Efirid JT, Hedley-Whyte ET. Progesterone and estrogen receptors in meningiomas: prognostic considerations. *J Neurosurg.* 1997;86(1):113-20.
17. Cossu G, Levivier M, Daniel RT, Messerer M. The Role of Mifepristone in Meningiomas Management: A Systematic Review of the Literature. *Biomed Res Int.* 2015;2015:267831.
18. Boari N, Gagliardi F, Spina A, Bailo M, Franzin A, Mortini P. Management of sphenoid-orbital meningiomas: clinical outcome in a consecutive series of 40 patients. *Br J Neurosurg.* 2013;27(1):84-90.
19. Roser F, Nakamura M, Jacobs C, Vorkapic P, Samii M. Sphenoid wing meningiomas with osseous involvement. *Surg Neurol.* 2005;64(1):37-43; discussion
20. Schick U, Bleyen J, Bani A, Hassler W. Management of meningiomas en plaque of the sphenoid wing. *J Neurosurg.* 2006;104(2):208-14.
21. Shrivastava RK, Sen C, Costantino PD, Della Rocca R. Sphenoorbital meningiomas: surgical limitations and lessons learned in their long-term management. *J Neurosurg.* 2005;103(3):491-7.
22. Scarone P, Leclercq D, Heran F, Robert G. Long-term results with exophthalmos in a surgical series of 30 sphenoorbital meningiomas. Clinical article. *J Neurosurg.* 2009;111(5):1069-77.
23. Mariniello G, Bonavolonta G, Tranfa F, Maiuri F. Management of the optic canal invasion and visual outcome in sphenoid-orbital meningiomas. *Clin Neurol Neurosurg.* 2013;115(9):1615-20.
24. Champagne PO, Lemoine E, Bojanowski MW. Surgical management of giant sphenoid wing meningiomas encasing major cerebral arteries. *Neurosurg Focus.* 2018;44(4):E12.
25. Dallan I, Sellari-Franceschini S, Turri-Zanoni M, de Notaris M, Fiacchini G, Fiorini FR, et al. Endoscopic Transorbital Superior Eyelid Approach for the Management of Selected Sphenoid-orbital Meningiomas: Preliminary Experience. *Oper Neurosurg (Hagerstown).* 2018;14(3):243-51.
26. Freeman JL, Davern MS, Oushy S, Sillau S, Ormond DR, Youssef AS, et al. Sphenoid-Orbital Meningiomas: A 16-Year Surgical Experience. *World Neurosurg.* 2017;99:369-80.
27. Oya S, Kawai K, Nakatomi H, Saito N. Significance of Simpson grading system in modern meningioma surgery: integration of the grade with MIB-1 labeling index

- as a key to predict the recurrence of WHO Grade I meningiomas. *J Neurosurg.* 2012;117(1):121-8.
28. Essa AA, Hamdan AR. Sphenoid meningioma en plaque with proptosis: Surgical excision, reconstruction and outcome. *Clin Neurol Neurosurg.* 2018;167:147-56.
29. Aboukais R, Baroncini M, Zairi F, Reyns N, Lejeune JP. Early postoperative radiotherapy improves progression free survival in patients with grade 2 meningioma. *Acta Neurochir (Wien).* 2013;155(8):1385-90; discussion 90.
30. Moe KS, Bergeron CM, Ellenbogen RG. Transorbital neuroendoscopic surgery. *Neurosurgery.* 2010;67(3 Suppl Operative):ons16-28.
31. Lubbe DM, H; Seayaroyh, K.; Goncalves, N; Fagan, J. . Transorbital Endoscopic Surgery Current Otorhinolaryngological Reports 2019;7(2):173-80.
32. Lubbe D, Mustak H, Taylor A, Fagan J. Minimally invasive endo-orbital approach to sphenoid wing meningiomas improves visual outcomes - our experience with the first seven cases. *Clin Otolaryngol.* 2017;42(4):876-80.

Chapter 2 (Publication Manuscript)

Transorbital Endoscopic Surgery for Sphenoid Wing Meningioma: Long-term

Outcomes & Surgical Technique

Goncalves N* MBBCh, FCORL (SA), Lubbe, DE* MBChB, FCORL (SA)

**Division of Otolaryngology, Groote Schuur Hospital, Faculty of Health Science, University of Cape Town.*

drnicgoncalves@gmail.com

Abstract

Sphenoid wing meningiomas are benign tumors that result in proptosis, visual impairment and pain. Traditional open surgical approaches are associated with significant morbidity. Transorbital endoscopic surgery has been developed as a minimally invasive approach to gain access to these tumors and address the main presenting symptoms. The aim of the study was to assess long term vision and proptosis outcomes in patients undergoing a transorbital endoscopic resection of sphenoid wing meningioma using a combined endonasal, precaruncular and extended superior eyelid approach and to describe the surgical approach.

Materials & Methods

A retrospective chart review was conducted in 21 patients with lateral sphenoid wing meningioma at Groote Schuur Hospital & Cape Town Mediclinic from 2015–2019. All patients had undergone a transorbital endoscopic subtotal resection (Simpson grade II – IV) by the same surgical team. Vision was assessed using a Snellen chart and proptosis measured in mm using a Hertel exophthalmometer by an ophthalmologist. Measurements were taken at 6 weeks, 6 months and at 1 year postoperatively and compared to pre-operative values. Patients were categorized according to the WHO classification of vision into group A (blind), group B (low vision) & group C (normal vision) according to their pre-operative visual acuity. Non-parametric statistical tests employing the Wilcoxon Signed-Ranks Test were used for analysis. Statistical significance was determined by a confidence interval of 0.95, $p = < 0.05$ for both visual acuity (converted to LogMar) and proptosis in mm.

Results

A total of 21 patient charts were reviewed. The mean age of presentation was 48.8 years (range 34-79 years), and the majority of patients were female (20/21 = 95%). The most common presenting complaints were loss of vision (100%), proptosis (95%) and headache (76%). Pre-operative visual results were as follows: 10 (48%) in group A (blind), 4 (19%) in group B (low vision) and 7 (33%) in group C (normal vision). In group A, 6 (60%) remained unchanged, 2 (20%) deteriorated & 1 (10%) improved. In group B, 3 (75%) improved, and 1 (25%) remained stable. In group C, 5 (71%) improved and 2 (29%) remained stable.

Vision in groups B & C showed no deterioration. Patients in group A showed no benefit from optic nerve decompression. Vision in groups B & C showed a statistically significant improvement at 6 weeks [95% CI] ($p = 0.021$). This trend extended to long term follow up at 6 months [95% CI] ($p = 0.021$) and 1 year [95% CI] ($p = 0.0054$) postoperatively.

Proptosis initially

decreased, proving statistical significance at 6 weeks [95% CI] ($p = 0.0054$) postoperatively. The decrease at 6 months ($p = 0.08$) was not statistically significant and trended towards an increase in proptosis by 1 year ($p = 0.78$) postoperatively. The mean hospital stay was 2.7 days (range 2 – 4 days). The majority of tumors were histologically classified as WHO grade I.

Conclusion

Endoscopic medial optic canal decompression prior to transorbital multiportal surgery for sphenoid wing meningioma stabilizes or improves visual acuity for at least 1 year. Lateral orbitotomy via a superior eyelid approach and subtotal tumor resection initially decreases proptosis, but in the long term, returns to its preoperative state by 1 year if the main tumor component is not addressed. The earlier that medial optic nerve decompression is performed and the better the preoperative visual acuity, the greater the likelihood of favorable long-term visual outcomes.

□ Keywords: transorbital; spheno-orbital; meningioma

Introduction

Sphenoid wing meningioma's are the most common tumor of the sphenoid wing. They account for 13-19% of all primary intracranial neoplasms (2, 4). Cushing and Eisenhardt were the first to describe the growth patterns of sphenoid wing meningioma and differentiated between the more common globoid and the rarer *en plaque* entities. En plaque tumors make up 2 -9% of all sphenoid wing meningiomas. They are also known as 'hyperostosing' or spheno-orbital meningioma and are characterized by a thin dural tumor component, which is

typically disproportionate to a significant bony hyperostosis of the lateral sphenoid wing (2, 6, 33). Although the exact nature of hyperostosis is unknown, it should be regarded as direct tumor invasion, which is evident by the presence of tumor cells within bony specimens (3, 4, 6). The tumor typically invades optic canal, orbit, SOF, cavernous sinus and intracranially (3). The location of the tumour and its spread determine the clinical presentation. The most common presenting symptom is proptosis, which is present in >90% of cases and may cause significant cosmetic deformity. Progressive proptosis is most likely due to the lateral hyperostosis of the sphenoid and orbital bone and invasion of the orbit and periorbita. Visual loss is the second most common presenting symptom resulting from a compressive optic neuropathy. Other symptoms include facial pain, headache, diplopia & ptosis, all of which negatively impact on quality of life (7, 21).

Traditional open surgical approaches include frontotemporal (pterional) approach, lateral orbitotomy and extradural optic nerve decompression (4, 21). Despite advancements in open microsurgical techniques sphenoidal meningiomas remain challenging to treat and are associated with significant morbidity and high recurrence rates. Complete surgical clearance is often not possible once tumor invades the SOF and cavernous sinus. Residual or recurrent tumor may be treated with adjuvant radiotherapy, although there is no current consensus on the timing of radiation (26, 34, 35).

Recently a novel minimally invasive endoscopic transorbital approaches have been described by the current surgical team to treat sphenoid wing meningioma. The endoscopic transorbital & combined endo-nasal approach aims to address the main symptoms of proptosis and visual loss. A medial optic nerve decompression is performed to relieve compressive optic neuropathy. The lateral tumour is removed by an extended superior eyelid approach which allows access to the orbital and intracranial tumor (31, 32) . The aim of the study was to

retrospectively determine the long-term outcomes of vision and proptosis in patients routinely undergoing an endoscopic transorbital resection of sphenoid wing meningioma and to provide a detailed description of the surgical technique used.

Rationalization for a multiportal approach to sphenoid wing meningiomas

A major advantage of this approach is the ability to stabilize and improve vision by performing a medial optic canal decompression prior to addressing the main intracranial and orbital tumor components (3).

Our hypothesis is that a medial optic nerve canal decompression allows for manipulation of the main tumor component during the second stage of the surgery, without the risk of compressive damage to the optic nerve, which may occur during traditional approaches and may cause worse visual outcomes. Removal of the medial sphenoid sinus tumor component is also only possible using an endonasal or precaruncular approach. The superior eyelid approach gives excellent and direct access to the superior and lateral hyperostotic orbital walls and orbit itself - structures that are often infiltrated by tumor. Other presenting symptoms such as proptosis and pain can therefore be addressed at the same time

by resecting the orbital component of the tumor and removing the lateral and superior walls of the orbit, up to temporalis muscle and anterior and middle fossa dura. The corridor thus created provides access to the intracranial component of the tumor. This multiportal approach potentially allows for resection of all components of the tumor during a single surgery with no brain retraction required and minimal collateral tissue damage while avoiding the need for reconstruction.

Step-wise surgical approach

1. Medial optic canal decompression (endonasal or multiportal precaruncular and endonasal)

Medial sphenoid wing meningiomas often involve the sphenoid sinus itself and a uni- or binostril approach can be used to resect this component. The binostril approach allows for four-handed surgery but requires a posterior septectomy as is typically done for transsphenoidal pituitary surgery. Using the precaruncular approach in combination with the above approach has some advantages. Firstly, these patients often have proptosis and with removal of the posterior lamina papyracea, periorbital fascia can herniate into the ethmoid cavity, obscuring good visualization of the optic canal. The precaruncular approach allows for a ribbon (dural) retractor to be inserted through this portal to protect the orbit and make visualization of the bony canal easier (Figure 1a and 1b). A 2nd advantage is the slight difference in angulation obtained, allowing for the endoscope and instruments to be manipulated and to converge at the target area. It is convenient to keep the endoscope and orbital retractor within the precaruncular portal while powered instruments are used at the target area.

2. Resection of superior and lateral hyperostotic orbital wall bone through an extended superior eyelid approach

Sphenoid wing meningiomas often involve the superior and lateral orbital walls and optic canal, with tumor directly infiltrating bone, causing bony hyperostosis leading to compression of the orbital apex and optic canal (Figure 2). The superior portal is accessed through an extended superior eyelid approach, using the same crease line as for blepharoplasty surgery (Figure 3). It is our opinion that it is best to use this incision rather than a retrocanthal or lateral canthotomy incision, since sparing of the lateral canthus allows

for wider surgical access, quicker healing and less patient discomfort. Crucial steps need to be followed to avoid post-operative sequelae such as ptosis and dystopia (36, 37).

- Use a natural upper eyelid crease line as for blepharoplasty surgery.
- Dissect through skin and orbicularis oculi muscle only and remain just deep to the orbicularis muscle until the bony orbital roof is reached. Remain superficial to orbital septum and avoid exposing orbital fat.
- Once deep to the orbicularis oculi muscle, dissection starts at the lateral aspect of the incision, going directly onto bone just lateral to the lateral orbital rim (Figure 4).
- Dissection is initiated at the lateral aspect of the orbit, using scissors to dissect in a subperiosteal plane, moving from the lateral orbital rim superiorly, dissecting tissue above the superior orbital rim to avoid damage to the levator muscle (Figure 5). This technique allows for quick access to the superior orbital rim. The limit of the dissection is usually the supra-orbital nerve although this nerve can be mobilized if required.
- The orbital periosteum is elevated in a lateral-to-medial fashion starting at the lateral orbital rim, thereby ‘rolling’ the periosteum over the orbital rim, keeping the ligamentous attachments to Whitnall’s tubercle attached to the periosteum. The periosteum is resutured at the end of the procedure to prevent dystopia due to lateral canthal tendon displacement.
- Deep within the orbital cavity, periosteum can easily be elevated off the lateral orbital wall to firstly identify a recurrent branch of the middle meningeal artery (Figure 6 & 7). This artery is an important landmark for the SOF. The limit of dissection along the lateral wall is the SOF, found 1cm posterior to this artery (Figure 8). It is important not to injure the structures entering the SOF and to avoid excessive traction,

especially in patients who have no neurological fallout. Excessive tissue retraction could cause a superior orbital fissure syndrome.

- Superiorly, the lacrimal gland is protected by the periorbital fascia that covers it and will not be damaged if dissection remains in the subperiosteal plane. Once the gland is elevated out of its fossa, this bony area can be drilled away to provide wider access, the so called 'lacrimal keyhole' area (Figure 9). This is a good space to rest the endoscope during surgery.
- The superior orbital wall can now be resected using a high speed drill - the extent of resection depending on bony tumor involvement. The anterior cranial fossa dura is exposed from the frontal sinus to the orbital apex if needed. No reconstruction is required and any dural pulsations felt should settle within 2 weeks.
- The inferior limit of dissection is the inferior orbital fissure (IOF). The amount of bone requiring resection depends on the extent of the hyperostosis. The area of bone between the SOF and the IOF is called the orbital door jamb. It is important to resect all this bone until the temporalis muscle is seen anterolaterally, the middle cranial fossa posterolaterally and the anterior cranial fossa dura superiorly (Figure 10). The entire lateral orbital wall therefore can be resected, leaving 5mm of orbital rim intact laterally for cosmetic purposes.

3. Resection of the orbital component through the lateral transorbital portal

It can initially be difficult to differentiate between orbital tumor and orbital fat, muscle and fibrotic tissue. It is relatively easy to resect the periorbital fascia up to the SOF but if patients have no neurological fallout, it is important to preserve the neurovascular structures to

prevent significant complications such as diplopia related to injury to cranial nerves III, IV or VI. More research is needed with the use of ultrasound and nerve monitoring to assist with achieving more complete resection of the orbital component.

4. Resection of the intracranial component through the lateral orbital portal

A wide surgical corridor is created once the lateral hyperostotic bone has been drilled away, allowing the intracranial component to be resected using either an endoscope or microscope (Figure 10). Standard neurosurgical principles apply with regards to the extent of resection, preservation of important neurovascular structures and repair of the ensuing cerebrospinal fluid (CSF) leak using fat, fascia or synthetic materials. The authors do not use any sealants within the orbit. The lateral orbital wall does not require reconstruction as the orbital rim is left intact and the aim in most patients is a reduction in proptosis. Access is gained to the anterior and lateral aspects of the temporal lobe.

Currently there is a lack of published data in the English literature regarding the level of reduction in proptosis, visual improvement and gross total resection achieved in patients that have undergone the above procedure for sphenoid wing meningiomas (25).

This study retrospectively determined the extent of reduction in proptosis as well as the improvement in visual outcomes in patients routinely undergoing a minimally invasive endoscopic transorbital approach for the treatment of sphenoid wing meningiomas. Most of the patients underwent initial multiportal surgery in an attempt to salvage vision and reduce proptosis while awaiting a craniotomy as definitive surgery for resection of the intracranial component.

Methods

Ethics approval was obtained from the Human Ethic Committee, University of Cape Town (HREC 345/2017). A retrospective folder review was conducted in 21 patients who had undergone transorbital endoscopic resection for sphenoid wing meningioma at Groote Schuur Hospital & Cape Town Mediclinic from 2015–2019. All patients were operated on by the same multidisciplinary surgical team which included otolaryngology, ophthalmology and neurosurgery. All patients had preoperative CT and MRI scans. The procedure included a combined endonasal and lateral orbitotomy using a superior eyelid approach.

The following data was collected: age, sex, presenting symptoms, comorbidities, history of previous radiation or craniotomy. Visual acuity using a Snellen Chart, and proptosis measurements using a Hertel exophthalmometer were recorded by ophthalmology and were recorded pre-operatively, at 6 weeks, 6 months and 1 year postoperatively. Patients were categorized according to WHO classification of vision into “blind”, “low vision” and “normal vision”. Tumor specimens were histopathologically analyzed.

Statistical Analysis

Nonparametric test analysis (performed in R) were used. The Wilcoxon Signed-Ranks Test was employed to evaluate visual acuity (Snellen fractions converted to logMar values) and proptosis in mm. Pre-operative values were compared to values obtained at 6 weeks, 6 months and 1 year postoperatively. Patients who were in the blind category preoperatively (group A) were excluded from analysis. Only patients who were in the category of low or

normal vision (group B & C) were included in the analysis. A *p-value* of <0.05 was considered to be statistically significant.

Results

Patient & Clinical Data

A total of 21 patients had undergone transorbital endoscopic tumor resection for sphenoid wing meningioma. A subtotal resection was performed in all cases (Simpson grade II – IV). The mean age at initial presentation was 48.8 years (range 34 – 79 years). Of these 20 (95%) patients were female and 1 (5%) was male. Of the 21 patients, 6 (28%) had hypertension, 4 (19%) had type 2 diabetes mellitus and 3 (14%) had asthma.

The most common presenting symptom was decreased visual acuity reported by 21 patients (100%), followed by proptosis & headache i.e. 20 (95%), 16 (76%) patients respectively (see Table 1 for summary of symptoms). The mean duration of symptoms prior to presentation was 9 months (range: 3 – 24 months). In 12 (57%) patients, tumors were located on the left side and in 9 (43%) patients they occurred on the right. Of the 21-patient cohort, 3 (14%) had had a previous craniotomy which included pterional and lateral orbitotomy approaches, and 2 (10%) had received previous radiation therapy. All patients had pre- and post-operative CT scans. All patients had lateral *en plaque* sphenoid wing meningiomas, with evidence of hyperostosis. CT scan identified 6 (29%) with intracranial extension, 11 (52%) with intraorbital extension and 1 (5%) with diffuse meningiomatosis. One resection was complicated by superior orbital fissure syndrome postoperatively which resolved

spontaneously. This patient had had a previous craniotomy and radiation therapy. There was one mortality unrelated to the surgery. There were no other major surgical complications and the mean hospital stay was 2.7 days (range 2-4).

Visual acuity

Improvement in visual acuity was defined as vision that remained the same or a single line increase on the Snellen chart. The average line improvement of vision was 1.5 at 6 weeks, 0.8 at 6 months and 1.4 at 1 year postoperatively (Table 2). Patients were placed into categories according to the WHO classification for vision, which was determined by their preoperative visual acuity (Tables 2 & 3). In Group A (blind), 6 (60%) patients remained unchanged, 1 (10%) improved and 2 (20%) had further decline in vision by 1 year postoperatively. In Group B (low vision), 3 (75%) had improvement in vision and 1 (25%) remained stable. In Group C, 5 (71%) of patients had improvement in vision and 2 (29%) remained stable. No patients in group B & C experienced deterioration in vision.

Proptosis

Twenty (95%) of patients presented with proptosis. The mean proptosis preoperatively was 23.8mm (range 18-28). The mean proptosis at 6 weeks, 6 months and 1 year were 21.3mm; 21.1mm and 23.8mm. Even though the average improvement in proptosis was 2.4mm at 6 weeks, proptosis trended towards preoperative values at 1 year.

Statistical analysis

The nonparametric data model shows a statistically significant improvement in visual acuity at 6 weeks [95% CI] ($p = 0.021$). This trend extends to long term follow-up at 6 months [95% CI] ($p = 0.021$) and 1 year [95% CI] ($p = 0.0054$) postoperatively. Proptosis was shown to decrease initially proving statistical significance at 6 weeks [95% CI] ($p = 0.0054$) postoperatively. The decrease at 6 months ($p = 0.08$) was not statistically significant and trended towards an increase in proptosis by 1 year ($p = 0.78$) postoperatively.

Histology

Nineteen tumors (95%) were WHO grade I 19 and 1 (5%) was WHO grade II. Histological examination of hyperostotic bone showed tumor infiltration in 14 (70%) patients. Biopsies of periorbita were positive for meningioma in 6 (28%) patients.

Discussion

Sphenoid wing meningiomas are complex and challenging to manage. Traditional open neurosurgical approaches have aimed for gross total resection and are associated with significant morbidity. Open surgical approaches result in brain retraction & manipulation, which increases the risk of new onset cranial nerve palsy, epilepsy, stroke and mortality (6,24). The open approach may inadequately address the primary symptoms of proptosis, decreased visual acuity & pain.

Thus a move to subtotal tumor resection has evolved due to the benign nature of the disease and the risk of damage to underlying vital neurovascular structures (8).

The advent of multiportal transorbital pathways introduced by Moe et al, (2010) has permitted a minimally invasive approach to resect sphenoid wing meningiomas (30). A superior eyelid approach utilizing the lateral corridor to resect the lateral hyperostotic bone has been reported (31, 32).

Since the popularization of transorbital neuroendoscopic surgery (TONES), there has been limited literature comparing open and extended endoscopic or transorbital surgical approaches. Bander et al, in 2018 compared endoscopic endonasal & transcranial approaches to meningiomas of the tuberculum sellae & planum sphenoidale. The study demonstrated that endoscopic resection resulted in statistically significant improvement or stabilization of vision compared to open craniotomy. In addition, there was less brain trauma and seizures with the endoscopic approach (42). Park et al, 2020 retrospectively compared an endoscopic transorbital approach and an open mini-pterional approach for sphenoid wing meningioma. A total of 24 patients were reviewed, 11 patients had undergone tumor resection via an endoscopic approach and 13 via open approach. Results showed that there was no difference in post-operative morbidity. However, the endoscopic transorbital approach showed significantly reduced intraoperative blood loss, reduced surgical time & shorter hospitalization. There was no difference in tumor regrowth or recurrence rate between the two approaches. It was concluded the endoscopic approach provided certain advantages over the open approach i.e. allowing for bony decompression, early tumor devascularization and direct tumor access without the need for brain retraction (43). Limitations of this study

included the lack of comment on outcomes with regards to visual acuity, proptosis, pain and cranial nerve fallout.

Despite the advantages of the endoscopic approach, there remains a role for open craniotomy, combined or staged procedures. Open craniotomy may be considered in patients with SWM with a large intracranial tumor component and patients with complete encasement of vital neurovascular structures. Park et al, 2020 proposed the following indications for an endoscopic transorbital approach for SWM i.e. tumor of any size, hyperostosis, orbital tumor invasion, incomplete encasement of cranial nerve & vital vasculature and patients with aesthetic & functional concerns (43). As neurosurgeons become more experienced with the TONES approach, indications will expand & limitations will be defined.

In the patients in this study, the goal of surgery was to address the presenting symptoms namely loss of vision and proptosis, while they were awaiting definitive neurosurgical management. In all cases a subtotal resection was performed (Simpson grade II – IV). Complete microscopic surgical clearance was not possible due to extensive dural involvement, and in most cases the dura was cauterized with bipolar.

It is well documented that meningiomas occur more commonly in females compared to males. In our study 95% of patients were female between the ages of 34 and 79 years. This correlates with other studies showing a similar demographic and reports that >90% of patients with sphenoorbital meningioma are female (4, 9, 10).

In the current study the most common presenting symptom was decline in vision (100%) followed by proptosis (95%). This differs from other studies that report a higher percentage

of proptosis as the most common symptom, and visual impairment ranging between 40 – 60% in lateral sphenoid wing tumors (7, 18, 23). Dallan et al reported proptosis to be the most common presenting symptom (100% of their cases) while 42.8% presented with

visual impairment (25). Our findings could be explained by the delayed presentation in South Africa, extended duration of symptoms, extensive disease and large number (52%) of patients with intraorbital tumor extension.

There was a statically significant improvement in visual acuity in groups B and C at all postoperative time intervals i.e. 6 weeks, 6 months and 1 year [95% CI] ($p = 0.0054$). If patients were category A or blind preoperatively, it was less likely that their vision would improve and their long-term outcomes were poor. Two category A patients had further deterioration in vision; 1 had diffuse meningiomatosis and the other WHO type II meningioma, which are both aggressive forms of the disease. It is possible that subsequent tumor growth had occurred post-resection which resulted in further decline in vision. In addition, patients in this group were older, had a longer duration of symptoms and evidence of optic nerve atrophy compared to groups B and C. One patient had improved vision postoperatively despite presenting with blindness. This patient was young (36 years), had a short duration of symptoms (3 months) and had no evidence of optic atrophy. These factors may have played a role in the ability of the optic nerve to recover from a compressive optic neuropathy following decompression.

In addition, it was noted in our study population that the poorer the preoperative vision the less likely vision would improve in the long term (Group A). The trend showed that the better the preoperative vision the more favorable the long-term vision outcomes, with most patients showing an improvement in visual acuity in group C. Additionally some patients showed a further improvement in vision between 6 weeks and 1 year, which would suggest a long-term

recovery in optic nerve function. Vision was also shown to stabilize in groups B and C with no further decline at 1 year. These findings were consistent with the literature (38).

In a systematic review and meta-analysis of visual outcomes following optic nerve decompression for chronic compressive optic neuropathy, it was reported that at least 60% of patients will show some improvement in vision. The factors that were statistically significant in predicting improvement were clinical factors i.e. absence of optic disc atrophy and small tumor size. Positive surgical factors included primary resection, a soft tumor consistency, a clear dissection plane, absence of tumor in the cavernous sinus and a complete tumor excision (38). Age and gender were not shown to have predictive value in determining visual outcomes. The duration of symptoms was shown to play a role in visual outcomes i.e. the longer the duration of symptoms the greater the chance of poor postoperative vision. Finally, preoperative vision status was noted to be of value to predict outcomes i.e. the worse the preoperative vision, the less likely vision will improve postoperatively. However if vision is on the poorer side preoperatively there is a small chance it may improve (38).

Shrivastava *et al* reported an improvement in visual acuity in only 28% and vision remained unchanged in 72% of cases when employing optic nerve decompression for sphenoid wing meningioma using an open surgical approach, (21). On review of the literature there is a wide range of improvement in visual outcomes in patients with sphenoid wing meningioma using an open craniotomy approach i.e. 28 – 70 % (9, 20, 39-41). Mariniello *et al* reported that vision improved in 50% of cases, remained the same in 36% and deteriorated in 14% of cases in 36 patients undergoing open optic nerve decompression via a supraorbital- pterional approach. Outcomes were thought to be predicted by extent of optic canal invasion, tumor

grade and Simpson grade of tumor resection. The intraorbital portion of the tumor is thought to be a less significant factor in visual outcomes. They therefore advocated for early optic nerve decompression (23).

There is less published data on visual outcomes using a transorbital endoscopic approach for sphenoid wing meningioma. Our surgical unit previously reported an average line increase of 2.7 in the Snellen chart and an average reduction in proptosis of 3.5 mm 6 weeks postoperatively (32). Almeida *et al*, reported 2 cases using an endoscopic transorbital technique via superior eyelid approach for sphenoid wing meningioma and showed an improvement in visual acuity and proptosis at 1 month postoperatively (33). Dallan *et al*, reported 14 cases of sphenoorbital meningioma treated via transorbital endoscopic and superior eyelid approach and demonstrated that the approach was feasible and safe. In 3 (21.4%) patients complete tumor resection was achieved. The tumor volume removed as measured by CT scan ranged between 55–100% (25).

Proptosis is caused by tumor infiltration of bone resulting in a hyperostotic reaction of the sphenoid wing. Hyperostosis displaces the globe from medially and by mass effect may stretch the optic nerve and has the potential to compromise vision (32, 39). Our results for proptosis were promising in the initial postoperative period with an average reduction of 2 mm which is statistically significant [95% CI] ($p = 0.0054$). However, it was noted that proptosis recurred by 1 year. This may be due to a number of factors i.e. subtotal tumor resection, growth of residual tumor and intraconal tumor involving the periorbita. Open craniotomy or lateral orbitotomy approaches have been shown to reduce proptosis. Scarone *et al* studied 30 patients with sphenoid wing meningiomas who had undergone open craniotomy

to remove hyperostotic bone. In their series proptosis improved in the short term (average 1 year) but in the long term (61 months) up to 50% of patients showed a worsening of proptosis despite Simpson grade I and II resections (22). Little has been published on the reduction in proptosis using the transorbital approach. Research carried out by our surgical unit demonstrated a reduction in proptosis in the early postoperative period of 3.5 mm on average (31).

Conclusions

This is the first report of long term outcomes of vision and proptosis using a transorbital endoscopic approach for the treatment of lateral sphenoid wing meningioma. Our results show that medial optic nerve decompression dramatically improves vision in patients who present with low to normal vision with minimal morbidity. This benefit is maintained for at least 1 year postoperatively. Patients with evidence of optic nerve atrophy and who are blind preoperatively did not benefit from optic nerve decompression. The earlier one performs optic nerve decompression the more favorable the long term vision outcomes. Proptosis was shown to improve postoperatively but recurred with time, returning to preoperative measurements by 1 year if a subtotal resection was performed. Of interest, vision remained stable or further improved despite an increase in proptosis over time. This supports the indication of optic nerve decompression as it buys time while awaiting definitive craniotomy or a more extensive resection using the transorbital route.

These results are valuable in selecting patients who would benefit from surgery and for preoperative counselling.

Based on our results we therefore recommend early medial optic nerve decompression to preserve or improve vision. It is however clear that these complex tumors require multidisciplinary teams for effective management as they may require multimodal treatment i.e. medial optic nerve decompression to improve vision, craniotomy to address lateral hyperostosis and postoperative radiation for residual disease.

Limitations & Future Research

We acknowledge that the retrospective nature and small sample size are limiting factors. These are however rare tumors, and this represents the largest sample of patients reported in the English literature. Future research is required to determine the role of progesterone in sphenoid wing meningioma. As technology and expertise advance, more likely total resection will become possible via a transorbital approach. A prospective trial comparing craniotomy and transorbital approach is needed.

Acknowledgements

Prof Allan Taylor, Department of Neurosurgery, Groote Schuur Hospital, Cape Town

Dr Hamzah Mustak, Division of Ophthalmology, Groote Schuur Hospital, Cape Town Mark

Webb and Duncan Brett for Statistical analysis, Research LampPost, Cape Town

References

1. Inamura A, Ideguchi M, Sadahiro H, Suzuki M. Sphenoid ridge meningioma with increased intracranial pressure caused by venous congestion. *Acta Neurochir (Wien)*. 2012;154(10):1945-6.
2. Sughrue ME, Rutkowski MJ, Chen CJ, Shangari G, Kane AJ, Parsa AT, et al. Modern surgical outcomes following surgery for sphenoid wing meningiomas. *J Neurosurg*. 2013;119(1):86-93.
3. Luetjens G, Krauss JK, Brandis A, Nakamura M. Bilateral sphenoorbital hyperostotic meningiomas with proptosis and visual impairment: a therapeutic challenge. Report of three patients and review of the literature. *Clin Neurol Neurosurg*. 2011;113(10):859-63.
4. Honig S, Trantakis C, Frerich B, Sterker I, Schober R, Meixensberger J. Sphenoorbital meningiomas: outcome after microsurgical treatment: a clinical review of 30 cases. *Neurol Res*. 2010;32(3):314-25.
5. Fohanno D, Bitar A. Sphenoidal ridge meningioma. *Adv Tech Stand Neurosurg*. 1986;14:137-74.
6. Simas NM, Farias JP. Sphenoid Wing en plaque meningiomas: Surgical results and recurrence rates. *Surg Neurol Int*. 2013;4:86.
7. Saeed P, van Furth WR, Tanck M, Kooremans F, Freling N, Streekstra GI, et al. Natural history of sphenoorbital meningiomas. *Acta Neurochir (Wien)*. 2011;153(2):395-402.
8. Chaichana KL, Jackson C, Patel A, Miller NR, Subramanian P, Lim M, et al. Predictors of visual outcome following surgical resection of medial sphenoid wing meningiomas. *J Neurol Surg B Skull Base*. 2012;73(5):321-6.
9. Bikmaz K, Mrak R, Al-Mefty O. Management of bone-invasive, hyperostotic sphenoid wing meningiomas. *J Neurosurg*. 2007;107(5):905-12.
10. Rogers L, Barani I, Chamberlain M, Kaley TJ, McDermott M, Raizer J, et al. Meningiomas: knowledge base, treatment outcomes, and uncertainties. A RANO review. *J Neurosurg*. 2015;122(1):4-23.
11. Evans DG, Huson SM, Donnai D, Neary W, Blair V, Newton V, et al. A clinical study of type 2 neurofibromatosis. *Q J Med*. 1992;84(304):603-18.
12. Umansky F, Shoshan Y, Rosenthal G, Fraifeld S, Spektor S. Radiation-induced meningioma. *Neurosurg Focus*. 2008;24(5):E7.
13. Carroll RS, Zhang J, Dashner K, Sar M, Wilson EM, Black PM. Androgen receptor expression in meningiomas. *J Neurosurg*. 1995;82(3):453-60.
14. Wiemels J, Wrensch M, Claus EB. Epidemiology and etiology of meningioma. *J Neurooncol*. 2010;99(3):307-14.
15. Jhawar BS, Fuchs CS, Colditz GA, Stampfer MJ. Sex steroid hormone exposures and risk for meningioma. *J Neurosurg*. 2003;99(5):848-53.
16. Hsu DW, Efird JT, Hedley-Whyte ET. Progesterone and estrogen receptors in meningiomas: prognostic considerations. *J Neurosurg*. 1997;86(1):113-20.
17. Cossu G, Levivier M, Daniel RT, Messerer M. The Role of Mifepristone in Meningiomas Management: A Systematic Review of the Literature. *Biomed Res Int*. 2015;2015:267831.

18. Boari N, Gagliardi F, Spina A, Bailo M, Franzin A, Mortini P. Management of sphenoid orbital en plaque meningiomas: clinical outcome in a consecutive series of 40 patients. *Br J Neurosurg.* 2013;27(1):84-90.
19. Roser F, Nakamura M, Jacobs C, Vorkapic P, Samii M. Sphenoid wing meningiomas with osseous involvement. *Surg Neurol.* 2005;64(1):37-43; discussion
20. Schick U, Bleyen J, Bani A, Hassler W. Management of meningiomas en plaque of the sphenoid wing. *J Neurosurg.* 2006;104(2):208-14.
21. Shrivastava RK, Sen C, Costantino PD, Della Rocca R. Sphenoorbital meningiomas: surgical limitations and lessons learned in their long-term management. *J Neurosurg.* 2005;103(3):491-7.
22. Scarone P, Leclercq D, Heran F, Robert G. Long-term results with exophthalmos in a surgical series of 30 sphenoorbital meningiomas. Clinical article. *J Neurosurg.* 2009;111(5):1069-77.
23. Mariniello G, Bonavolonta G, Tranfa F, Maiuri F. Management of the optic canal invasion and visual outcome in sphenoid orbital meningiomas. *Clin Neurol Neurosurg.* 2013;115(9):1615-20.
24. Champagne PO, Lemoine E, Bojanowski MW. Surgical management of giant sphenoid wing meningiomas encasing major cerebral arteries. *Neurosurg Focus.* 2018;44(4):E12.
25. Dallan I, Sellari-Franceschini S, Turri-Zanoni M, de Notaris M, Fiacchini G, Fiorini FR, et al. Endoscopic Transorbital Superior Eyelid Approach for the Management of Selected Sphenoid Orbital Meningiomas: Preliminary Experience. *Oper Neurosurg (Hagerstown).* 2018;14(3):243-51.
26. Freeman JL, Davern MS, Oushy S, Sillau S, Ormond DR, Youssef AS, et al. Sphenoid Orbital Meningiomas: A 16-Year Surgical Experience. *World Neurosurg.* 2017;99:369-80.
27. Oya S, Kawai K, Nakatomi H, Saito N. Significance of Simpson grading system in modern meningioma surgery: integration of the grade with MIB-1 labeling index as a key to predict the recurrence of WHO Grade I meningiomas. *J Neurosurg.* 2012;117(1):121-8.
28. Essa AA, Hamdan AR. Sphenoid meningioma en plaque with proptosis: Surgical excision, reconstruction and outcome. *Clin Neurol Neurosurg.* 2018;167:147-56.
29. Aboukais R, Baroncini M, Zairi F, Reyns N, Lejeune JP. Early postoperative radiotherapy improves progression free survival in patients with grade 2 meningioma. *Acta Neurochir (Wien).* 2013;155(8):1385-90; discussion 90.
30. Moe KS, Bergeron CM, Ellenbogen RG. Transorbital neuroendoscopic surgery. *Neurosurgery.* 2010;67(3 Suppl Operative):ons16-28.
31. Lubbe DM, H; Seayarooyh, K.; Goncalves, N; Fagan, J. . Transorbital Endoscopic Surgery Current Otorhinolaryngological Reports 2019;7(2):173-80.
32. Lubbe D, Mustak H, Taylor A, Fagan J. Minimally invasive endo-orbital approach to sphenoid wing meningiomas improves visual outcomes - our experience with the first seven cases. *Clin Otolaryngol.* 2017;42(4):876-80.
33. Almeida JP, Omay SB, Shetty SR, Chen YN, Ruiz-Trevino AS, Liang B, et al. Transorbital endoscopic eyelid approach for resection of sphenoid orbital meningiomas with predominant hyperostosis: report of 2 cases. *J Neurosurg.* 2018;128(6):1885-95.
34. Oya S, Sade B, Lee JH. Sphenoid orbital meningioma: surgical technique and outcome. *J Neurosurg.* 2011;114(5):1241-9.

35. Marcus H, Schwindack C, Santarius T, Mannion R, Kirollos R. Image-guided resection of sphenoid-orbital skull-base meningiomas with predominant intraosseous component. *Acta Neurochir (Wien)*. 2013;155(6):981-8.
36. Moe KSL, D. *Transorbital Neuroendoscopic Surgery of the Skull Base and Brain*: Thieme; 2019.
37. Lubbe DM, K.S. *Transorbital Approaches to the Sinuses, Skull Base, and Intracranial Space*: Thieme; 2019.
38. Carlson AP, Stippler M, Myers O. Predictive factors for vision recovery after optic nerve decompression for chronic compressive neuropathy: systematic review and meta-analysis. *J Neurol Surg B Skull Base*. 2013;74(1):20-38.
39. Ringel F, Cedzich C, Schramm J. Microsurgical technique and results of a series of 63 sphenoid-orbital meningiomas. *Neurosurgery*. 2007;60(4 Suppl 2):214-21; discussion 21-2.
40. Sandalcioglu IE, Gasser T, Mohr C, Stolke D, Wiedemayer H. Sphenoid-orbital meningiomas: interdisciplinary surgical approach, resectability and long-term results. *J Craniomaxillofac Surg*. 2005;33(4):260-6.
41. Cannon PS, Rutherford SA, Richardson PL, King A, Leatherbarrow B. The surgical management and outcomes for sphenoid-orbital meningiomas: a 7-year review of multidisciplinary practice. *Orbit*. 2009;28(6):371-6.
42. Bander ED, Singh H, Ogilvie CB, Cusic RC, Pisapia DJ, Tsiouris AJ, et al. Endoscopic endonasal versus transcranial approach to tuberculum sellae and planum sphenoidale meningiomas in a similar cohort of patients. *J Neurosurg*. 2018.
43. Park HH, Yoo J, Yun IS, Hong CK. Comparative Analysis of Endoscopic Transorbital Approach and Extended Mini-Pterional Approach for Sphenoid Wing Meningiomas with Osseous Involvement: Preliminary Surgical Results. *World Neurosurg*. 2020.

Tables & Figures

Visual impairment	21 (100%)
Proptosis	20 (95%)
Headache	16 (76%)
Facial Pain	15 (71%)
Diplopia	3 (14%)
Ptosis	1 (5%)
Blocked nose	1 (5%)
Epiphora	1 (5%)

Table 1: Presenting symptoms

Patient	VA Pre op	VA 6 weeks post op	VA 6 months post op	VA 1 year post op	Proptosis (mm) Pre op	Proptosis (mm) 6 weeks post op	Proptosis (mm) 6 months post op	Proptosis (mm) 1 year post op
1	NLP	NLP	NLP	NLP	28	28	26	28
2	CF	6/36	NLP	NLP	22	19	19	26
3	HM	6/9	HM	NLP	24	22	22	24
4	6/6	6/5	6/5	6/5	24	22	23	24
5	NLP	NLP	NLP	NLP	25	21	21	27
6	CF	6/12	6/12	6/12	23	21	21	21
7	6/12	6/9	6/9	6/6	24	23	20	20
8	6/18	6/18	6/18	6/18	18	18	18	18
9	NLP	NLP	NLP	D	24	21	21	D
10	6/12	6/12	6/12	6/12	23	20	21	23
11	6/12	6/9	6/9	6/6	22	19	18	22
12	NLP	NLP	NLP	NLP	29	27	18	29
13	6/12	6/9	6/9	6/9	24	22	22	23
14	6/18	6/18	6/18	6/5	21	20	20	25
15	6/36	6/24	6/18	6/18	22	20	19	20
16	NLP	NLP	NLP	NLP	28	26	26	28
17	HM	HM	HM	HM	24	20	19	22
18	6/9	6/6	6/6	6/6	22	19	20	22
19	CF	CF	CF	CF	25	21	21	23
20	6/60	6/24	6/24	6/24	28	22	23	28
21	6/12	6/12	6/12	6/12	21	18	27	22

NLP (No light perception); HM (Hand movements); CF (counting fingers)

Table 2: Visual acuity (VA) fractions according to Snellen Chart pre-operatively, 6 weeks, 6 months and at 1 year postoperatively. Proptosis (mm) measured by Hertel exophthalmometer preoperatively, and 6 weeks, 6-8 months and 1 year post-operatively.

Category	VA	Pre op	Number of Patients	
A Blind	NLP/HM/CF	10 (48%)	Unchanged /	6 (60%)
			Stabilized	
			Deteriorated	2 (20%)
			Improved	1 (10%)
B Low Vision	6/18 – 6/60	4 (19%)	Unchanged /	1 (25%)
			Stabilized	
			Deteriorated	0
			Improved	3 (75%)
C Normal vision	6/6 – 6/12	7 (33%)	Unchanged /	2 (29%)
			Stabilized	
			Deteriorated	0
			Improved	5 (71%)

Table 3: Category of VA preoperatively & number of patients in which vision had either remained unchanged or stabilized, improved or deteriorated by 1 year postoperatively

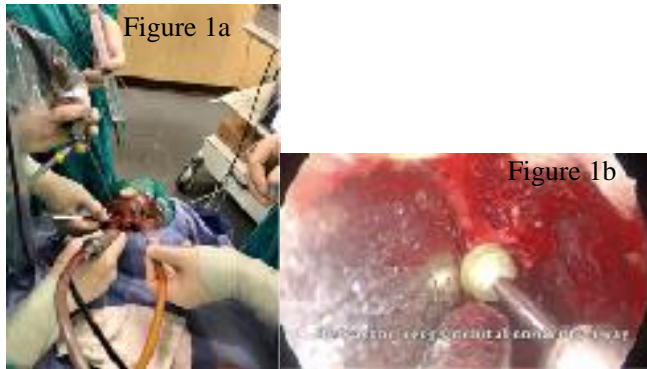

Figure 1a and 1b: Multiportal surgery (1a) using a precaruncular and unilateral endonasal approach to decompress the medial optic nerve canal (right eye). Instruments converge on the target area (1b)

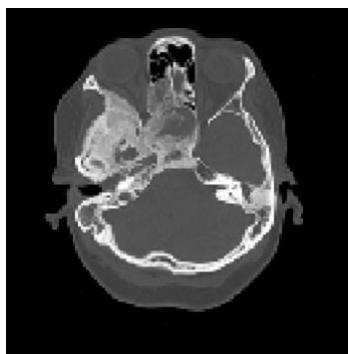


Figure 2: Sphenoid wing meningioma with bony hyperostosis causing compression at the optic canal and orbital apex

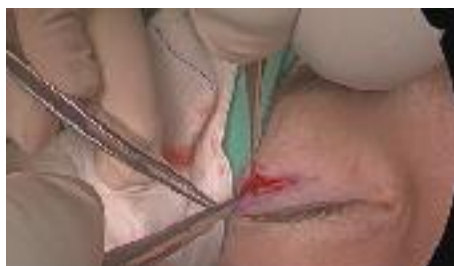

Figure 3: The superior eyelid incision is made as for blepharoplasty surgery using a natural crease line. The incision can be extended laterally to spare the lateral canthus of the eye

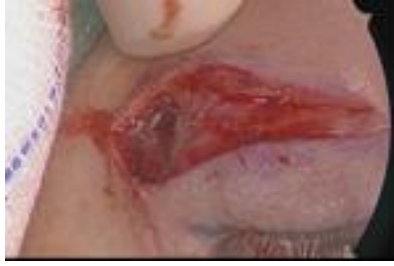

Figure 4: Dissection starts on the lateral orbital rim to prevent damage to the levator muscle

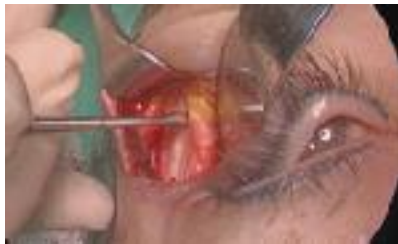
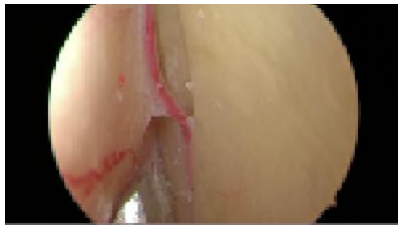
Figure 5: The periosteum is elevated off the orbital rim from laterally to medially around the orbital rim and then off the superior orbital rim



Figures 6: A recurrent branch of the middle meningeal artery in a cadaveric specimen (left eye)

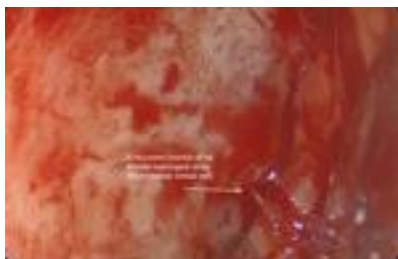

Figure 7: Recurrent branch of the middle meningeal artery (right eye), 1cm anterior to the SOF

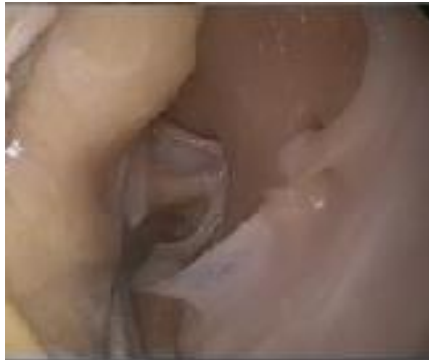

Figure 8: The SOF is 1cm posterior to the recurrent branch of the middle meningeal artery (left eye in cadaveric specimen)

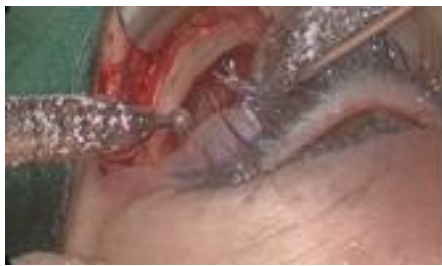

Figure 9: Lacrimal keyhole area is drilled away once the lacrimal gland is dissected out of its fossa

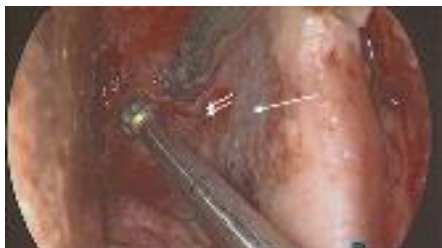

Figure 10: The lateral orbital corridor: the thick area of bone requiring removal to expose the temporalis muscle anterolaterally (arrow), the middle cranial fossa posterolaterally (double arrow) and the anterior cranial fossa dura superiorly (Left eye)

Appendix

1. Author Instructions: Journal of Neurological Surgery (JNLS Part B)

Author Instructions

Thank you for contributing to *Journal of Neurological Surgery Part B: Skull Base*. Please read the instructions carefully and observe all the directions given. Failure to do so may result in unnecessary delays in publishing your article.

SUBMISSION CHECKLIST

All manuscripts must be submitted at the following link:

AUTHOR INFORMATION

- All authors: full name, degrees, department, affiliation, e-mail address -
Corresponding author: mailing address, telephone number

MANUSCRIPT FILE

- Must be digital - hard copy submissions are not accepted

ABSTRACT AND KEYWORDS

- See the section Article Types for word limits

REFERENCES

- Cited sequentially in AMA style

FIGURES AND TABLES

- Cited sequentially and included in the main document

ART FILES

- Must be saved separately from the main document

□ □ **PERMISSIONS**

- Required if you plan to reproduce content from a published source or include a photograph of a patient
- Patient permission forms available at www.thieme.com/journal-authors

MANUSCRIPT FORMAT

General Guidelines

- · You must submit a digital copy of your manuscript. Hard copy submissions are not accepted.
- · Keep the format of your manuscript simple and clear. We will set your manuscript according to our style—do not try to “design” the document.
- · The manuscript, including the title page, abstract and keywords, text, references, figure captions, and tables should be typewritten, double-spaced in 12-point font with 1-inch margins all around and saved as one file.
- · Each figure should be saved as its own separate file. Do not embed figures within the manuscript file.

This requires special handling by Thieme’s Production Department.
- · Keep abbreviations to a minimum and be sure to explain all of them the first time they are used in the text.

- · The manuscripts should be written in American English.
- · The authors should use Système International (SI) measurements. For clarity, nonmetric equivalents may be included in parentheses following the SI measurements.
- · Use generic names for drugs. You may cite proprietary names in parentheses along with the name and location of the manufacturer.
- · Credit suppliers and manufacturers of equipment, drugs, and other brand-name material mentioned in the manuscript within parentheses, giving the company name and primary location.

Title Page

- · This journal adheres to a single-blinded peer-review policy. The title page should be included in the main document.
- · The title page should list the article title and the corresponding author's full name, degree, title, department, affiliation, mailing address, e-mail address, and telephone and fax numbers. It should also list the full name, degree, title, department, and affiliation of every co-author.

Abstract and Keywords

See the section Article Types for word limits.

The abstract should briefly outline the content of the article and any conclusions it may reach. It should contain the following elements: Objectives, Design, Setting, Participants, Main Outcome Measures, Results, Conclusions.

The keywords should be words a reader would be likely to use in searching for the content of the article.

Main Document

- · Please clearly distinguish the hierarchy of headings within the manuscript by using capital letters, underline, italic, and bold styles as necessary.
- · As needed, use italic, superscripts, subscripts, and boldface, but otherwise do not use multiple fonts and font sizes.
- · Do not insert page or section breaks except where noted in the Author Instructions.
- · Use hard returns (the Enter key) only at the end of a paragraph, not at the end of a line. Allow lines of text to break automatically in your word-processing software. Do not justify your text.
- · Use only one space, not two, after periods.
- · Create tables using the Table function in Microsoft Word.

Thieme Editing Services

Thieme offers a language editing service for manuscripts, abstracts and theses in partnership with Enago, a world-leading provider of author services to researchers around the world. Authors can choose from a range of editing services and get their manuscripts edited by Enago's professional medical editors. Authors that wish to use

this service will receive a 20% discount on all editing services. To find out more information or get a quote, please visit <https://www.enago.com/thieme>

Acknowledgments

The source of any financial support received and recognition of personal assistance for the work being published should be indicated at the end of the article, just before the Reference section, under the heading Acknowledgments.

Conflict of Interest

Please click <http://www.icmje.org/conflicts-of-interest> to download a Conflict of Interest form

References

References should be the most recent and pertinent literature available. It is essential that they are complete and thoroughly checked. If the reference information is incomplete, good online sites to search for full details are the National Library of Medicine: www.nlm.nih.gov; Books in Print: www.booksinprint.com; PubMed: www.ncbi.nlm.nih.gov/PubMed/; or individual publisher Web sites.

- ·References must be listed in AMA style, using Index Medicus journal title abbreviations.
- · References follow the article text. Insert a page break between the end of text and the start of references.
- · References must be cited sequentially (NOT alphabetically) in the text using superscript numbers.

- ·By way of exception to AMA style, do not italicize book titles or journal title abbreviations and do not put a period at the end of a reference.
- · List all author names, up to and including six names. For more than six authors, list the first three followed by et al.
- · References should be styled per the following examples:
 1. Citing a journal article:

Newburger JW, Takahashi M, Burns JC, et al. The treatment of Kawasaki syndrome with intravenous gamma-globulin. *N Engl J Med* 1986;315:341–347
 2. Citing a chapter in a book:

Toma H. Takayasu’s arteritis. In: Novick A, Scoble J, Hamilton G, eds. *Renal Vascular Disease*. Philadelphia: WB Saunders; 1995:47–62
 3. Citing a book:

Stryer L. *Biochemistry*. 2nd ed. San Francisco: WH Freeman; 1981:559–596
 4. Citing a thesis:

Stern I. Hemorrhagic Complications of Anticoagulant Therapy [Ph.D. dissertation]. Evanston, IL: Northwestern University; 1994
 5. Citing a government publication:

Food and Drug Administration. *Jin Bu Huan Herbal Tablets*. Rockville, MD: National Press Office; April 15, 1994. Talk Paper T94-22

6. Citing an online article:

Rosenthal S, Chen R, Hadler S. The safety of acellular pertussis vaccine vs whole-cell pertussis vaccine [abstract]. Arch Pediatr Adolesc Med [serial online]. 1996;150:457–460. Available at: http://www.ama-assn.org/sci-pubs/journals/archive/ajdc/vol_150/no_5/abstract/htm. Accessed November 10, 1996

7. Citing a symposium article:

Eisenberg J. Market forces and physician workforce reform: why they may not work. Paper presented at: Annual Meeting of the Association of American Medical Colleges; October 28, 1995; Washington, DC

Figure Captions

- · Figures include photographs or radiographs, drawings, graphs, bar charts, flow charts, and pathways, but NOT lists or tables.
- · Figures must be cited sequentially in the text. Number all figures (and corresponding figure captions) sequentially in the order they are cited in the text.
- · Figure captions should be written after the reference list. Insert a page break between the end of references and the start of figure captions.
- · Figure captions should include a description of the figure and/or each lettered part (A, B, etc.) and of any portions of the figure highlighted by arrows, arrowheads, asterisks, etc.
- · For a figure borrowed or adapted from another publication (used with permission), add a credit line in parentheses at the end of each figure legend. This credit line should be a complete bibliographic listing of the source publication (as a reference),

or other credit line as supplied by the copyright holder. For example (Reprinted with permission from Calfee DR, Wispelwey B. Brain abscess. *Semin Neurol* 2000;20:357.)

Tables

- · Data given in tables should be commented on but not repeated in the text. Be sure that lists or columns of related data are composed in a word-processing program like the rest of the text.
- · Do not intersperse tables in the text. Tables should appear after the figure captions. Insert a page break between the end of the figure captions and the start of the tables.
- · Tables must be double-spaced and numbered in the same sequence they are cited in the text. A short descriptive title should be provided for each table.
- · If a table contains artwork, supply the artwork separately as a digital file.
- · For tables borrowed or adapted from another publication (used with permission), add a credit line as the first footnote beneath each table. This credit line should be a complete bibliographical listing of the source publication (as a reference), or other credit line as supplied by the copyright holder. For example, “Reprinted with permission from Calfee DR, Wispelwey B. Brain abscess. *Semin Neurol* 2000;20:357.” (“Data from . . .” or “Adapted from . . .” may also be used, as appropriate.)
- · Other footnotes for tables should be indicated in the table using superscript letters in alphabetical order.

- · Any abbreviations used in the table should be explained at the end of the table in a footnote.

6

DIGITAL ARTWORK PREPARATION

General Guidelines

- · It is best to use Adobe Photoshop to create and save images, and Adobe Illustrator for line art and labels.
- · Do not submit art created in Microsoft Excel, Word, or PowerPoint. These files cannot be used by the typesetter.
- · Save each figure in a separate file.
- · Do not compress files.
- · All black-and-white and color artwork should be at a resolution of 300 dpi (dots per inch) in TIFF format.

Line art should be 1,200 dpi in EPS or TIFF format. Contact the Production Editor at Thieme if you are unsure of the final size.

- · It is preferable for figures to be cropped to their final size (approximately 3 1/2 inches for a single column and

up to 7 inches for a double column), or larger, and in the correct orientation. If art is submitted smaller and then has to be enlarged, its resolution (dpi) and clarity will decrease.

Note: Lower resolutions (less than 300 dpi) and JPEG format (.jpg extension) for grayscale and color artwork are strongly discouraged due to the poor quality they yield in printing, which requires 300 dpi resolution for sharp, clear, detailed images. JPEG format, by definition, is a lower resolution (compressed) format designed for quick upload on computer screens.

Black-and-White Art

- · Black-and-white artwork can be halftone (or grayscale) photographs, radiographs, drawings, line art, graphs, and flowcharts. Thieme will only accept digital artwork.
- · If possible, do not send color art for conversion to black-and-white. Do the conversion yourself so that you can check the results and confirm in advance that no critical details are lost or obscured by the change to black-and-white.
- · For best results, line art should be black on a white background. Lines and type should be clean and evenly dark. Avoid screens or cross-hatching, as they can darken or be uneven in printing and lead to unacceptable printing quality.

Color Art

- · Color illustrations are expensive to produce and usually cannot be accepted unless the author is willing to cover the additional production costs incurred. Please check with the Editor in Chief or Thieme for details. We will convert color illustrations to black-and-white unless we receive a letter from the author assuming responsibility for

the cost of printing color. Upon request, we will provide you with a cost estimate for the color printing.

- · All color artwork should be saved in CMYK, not RGB.

Art Labels

- · Arrows, asterisks, and arrowheads (or other markers) should be white in dark or black areas and black in light or white areas, and large in size. If not, these highlighting marks may become difficult to see when figures are reduced in size during the typesetting process.
- · Use 1-point (or thicker) rules and leader lines.
- · Capitalize the first word of each label and all proper nouns. Consider using all capitals if you need a higher level of labels.
- · Where there are alternate terms or spellings for a named structure, use the most common one and make sure it is consistent with what is used in the text.
- · Avoid using multiple fonts and font sizes for the labels; use only one or two sizes of a serif font.

As the author, it is your responsibility to obtain all permissions, pay any permission fees, furnish copies of permissions to Thieme with your manuscript, and include a credit line at the end of the figure caption, beneath the table, or in a text footnote.

Upon publication of an article, all rights are held by the publishers, including the rights to reproduce all or part of any publication. The reproduction of articles or illustrations without prior consent from the publisher is prohibited.

Statement of Ethics

This journal adheres to the ethical standards described by the Committee on Publication Ethics and the International Committee of Medical Journal Editors. Authors are expected to adhere to these standards.

For all manuscripts reporting data from studies involving human or animal participants, formal review and approval, or formal review and waiver (exemption), by an appropriate institutional review board (IRB) or ethics committee is required, as well as any necessary HIPAA consent, and should be described in the Methods section with the full name of the reviewing entity. All clinical trials must be registered in a public trials registry. Denote the registry and registry number.

Patient Permission Policy

You must obtain a signed patient permission form for every patient whose recognizable photograph will be used. If you do not supply this, the identity of the patient must be obscured before the image is published; this could interfere with the instructive value of the photograph. Patient permission forms are available at www.thieme.com/journal-authors

2. Ethics Approval

18 NOV 2018
 FHS017: Annual Progress Report / Renewal

Record Reviews/Audits/Collection of Biological Specimens/Repositories/Databases/Registries

HREC office use only (FWA0001807; IRB04001934)			
This agrees as notification of annual approval, including any documentation described below:			
<input type="checkbox"/> Approved	Actual progress report	Approved until/next renewal date	30-12-2020
<input type="checkbox"/> Not approved	See attached comments		
Signature Chairperson of the HREC:	Signature Removed		Date Signed: 17/11/2018

Principal Investigator to complete the following:

1. Protocol information

Date when submitted (this form)	15/11/2018		
HREC REF Number	345/2017	Current Ethics Approval used for this HREC	09/03/2019
Protocol title	Evaluation of Proposals & Vision in patients undergoing a minimally invasive endo-orbital approach for the treatment of sphenoidal wing meningioma		
Principal Investigator	Prof Dafene Lubbe		
Department / Office Internal Mail Address	dcolubbe@gmail.com		
1.1 Does this protocol receive US Federal funding?			<input type="checkbox"/> Yes <input checked="" type="checkbox"/> No

2. Protocol status (tick ✓)

<input checked="" type="checkbox"/>	Research-related activities are ongoing
<input type="checkbox"/>	Data collection is complete, data analysis only
Please indicate (in the block below) the titles and HREC reference numbers of any projects currently making use of the Database/registry/repository	

3. Protocol summary

Total number of records or specimens collected, reviewed or stored since last approval	6
Total number of records or specimens collected, reviewed or stored since last progress report	10
Have any research-related outputs (e.g. publications, abstracts, posters) been formally issued from this research? If yes, please list and submit with this report.	<input type="checkbox"/> Yes <input checked="" type="checkbox"/> No

4. Signature

Signature of PI	Signature Removed	Date	16th November 2018
-----------------	-------------------	------	--------------------