

Ischaemic preconditioning of the liver before transplantation

A. B. VAN AS, M.B. CH.B., M.B.A., F.C.S. (S.A.), PH.D.

H. R. FOROUTAN, M.B. CH.B., F.C.S.

Z. LOTZ, DIPL. MED. TECH. (CHEM. PATH.)

M. TYLER, DIPL. MED. TECH. (CHEM. PATH.)

A. J. W. MILLAR, M.B. CH.B., F.R.C.S., (ENG.), F.R.C.S. (EDIN.), F.R.A.C.S. (PED. SURG.), F.C.S. (S.A.), D.C.H.

D. KAHN, M.B. CH.B., F.C.S. (S.A.), CH.M.

Department of Surgery and Medical Research Council Liver Research Centre, Liver Transplantation Unit, University of Cape Town

Summary

Purpose. Assessment of the effect of a short ischaemic time prior to liver transplantation on the liver graft.

Methods. White X Landrace pigs ($N=10$) were subjected to liver transplantation. Before being removed from the donor animal, the livers were randomised into two groups: group 1 – pre-procurement ischaemia (15 minutes' temporary arrest of portal venous and hepatic arterial inflow to the liver, followed by reperfusion of these vessels for a period of 15 minutes); group 2 – no prior inflow occlusion (control group). In group 1 a spleno-jugular bypass was established to prevent venous congestion, portal venous hypertension, intestinal oedema and bacterial translocation. The livers were perfused with Eurocollins solution (4°C), after which they were stored on ice for a period of 3 hours' cold ischaemic time. Hepatocellular injury was assessed according to liver cell function tests (aspartate aminotransferase, AST), biochemical indicators of reperfusion injury (malondialdehyde) and histopathology.

Results. There was a significant rise of AST in both groups 1 hour after transplantation (from 51 ± 27 IU/l to 357 ± 152 IU/l in group 1 and from 29 ± 10 IU/l to 359 ± 198 IU/l in group 2). AST levels were marginally lower in group 1 at 2 and 4 hours after transplantation. There was also a rise in malondialdehyde levels in both groups at 5, 20, 40 and 60 minutes after transplantation. Levels of malondialdehyde were lower in the primed group at 5, 20 and 40 minutes, while the levels at 60 minutes after transplantation were comparable. Histological changes, as measured by vacuolisation, neutrophil infiltration and hepatic cell necrosis, were less in livers transplanted after ischaemic preconditioning, although the difference was not significant.

Conclusions. Ischaemic preconditioning of the donor liver seems to decrease hepatocellular damage, reperfusion injury and histological changes in the liver after transplantation. Further studies with larger numbers are indicated.

The protection of the myocardium by ischaemic preconditioning (IP) has been well established.^{1,2} Recently there have been several studies indicating that a similar process exists in the liver.^{3,4} The exact mechanism of IP has not yet been clarified. There is ample evidence that toxic oxygen radicals play the crucial role in preservation-reperfusion injury.^{5,6} It is therefore likely that free radicals are also involved in IP. Indeed, a recent study shows that intermittent pedicle clamping lessens free radical production when compared with continuous clamping in an experimental model.⁷ Nearly all experiments so far have been performed in small laboratory animals. To our knowledge, there have been no reports of IP in large mammals. The present study was designed to clarify the protective effect of IP on ischaemia-reperfusion injury after porcine liver transplantation.

Material and methods

The experiment was approved by the University of Cape Town Ethics Committee. The 'Principles of laboratory animal care' (NIH publication No. 86-23, revised 1985) were followed. Ten white X Landrace pigs were subjected to liver transplantation. The livers were stored on ice after perfusion with Eurocollins solution (4°C) for a period of 3 hours' cold ischaemic time. Before liver transplantation the animals were randomised into two groups (group 1 – ischaemic priming (IP) 15 minutes, reperfusion 15 minutes; group 2 – no ischaemic priming).

Operative technique

The experimental protocol was approved by the Animal Research Review Committee of the University of Cape Town. Ten young Large White X Landrace pigs of either sex and weighing 20 - 30 kg were fasted overnight and anaesthetised with intravenous sodium thiopentone (2 mg/kg). Anaesthesia was maintained with nitrous oxide and oxygen administered through an endotracheal tube. Catheters (Fr 8) were inserted into the common carotid artery for monitoring of blood pressure and for sampling of arterial blood, and into the internal jugular vein for the infusion of intravenous fluids. The ani-

imals were subjected to orthotopic liver transplantation using the technique described previously.⁸

Donor operation

The abdomen was explored via a midline incision extending from the xiphisternum to the symphysis pubis. After hilar dissection and mobilisation of the suprahepatic and infrahepatic vena cava, the pigs were randomised into two groups: group 1 – IP 15 minutes, reperfusion 15 minutes; group 2 – no priming (control group).

In group 1 the inflow to the liver was arrested by clamping the portal vein as well as the hepatic artery for a duration of 15 minutes. The clamps were then taken off and the liver reperfused with both hepatic arterial and portal venous blood. A spleno-jugular bypass was established prior to clamping to prevent venous congestion, portal venous hypertension, intestinal oedema and bacterial translocation.

In group 2 the liver vessels were isolated but not clamped and the abdomen was left open for 30 minutes, to keep the total anaesthetic time similar in both groups. No spleno-jugular bypass was inserted in the control group. After this the animal was heparinised and a catheter inserted into the portal vein for initial flushing. Eurocollins solution was used instead of University of Wisconsin solution to reduce costs. The liver was then excised during *in situ* flushing with ice-cold Eurocollins solution through the portal vein. Flushing of the liver with Eurocollins solution was continued on the back-table. Seven hundred millilitres was used to flush the portal vein, 100 ml to flush the hepatic artery and 100 ml to flush the bile duct. The remaining fluid was placed in the storage plastic bag containing the liver.

Storage

The donor liver was placed in a plastic bag with Eurocollins solution and stored on ice for 3 hours, since long storage times are associated with poor survival in the porcine liver transplantation model.

Recipient operation

The preparation of the liver was as described above. After dissection of the hilum of the liver and the suprahepatic and infrahepatic vena cavae, the animal was heparinised and passive spleno-jugular venous bypass established. The recipient liver was excised, and the donor liver implanted by anastomosing the suprahepatic vena cava, infrahepatic vena cava, portal vein, hepatic artery and bile duct.

Perioperative management

During the operation the animals received an infusion of plasmalyte B with 10% dextrose and 300 ml of donor blood to maintain haemodynamic stability. Postoperatively the pigs were returned to warmed cages and intravenous infusion continued for 1 day.

Blood sampling

The time at which the liver was reperfused with both portal venous blood and arterial blood was set as the zero point ('0 minutes'). Times before reperfusion (negative time scale) and after completed reperfusion (positive time scale) were recorded.

As previous studies have shown that the first hour is the most sensitive period in which to demonstrate alterations in the reperfusion injury markers, blood samples were taken

preoperatively, before pre-clamping (the hilar vessels), post clamping (the hilar vessels) and post reperfusion in group 1 and at base level, pre-reperfusion and at 5, 20, 40 and 60 minutes after total reperfusion in groups 1 and 2 for assessment of the reperfusion injury.

The hepatocellular injury related to the reperfusion injury was determined in the first 24 hours. Blood samples were taken preoperatively (baseline in donor and recipient) and at 1 hour, 2 hours and 4 hours after transplantation for serum aspartate aminotransferase (AST) levels as a marker of the hepatocellular injury.

Plasma malondialdehyde (MDA) levels were determined by the thiobarbituric assay as described by Lepage *et al.*⁹ 2-thiobarbituric acid (TBA) was added to deproteinised plasma and the reaction between the MDA and TBA, under conditions of low pH and high temperature, yielded a chromogenic adduct that was detectable by fluorometry.

Serum AST levels were determined spectrophotometrically using a continuous monitoring assay.

All statistics were calculated according to the method of the least significant difference (general ANOVA) as described by Snedecor and Cochran.¹⁰

Histology

Three liver biopsies were taken from the transplanted liver in each group. The first liver biopsy was taken immediately after removal of the donor liver at the dissection table, the second immediately after the cold storage period and the third 1 hour after transplantation. All liver biopsies were taken as a 1 cm × 1 cm wedge from the anterior border of the right lobe of the liver. The liver surface was secured with chromic catgut (2.0).

Technique

Tissues were fixed in a buffered 10% formalin solution. Following fixing the specimens were processed automatically in a tissue processor overnight, through alcohol 70%, 96% and absolute alcohol, xylol to paraffin wax. The tissues were then embedded in paraffin wax for cutting. Sections were cut with the aid of a microtome 2 µm thick, floated onto glass slides and fixed onto the slide with aid of heat (55 - 60°C). The sections were stained using Mayer's haematoxylin eosin method.¹¹

The sections of the liver were assessed for the following features: (i) hepatocyte vacuolisation; (ii) single-cell necrosis of the hepatocytes; (iii) group-cell necrosis of the hepatocytes; and (iv) infiltration of neutrophils. Morphometric analysis of the histological indicators was performed on a semi-quantitative assessment of changes based on a score from 0 to 5, in which zero represents normal tissue, and the score increases gradually from 1 (representing minimal changes) to 5 (representing severe alteration from normal tissue). Two independent pathologists, with experience in the transplantation field, assessed all sections blinded as to the experimental groups.

Results

AST results are shown in Fig. 1. There was a significant rise of AST in both groups 1 hour after transplantation (from 51±27 IU/l to 357±152 IU/l in group 1 and from 29±10 IU/l to 359±198 IU/l in group 2). AST levels were marginally lower in group 1 at 2 and 4 hours after transplantation.

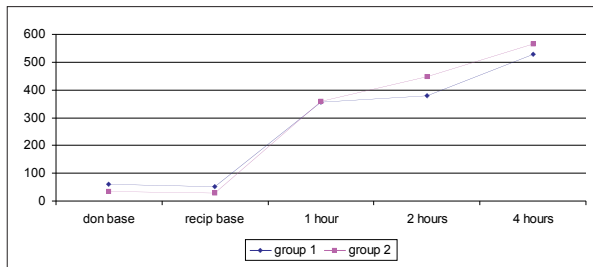


Fig. 1. Peripheral venous levels of AST (IU) post transplantation at various times (group 1 = ischaemic preconditioning; group 2 = control).

Results of MDA levels are shown in Fig. 2. Levels rose after transplantation in both groups at 5, 20, 40 and 60 minutes. Levels of MDA were lower in the primed group at 5, 20 and 40 minutes, while the levels at 60 minutes after transplantation were comparable, but the difference was not statistically significant.

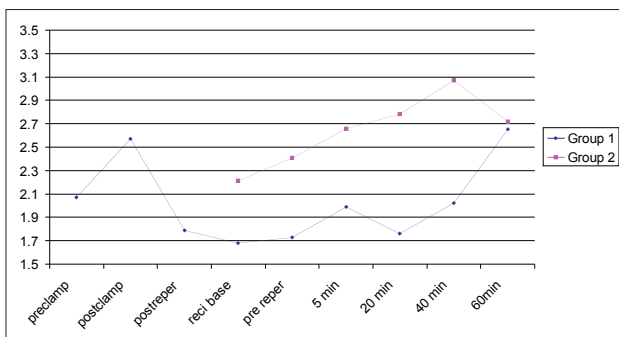


Fig. 2. Arterial levels of malondialdehyde (µmol/l) in both groups at the various times (group 1 = ischaemic preconditioning; group 2 = control).

Vacuolisation results are shown in Fig. 3. There was an increase of vacuolisation in both groups during the procedure. There was less vacuolisation in group 1 at base, post storage and post transplantation. The difference was greatest at base and the least post transplantation, but neither was statistically significant.

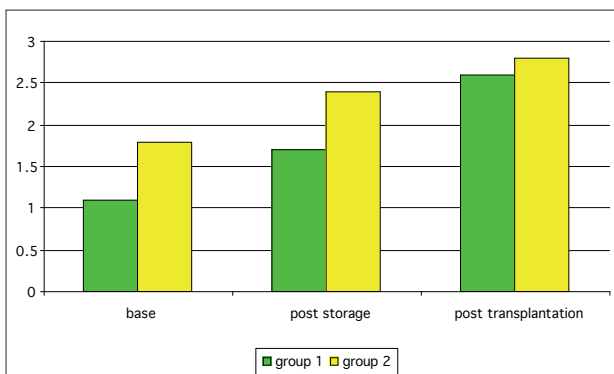


Fig. 3. Mean hepatocyte vacuolisation after liver transplantation in both groups in a semi-quantitative score from 0 to 5 (group 1 = ischaemic preconditioning; group 2 = control).

Results of neutrophil infiltration are shown in Fig. 4. There was less neutrophil infiltration in the livers that were transplanted after IP at base, post storage and post trans-

plantation. Although there was an increase over time in both groups, the difference remained comparable at the various biopsy times. The differences were not statistically significant.

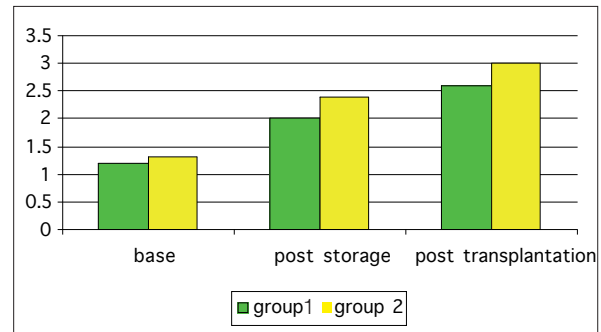


Fig. 4. Mean neutrophil infiltration after liver transplantation in both groups in a semi-quantitative score (group 1 = ischaemic preconditioning; group 2 = control).

Results of hepatic single-cell necrosis are demonstrated in Fig. 5. Although there was an increase of liver single-cell necrosis in both groups, there was less single-cell necrosis in group 1 at base, post storage and post transplantation. The difference between the two groups remained comparable. The differences were not statistically significant.

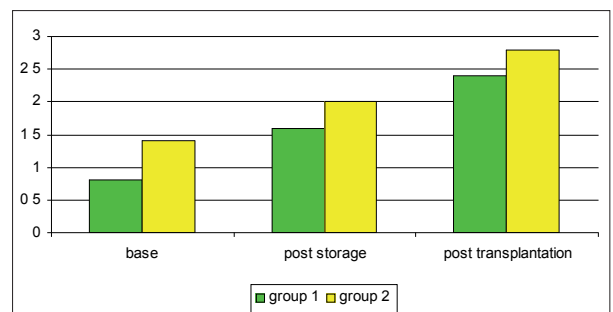


Fig. 5. Mean single-cell necrosis after liver transplantation in both groups (group 1 = ischaemic preconditioning; group 2 = control).

Results of hepatic group-cell necrosis are shown in Fig. 6. There was an increase in hepatic group-cell necrosis in both groups. There was less group-cell necrosis in liver transplanted after IP at base, post storage and post transplantation. The difference between the two groups remained comparable during the procedure. The differences were not statistically significant.

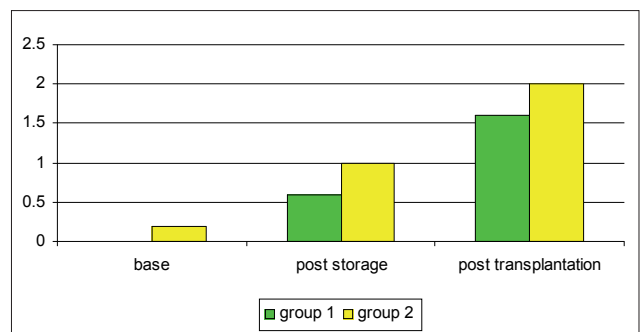


Fig. 6. Mean group-cell necrosis in the both groups after liver transplantation in a semi-quantitative score (group 1 = ischaemic preconditioning; group 2 = control).

Discussion

Since 1986, when the first preconditioning studies were reported,¹ there has been a considerable interest in this phenomenon. Although the original studies were limited to ischaemic injury of the heart, research quickly extended into various fields and preconditioning studies have now been performed in central nervous system, skeletal muscle and recently also in kidney and liver.³ Many studies have been performed to elucidate the effects of IP,¹²⁻¹⁶ but there is no certainty that any beneficial effects claimed represent causes, effects or epiphenomena.¹⁷ Although its clinical therapeutic effect has so far been limited to minimally invasive coronary artery bypass surgery,¹⁸ it is likely that future specialists will see the implementation of IP in a wide range of surgical patients.

The potential use of IP in liver surgery is twofold: IP as a protective mechanism in liver resections and IP as a protective mechanism before transplantation.

Rats preconditioned with 5 minutes of portal triad clamping showed improved survival and lower liver enzyme levels after 90 minutes' ischaemia¹⁹ and improved survival in 80% hepatectomy after IP.^{3,4} These studies were performed in rats, with few studies reported on large laboratory animals and even fewer clinical studies. Van Gulik's group reported that intermittent hepatic vascular inflow occlusion during prolonged liver ischaemia in pigs resulted in less microcirculatory and hepatocellular injury.²⁰ A further clinical controlled study clearly demonstrated better parenchymal tolerance to intermittent rather than continuous IP.²¹

Nearly all research has focused on the effect of IP on liver resection. Primary non-function of the transplanted liver still occurs at an unacceptably high rate (up to 20%) and continues to be a major cause of death after transplantation,²² while there is evidence that severe reperfusion injury is also associated with an increased incidence of liver graft rejection.²³ We studied the effect of IP on reperfusion injury markers in an experimental pig model.

In liver transplantation, the liver undergoes a significant preservation-reperfusion injury. Normally the liver is transported on ice at 4°C and stored for several hours. It would therefore be advantageous to precondition the liver before excision with a period of ischaemia. The study protocol was designed to test the thesis that warm IP could be of clinical benefit in reducing preservation and reperfusion injury.

AST is a well-established marker for hepatocellular injury. Reperfusion injury is known to be mediated, at least in part, by the formation of reactive oxygen metabolites, which damage a spectrum of bio-molecules found in tissues, including membrane lipids. Peroxidation of these membrane lipids results in the formation of malondialdehyde, which can therefore be used as a marker of reperfusion injury.²⁴ It is well known that routine histopathological findings in biopsy specimens taken within hours after completed revascularisation can, with reasonable accuracy, predict poor allograft function during the first few postoperative weeks.²⁵

Results of this study indicate that there are potential advantages from IP in clinical liver transplantation. Further

experimental studies with greater numbers are indicated to elucidate the significance and the underlying mechanisms of this promising technique.

REFERENCES

- Murry CE, Jennings RB, Reimer KA. Preconditioning with ischemia: a delay of lethal cell injury in ischemic myocardium. *Circulation* 1986; 74: 1124-1136.
- Yellon DM, Baxter GF, Garcia-Dorado D, Heusch G, Sumeray MS. Ischaemic preconditioning: present position and future directions. *Cardiovasc Res* 1998; 37: 21-33.
- Hardy KJ, Tancheroen, Shulkes A. Comparison of continuous versus intermittent ischaemia-reperfusion during liver resection in an experimental model. *Br J Surg* 1995; 82: 833-836.
- Yoshizumi T, Yanaga K, Soejima Y, Maeda T, Uchiyama H, Sugimachi K. Amelioration of liver injury by ischaemic preconditioning. *Br J Surg* 1998; 85: 1636-1640.
- Adkison D, Hollwarth ME, Benoit JN, Parks DA, McCord JM, Granger DN. Role of free radicals in ischaemia-reperfusion injury to the liver. *Acta Physiol Scand* (Suppl) 1986; 548: 101-107.
- Connor HD, Gao W, Nukita S, Lemasters JJ, Mason RP, Thurman RG. Evidence that free radicals are involved in graft failure following orthotopic liver transplantation in the rat: an electron paramagnetic resonance spin trapping study. *Transplantation* 1992; 54: 199-204.
- Uchinami M, Muraoka R, Horiuchi T, et al. Effect of intermittent hepatic pedicle clamping on free radical generation in the rat liver. *Surgery* 1998; 124: 49-56.
- Dent DM, Hickman R, Uys CJ, Saunders SJ, Terblanche J. The natural history of liver allo- and autotransplantation in the pig. *Br J Surg* 1971; 58(6): 407-413.
- Lepage G, Munoz G, Champagne J, Roy CC. Preparative steps necessary for the accurate measurement of malondialdehyde by high-performance liquid chromatography. *Anal Biochem* 1991; 197: 277-283.
- Snedecor GW, Cochran WG. *Statistical Methods*. 7th ed. Ames, Iowa: Iowa State University Press, 1980.
- General staining procedures. In: Drury RAB, Wallington EA, eds. *Carleton's Histological Technique*. 4th ed, London: Oxford University Press, 1967: 126-130.
- Bouchard JF, Chouinard J, Lamontagne D. Participation of prostaglandin E2 in the endothelial protective effect of ischaemic preconditioning in isolated rat heart. *Cardiovasc Res* 2000; 45: 418-427.
- Das DK, Maulik N, Sato M, Ray PS. Reactive oxygen species function as second messenger during ischaemic preconditioning of the heart. *Mol Cell Biochem* 1999; 196: 59-67.
- Ito K, Ozasa H, Sanada K, Horikawa S. Doxorubicin preconditioning: a protection against rat hepatic ischaemia-reperfusion injury. *Hepatology* 2000; 31: 416-419.
- Piot CA, Martine JF, Bui SK, Wolfe CL. Ischaemic preconditioning attenuates ischaemia/reperfusion-induced activation of caspases and subsequent cleavage of poly(ADP-ribose) polymerase in rat hearts in vivo. *Cardiovasc Res* 1999; 44: 536-542.
- Bouchard JF, Chouinard J, Lamontagne D. Role of kinins in the endothelial protective effect of ischaemic preconditioning. *Br J Pharmacol* 1998; 123: 413-420.
- Bulkeley GB. Preconditioning for protection from ischemic injury: discriminating cause from effect from epiphenomenon. *Ann Surg* 2000; 232(2): 163-165.
- Hawaleshka A, Jacobsohn AE. Ischaemic preconditioning: mechanisms and potential clinical application. *Can J Anaesth* 1998; 45(7): 670-682.
- Lloris-Carsi JM, Cejalvo D, Toledo-Pereyra LH, Calvo MA, Suzuki S. Preconditioning: effect upon lesion modulation in warm ischaemia. *Transplant Proc* 1993; 25: 3303-3304.
- Van Wagenveld BA, van Gulik TM, Gelderblom HC, et al. Prolonged continuous or intermittent vascular inflow occlusion during hemihepatectomy in pigs. *Ann Surg* 1999; 229(3): 376-384.
- Beghiti J, Noun R, Malafosse R, et al. Continuous versus intermittent portal triad clamping for liver resection. *Ann Surg* 1999; 229(3): 369-375.
- Greig PD, Woolf GM, Sinclair SB, et al. Treatment of primary liver graft nonfunction with prostaglandin E1. *Transplantation* 1989; 48(3): 447-453.
- Howard TK, Klintmalm GB, Cofer JB, Husberg BS, Goldstein RM, Gonwa TA. The influence of preservation injury on rejection in the hepatic transplant recipient. *Transplantation* 1990; 49(1): 103-107.
- Auer T, Khoschorur GA, Rabl H, et al. Detection of lipid peroxidation products by malondialdehyde (MDA-TBA) reaction in organ transplantation. *Transplant Proc* 1995; 27(5): 2749-2751.
- Tillery W, Demetris J, Watkins D, et al. Pathologic recognition of preservation injury in hepatic allografts with six month's follow-up. *Transplant Proc* 1989; 21(1, Pt 2): 1330-1331.