

**THE EFFECT OF A CHANGE IN PLASTERING TECHNIQUE
ON THE RATE OF MAJOR SURGERY IN IDIOPATHIC
CLUBFOOT**

MASTER OF MEDICINE

ORTHOPAEDIC SURGERY

DR ANRIA HORN

MBChB (UP)

REGISTRAR IN ORTHOPAEDIC SURGERY

GROOTE SCHUUR HOSPITAL

UNIVERSITY OF CAPE TOWN

SUPERVISOR: DR S DIX-PEEK

The research reported in this dissertation is based solely on the independent performed by the candidate neither the whole work nor any part of it has been, is being, or is to be submitted to any other university for any other degree purposes. This work has not been reported or published prior to registration by the candidate for the above mentioned degree.

The copyright of this thesis vests in the author. No quotation from it or information derived from it is to be published without full acknowledgement of the source. The thesis is to be used for private study or non-commercial research purposes only.

Published by the University of Cape Town (UCT) in terms of the non-exclusive license granted to UCT by the author.

ABSTRACT

Rationale

The Ponseti technique of manipulation and casting is reported to have almost eliminated the need for extensive soft tissue release in the treatment of idiopathic clubfoot. This technique of treatment has however not been universally adopted and results of treatment vary significantly between treatment centres. Furthermore, surgical decision making in the treatment of clubfoot is currently largely based on clinical findings as opposed to radiographic parameters. The Ponseti method of manipulation and casting was introduced at our institution in 2002, prior to which we used the Kite method. Both prior to, and following the introduction of Ponseti casting, surgical decision making was based on pre-operative radiology, and intra-operative clinical assessment. We propose to determine the impact on this change of plastering technique on the rate of major surgery performed primarily in our patients with idiopathic clubfoot. We also aim to determine whether or not pre-operative radiographs have any bearing on the surgery performed on these patients.

Methods

A retrospective comparative study was performed to compare the incidence of extensive soft tissue release in patients initially treated with the Kite method of plastering versus the Ponseti method. The antero-posterior (AP) and lateral talocalcaneal angle, the tibio-calcaneal angle and talo-1stmetatarsal (TMT) angle were measured on all available radiographs and statistical analysis was performed in order to determine the correlation between the measured angles and the surgery performed.

Results

The incidence of radical surgery decreased from 40% in patients initially treated with Kite's method to zero in patients treated with the Ponseti method ($p < 0.001$). Of the four routinely measured radiographic angles, only the tibio-calcaneal angle ($p=0.009$) and the TMT angle ($p=0.002$) significantly correlated with the extent of surgery performed.

Discussion and Conclusion

The results of this study is in agreement with the majority of the published literature with regards to the success of the Ponseti method of treatment for idiopathic clubfoot, and supports the notion that this treatment method is feasible in lower socio-economic settings. We found a statistically significant correlation between the tibio-calcaneal and TMT angle and the surgery performed, but concluded that surgical decision making was not significantly influenced by radiographic parameters. In contrast to the majority of published literature, there was no significant correlation between the lateral and AP talocalcaneal angles and the surgery performed in our patients. We therefore refute the need for routine radiographic evaluation in the treatment on idiopathic clubfoot.

PUBLICATION-READY FORMAT

Table of Contents

Part A – Research Protocol

- I. Introduction
- II. Study Design
- III. Methods
- IV. Relevance
- V. Report of findings
- VI. Budget and Funding
- VII. Ethical Considerations
- VIII. References

Part B – Literature Review

- I. Objectives of the literature review
- II. Search methodology
- III. Introduction
- IV. Surgery for clubfoot
- V. Manipulative treatment for clubfoot
- VI. The Ponseti method of treatment for clubfoot
- VII. Ponseti versus other methods of non-operative treatment
- VIII. Radiography in clubfoot
- IX. Discussion
- X. Quality Criteria
- XI. References

Part C – Manuscript (publication-ready format)

Part D- Appendices

- I. Acknowledgements
- II. Ethics approval

Protocol Summary

Title: The effects of a change in plastering technique on the rate of major surgery in CTEV

Principal investigator: Dr Anria Horn

Supervisor: Dr Stewart Dix-Peek. MBChB (UCT), MMed Ortho (UCT), FCS Orth (SA)

Clinical Head, Paediatric Orthopaedics Services, Red Cross War Memorial Children's Hospital and Maitland Cottage Home for Disabled Children.

Consultant, Paediatric Trauma Unit, Red Cross War Memorial Children's Hospital

I. Introduction

Congenital clubfoot is one of the commonest paediatric orthopaedic deformities. It is often associated with other congenital malformations such as spina bifida and arthrogryposis, but the exact aetiology of idiopathic clubfoot remains shrouded in uncertainty. The deformity is complex and three-dimensional consisting of hindfoot varus and equinus, with forefoot cavus and adductus. The incidence of congenital clubfoot is quoted to be 0,6-7/1000 live births internationally, and is estimated to be 3/1000 live births amongst the South African population.²

It is currently accepted almost universally that the initial management of this condition should be conservative, and should start as soon after birth as possible.⁵ This initial conservative management consists of serial manipulations, with or without casting, and preferred techniques vary considerably. Surgical procedures are then performed on those feet that do not respond to conservative efforts. As the deformity is difficult to quantify exactly, Bensahel et al³ recommended an '*a la carte*' approach to surgery, where each foot is individualised, and only what surgery is required to correct the residual deformity, is done.

In 1963 Ponseti¹ revolutionised the conservative management of clubfoot by stressing the importance of abducting the forefoot around the navicular head rather than at the level of the midfoot, as had been the accepted method until then. He illustrated that by forcing abduction of the forefoot around the calcaneo-cuboid joint, correction of the hindfoot varus is effectively blocked, resulting in early relapse and unsatisfactory outcomes.⁴ Ponseti showed that with his method the deformity was corrected with less changes of plaster, and the need for surgery was also greatly reduced when a strict, long term maintenance program was followed.

At The Maitland Cottage Children's Hospital, the Ponseti method of casting was only employed as late as 2002. It was noted that since this change in technique was introduced, the rate of major surgery performed to correct residual deformity in clubfoot was dramatically decreased. The purpose of this study is to investigate and quantify retrospectively the incidence of major surgery for congenital clubfoot before and after the introduction of the Ponseti method.

A secondary aim of this study is to evaluate whether there was any correlation between radiological parameters measured pre-operatively and the type of surgery performed. Radiographs are commonly used in the initial evaluation and follow up of patients with clubfoot. Herbsthofer et al found no significant value in the measurement of radiographic parameters due to large standard

deviation in measured angles and overlap between normal and abnormal cohorts.⁶ Radler et al found radiographs to be of some help in identifying pseudocorrection of hindfoot equinus prior to percutaneous tenotomy,⁷ however, even here clinical evaluation is equally accurate in detecting this phenomenon. We therefore aim to evaluate the correlation between measured abnormalities and the surgery performed for each individual, and thereby defining the need, if any, for routine radiographs in the management of this condition.

II. Study Design

A retrospective audit of records and radiographs for patients that presented to Groote Schuur clubfoot clinic in the years 1999-2000, and for patients presenting to Maitland Cottage clubfoot clinic in the years 2009-2010. These patients represent the pre- and post-Ponseti groups respectively.

III. Methods

We aim to perform a retrospective review of the records and radiographs of all patients that presented to our clubfoot clinic in the years 1999-2000 and 2009-2010 respectively.

Inclusion criteria:

- Clinical diagnosis of congenital clubfoot
- Age less than three months
- No previous treatment received

Patients with teratological clubfoot were excluded from this study

The following parameters are to be recorded:

- Age at presentation
- Gender and limb involved
- Number of serial plaster casts applied
- Pre-operative radiological parameters:
 - Lateral talocalcaneal angle
 - Lateral tibio-calcaneal angle
 - Anterior talocalcaneal angle
 - Anterior talar-1st metatarsal angle
- Date of surgery
- Type of surgery performed

The collected data will then be analysed to determine the effect that the change in plastering technique brought about with the outcome measured being the type of surgery performed, using the Chi-square test.

Secondary analysis will be performed to determine whether there is any significant correlation between radiological measurements and the type of surgery performed. The Analysis of Variance (ANOVA) test will be performed for data sets that are normally distributed, and the Kruskal-Wallis test for data that is not normally distributed.

IV. Relevance

The relevance of this research is twofold. Firstly to quantify and thereby critically appraise the success of our current treatment regime, and to compare it to that of other institutions. Secondly, to determine the relevance, if any, of pre-operative radiological evaluation of our patients.

V. Report of Findings

This study will be submitted for publication in peer-review journals (for example, South African Orthopaedic Journal), and will be submitted for discussion at the annual South African Orthopaedic Association Congress. Results will also be presented and discussed at faculty and departmental research meetings.

VI. Budget and Funding

The research conducted here forms part of the researcher's academic obligations, therefore no funding is required.

VII. Ethical Considerations

As this a retrospective review of records, no consent is required. Patients' confidentiality and anonymity will be maintained at all times. Ethical approval has been obtained from the University of Cape Town's Human Research Ethics Committee.

VIII. References:

1. Ponseti IV, Smoley EN. Congenital Clubfoot: The Results of Treatment. *J Bone Joint Surg [Am]*. 1963; **45-A(2)** :261-273
2. Singer M. Club Foot Revisited. *Transactions of the College of Medicine of South Africa*. January-June, 1986
3. Bensahel H, Dimeglio A, Souchet P. Final evaluation of clubfoot. *J Pediatr Orthop-B*. 1995;**4(2)**:137-41
4. Ponseti IV. Common Errors in the treatment of congenital clubfoot. *Current Concepts, Int Orthop (SICOT)*1997: **21**,137–141
5. Sud A, Tiwari A, Sharma D, et al. Ponseti's vs. Kite's method in the treatment of clubfoot-a prospective randomised study. *Int Orthop*.2008; **32(2)**: 409-413
6. Herbsthofer B, Eckardt A, Rompe J-D, et al. Significance of radiographic angle measurements in evaluation of congenital clubfoot. *Arch Orthop Trauma Surg*. 1998; **117**:324-329
7. Radler C, Manner H, Suda R, et al. Radiographic Evaluation of Idiopathic Clubfeet Undergoing Ponseti Treatment. *J Bone Joint Surg [Am]*. 2007; **89(6)**: 1177-83

Part B - Literature Review

I. Objectives of literature review

1. To provide insight into burden of disease, aetiology and pathology and clinical features of idiopathic clubfoot
2. To review the commonly performed surgical procedures for idiopathic clubfoot and the reported outcomes and complications
3. To review methods of non-surgical treatment for idiopathic clubfoot
4. To review the Ponseti method of treatment for idiopathic clubfoot and the reported outcomes and complications
5. To review existing studies comparing the outcomes of traditional non-surgical methods and the Ponseti method of treatment for idiopathic clubfoot
6. To review studies evaluating the role of radiographic parameters in the treatment and prognostication of idiopathic clubfoot

II. Search methodology

Internet based search engines such as Pubmed, Medline and Google Scholar were used to identify articles relevant to the review. The lists of references of the selected articles were further scrutinised for relevant publications. Publications were included in the literature review if they were written in English and published in a peer reviewed journal.

III. Introduction

Clubfoot, or idiopathic talipes equinovarus, is one of the commonest congenital abnormalities.¹ The reported incidence ranges from 0.6 – 7/1000 live births with males being affected twice as commonly as females.²⁻⁵ The condition is bilateral in 49% of cases, and in unilateral cases, the right foot is affected slightly more frequently than the left (60% vs 40%).⁵ Eighty percent of cases are idiopathic, the remaining 20% being associated with other conditions such as spinal dysraphisms, arthrogryposis, congenital myotonic dystrophy and amniotic band syndrome.²

The exact aetiology of idiopathic clubfoot is yet to be determined. Environmental risk factors that have been identified include parental smoking⁵ and amniocentesis in the first trimester.⁶ Conditions associated with reduced intra-uterine volume, such as oligohydramnios, multiple pregnancies and primigravida are also associated with milder forms of clubfoot. Delayed closure of the L5 spinal segment, the segment responsible for peroneal innervation, has been implicated in abnormal muscle development in patients with clubfoot and could explain some of the histological abnormalities found on muscle biopsy.⁵ Although no specific genetic basis for clubfoot has been elucidated, the condition is clearly inherited as 25%-27% of patients have a positive family history,

and there is a significantly higher concordance amongst identical twins than fraternal twins (33% vs 3%).^{2,5}

Histological evaluation of cadaveric clubfeet reveals delayed growth and ossification of the talus as and shortening of the spring ligament in affected feet.⁷ Vascular channels within the talus are fewer and disorganised compared to unaffected tali,⁸ and the contracted medial tissues display disorganised, fragmented collagen bundles with an abnormally high concentration of Type III fibres and cells resembling myofibroblasts.⁷

Pathological anatomical relations in clubfoot consist of hypoplasia of the talus with medial deviation of the talar neck. The navicular is displaced medially on the talar head, the calcaneus is in equinus and rotated medially under the talus and there is medial subluxation of the calcaneocuboid joint. The cuneiforms are displaced inferomedially in relation to the navicular. The forefoot is pronated in relation to the hindfoot and the 1st metatarsal is plantar-flexed, resulting in a cavus deformity.^{5,7,9} There is a dense fibrous mass medially at the insertion of the tibialis posterior tendon on the navicular, involving the deltoid and spring ligaments.⁷ There is thickening of the peroneal sheaths and calcaneofibular ligament and often, contracture of the plantar fascia.⁵ Finally, anterior tibial artery hypoplasia has been demonstrated in up to 80% of patients with clubfoot.²

The clinical presentation of clubfoot is that of a severely equinus hindfoot with a varus heel, an adducted forefoot and varying degrees of cavus. Associated findings include internal torsion of the tibia, posterior displacement of the lateral malleolus, calf muscle atrophy and a foot that is relatively smaller than the unaffected foot in unilateral cases.⁵

Various systems have been developed to classify idiopathic clubfoot in order to prognosticate and guide treatment, as well as aid communication between clinicians and researchers. The system devised by Pirani is the most frequently used in clinical practice today.¹⁰ This simple system measures 6 clinical signs of contracture, each feature given a score of 0, 0.5 or 1, depending on severity. (*Table 1*) This system has been found to have almost perfect interobserver reliability and to correlate well with duration and extent of treatment eventually required.^{11,12}


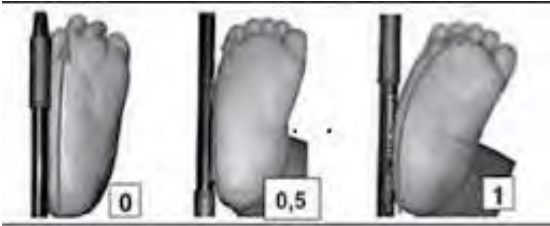
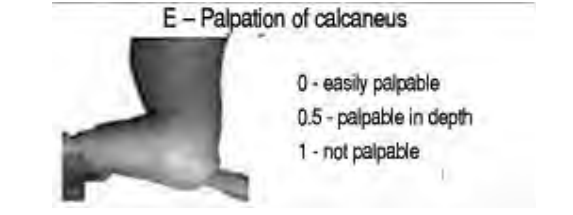
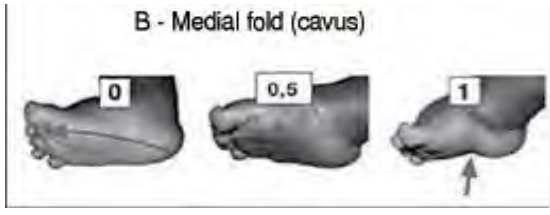
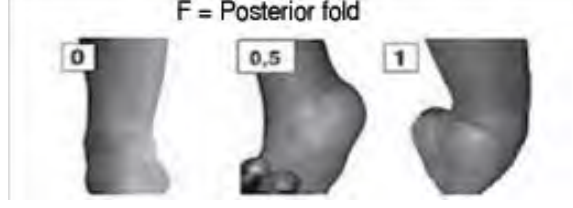

IV. Surgery for clubfoot

Extensive soft tissue releases as primary intervention for clubfoot has fallen out of favour following the good results seen with non-operative management. There are certain patients, however, that still require extensive soft tissue releases. These include syndromic clubfeet, severe resistant or recurrent clubfeet, and patients who are poorly compliant with non-operative protocols.¹³

Frequently performed procedures include the posteromedial release described by Turco in 1970,¹⁴ and the less extensive posterolateral release described by Hudson and Catterall in 1994.¹⁵

The posteromedial release involves sectioning of the contracted medial, posterior, lateral and plantar structures, including the ankle, subtalar, talonavicular and calcaneocuboid joint. Turco reported 90% good or excellent results using this method but noted that residual deformity was present in all patients, though not necessarily functionally limiting. These deformities included pes planus due to overcorrection, in-toeing, forefoot adductus and limited ankle and subtalar motion.¹⁴

Table 1. The Pirani scoring system for clubfoot.¹⁰

| Hindfoot Signs | Midfoot signs |
|---|--|
| Rigid equinus  | Curved lateral border  |
| Empty heel E – Palpation of calcaneus 0 - easily palpable 0.5 - palpable in depth 1 - not palpable  | Medial crease B - Medial fold (cavus)  |
| Posterior crease F = Posterior fold  | Uncovering of talar head C - Palpation of the talar head 0 - not palpable 0.5 - partially palpable 1 - easily palpable  |

These late complications, most markedly overcorrection and stiffness, were also noted by other authors at long term follow-up. Up to 50% poor results are reported and up to 86% of patients require on or more additional procedure following the index surgery.^{3,13,16} Thompson et al, however, reported 86% good and satisfactory results in patients treated by one-stage posteromedial release, compared to only 42% good or satisfactory results in those treated with limited soft tissue procedures.¹⁷

The less extensive posterolateral release spares the mid-tarsal joints, the medial ankle and subtalar joints and does not involve sectioning of tibialis posterior and flexor hallucis longus tendon. In their original paper reporting intermediate term follow-up results, Hudson and Catterall found that 32% of patients required reoperation during the follow-up period and 46% of patients had satisfactory results.¹⁵ Hutchins et al, in a 15 year follow-up study, found similar results with 26% of patients requiring further surgery following the initial posterolateral release.¹⁶ In their cohort, 81% of patients had satisfactory results using the scoring system devised by Laaveg and Ponseti.¹⁸ Reported long term complications and causes for poor results following posterolateral release include recurrence of the hindfoot equinus, hindfoot or forefoot varus, scar-related problems and stiffness.^{15,16}

Lengthening or tenotomy of the Achilles tendon and transfer of the tibialis anterior tendon to the lateral cuneiform or cuboid are commonly performed following manipulative treatment and are discussed in more detail in the following sections.

V. Manipulative treatment for clubfoot

Modern manipulative treatment for clubfoot was pioneered by Kite, who published the results of his non-operative method of casting and wedging in 1932.¹⁹ He corrected the clubfeet in the following sequence: Correction of forefoot adduction around the tarsometatarsal joint, correction of the hindfoot varus through the subtalar joint and finally, correction of the hindfoot equinus through the ankle joint.²⁰ Below knee casts were used and following complete correction, retention casts were worn for 6-10 weeks, and night splints until the age of three years.²¹⁻²⁴ In a later publication, he emphasised the importance of correcting the hindfoot inversion before any attempt at dorsiflexion is made. Failing to do so places the foot at risk of developing a rocker bottom deformity, as well as a tendency to recur.^{22,23} He reported excellent outcomes with his treatment method in 90% of patients. One drawback of this method, stated by the author himself, was the prolonged treatment period, on average 29.3 weeks in casts. Nineteen percent of his patients suffered one or more recurrence of the deformity, requiring repeat treatment with serial casting and wedging.¹⁹ These results were not replicated by other authors, with poor results requiring surgery reported in up to 87% of patients.^{6,21,25}

The French functional method of treatment for clubfoot, described by Bensahel in the early 1970's,²⁶ involves daily manipulation of the foot by a skilled physical therapist, stimulation of the muscles around the foot, and temporary immobilisation of the foot with adhesive strapping.²¹ Application of a continuous passive motion machine has been found to decrease the need for extensive surgery further. Daily manipulation and strapping of the feet is continued by the patient's parents once daily physiotherapy has been discontinued, usually around the age of three months, and is maintained until walking age or when the correction has become stabilized. Good outcomes are reported for patients with moderate deformity but surgery is still required in up to 42% of patients being treated with this method.^{21,26} This treatment method also requires a very significant time commitment from the parents and problems with compliance are frequent.⁶ Proponents of this method, most markedly the French, report significant improvement in deformity in all patients and recommend what is called an '*a la carte*' approach to surgical intervention, meaning that only that aspect of the deformity that proves resistant to conservative methods should be addressed surgically.²⁶ In a study published by Van Campenhout et al, all patients that did not have satisfactory results underwent a full posteromedial release. In their series, 75 out of a hundred patients required surgery, 18 of whom were classified as having mild or moderate deformity at initial presentation.²⁷ They did however state that the functional method provided a more supple foot to operate on. None of their patients required re-operation at 3 year follow-up.²⁷

VI. The Ponseti method of treatment for clubfoot

Following an in depth study of the pathoanatomy of the clubfoot, Ponseti developed and started practising his method of treatment in the 1940's. He was disappointed with poor results observed in

clubfeet that were treated with extensive soft tissue releases, noting that these feet were usually stiff, painful and functioned poorly.^{9,28} Treatment is started as early as possible, preferably before the age of 1 month, and consists of gentle manipulation and maintenance of the correction in an above knee plaster that is changed every 4-7 days. The use of an above knee plaster corrects the internal torsion of the tibia and is considered an essential aspect of this method. The deformity is corrected in the following sequence. (*Figure 1*) First, the forefoot pronation or cavus deformity is corrected by paradoxically supinating the forefoot on the hindfoot, bringing the foot as a whole in alignment.^{9,29} Following realignment of the hindfoot on the forefoot, the adducted forefoot is gradually abducted around the head of the talus. This is another critical difference between Ponseti's method and Kite's method. Kite placed counter pressure on the calcaneocuboid joint during abduction of the forefoot, thereby effectively blocking calcaneal eversion and dramatically slowing down the process of correction.³ Once abduction of 50 degrees have been achieved, the equinus deformity can be corrected by serial casting and in up to 90% of cases, a percutaneous Achilles tenotomy.^{6,9} Following the tenotomy, the foot is placed in a retention cast for 3-4 weeks after which the Achilles tendon has healed and a bracing protocol is begun. The brace consists of two high-topped shoes attached to a horizontal bar with adjustable degrees of abduction. The affected feet are abducted to 70 degrees and the normal feet to 40 degrees. The brace is worn 23 hours a day for three months and thereafter at night and during nap times until the age of 4.

Figure 1. Photograph illustrating the progressive deformity correction with the Ponseti method of treatment for clubfoot.¹⁰



In Ponseti's first published series 56% of the treated feet had at least one recurrence.⁹ Half of these were thought to be a result of early discontinuation of the brace, usually at the parents' own initiative. Recurrent deformities were also observed in more severe and rigid clubfeet with poor calf musculature. The recurrences were treated with a combination of repeat bracing, casting, Achilles tenotomies and soft tissue procedures tailored to the specific aspect of the deformity that recurred. Only 8% of patients required formal Achilles lengthening and only one a medial release procedure. Transfer of the tibialis anterior tendon to the lateral cuneiform or cuboid was performed in 42% of patients to address recurrence of the heel varus deformity, and was successful in preventing further recurrence in all but a few. Other surgeries performed were percutaneous plantar fascia release for recurrent cavus, recession of the extensor hallucis longus tendon for cock-up toe deformity and medial tarsometatarsal joint capsulotomy for severe adductus deformity. At his final assessment, 71% had good or excellent results and only 1% poor results.

In a long term follow up study by Laaveg and Ponseti on the results of their treatment in 104 clubfeet,¹⁸ 42 feet required an Achilles tendon lengthening, mostly percutaneous, and 48 a tibialis

anterior transfer, with or without further specific procedures as described above. Using their own functional rating system at final follow up, they had 74% good or excellent results, 14% fair and 12% poor. Factors that correlated with worse results and patient dissatisfaction were tibialis anterior transfer, decreased range of ankle and subtalar motion, poor cosmetic result, pain, level of activity and the lateral talocalcaneal angle. In a report by Cooper et al evaluating treated clubfeet at an average of 35 years follow-up, patients showed no functional impairment when compared to a normal control group. While they had the same amount of high foot demand occupations and sporting participation, there were more clubfoot patients that had long-distance walking limitation.³⁰

The Ponseti method has been used with success in many centres,^{4,12,31} and Ponseti's good results are mostly reproducible if compliance with the bracing protocol is good.^{3,4,18,28,30,31} Complications are few and are usually associated with poor technique or the use of inappropriate materials.^{4,28} As experience with this method improves, it is being applied to more severe and more resistant cases of clubfoot, including syndromic clubfeet, neglected clubfeet and feet that have undergone multiple previous surgeries.⁶ The Ponseti method significantly reduces the cost of treatment of clubfoot²⁵ and is accessible to patients in low income countries where access to surgical facilities are limited.^{3,31}

VII. Ponseti versus other methods of non-operative treatment.

Several authors have investigated the results of Ponseti's method of treatment when compared to traditional methods of manipulation. Herzenberg et al compared 34 clubfeet treated with the Ponseti method and 34 feet treated with short leg casts and traditional manipulative methods. They demonstrated that the need for posteromedial release in the first year of life decreased from 94% in the control group to 3% (1 patient) in the Ponseti group. They also demonstrated superior flexibility in the feet treated with Ponseti's method.²⁵ Similar results were found in other comparable studies. Sud et al found shorter manipulative time, better correction and a decrease in need for surgery from 33% to 8% with using the Ponseti method.³² Boden et al found a decrease in need for surgery from 65% to 25.5% with the Ponseti method,³³ and Halanski et al, a decrease from 93% to 10%.³⁴ Rijal et al³⁵ found patients treated with Ponseti's method achieved a Pirani score of 0 much faster than patients treated with Kite's method of manipulation, and Zwick et al found higher functional ratings and improved range of ankle and subtalar motion in the Ponseti group at three year follow-up.³⁶ Richards et al compared prospectively the results of clubfeet treated with the French method and Ponseti's method. They found a non-significant trend towards improved outcomes using Ponseti's method but the amount of patients eventually requiring surgery were the same for both groups. As in other reports, the majority of relapses in the Ponseti group occurred as a result of non-compliance with the abduction bracing protocol.³⁷ Molteno and Colyn, in a large retrospective study, found a decrease in the need for posteromedial release from 85.1% to 64.5% after introducing the Ponseti method at their institution. This relatively high rate of extensive surgery was ascribed to their patient population being largely of low socio-economic status and living far away, therefore finding compliance with bracing and follow-up problematic.³⁸

VIII. Radiography in clubfoot

Radiographic parameters and findings are often used as indicators of severity of deformity and success of treatment in clubfoot. Frequently quoted radiographic measurements are the talocalcaneal angle,^{14,17,39-42} measured on both the antero-posterior (AP) view and the lateral view, the talocalcaneal index, which is a sum of the AP and lateral talocalcaneal angles, the tibiocalcaneal angle,^{17,41} the talo-1st metatarsal (TMT) angle,³⁹ the calcaneo-5th metatarsal angle^{17,40} and the talonavicular angle.⁴⁰ (Figures 2-5)

Figure 2a. The ventrally open AP talocalcaneal angle in a normal foot

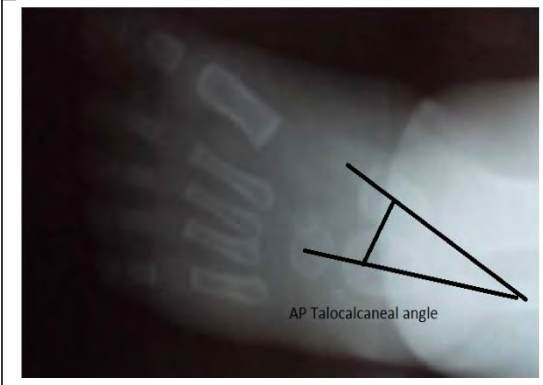


Figure 2b. Marked parallelism of the AP talocalcaneal angle in a clubfoot

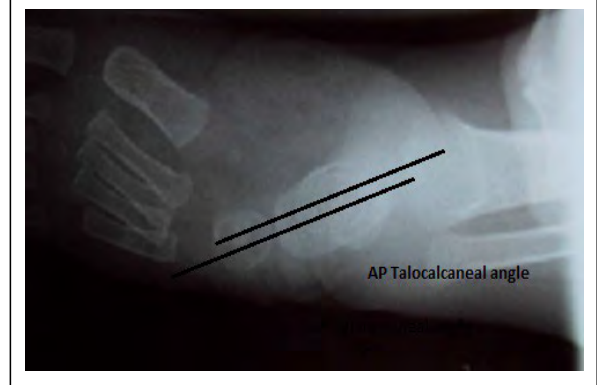
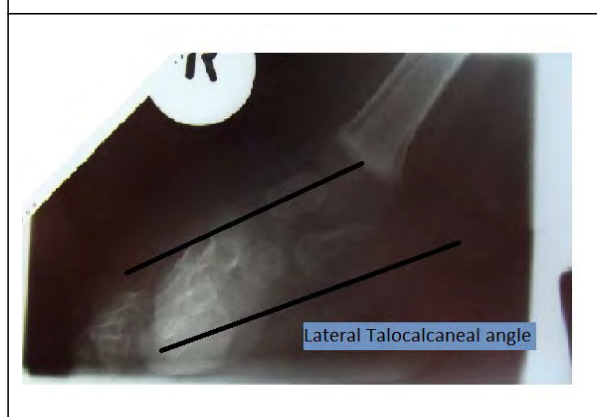


Figure 3a. The lateral talocalcaneal angle in a normal foot.

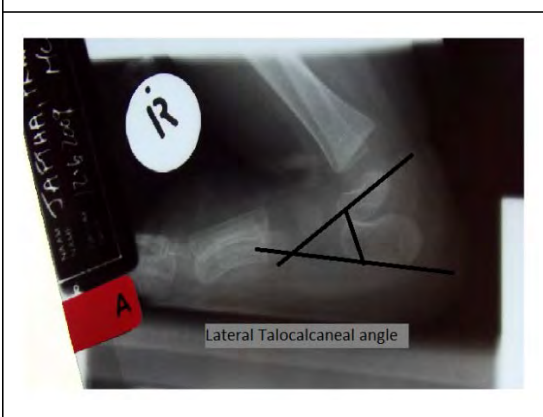

Figure 3b. Parallelism of the lateral talocalcaneal angle in a clubfoot



A standardised method for taking X-rays in clubfoot was described by Simons in 1977 and involves holding or strapping the foot in the position of maximum correction and aiming the X-ray beam at the head of the talus for the AP view.³⁹ Simons found that persistent talonavicular subluxation was often implicated in failure of conservative management, and that the combination of an AP talocalcaneal angle of <15 degrees and a TMT angle of >15 degrees were always indicative of talonavicular subluxation.³⁹

Figure 4. The talo-1st metatarsal angle

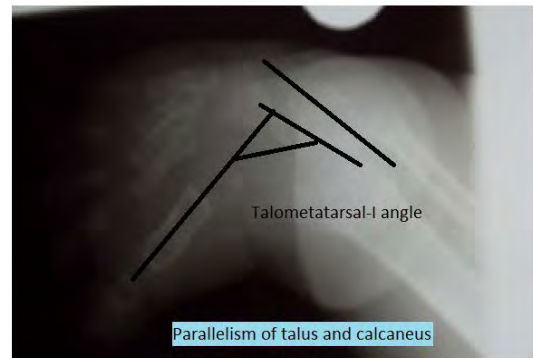
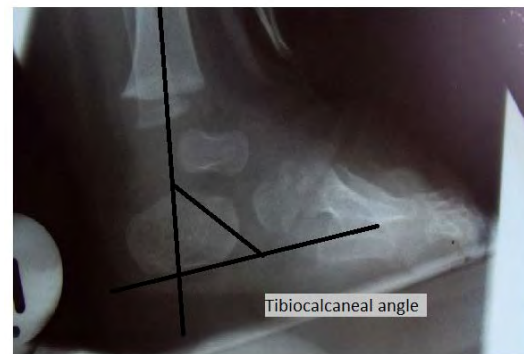


Figure 5. The tibiocalcaneal angle



A decreased lateral talocalcaneal angle, an indicator of the degree of hindfoot varus, has been found to correlate well with poor clinical results by several authors.^{14,17,18,40} Herbsthofer et al compared measured angles in normal feet to clubfeet of varying degrees of severity and found that, though the lateral talocalcaneal angle was generally smaller in clubfeet than in normal feet, high standard deviation precluded the definite assignment of angle measurements to healthy or normal feet, and that severity classification based on angle measurements therefore made no sense.⁴⁰ The AP talocalcaneal angle correlates poorly with clinical findings, this may be due to measurement errors caused by poor visualisation of the proximal ends of the talus and calcaneus on X-rays, as well as the inherent medial deviation of the talar neck, creating a false impression of divergence.^{17,42} The lateral tibiocalcaneal angle was found to correlate with clinical correction, especially dorsiflexion, and was the only radiographic parameter to change following Achilles tenotomy in a study by Radler et al.⁴¹ Hutchins et al found good correlation between the talocalcaneal index and final outcome in their patients. They also noted that the presence of a flattened talar dome, probably as a result of poor ankle movement in utero, was predictive of poor outcome, therefore more severely affected feet performed worse.¹⁶

The value of radiographic measurements in the treatment and follow-up of clubfoot remains controversial. Most authors agree that evaluation of severity and response to treatment should be clinical, with X-rays reserved for those feet that fail to respond to treatment.^{18,29,41}

IX. Discussion

It is clear from this review of the literature that the perfect solution to the complex problem of clubfoot has not yet been found. Significant progress has been made over the years, and it is now possible to obtain cosmetically acceptable and functional feet in most cases of clubfoot, provided

that the treating surgeon adheres to the principles that have been developed and elucidated through years of trial and error. Surgery should be reserved as a last resort for feet that prove resistant to non-surgical treatment as it is clear that the results of extensive soft tissue surgery are inferior to that of purely manipulative treatment. The Ponseti method of treatment has reduced the need for surgery in patients with clubfoot in most of the studies reviewed, though not always to the same extent. It is interesting to note that the decreased rate of major surgery was not nearly as marked in the single South African study³⁸ as in the studies from Western countries. This could be as a result of differing patient demographics, but cannot fully be explained by low socio-economic status as the results from other low socio-economic countries were comparable to that of the developed world.^{31,35} The question of whether or not the Ponseti method is as effective in the South African setting therefore remains, warranting further investigation.

Radiographic investigation, though widely available and inexpensive, still constitutes a valuable resource and exposes the patient to radiation risk, albeit minimal. There is some controversy regarding the value of X-rays in the diagnosis, classification and management of clubfoot, and its exact role is yet to be clearly defined. It therefore would also be useful to assess the role of X-rays in the management of clubfoot in our setting, with the aim of tailoring existing protocols based on the findings of this study.

The topic of clubfoot has been thoroughly researched and certain factors, such as non-compliance with bracing, have been identified repeatedly as cause for treatment failure. Further research should therefore be aimed at addressing this deficit. The exact aetiology and genetic influence of clubfoot have not yet been established, and this is also a potential subject for ongoing research.

X. Quality Criteria

To ensure the quality of the research produced, the following steps will be taken by the researchers:

1. To ensure homogeneity of the two cohorts compared, all patients presenting to our clubfoot clinic will be screened for inclusion, but strict exclusion criteria will be enforced as outlined in the research protocol
2. All available records will be utilised to ensure completeness of data collected. The surgical notes of all patients operated at our unit is stored on a local database and is therefore available for scrutiny.
3. On measuring the radiographic angles, the investigator will be blinded to the group allocation of the patient in question to eliminate bias.
4. A single investigator will perform all measurements to eliminate interobserver variation
5. The statistical analysis will be performed by an independent entity with no formal medical training and no invested interest in the outcome of the research in question
6. The results of the study will be submitted to a peer reviewed local journal for publication.
7. None of the researchers will have any financial or other interest vested in the outcome of the research.

XI. References

1. Wainwright AM, Auld T, Benson MK, et al. The classification of congenital talipes equinovarus. *J Bone Joint Surg [Br]*. 2002;**84-B(7)**:1020–4.
2. Dobbs M, Gurnett C. Genetics of clubfoot. *J Pediatr Orthop B*. 2012;**21(1)**:7–9.
3. Morcuende JA, Dolan LA, Dietz FR, et al. Radical Reduction in the Rate of Extensive Corrective Surgery for Clubfoot Using the Ponseti Method. *Pediatrics*. 2004;**113(2)**:376–80.
4. Lehman WB, Mohaideen A, Madan S, et al. A method for the early evaluation of the Ponseti (Iowa) technique for the treatment of idiopathic clubfoot. *J Pediatr Orthop B*. 2003;**12(2)**:133–40.
5. Ballantyne JA, Macnicol MF. Mini-symposium: The paediatric foot. (i) Congenital talipes equinovarus (clubfoot) : an overview of the aetiology and treatment. *Curr Orthop*. 2002;**16**:85–95.
6. Dobbs MB, Gurnett CA. Update on clubfoot: etiology and treatment. *Clin Orthop Relat Res*. 2009;**467(5)**:1146–53.
7. Fukuhara K. The pathogenesis of club foot. A histomorphometric and immunohistochemical study of fetuses. *J Bone Joint Surg [Br]*. 1994;**76-B(3)**:450–7.
8. Waisbrod H. Congenital Club Foot. An Anatomical Study. *J Bone Joint Surg [Br]*. 1973;**55-B(4)**:796–801.
9. Ponseti IV, Smoley E. Congenital Clubfoot: The Results of Treatment. *J Bone Joint Surg [Am]*. 1963;**45-A**:261–344.
10. Pirani S. A reliable method of clinically evaluating a virgin clubfoot. *21st SICOT congress* 1999.
11. Scher DM, Feldman DS, van Bosse HJP, et al. Predicting the need for tenotomy in the Ponseti method for correction of clubfeet. *J Pediatr Orthop*. 2004;**24(4)**:349–52.
12. Dyer PJ, Davis N. The role of the Pirani scoring system in the management of club foot by the Ponseti method. *J Bone Joint Surg [Br]*. 2006;**88-B(8)**:1082–4.
13. Dobbs MB, Nunley R, Schoenecker PL. Long-Term Follow-up of Patients with Clubfeet Treated with Extensive Soft-Tissue Release. *J Bone Joint Surg [Am]*. 2006;**88-A(5)**:986–96.
14. Turco V. Surgical Correction of the Resistant Clubfoot. *J Bone Joint Surgery [Am]*. 1971;**53-A(3)**:477–97.

15. Hudson I, Catterall A. Posterolateral Release for Resistant Club Foot. *J Bone Joint Surg [Br]*. 1994;**76-B(2)**:281–4.
16. Hutchins P, Foster B, Paterson D, et al. Long-term results of early surgical release in club feet. *J Bone Joint Surg [Br]*. 1985;**67(5)**:791–9.
17. Thompson G, Richardson A, Westin G. Surgical management of resistant congenital talipes equinovarus deformities. *J Bone Joint Surg [Am]*. 1982;**64-A(5)**:652–65.
18. Laaveg SJ, Ponseti IV. Long-Term Results of Treatment of Congenital Club-Foot. *J Bone Joint Surg [Am]*. 1980;**62-A(1)**:23-31.
19. Kite JH. The Treatment of Congenital Clubfeet. *J Am Med Assoc*. 1932;**99(14)**:1156–62.
20. Fripp AT, Show NE. *Club-Foot*. London: E. & S. Livingstone LTD; 1967:70-71
21. Richards BS, Johnston CE, Wilson H. Nonoperative clubfoot treatment using the French physical therapy method. *J Pediatr Orthop*. 2005;**25(1)**:98–102.
22. Kite JH. Principles involved in the treatment of congenital club-foot. *J Bone Joint Surg*. 1939;**21(3)**:595–606.
23. Kite JH. Some Suggestions on the Treatment of Club Foot by Casts. *J Bone Joint Surg [Am]*. 1963;**45-A(2)**:406–12.
24. Singer M, Fripp A. Tibialis anterior transfer in congenital club foot. *J Bone Joint Surg [Br]*. 1958;**40-B(2)**:252–5.
25. Herzenberg JE, Radler C, Bor N. Ponseti Versus Traditional Methods of Casting for Idiopathic Clubfoot. *J Pediatr Orthop*. 2002;**22(4)**:517–21.
26. Souchet P, Bensahel H, Themar-Noel C, et al. Functional treatment of clubfoot: a new series of 350 idiopathic clubfeet with long-term follow-up. *J Pediatr Orthop B*. 2004;**13(3)**:189–96.
27. Van Campenhout A, Molenaers G, Moens P, et al. Does functional treatment of idiopathic clubfoot reduce the indication for surgery? Call for a widely accepted rating system. *J Pediatr Orthop*. 2001;**10(4)**:315–8.
28. Ponseti IV. Treatment of congenital clubfoot. *J Bone Joint Surg [Am]*. 1992;**74-A(3)**:448–54.
29. Ponseti IV. Current concepts: Common errors in the treatment of congenital clubfoot. *Int Orthop*. 1997;**21**:137–41.
30. Cooper DM, Dietz FR. Treatment of Idiopathic Clubfoot. *J Bone Joint Surg [Am]*. 1995;**77-A(10)**:1477–89.
31. Gupta A, Singh S, Patel P, et al. Evaluation of the utility of the Ponseti method of correction of clubfoot deformity in a developing nation. *Int Orthop*. 2008;**32(1)**:75-79.
32. Sud A, Tiwari A, Sharma D, et al. Ponseti's versus Kite's method in the treatment of clubfoot--a prospective randomised study. *Int Orthop*. 2008;**32(3)**:409–13.

33. Boden RA, Nuttall GH, Paton RW. A 14-year longitudinal comparison study of two treatment methods in clubfoot : Ponseti versus traditional. *Acta Orthop Belg.* 2011;**77**:522–8.
34. Halanski MA, Davison JE, Huang J-C, et al. Ponseti method compared with surgical treatment of clubfoot: a prospective comparison. *J Bone Joint Surg [Am].* 2010;**92(2)**:270–8.
35. Rijal R, Shrestha BP, Singh GK, et al. Comparison of Ponseti and Kite’s method of treatment for idiopathic clubfoot. *Indian J Orthop.* 2010;**44(2)**:202–7.
36. Zwick EB, Kraus T, Maizen C, et al. Comparison of Ponseti versus surgical treatment for idiopathic clubfoot: a short-term preliminary report. *Clin Orthop Relat Res.* 2009;**467(10)**:2668–76.
37. Richards B, Faulks S, Rathjen K. A comparison of two nonoperative methods of idiopathic clubfoot correction: the Ponseti method and the French functional (physiotherapy) method. *J Bone Joint Surg [Am].* 2008;**90-A(11)**:2313-2321
38. Molteno R, Colyn S. The treatment of idiopathic clubfoot: A comparison of two methods of manipulative treatment. *South African Orthop J.* 2005;**2**:12–8.
39. Simons G. Analytical radiography of club feet. *J Bone Joint Surg [Br].* 1977;**59-B(4)**:485–9.
40. Herbsthofer B, Eckardt A, Rompe JD, et al. Significance of radiographic angle measurements in evaluation of congenital clubfoot. *Arch Orthop Trauma Surg.* 1998;**117(6-7)**:324–9.
41. Radler C, Manner HM, Suda R, et al. Radiographic evaluation of idiopathic clubfeet undergoing Ponseti treatment. *J Bone Joint Surg [Am].* 2007;**89(6)**:1177–83.
42. Ippolito E, Fraracci L, Farsetti P, et al. Validity of the anteroposterior talocalcaneal angle to assess congenital clubfoot correction. *Am J Roentgenol.* 2004;**182(5)**:1279–82

Part C - Published Manuscript

**The effect of two different plastering
techniques on the rate of major surgery in
idiopathic clubfoot**

**A Horn
S Dix-Peek
EB Hoffman**

**South African Orthopaedic Journal
Summer 2013
12(14): 28-32**

The effect of two different plastering techniques on the rate of major surgery in idiopathic clubfoot

A Horn, MBChB(Pret)

Registrar, Department of Orthopaedics, University of Cape Town

SI Dix-Peek, MBChB(UCT), FCS(SA)Ortho

Head of Paediatric Orthopaedics Red Cross Children's Hospital and Maitland Cottage Paediatric Orthopaedic Hospital, Department of Orthopaedics, University of Cape Town

EB Hoffman, MBChB(UCT), FCS(SA)Ortho

Associate Professor (retired)

Correspondence:

Dr Anria Horn

Postnet Suite 342

Private Bag X18

Rondebosch 7701

Cape Town

Email: anriahorn@gmail.com

Cell: 071 679 4228

Work: 021 404 5108

Abstract

Background

The Ponseti technique of clubfoot manipulation and casting is reported to have almost eliminated the need for extensive surgery (posterior and posteromedial release) and surgical decision-making is now largely based on clinical assessment, as opposed to pre-operative radiographs. The Ponseti method of manipulation and casting was introduced at our institution in 2002, prior to which we used the Kite method. Both prior to, and following the introduction of Ponseti casting, surgical decision-making was based on pre-operative radiology, and intra-operative clinical assessment.

Methods

A retrospective comparative study was performed to compare the incidence of radical surgery following the use of the Kite method versus the Ponseti method. In addition, the accuracy of measured radiographic parameters in predicting which surgery was to be performed was investigated.

Results

The incidence of radical surgery decreased from 40% with the Kite method to zero with the Ponseti method. Of the four routinely measured radiographic angles, only the tibio-calcaneal angle and the talometatarsal angle significantly correlated with the extent of surgery performed.

Conclusions

Using the Ponseti method greatly decreases the need for radical surgery in idiopathic clubfoot. Radiographic measurements do not influence surgical decision-making significantly.

Key words: clubfoot, Ponseti, posteromedial release, radiographic, angles

Introduction

Most orthopaedic surgeons agree that the initial treatment for idiopathic clubfoot should consist of gentle manipulation and serial casting, with surgery being reserved for resistant and relapsed feet.¹⁻³ Many methods of manipulation and casting have been described, with varying degrees of success.

Kite described a technique whereby forefoot adduction was corrected first by abduction, using the calcaneocuboid joint as a fulcrum. Once this was corrected, the heel could be everted and lastly, the equinus corrected.^{4,5} Although Kite advocated conservative treatment with casting and even wedging of casts, most surgeons performed either a posterior release (PR)^{6,7} or a posteromedial release (PMR) for residual deformity based on clinical and/or radiographic evaluation.⁸⁻¹⁰

Ponseti revolutionised the treatment of clubfoot with the publication of his method in 1963.¹¹ Based on thorough understanding of the three-dimensional patho-anatomy of the clubfoot, he developed his treatment principles. He emphasised that the cavus deformity is caused by pronation of the forefoot in relation to the hindfoot, and should be corrected first in order to realign the foot. He also stated that abduction of the forefoot should occur around the head of the talus, not at the calcaneocuboid joint, as this manoeuvre would successfully unlock the calcaneus from under the talus, allowing dorsiflexion to be achieved, usually with the aid of a percutaneous Achilles tenotomy.^{11,12} The indication for Achilles tenotomy was assessed clinically without radiographs. Pirani subsequently described a clinical classification which is now routinely used.¹³

Ponseti reported 74% good to excellent results using this method, although 40% of patients required Achilles tendon lengthening, and 46% tibialis anterior transfer for dynamic forefoot varus, the tibialis anterior transfers performed after the age of 2.5 years.¹⁴ Subsequent studies showed superior results to previous methods with the need for radical surgery being almost completely eliminated.

Many methods of manipulation and casting have been described, with varying degrees of success

Some controversy still exists around the performance of a PMR as primary surgical intervention for idiopathic clubfoot. Many authors believe that even though PMR leads to correction of the anatomical deformity on radiographs, and has excellent short-term results, it leads to considerable stiffness of the foot and ankle at late follow-up, and recurrences as well as overcorrections are frequently observed.^{11,12,15} Other authors have found that patients undergoing PMR primarily have less need for subsequent operations¹⁶ and also better outcomes, as evidenced by better muscle strength, less hindfoot varus and less subtalar stiffness, when compared to patients who had minor surgical procedures.^{16,17} Turco, who first described the PMR as we know it today, claimed a 83% good or excellent result at 15-year follow-up, and found the best results were achieved in patients who were operated between one and two years of age.^{8,18}

In this study the Ponseti method of treatment for idiopathic clubfoot was introduced in 2002. Prior to this, serial manipulation and casting was performed in the method described by Kite.⁵ PMR was performed on those feet that displayed inadequate talocalcaneal divergence (<20°) on pre-operative radiographs, or intra-operatively, where persistent cavus and hindfoot varus was evident after posterior release had been performed. It was noted that since adopting the Ponseti method of manipulation, the rate of major surgery (PMR) as primary surgical intervention for idiopathic clubfoot, decreased significantly.

The purpose of this study is to quantify retrospectively the change in incidence of major surgery since the introduction of the Ponseti method. Additionally, the value of pre-operative radiographs was assessed as a tool for predicting the extent and complexity of surgery, i.e. PR vs PMR.

Patients and methods

A retrospective review of the clinical records and radiographs of all patients presenting to our clubfoot clinic was performed. Two cohorts were identified; those from 1999–2000 (pre-Ponseti) and those from 2009–2010 (Ponseti). The groups were chosen to represent patients preceding and following the introduction of a different plastering technique introduced in 2002. Patients were included in the study if they had idiopathic clubfoot, presented within the first three months of life and had received no prior treatment. Teratological clubfeet were excluded. Ethical approval was obtained from our institution's Research Ethics Committee.

In the pre-Ponseti group there were 60 patients with 85 clubfeet. There were 24 females and 36 males; 25 were bilateral, 19 were left-sided and 16 were right-sided. Average age at presentation was 4.2 weeks (range 1–12 weeks), average number of plasters applied was 9 (range 0–18). Average age at first surgery was 10.3 months (range 3–44).

In the Ponseti group there were 50 patients with 70 clubfeet. There were 16 females and 34 males; 20 cases were bilateral, 11 were left-sided, and 19 were right-sided. Average age at presentation was 4 weeks (range 0–12), average number of plasters applied was 7 (range 1–14). Average age at surgery was 6.7 months (range 3–18 months).

Table 1. Carroll assessment criteria for clubfoot (total score 0–10)¹⁹

| | Assessment criteria | Score |
|----|---|-------|
| 1 | Calf atrophy | |
| 2 | Posterior displacement of lateral malleolus | |
| 3 | Creases, medial or posterior | |
| 4 | Curved lateral border | |
| 5 | Cavus | |
| 6 | Fixed equinus | |
| 7 | Navicular fixed to medial malleolus | |
| 8 | Os calcis fixed to fibula | |
| 9 | No mid-tarsal mobility | |
| 10 | Fixed forefoot supination | |

Table II. Average measured angles for different surgical groups

| Surgical group | AP talocalcaneal angle | Talometatarsal-I angle | Lateral talocalcaneal angle | Tibiocalcaneal angle |
|-----------------------|------------------------|------------------------|-----------------------------|----------------------|
| Posteromedial release | 21.87 | 36.88 | 12.72 | 120 |
| Minor surgery | 22.34 | 17.25 | 22.01 | 102.75 |
| No surgery | 29.14 | 6.07 | 35.64 | 68.42 |
| Normal range | 15–30 | 0–(–20) | 25–35 | 25–60 |

Radiographic parameters were measured in all cases where radiographs were available by a single investigator (AH). The angles measured were on the antero-posterior (AP) view, the talocalcaneal angle and the talometatarsal-I angle; and on the lateral view, the talocalcaneal and the tibiocalcaneal angle. All radiographs were performed in a standardised fashion as described by Simons,⁹ and were taken after the initial period of plaster casting, prior to surgery. Pre-operative clinical severity was quantified using the scoring system described by Carroll (Table I).¹⁹

Statistical analysis

The Chi-square test was performed to determine the significance of the change in rate of posteromedial release being performed as primary surgical intervention.

In order to determine the predictive value of pre-operative radiographs in determining whether major surgery was to be performed, the data from both cohorts were pooled. This follows the fact that surgical decision-making for both groups was performed either by, or under the supervision of the same surgeon (EBH). The patients were divided into three groups as follows: major surgery (PMR), minor surgery and no surgery. Analysis of variance (ANOVA) tests were performed on the data sets that were normally distributed, and if the data was not normally distributed, the Kruskal-Wallis test of significance was performed.

Results

In the pre-Ponseti group 34 of the 85 feet (40%) had a PMR as primary intervention. Posterior release (PR) was performed on 41 feet (48%); three feet (4%) were treated with a percutaneous tenotomy; and the remaining seven feet (8%) required no surgery. The average pre-operative Carroll score was 8 for the patients treated with PMR, and 2.8 for patients treated with PR or lesser surgeries.

In the Ponseti group, PMR was performed on no patients as primary surgical intervention. PR was performed on 32 feet (48%); 12 feet (17%) had formal elongation of the Achilles tendon (ETA); percutaneous tenotomy was performed on two feet only (3%); 18 feet (26%) required no surgery; and four patients were lost to follow up after initial presentation. The average Carroll score for patients undergoing PR was 3.8 and for patients undergoing ETA 2.4.

The decrease in the rate of major surgery was found to be highly statistically significant using the Chi-square test ($p \leq 0.002$). In addition the average Carroll score decreased from 6.8 in the pre-Ponseti group to 3.4 in the Ponseti group.

Table III. Results of statistical analysis

| Radiographic angle | F-statistic | P-value | Significance |
|-----------------------------|-------------|---------|---------------|
| Tibiocalcaneal angle | 2.21 | 0.0009 | High |
| Talometatarsal-I angle | – | 0.0002 | High |
| Lateral talocalcaneal angle | 1.11 | 0.33 | Insignificant |
| AP talocalcaneal angle | 0.80 | 0.77 | Insignificant |

The average measured radiographic angles for the different surgical groups are summarised in Table II, and the results of the statistical analysis in Table III. The one-way analysis of variance was determined for all angles except the AP talometatarsal-I angle, for which the Kruskal-Wallis test was performed, as the data for this angle was not normally distributed. A p-value of 0.05 was chosen as the cut-off for significance. Graphic illustration of the distribution of measured angles in the different groups is provided in Figures 1–4.

Discussion

In this study, the average pre-operative Carroll score changed from 6.8 to 3.4 after the introduction of the Ponseti plastering technique. In addition, and more clinically relevant, 40% of patients in the group treated with the traditional manipulation and casting technique required PMR as primary intervention, whereas in the Ponseti group, not one PMR was performed as initial surgical intervention for idiopathic clubfoot. This result was found to be highly statistically significant using the Chi-square test ($p < 0.002$).

Herzenberg *et al* previously compared the rate of PMR between patients treated by traditional means to those treated with a strict Ponseti protocol. In his control group, 32 out of 34 patients required PMR, in the Ponseti group, only one PMR was performed in 34 patients, and this was after multiple recurrences due to persistent non-compliance with abduction bracing. At follow-up, he also noted significantly decreased subtalar and ankle motion in the group treated with early PMR.²

In their review of 70 patients treated with strict Ponseti protocol including bracing, Firth *et al* found a very low rate of major surgery (7%) and only a 23% recurrence rate requiring repeat bracing. Included in this study were teratological clubfeet.²⁰

In this study, in the Ponseti group, not one PMR was performed as initial surgical intervention for idiopathic clubfoot

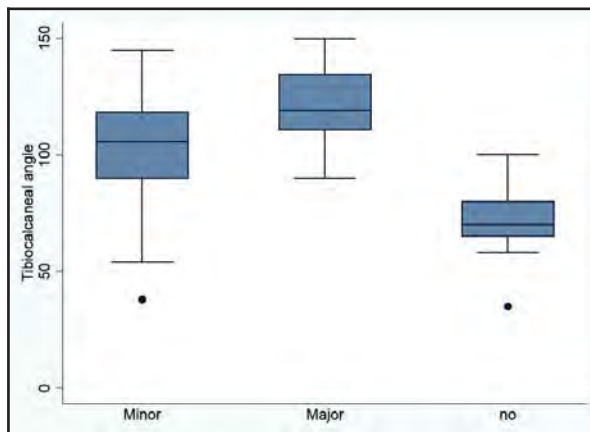


Figure 1. Box plot of tibiocalcaneal angle for different groups

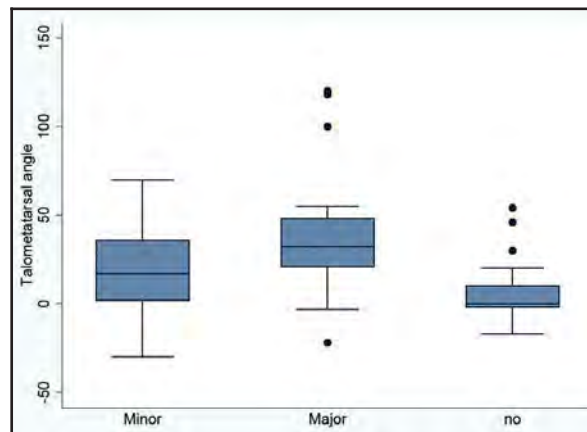


Figure 2. Box plot of talometatarsal-I angles for different groups

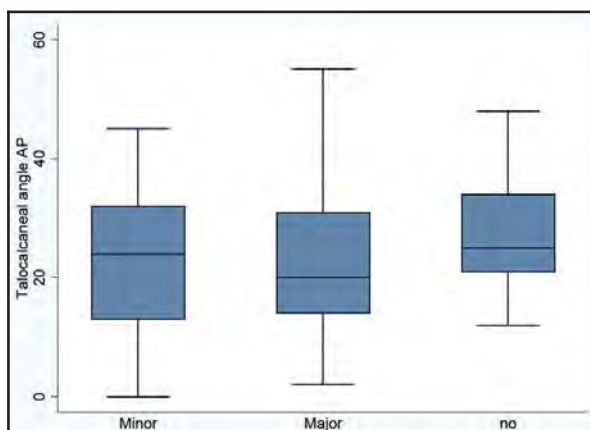


Figure 3. Box plot of AP talocalcaneal angles for different groups

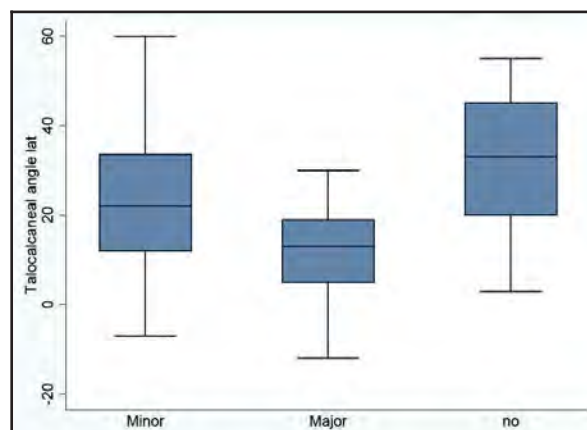


Figure 4. Box plot of lateral talocalcaneal angles for different groups

In contrast to these findings, in a similar review by Molteno and Colyn, 897 idiopathic clubfeet treated from 1978–2003 were evaluated. In their study the rate of PMR as primary surgical intervention, decreased from 85.1% to 64.5% after changing plastering techniques from the Kite method to the Ponseti method. They stated that this relatively high rate of major surgery is attributed to the nature of the patients attending their clinic, noting that patients had to travel hundreds of kilometres to attend the clinic, and that compliance was low, therefore necessitating more radical intervention at an earlier stage.²¹ The pre-operative criteria for determining the degree of surgery to be performed was not included in this study.

Radiography

The talocalcaneal angle, on both the AP and lateral projections, is the most commonly quoted radiographic measure in clubfoot literature and is thought to be a measure of correction of hindfoot varus. Simons wrote extensively on the subject and found that a combination of an AP talocalcaneal angle of less than 15° and a talometatarsal-I angle of

In our study, both the tibiocalcaneal angle and the AP talometatarsal-I angle were significantly related to the degree of surgery performed

more than 15° always indicated the presence of talonavicular subluxation.⁹ In our study, neither the AP nor the lateral talocalcaneal angle were found to be significantly related to the degree of surgery performed. This is in agreement with Radler *et al.*,³ who noted a poor correlation between these two angles and clinical severity as measured using the Pirani¹³ and Diméglio²² scores. Contrary to this, several authors, including Laaveg,¹ Ponseti and Turco⁸ found the lateral talocalcaneal angle to be a good indicator of clinical severity. Thompson *et al* concluded that of all radiographic measures, the lateral talocalcaneal angle had the best correlation with clinical severity and the AP talocalcaneal angle the worst.¹⁶

In our study, both the tibiocalcaneal angle and the AP talometatarsal-I angle were significantly related to the degree of surgery performed.

The talometatarsal-I angle is a measure of forefoot adduction and normal ranges vary with age²³ but is generally considered to 0° to -20°, with any positive value considered abnormal.⁹ The tibio-calcaneal angle is measured on the lateral projection between a line parallel with the axis of the tibia and a line parallel with the plantar surface of the calcaneus, and is indicative of the degree of hindfoot equinus. This angle measures 25°-60° in normal feet and was also found to correlate well with the Pirani and Diméglio scores respectively by Radler *et al.*³

Herbsthofer *et al* performed a statistical analysis in order to determine the significance of radiographic measurements in clubfoot. They found that clubfeet did have on average a smaller talocalcaneal (TC) angle (AP and lateral) but due to high standard deviations, definite assignment of angle measurements to healthy feet or clubfeet was not possible. They also felt that a differentiated distribution of clubfoot change according to degrees of severity based on the TC angle would make no sense. They concluded that the routine use of radiographic studies in the diagnosis, classification and follow-up of clubfoot does not appear to be a useful tool in view of the wide range of deviation of values within individual clinical groups.²⁴ Radler *et al* concluded that, although there was generally poor correlation between radiographic measurements and clinical severity in clubfoot, X-rays were useful in diagnosing pseudo-correction and aiding decision to do a tenotomy.³ In our study, even though there was correlation between the tibio-calcaneal angle and the talometatarsal-I angle, radiography did not supersede the value of clinical evaluation in deciding the need for surgery and the extent thereof.

We conclude that, based on our results and a review of the current literature, the Ponseti method of casting significantly reduces the need for major surgery in the treatment of idiopathic clubfoot, compared to traditional methods.

We also suggest that the use of routine radiographs in the treatment of clubfoot does not appear to contribute to decision-making and is therefore not justified.

The content of this article is the sole work of the authors. No benefits of any form have been or are to be received from a commercial party related directly or indirectly to the subject of this article. The research has been approved by the Research Ethics Committee, Health Sciences Faculty, University of Cape Town (ref: 349/2008).

References

- Laaveg SJ. Long-term results of treatment of congenital club foot. *Journal of Bone and Joint Surgery [Am]* 1980;**62**(1):23-31.
- Herzenberg JE. Ponseti versus traditional methods of casting for idiopathic clubfoot. *J Pediatr Orthop* 2002;**22**(4):517-21.
- Radler C. Radiographic evaluation of idiopathic clubfeet undergoing Ponseti treatment. *Journal of Bone and Joint Surgery [Am]* 2007;**89**(6):1177-83.
- Fripp AT, Shaw NE. *Club-foot*. 1st ed. London: E. & S. Livingstone; 1967.
- Kite JH. *The Clubfoot*. 1st ed. New York: Grune & Stratton, Inc.; 1964.
- Attenborough G. Early posterior soft-tissue release in severe congenital talipes equinovarus. *Clinical Orthopaedics and Related Research* 1972;**3**(1):10-21.
- Hudson I. Posterolateral release for resistant club foot. *Journal of Bone and Joint Surgery [Br]* 1994;**76**(2):281-84.
- Turco VJ. Surgical correction of the resistant club foot one-stage posteromedial release with internal fixation: A preliminary report. *Journal of Bone and Joint Surgery [Am]* 1971;**53**(3):477-87.
- Simons GW. Analytical radiography of club feet. *Journal of Bone and Joint Surgery [Br]* 1977;**59**(4):485-90.
- Beatson TR. A method of assessing correction in club feet. *Journal of Bone and Joint Surgery [Br]* 1966;**48**(1):40-50.
- Ponseti IV, Smoley EN. Congenital clubfoot: The results of treatment. *Journal of Bone and Joint Surgery [Am]* 1963 March;**45**(2):261-344.
- Ponseti IV. Treatment of congenital club foot. *Journal of Bone and Joint Surgery [Am]* 1992 March;**74**(3):448-54.
- Pirani S. A reliable and valid method of assessing the amount of deformity in the congenital clubfoot deformity. *Journal of bone and joint surgery [Br]* 2008;**90**(Suppl 1):53.
- Laaveg SJ, Ponseti IV. Long-term results of treatment of congenital clubfoot. *Journal of Bone and Joint Surgery [Am]* 1980;**62**(1):23-31.
- Cooper DM. Treatment of idiopathic clubfoot. A thirty-year follow-up note. *Journal of Bone and Joint Surgery [Am]* 1995;**77**(10):1477-89.
- Thompson GH, Richardson AB, Westin GW. Surgical management of resistant congenital talipes equinovarus deformities. *Journal of Bone and Joint Surgery [Am]* 1982;**64**(5):652-65.
- Haasbeek JF. A comparison of the long-term results of posterior and comprehensive release in the treatment of clubfoot. *J Pediatr Orthop* 1997;**17**(1):29-35.
- Turco VJ. Resistant congenital club foot - one-stage posteromedial release with internal fixation. A follow-up report of a fifteen-year experience. *Journal of Bone and Joint Surgery [Am]* 1979;**61**(6A):805-14.
- Carroll NC, McMurty R, Leete SF. The pathoanatomy of congenital clubfoot. *Orthopedic clinics of North America* 1978;**9**(1):225-32.
- Firth G, Eltringham M, Shnier G. Early results of the Ponseti technique for a clubfoot clinic in South Africa. *South African Orthopaedic Journal* 2009;**8**(Summer):67-72.
- Moltano R, Colyn S. The treatment of idiopathic clubfoot: A comparison of two methods of manipulative treatment. *South African Orthopaedic Journal* 2005;**4**(May):12-18.
- Diméglio A, Bensahel H, Souchet PH *et al*. Classification of Clubfoot. *J Pediatr Orthop B*;1995;**4**(2):129-36.
- Vanderwilde R, Stahelli LT, Chew DE *et al*. Measurements on radiographs of the foot in normal infants and children. *Journal of Bone and Joint Surgery* 1968;**70**(3):407-15.
- Herbsthofer B. Significance of radiographic angle measurements in evaluation of congenital clubfoot. *Arch Orthop Trauma Surg* 1998;**117**(6):324-29.

Part B - Appendices

I. Acknowledgements

Description of roles played by each co-author.

| | |
|-----------------|---|
| Dr A Horn | Principle investigator and primary author |
| Dr S Dix-Peek | Supervisor and editor of final script |
| Prof EB Hoffman | Supervisor and academic counsellor |

II. Ethics approval



UNIVERSITY OF CAPE TOWN

Faculty of Health Sciences
Human Research Ethics Committee
Room E52-24 Groote Schuur Hospital Old Main Building
Observatory 7925
Ms S Ariefdien - Tel: [021]4066492 • Fax: [021]4066411
email: sumayah.ariefdien@uct.ac.za

14 November 2012

HREC REF: 611/2012

Dr A Horn,
Orthopaedics Surgery
H-49
OMB

Dear Dr Horn,

PROJECT TITLE: THE EFFECTS AT A CHANGE IN PLASTERING TECHNIQUE ON THE RATE AT MAJOR SURGERY IN CTEU

Thank you for submitting your new study to the Faculty of Health Sciences Human Research Ethics Committee

It is a pleasure to inform you that the Ethics Committee has formally approved the above-mentioned study.

Approval is granted until 15 November 2013

Please submit an annual progress report (FHS016) if the research continues beyond the expiry date. Please submit a brief summary of findings if you complete the study within the approval period so that we can close our file (FHS010).

Please note that the ongoing ethical conduct of the study remains the responsibility of the principal investigator.

Please quote the HREC. REF in all your correspondence.

Yours sincerely

PROFESSOR MARC BLOCKMAN
CHAIRPERSON, FHS HUMAN RESEARCH ETHICS

Federal Wide Assurance Number: FWA00001637.
Institutional Review Board (IRB) number: IRB00001938

This serves to confirm that the University of Cape Town Human Research Ethics Committee complies to the Ethics Standards for Clinical Research with a new drug in patients, based on the Medical Research Council (MRC-SA), Food and Drug Administration (FDA-USA), International Convention on Harmonisation Good Clinical Practice (ICH GCP) and Declaration of Helsinki guidelines.

The Human Research Ethics Committee granting this approval is in compliance with the ICH Harmonised Tripartite Guidelines E6: Note for Guidance on Good Clinical Practice (CPMP/ICH/135/95) and FDA Code Federal Regulation Part 50, 56 and 312.