

**Traumatic Posterior Fracture-dislocation**  
**of the Hip Joint**  
**in Adults**

by

**David M Selvey, MB BCh (Wits), FRCS (Glas.), FCS (SA) Orth.**

**As Part of the Requirements  
for the  
Part III of Masters of Medicine in Orthopaedics**

**Supervisor: Dr. Gordon M Siboto**

The copyright of this thesis vests in the author. No quotation from it or information derived from it is to be published without full acknowledgement of the source. The thesis is to be used for private study or non-commercial research purposes only.

Published by the University of Cape Town (UCT) in terms of the non-exclusive license granted to UCT by the author.

## **Declaration**

I declare that the work contained in this research report is original and has not been used for any other degree.

The University may reproduce the thesis for the purposes of research.

## **Acknowledgements**

To all my colleagues who contribute to making the Orthopaedic Department of Cape Town the institution that it is. Despite unsettling times they strive to maintain the standards, which are synonymous with this department.

Specifically to Dr Gordon Siboto who afforded me the opportunity to review his work. He has been a great strength both as a colleague and a friend. Mike Giliam is another friend whose efforts were deeply appreciated.

Especially to Susan Williams, my wife who has always motivated me with her love and endless energy.

Finally to Zoe, Huw, Teagan and Carys who have sacrificed a large part of their time with their father to allow him to pursue his studies and career.

## Table of Contents

1. Introduction.....	1
2. Literature Study .....	3
2.1 A Review of the Literature.....	3
2.2 Summary of Literature Findings.....	13
2.3 Discussion of Literature.....	15
3. Patient Profile in this Series.....	18
4. The Value of the Obturator-Oblique View with the Hip Still Dislocated.....	23
4.1 Introduction.....	23
4.2 Method of Research.....	24
4.3 Results.....	27
4.4 Discussion .....	28
4.5 Conclusion.....	29
5. The Mechanism of Injury in Posterior Fracture-dislocation of the Hip Joint.....	34
5.1 Introduction.....	34
5.2 Method of Research.....	35
5.3 Results.....	35
5.4 Discussion .....	36
5.5 Conclusion.....	37
6. A Modification of the Thompson Epstein Classification .....	38
6.1 Introduction.....	38
6.2 Method of Research.....	39
6.3 Results.....	40
6.4 Discussion .....	40
6.5 Conclusion.....	41
7. The Relevance of Stability? .....	42
7.1 Introduction.....	42
7.2 Method of Research.....	42
7.3 Results.....	43
7.4 Discussion .....	44
7.5 Conclusion.....	45
8. Research Summary .....	47
8.1 A Proposed Protocol for the Management of Hip Dislocations.....	47
9. References .....	51

## Table of Figures

Fig. 1 and 2	Associated femoral shaft fracture	19
Fig.3	Associated femoral fracture	20
Fig. 4 and 5	Progression onto avascular necrosis at six weeks	21
Fig. 6 and 7	Post surgery AVN at 6 weeks	22
Fig. 8 and 9	Demonstration of the "Serendipity Obturator-oblique dislocated view"	25
Fig. 10	The Serendipity OOD-view	26
Fig. 11 and 12	Comparison of OOD-view and OOReduced view.	30
Fig. 13 and 14	Complementation of OOD and OOReduced view.	31
Fig. 15 and 16	Oblique view taken with beam tilted 45° rather than patient.	32
Fig. 17 and 18	Comparison of OOD-view and OOReduced view.	33
Fig. 19	A stable hip that required surgery.	46

## **1. Introduction**

During the period July 1994 to September 1998 surgery was carried out on seventy-six hips in seventy-five patients that sustained posterior fracture-dislocation of their hip joints. During my training I was personally involved in thirteen of these cases and was the primary surgeon in seven cases.

Because of my personal interest in these patients Dr Siboto provided me the records of all seventy-five patients for my scrutiny. While he has carried out the surgery on all but the seven cases which I operated on, the literature review, the correlating of the data and all of the interpretation is my own personal work.

At surgery prospective records were kept of the degree of comminution of the fracture, the presence of marginal impacting and the presence of fragments in the joint. Fractures were then classified according to Thompson and Epstein (1951). The surgical time was recorded as well as the nature of the associated acetabular floor fracture when it occurred. Anatomical reconstruction was always attempted including elevation of marginal impaction and bone grafting where appropriate. Fragments were only discarded when too small and unattached to permit their inclusion in the reconstruction. All patients had neurological assessment preoperatively and their Sciatic nerves were explored and the state of the nerve recorded at surgery.

The process of formulating this dissertation took place over a two-year period from September of 1997 until June of 1999. As a result the number of patients examined in relationship to a specific subject is not constant but alters according to the group under scrutiny at that particular point in time. An initial review of sixty cases in September 1997 was carried out and then an additional fifteen patients up until September 1998 were included where relevant.

The aim of carrying out this study was to gain a better understanding of this injury so that we could formulate a management protocol for our patients in Groote Schuur Hospital. First of all I reviewed the literature to discover exactly what has been written about this pathology. In the process I hoped to gain a better understanding of the problem and attempt to define a more concise approach to the injury by consolidating the broad array of articles written on this subject. Then by reviewing our findings in our large series of patients I aimed to discover whether we were encountering similar problems to the surgeons who had preceded us and whether we had made any new discoveries that might positively contribute to the future management of these patients.

After an extensive review of the English literature it became apparent that because of the infrequency of this injury much of the knowledge about its management is based on a framework provided by early surgeons and then added to by the experience of those who followed. Many early practices dictated by the expertise of the time have persisted despite having questionable value today. By reviewing the experience at Groote Schuur Hospital this dissertation will hopefully add positively to the pool of knowledge that forms the foundation for management planning of this problem.

This series of patients comprised two groups. The first group was managed at Groote Schuur Hospital from presentation until discharge. The second group was managed at an outlying hospital and then referred for subsequent management. Three patients had irreducible hips. All other patients underwent surgery for reconstruction of the posterior wall with removal of fragments from the joint and elevation and bone graft of marginal impaction where present. Of the three patients that were irreducible, they were all referred after several days and therefore underwent full investigation including CT prior to surgery.

Unfortunately only a little over half of these patients returned for their twelve month follow up. Consequently I decided to concentrate on the information that was available for assessment. The first and obvious is the literature. I endeavoured to locate every article written on this topic in the English literature between 1929 and 1997 and gleaned from these articles the experience of previous surgeons. Then I looked at four specific aspects of the subject. The first was a review of the patients' radiographs, which could be easily scrutinised with out any need for the patients to return. The second is a review of the mechanism of injury that the patients sustained to induce their fracture-dislocation. The third is a review of the classification of Thompson and Epstein as it related to our experience in applying it to our patients. The fourth is a discussion on the relevance of testing these patients for stability after their initial reduction. Each aspect will be presented as an individual "paper" with an explanation of the method used to carry out the study, the results we encountered and then a discussion and conclusion on the subject.

Based on what we have read in the literature, as well as our particular experience in reviewing certain aspects, we have formulated a protocol on our management of this injury. Because of the learning curve, which can incline only as rapidly as this relatively rare condition presents itself, our protocol will no doubt continue to evolve as more experience is gained. I do believe however that because of the sheer volume of patients with this injury that pass through our department we have a positive contribution to make on the management of patients with posterior fracture-dislocations of their hip joints.

## **2. Literature Study**

### **2.1 A Review of the Literature**

According to Rosenthal (1979), Sir Astley Cooper first described the fracture-dislocation of the hip in 1791, in an autopsy specimen. Cooper and Malgaigne (1825) described posterior fracture-dislocation in patients thrown from a cart or kicked by a horse. They distinguished this injury from a pure dislocation by the presence of crepitus and the presence of easy dislocation following reduction.

The mechanism according to Griswold and Herd (1929) was extreme abduction with the femur acting as a lever arm and forcing the femoral head out through the inferior capsule. The musculature evidently then "located" the head in the typical posterior position. This was prior to commonplace high-speed motor vehicles and the profound effect they would have on the incidence of this injury.

Banks (1941) presented a review of the literature and found fifty-one cases of reported Avascular Necrosis (AVN) subsequent to simple dislocation. As the injury prevalence increased with the increase in vehicle traffic, articles by King (1941) compiled research on the outcome of incongruent reductions in dogs and Watson Jones (1944), and Gordon and Freiberg (1949) discussed the incidence of associated fracture with dislocation.

Urist (1947) described the injury subsequent to jeep accidents during the Second World War. He reviewed forty-two dislocations, twenty-seven fracture-dislocations and concluded that there was no difference in the outcome if the femoral head was protected from weight bearing beyond six to eight weeks or not. He was the first advocate of primary open reduction for all comminuted fracture-dislocations, because of his concern for sciatic nerve injury. This surgeon was far more aggressive than his peers in carrying out reconstructive surgery and also made the very astute observation that the nature and magnitude of the initial injury played the major role in determining the final outcome, rather than the operative treatment.

Stuck and Vaughan (1948) concluded that non-weight bearing for twelve months would protect the head until it had been revascularised. They noted AVN in only one of twenty-two cases protected in this way.

Armstrong (1948) described the first classification for the severity of these injuries. He reviewed 101 patients who had sustained posterior dislocation of the hip during the Second World War, and treated in the Orthopaedic centres of the Royal Air Force. Fifty-five of these patients sustained posterior fracture-dislocations. All but one patient were treated with closed reduction followed by immobilisation in hip spica. He made the observation of the high

incidence of associated fractures with this pathology. Fifty-three of his cases sustained their injuries in aircraft accidents. In fact two of his patients were subsequently killed in battle when shot down in their aircraft.

Armstrong believed that early mobilisation, was to be avoided. In only one of his patients, was heterotrophic ossification a problem. This particular patient was the only one in his study who had been treated with "massage and mobilisation" as opposed to immediate post reduction immobilisation. He went on to emphasise that patients who went for rehabilitation after completing their time in spica or traction, made a far quicker recovery than those who did not go for rehabilitation.

These early papers discussed the variations on conservative treatment. Watson-Jones (1960) recommended hip spica for two months, non-weight bearing for six months. Armstrong, a spica for two months, non-weight bearing for one month and six weeks rehabilitation. At the other end of the spectrum Paus (1951) recommended a few days bed rest followed by weight bearing. Few carried out surgery on the dislocated hip, and the only indication appears to have been irreducibility. Armstrong had one case that had complete sciatic nerve palsy. This was the only patient in his series who underwent surgery, which demonstrated a large fragment of posterior wall compressing the nerve. This was carried out at 9 months, but this experience lead Armstrong to the conclusion that sciatic nerve injury was a second indication for early surgical exploration. Due to the results in those cases with acetabular floor fractures he also advocated early arthrodesis for this group.

By the early fifty's it is apparent that the frequency of these injuries had increased and an awareness of the incidence of associated fractures, maxillofacial injuries and nerve injuries had replaced the simple concern for protecting against avascular necrosis. The results of earlier treatment highlighted the more serious problem of secondary osteoarthritis, and an incidence of heterotrophic ossification was described subsequent to surgery. Nicol (1952) at a scientific meeting of The British Orthopaedic Association read a paper in which he emphasised the need to appreciate and distinguish the difference between AVN and what he termed "traumatic osteoarthritis".

Vernon Thompson and Herman Epstein (1951) published an article in the Journal of Bone and Joint Surgery of America entitled "Traumatic dislocations of the hip. A survey of two hundred and four cases covering a period of twenty one years." In this article they discussed the incidence of this injury as well as that of associated injuries and complications. They produced a classification for the severity of these injuries. In addition they also described criteria for the classification of long-term results of treatment.

They emphasised the fact that those patients who developed AVN usually had warning signs as early as six months and always by one year. They therefore did not believe in routine non-weight bearing for all patients for an extended period, rather a close evaluation of each patient. They made the very pertinent point that the rarity of this injury makes it almost impossible for each surgeon to accumulate significant numbers to make significant conclusions. When the injuries are separated into their various categories for comparison, the sample numbers become so small that "trends" which appear cannot be shown to be significant until much bigger numbers are accumulated." They stated that they hoped to establish a few probabilities that could help to confirm sound opinion and provide surgeons with guides towards more astute management. They felt that if incongruity of the articular surfaces can be avoided by restoring the position of the fragments, it will be possible to reduce the incidence of traumatic arthritis.

This article was the largest series regarding this pathology published at that time. Epstein updated his series in 1974 and 1980 in which he reviewed 242 and 368 respectively. To-date this number remains the largest series presented by one author. Brav (1962) collected the records of all Army personnel treated with this injury to produce a series of 223 and Judet and Letournel in their book "Fractures of the Acetabulum" (1993) also describe 223 cases of posterior fracture-dislocation of the hip joint. Epstein has as a result of his vast experience and publications provided a nucleus for most of the practices, which surround the management of this injury today. His two classifications have formed the platform for comparison in most subsequent literature, especially in comparing results of treatment.

The degree of comminution of the posterior wall was shown in Thompson and Epstein's review, to have significant effects upon the final outcome of the injury and also played a significant role in determining the modality of treatment by these authors. This observation has subsequently become the single most important factor in the pathogenesis of this injury in the modern era, as borne out by most of the recent literature.

Stewart and Millford (1954) produced a classification of injury severity after reviewing 123 cases with posterior fracture-dislocation (three years after Thompson and Epstein). They described this classification as an alternative to Epstein's, because they found it more helpful in terms of predicting the appropriate treatment. They treated a large percentage of their patients conservatively and advocated immobilisation if the hip was unstable. Epstein however felt that the presence of fragments within the joint would have profound effect on the long-term outcome of treatment and that it was essential to remove all fragments from the joint so as to avoid accelerated secondary osteoarthritis. For this reason he placed his emphasis on the degree of comminution of the posterior wall.

In Stewart's series 48.8% of his patients developed osteoarthritis when treated with closed reduction. In his group treated with open reduction, 71.4% developed osteoarthritis. 15.5% of those treated closed and 40% in the open group developed AVN. Stewart's philosophy that most hips should be reduced closed and then treated conservatively, contrasted dramatically with Epstein's' belief in primary open reduction for all posterior dislocations with evidence of fracture, (combined with reconstruction of the posterior wall where appropriate).

Pipkin (1957) reviewed twenty-five hips that had sustained a posterior fracture-dislocation with a fracture of the femoral head or neck. (Epstein grade V, Stewart grade IV). He re-emphasised the risk of causing fracture during overzealous repeated reduction attempts. (This was the cause of two of their cases). He felt it was necessary to reclassify this group of patients into more specific groups because of the very varied results, which occurred according to the type of head fracture.

- Type I Dislocation with fracture of the femoral head caudal to the fovea capitis femoris.
- Type II Dislocation with fracture of the femoral head cephalad to the fovea capitis femoris.
- Type III Type I or II with associated femoral neck fracture.
- Type IV Type I or II with fracture of the acetabular rim

He concluded that despite his relatively large series sample sizes were so small as to make any concrete conclusions about these injuries, mostly conjecture. Nevertheless while good results were rare he did have cases that did well and the message with regard this injury was not as grave as previously reported.

Carter Rowe (1961) in a review of all acetabular fractures (including seventeen posterior fracture-dislocations) concluded that the contributions to a poor outcome are multifactorial. These included instability of the hip joint post reduction, delayed reduction of the dislocation and the degree of injury to the femoral head at the time of injury with the possibility of fragments within the joint. In his group with good results, none had femoral head injury and all had bone fragments removed surgically where present. He did however still feel that small fragments within the joint that were not necessary for stability and not causing incongruent reductions could be treated conservatively.

Brav (1962) reviewed the folders of 457 posterior dislocations treated in the US Army hospitals in the twelve-year period 1947-1958. Of these 223 sustained posterior fracture-dislocation. Sixty-six were treated with surgery. Thirty-four primarily as reduction was impossible or so unstable as to be impossible without fixation of the posterior wall, and thirty-two who were explored subsequently because of nerve injury or where the hip was found to

be unstable due to a large posterior wall fracture. Of the sample which he reviewed 110 pure dislocations and 120 fracture-dislocations were available for follow up. 22% of pure dislocations developed AVN and 26% developed Osteoarthritis. 35% of the fracture-dislocations developed AVN and 56% developed Osteoarthritis. He concluded that those patients who underwent surgery were more likely to develop osteoarthritis. He also made the observation that those dislocations reduced within twelve hours had a 22.1% chance of developing a poor result and 17.6% chance of developing AVN. Those reduced after twelve hours developed poor results in 51.7% and AVN in 56.9%. He observed absolutely no difference in the incidence of AVN in relationship to the period of non-weight bearing. It is of interest that despite Proctor's (1973) claims of stability Brav had four cases that subsequently dislocated after full conservative treatment.

Helal (1967) presented a paper of fourteen cases of missed posterior dislocation of the hip in association with femoral shaft fracture. At that point eighty-one similar injuries had been described. They were only able to reproduce the injury pattern on cadavers with two separate combined forces. First dislocating with an axial loading of the flexed hip and then applying a second direct blow across the femur. The fractures of the femurs were always transverse as a result of the second blow. These occur typically in a motorcyclist who is struck subsequent to the initial impact that produced the dislocation. Interestingly, in almost every series subsequent, there is a 1 or 2 % incidence of this combined injury and in almost every series this injury is missed initially.

Hunter (1969) produced a review of fifty-seven patients with fifty-eight posterior dislocations, thirty-two fracture-dislocations. They practised closed reduction followed by traction and carried out open reduction in only four cases in their series. They concluded that they would continue to pursue a policy of conservative treatment as they felt that their results were good or excellent overall in 88% of their patients.

Larson (1973) described a test of stability. Keeping the hip in neutral rotation, and neutral abduction, adduction he flexed the reduced hip 30° to 40° and then applied a longitudinal force toward the hip along the axis of the femur. He concluded that an unstable hip would re-dislocate with this manoeuvre, and felt that this implied that a significantly large fragment of the acetabular dome had been avulsed. He believed that surgery was warranted and reserved exclusively for this group of patients. Procter (1973) believed that if the fragment is "fully" reduced then conservative treatment can be employed and a stable functional hip will ensure.

In 1974 Epstein again published his results. This series included 242 posterior fracture-dislocations. He cited the very poor results in the type III injuries treated closed (one of thirty-five good results) as good indication for performing open reductions because of the

incidence of fragments in the joint. He concluded that early primary open reduction with removal of all loose fragments and restoration of stability by internal fixation of the posterior wall fracture offered the best prognosis in all groups. Of his type V injuries, none that were treated closed did well. In 150 patients who were followed up for longer than four years, (forty-two for more than ten years) he noted that the initial result at one year seldom improved. Only eight of the forty-two followed for longer than ten years developed evidence of traumatic arthritis as a late complication. He described eleven patients who had open reductions via an anterior approach, all with poor results and he condemned this approach.

Amihood (1974) from Cape Town showed that patients treated in hip spicas did worse than those in traction in the short term. He also demonstrated a more aggressive approach to reconstruction of the posterior wall than his peers of the time did. At the conclusion of his study he was of the opinion that Epstein's primary open reduction was treatment of choice.

Whitehouse (1978) presented seventy-eight posterior fracture-dislocations. He made the observation that in his series younger patients were less likely to suffer a simple posterior wall fracture. Older patients were more likely to sustain comminuted fractures. This has not been the finding of subsequent authors.

Rosenthal (1979) reviewed forty-six posterior fracture-dislocations retrospectively. Thirty-three sustained maxillofacial injuries and three cervical spine injuries. Two ipsilateral femoral fractures occurred. In both cases the dislocation was missed initially. Twenty-two cases were managed surgically. A posterior or posterolateral approach was used and the hip was re-dislocated in all cases where possible. They noted that posterior approach was difficult and commented that it was difficult to dislocate the hip with the patient prone. They noted intra-articular fragments and scoring of the femoral head in all cases dislocated intra-operatively. While they noted contusion in two of the sciatic nerves impaired preoperatively, they also noted contusion in two of the normal sciatic nerves. Rosenthal argued that whenever it was necessary to explore a hip surgically some intra-articular bone fragments were seen. He expounded that some of the good results in patients treated conservatively must therefore have occurred in hips where intra-articular bone fragments were present. "The mere presence of intra-articular fragments thus does not necessarily indicate that open reduction is necessary. However fragments trapped between weight bearing surfaces ought to be identified and removed."

Rosenthal experienced 100% heterotrophic ossification in his twenty-two patients who underwent surgery. He presents a patient who had a large posterior wall fragment, planned for surgery but had to be treated conservatively because of a pulmonary embolus. At fifteen months this patient had a good hip. He therefore agreed with Proctor's practice of conservative treatment where the posterior wall could be adequately reduced.

In 1980 Epstein in a monograph on Traumatic Dislocation of the hip, reviewed 830 dislocations. 368 were posterior fracture-dislocations and 292 had adequate follow up.

He compared three different treatment protocols and their outcomes.

In group I treated with closed reduction only, he had 116 patients.

In group II closed reduction was followed by open reduction. He had 93 patients.

In group III treated with primary open reduction he had 83 cases.

He compared the results in each group according to his classification as described in 1951 (and subsequently adopted by most authors for comparison of results).

Excellent	Patient has no complaints; full range of movement; normal radiograph
Good	Minor complaints; slight limitation of movement; no significant disability; minimal radiological changes.
Fair	Complains of disability; moderate limitation of movement; moderate radiographic changes.
Poor	Severe limitation of function; marked limitation of movement; marked radiographic changes; second operation required.

In type II injuries, 32% from group I (closed) had good results  
This increased to 54% in group II (closed followed by open reduction)  
and increased to 87% in group III ( primary open reductions)

In type III injuries 2% good results in group I  
This increased to 45% in group II  
And increases to 67% in group III

Type IV injuries went from 13% to 40% to 47% in the three respective groups.

In light of the number of patients that he has managed, he presents a very good case for primary open reduction in all posterior fracture-dislocations.

Upadhyay (1981) presented a review of eighty-one patients with posterior dislocated hips, twenty-eight of who had fracture-dislocations. They treated eleven patients in their series with surgery. All of their patients had in excess of ten year follow up. They had extremely bad results in the group who under went surgery and observed that irrespective of initial results with progress of time they had a reduction in the number of good results. They concluded that irrespective of other factors the severity of the initial injury inducing force played the major role in determining the final outcome.

In 1985 Epstein wrote his final review, concentrating specifically on his type V injuries. A total of sixty-three patients had been treated with this injury during a fifty-six year period. He described two patients whose fracture-dislocations were irreducible closed and two patients who sustained fractures to the neck of their femurs during attempted closed manipulation. He strongly condemned the practice of repeated attempts at closed reduction. He felt that nerve injury was most likely as a result of the severe internal rotation of the hip at the time of reduction with subsequent traction on the nerve, rather than simply from direct pressure from the dislocated head or fragments of the posterior wall. He concluded that pre-reduction nerve palsies constituted an orthopaedic emergency for urgent reduction of the dislocation.

He re-emphasised his belief that open reduction is important in posterior fracture-dislocations, and no less so in the type V with a Pipkin type injury. In his series he found debris in the joint of every single type V head fracture and in light of his very firm beliefs that all debris should be removed concluded that closed treatment in these injuries is inadequate. He agreed with most authors who felt that despite open reduction and removal of small head fragments or fixation of larger fragments, the long-term results are disappointing, but stressed his belief that open treatment would protect the head longer from traumatic osteoarthritis when the fragments were removed.

Epstein also found four cases that were irreducible because of the large fragment of the head blocking reduction into the acetabulum. He strongly advocated primary open reduction so as to avoid repeated attempts at reduction with scoring of the femoral head, or the risk of neck of femur fracture as experienced on two occasions and also described in other literature. The absence of excellent results and presence of very few good results overall are, he concluded, to be expected in an injury which clearly is sustained after severe force, and in which he noticed additional depressions, fissures and scarring of the head in many of his cases.

The presence of a neck of femur fracture (Pipkin III) still remained an unresolved problem in his hands. Because of the age group in which this injury occurred, he advocated primary fixation and then dealt with the failures as they occurred. This usually involved total hip replacement or arthrodesis.

Joel Matta (1986) says that osteoarthritis develops for two reasons. One is the damage to hyaline cartilage that occurs at the time of initial impact. The second is the gradual breakdown of articular cartilage that can occur over a period of months or years following the injury. Articular cartilage remains viable in most cases even after severe fractures and the primary thrust of treatment should be towards preventing the late breakdown that occurs due to marked alterations in pressure distributions within the hip joint. Fractures that alter the anatomy decrease the contact area of the femoral head and acetabulum and therefore

increase the unit pressure load on the articular cartilage. Articular cartilage obviously has some capacity to respond to alterations in the pressure distribution. This is demonstrated by good results despite minor incongruencies subsequent to conservative treatment or imperfect operative reductions. However marked changes in the pressure applied to articular cartilage leads to the breakdown of the cartilage. The prevention of osteoarthritis is particularly important because of the fact that most commonly these patients are young adults. He also makes the important observation that surgery involves an approach to the pelvis not simply the acetabulum. Hemiarthroplasty or even total arthroplasty did not require the extent of dissection to adequately carry out reconstructive surgery of the acetabulum.

Hougaard and Thomsen (1987) reviewed the results of 127 posterior dislocations of which fifty-two were fracture-dislocations. One hundred hips were available for review at a minimum of five years. The single most significant finding in their review was that amongst the eighty-three patients reduced within six hours of dislocation only four developed AVN (5%) and twenty-five developed osteoarthritis (30%). Of the seventeen reduced after six hours ten (58%) developed AVN and thirteen (76%) developed osteoarthritis. Stewart and Milford (1954) had noted a worse prognosis if reduction after twenty-four hours and Brav (1962) noted a worse prognosis if reduction after twelve hours.

They concluded as well, that of their patients who developed coxarthrosis in the majority it developed within five years and all patients with poor results had symptoms at one year. They made the observation that of their patients, who had excellent or good results, 22% had AVN. Forty-eight (38%) of their patients developed osteoarthrosis but in only thirteen of these (30%) could this be attributed to AVN.

Jacob (1987) reviewed seventy-three posterior fracture-dislocations. In his series sixty-one of seventy-three cases had reduction within six hours. None of these patients developed AVN and none of his patients developed nerve injury as a result of their dislocation. Jacob observed that 70% of his patients were involved in Motor Vehicle Accidents (MVA) and none wore seat belts. He discussed the mechanism of injury as postulated by Judet (1964) and made the observation that passengers who strike their knee on the dashboard with a flexed hip are likely to suffer a pure dislocation. Drivers who have their hips in slight extension are more prone to develop fracture-dislocation.

Jaskulka (1991) reviewed forty-five dislocations. Twenty-four of these had fracture-dislocations. All forty-five of their patients were reduced within six hours of dislocation. Only one of their fracture-dislocations developed AVN (4%). They treated fourteen patients surgically and ten conservatively, and concluded that they could find no statistical difference between the operative and non-operative group. Despite their early reductions they still had four nerve palsies one of which presented post operatively. They believe that surgical

exploration in the presence of nerve injury should always be carried out. They base this on their experience with regard to one patient who made a full recovery after the fragment was reduced and fixed, and two cases treated conservatively who still had residual neurology at their time of writing. They stated that intra-articular fragments, whether cartilage or bony are always an indication for surgery. They do not agree with those who consider that fragments outside the weight-bearing zone are unimportant.

Pantazoupolus (1993) reviewed fifty-eight fracture-dislocations of which fifty-two were available for follow up. All underwent surgery, fifty for reconstruction of the posterior wall and two for removal of small fragments. They included sixteen type II and thirty-six type III fractures. Their indications for surgery were an abnormal Larsons test, (though they modified the Larsons test to 90° of flexion) a large posterior fragment if displacement was more than 5mm after reduction of dislocation and any evidence of impaction of the acetabular margin. They believed that restoration of the articular surface is absolutely essential. The mechanism of injury was MVA in all but one case that sustained a fall from a height. Reduction was achieved within a few hours in all but three cases. AVN developed in one of these three cases but the other two cases of AVN recorded in their series were from the group reduced within six hours.

They assessed their intraoperative findings according to the degree of anatomical reduction they were able to achieve at surgery and then confirmed on radiology. Forty-two of their cases had excellent surgical results of which thirty-three had excellent results and seven had good results. In their series only three cases developed moderate to severe osteoarthritis.

An article by Keene and Villar (1994) makes mention of CT routinely for exclusion of small bony fragments and quotes Hougaard and Nielsen (1987) who had shown the significant role of CT in detecting radiologically occult fragments. They go on to say that arthroscopic retrieval must be the natural progression for removal of these fragments.

Marchetti (1996) described results of thirty-eight patients who sustained a Pipkin fracture-dislocation. Thirty-one had undergone surgery. Three patients developed AVN; all had been reduced within six hours. Despite very poor overall results with these injuries in previous literature, this study had 67% good results. They attribute this success to their goals of achieving restoration of stability, removal of interposed bone fragments and achievement of anatomical reduction.

## 2.2 Summary of Literature Findings

In reviewing the English literature, there were thirty-one papers that presented the results of a series of patients who had sustained posterior fracture-dislocations of the hip joint. These ranged from series that compiled only fracture-dislocations to those that were predominantly pure dislocations. Most series presented an overview of their numbers, incidence of other injury, complications, etc. but different papers concentrated on different features and omitted features discussed in other papers.

In performing a meta-analysis of these series the percentage incidence of respective features is calculated as a percentage of the total number of patients included in the articles that made reference to that particular injury. Pure dislocations are often included with fracture-dislocations, however when all the articles that mention AVN are considered, on extracting just the fracture-dislocations the total number of patients is 1129. The total number of AVN cases reported in these series is 160. (14%) The incidence of nerve injury is also 14%.

### **Avascular necrosis and nerve injury from sample available for follow up.**

AUTHOR	YEAR	FRACTURE-DISLOCATIONS**	AVN	NERVE INJURY
Amihood	1974	55	2	2
Armstrong	1948	55	3	1
Brav	1962	120	42	35
Chiu	1996	24	3	2
Epstein(1974)	1980	292	64	47
Hunter	1969	32	1	6
Jacob	1987	55	5	0
Jaskulka	1991	24	1	3
Larson	1973	64	6	16
Marchetti	1996	38	3	5
Pantazopol.	1993	52	3	4
Paus	1952	60	1	*
Procter	1973	96	2	7
Reigstad	1980	57	3	2
Thomsen	1987	52	14	7
Upadhyay	1981	28	5	6
Whitehouse	1978	25	0	0
<b>Total number</b>		1129	160	146/1069
<b>Percentage</b>			14%	13.66%

\* No mention of this specific aspect in this paper

\*\* This is the number of patients from each series available for follow up. This may obviously differ from the original sample that sustained this injury

In the four papers that mentioned craniofacial injuries specifically 17.75 % (120/676) sustained craniofacial injuries.

The ratio of pure dislocation (Type I) to fracture-dislocation is 1 : 1.95 - (928:1810).

(In Epstein's series he has 370 : 368 almost 1:1)

The ratio of type II to type III fracture-dislocation is 1.03 : 1 - (267 : 257)

(In Epstein's massive series his ratio of simple posterior wall to comminuted posterior wall was 1 : 2.8 but most other series have the reverse of this and subsequently this overall ratio approximates 1 : 1.)

**Mechanism of injury. (both pure dislocation and fracture-dislocations in entire series)**

<u>AUTHOR</u>	<u>MVA</u>	<u>DRIVER</u>	<u>PASSENGER</u>	<u>PEDESTRIAN</u>	<u>TOTAL with injury.*</u>
Amihood	27	16	11	4	55
Brav	205	100	105	11	223
Jaskulka	39	25	14	0	45
Armstrong	36			0	55
Epstein (1980)	312			6	368
Hunter	26			*	58
Jacob	58			*	73
Procter	34			4	96
Reigstad	25			3	57
Upadhyay	37			0	81
<b>Total</b>	799	141	130	28/980	1111
<b>Percentage</b>	72% of total	52% of MVA	48% of MVA	2.9% of total	

\*This is the total number of patients in each series that sustained a posterior dislocation, with or without a fracture.

In each series the numbers available for follow-up is obviously not necessarily the same.

With regard to the mechanism of injury, the majority of patients are involved in motor vehicle accident. Only three papers distinguish between passengers and drivers, but there appears to be a roughly even spread between passengers and drivers.

Only very small percentages (2.9%) of patients who sustain this injury are pedestrians. In Judets series of 940 acetabular fractures (not just posterior fracture-dislocations) 12.65% are pedestrians. The pedestrian is struck over the trochanter and sustains an acetabular fracture rather than a dislocation of the hip joint. The balance is made up of a mixture of trauma, including assault, sport, falls, "cave ins" in miners on all fours and in three series a very high incidence of motorbike accidents (MBA). These three papers were all from the UK, from Oxford, Birmingham and Nottingham. They were published in 1969, 1973 and 1981 and MBAs' represented 25%, 40% and 18% of their cases respectively. Perhaps the proximity of these centres to race tracks at Silverstone and Donnington have a bearing, but no other authors have a significant number of victims of MBA.

### 2.3 Discussion of Literature

Letournel and Judet point out that the posterior fracture-dislocation of the acetabulum is a partial posterior column fracture but as it is the most common fracture of the acetabulum it should be considered as a separate group. It occurred in 223 cases of their series of 940 fractures of the acetabulum. (23.72%)

In the early literature the authors major concern was the association of posterior dislocation of the hip joint with avascular necrosis. Achieving early reduction was the pinnacle of their treatment protocol. Later on the appreciation of the significance of secondary osteoarthritis has altered the focus. The goals of treatment now centre on avoiding osteoarthritis. Avoiding AVN remains important but is one of many factors that contribute to achieving a good hip with long-term function.

It is difficult to determine a cut off time of dislocation after which a bad result is inevitable since numbers are too small to divide groups up into periods of six or twelve hours and draw significant conclusions. Many of the cases reduced after twenty-four hours still had good results and many cases reduced before six hours still develop AVN. Those studies that examine the blood supply of the hip whether by anatomical dissection or angiographic examination during dislocation add weight to the argument for early reduction. (Yue 1996) The delay to reduction certainly is one of the influencing factors but the overall message is reiterated that there are many factors involved in determining the risk of AVN and indeed the likelihood of a good long-term result.

Many of the early authors made a case for conservative treatment. Stewart showed that 71% cases developed osteoarthritis after surgery while only 48% developed OA when treated conservatively. Brav concluded that those patients that underwent surgery were more likely to develop OA. Rosenthal had 100% heterotrophic ossification after surgery and claimed good results after conservative treatment. Upadhyay who also treated only eleven of eighty-one patients with surgery had the longest follow up and noted that irrespective of initial outcome with progress of time the results continued to deteriorate. Finally Jaskulka compared twenty-four cases; fourteen treated surgically and claimed no significant difference in the outcome.

In all of these studies that have carried out surgery on a small percentage of their cases, it begs the question. Why did these patients have surgery? One or two percent were for irreducible dislocations. The balance of operations must have been done in cases that were unstable or had significant comminution to convince these primarily conservative surgeons that surgery was indicated. This is plainly separating out all the bad injuries and attributing their bad results to the surgery that they had rather than the personality of the fracture sustained.

Rosenthal, despite his claims of good results in conservatively treated patients, noted that none of his patients, who performed their occupation while standing, were able to return to work. 50% of all his cases did not return to their pre-injury occupation. He used no Indomethacin in preventing heterotrophic calcification. He also put patients prone on the table making surgery extremely difficult. His poor surgical results were not simply the result of surgery. His allegedly good conservative results were not simply the result of not having been treated with surgery.

Upadhyay who had an average follow up of 12.5 years claimed good results with conservative management. He nevertheless went on to conclude that the long-term results of his patients were always bad. He expressed surprise that this was the case in light of the fact that the majority of his cases were reduced early. He blamed the nature of the injury on this disastrous outcome. This obviously played an important role, but the failure to remove fragments or achieve anatomical reduction would play an equally significant role in the poor outcome.

Jaskulka who was more aggressive in his approach to surgery concluded that he could find no significant difference in the results between those treated with surgery and those treated conservatively. The implication being that there is no need to do surgery, as the results are no better. This is a very unfortunate misrepresentation of a very important message. The conservative group with less sinister injuries would be expected to do well with conservative therapy. By detecting no significant difference in the outcome of the two groups he demonstrated that the group of patients treated with surgery could be expected to do as well as a group of patients who had minor injuries and could be treated conservatively. Quite apart from being an argument for conservative therapy this was a very good advert for surgical treatment.

As a result of the number of patients that Epstein has treated over the years, he is the one author who has been able to make substantial observations from which he bases his management protocol. Consequently many authors still follow his practice of carrying out primary open reduction of all fracture-dislocations. Jesse De Lee (1996) says that he aspires to this philosophy. He nevertheless makes the point that the delay involved in awaiting general anaesthetic means that it is usually more realistic to carry out closed reduction under sedation and then proceed onto open reduction as a semi-elective procedure where optimum conditions can be obtained. Joel Matta too agrees that he carries out primary open reduction.

In contrast to the conservative surgeons' results, Epstein (1980) in his series showed significant differences in all grades of injuries in patients treated with primary open reduction over those treated with closed reduction and delayed surgery. Both groups had significantly

better results than those that were treated conservatively. No doubt the single most important factor in Epstein's approach was an appreciation of the need for reconstruction of an anatomical posterior wall with removal of joint fragments. Epstein came to this appreciation over a lifetime of practice. What we now know about the weight distribution across joints and the effect small fragments have on the force distribution substantiates this philosophy. As the number of surgeons with expertise in acetabular surgery grows the outcome of treatment improves.

Epstein was however practising at a time pre computed tomography and did not have the benefit of looking for fragments on post reduction CT pictures. He was left with getting his best visualisation of the acetabulum and the posterior wall before the head of the femur obscured his view. On those occasions where he went back and had to re-dislocate the hip in order to accurately assess the acetabulum, he was not able to reproduce the results of primary open reduction. (Epstein himself states that he believes the practice of re-dislocation to be detrimental to the hip joint).

Clearly there has been an improvement in the overall results of patients treated surgically. The basic AO principle that intra-articular fractures should be fixed anatomically and rigidly has gradually caught on and changed the attitudes of surgeons. (Though because of the complexity of the surgery and the infrequency with which it is encountered appears to have lagged behind when compared to a generally accepted more aggressive approach to other joints.) This surgery does however have a long learning curve. Besides the fact that this injury has become more common with the increase of motor vehicles on the roads, the surgeons are now fixing cases that previously might have been treated conservatively. The net result is that surgeons are carrying out this surgery more often and able to traverse the learning curve sooner. The overall effect is that when Pantazopoulos published his paper in 1993 he would be expected to have 80% good results while in 1948 it was acceptable to have only 50% good results.

### **3. Patient Profile in this Series**

In the 75 cases treated in the series, the mean age of the patients was 35.3 years. Ranging from 19-75 years. (Patients below the age of thirteen are treated at the Red Cross Children's Memorial Hospital.)

The average surgical time was one hour and fifty-two minutes for all cases. For cases with just a fracture of the posterior wall the average time was one hour twenty-three. For cases with an associated floor fracture the average time was three hours.

Fifty-two patients were male. (69.3%) Fifty sustained their injury in the right hip. (66.7%) Thirty-five had associated injuries. (46.6%) Three cases had ipsilateral femur fractures, two of these were referred from elsewhere and in one the dislocation was missed. This hip remained dislocated for seven days.

Fifteen patients had intra-articular fragments.(20%) Twenty-two patients had marginal impaction.(29.3%) Judet and Letournel who coined the term marginal impaction described this lesion in 16% of their cases and Brumback *et al* who described this lesion as the acetabular depression fracture identified it in 22.67%. (17/75)

Sixty cases were occupants of motor vehicles. (80%) Thirty-three were drivers of vehicles and twenty-seven were passengers. Only one patient (1.3%) sustained this injury in a motorbike accident. Nine cases (12%) were pedestrians. The remainder included three who fell from a moving train, one assault and one who fell from a height and landed on all-fours.

Seventeen cases (22.6 %) were dislocated for longer than twelve hours. Fourteen of these were referred from outlying hospitals. Of the three cases dislocated longer than twelve hours and treated at Groote Schuur from outset, two lay in Intensive care for ten and twelve days respectively. The first case had an irreducible hip and was not well enough to tolerate General Anaesthetic for the first five days. The other case lay in ICU undiagnosed for twelve days. The third case was a young twenty-year-old woman who fell while dismounting a moving train and then hobbled home to bed for seven days before her parents called the family doctor.

Eleven cases sustained nerve injury.(14.6%) Eight of these were peroneal palsies and three complete sciatic nerve palsies. The three complete palsies were dislocated for sixty, twenty-one and six days respectively. All but one of the peroneal palsies was reduced within twelve hours. This one case was dislocated for twelve days. No patients developed post-operative palsies.

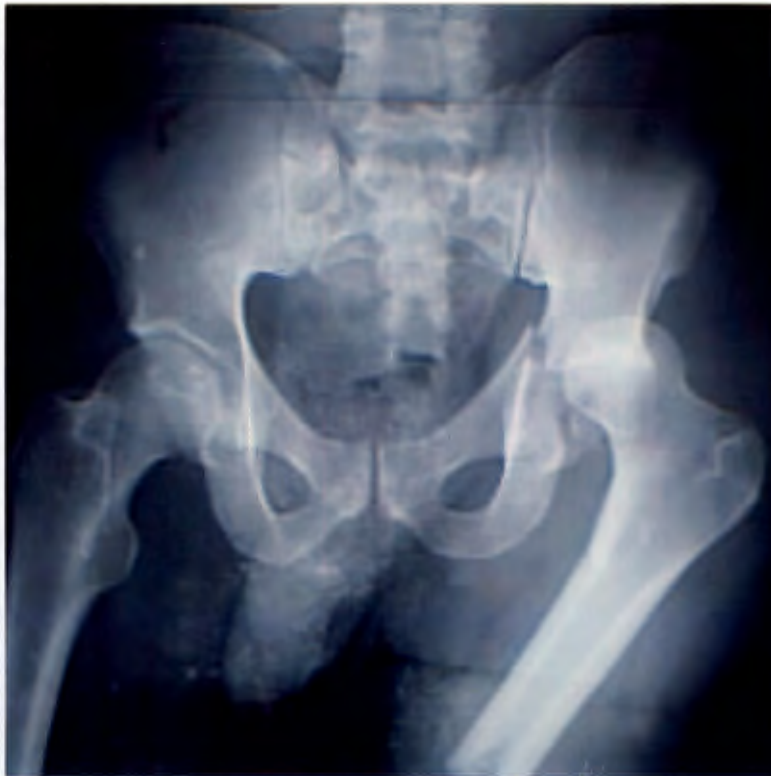
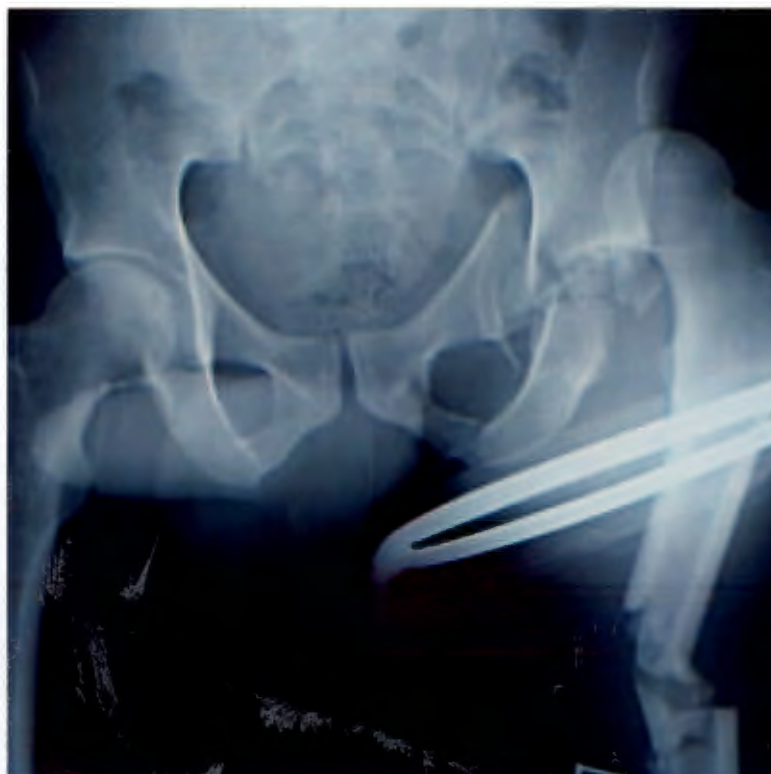
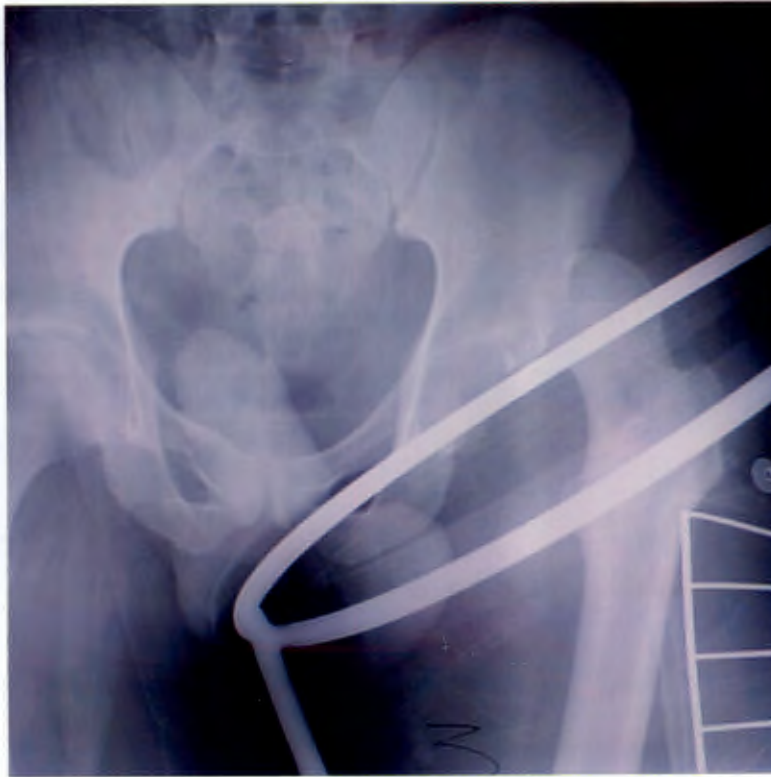Fig. 1 and fig. 2. Two examples of an associated femoral shaft fracture. Note the transverse nature of the shaft fracture. The posterior dislocation of the hip displays the classic clinical appearance of the flexed, adducted and internally rotated hip. Internal rotation is recognised by invisible lesser trochanter.



**Fig.3** In this third example, despite this radiograph the femur was nailed with the hip still dislocated by a tired resident who only noted the dislocation when he came to put the hip through its range of motion at the end of the procedure.



The cause of AVN is clearly multifactorial. Hougart and Thomsen; Brav; and Stewart and Millford suggested 6,12 and 24 hours respectively as the critical time to achieve reduction. Despite their observations patients dislocated longer often don't develop AVN and some patients with brief dislocations do. In this particular case the hip was dislocated for five days. The AVN which occurred was however more likely a result of the undiagnosed femoral head fracture. This is not evident on either (Fig 4) the AP or (Fig 5) the obturator-oblique view taken with the hip dislocated. At surgery too, no head fracture was visualised. The microfractures of the trabeculae, a reflection of the initial impact are seldom as obvious as in this case but would most likely result in AVN irrespective of the period of dislocation.

Fig.4

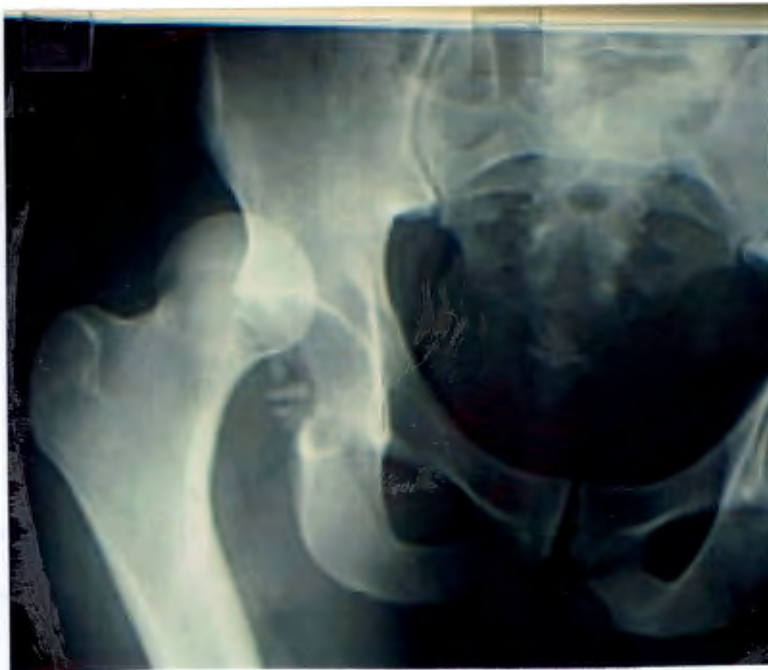

Fig. 5

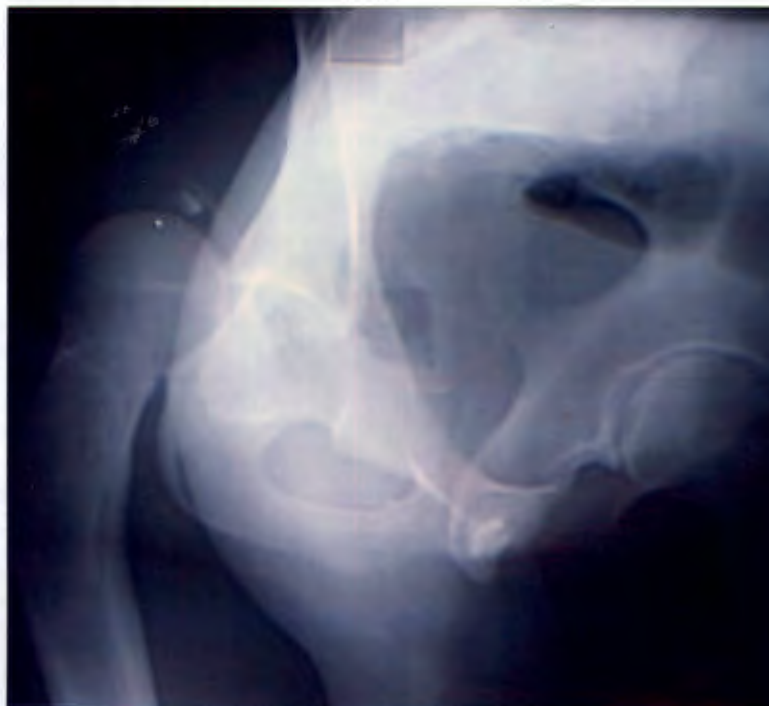

Fig. 6 A very good intra-operative reduction confirmed radiologically.

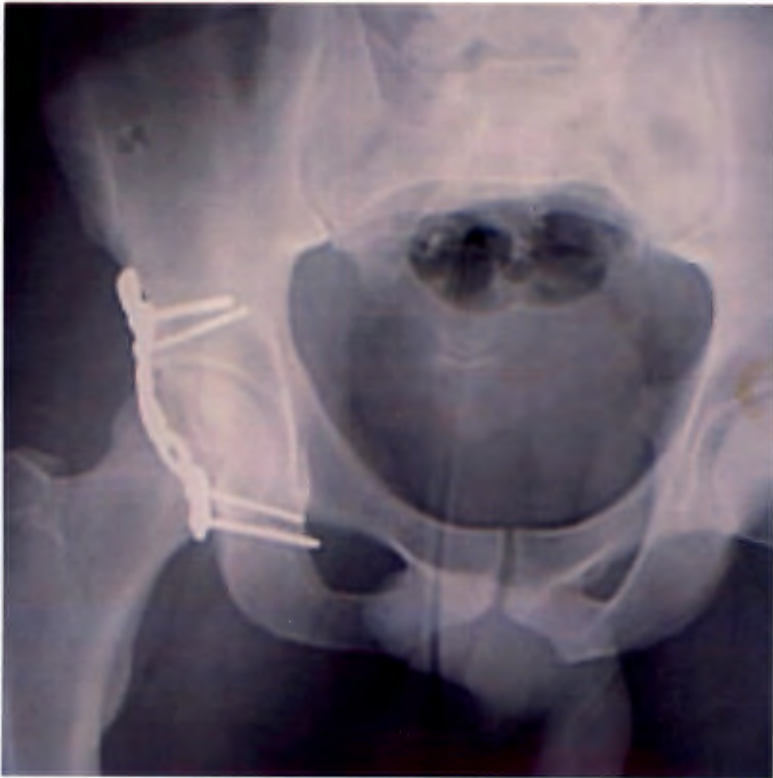
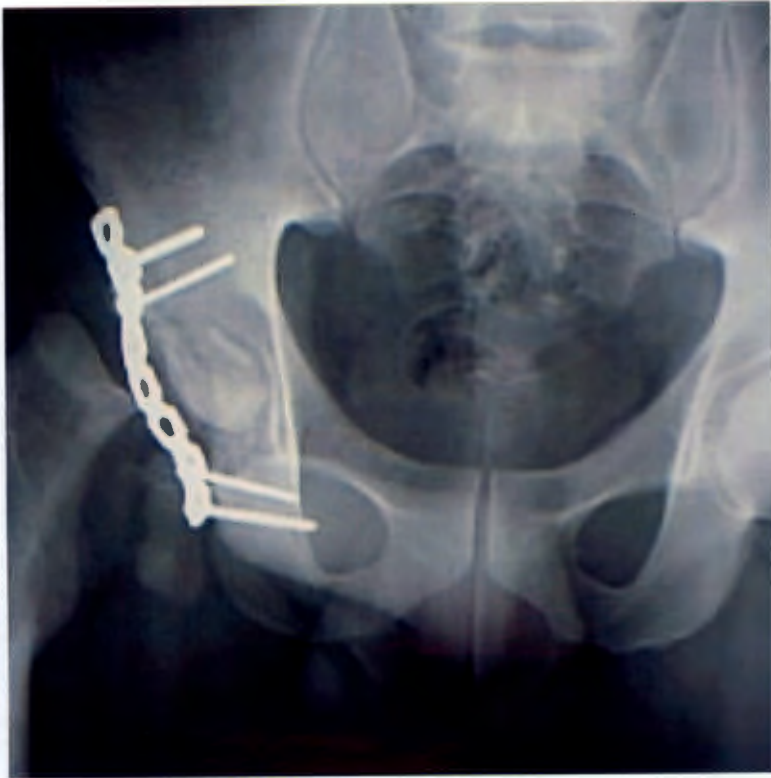
Fig.7 The patient presented with complete avascular necrosis of the femoral head at only six weeks. The fragment within the joint a remnant of the femoral head.



## **4. The Value of the Obturator-Oblique View with the Hip Still Dislocated**

### **4.1 Introduction**

The diagnosis of a posterior fracture-dislocation of the hip joint is invariably made on clinical grounds and then confirmed with an AP radiographic view of the pelvis. The routine pelvic radiography in the polytraumatised patient as practised in ATLS (1993) is a safe guard against missing this injury especially in the presence of an ipsilateral femoral shaft fracture. (Helal 1967)

Precise evaluation of associated fractures of the acetabulum, femoral head or femoral neck invariably requires further investigation. Various authors advocate different views of the hip. De Lee (1996) uses a view where the injured side is tilted 15° towards the beam. Urist (1948) described a 60° posterior oblique view and Tile (1996) recommends the 45° oblique views as originally described by Judet. (1964)

The obturator-oblique view is obtained by elevating the affected hip 45° to the horizontal and directing the beam through the hip joint. By raising the injured hip, the hemipelvis is internally rotated, providing a view of the obturator foramen. This view outlines the anterior column, the posterior wall of the acetabulum and the superior and inferior pubic rami. The iliac oblique view performed with the normal side elevated 45° demonstrates the posterior column, the anterior wall and the iliac blade. In the acutely injured patient attempts to rotate the pelvis may accentuate discomfort. In these cases, the tube may be tilted at 45° in both directions. This produces a distorted but accurate view of the acetabulum. (See fig 15)

Once the hip is reduced this is confirmed on a second AP view of the pelvis. Traditionally, Judet oblique views are then used to assess the hip joint and decide upon the need for CT scan. By serendipity we were exposed to the Judet oblique view taken with the hip still dislocated. The dislocated femoral head in the iliac-oblique often obstructs the view of the posterior column. The obturator-oblique by contrast provides an uninterrupted view of the empty acetabulum. It enables visualisation of the state of the posterior wall, familiarisation with the number, the location and the size of the fragments and also provides the opportunity to compare with the same view repeated once the hip is reduced. Because fragments tend to move with reduction, having the two views enables a better interpretation of the true size and shape of respective fragments. It also often alerts to the presence of intra-articular fragments post reduction and assists with localising fragments that might otherwise be missed intra-operatively. The CT scan has on occasion tended to exaggerate the degree of comminution and this additional view often simplifies the understanding of the fracture configuration.

## 4.2 Method of Research

One of our patients that was referred to us from a peripheral hospital provided us an interesting discovery. We requested that the referring hospital carried out Judet views prior to transfer. The patient arrived with the Judet views but the hip was still dislocated. The view we got of the posterior wall while the hip was dislocated was not obstructed by the femoral head and provided a meaningful contribution to the overall understanding of the fracture. We therefore endeavoured to obtain this view in addition to the normal set of radiographs whenever a patient was admitted with a posterior fracture-dislocation. We managed to obtain the obturator-oblique view with the hip still dislocated in a further thirty-one cases. (The OOD-view)

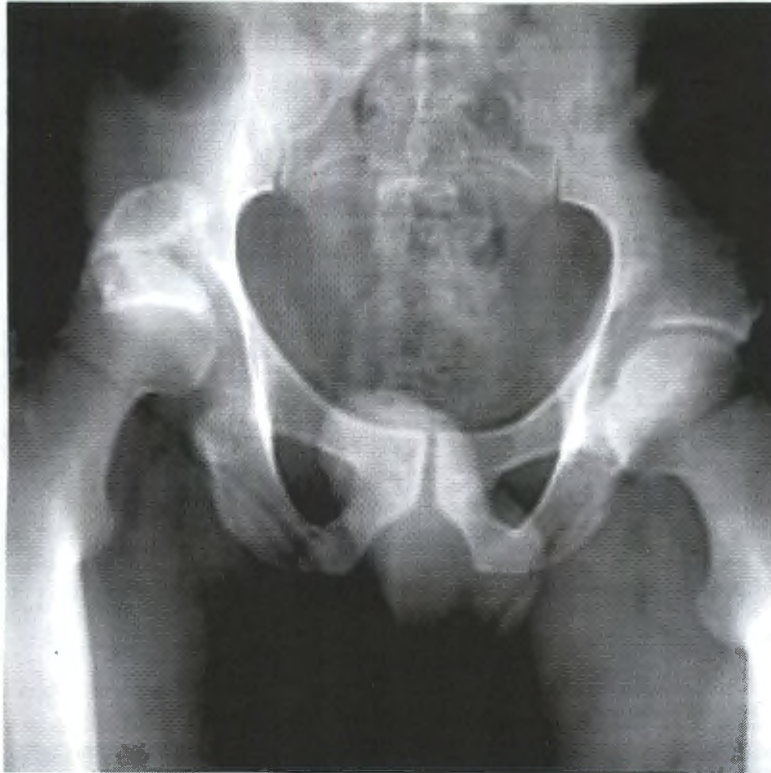
Although it was our impression that this was a helpful view we endeavoured to carry out a blind study that would "quantify" whether this view was in fact of additional value. Under the pretext that if any view enabled a more accurate classification of the fracture than the other views, it must be providing more information, we assessed the quantitative value of each radiological view according to our ability to accurately classify the fracture using that view.

For the purpose of this study the Thompson and Epstein classification (1951) was slightly adapted as follows:

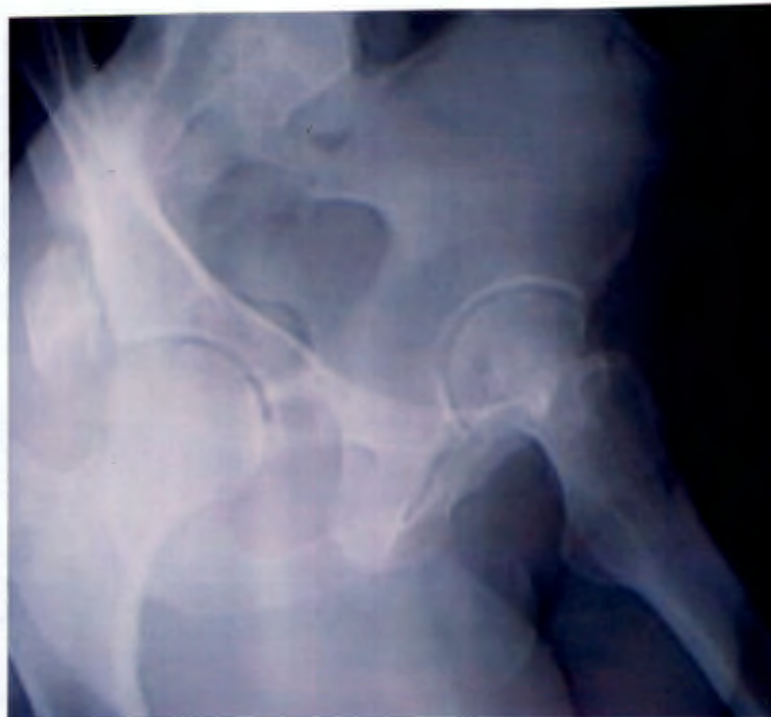- **Type II**                      The posterior wall fracture configuration consisted of one major fragment.
- **Type III**                     The posterior wall was comminuted with or without a dominant fragment.
- **Inconclusive**                The radiograph or CT did not provide enough information for us to make a confident prediction of the classification.

Cases with one large fragment with minor fracture "dust" were included as type II. The presence of associated acetabular floor fracture or femoral head fracture was ignored for the purpose of the comparison.

The entire series of AP views of the pelvis with the hip dislocated was scored in this way. Then the procedure was repeated for each of the other views. This meant that a full set of AP radiographs would be inspected and scrutinised before returning to the same patients radiograph. The radiological classification was then compared to the classification ascribed intra-operatively. In so doing it was possible to calculate how often the radiological classification had been correct.



**Fig.8** These are the radiographs of the first patient who presented with the “Serendipity OOD-view” taken before they reduced the hip. This AP-view demonstrates the fragments vertical displacement.



**Fig.9** The Obturator-oblique view taken in the traditional fashion after reduction, demonstrates the fragment partially reduced. The posterior wall however is obscured from a clear view by the reduced femoral head. A basic principle of Orthopaedics is to see every fracture on at least two views. We take an AP and a Judet view but often the fragments are obscured by over lying bone. By having the OOD-view this gives a second clear view of the fragments which move with the reduction. (see Fig.10)

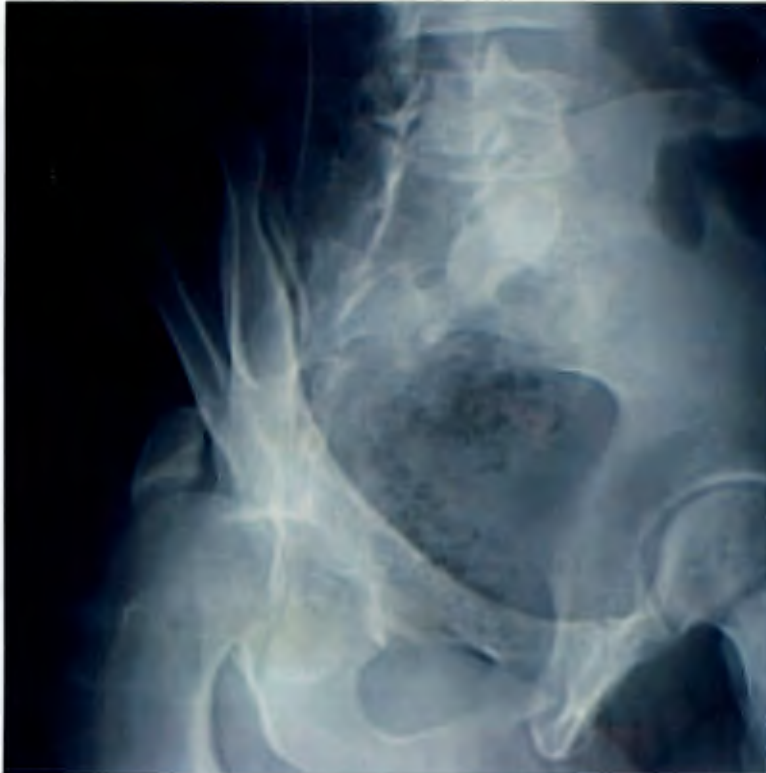

Fig. 10 The Serendipity OOD-view demonstrates the amount of initial displacement of the fragment. By seeing two views of the fragment we also have a better appreciation of its size and shape. The location of the defect in the posterior wall is well demonstrated in the dislocated view but obscured in the reduced view. The uninitiated might be inclined to treat this injury conservatively based on the reduced view but with an appreciation of how much the fragment has moved it becomes obvious that this intra-articular fracture could not be adequately reduced and surgery is essential.

See also the incomplete fracture of the remaining posterior wall lying anterior to the dislocated femoral head. These fragments will be "swept" into the acetabulum when hip is reduced closed. The true size of the defect is bigger than the apparently smaller superiorly displaced posterior wall which is viewed end on. (See also Figs 11 &12)

## Results

When we inspected the entire series (75 patients) AP views of the pelvis with the hip dislocated, this provided information for accurate classification 46% of the time. The information was not adequate to classify 46% of the time and the incorrect classification was ascribed the remaining 8%. The AP view after the hip was reduced produced similar results of 44%, 39% and 17% respectively. The Judet obturator-oblique view of the reduced hip;- correct 50%, inconclusive 28% and incorrect 22 %.

When we looked at just the thirty-two cases that had a full set of radiographs, the findings although altered were very similar. The obturator–oblique view taken with the hip dislocated produced markedly different results however.

### Results of 32 cases with full set of radiographs

	Inconclusive	Incorrect	Correct
<b>1. AP pelvis <u>dislocated</u></b>	44%	6%	50%
<b>2. AP pelvis reduced</b>	41%	16%	43%
<b>3. Obturator-oblique reduced (OOR-view)</b>	22%	22%	56%
<b>4. Iliac-oblique reduced</b>	97%	3%	0%
<b>Obturator-oblique <u>dislocated</u> (OOD-view)</b>	10%	6%	84%
<b>Iliac-oblique <u>dislocated</u></b>	72%	3%	25%
<b>Combination of 1- 4 traditional views</b>	18%	16%	66%
<b>Combination of 6 views</b>	9%	3%	88%
<b>CT series</b>	13%	6%	81%
<b>Combination of 4 radiographs and CT.</b>	6%	10%	84%
<b>Combination of 6 radiographs and CT</b>	6%	0%	94%

CT scans demonstrated intra-articular fragments in 20.3% of our cases and articular marginal impaction in 27.1% of our cases.

#### 4.4 Discussion

Shirkoda *et al* (1980) and Ordway and Xeller (1984) emphasised the ability of CT to identify impaction of the acetabulum and femoral head as well as to exclude the presence of fragments in the joint. Hougaard and Nielsen (1987) concluded that CT information altered both their classification and treatment of the fracture. Ebrahim *et al* (1993) pointed out that 3-D CT lacks the resolution necessary for detecting and evaluating the small intra-articular fragments and Baird (1982) demonstrated that fragments smaller than 3mm in size would not cause joint space widening on simple radiographs.

Frick and Sims (1995) reviewed 136 cases that had CT scan after posterior dislocations. Of the twenty-three cases that had no associated fracture no CT scan identified additional significant pathology. They concluded that CT is not necessary after simple posterior dislocation. Laorr *et al* (1995) (who performed MRI on eighteen patients) concluded that MRI has a very limited role in this injury.

In our experience we have found that the CT scan while unparalleled in its ability to demonstrate fragments in the joint and marginal impaction, often gives the impression of more comminution than we have found at surgery. The OOD-view helps to simplify our understanding and augments the information available on CT.

We have found the following features about the OOD-view to make it especially helpful in consolidating our understanding of the fracture configuration;

- 1) You have an uninterrupted view of the posterior wall and can accurately visualise the fracture configuration. Intra-operatively what we found was most representatively demonstrated in the OOD-view.
- 2) You can more accurately appreciate the size of the dominant fragment by correlating the fragment with the defect in the posterior wall.
- 3) You can most accurately appreciate the location of the defect in the posterior wall. We have had two Type I (simple dislocations) that were referred to us because they re-dislocated after primary reduction. In both a very small fragment was avulsed off the superior aspect of the posterior wall. It may be that type I injuries with a small defect in this area require surgery or longer immobilisation. Only the OOD-view permitted adequate appreciation of this defect.
- 4) If an undisplaced fracture of the posterior wall is present as visualised on the OOD-view then a primary open reduction should be carried out so as to prevent knocking the fragments off into the joint. (See Fig 10)
- 5) The number of fragments evident on the OOD-view can be compared to the number of fragments in the post-reduction view and give clues to the possibility of fragments in the

joint. CT can miss fragments in the joint and also often exaggerates the degree of comminution of the fragments.

- 6) Some surgeons may view a post reduction view and believe that a fragment is well reduced and can be treated conservatively. By being able to visualise the amount of displacement of the posterior wall on the OOD-view this will serve to give them insight into how much the fragment has moved and how unlikely it is that it has reduced anatomically. (See Fig 10)

#### **4.5 Conclusion**

This attempt to quantify the value of the obturator-oblique dislocated view by "measuring" its ability to accurately classify the fractures adds support to the qualitative value of this view as described above.

The iliac-oblique view has limited value in the assessment of the posterior wall. With the hip dislocated the femoral head often obstructs the posterior wall. It does still have value for visualising associated acetabular floor fractures. Pre-reduction obturator-oblique views by contrast provide significant additional information about the posterior wall and it is recommended that this view should be carried out as a matter of routine whenever possible.

The radiographers in the Groote Schuur trauma unit are primed to carry out obturator-oblique views whenever a dislocation is evident on the AP view. By tilting the X-ray beam rather than the patient this results in little delay or discomfort for the patient.

Routine CT is performed on all patients in whom any element of fracture of the posterior wall is identified, as CT is unparalleled in detecting marginal impaction and intra-articular fragments.

The key to accurate assessment however lies in a meticulous scrutiny of the full series of radiographs (including two AP views of the pelvis, two reduced Judet views and an obturator-oblique with the hip dislocated) that are then augmented by the CT imaging series.

Because of the expense of CT we would still like to answer the question as to whether CT is indicated in pure dislocations. The uninterrupted view of the empty acetabulum provided by the dislocated obturator-oblique view should enable us to accurately say whether a fracture is present or not. An ongoing prospective comparison will hopefully answer this question.

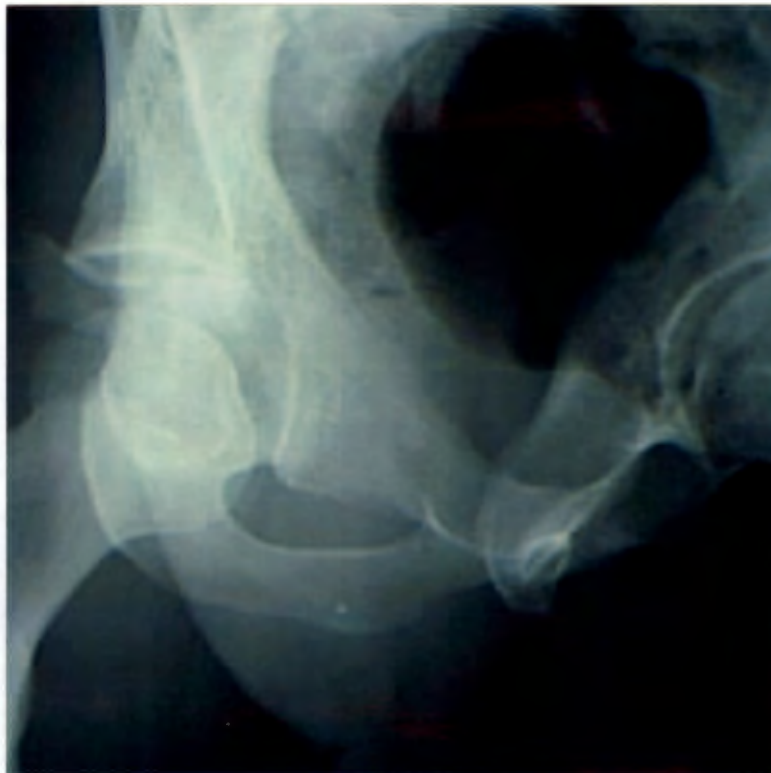
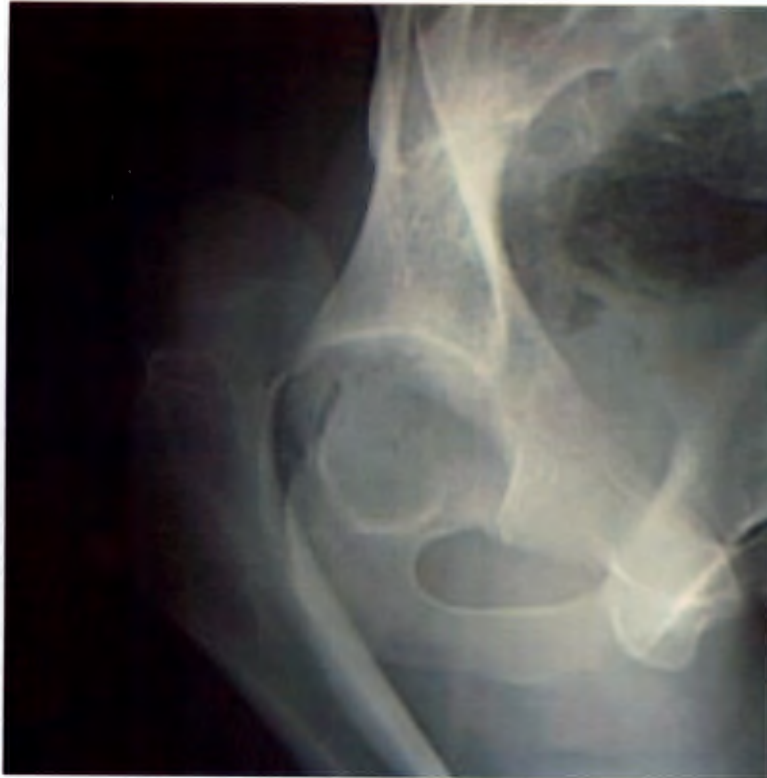
Fig.11 and Fig.12 This OOD-view demonstrates an undisplaced but fractured posterior wall. The post-reduction view demonstrates fragments within the joint. Based on the OOD-view a primary open reduction could have spared displacement of this fracture making anatomical "reconstruction" more accurate as well as protecting the scuffing of the articular cartilage which results from dragging these fragments across the articular surface.

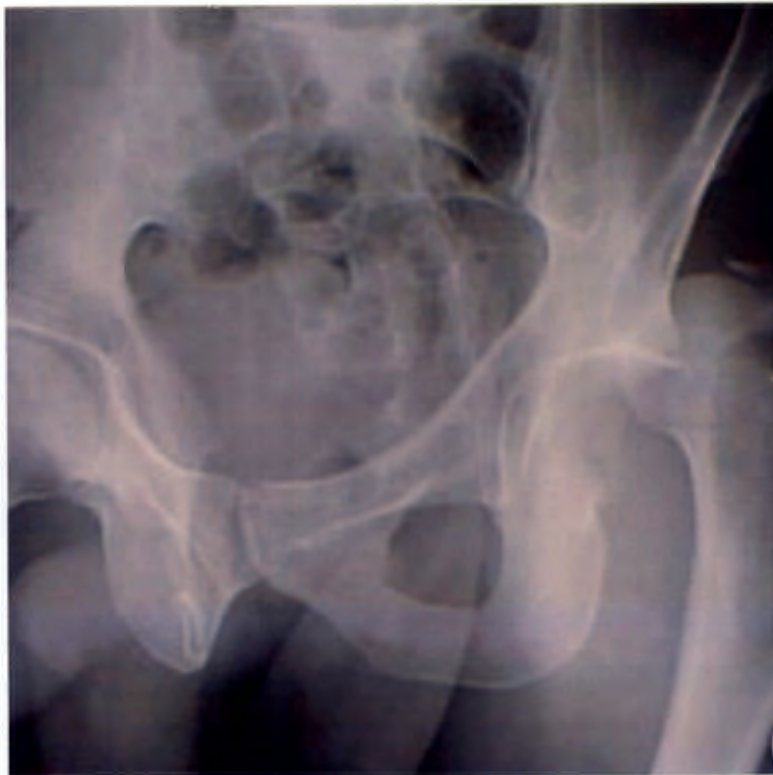
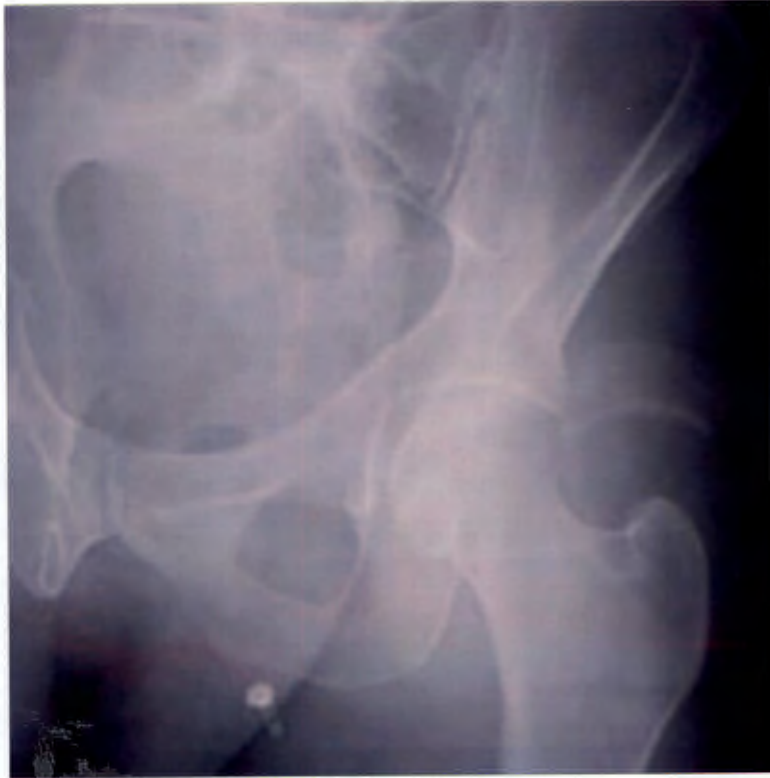
Fig.13 and Fig.14 In these two views you can see the advantage of seeing the uninterrupted posterior wall in the OOD which is obscured by the reduced femoral head in the OOR. Although the OOD view does not show the fragment well, it shows clearly the size, shape and location of the defect. The two views clearly augment each other

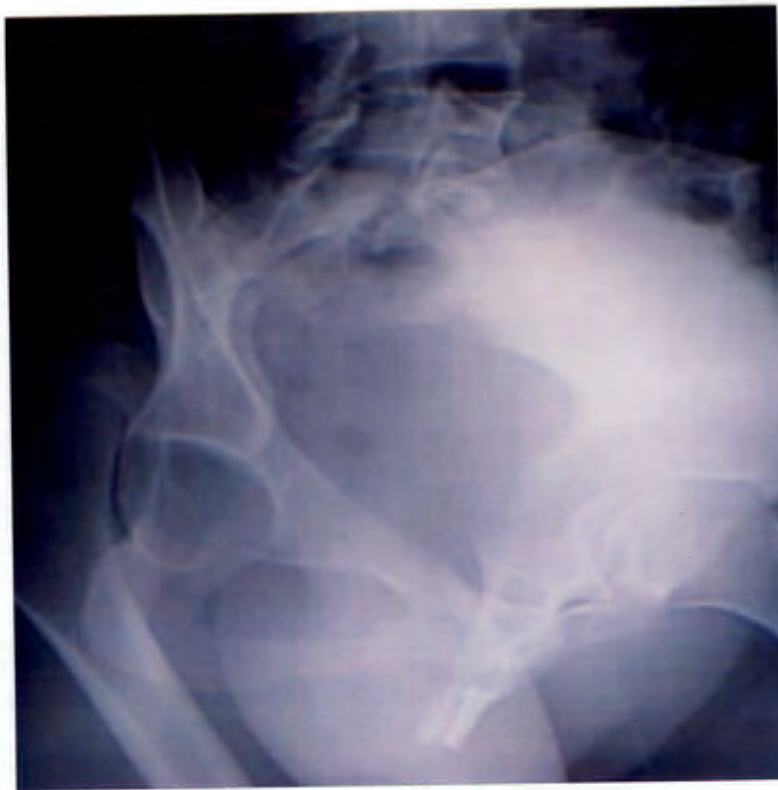

Fig.15 The majority of our cases are taken with the x-ray beam been tilted 45°. The view is somewhat distorted showing oval obturator foramen but demonstrates the uninterrupted view of the posterior wall. In Fig.16 the OOD-view with the patient tilted demonstrates the normal shaped obturator foramen. Unfortunately despite the effort of tilting the patient the quality of this particular radiograph is poor.

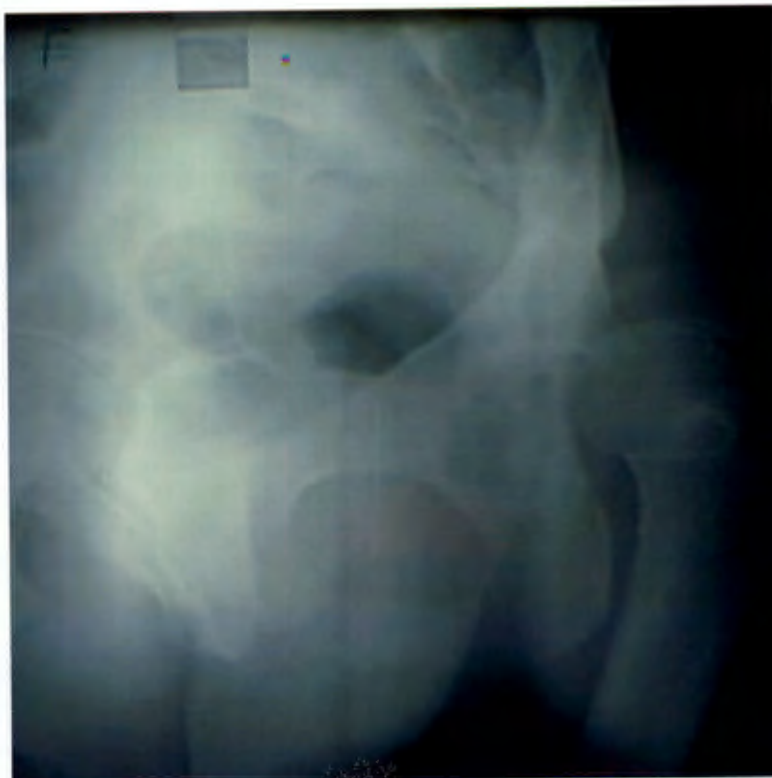
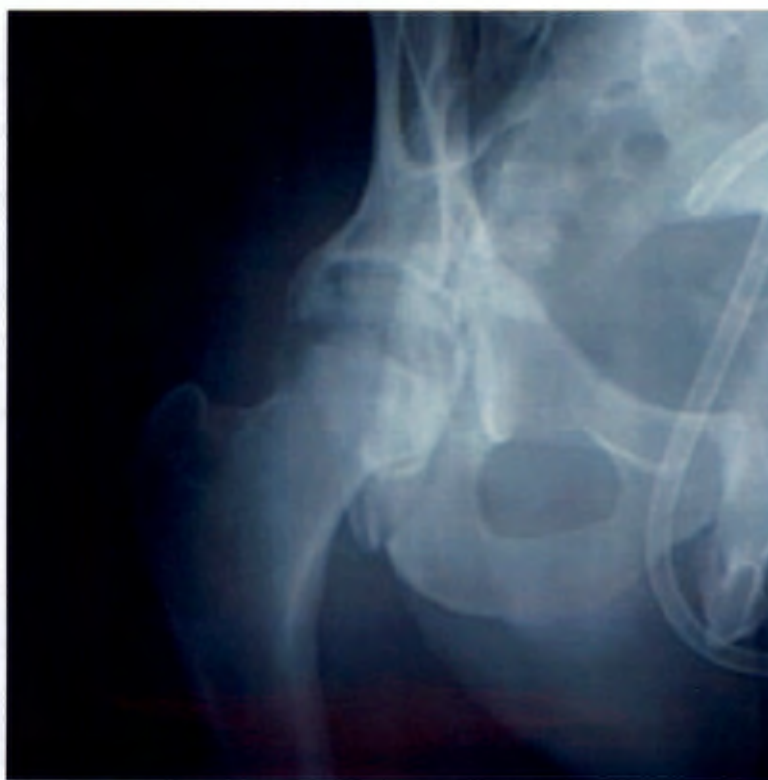
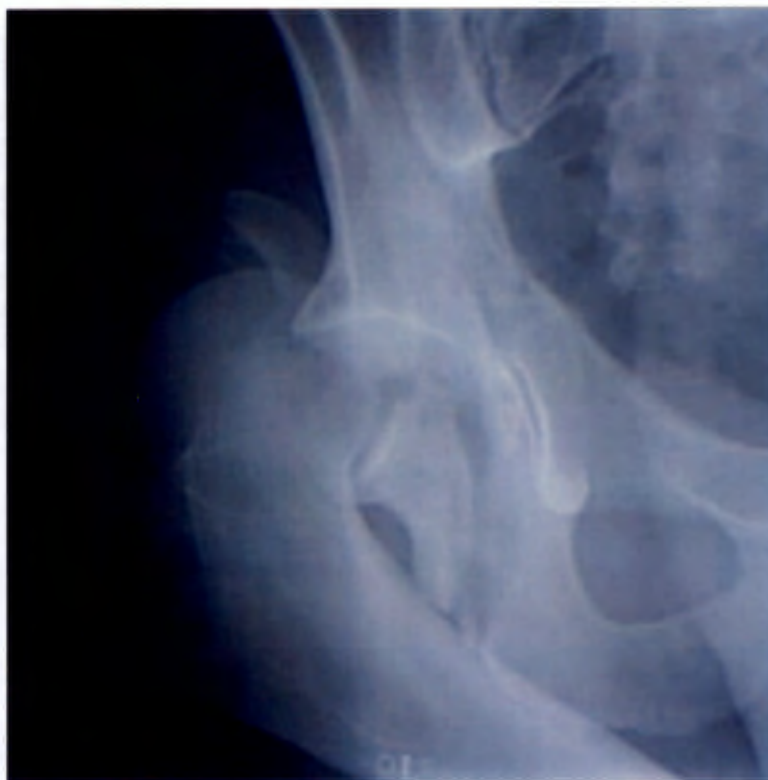Fig. 16 and Fig 17 In these two views of the same patient the OOD-view demonstrates the two large fragments as well as the defect in the posterior wall. The OOReduced-view is less informative and it is very difficult to appreciate the degree of displacement of the fragments, so well demonstrated on the OOD-view



## **5. The Mechanism of Injury in Posterior Fracture-dislocation of the Hip Joint**

### **5.1 Introduction**

The first description of the mechanism of this injury in the literature according to Griswold and Herd (1929) was extreme abduction with the femur acting as a lever arm and forcing the femoral head out through the inferior capsule. The musculature evidently then “located” the head in the typical posterior position.

With the advent of motor vehicles this injury became more common and it became more obvious that this injury was not from abduction but more likely from a blow over the knee in a flexed hip. Funstel *et al* (1938) reported on thirteen cases that sustained what he termed “Dashboard dislocation of the hip”.

Urist (1948) published a series collected from US army personal that were mostly involved in jeep accidents. Armstrong (1952) who collected cases from RAF hospitals found that more than half of his cases occurred after plane accidents. (Two of his patients were subsequently killed in active duty.)

Stewart (1953) first observed a difference between the type of injury sustained by the driver of a vehicle and the passenger. He observed that “the driver of a an automobile who sustains a posterior dislocation usually has a more severe injury than a passenger. Because of the difference in hip position between the two occupants, the driver sustains a postero-superior injury and the passenger with a more flexed hip has less damage.” A report by Grattan and Hobs (1967) concluded that it was less the degree of abduction than flexion, which contributed to a hip fracture-dislocation.

Epstein (1980) makes the point that in a hip that sustains an abducting force, an anterior dislocation is more likely. This is in complete contrast to the original description by Griswold and Herd. Extensive descriptions of the mechanics of acetabular fractures by Judet (1992) showed that a loading force applied to a flexed hip in neutral will most likely result in a posterior hip dislocation with an associated simple posterior wall fracture. When the hip is adducted the direction of maximal force is lateral to the posterior wall and a pure dislocation is more likely to occur. As the leg is abducted from neutral the point of maximum impact is “mapped out” medially in an arc across the acetabulum. (Epstein referred to this part of the acetabulum as the “floor” of the acetabulum.)

The abducted hip is therefore likely to sustain in addition to the posterior wall fracture, an associated acetabular floor fracture. Once the abduction exceeds 60° the force is the same as for a blow over the trochanter with the hip in neutral, and the likelihood of a posterior dislocation almost nil.

## 5.2 Method of Research

In our series, the fracture patterns were classified at surgery with specific reference to the posterior wall, based upon the Thompson Epstein classification. There were no type I injuries in the series as surgery is only performed on cases that are considered to have significant posterior wall fractures. (Two cases with type I injuries that were mentioned under the section on radiographic views were not included in this series)

**Type II** One fragment off the posterior wall or one dominant fragment in the presence of very minor comminution.

**Type III** Comminution of the posterior wall or more than one dominant fragment.

### **Type IV and Type V**

This group was ascribed type II or III according to the state of the posterior wall. The presence and location of an associated floor fracture was noted for comparison.

## 5.3 Results

Of the seventy-five cases, only one patient sustained an injury in a motor bike accident (1.3%). Nine pedestrians sustained this injury (12%). Sixty patients were occupants of motor vehicles (80%). Thirty-three patients were drivers of vehicles and twenty-seven were passengers. One patient sustained bilateral injuries and fifty (66.7%) sustained their injury in the right hip. The patient who sustained bilateral injuries was a driver when he sustained his first injury and a passenger when he sustained his second injury. He sustained a type II fracture in both accidents.

Regarding the thirty-three drivers;

Twenty-three sustained a type III fracture. (69.7%)

Twenty-five sustained their injury on the right hand side. (75.8%)

Of the twenty-three grade III injuries eighteen occurred on the right side. (78.26%)

Of the ten grade II injuries five were on the right hand side. (50%)

Regarding the twenty-seven passengers;

Nineteen of the twenty-seven sustained a type II fracture. (70.4%)

The remaining eight passengers sustained a type III fracture. (29.6%)

Six of eight grade III injuries occurred on the right hand side. (75%)

Nine of nineteen grade II injuries occurred on the right side. (47.4 %)

Thirty-one type III injuries occurred in motor vehicle occupants. Twenty-four of these occurred on the right side.(77.4%) Twenty-nine type II injuries occurred. Fourteen of these occurred on the right side. (48.2%)

Twelve patients sustained an associated acetabular floor fracture. Three infra tectal fractures occurred (according to Letournel and Judet classification). All associated with type II injuries. Four juxta-tectal fractures occurred; three of them associated with type III fractures. The remaining five all had associated trans-tectal fractures, two with a type II and three with a type III.

#### **5.4 Discussion**

The extended hip is a "more stable" hip than the flexed hip when exposed to a longitudinal force directed from the knee or from the foot back through the knee. A greater force is therefore required to dislocate the joint. This results in greater comminution in much the same way that a glass will chip off a fragment if knocked against the tap during washing, but shatter into many pieces when dropped to the floor.

The comminuted, type III injuries occurred predominantly on the right hand side. (77%) Of note is that of the drivers who sustained a type III injury 78% were right side but if they sustained a type II injury only 50% were right sided. Similarly, although this was a less frequent occurrence in the passengers, when they did sustain a type III injury 75% were right sided. The passengers who sustained the more common type II injury were right sided in only 47%. From this it would appear that the driver with their foot on the brake and their hip extended is at higher risk for a more comminuted injury, and so too the passenger bracing themselves for impact. If they simply sustain a blow on the knee with the hip flexed such that they sustain a type II injury then each hip is at equal risk.

In the meta-analysis that was performed an overall incidence of 2% of all dislocations occurs in pedestrians. The higher incidence in this series (12%) can be explained by the very biased sample that is treated at Groote Schuur. Roughly 70% of all road deaths in the Western Cape are pedestrians.

Two of the pedestrians were deliberately knocked down. They were struck from behind while running but at relatively low speed when compared to the average pedestrian that is a "motorway dasher". Both patients sustained a simple type II fracture-dislocation in keeping with a flexed hip. The direct blow from behind would correlate with the mechanism as described in mine workers who were trapped in cave-ins while on all fours. The force on the knee through the flexed hip was indirect as the pelvis is loaded from behind. The same applies to the patient who fell from a height and landed on all fours.

## **5.5 Conclusion**

There is a significant correlation between the mechanism of injury and the type of posterior acetabular wall fracture association with a posterior dislocation of the hip joint. The less stable flexed hip requires less force to dislocate than the more stable extended hip. Similarly the abducted hip will sustain a less sinister acetabular floor fracture when flexed than when extended.

The classic "dashboard injury" is in fact a description of only a small group of patients in this series. Had pure dislocations been included, there would most likely have been a greater number. The "brake-pedal injury" is more commonly a description for the driver (or the alert or nervous passenger) that sustains a fracture-dislocation with higher risk of comminution. At least three of the type III injuries had associated talus fractures (aviator's astragalus) in keeping with the "brake-pedal injury"

As with other intra-articular fractures, the more force involved in inflicting the injury, the greater the comminution and the greater the articular cartilage damage at impact. Both factors have significant implications for the onset of early osteoarthritis.

## **6. A Modification of the Thompson Epstein Classification**

### **6.1 Introduction**

Armstrong (1948) first classified posterior fracture-dislocations of the hip joint:

- Type I            Simple dislocation.
- Type II           Dislocation with fracture of the acetabular rim.
- Type III          Dislocation with fracture of the acetabular floor.
- Type IV          Dislocation with fracture of the femoral head.

Thompson and Epstein (1951) then described their classification:

- Type I            Dislocation with or without minor fracture.
- Type II           Dislocation with a large single fracture of the posterior acetabular rim.
- Type III          Dislocation with a comminuted fracture of the rim of the acetabulum with or without a major fragment.
- Type IV          Dislocation with fracture of the acetabular rim and floor
- Type V            With fracture of the femoral head.

Stewart and Milford (1954) three years later described a further classification.

- Type I            Simple dislocation without fracture or with a chip from the acetabulum so small as to be of no consequence.
- Type II           Dislocation with one or more large rim fragments, but with sufficient socket remaining to ensure stability after reduction.
- Type III          Explosive or blast fracture with disintegration of the rim of the acetabulum, which produces gross instability.
- Type IV          Dislocation with a fracture of the head or neck of the femur.

Levine (1992) suggests a classification based on radiological and CT findings.

- Type I            no significant associated fractures; no clinical instability following concentric reduction.
- Type II           Irreducible dislocation without significant femoral head or acetabular fractures. (Reduction must be attempted under GA)
- Type III          Unstable hip following reduction or incarcerated fragments of cartilage, labrum or bone.
- Type IV          Associated acetabular fracture requiring reconstruction to restore hip stability or joint congruity.
- Type V            Associated femoral head or femoral neck injury (fracture or impaction).

Armstrong treated all of his patients conservatively, and felt that his classification was a prognosticator. Epstein (1951) was sensitive to the relevance of comminution of the posterior wall. He modified Armstrong's' classification subdividing the group with posterior wall fracture into those with, and those without comminution. He was very aggressive in his management and aspired to achieving an anatomical reconstruction. When he subsequently reviewed two hundred and ninety-two patients in 1980 he noted a significant deterioration in the prognosis according to his classification.

In Stewart and Milford's classification there is not a natural progression from a type II injury ("with one or more large fragments") to type III injury ("explosive or blast fracture with disintegration of the rim of the acetabulum"). As a result the overriding factor in distinguishing type II from type III, is the presence or absence of stability.

Levine's classification has identified the sub group with small fragments that become incarcerated and require surgery for their removal. It would seem logical that this group would not fare as well as the group that does not need surgery. (In our series we had two cases with this injury and could not classify them easily into the Thompson Epstein classification). Besides this observation he incorporates all of Epstein's' type II, III and IV injuries into one group.

## **6.2 Method of Research**

All our cases in our series were classified at surgery using the Thompson Epstein Classification. Type IV injuries however were divided into type II "with associated fracture" and type III "with associated fracture" according to the state of the posterior wall. The location of the acetabular floor fracture was noted specifically at surgery. In addition the surgical outcome was recorded and classified according to whether an anatomical reconstruction was achieved.

Results of the surgical reconstruction were graded as:

Excellent	Perfect anatomical reconstruction achieved.
Good	Reconstruction achieved but either a small fragment was absent or a step less than 2mm was present.
Satisfactory	Step more than 2mm present or a significant area of articular cartilage lost due to comminution.
Poor	Unable to achieve anatomical reconstruction.

### **6.3 Results**

When we reviewed the series of sixty patients in 1998 there were thirty-two type II fractures and twenty-eight type III fractures. Six of the thirty-two type II fractures had associated acetabular floor fractures. Six of the twenty-eight type III fractures had associated acetabular floor fractures. Four cases had associated femoral head fractures, all in type III injuries.

50 cases (83%) achieved good or excellent results.

This included all 32 type II fractures and 18 type III fractures.

6 cases (10%) achieved satisfactory results.

These were all type III injuries and included 2 cases with associated femoral head fractures. Four had an associated transverse acetabular floor fracture.

4 cases (7%) achieved poor results.

All 4 cases were referred to GSH after more than 5 days. This included one referred after 58 days of dislocation. 2 of these cases had associated femoral head fractures.

### **6.4 Discussion**

As discussed in the previous section, Judet has shown that the presence of an acetabular floor fracture is simply a reflection of the amount of abduction of the hip joint. As the hip becomes more abducted or more extended so it is more stable with regard to dislocating posteriorly. If the hip is more stable then greater force is required to dislocate the hip. The greater force will impart more cartilage damage and more bony comminution. The advent of early osteoarthritis is dependent upon the primary and secondary injury. The primary injury is determined by the severity of the force inflicted on the hip and is largely a function of the position of the hip at impact. The surgeons' role is to prevent secondary injury. Early relocation will reduce the risk of developing AVN and secondary osteoarthritis. Reduction under GA and avoidance of re-dislocation intra-operatively can avoid secondary articular damage and anatomical reconstruction of a congruent joint will prevent abnormal cartilage wear.

A hip at 90° in neutral gets a simple posterior wall fracture. The same hip with some abduction has an associated floor fracture that is arced across the lower aspect of the acetabular floor. The extended hip in neutral sustains a comminuted posterior wall fracture, and the same hip in abduction; an associated floor fracture arced across the superior weight-bearing region of the acetabulum. The more comminuted fracture will therefore be associated with an acetabular fracture located more in the superior weight-bearing zone. Both of the injuries sustained with the hip flexed are less sinister than their counterparts that occur when the hip is more extended. Since the degree of comminution is a product of the force required to dislocate the hip, it serves as a "tumour marker" for the prognosis of this injury. It will correlate with the likelihood of successful reconstruction, the amount of articular damage and the location of the associated acetabular floor fracture with regard to the weight bearing area.

## 6.5 Conclusion

The degree of comminution in this series was the primary factor that determined the ability to achieve an anatomical reconstruction. The presence of a transverse fracture of the acetabular floor was less influential in this regard. In Epstein' review of his work (Baltimore 1980) he demonstrates a significant difference in prognosis of type II and III injuries. Yet these two groups of injuries are grouped together in a Thompson & Epstein type IV because of the presence of an associated floor fracture. A modification of the Thompson - Epstein is proposed, as being more relevant to the practice of acetabular surgeons who strive for anatomical reconstruction.

Type I A	Pure dislocation with or without minor fracture.
I B	Dislocation with minor fracture of posterior rim which becomes incarcerated during reduction and requires removal.
Type II A	Simple posterior wall fracture with no comminution or very small amount of fracture "dust" in the presence of a large fragment. (Making reconstruction straightforward and relatively easy).
Type II B	As above with an associated acetabular floor fracture (Usually infra- tectal or juxta-tectal).
Type III A	Dislocation with associated comminution of the posterior wall. With or without a major fragment.
Type III B	As above with an associated transverse fracture of the acetabulum (usually trans-tectal or juxta-tectal).
Type IV	Dislocation with an associated fracture of the femoral neck or head.

This classification has little bearing upon treatment except for the Grade IB that might require arthroscopy or arthrotomy for fragment removal depending upon the expertise of the surgeon. (Villar 1995; Keen 1994) All other fractures with significant fragments, which might have an influence on the likelihood of osteoarthritis development, should be reconstructed anatomically.

Because the degree of comminution is a direct result of forces involved, (with the implications for cartilage site and severity damage), this classification in prognosticating the likelihood of good anatomical reduction will have a direct correlation with long-term results. The validity of this must obviously expose itself to the scrutiny of our long-term follow up in subsequent reviews but we are encouraged by Pantazopoulos (1993) who found a significant correlation between those cases which had good surgical results and good long term outcomes.

## **7. The Relevance of Stability?**

### **7.1 Introduction**

In discussing the management of posterior fracture-dislocations of the hip joint many of the major texts aspire to the belief that if a hip is stable it does not require surgery. Campbell's Operative Orthopaedics states, "if reduction is satisfactory and the hip is stable, no surgery is indicated". Marvin Tile (1996) states that "for decision making on the desirability or otherwise of surgery one studies the stability and congruity of the hip joint" and goes on to say that "If the stability of the hip joint is uncertain, a general anaesthetic should be given and the hip put through a full range of motion." Jesse De Lee (1996) states that "open reduction is reserved for those patients in whom 1) closed reduction is not successful, 2) The reduction is unstable and 3) fracture fragments are trapped between the joint after reduction and Koval, Egol and Zuckerman (1996) make the statement: that "Hip stability should be assessed following either closed or open reduction."

In an extensive review of the literature the first reference to stability as it related to treatment was by Urist (1947) who states that the patients he treated conservatively were all stable. Dr Marcus Stewart (1952) stated that only if the hip was unstable was immobilisation necessary. He did not advocate surgery for unstable hips. Although Stewart and Milford's' (1954) classification distinguishes a type II from III by the presence or absence of stability they treated more than half of their unstable injuries conservatively.

Larson (1973) first formally advocated conservative treatment for stable hips and surgery for unstable. He described his test of stability as a force applied in a longitudinal direction along the shaft of the femur with the hip flexed 30° to 40°. Larson felt that if the hip re-dislocated then a sufficiently large fragment had been avulsed and should be fixed.

Epstein made little reference to stability since he strongly supported Urist's (1947) view of carrying out primary open reduction for all posterior fracture-dislocations. When he reviewed his series in 1980 and compared the long-term follow up, the group that were treated with primary open reduction had better results than the group reduced closed and then opened.

### **7.2 Method of Research**

In reviewing our first sixty cases, twenty-two were referred from elsewhere. Of the remaining thirty-eight patients, six were reduced under general anaesthetic and thirty-two under sedation in the Groote Schuur Trauma Unit. Orthopaedic Specialist Registrars were responsible for reducing all nine cases done under General Anaesthetic as well as twenty-three of the cases reduced under sedation. Trauma staff carried out the remaining nine reductions done under sedation. Because of a high demand on theatre time, most cases are reduced under sedation so as to avoid excessive delay in reduction.

After a radiological and CT assessment treatment was then decided upon. Indications for surgery included;

- Irreducible hip on two attempted closed reductions.
- A fragment or fragments within the joint after reduction.
- Marginal impaction as evident on CT scans.
- Fractures large enough to influence loading across the hip joint. (With subsequent increase in the risk of development of osteoarthritis)

All fractures, which had fragments large enough to justify surgery, were operated on. None of those cases that appeared to be well reduced on radiology, and could potentially have been managed conservatively, were anatomically reduced on exploration.

The records of patients reduced at Groote Schuur as well as the referral letters of patients referred were reviewed to determine how many had been assessed as unstable post-reduction by the referring surgeon. We did not carry out any tests of stability on the patients.

### **7.3 Results**

Thirty-five patients contained reference in their notes to the stability of the hip joint post reduction. Of the twenty-two referred patients ten referral letters made reference to stability and six of these cases were assessed as unstable post reduction.

Of the nine patients reduced by trauma unit registrars, five had made reference to testing for stability, but none were assessed as unstable. Of the twenty-seven cases reduced by Orthopaedic registrars, twenty had made references to testing for stability but only four were assessed as unstable.

Six of the registrars made reference to the Larson test and one described his test along the lines of Levine's recommended flexion to 90°. A further mentioned that they had put the patient through a full range of motion as described by Tile. None of the referrals from outside hospitals or the trauma unit made reference to their method of testing for stability.

Two Orthopaedic registrars stated that no test of stability was attempted for fear of re-dislocation and two others for fear of dislodging fragments that might become entrapped on second reduction. Three Orthopaedic registrars felt that the patients were in too severe discomfort to attempt a stability test.

Of the thirty-five cases that had documentation of stability testing only ten had demonstrated instability.(28.57%) All Sixty cases in the series were assessed as being appropriate for surgery pre-operatively and this was confirmed intra-operatively.

#### 7.4 Discussion

When Epstein (1980) compared the long-term results between those cases which were reduced closed and then opened for reconstruction versus those cases that were primarily opened, the later group did significantly better. The only significant difference in the treatment of the two groups was that the first group required re-dislocation and Epstein himself condemned the practice of re-dislocation. Based on his experience it would appear that the practice of re-dislocating every unstable hip by testing for stability could potentially result in a worse prognosis for the hip.

Both Keith et al (1988) and Vailas et al (1989) have attempted to predict stability according to the size of the posterior wall fragment. The maximum size for guaranteed stability determined as 20% and 25 % respectively and the minimum size for possible instability as 40% and 50 % respectively. Despite these claims there are cases described in the literature of recurrent dislocation after pure dislocations.

Olson (1996) carried out osteotomies of the posterior wall in cadaveric studies in progressive increments. He demonstrated that when a fragment of the outer 1/3 of an arc 50% of the posterior wall was removed, the percentage of loading through the superior dome was increased from a normal of 48% to 64%. When 2/3 was removed this increased to 71 % and to 77% when the entire arc was removed. Because the human hip consists of two incongruent surfaces, an arched acetabulum and a spherical femoral head, there is limited contact between the surfaces. As weight bearing increases plastic deformation of the articular cartilage transmits the weight bearing up the sides of the acetabulum to convert the two surfaces into congruency. As a result the outer rim of the acetabulum plays a very important role in weight bearing with lesser weights. This means that the changes in force transmission in the superior dome are not linear as the progressive osteotomies are performed. The smallest defect resulted in the largest relative change in articular weight bearing in the superior dome.

The smallest fragment (1/3 of 50%) is roughly 16% of the posterior wall. In both the studies by Keith and Vailas this would not have induced instability. The absence of instability therefore does not protect the hip against the development of premature osteoarthritis.

If the cases that had reference to stability are considered, 70% were assessed as being stable. If it is assumed that the cases that had no mention of instability were stable, then 83% of the cases operated on for significant posterior wall defects were assessed clinically as being stable post reduction. If stability were taken as the criteria for surgery, between 70% and 83% of cases that required surgery would not have received appropriate treatment.

Different surgeons, under different circumstances, using different techniques carried out these tests of stability. In many cases there is no documentation that any test of stability was carried out. The numbers of patients documented, as being unstable would appear to be nothing more than a rough estimate of the precise number. The correlation of this data is in itself a deliberate demonstration of the inconsistency of this test of stability. Since the literature itself cannot agree on a specific test it is unlikely that any two surgeons would conduct the same test of stability or indeed, that the same surgeon would consistently perform a test of stability appropriate to the weight and anatomy of each individual patient.

Of those patients that were referred a relatively high percentage were considered unstable by the referring doctors. This is of further concern because it is likely that patients who they assessed as being stable were treated conservatively and a significant number of cases that would benefit from surgery may not have been referred.

Epstein collated most of his data before the advent of CT scan. With CT scan it is now possible to accurately "visualise" the acetabulum without the need for further dislocation. With the use of a large bone hook placed over the greater trochanter it is possible to achieve sufficient distraction of the hip joint to remove fragments or elevate impaction without ever the need for re-dislocation. On those occasions where adequate distraction is not possible, the capsule can be released at the acetabular margin posteroinferiorly.

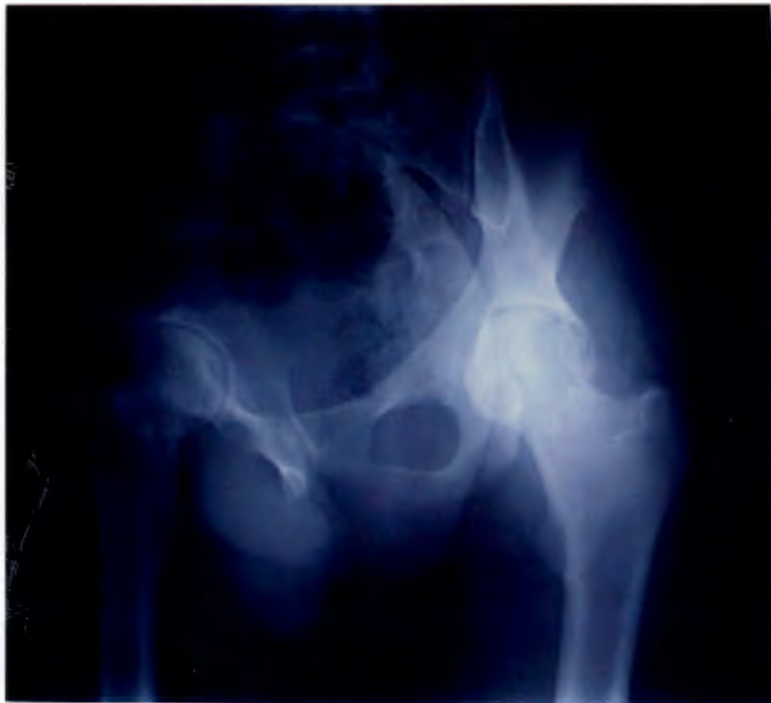## **7.5 Conclusion**

Urist in 1948 concluded, "fractures of the posterosuperior rim of the acetabulum should be repaired as carefully as any other fracture of a weight bearing joint." The AO foundation preaches the importance of rigid anatomical fixation of all intra-articular fractures. Despite the fact that most practising Orthopaedic surgeons have done a basic AO course, more than fifty years after Urist made this statement there is still the belief that provided a hip is stable after sustaining an intra-articular fracture it does not warrant surgical reconstruction.

Based on Epstein's findings that hips that were re-dislocated intra-operatively did worse than those that were not this practice is not desirable. Epstein himself condemned it. If a hip is stable this will not protect it from developing osteoarthritis and any fragment large enough to render the hip unstable is more than large enough to induce premature osteoarthrosis.

Surgical reconstruction of an acetabular fracture must prevent recurrent instability. However the decision to carry out surgery should not be made based on the stability of the joint, but on the fracture configuration. Is a test of stability carried out by the doctor who reduces the hip not a vague and inconsistent test, which potentially places the hip joint at risk of further damage and at the same time, bears little or no relevance to the selection of treatment?

Figure 19. This patient decided to mobilise himself earlier than we had planned. While he was awaiting CT scan he climbed out of bed and walked. He experienced no pain and sustained no further dislocation. CT showed a large bony defect off the posterior wall. At surgery we found this to have come off the posterior aspect of the wall avulsed by the posterior capsule much like a "bony Bankart lesion." Would this hip, which was stable on walking, have survived a Larsons stability test? Would a test of stability whether positive or negative have altered a decision to reconstruct the posterior wall?



## **8. Research Summary**

### **8.1 A Proposed Protocol for the Management of Hip Dislocations**

Epstein makes the point that because of the numbers involved it is difficult to make concrete decisions about best management protocols for posterior fracture-dislocations. He nevertheless aims to create a backbone on which to hang respective principles. This series of patients have not been followed up for extended periods as many of the previous authors have. Decisions must therefore be made based on the information available in the literature from the experience of others in conjunction with our own progressive experience. The management of acetabular fracture philosophy is changing. Much of the previous literature was relevant at a time when conservative treatment was the order of the day, and debate revolved around the length of time on traction. The main factor that the surgeon could influence was the period of dislocation and the emphasis was on rapid reduction and avoidance of AVN. Today however there is much literature to support the goal of achieving anatomical congruency in the hip joint. Many of the series that claimed good results after conservative treatment had short follow up, and only Upadhyay who followed his patients for an average of fourteen years noted that osteoarthritis continued to develop for many years. There is now also a greater awareness of the fact that many of the patients who were believed to be victims of AVN did in fact not have AVN but simply developed premature Osteoarthritis due to incongruent joint surfaces.

There are still centres that practice Epstein's planned primary open reduction for all patients. Most centres however will find it impossible to get patients to theatre for an open reduction within 6 hours of their injury. It is generally accepted that the immediate reduction of a dislocated hip is the major priority in reducing the likelihood of avascular necrosis or lasting nerve palsy. With this in mind, and considering that Epstein described this practice before the advent of CT, carrying out a closed reduction as soon as possible followed by a CT scan for all cases that demonstrate damage to the posterior wall is an acceptable practice.

At Groote Schuur Hospital, when a dislocated hip is diagnosed routine Judet oblique views are carried out before reduction. These have been a very helpful adjunct to the assessment of the state of the posterior wall. Post reduction, Judet Oblique views are taken in addition to the straight AP view. All cases that have any evidence of fracture of the posterior wall receive routine CT scans.

In those cases where patient discomfort or associated injuries make the Judet view dislocated impossible, reduction is not delayed by trying to perform these under general anaesthetic as suggested by De Lee. This would result in significant delay. Instead the X-ray beam is simply tilted 45° rather than the patient.

At Groote Schuur it is seldom possible to get a patient to theatre immediately, so reduction of the dislocated hip is most often carried out in the trauma unit under sedation. This is usually within two hours of presentation but the pre-hospital delay is extremely variable. Despite rapid intervention reduction within twelve hours of injury cannot always be guaranteed.

The technique for reduction employed is dependent largely upon the expertise of the treating surgeon, but this is usually with the patient supine and the surgeon on the trolley. After initial reduction patients are placed on skin traction only. This practice is subsequent to an experience where surgery was delayed due to a skeletal traction pin-tract infection.

The criteria, which we have arrived at for decision making with regard to carrying out surgery, are largely based on the experience of those that have passed before us and published their experience for us to benefit from. These include:

- 1) Inability to achieve closed reduction.
- 2) The presence of bony fragments within the joint. If a very small fragment is located in the cotyloid fossa it may be left alone. We have no experience in arthroscopy of the hip joint, but this would seem the logical approach to the presence of small isolated fragments within the joint.
- 3) The presence of any marginal impaction or acetabular depression fracture.
- 4) Any fracture which will technically allow for reconstruction of the posterior wall.

Criterion number (4) is one arrived at with experience but difficult to quantify. Since accurate reconstruction of the posterior wall is fundamental to reducing the risk of osteoarthritis, any fracture should be fixed if the fragment or fragments are 1) large enough to have an effect on the point loading through the hip and 2) large enough to be fixed with at least two screws or a buttress plate. Even in the presence of the severely comminuted fracture it is in the patients interest to have an attempt at anatomical reconstruction so as to facilitate later total hip replacement. Coventry (1974) described what he termed primary Total Hip for fracture-dislocation, but he carried out a two-stage procedure with reconstruction of the acetabulum as the first stage.

A decision to carry out surgery is not based on stability and a posterior stress test is not carried out. If a fragment were large enough to render the hip unstable, it would comfortably fall within the criteria for reconstruction of the posterior wall. Surgery for nerve injury alone has not been carried out. In all cases with nerve palsies there was a fracture significant enough in its own right to warrant surgery.

Postoperative traction is not used in our unit. Although those cases described in the literature which have developed recurrent dislocation in the absence of a fracture all share the common feature of not having been immobilised post reduction, we feel that

immobilisation with traction is ineffective and unnecessary. We had two patients in this series who both re-dislocated post surgery whilst receiving 20 pounds traction.

All patients receive Indomethacin from date of admission until six weeks post operation unless contra-indicated. The use of Indomethacin as a prophylaxis has long been recommended but as far as we know few authors advocate giving this drug prior to surgery. We have found this makes a significant difference to the risk of developing heterotrophic ossification as opposed to that given only post operatively.

All patients receive low molecular weight heparin Fragmin 5000 IU daily from admission until mobilised unless contra-indicated.

A Kocher-Langenbeck approach is employed with the patient positioned on the side. Fixation of fragments is usually by two or three screws directed towards the quadrilateral surface. A plate is used when the shape or comminution of the fragment does not permit simple screw fixation. Care is taken to preserve all soft tissue attachments to fragments and fragments too small to be replaced are painstakingly reconstructed to correlate with the visible defect in the articular surface in an attempt to reduce the risk of leaving any unaccounted for behind. The hip is then put through a range of movement and crepitus is both felt and listened for. Even in Epstein's' series there were four cases which had inadequate removal of fragments which required repeat surgery. When there is impaction of the articular surface, care is taken to elevate the depressed fragment against the femoral head and support the resulting defect with bone graft.

With regard cases that have re-dislocated post reconstruction because of severe comminution, a paper by Wayne Daum (1993) discusses the use of iliac crest autograft, used as a buttress to reconstruct the posterior wall. This has been attempted twice in this series and on three other occasions not included in this series. All five cases have failed within six months despite very encouraging intra-operative impressions. In our hands good results have not been encountered with this technique.

Most of our practices we have learned from previous surgeons experience as published in the literature. Certainly we do not intend to re-invent the wheel, but believe that in light of the fact that we have managed such a large number of patients in a relatively short period we can confidently comment on the relevance of certain practices. Each of our criteria for surgery have been described by other surgeons and added to the pool of criteria before us, but none have outlined their criteria as specifically. There remains a hazy group accumulated over the years but no one has attempted to tidy up the features as we have attempted to here. For example many have included features like nerve injury and all

include instability. We have deliberately omitted these two features from our criteria to emphasise the importance of criteria number (4).

I said at the beginning that the aim of this study was to gain a better understanding of this injury. Certainly the literature review has given us a greater insight into the thinking and attitudes of the surgeons who have managed this problem before us. It has also confirmed many of the practices that we already carry out as being consistent with the overall consensus, and has gone some way to explaining the origins of some of the practices that we feel are now obsolete.

I also said that we wanted to make new contributions to "the pool of knowledge". In this regard, I believe that we have been successful too. There are several practices that we do differently which are not mentioned in the literature by other authors. Some of these are minor, others more significant. Carrying out Obturator-oblique views with the hip still dislocated is one. Avoiding any testing of stability is another. Avoiding skeletal traction after surgery is a third.

Although recommended by many authors we initially did not use any Fragmin in treating acetabular fractures but had three massive on table pulmonary emboli in short succession. Subsequent to this bitter experience we now feel that the risk of postoperative haematoma is the lesser of the two evils and now use Fragmin routinely. The use of Indomethacin is well described and not something new that we have discovered. However administration of Indomethacin from onset of admission (rather than simply postoperatively) is something that is not previously addressed in the literature. In a study carried out by one of my colleagues this has been shown to be a significant factor in reducing heterotrophic ossification. This study is not included in my dissertation as it is not my work.

Contributing positively does not only involve making new discoveries. As Epstein pointed out the sample sizes are so small as to make any scientific conclusion impossible. The knowledge pool must be expanded by the experience of many surgeons each of them reinforcing or challenging the accepted beliefs and practices. In prescribing a new classification we hope to add a different slant to the perception of the problems encountered in managing these patients. In addition by consolidating a list of criteria for surgery I believe we have achieved our aim of providing a very definitive contribution to the pool of knowledge on this subject and have contributed positively to its future management.

## **9. References**

**Advanced Trauma Life Support Manual 1993** Fifth edition.

**Amihood S.** Posterior dislocation of the hip. Clinical observations and review of literature. S Afr. Med. J. 1974 May 18; 48(24): 1029-1032.

**Armstrong J R.** Traumatic dislocation of the hip joint. JBJS (Br) 1948; 34-B: 503-4.

**Baird RA et al.** Radiographic identification of loose bodies in the traumatised hip joint. Radiology 1982 Dec; 145(3): 661-665.

**Banks S W.** Aseptic necrosis of the femoral head following traumatic dislocation of the hip. JBJS 23, 753 Oct. 1941.

**Bircher Martin D.** 1997 Overseas correspondence.  
Consultant Orthopaedic Surgeon St. George's Hospital, Tooting, London.

**Brav E A.** Traumatic dislocation of the hip. Army experience and results over a twelve year experience. JBJS (Am) Sept 1962; 44-A: 1115-1134.

**Brumback R J, Holt E S, Mc Bride M S, Poka A, Bathon G H, Burgess A R.** Acetabular depression fracture accompanying posterior fracture-dislocation of the hip. J Orthop. Trauma 1990; 4(1): 42-48.

**Byrd J W, Pappas J N, Pedley M J.** Hip Arthroscopy: an anatomic study of portal placement and relationship to the extra-articular structures. Arthroscopy 1995 Aug;11(4): 418-423.

**Campbell, W C.** Posterior dislocation of the hip with fracture of the acetabulum. JBJS.18; 842-850, Oct 1936.

**Coventry M B.** The treatment of fracture-dislocation of the hip by total hip arthroplasty. JBJS (A) 1974 Sept; 56(6): 1128-1134.

**De Lee J C.** *Rockwood and Green's Fractures in Adults*. Volume 2. Fourth ed. Philadelphia, Lippincott-Raven, 1996; pp 1659 –1825.

**Ebraheim NA, et al.** Soft-tissue window to enhance visualisation of entrapped osteocartilagenous fragment in the hip joint. Orthop. Rev 1993 Sept; 22(9): 1017-1021.

**Edwards D J, Lomass D, Villar R N.** Diagnosis of the painful hip by magnetic resonance imaging and arthroscopy. *JBJS (Br)* 1995 May; 77(3): 374-376.

**Epstein H C.** Posterior fracture-dislocations of the hip; long term follow up. *JBJS (Am)* 1974 Sept; 56(6): 1103-1127.

**Epstein H C.** Traumatic Dislocation of the hip: Baltimore, Williams and Wilkins, 1980: Pp 17-41.

**Epstein H C, Wiss D A, Cozen L.** Posterior fracture-dislocation of the hip with fractures of the femoral head. *Clin. Orthop.* 1985 Dec; 201:9-17.

**Freeman Barney L.** *Campbell's Operative Orthopaedics*. Vol.3 seventh ed. St Louis, Mosby, 1987 pp 2129.

**Frick S L, Sims S H.** Is CT useful after simple posterior dislocations? *J Orthop. Trauma* 1995; 9(5): 388-391.

**Funsten R V, Kinser P, Frankel C J.** Dashboard dislocations of the hip: A report of twenty cases of traumatic dislocation. *JBJS* 1938; 20: 124-132.

**Grattan and Hobs J A.** Injuries to the hip joint in vehicle occupants. 1967; Road Research council.

**Griswold R A, Herd C R.** Dislocation of the hip with fracture of posterior rim of acetabulum. *J Indiana State Med.* ASSN 1929; 22: 150-153.

**Helal B, Skevis X.** Unrecognised dislocation of the hip in fractures of the femoral shaft. *JBJS (Br)* 1967 49B 293-300.

**Hougaard Kjeld, Lindequist S, Nielsen LB.** Computerised Tomography after Posterior-dislocation of the hip. *JBJS (Br)* 1987; 69B: 556-557.

**Hougaard Kjeld, Thomsen P B.** Coxarthrosis following traumatic posterior dislocation. *JBJS (Am)* 1987; 69A: 679-683.

**Hunter GA.** Posterior dislocations and fracture-dislocations of the hip. A review of 57 patients. *JBJS (Br)* 1969 Feb; 1-B; 51: 38-44.

**Jacob J R, Rao J P, Ciccarelli C.** Traumatic dislocation and fracture-dislocation of the hip. A long-term follow-up study. Clin. Orthop. 1987 Jan; 214: 249-263.

**Jaskulka R A, Fischer G, Fenzl G.** Dislocation and fracture-dislocation of the hip. JBJS (Br) 1991 May; 73(3): 465-469.

**Judet Professor Robert, Judet Dr Jean and Letournel Dr E.** Fractures of the Acetabulum: Classification and surgical Approaches for open reduction. JBJS (Am); Dec 1964: 46-48.

**Keene GS, Villar RN.** Arthroscopic loose body retrieval following traumatic hip dislocation. Injury 1994 Oct; 25(8): 507-510.

**Keith JE. et al.** Stability of posterior fracture-dislocations of the hip. Quantitative assessment using CT. JBJS (A) 1988 Jun; 70(5): 711-714.

**Koval Keith J, Igol Keith A, Zuckerman Joseph.** *Principles of Orthopaedic Practice.* Second ed. Mc Graw Hill 1997.

**Laorr A, et al.** Traumatic hip dislocation: early MRI findings. Skeletal Radiol. 1995 May; 24(4): 239-245.

**Larson C B.** Fracture-dislocations of the hip. Clin Orthop 1973 May; 92: 147-154.

**Letournel Emile, Judet Robert.** *Fractures of the acetabulum.* New York Springer Verlag, Second Edition, 1992.

**Letournel E.** Results of acetabular fractures treated surgically: 21 years experience. In: The hip proceedings of the 7th open Scientific Meeting of the Hip Society. St. Louis MO, CV Mosby, 1979.

**Levin Paul E.** *Skeletal Trauma: fractures, dislocations, ligamentous injuries.* Vol.2 second ed. Philadelphia, Saunders, 1998: pp 1713 – 1750.

**Marchetti M E, et al.** Intermediate-term experience of Pipkin fracture-dislocations of the hip. J Orthop Trauma 1996; 10(7): 455-461.

**Matta Joel M, Anderson Lowell M, Epstein Herman C, and Hendricks Pierre.** Fractures of the Acetabulum. A retrospective Analysis. Clin. Orthop; April 1986 Number 205; 230-250.

**Matta Joel M and Merrit Phillip O.** Displaced Acetabular fractures. Clin. Orthop; May 1988 number 230; 83-97.

**Nicol E A.** Traumatic dislocation of the hip joint. JBJS (Br) 1952; 34-B: 503-4.

**Olson S A et al.** The effect of variable size posterior wall acetabular fracture on contact characteristics of the hip joint. J Orthop. Trauma 1996; 10(6): 395-402.

**Ordway C B, Xeller C F.** Transverse Computerised axial Tomography of patients with posterior dislocation of the hip. J Trauma 1984; 24: 76-9.

**Pantazopoulos T, et al.** Surgical treatment of acetabular posterior wall fractures. Injury 1993 May; 24(5): 319-323.

**Paus B.** Traumatic dislocations of the hip joint. Acta Orthop. Scandinavica, 1951 21,99

**Pipkin, Garret.** Treatment of grade IV Fracture-Dislocations of the hip. A review. JBJS, 39-A: 1027 -1042, Oct 1957.

**Proctor H.** Dislocations of the hip joint (excluding "central" dislocations) and their complications. Injury 1973 Aug; 5(1): 1-12.

**Rashleigh-Belcher H J C, Cannon S R.** Recurrent dislocation of the hip with a "Bankart-type" lesion. JBJS (B) 1986 68B(3) 398-399.

**Reigstad A.** Traumatic dislocation of the hip. J Trauma 1980; 20: 603 – 606.

**Rosenthal R E, Coker W L.** Posterior fracture-dislocation of the hip: an epidemiological review. J Trauma 1979 Aug; 19(8): 572-581.

**Shirkoda, Ali Brashear.** Computed Tomography of acetabular fractures. Radiology 1980; 134: 683-688.

**Stewart M J, and Millford L W.** Fracture-dislocations of the hip and end result study. JBJS (Am) 1954; 36A: 315.

**Suraci A J.** Distribution and severity of injuries associated with hip dislocations secondary to motor vehicle accidents. J Trauma 26: 458 - 460, 1986.

**Thompson Vernon P, Epstein Herman C.** Traumatic dislocation of the hip. A survey of two hundred and four cases covering a period of twenty-one years. *JBJS* Vol. 33-A July 1951; 746-778.

**Tile Marvin.** *Rockwood and Green's Fractures in Adults*. Vol. 2, Fourth ed. Philadelphia: Lippincott-Raven, 1996.

**Upadhyay S S, Moulton A.** The long-term results of traumatic posterior-dislocation of the hip. *JBJS (Br)* 1981; 63B (4): 548-551.

**Urist M R.** Fracture-dislocations of the hip joint. *JBJS (Am)* 1948; 30-A: 699.

**Vailas J C, Hurwitz S, Wiesel S W.** Posterior acetabular fracture-dislocations: fragment size, joint capsule, and stability. *J Trauma* 1989 Nov; 29(11): 1494-1496.

**Villar Richard.** Hip Arthroscopy Editorial. *JBJS (B)* 1995 Jul; 77(4): 517-518.

**Watson - Jones Sir R.** *Fractures and joint injuries* 4th edition Vol. II p 664 1960.

**Whitehouse GH.** Radiological aspects of posterior-dislocation of the hip. *Clin. Radiol.* 1978 Jul; 29(4): 431-441.

**Wright R, et al.** Acetabular fractures: long term follow up of open reduction and internal fixation. *J Orthop. Trauma* 8: 397-403; 1994.

**Yue JJ, et al.** Posterior hip dislocations: a cadaveric angiographic study. *J Orthop. Trauma* 1996; 10(7): 447-454.